Bronchopulmonary Diseases

BASIC ASPECTS, DIAGNOSIS AND TREATMENT

by 142 authors

EDITED BY

EMIL A. NACLERIO, M.D.

Chief of the Thoracic Surgical Services,
Harlem and Columbus Hospitals, New York

FOREWORD BY

RICHARD H. OVERHOLT, M.D.

Director, Overholt Thoracic Clinic, Boston,
Clinical Professor of Surgery,
Tufts College Medical School

719 ILLUSTRATIONS

A HOEBER HARPER BOOK

BRONCHOPULMONARY DISEASES BASIC ASPECTS, DIAGNOSIS AND TREATMENT

Copyright © 1957, by Paul B Hoeber, Inc

Medical Book Department of Harper & Brothers

Library of Congress catalog card number 57-6023

All rights reserved

For information address PAUL B HOEBER, INC
Medical Book Department of Harper & Brothers,
49 East 33rd Street New York 16, N Y

Printed in the United States of America

To my inspirer and former chief
RICHARD H OVERHOLT, M D
and to other pioneers and indefatigable workers
in the field of thoracic disease

Contents

THE CONTRIBUTING AUTHORS xv

FOREWORD

by Richard H Overholt xviii

PREFACE xxv

I EMBRYOLOGY DEVELOPMENTAL ANOMALIES AND ANATOMY

1 Developmental Anomalies of Lungs — Eduard A Boyden 1

2 Segmental Bronchi and Bronchopulmonary Segments — Chevalier L Jackson 12

II PHYSIOLOGY AND PATHOLOGY

3 Functional Anatomy of Lung — Leroy D Vandam 17

4 Normal Physiology of Respiration — Arthur A Siebens 24

5 Pathologic Physiology of Respiration — Hurley L Motley 37

6 Hematologic Role of the Lung — Howard R Bierman 49

7 Pathogenetic Concepts — David M Spain 60

III DIAGNOSIS

8 Diagnostic Methods — Louis L Friedman 73

9 Bacterial Examination of Sputum — I D Bobrowitz 81

10 Lung Biopsy in Disseminated Pulmonary Disease — Henry P Close 89

11 Bronchoscopy — F Johnson Putney 93

IV ROENTGENOLOGY

12 Problems in Roentgen Differential Diagnosis — Noel F Bartone, R Vincent Grieco 99

13 Fluoroscopy — Charles B Storch 117

14 Radiographic Technics — Irving J Kane 128

15 Bronchography 143
Arthur J Cracoraner

16 Angiocardiography 147
Israel Steinberg

17 Reliability of Chest Radiography 163
J Yerushalmy

V HEART AND LUNG DISEASES

18 Clinical Differentiation between Pulmonary and Cardiac Disease 173
Simon Dack

19 Effect of Chronic Pulmonary Disease on the Heart 180
Maxwell L Gelfand

20 Pulmonary Diseases Secondary to Heart Diseases 187
Nathaniel E Reich

VI EDEMA AND HEMORRHAGE

21 Pulmonary Edema 200
F J Beattie

22 Pulmonary Hemorrhage 206
Edward F Parker

VII EMBOLISM INFARCTION AND THROMBOSIS

23 Pulmonary Embolism and Infarction 209
Irving S Wright
William T Foley

24 Thrombosis of Pulmonary Arteries 217
D R Keating

VIII UPPER RESPIRATORY TRACT AND PULMONARY DISEASE

25 Relation of the Nose and Throat to Pulmonary Diseases 223
Arthur J Cracoraner

IX COUGH

26 Cough Its Pathology and Management 226
A Worth Hobby

X BRONCHITIS BRONCHOLITHIASIS AND BRONCHIAL FISTULA

27 Bronchitis 233
Coleman B Rabin

28 Broncholithiasis 241
Coleman B Rabin

29 Bronchial Fistulas 246
J Winthrop Peabody Jr
Sol Katz
Edgar W Davis

XI ALLERGY

30 Allergic Manifestations in the Respiratory Tract 251
Joseph Harkavy

XII PULMONARY MANIFESTATIONS OF SYSTEMIC DISEASES

31 Blood Dyscrasias and Metabolic Disorders — *Richard R Ferayorni* 269

32 Collagen Diseases — *L H Garland, M A Sisson* 273

33 Sarcoidosis — *Louis E Siltzbach* 28-

34 Pulmonary Manifestations of Infectious Diseases — *Maxwell L Gelfand* 300

XIII CONGENITAL DISEASES

35 Agenesis of the Lung — *Emil A Naclerio* 309

36 Atelectasis in the Newborn—A New Treatment — *Emil A Naclerio* 314

37 Pulmonary Arteriovenous Aneurysm — *Jan H Muri* 321

XIV HERNIA (PNEUMONOCELE) OF THE LUNG

38 Hernia of Lung — *Emil A Naclerio* 328

XV THE PNEUMONIAS

39 The Pneumonias — *Paul A Bunn, G L Eastman* 333

40 Chemotherapy in Acute Pneumonias — *Paul A Bunn* 336

41 Lipoid Pneumonia—Diagnosis — *Bruno W Volk, Samuel Losner, Alexander Leuritan, Louis Nathanson* 346

XVI EMPHYSEMA

42 Chronic Pulmonary Emphysema — *Maurice S Segal* 354

43 Application of Pressure Including Exsufflation, in Pulmonary Emphysema — *Alvin L Barach* 362

44 Rationale of Pneumoperitoneum — *Andrew L Banyai* 373

XVII PNEUMOCONIOSIS

45 Pathogenesis and Management of Pneumoconiosis — *Arthur J Vorwald* 377

46 Silicosis and Asbestosis — *O A Sander* 385

47 Beryllium Poisoning (Berylliosis) — *H E Tebrock* 390

CONTENTS

XVIII PULMONARY MYCOSES

48 Mycotic Infections — 393
Arthur Q Penta

49 Histoplasmosis — 408
Thomas F Puckett

50 Surgical Considerations in Coccidioidomycosis — 417
Bert H Cotton
George A Paulsen
J W Birsner

XIX PARASITIC DISEASES

51 Animal Parasitic Infections — 423
Rodney C Jung

52 Hydatid Cysts — 430
Louis R Davidson

XX FOREIGN BODIES

53 Foreign Bodies in the Bronchopulmonary Tract — 442
Walter H Maloney

XXI ATELECTASIS

54 Acquired Atelectasis and Massive Pulmonary Collapse — 447
Emil A Naclerio

XXII POSTOPERATIVE PULMONARY COMPLICATIONS

55 Postoperative Pulmonary Complications — 451
Robert M Janes

XXIII FUNDAMENTAL CONSIDERATIONS IN PULMONARY SURGERY

56 Indications for Pulmonary Resection — 548
Emil A Naclerio

57 Autonomic Nerve Surgery in Pulmonary Disease — 466
Osler A Abbott

58 Anesthesiology — 477
John W Pender
John S Lundy

59 Operative Positions and Approaches — 486
Emil A Naclerio

60 Open Thorax Procedures — 493
J Maxwell Chamberlain

61 Cardiac Arrest during Pulmonary Resection — 498
Julian Johnson
Charles K Kirby

62 Complications Following Pulmonary Surgery — 506
O C Brantigan
C S Hadidian

63 Rehabilitation — 515
Albert Haas
Howard A Rusk

XXIV PULMONARY TUBERCULOSIS

64 Diagnosis and Treatment — 320
Roger S Mitchell

65 Antimicrobial Agents — 326
Nicholas D D Esopo

66 Tuberculosis As Affected by Antibiotics — 336
Oscar Auerbach

67 Fatal Pulmonary Hemorrhage in Tuberculosis — 346
J Robert Thompson

68 Indications for Treatment in Children — 354 ✓
Edith M Lincoln

69 Surgical Treatment — 358
Norman J Wilson
Orlando Armada
William B O Brien
William V Vindzberg

70 Resection in Children and Adolescents — 368
Morris Rubin

71 Segmental Resection — 382
J Maxwell Chamberlain

72 Pneumotherapy — 391
James H Cullen

XXV BRONCHIECTASIS ABSCESS AND CYSTIC DISEASES

73 Bronchiectasis — 396
Francis M Woods

74 Bronchiectasis in the Older Patient — 603
Helen S Pittman

75 Lung Abscess—Medical Aspects — 618
S Aubrey Gittens
John P Mihaly

76 Lung Abscess—a Medicosurgical Problem — 617
David H Waterman
Sheldon F Domm
William K Rogers

77 Air Space Abnormalities — 624
Israel Rappaport
Edgar Mayer

78 Pulmonary Tension Disorders in Infants and Children — 316 ✓
John A Campbell

79 Cystic Disease with Emphasis on Emphysematous Blebs and Bullae — 641 ✓
Jerome R Head

80 Pulmonary Air Cysts—A Therapeutic Concept — 645 ✓
David J Dugan
Kenneth L Hardy

81 Infected Cystic Disease — 654 ✓
Richard H Meade

82 Intralobar Bronchopulmonary Sequestration — 657
Andre J Bruwer

XXVI TUMORS—BENIGN, MALIGNANT AND METASTATIC

83 Benign Tumors 664
Leu A Hochberg
Bernard Schacter

84 Hamartoma 678
Joseph Stein
Maxwell H Poppel

85 Preclinical Bronchogenic Carcinoma 686
Katherine R Boucot

86 Cytology 691
John R McDonald

87 Bronchogenic Carcinoma 694
Foster Murray

88 Roentgen Manifestations of Carcinoma 699
Max Ritro

89 Detection, Selection and Resection in Pulmonary Carcinoma 703
Richard H Overholt
James A Bougas

90 Radical Surgery for Carcinoma 712
John H Gibbon, Jr
T. Lane Stokes
John J McKeown, Jr

91 Lung Cancer Associated with Cancer Primary in Other Sites 722
William G Caban

92 Bronchiolar Carcinoma 735
Clifford F Storey

93 Metastatic Tumors 746
Emil A Naclerio

94 Sarcoma 752
Theodore H Noebren

95 Lymphomatoid Lesions 755
A Rottino
G Hoffman

96 Treatment of Inoperable Cancer, Primary and Metastatic 761
David A Karnofsky
W P Laird Myers
Ralph Phillips

97 Radioisotope Therapy 773
B Rosvit

XXVII "COIN" LESIONS AND SOLITARY TUMORS

98 "Coin" Lesions—Medical and Pathologic Aspects 783
Harold Guyon Trimble

99 Solitary Circumscribed Lesions—Diagnosis and Management 792
Corrin H Hodgson

100 The Solitary Pulmonary Nodule 797
Edgar W Davis
Sol Katz
J Winthrop Peabody, Jr

101 Importance of Surgery in the Management of Coin Lesions — William M Tuttle, Raymond J Barrett, J H Hertzler — 803

XXVIII TRAUMATIC CHEMICAL AND RADIATION INJURY

102 Injury to Lung — Aubre de L Maynard, Emil A Naclerio, John W V Cordice, Jr — 806

XXIX PLEUROPULMONARY DISEASES

103 Diseases of the Pleura — Louis L Friedman — 817

104 Spontaneous Pneumothorax—Clinical Diagnosis and Management — Donald S Tysinger, Jr, George R Meneely — 837

105 Spontaneous Pneumothorax—With Emphasis on Treatment — John N Briggs, Francis V Byron — 841

106 Surgical Considerations in Decortication — Paul C Samson — 845

107 Pleuropulmonary Resection—Excision of Chronic Empyema — Irving Arthur Sarot — 853

XXX PRESERVATION OF LUNG TISSUE

108 Surgery of the Bronchi and Trachea — Lyman A Brewer, III, Angel F Bai — 863

109 Bronchoplastic Procedures — Donald L Paulson, Robert R Shau — 879

XXXI FUNDAMENTAL CONSIDERATIONS IN MANAGEMENT

110 Impaired Respiratory Function — James L Whittenberger — 888

111 Inhalational Therapy — Maurice S Segal, Ernst Attinger — 893

112 Corticotrophin and Corticosteroids — Maurice S Segal, J A Herschfus, A Salomon — 908

113 Anesthetic Management of Patients with Altered Pulmonary Function — Joseph G Giuffrida, Dante Bizzarri — 921

114 Tracheotomy — Mark H Williams — 928

115 Selection and Management of Patients for Air Travel — Burgess Gordon — 935

The Contributing Authors

OSLER A ABBOTT M D, F A C S F C C P F A C C
Assistant Professor of Surgery and Chief of Division of Thoracic Surgery Emory University School of Medicine and Emory University Clinic Chief of Thoracic Surgery Emory University Hospital Emory University Ga and Henrietta Eggleston Hospital for Children Atlanta Ga

ORLANDO ARMADA M D F C C P
Assistant Chief Communicable Disease Service Brooke Army Hospital Fort Sam Houston Tex

ERNST ATTINGER M D
Assistant Professor of Medicine Tufts University School of Medicine Assistant in Medicine Lung Station (Tufts) and Department of Inhalation Therapy Boston City Hospital Boston Mass

OSCAR AUERBACH M D F A C P F C A P F C C P
Chief Laboratory Service Veterans Administration Hospital East Orange N J Associate Professor of Pathology New York Medical College New York N Y

ANGEL F BAI M D
Associate in Surgery University of Cordoba Medical School Cordoba Argentina Formerly Fellow in Thoracic Surgery College of Medical Evangelists Los Angeles Calif

ANDREW L. BANYAI M D F A C P F C C P
Associate Clinical Professor of Medicine Marquette University School of Medicine Milwaukee Wis

ALVAN L. BARACH M D, F A C P F C C P
Clinical Professor of Medicine College of Physicians and Surgeons Columbia University Associate Attending Presbyterian Hospital New York N Y

RAYMOND J BARRETT M D F A C S
Instructor in Surgery Wayne State University College of Medicine Chief Thoracic Surgery Outpatient Department Harper Hospital Detroit Mich

NOEL F BARTONE M D M S (Radiology)
Director of Radiology Methodist Hospital Consulting Radiologist U S Public Health Service and Columbus Hospital New York N Y

F J BEATTIE M D F A C S
Chairman Department of Surgery Presbyterian Hospital Professor of Surgery University of Illinois School of Medicine Chicago Ill

HOWARD R BIERMAN M D B S C (Medicine) F A C P
Medical and Scientific Director City of Hope Medical Center Hospital for Tumors and Allied Diseases Duarte Calif

J W BIRSNER, M D F C C P
Chief of Radiology Kern General Hospital Bakersfield Calif Radiologist Antelope Valley District Hospital Lancaster Calif

DANTE BIZZARRI M D
Director Department of Anesthesiology Columbus Hospital Instructor in Anesthesiology New York Medical College New York N Y

I D BOBROWITZ M D F C C P
Visiting Physician (Pulmonary Diseases) Bronx Municipal Hospital Center Associate Clinical Professor of Medicine (Pulmonary Diseases) Albert Einstein College of Medicine New York, N Y

KATHARINE R BOLCOT M D F A C P
Professor of Preventive Medicine and Clinical Professor of Medicine Woman's Medical College of Pennsylvania Director of Survey Philadelphia Department of Health Philadelphia Pa

JAMES A BOLGAS M D
Associate Overholt Thoracic Clinic Surgeon, New England Deaconess Hospital Boston, Mass.

EDWARD A BOYDEN, PH D (Med Sc)
Professor Emeritus of Anatomy, University of Minnesota Minneapolis Minn Research Professor of Anatomy University of Washington, Seattle Wash

O C BRANTIGAN M D F A C S, F C C P
Professor of Clinical Surgery and Professor of Clinical Anatomy University of Maryland School of Medicine Chief in Thoracic Surgery, St Joseph's Hospital, Baltimore, Md

LYMAN A BREWER III M D F A C S F C C P
Associate Professor of Surgery College of Medical Evangelists Senior Attending Surgeon Los Angeles County General Hospital Los Angeles, Calif

JOHN N BRIGGS M D, F A C S F C C P
Attending Thoracic Surgeon Los Angeles County General Hospital Olive View Sanatorium San Fernand Veterans' Hospital and Sepulveda Veterans Hospital Los Angeles Calif

ANDRE J BREWER, M B, CH B, M S (Radiology)
Instructor in Radiology, Mayo Foundation Graduate School, University of Minnesota, Consultant Section of Roentgenology, Mayo Clinic, Rochester, Minn

PAUL A BUNN, M D, F A C P
Professor of Medicine, State University of New York Upstate Medical School, Attending Physician, University Hospital Memorial Hospital and City Hospital, Syracuse, N Y

FRANCIS X BYRON, M D, F A C S
Consultant and Chief, Thoracic Surgery, Wadsworth Veterans Hospital, Associate Professor of Surgery, College of Medical Evangelists, Senior Attending Surgeon Los Angeles County General Hospital Los Angeles, Calif

WILLIAM G CAHAN M D, F A C S
Assistant Attending Surgeon, Memorial Center for Cancer and Allied Diseases Assistant Professor of Surgery, Cornell Medical School, New York N Y

JOHN A CAMPBELL, M D, F A C R
Director, Department of Radiology, Indiana University Hospitals, Consultant in Radiology, Veterans' Administration Hospital, Indianapolis General Hospital and Community Hospital, Indianapolis, Indiana

J MAXWELL CHAMBERLAIN, M D, F.A C.S, F C C P
Assistant Clinical Professor of Surgery, College of Physicians and Surgeons, Columbia University, Attending in Charge of Thoracic Surgery, Roosevelt Hospital, New York, N Y

HENRY B CLOSE, M D, F A.C.P
Chief, Medical Service, Veterans' Administration Hospital, Philadelphia, Pa

JOHN W V CORDICE, JR, M D
Assistant Visiting Surgeon, Harlem Hospital, New York, N Y

BERT H COTTON, M D, F C C P
Thoracic Surgeon, Huntington Memorial Hospital, Pasadena, Calif, Hollywood Presbyterian Hospital, Los Angeles, Calif, and St Joseph Hospital, Burbank, Calif

ARTHUR J CRACOVANER, M D, F A C S, F C C.P
Clinical Professor of Otorhinolaryngology, Post-Graduate Medical School, New York University-Bellevue Medical Center, Attending Otolaryngologist, Lenox Hill Hospital and New York Eye and Ear Infirmary, New York, N Y

JAMES H CULLEN M D, F A C P, F C C P
Chief, Pulmonary Disease Section, Veterans' Administration Hospital Assistant Professor of Medicine, Albany Medical College, Albany, N Y

SIMON DACK, M D, F A C P, F C.C.P
Adjunct Physician for Cardiology, The Mt Sinai Hospital, Assistant Professor of Medicine, New York Medical College and Flower-Fifth Avenue Hospital, New York, N Y.

LOUIS R DAVIDSON, M D, F A C S, F C C P
Director of Surgery, Sea View Hospital, Attending Surgeon, Triboro Hospital, New York, N Y

EDGAR W DAVIS, M D, F A C S, F C C P.
Professor of Thoracic Surgery, Georgetown University School of Medicine, Chief, Department of Thoracic Surgery, Georgetown University Unit, District of Columbia General Hospital, Washington, D C.

NICHOLAS D D ESOPO, M D
Chief, Pulmonary Disease Service, Veterans' Administration Hospital, West Haven, Conn, Associate Clinical Professor of Medicine, Yale University School of Medicine, New Haven, Conn

SHELDON E DOWN, M D, F A C S, F C C.P
Attending Thoracic Surgeon, University of Tennessee Memorial Hospital and East Tennessee Tuberculosis Hospital, Knoxville, Tenn

DAVID J DUGAN, M D, F.A C.S, F C.C.P
Clinical Instructor in Surgery, Stanford University School of Medicine, San Francisco, Calif, Consultant in Thoracic Surgery, Veterans' Administration Hospital, Oakland, Calif

G L EASTMAN, M D
Instructor, State University of New York, Upstate Medical Center, Department of Medicine, Junior Assistant Attending Physician, Good Shepherd Hospital, Syracuse, N Y.

RICHARD R FERAYORNI, M D, M S (Medicine)
Director, Department of Medicine, Columbus Hospital, Assistant in Medicine, University Hospital and New York University Bellevue Medical Center, New York, N Y

WILLIAM T FOLEY, M D, F A C P
Chief of Vascular Clinic, New York Hospital Cornell Medical Center, Associate Professor of Medicine, Cornell University Medical College, New York, N Y.

LOUIS L FRIEDMAN, M D, F C C P
Chest Physician, University Hospital, South Highlands Infirmary and East End Memorial, Birmingham, Ala, Consultant in Chest Diseases, Veterans' Hospital, Tuscaloosa, Ala

L H GARLAND, M D
Clinical Professor of Radiology, Stanford University Medical School, Visiting Radiologist in Charge of Stanford Service, San Francisco Hospital, San Francisco, Calif

MAXWELL L. GELFAND, M D, F A C P
Associate Professor of Clinical Medicine, New York University Post-Graduate Medical School Associate Visiting Physician, Bellevue Hospital New York, N Y

JOHN H GIBBON, JR, M D, F A C S
Samuel D Gross Professor of Surgery and Head of Department of Surgery, The Jefferson Medical College Hospital, Consultant in General Surgery, Veterans' Administration Hospital Philadelphia, Pa

E ALBREY GITTENS, M D, F C C P
Visiting Physician, Tuberculosis & Chest Diseases, Harlem Hospital, Director of Radiology and Chest Consultant, Mt Morris Park Hospital New York, N Y.

JOSEPH G GIUFFRIDA, M D
Co-Director, Department of Anesthesiology Columbus Hospital, Clinical Associate in Anesthesiology and Assistant Anesthesiologist New York Medical College and Flower Fifth Avenue Hospital, New York, N Y

BURGESS GORDON, M D, F A C P, F C C P
President and William J Mullen Professor of Medicine, The Woman's Medical College Philadelphia, Pa

R VINCENT GRIECO, M D, M S (Pathology)
Co-Director of Radiology, Methodist Hospital Assistant Clinical Professor of Radiology, New York Medical College, New York, N Y, Director, Radioisotope Laboratory, Jersey City Medical Center, Jersey City, N.J

ALBERT HAAS M D
Clinical Instructor, Department of Physical Medicine and Rehabilitation, New York University College of Medicine, Physician in charge, Chest Rehabilitation Service, Bellevue Hospital, New York N Y.

C Y HADIDIAN, M D.
Assistant in Thoracic Surgery, University of Maryland School of Medicine, Visiting Thoracic Surgeon, Baltimore City Hospital, Baltimore, Md

KENNETH L. HARDY, M D
Attending Thoracic Surgeon, Highland Alameda County Hospital and Merritt Hospital, Oakland, Calif

JOSEPH HARKAVY, M D, F A A A
Head of Allergy Service, Montefiore Hospital, Consultant Allergist, The Mt Sinai Hospital, New York, N Y

JEROME R HEAD, M D, F A C S, F C C P
Associate Professor of Surgery, Northwestern University Medical School, Attending Staff, Chicago Wesley Memorial Hospital, Chicago, Ill

J A HERSCHFUS, M D
Assistant in Medicine, Tufts College Medical School, Boston City Hospital and Beth Israel Hospital Boston, Mass

J M HERTZLER, M D
Associate Surgeon, Children's Hospital of Michigan Clinical Instructor in Surgery, Wayne University College of Medicine, Detroit, Mich

A WORTH HOBBY, M D, F C C P
Chest Physician, Georgia Baptist Hospital and Piedmont Hospital, Atlanta, Ga, and Emory University Medical School, Emory University Ga

LEW A HOCHBERG, M D, F.A C S, F C C P
Attending Thoracic Surgeon, Jewish Hospital of Brooklyn, Visiting Thoracic Surgeon, Coney Island Hospital, New York, N Y

CORRIN H HODGSON, M D, M S (Medicine), F A C P, F C C P
Assistant Professor of Medicine, University of Minnesota Graduate School and Mayo Foundation Consultant in Internal Medicine, Department of Medical Chest Diseases, Mayo Clinic, Rochester, Minn

G HOFFMAN, M D, F C A P
Associate Attending Pathologist, St Vincent's Hospital New York, N Y, Pathologist, Riverview Hospital, Red Bank, N.J.

CHEVALIER L. JACKSON, M D, M SC., F A C S, F C C P
Professor of Laryngology and Broncho-esophagology, Temple University School of Medicine, Philadelphia, Pa

ROBERT M. JANES, M B (Tor), M D (Hon Laval), F R C S (C.), F R C S (Eng Hon), F.A C.S
Professor of Surgery and Head of Department of Surgery, University of Toronto, Surgeon in Chief, Toronto General Hospital, Toronto, Canada

JULIAN JOHNSON, M D, D SC. (Med), F.A C.S
Professor of Surgery, School of Medicine and Graduate School of Medicine, University of Pennsylvania, Philadelphia, Pa

RODNEY C. JUNG, M D, M S, PH D
Assistant Professor of Tropical Medicine, Tulane University of Louisiana School of Medicine, Visiting Physician, Charity Hospital of Louisiana, New Orleans, La

IRVING J KANE, M D, F.A C P, F C C P
Consultant in Chest Diseases, U S Naval Hospital, St Albans, N.Y, Associate Attending Physician, Diagnostic Roentgenology, Montefiore Hospital, New York, N Y

DAVID A KARNOFSKY, M D
Associate Attending Physician, Chemotherapy Service, Department of Medicine, Memorial Center, Associate Professor of Medicine, Cornell University Medical College, New York, N Y

SOL KATZ, M D, F C C P
Chief, Pulmonary Disease Division, District of Columbia General Hospital, Adjunct Clinical Professor of Medicine, Georgetown and George Washington University Schools of Medicine, Washington, D C

D R KEATING, M D, F A C R
Assistant Clinical Professor, Radiology, Western Reserve University, Cleveland, Ohio

CHARLES K KIRBY M D, F A C S
Assistant Surgeon, Hospital of the University of Pennsylvania, Assistant Professor of Surgery, School of Medicine and Graduate School of Medicine, University of Pennsylvania, Philadelphia, Pa

ALEXANDER LEWITAN, M D, F A C R
Attending Radiologist, Jewish Chronic Disease Hospital, Adjunct Professor, N Y Polyclinic Medical School and Hospital, New York N Y

EDITH M LINCOLN M D, F A A P
Visiting Physician Children's Medical Service, Bellevue Hospital Professor of Clinical Pediatrics, New York University College of Medicine, New York, N Y

SAMUEL LOSNER, M D
Assistant Director of Medicine, Jewish Chronic Disease Hospital, Clinical Instructor, State University of New York, College of Medicine at New York City, New York, N Y

JOHN S LUNDY M D
Senior Consultant, Section of Anesthesiology, Mayo Clinic, Professor of Anesthesiology, Mayo Foundation for Medical Education and Research, Graduate School, University of Minnesota, Rochester, Minn

JOHN H McDONALD, M D, M S (Path), F C A I, F C C P
Professor of Pathology, Mayo Foundation Graduate School University of Minnesota, Rochester, Minn

JOHN J McKEOWN, M D
Instructor in Surgery, Jefferson Medical College, Philadelphia, Pa

WALTER H. MALONEY, M D, M SC.
Professor and Head of Department of Laryngology and Broncho-esophagology, Hahnemann Medical College and Hospital, Philadelphia, Pa.

EDGAR MAYER, M D, F.A C P, F C C P.
Clinical Professor of Medicine, N.Y University Post-Graduate Medical Center, Visiting Physician, University Hospital, New York, N Y.

ALBRE DE L. MAYNARD, M D, F A C S
Director of Surgery, Harlem Hospital, New York, N Y

RICHARD H MEADE, M D, F A C S, F C C P
Senior Attending Thoracic Surgeon, Butterworth Hospital, Consulting Thoracic Surgeon, Blodgett Memorial Hospital, Grand Rapids, Mich.

GEORGE R MENEELY, M D, F A C P, F.C C I
Associate Professor of Medicine and Director of Clinical Radioisotope Center, Vanderbilt University School of Medicine, Chief, Radioisotope Service, Thayer Veterans' Administration Hospital, Nashville, Tenn

JOHN P MIHALY, M D, F C C P
Associate Attending Physician, Harlem Hospital and Mt Morris Park Hospital, New York, N Y

RODGER S MITCHELL, M D, F A C P, F C C P.
Associate Professor of Medicine, University of Colorado School of Medicine, Denver, Colo, Director, Colorado Foundation for Research in Tuberculosis, Colorado Springs, Colo

HURLEY L MOTLEY, PH D, M D, F C C P.
Professor of Medicine and Director of Cardiorespiratory Laboratory, University of Southern California School of Medicine, Attending staff, Hospital of the Good Samaritan and Los Angeles County Hospital, Los Angeles, Calif

JAN W MURI, M D
First Assistant, Medical Department, Aker Hospital, University of Oslo, Oslo, Norway

FOSTER MURRAY, M D, F A C P, F C C P.
Consulting Physician, Methodist Hospital and Brooklyn Regional Office, Veterans' Administration, New York, N Y

W P LAIRD MYERS, M D, M S (Medicine)
Assisting Attending Physician, Memorial Hospital, Assistant Professor of Medicine, Cornell University Medical College, New York, N Y

EMIL A NACLERIO, M D, F C C P
Chief, Thoracic Surgical Service, Harlem Hospital and Columbus Hospital New York, N Y

LOUIS NATHANSON, M D, M E (Medicine), F A C R F A C P
Attending Radiologist, Jewish Hospital and Maimonides Hospital, Associate Clinical Professor of Radiology, Albert Einstein College of Medicine, New York, N Y.

THEODORE H NOEHREN, M D, M A (Medicine), F C C P
Assistant Professor, Internal Medicine Buffalo General Hospital, University of Buffalo Consultant, Pulmonary Disease, Roswell Park Memorial Institute, Buffalo, N Y and U S P H S Division Industrial Health, Washington D C

WILLIAM B O'BRIEN, M D, F C C P
Consulting Staff, Pawtucket Memorial Hospital, Pawtucket, R I, Superintendent, Dr U F Zambarano Memorial Hospital, Wallum Lake R I

RICHARD H OVERHOLT, M D, F A C S F C C P
Director, Overholt Thoracic Clinic Clinical Professor of Surgery, Tufts College Medical School Staff member, New England Deaconess Hospital and New England Baptist Hospital Boston Mass

EDWARD F PARKER, M D, F A C S
Associate Professor of Surgery, Medical College of South Carolina, Charleston S C Consultant in Thoracic Surgery, Atlanta Medical Area Veterans' Administration, S C

GEORGE A PAULSEN, M E
Thoracic Surgeon, Kern County General Hospital, Bakersfield, Calif, Stony Brook Tuberculosis Hospital, Keene, Calif, and La Vina Sanitorium and Hospital Altadena Calif

DONALD L PAULSON, M D, F A C S, F C C P
Associate Clinical Professor of Thoracic Surgery University of Texas Southwestern Medical School Attending Physician Baylor Hospital Dallas, Tex

J WINTHROP PEABODY, JR, M D
Instructor in Thoracic Surgery Georgetown University School of Medicine Associate Attending Thoracic Surgeon, Children's Hospital and Garfield Memorial Hospital, Washington D C.

JOHN W PENDER, M D, M S (Anesthesiology) F A C S
Assistant Clinical Professor of Surgery (Anesthesiology), Stanford University San Francisco Calif, Director of Department of Anesthesiology, Palo Alto Medical Clinic Palo Alto, Calif

ARTHUR Q PENTA, M D, F C C P
Visiting Lecturer, Department of Medicine, Temple University Medical School, Philadelphia, Pa, Director, Department of Broncho-esophagology, St Clare's Hospital and Ellis Hospital Schenectady, N Y.

RALPH PHILLIPS, M D, F R C S
Associate Attending Radiotherapist, Memorial Hospital Associate Professor, Clinical Radiology, Cornell University Medical College, New York N Y

HELEN S PITTMAN, M D F A C P
Associate Physician, Massachusetts General Hospital Clinical Associate in Medicine, Harvard Medical School, Boston, Mass

MAXWELL H POPPEL, M D, F A C R
Professor and Chairman, Department of Radiology, New York University College of Medicine Director of Radiology, Bellevue Hospital and University Hospital, New York, N Y

THOMAS F PUCKETT M D, M S (Path)
Pathologist Methodist Hospital and Forrest General Hospital Hattiesburg, Miss

F JOHNSON PUTNEY, M D, F A C S
Associate Professor of Laryngology and Bronchoesophagology Jefferson Medical College, Philadelphia Pa

COLEMAN B RABIN, M D, F C A P F C C P
Attending Physician and Associate Radiologist for Chest Diseases, The Mt Sinai Hospital, Assistant Clinical Professor of Medicine, Columbia University, New York, N Y

ISRAEL RAPPAPORT M D, F C C P
Visiting Physician Bellevue Hospital, Associate Clinical Professor of Medicine, Columbia University Medical School New York, N Y

NATHANIEL C REICH, M D, F A C P, F C C P
Assistant Clinical Professor of Medicine, State University of New York, College of Medicine at New York City, Attending at Jewish Chronic Disease Hospital and Unity Hospital, New York, N Y

MAX RIFKO M D F A C R
Director Department of Radiology, Boston City Hospital Assistant Clinical Professor of Radiology Harvard Medical School, Boston, Mass

WILLIAM K ROGERS M D
Attending Thoracic Surgeon Fort Sanders Presbyterian Hospital and East Tennessee Tuberculosis Hospital Knoxville, Tenn

H ROSWIT, M D F A C R
Chief Radiotherapy Service Veterans Administration Hospital Assistant Clinical Professor, Radiology (Radiation Therapy) New York University Bellevue Medical Center, New York, N Y

A ROTTINO M D, F C A P
Associate Clinical Professor, Department of Pathology, N Y U Medical School, Director of Laboratories in Hodgkins Disease Research, St Vincent's Hospital, New York, N Y

MORRIS RUBIN, M D, F A C S, F C C P
Assistant Clinical Professor of Surgery, Albert Einstein College of Medicine, Visiting Thoracic Surgeon, Bronx Municipal Hospital Center, New York, N Y

HOWARD A RUSK, M D, D SC (Hon), LL D (Hon), F A C P
Professor and Chairman, Department of Physical Medicine and Rehabilitation, New York University Bellevue Medical Center, New York, N Y

A SALOMON, M D, F C C P
Associate Director, Suburban Cardio-pulmonary Diagnostic Laboratory, Inc, LaGrange, Ill

PAUL C. SAMSON, M D, M S (Surg), F A C S, F C C P
Associate Clinical Professor of Surgery, Stanford University School of Medicine, San Francisco, Calif Chief, Thoracic Surgery, Highland Alameda County Hospital, Alameda, Calif

O A SANDER, M D, F A C P, F C C P
Assistant Professor of Clinical Medicine, Marquette University School of Medicine, Chest Physician Milwaukee County General Hospital, Columbia Hospital and St Luke's Hospital, Milwaukee, Wis

IRVING A SAROT M D, F A C S, F C C P
Professor of Thoracic and Cardiovascular Surgery, New York Polyclinic Medical School and Hospital, Attending Thoracic and Cardiovascular Surgeon New York Polyclinic Medical School and Hospital and Beth Israel Hospital, New York, N Y

I BERNARD SCHACTER, M D
Formerly Resident in Surgery, Beth El Hospital, New York, N Y

MAURICE S SEGAL, M D, F A C P, F C C P
Clinical Professor of Medicine, Tufts University School of Medicine, Director, Lung Station (Tufts) and Department of Inhalation Therapy, Boston City Hospital, Boston, Mass

ROBERT R SHAW, M D, F A C S, F C C P
Clinical Professor of Surgery, University of Texas Southwestern Medical School, Chief of Section of Thoracic Surgery, Baylor University Hospital, Dallas, Tex

ARTHUR A SIEBENS, M D
Associate Professor, Department of Physiology, State University of New York, College of Medicine at New York City, New York, N Y, Consultant in Cardio respiratory Function, U S Naval Hospital, St Albans N Y, Brooklyn Veteran's Administration Hospital, New York, N Y, Veteran's Administration Hospital Castle Point, N Y

LOUIS E SILTZBACH, M D
Associate Attending Physician and Chief of Sarcoidosis Clinic, The Mt Sinai Hospital, Attending Physician, Pulmonary Diseases, Montefiore Hospital, Assistant Clinical Professor of Medicine, College of Physicians and Surgeons, Columbia University, New York, N Y

M A SISSON, M D, F A C R
Assistant Clinical Professor of Radiology, Stanford University, Attending Radiologist, Stanford Service, San Francisco Hospital, San Francisco, Calif

DAVID M SPAIN, M D, F C A P, F C C P
Associate Professor of Pathology, College of Physicians & Surgeons, Columbia University, Director of Laboratories, Beth El Hospital, New York, N Y

JOSEPH STEIN, M D, F A C R
Director of Radiology, Veterans Administration Hospital, Assistant Clinical Professor of Radiology, New York University College of Medicine, New York, N Y.

ISRAEL STEINBERG, M D, F A C P, F C C P
Associate Professor of Radiology and Assistant Professor of Medicine, Cornell University Medical College, New York, N Y.

T LANE STONES, M D
Surgeon, Norfolk General Hospital, De Paul Hospital and Leigh Memorial Hospital, Norfolk, Va

CHARLES B STORCH, M D
Associate Attending Radiologist, Beth El Hospital, New York, N Y

CLIFFORD F STOREY, M D, F A C S, F C C P, F A C C
Thoracic Surgeon, Central Community, Children's, Mercy, Quintard, Sharp Memorial, San Diego County and U S Naval Hospitals San Diego, Calif

H E TEBROCK, M D
Associate Clinical Professor of Industrial Medicine, New York University-Bellevue Medical Center, Attending Physician, Medical Service, City Hospital, New York, N Y.

J ROBERT THOMPSON, M D
Chief, Division of Laboratories, City of Chicago, Municipal Tuberculosis Sanitarium, Clinical Assistant Professor, Department of Pathology, University of Illinois College of Medicine, Chicago Ill

HAROLD G TRIMBLE M D, F A C P, F C C P
Associate Clinical Professor of Medicine (Diseases of the Chest), Stanford University School of Medicine, San Francisco, Calif, Consultant, Highland and Fairmount Hospitals, Oakland, Calif

WILLIAM M TUTTLE, M D, F A C S
Associate Clinical Professor of Surgery, Wayne State University. Chief of Thoracic Surgery Services, Harper Hospital, Herman Kiefer Hospital and Woman's Hospital, Detroit, Mich

DONALD S TYSINGER, JR, M D.
Chest Physician Flowers Hospital, Moody Hospital and Frazier Ellis Hospital, Dothan Ala

LEROY D VANDAM PH D, M D
Associate Clinical Professor of Anesthesia Harvard Medical School Director of Anesthesia Peter Bent Brigham Hospital Boston Mass

WILLIAM V VINDZBERG, M D
Senior Chest Physician, Dr U E Zambarano Memorial Hospital, Wallum Lake, R I

BRUNO W. VOLK M D, F C A P
Director, Isaac Albert Research Institute of the Jewish Chronic Disease Hospital, Visiting Associate Professor of Pathology, Albert Einstein College of Medicine, New York N Y

ARTHUR J VORWALD M D, SC D (Hon) LL D (Hon) F A C P, F C A P, F C C P
Professor and Chairman, Department of Industrial Medicine and Hygiene, College of Medicine Wayne State University, Consultant in Medicine, Receiving Hospital, Detroit, Mich

DAVID H WATERMAN, M D, F A C S, F C C P
Attending Thoracic Surgeon, University of Tennessee Memorial Research Center and Hospital, and Fort Sanders Presbyterian Hospital Knoxville, Tenn

JAMES L WHITTENBERGER, M D
Professor of Physiology, Harvard School of Public Health, Boston, Mass

MARK H WILLIAMS, M D, F A C S, F C C P
Thoracic Surgeon, Binghamton City Hospital, Binghamton, N Y, and C S Wilson Memorial Hospital, Johnson City, N Y

NORMAN J WILSON, M D, F A C S, F C C P
Associate, Overholt Thoracic Clinic, Thoracic Surgeon New England Deaconess Hospital, Boston, Mass, and Cambridge Sanatorium, Cambridge, Mass

FRANCIS M WOODS, M D, F A C S, F C C P
Associate, Overholt Thoracic Clinic, Associate Professor of Surgery, Tufts College Medical School Boston, Mass

IRVING S WRIGHT, M D, F A C P
Professor of Clinical Medicine, Cornell University Medical College, Attending Physician, The New York Hospital, New York, N Y.

J YERUSHALMY, B A, M A, PH D
Professor of Biostatistics, University of California Berkeley, Calif

Foreword

Doctors dedicated to the task of prevention and cure of disease are fully conscious of the necessity of keeping abreast of current thought and practice. Unlike a judge or jury who may take days, weeks or even months before handing down a decision, the doctor must quickly gather the evidence and make the wise decision on the spot. We cannot always adjourn our court or postpone settlement to spend great periods in a library to make retrograde studies. It is necessary to prepare in advance for service to persons not yet struck down by disease. When confronted by varied and unpredictable problems, the prepared doctor will be able to hand down the correct decision and give wise counsel immediately.

There are various ways doctors have of trading information in the free "give and take" of the scientific world. The benefits of the most advanced methods of diagnosis and treatment should be made promptly available to all the sick. Information can be sorted out and channeled most directly and with less delay at medical meetings by word of mouth. Many times it is difficult to sift out the valuable from the less valuable, although program committees can in effect edit the context of the meeting fairly well by a review of abstracts in advance. However, since most medical meetings today serve the various specialty fields, areas of the body are often divided along artificial lines. Distortion of points of view lead to confused thinking and competitive methods of treatment.

Medical journals also serve well to channel information to those in the frontline of treatment. The editing and control of subject matter can be more effectively managed than in the assembly hall. Yet the bulk of the material that flows out through specialty journals may be artificially segregated. Such a medium does not necessarily form the simplified approach to many problems which confront the doctor. A book or monograph by a single author may best document thought, knowledge and seasoned methods of procedure. However, it is difficult today for one author to cover the waterfront of a particular area of the body, prepare the material, follow it through to publication and at the same time to have it appear before much of the subject matter is outdated.

The early publication in book form of papers prepared by many authors for an immediate

be victims of pulmonary disease may prepare himself for decisions based on very current thought and practice. In fact, the material has been edited doubly. In the first place, authors were selected for a presentation of the subject of bronchopulmonary diseases to be published in special numbers of the *American Journal of Surgery*. This preliminary symposium was so enthusiastically received that it emphasized the need for a book of wider scope to include all the best of current knowledge of the diagnosis and management of pulmonary disease. This entailed not only a further culling and scanning of the original material to select that of greatest usefulness, but also required the addition of many new subjects by other authors. As a consequence, subject matter has been covered not by men in one specialty, but by those best qualified in all related specialties. A valuable reference library has resulted. The availability of these many points of view and of current methods of management of pulmonary disease freshly presented should help us all to pass on greater benefits of medicine and surgery to victims of pulmonary disease.

Richard H. Overholt, M.D.

Preface

During the past decade the field of bron[illegible] pulmonary disease (BPD) has devel[illegible]d with such rapidity that it has gained [illegible]p[illegible]ance and recognition as an integral p[illegible]rt [illegible] internal medicine and thoracic surgery [illegible] recently our knowledge of BPD ha[illegible] scanty Our diagnostic and therapeutic [illegible]r[illegible]mentarium has been limited and [illegible] patients with BPD succumbed to undi[illegible] and untreated conditions Today howeve[illegible] picture is considerably brighter many pati[illegible] have an excellent chance of becoming [illegible]pletely well while others are offered a new hope for improvement and for prolongation of life The tremendous progress in our fundamental knowledge and the potentiality for successful therapy make an understanding of the diagnosis and management of BPD of major clinical importance

The basic motive in preparing this volume has been the need for an up to date compact authoritative and comprehensive compilation on the diagnosis and management of BPD In addition the rapid pace of recent advances justifies a reorientation in presentation and modification in emphasis from that found in standard textbooks on chest diseases So prom[illegible]nent is the place which BPD holds in the field of medicine that such a demand must surely express the needs of many who look at the problem from different angles

A unique departure in a book of this type is the emphasis on certain aspects of embryology anatomy, physiology and pathology that are essential to an understanding of this complex subject as well as the inclusion of principles of medical and surgical treatment This is prompted by the fact that these patients not infrequently require protean methods of medical and surgical attention Thus the practicing physician should be familiar with all facets of this rapidly developing field one which calls for the combined efforts of physician surgeon radiologist endoscopist and anesthesiologist

[illegible] is assembled in sections the con[illegible] covering a particular phase of [illegible] Th[illegible] first two sections deal with funda[illegible] [illegible] To understand the malformation of [illegible] is necessary to know something [illegible] normal development The increas[illegible] results obtained with physiologically [illegible] therapy in the management of asthma [illegible]sema require a knowledge of physio[illegible] principles and physiopathologic mecha[illegible] responsible for the sequence of events that occurs The use of special drugs in the prevention of BPD the careful study of diseased resected lungs and lungs from apparently healthy individuals who have died from violence and the development of such procedures as bronchospirometry and pulmonary arterial catheterization in the study of pulmonary function necessitate a revaluation of our concept of the pathogenesis and the complications of many forms of BPD

In the section on diagnosis the clinical and laboratory procedures which help establish correct diagnoses are discussed The importance of lung biopsy in undiagnosed disseminated disease is emphasized The section which deals with roentgenology points out the reliability and pitfalls associated with x ray diagnosis

insufficiency in one organ is reflected in the other This creates a problem of differential diagnosis since it is often difficult to assess which is the primary disturbance when heart and lung disease co-exist as they frequently do The section on tuberculosis indicates that recent years have witnessed the evolution of our present-day concept of prolonged interrupted therapy with antimicrobial agents and a definite change in our concepts of surgical management The changes that occur in pulmonary tuberculosis brought about by chemotherapy, are discussed in detail In the section on primary bronchogenic carcinoma which today

I. EMBRYOLOGY, DEVELOPMENTAL ANOMALIES, AND ANATOMY

1

Developmental Anomalies of the Lungs

EDWARD A BOYDEN ph D *Seattle Washington*

From Department of Anatomy University of Washington Seattle Washington

To understand the malformations of organs it is necessary to know something about their normal development The first indication of lungs appears in embryos of about seventeen to twenty somites at an ovulation age of twenty four days (Streeter s Horizon XI It consists of a median thickening of the ventral wall of the foregut just cranial to the liver diverticulum In the beginning therefore the lungs develop at a very high level near the junction of occipital and cervical segments Within two days (Horizon XII twenty five to twenty seven days embryos of twenty five to thirty somites) the primordium develops into a pear shaped bulge of the ventral wall at the caudal end of a laryngotracheal groove (Fig 1 left upper sketch) In another day or so (Horizon XIII twenty six to twenty eight days embryos of 4 to 5 mm) this bulge gives rise to right and left lung buds with characteristic direction of growth that of the right lung being more downward and that of the left more transverse (see series of sketches Streeter 1945) Meanwhile as the lung buds elongate the respiratory portion of the gut is being separated from the esophageal portion by [illegible]

arrows in Figure 1 indicate the level of separation of the two tubes By the end of another two days (Horizon XIV, twenty eight to thirty days embryos of 6 to 7 mm) the lung buds have elongated into the primary lung sacs or primary bronchi (Fig 1, left middle sketches) Lateral views would show that they are growing dorsalward crossing the plane of the esophagus, as well as downward

On the thirtieth to thirty second day (Horizon XV embryos of 7 to 8 mm) the five lobar bronchi appear as monopodial outgrowths of the primary bronchi (Fig 1, *U, M L*, middle row of sketches) From the thirty second to the thirty fourth day (Horizon XVI, 8 to 11 mm embryos) the lobar bronchi merely elongate Up to this time growth has been rather slow, (thirty four to thirty six days embryos of 11 to 13 6 mm) all segmental bronchi are present In Horizon XVIII (thirty six to thirty eight days embryos of 14 to 16 mm) the subsegmental buds are beginning to appear (Fig 2), and by the thirty eighth to fortieth day (Horizon XIX embryos of 17 to 20 mm) all subsegmental bronchi are represented and many are undergoing further subdivision

Details of these last three stages covering the origin of the bronchopulmonary segments may be found in a recent article by Wells and Boyden (1954) Suffice to say that these are the stages in which variations of the segmental bronchi first appear and study of embryos fails to support the "doctrine of the stem bronchus —an axial structure with alternating dorsal and ventral branches (See discussion of Aeby's theory in Chapters 1 and 9 Boyden 1954)

AGENESIS OF THE LUNGS

Obviously the factors that prevent the formation of the lungs must become effective not later than the period represented by Horizon XII (twenty six days after ovulation) i e early in the second month of menstrual age

Three different degrees of arrest of development may occur (Schneider, 1912) (1) complete absence of one or both lungs (agenesis),

(2) suppression of all but a rudimentary bronchus (aplasia), and (3) abortive growth (hypoplasia). Until the significant studies of Wilson and Warkany appeared (1949) it was difficult to explain these anomalies on other than a genetic basis. Recently, these authors have shown that agenesis can be produced experimentally in rat fetuses by depriving the mother of vitamin A. However, Warkany (1951) does not believe that in our American hospital patients there is sufficient malnutrition of this type to explain the agenesis that occurs. He suggests that diseases of the placenta or infectious agents such as rubella may so modify the vascular supply to the embryonic lung as to produce a nutritional deficiency that affects the chemistry of development.

Oyamada, Gasul and Holinger (1953) recorded seventy three cases which clearly fall into the category of agenesis and aplasia and then confine further remarks to the phase of the subject in which we have had special experience, namely the structure of the persisting lung in cases of unilateral agenesis.

In the three cases of agenesis of the right lung that have come to our attention (Thomas

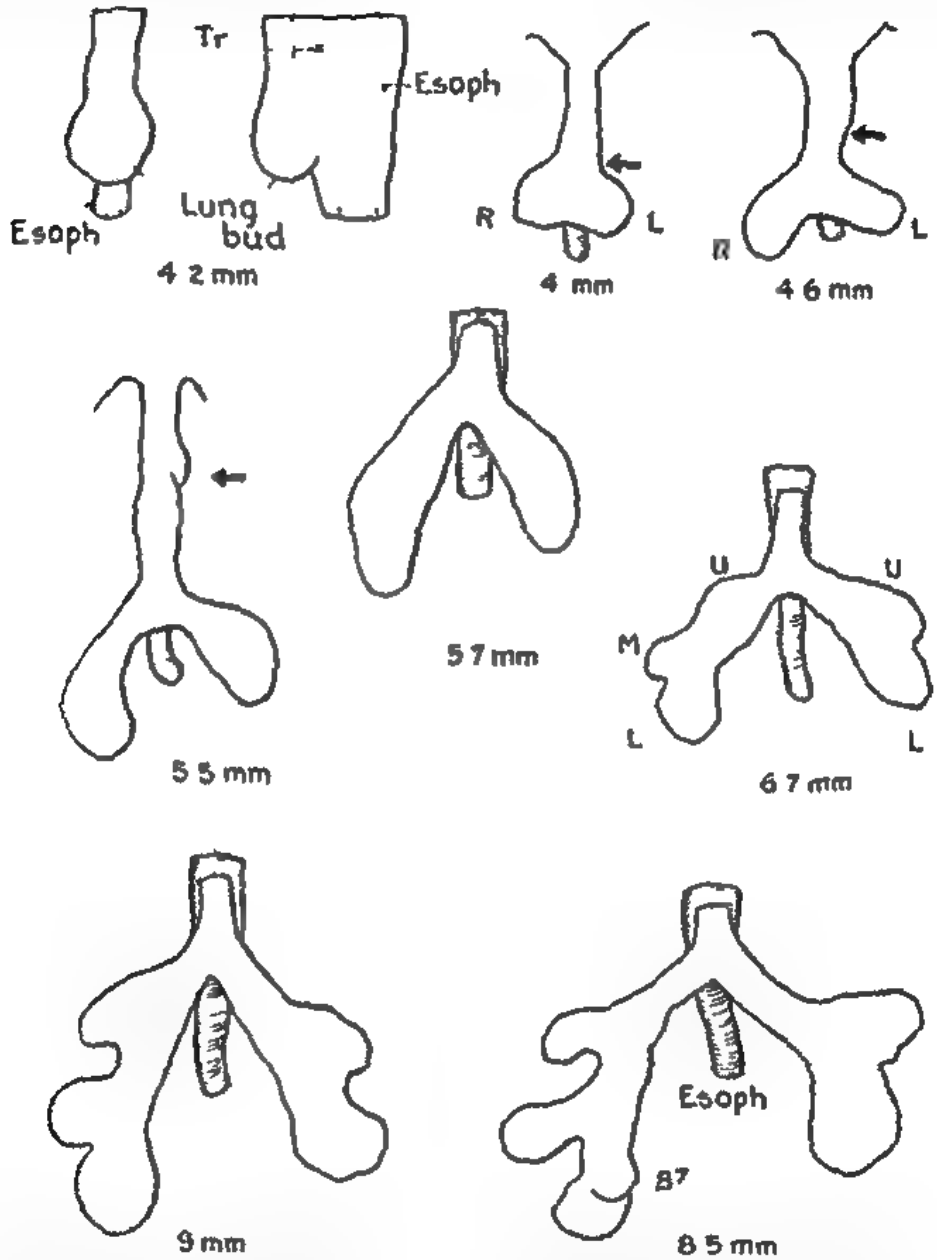

FIG. 1. Early stages in the development of the human tracheobronchial tree (after Hess, 1919) covering Horizons XII to XVI of Streeter's age groups. The arrows indicate the level of separation of tracheal and esophageal tubes. *U M L*, upper, middle and lower lobar bronchi.

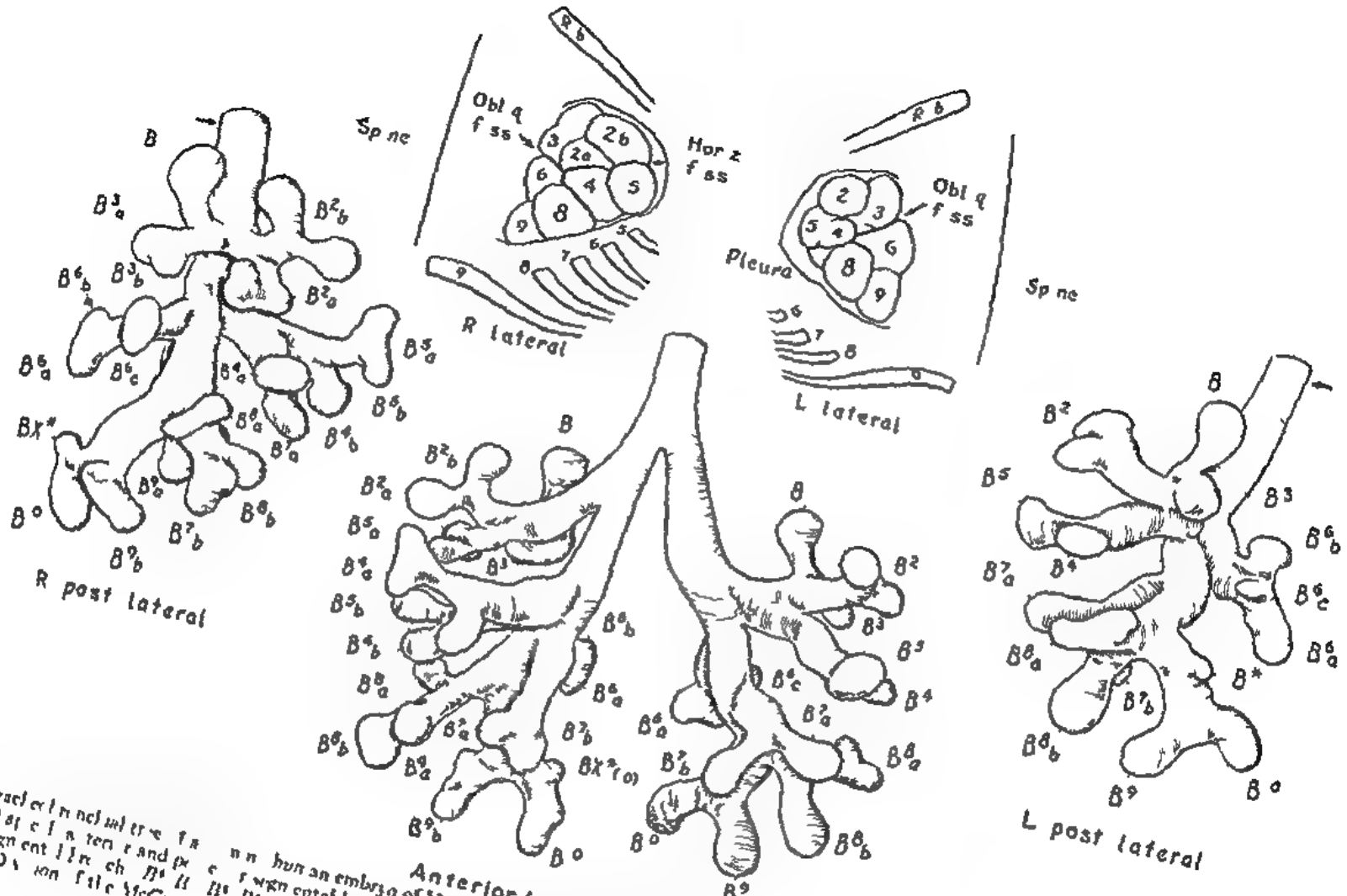

F 2 Tracheobronchial tree fr n hun an embryo of Ho zon x (after B y len 954 l xt n of pl r l c t van l wx n od l by I 3)) (ls) B B B' B' B' B' B' superior medial basal ante or bas l late al l ssal and pr t no b sal segm ntal bronch (Courtesy of the l ngular segment l br ch B' B' B' B' (l ft) a per or l ngular an l nf or l ngular segment l br ch B' B' B' B' (right) lateral an l med l segm ent l bronch (Black ton D v ion f the McGraw H ll Book Co)

and Boyden (1951) the left lung exhibited many variants from the usual pattern. The first two cases had three lobes each, and the third none. The first had many variations of the segments, the second had a left eparterial bronchus, and the third had such vascular anomalies as coarctation of the aorta, persistent ductus arteriosus, and a left postbranchial pulmonary artery. Therefore, even in surviving lungs there has been modification of normal development during the critical period of organ formation.

In addition to hypoplasia of a whole lung there may be hypoplasia of just one lobe. A striking example of this is Hepburn's case (1925). Externally the right lung appeared to have only two lobes, but in the oblique fissure a flattened piece of tissue was found which adhered to the right upper lobe. This was supplied by a small bronchus (10 mm. in diameter), which originated at the expected site of the middle lobe bronchus (in this case 26 mm. below the bifurcation of the trachea). Foster-Carter (1946) in discussing such hypoplastic lobes records a pertinent case of hyperplasia of the left lung in a male infant who had breathed only a few minutes. Here the anomaly was associated with absence of the left half of the diaphragm and herniation of the stomach and most of the intestines into the left pleural cavity. The right lung was expanded and normal, but the left bronchus led into a tiny lung about the size of a hazel nut. Bronchography revealed a branching bronchial system in the hyperplastic left lung.

In this case external pressures would seem to have provided the inhibitory factor. Similarly, in Hepburn's case a delayed origin of the bronchial bud could have given the upper and lower lobe bronchi such a head start that there was little room for arborization of a middle lobe bronchus. It will be recalled that irregular timing in the appearance of different buds is one of the characteristics of Horizon XVII.

ACCESSORY OR SUPERNUMERARY LUNGS

Of equal interest but of much rarer occurrence than agenesis are the rudiments of lung tissue that appear in ectopic positions. The most common site of origin is the trachea. A good example is Herxheimer's case (1901). He found a small functional "third lung" stemming from a tracheal bronchus 2.5 cm. down from the cricoid cartilage. This "sat above the lung on the right side and had caused stenosis of the trachea when it pressed against its right [illegible] was the mass [illegible] one year old [illegible] nubrium in a crotch of the great vessels but was still attached to the right posterior wall of the trachea, an inch above the trifurcation. It was hollow and lined by ciliated columnar epithelium.

Such supernumerary lungs are not to be confused with bronchi of the apical lobe that have been displaced to the trachea (see section on displacement of lobar bronchi). Presumably the former arise from tracheal diverticula. Bremer (1932) found two sizable tracheal diverticula in young human embryos—a long one in a 16.5 mm. specimen and a somewhat shorter one in a 10.6 mm. embryo. Such diverticula may either branch or develop into tubular structures with walls that resemble the trachea. Chiari (1889) found five such specimens in 6,000 autopsies.

Probably the most impressive type of supernumerary lungs are the so-called Rokitansky lobes. Such isolated masses of lung tissue are located in the lower thorax. They occur most commonly on the left side above the diaphragm* and are usually separated from the tracheobronchial tree and pulmonary vascular system. Significantly these masses are subject to diseases that affect the main lungs.† About forty cases have been summarized by Davies and Gunz (1944). Their second specimen is an excellent example of this anomaly. It consisted [illegible] upper face of the free margin of the defect. When sectioned it was found to consist of "fairly regular lung tissue but differed from an aerated lung in the greater thickness of the interlobular septa, in an excess of bronchioles over alveoli and in decreased vascularity."

A case of extraordinary interest is that of Scheidegger (1936). In a newborn male infant a grayish red bilobed mass of lung tissue (52 by 45 by 38 mm.) occupied the lower left

* Bolck (1951) lists twenty-seven of forty-one cases in this position and five more on this side below the diaphragm.

† Findley and Maier (1951) have reviewed the blood supply of such accessory lungs as well as cases in which there is communication between greater and lesser circulations.

pleural cavity which in turn was filled with clear yellow fluid As a result the heart was markedly shifted to the right The right lung was three lobed but contained no air The definitive left lung consisted of two diminutive lobes 25 and 27 mm long, both atelectatic The anomalous mass contained gas and was attached to the medial portion of the left dome of the diaphragm by a hollow stalk Beneath the diaphragm, the stalk continued for 2 mm to the stomach, joining it near the esophagus Throughout, the stalk was lined with gastric mucosa which connected the cavity of the stomach with the bronchi at the base of the accessory lung The author concluded that the anomalous mass was a "third lung that had grown out of the stomach"

This theory is not so improbable as one might think At the time that the respiratory primordium first appears it lies adjacent to the esophagus and stomach Perhaps this adjacent portion retained the potency to form lung tissue in the same way that lower derivatives of the foregut—from gallbladder to Meckel's diverticulum—retain the potency to form accessory pancreas In this connection one might mention the case of Gans and Potts (1951) in which a mass of atelectatic lung parenchyma [illegible] pressing the left bronchus, was found attached (by hollow pedicle) to the left side [illegible] esophagus at the level of the bifurcation [illegible] trachea

Another way of explaining these anomalies has been revived recently by Davies and [illegible] (1944) They suggest that the lowest part of the laryngotracheal groove (from which lung buds develop) may become separated from the main primordium—owing to the [illegible] elongation of the foregut—and grow down with the esophagus and stomach to the level of the diaph- [illegible] elonga [illegible] the es [illegible] ducts— [illegible] stomac [illegible] the lower one into the duoden [illegible] —may develop by the separation and growing apart of portions of the hepatic diverticulum (Boyden, 1932) *

* In this connection mention should be made of the case of a five month old girl (Neuhauser and Elkins Am. J Dis Child, 83 654-659 1952) in which there was an anomalous tract paralleling the esophagus which connected the medial side of the right primary bronchus with the stem of the left hepatic duct By means of this tract bile entered the lungs The upper segment of the tract resembled trachea the large middle segment the esophagus the lower segment the bile duct Two explanations are offered (1) the [illegible]

However, Cockayne and Gladstone (1917) consider that while these theories may account for the formation of accessory lungs in certain atypical situations, they do not offer an explanation for the preponderance of cases of lower accessory lung on the left side or account for the frequency with which such accessory lungs are associated with defective development of the diaphragm on the left side They incline to another standing theory, namely, that lower accessory lungs are formed by adhesions taking place between the growing lung bud and the celomic epithelium, and that a portion of the adherent lung tissue becomes separated from the main part and takes on independent growth They have found support for this hypothesis in a restudy of the [illegible] [illegible] below the pleuroperitoneal membrane into the peritoneal cavity, where they come into contact with such abdominal organs as the liver and stomach The factor which they consider responsible for the adhesion taking place more commonly on the left side is the normal movement of the stomach to the left which also carries the lung buds to the left and narrows the left pleural cavity over that of the right thus favoring adhesions A carefully detailed study of the successive stages of the development of the diaphragm is now [illegible] (Wells 1954) and one should be able to test this hypothesis in a way that has not been possible hitherto

THE LEFT EPARTERIAL BRONCHUS

Since the time when Aeby first characterized the human lungs as being asymmetric—because of the presence of a right eparterial bronchus—and speculated that this condition had arisen through suppression of a corresponding left bronchus students of the subject have searched in vain for a left eparterial bronchus in man Through good fortune, we have encountered five cases in the Minnesota Labora-

tory in the last eight years Four of these were in cadavers and one in the sixteen day old twin baby girl mentioned previously as having agenesis of the right lung Incidentally, there was no agenesis of the lung of the identical twin suggesting that in these two siblings the defects were of environmental but not genetic origin

In such specimens the feature which strikes the observer first is the ectopic position of the large left pulmonary artery This enters the left lung between two bronchial stems that arise separately from the left primary bronchus The upper (or eparterial) stem supplies the left apical anterior segment (B^{1+2}) and may enter a portion of the anterior segment (B^3) Therefore the left eparterial is not exactly comparable to the right eparterial bronchus The lower stem supplies the anterior (B^3) and lingular segments (B^4 and B^5) In two cases a supernumerary fissure led to the pulmonary artery from the anterior margin of the lobe (Boyden 1949)

What is the etiology of this anomalous bronchus? From our study of embryonic lungs we infer that about Horizon xx (cf right middle sketch of Fig 1) two left upper lobe buds (instead of one) must have arisen from the left primary lung sac Since only one case was found in 100 consecutive dissections it is assumed that this anomaly has an incidence of not more than 1 per cent It is important surgically, however that it be recognized when present

DISPLACEMENT OF LOBAR BRONCHI

In addition to the foregoing cases it occasionally happens that a single lobar bronchus develops at a lower or higher point than usual on the primary lung sacs Huizinga and Smelt (1949) present a bronchogram of such a case (their Fig 108) in which the whole right upper lobe bronchus originates just above the normally placed middle lobe bronchus In a second case (their Fig 17e) both right upper and middle lobe bronchi arose from a common stem at the usual site of the middle lobe Sweet records a surgical case in which the reverse condition occurs There the middle lobe bronchus arose from a normally placed right upper lobe bronchus either from its main trunk or from the proximal part of the anterior segmental bronchus (Boyden 1954 Chapter 5) Finally, the whole right upper lobe bronchus may originate from the right lateral wall of the trachea as in certain Ungulates

DISPLACEMENT OF SEGMENTAL AND SUBSEGMENTAL BRONCHI

The lesser variations in the patterns of the bronchial trees are due primarily to displacement of segmental and subsegmental bronchi Although lesser in degree than those of other categories they are nevertheless of great practical importance in the resection of bronchopulmonary segments The displacement occurs at the time that the segmental and subsegmental buds appear namely, in embryos of Horizons xvii to xix (thirty four to forty days after ovulation) It takes the form of buds originating at atypical sites on the tree Only a few of the more significant variations will be mentioned here (For the remainder see Boyden 1954)

One of the most confusing variants is the one which supplies all or part of the apical segment and arises on the right side of the trachea or from the lateral wall of the right primary bronchus before the lobar bronchus is given off It is the displaced variety of what we have termed the preeparterial bronchus It is not a supernumerary bronchus but merely a displaced apical ramus or apical bronchus (cf Plate 1 Boyden 1952)

Similarly one of the upper lobe bronchi may originate at a lower level For example, the right anterior bronchus (B^3) may arise from the middle lobe stem Such a variation we have termed the posteparterial bronchus (cf Fig 2 Boyden and Hamre 1951) It too is not supernumerary but merely a displaced portion of the upper lobe bronchus since it distributes to the territory of B^3 in that lobe

Another example of displacement may be seen in Figure 2 of this chapter Normally the left medial basal bronchus (B^7) and left anterior basal (B^8) arise from a common stem But in 7 per cent of 100 specimens B^7 arises alone at a higher level on the tree (see bronchi labeled 7a and 7b in the right hand portion of the central sketch of Fig 2) The same sketch (left hand side) illustrates one of four types of right medial basal bronchus In this type the two subsegmental buds are so oriented that they will supply only the anterior surface of the right lower lobe (cf Plate 4 of Ferry and Boyden 1951)

Again the posterolateral view of the left lower lobe in Figure 2 (sketch on the extreme right) reveals the absence of B^8a the posterior ramus of the anterior segment When present

(65 per cent) it is a site in which lung absence of the left upper lobe most frequently occurs The surface view of the same lung confirms the absence of this ramus in the embryo for B^2 fails to reach the oblique fissure (see left upper central sketch)

From these few examples it is apparent that such variations develop during the period when the segmental and subsegmental buds are being formed What is not clear is the cause of these variations Probably they are due to minor environmental factors of intrauterine life for Ando (1951) has shown that even in monozygotic twins the respective right or left lungs have slightly different patterns

SUPERNUMERARY FISSURES AND CONGENITALLY FUSED LOBES

One of the most common anomalies of the lungs is the supernumerary fissure A good account of these is presented by Mueller (1928) and Foster Carter s discuss on of abnormalities of lobation (1946) Contrary to common belief such fissures do not always separate segments but may enter subsegmental or even smaller interbronchial planes

Perhaps the most common site for a supernumerary fissure is the line between the medial basal and anterior basal segments (B and B^3) of the right lower lobe It partially segregates a cardiac or infracardiac lobe This corresponds to the free cardiac lobe of quadrupedal mammals but should not be considered atavistic since it in no wise differs from anomalous fissure formation in other portions of the lungs Dove (1900) found traces of it in 35 per cent of 180 human lungs A similar incisure of varying depth was observed by Smith and Boyden (1949) in 38 per cent of fifty injected right lungs All of them would have been noted in surgical exploration and some in roentgenologic examination A comparable fissure occurs in the left lung but infrequently (cf Plate xi) Boyden 1954)

Another common fissure is the one that separates the so-called dorsal lobe of Nelson (1934) This fissure segregates to a greater or lesser degree the superior segment of the right or left lower lobe Long before Nelson this fissure was found by Dove in forty right lower lobes and fourteen left lower lobes (In twelve cases the fissure was bilateral) He called the segregated portion the posterior lobe Curious enough such horizontal fissures cannot be depended upon to follow intersegmental planes In a case reported by Ferry and Boyden (their Plate 6) the fissure developed not between superior and subsuperior segments but between subsuperior and lateral basal zones

A third common form is the left horizontal fissure This subdivides the left upper lobe into two more or less equal portions the lower of which is called the left middle lobe But it is not always comparable to a right middle lobe Four types (Boyden 1949) have been described (1) a true middle separating normal upper and lower division segments (2) a compressed lingular (3) an expanded lingular, and (4) the ectopic pulmonary type This last always separates the sector of an eparterial bronchus from the remainder of the left upper lobe It also illustrates Foster Carter s category of fissures that are due to displaced blood vessels such as Monod s case (1911) of a subclavian artery that split the apex of the right lung to a depth of 3 cm and second the fissures that separate the lobe of the azygos vein

Both normal and supernumerary fissures develop during the period when the segmental and subsegmental buds first appear In the surface views of the 17 mm human embryo in Figure 2 both oblique and horizontal fissures are evident as deeper crevices lying between the lobular elevations formed by the segmental buds of the bronchial tree In a somewhat older embryo of 20 mm presented by Wells and Boyden (their Fig 38) there is a supernumerary fissure separating the left middle lobe from superior division bronchi This early appearance of fissures suggests that the cutting in of visceral pleura around bronchial buds may depend partly upon the prominence of given buds at the time of their formation That is a precociously appearing bronchus might favor the development of an accessory fissure Subsequent growth however may modify the situation, for it is well recognized that peripheral portions of the right horizontal fissure for example are frequently found to be congenitally fused while the deeper hidden portions remain open and lined with a pleural investment

This brings us to the subject of congenital fusion of lobes This again is one of the most common anomalies Kent and Blades (1942) found the horizontal fissure absent in 21 per cent of 277 lungs and incomplete in 67 per cent

more The oblique fissures were incomplete in 30 per cent of both right and left lungs

LOBE OF THE AZYGOS VEIN

This striking malformation of the apex of the lungs has been known since 1[illegible] when it was first described by Wrisberg in the cadaver of a three year old boy It is noteworthy that the first case was a bilateral one for as late as 1952 its occurrence on the left side has been denied (Kane) In 1953 Weston reported a case of his own and ten others from the literature However the anomaly is much more common in the right lung Bluntschli (1905) quotes Professor Bostrom as having found seventeen azygos lobes in 1 600 dissections On the other hand we have been favored with only one in almost 500 dissections Schmitz Chever estimates that it occurs in 0 3 per cent of all x rayed lungs

The lobe in question is a medial split off portion of the apex caused by the descent of the right (or left) posterior cardinal vein within its drawn out fold of costal pleura (the mesoazygos) Evidence that it is a phenomenon of the mechanics of growth is found in the fact that the apical bronchi are bent almost double along the line of contact with the vein The right posterior cardinal vein at its proximal end becomes the arch of the azygos vein Hence the name of the lobe

As the heart descends in development it drags the vein down into the apex This process may be supplemented by the upward growth of the apex for a glance at Figure 2 indicates that as late as the thirty seventh day the apical portion of the lung has not grown higher than the second rib Until lately there has been no satisfactory explanation of why a vein which lies medial to the adult lung should have cut into it laterally Recently (cf Boyden 1952) Professor L J Wells has advanced the theory that since the posterior cardinal veins originally lie lateral to the pleuropericardial canals—which latter extend upward from the pleural dome—any delay in closure of these canals would leave the vein in a position to descend upon the apex

The angle at which the vein descends determines the size of the wedge and the particular bronchi that will be segregated The line of descent may pass quite obliquely from the lateral side of the apex toward the hilum it may lie approximately in a vertical plane (thereby splitting the apex) or it may descend medial to the apex Roentgenologically, the mesoazygos appears as a curved descending line having its concavity toward the vertebral column and expanding at its lower end to enclose the drop-like azygos vein

With the advent of segmental anatomy it has been possible to identify the bronchial supply of the lobe Either the apical or the anterior ramus of the apical segment (B^1a or $B\ b$) is always present In the larger lobes both may be present or $B\ a$ and B^1a the apical rami of the apical and posterior segments (Boyden 1952) In the article quoted a detailed account of the attachments of the mesoazygos is presented

The clinical importance of the mesoazygos is at least twofold First it must not be confused with pathologic markings in the apex Second its presence or absence should be verified before operating on the upper lobe lest in cases of adherent mesoazygos the vein be ruptured unwittingly with ensuing hemorrhage

SEQUESTRATION OF BRONCHI

The etiology of cystic disease of the lungs is one upon which few investigators agree Embryologically there is little evidence if any supporting an early separation or constriction of portions of the developing bronchial tree That such may occur in late fetal stages or at birth through pathologic processes or otherwise seems more probable Curiously enough cystic disease is often associated with the presence of a large accessory pulmonary artery arising from the lower thoracic aorta or even from lower intercostal or subdiaphragmatic arteries (inferior phrenic and celiac) Because of this Pryce (1946 1947) Bruwer and associates (1950) and Kergin (1952) have related the two anomalies causally postulating that in early embryonic stages the terminal buds of the growing bronchial tree have been captured by systemic arteries that anchor the mass while the lung is undergoing developmental shifts It is then suggested that the resulting traction results in formation of cysts and sequestration of the captured mass

This seems to be a plausible explanation until embryonic processes are analyzed First accessory arteries to the base of the lungs occur in the absence of cysts and vice versa (cf Fig 120 Boyden 1954) Second the distribution of an accessory artery is often such that mechanically the artery could not have pro

duced a traction defect (cf Fig 123 Boyden 1954) Third arteries do not exert traction upon viscera in developmental stages Instead there is either a gradual shifting of an artery along the wall of a major vessel like the aorta (either through differential growth or selection of plexiform channels) or new arteries develop successively to keep pace with a descending organ

Such a process occurs for example in the development of the bronchial arteries In early stages the developing lung buds trachea and esophagus are surrounded by a common splanchnic plexus supplied by a series of small segmental arteries from the ventral side of the paired dorsal aortas These arteries of the upper cervical region are the precursors of the bronchial arteries Tobin (1952) has shown that as the lung grows downward the more cranially situated segmental arteries drop out and others formed lower down take their place In a subsequent stage the bronchial arteries are found to arise from the left aorta from the subclavian artery the highest intercostal and even from the right internal mammary—thus explaining some of the atypical origins of the bronchial arteries recorded in adults The lowest of this series of aortic branches are the accessory pulmonary arteries frequently associated with cysts One may assume that once having established connection with the lower portion of the growing lung they keep pace with the downward growth of the lung by shifting downward themselves until finally they may arise from the aorta just before it pierces the diaphragm

Another example of this process is the blood supply to the stomach Originally it arises from the cervical region of the embryo but gradually it shifts its position along the ventral wall of the aorta until it becomes the definitive celiac artery all this without having captured the stomach

GROSS ANOMALIES OF THE PULMONARY VESSELS

Arteries In addition to the accessory pulmonary arteries discussed in the preceding section i e those originating from the thoracic aorta below the hilum of each lung pulmonary arteries may arise atypically from the derivatives of the embryonic aortic arches Findlay and Maier (1951) have listed twenty five such cases (their Fig 1) as follows ten from the ascending aorta and arch of the aorta four from the innominate artery, two from the right subclavian five from the left subclavian and four from the descending aorta above the hilum of each lung Such aberrancies are usually associated with malformations of the heart and developmental anomalies of the aortic arches

Another recent summary may be found in the article by Castellanos and Garcia (1951) A classic case is that of Ingalls (1932) in which the stem of the right pulmonary artery arose from the right ductus arteriosus near the point where the latter joined the persisting right fourth aortic arch

Veins In the preceding section reference was made to the existence of a primitive splanchnic plexus which surrounds the developing lung buds trachea and esophagus At an early embryonic period this plexus drains into the anterior cardinal veins Thus it is possible under abnormal conditions for the pulmonary veins to retain connection with the derivatives of the anterior cardinal Brantigan (1947) in summarizing Brody s and other reports of 106 such cases found that the drainage from the lungs passed wholly into the right atrium or its tributaries in 36 per cent and partially in the remaining 64 per cent In the latter cases the most common site in order of frequency was the superior vena cava the right atrium and the left innominate vein Right pulmonary venous anomalies occurred twice as often as left ones Other sites of drainage were the coronary sinus inferior vena cava azygos vein left subclavian vein portal vein and left persistent superior vena cava Young (1947) has discussed the drainage into the portal vein

Anomalous drainage into the right atrium vena cavas and coronary sinus is differently explained than drainage into derivatives of the anterior cardinal veins Auer (1948) has shown that in a series of 2 to 7 mm human embryos there are both caudal and cranial evaginations of the sinu atrial region into the dorsal mesocardium The cranial type is the one that usually gives rise to the stem of the pulmonary vein that makes contact with the capillaries of the splanchnic plexus The caudal type normally disappears but persistence of it may lead to the formation of anomalous pulmonary veins that empty either into the coronary sinus, the superior or inferior vena cava or the right atrium

Mention should also be made of the variations in the mode of entrance of the

veins into the left atrium This is important from the standpoint of new operative procedures in which the pulmonary veins are ligated intrapericardially Healey and Gibbon (1950) report that in 3 per cent of 184 specimens, the right lung drained into a common right pulmonary vein before emptying into the left atrium On the left side the figure rose to 25 per cent Conversely, the right pulmonary may be represented by three veins emptying side by side In three cases by Healey and Gibbon, and two by Brantigan the three veins came respectively from the three lobes of the right lung, but in the case of Ferry and Boyden, the middle vein drained not only a portion of the middle lobe, but also much of the lower lobe Therefore, in intrapericardial ligation of such cases, it is not safe to assume that the three veins drain the respective lobes

Arteries and Veins of the Bronchopulmonary Segments Variations in the blood supply and drainage of the segments of the lungs are so numerous that they cannot be easily summarized Accordingly interested readers are referred to the chapters dealing with variations in the individual lobes of the lungs (Boyden, 1954)

REFERENCES

Aeby C. Der Bronchialbaum der Säugethiere und des Menschen Leipzig 1880 Wilhelm Engelmann

Ando T Ueber die bronchiale Ramification bei den Japanischen Zwillingsfeten *Folia anat Japonica* 23 167–214 1951

Auler J The development of the human pulmonary vein and its major variations *Anat Rec*, 101 581 594 1948

Blumtschli H Bemerkungen über einen abnormen Verlauf der Vena azygos in einer den Oberlappen der rechten Lunge durchsetzen den Pleurafalte *Morphol Jahrb Leipz* 33 562 576 1905

Bolck, F Zur Frage der Entstehung von Nebelungen *Virchows Arch f path Anat* 319 20–43 1951

Boyden E A The problem of the double ductus choledochus (an interpretation of an accessory bile duct found attached to the pars superior of the duodenum) *Anat Rec* 55 71–93 1932 Cleft left upper lobes and the split anterior bronchus *Surgery* 26 167 180 1949 The distribution of bronchi in gross anomalies of the right upper lobe particularly lobes subdivided by the azygos vein and those containing pre-eparterial bronchi *Radiology* 58 797 807 1952 Segmental Anatomy of the Lungs A study of the patterns of the principal bronchi and related pulmonary vessels New York 1954 Blakiston Div McGraw Hill Book Co

Boyden, E A and Hamre C. J An analysis of variations in the bronchovascular patterns of the middle lobe in fifty dissected and twenty injected lungs *J Thorac Surg* 21 172–188 1951

Brantigan, C. Anomalies of the pulmonary veins—their surgical significance *Surg., Gynec & Obst* 84 653–658 1947

Bremer, J L Accessory bronchi in embryos their occurrence and probable fate *Anat Rec*, 54 361–374 1932

Brody, H Drainage of the pulmonary veins into the right side of the heart *Arch Path*, 33 221–240 1942

Brown A J The development of the pulmonary vein in the domestic cat *Anat Rec* 7 299–329 1913

Brumer, A J, Claggett, D T and McDonald J P Anomalous arteries to the lung associated with congenital pulmonary abnormality *J Thorac Surg*, 19 957–972 1950

Castellanos A and Garcia O Classification des anomalies de l artère pulmonaire et de ses branches *Arch d mal du coeur*, 44 193–208 1951

Chiari H Ueber einen neuen Typus von Missbildung an der Trachea des Menschen *Beitr z path Anat u z allg Path*, 5 329–344 1889

Davies D W and Gunz F W Two cases of lower accessory lung in the human subject *J Path & Bact*, 56 417–428 1944

Devé, M F Les lobes surnuméraires du poumon Le lobe postérieur Le lobe cardiaque Valeur du lobe supérieur du poumon gauche *Bull et mém Soc Anat de Paris* 75 341–374 1900

Ferry R M Jr. and Boyden E A Variations in the bronchovascular patterns of the right lower lobe of fifty lungs *J Thorac Surg*, 22 189 201, 1951

Findlay C W Jr and Maier, H C. Anomalies of the pulmonary vessels and their surgical significance with a review of the literature *Surgery*, 29 604–641 1951

Foster Carter, A F Bronchopulmonary abnormalities *Brit J Tuberc* 40 111–124 1946

Gass S L. and Potts W J Anomalous lobe of lung arising from the esophagus *J Thorac Surg* 21 313 318 1951

Healy J E Jr. and Gibbon J M Intrapericardial anatomy in relation to pneumonectomy for pulmonary carcinoma *J Thorac Surg*, 19 864–874 1950

Heiss R Zur Entwicklung und Anatomie der menschlichen Lunge *Arch f Anat u Entwicklungsgesch Leipz* 1 129 1919

Hepburn D Note on a right lung which resembled a left lung in presenting only apical and basal lobes *J Anat* 59 326–327 1925

Herxheimer G Ueber einen Fall von echter Nebenlunge *Centralbl f allg Path u path Anat* 12 529–532 1901

Huizinga E and Suelt G J Bronchography Assen Netherlands 1949 Van Gorcum Co Ltd

Ingalls N W Anomalous pulmonary vessels *Anat Rec* 53 269–281 1932

Kane I J Segmental localization of pulmonary disease on postero-anterior chest roentgenogram *Radiology* 59 229 1952 Quoted by Weston

Kent, F M and Blades B The surgical anatomy of the pulmonary lobes *J Thorac Surg*, 12 18–30 1942

Kergin F G Congenital cystic disease of lung associated with anomalous arteries *J Thorac Surg* 23 55–65 1952

MONOD O *Bull et mem Soc Anat Paris* 86 92 1911
Quoted by Foster Carter
MUELLER, H Missbildungen der Lunge und Pleura In Henke u Lubarsch. *Handb d spez path Anat u Hist* 1 531 598 1928
NELSON H P Postural drainage of the lungs *Brit M J* 2 251 255 1934
OYAMADA A GASUL, B M and HOLINGER P H Agenesis of the lung Report of a case with a review of all previously reported cases *Am J Dis Child* 85 182 201 1953
PRYCE D M Lower accessory pulmonary artery with intralobar sequestration of lung a report of seven cases *J Path & Bact* 58 457 467 1946 see also *Brit J Surg* 35 18-29 1947
HEIDEGGER S Lungenmissbildungen (Beitrag zur Enstehung der Nebenlunge) *Frankfurt Ztschr J Path* 49 362 373 1936
SCHMITZ GLIEVER I Ueber das Vorkommen des Lobus venae azygos der linken Lungenspitze *Fortschr Geb Röntgenstrahlen* 728 731 1950
SCHNEIDER, P Die Missbildungen der Atmungsorgane In Schwalbe s Die Morphologie der Missbildungen des Menschen und der Thiere vol 3 pp 463 857 Jena 1912 Gustav Fischer
SMITH F R and Boyden E A An analysis of variations of the segmental bronchi of the right lower lobe of fifty injected lungs *J Thorac Surg* 18 195 215 1949
STIBBE E P True congenital diverticulum of the trachea in a subject showing also right aortic arch *J Anat* 64 62-66 1929
STREETER, G L Developmental horizons in human embryos *Carnegie Collection Contrib Embryol* Published successively as follows Description of age group XI 13 to 20 somites, and age group XII 21 to 29 somites (No 541) 30 211-245 1942 Description of age group XIII embryos about 4 or 5 millimeters long and age group XIV period of indentation of the lens vesicle (No 557) 31 27-63 1945 Description of age groups XV, XVI XVII and XVIII (No 575) 32 133-203 1948 Description of age groups XIX, XX XXI XXII and XXIII (Prepared by C. H Heuser and George W Corner) (No 592) 34 165 196 1951
SWEET R H Quoted by Boyden 1954
THOMAS L B and BOYDEN E A Agenesis of the right lung *Surgery* 31 429 435 1952
TOBIN C E The bronchial arteries and their connections with other vessels in the human lung *Surg Gynec & Obst* 95 741-750 1952
WARKANY J Congenital anomalies *Pediatrics* 7 607-610 1951
WELLS L J Development of the human diaphragm and pleural sacs *Carnegie Collection Contrib Embryol* 35 107 134 1954
WELLS L. J and BOYDEN E A The development of the bronchopulmonary segments in human embryos of Horizons XVII to XIX *Am J Anat*, in press
WESTON W J Left sided lobe of the azygos vein *J Fac Rad Rad ologists (New Zealand)* no 5 1954
WILSON J G and WARKANY J Aortic arch and cardiac anomalies in the offspring of vitamin A deficient rats *Am J Anat* 85 113 156 1949
WRISBERG H A Observationes anatomicae de venis azygis duplicibus atque huiusmodi venae varietatibus *Novis Commentariis Societatis Reg Scient* 8 14 1777 *Commentationum medicarum physiologicarum anatomici et obstetrici argumenti* 1 127 149 1800
YOUNG M O Common trunk of pulmonary veins tributary to the portal vein with a multiple cardiac anomaly *Arch Path* 44 169-172 1947

Segmental Bronchi and Bronchopulmonary Segments

CHEVALIER L. JACKSON, M.D., *Philadelphia, Pennsylvania*

From the Department of Laryngology and Bronchoesophagology, Temple University School of Medicine, Philadelphia, Pa.

THE concept of the bronchopulmonary segment may be said to date from the writings of Ewart[1] whose classic treatise on the bronchi and pulmonary vessels was published in London in 1889. However little attention was paid to this concept and little or no clinical use made of it until the paper of Kramer and Glass[2] presented before the American Bronchoesophagological Association in 1932. This paper was a combined bronchoscopic and surgical study dealing with the diagnosis, localization and external drainage of pulmonary abscess. The authors sought to establish a smaller and more accurate unit of localization than the lobe, and they described the bronchopulmonary segment as not only an anatomic but also a pathologic unit, pointing out the importance of identification of the various segmental orifices and knowledge of the size, shape and topographic position of the outer surface of each associated segment on the chest wall. In an anatomic study of eighty pairs of human lungs they found the lobar and segmental branches to be constant in 85 per cent of the cases and they named these segments and their corresponding bronchi using a simple nomenclature based on their position in the lung. Furthermore, with specific relation to the problem of pulmonary abscess, they found that practically all abscesses have a definite position in one of the bronchopulmonary segments, and they emphasized the fact that the bronchoscopist holds the key position for information concerning bronchopulmonary suppurative disease. Two years later (in 1934) a paper by Nelson[3] appeared likewise calling attention to the importance of the study of bronchial anatomy in the management of pulmonary abscess, but particularly with respect to position for postural drainage. He pointed out the advantage of continuous postural drainage in a correct position over intermittent postural drainage of the kind generally practiced without regard to the anatomic direction of the bronchus draining the abscess or the location of its orifice in relation to other orifices. He stated that postural drainage attempted without consideration of these facts was not only valueless but also dangerous. Hardie Neil[4-6] has contributed a number of valuable papers on this subject, the first published in 1936. He brought to bear a large experience in comparative as well as human anatomy and a keen clinical sense. One of his outstanding contributions was a composite perimetric perspective diagram representing the position and relations of various segmental orifices as seen by the bronchoscopist. In a paper read in 1942 and published the following year Jackson and Huber[7] reiterated what others had said concerning the importance of the study of applied anatomy of the bronchi and lungs and particularly the significance of the concept of the bronchopulmonary segment. They suggested that the pathology of the bronchi and lungs. After prolonged laboratory and clinical studies they reviewed all the systems of nomenclature suggested by the numerous authors who had by that time contributed to this subject. They decided to work out a new terminology because none of those previously suggested satisfied them. They sought "a standard clinical terminology which will be acceptable to the bronchologist, the thoracic surgeon and the radiologist and which will meet with the

approval of the anatomist ' The nomenclature suggested by Jackson and Huber was as follows

Lobes		Segments
Right	Upper	Apical Posterior Anterior
	Middle	Lateral Medial
	Lower	Superior Medial basal Anterior basal Lateral basal Posterior basal
Left	Upper: Upper Division	Apical posterior Anterior
	Upper: Lower Division (Lingular)	Superior Inferior
	Lower	Superior Anterior basal Lateral basal Posterior basal

This nomenclature (Fig 1) has met with unexpectedly wide acceptance by anatomists[9] and clinicians of various specialties[10-12] Some of the comments concerning it are quoted in a Report of the Committee on Nomenclature of the American Broncho-Esophagological Association and published in its Transactions[13] Gray s standard textbook of anatomy[14] has adopted the terminology for its current (25th) edition At the New Orleans meeting of the American Association for Thoracic Surgery in 1948 this terminology was officially approved

In 1949 an international committee met in London at the invitation of Mr Victor Negus, President of the Fourth International Congress of Otolaryngology, and this committee, after several hours of deliberation, decided upon a terminology almost identical with that of Jackson and Huber though differing in the preference for the old term ' apical ' of the lower lobe for the segment called ' superior ' by Jackson and Huber This was really the only important difference The report of the aforementioned committee was carefully prepared by Brock[15] The nomenclature suggested by this committee has still not been adopted in the United States nor has it been adopted universally elsewhere although the Thoracic Society (British) adopted it * Boyden[16] advises that we hold to the Jackson Huber terminology until such a time as an official international committee can deal with these problems Boyden particularly prefers the terms "superior" and "subsuperior" for the upper segments of the lower lobe

CLINICAL IMPORTANCE OF BRONCHOPULMONARY SEGMENTS

Nomenclature is important and the general adoption of one set of names would certainly lead to better understanding of the literature, but even more important is the anatomic concept itself To the bronchoscopist the concept of the bronchopulmonary segment is important in two ways first, a knowledge of the topographic anatomy enables him to tell from the roentgenograms, and particularly from the lateral projections, how to chart his course in the bronchoscopic approach to a lesion or a foreign body, second such knowledge enables him, when he looks through the bronchoscope, to interpret the endoscopic findings intelligently, since he will know when he looks at a certain branch bronchial orifice just what direction its bronchus takes, and what the size shape and relations of its tributary segments are Furthermore he will be able to report his findings in such a way as to be of maximum value to the referring physician or surgeon and to fit in with the reports of the other clinicians and the radiologist

The clinical importance of bronchopulmonary anatomy, and particularly the segmental concept, might be summarized as follows (1) In abscess (Fig 2) such study facilitates both external surgical drainage and postural drainage, as well as endoscopic drainage and the endobronchial instillation, by means of a catheter or bronchoscope, of penicillin or other drugs as described by Metras[17] (2) Bronchiectasis is as emphasized by Overholt,[18] a segmental disease, and segmental resection is the order of the day especially in bilateral cases Leonomic resection of only the diseased segments (after careful complete mapping of all segments of both lungs) can often be carried out in patients who would have been considered inoperable a few years ago In 60 per cent of the cases of left lower lobe bronchiectasis the adjacent segment of the upper lobe must be removed along with the lower if the patient is to be cured (Fig 3) (3) In tumors early diagnosis may often be made by bronchoscopy when the lesion is segmental, causing only a segmental atelectasis, and although cure may require removal of the entire lobe or even the lung if the tumor is malignant, there will be a

* This nomenclature is shown on pages 139 141

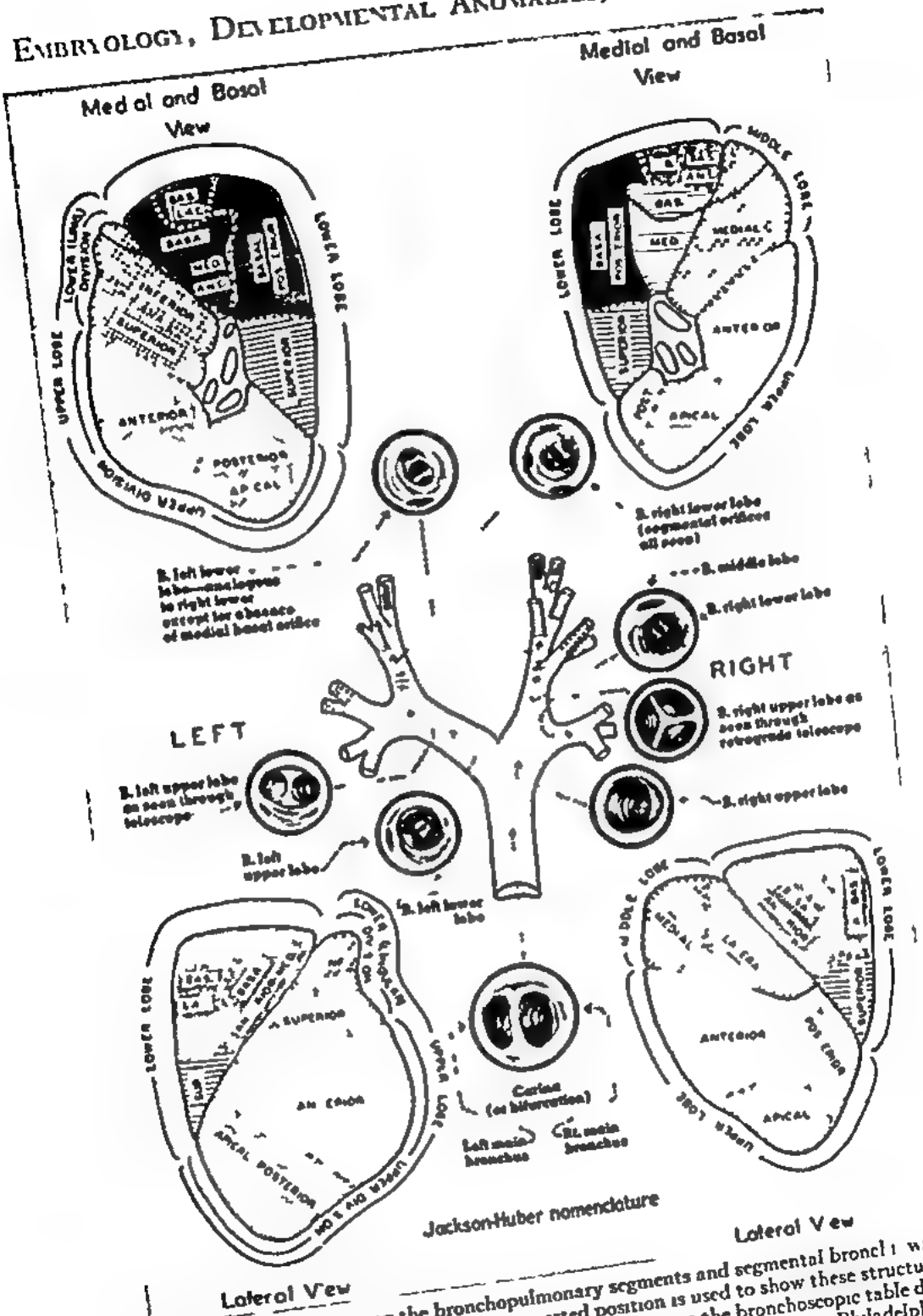

FIG 1 Diagrams showing the bronchopulmonary segments and segmental bronchi with the Jackson Huber nomenclature The inverted position is used to show these structures in the same relation as the bronchi and lungs of a patient on the bronchoscopic table during bronchoscopy (From JACKSON and JACKSON Bronchoesophagology Philadelphia 1950 W B Saunders Co)

better prospect of cure than if diagnosis is not made until the whole lobe or the whole lung is atelectatic As Foster Carter[18] has well stated, "perhaps the most important contribution to diagnosis is that recognition of a segmental lesion directs attention to the condition of the related bronchus" (4) In tuberculosis the sites of predilection are found to be not the apical but the posterior (or 'subapical') segment of the upper lobe and the supe



FIG 2 Abscess of the posterior segment of the upper lobe of the right lung.

of the cases

rior (or apical) segment of the lower Much light has been thrown on the pathogenesis of tuberculosis by the application of modern anatomic concepts to the study of the dis ease which as pointed out by the distin guished Spanish phthisiologist Suyé,[19] should be thought of as a tracheobronchopulmo-nary disease (5) In foreign body a knowledge of the segmental anatomy is of vital importance, and no case of foreign body in the air passages should be [illegible]

explained the mysterious inability to contact a foreign body seemingly easy to reach by show-

FIG 4 Foreign body (tooth inlay) in superior segmental branch of right lower lobe bronchus

ing that instead of being in the main bronchus as it appeared to be in the anteroposterior film, the foreign body was really in a segmental branch (Fig 4)

In view of the aforementioned facts it can be stated without hesitation that the concept of the bronchopulmonary segment, based upon the subdivision of the lung according to bronchial distribution is one of the most important practical principles in the present day diagnosis and treatment of bronchopulmonary disease

REFERENCES

1 EWART W The Bronchi and Pulmonary Vessels London 1889 J and A Churchill

2 KRAMER R and GLASS A Bronchoscopic localization of lung abscess Ann Otol Rhin & Laryng 41 121 1932

3 NELSON H P Postural drainage of the lungs Brit M J 2 251 1934

4 NEIL J H GILMOUR W and GWYNNE F J The broncho-pulmonary segments radiological pathological and bronchoscopic considerations with special reference to the subapical broncho-pulmonary segment M J Australia 2 165 1937

5 NEIL J H GILMOUR W GWYNNE F J MAIN W W and FAIRCLOUGH W A The anatomy of the bronchial tree and its clinical application Australian & New Zealand J Surg 8 118 1938

6 NEIL J H GILMOUR W and GWYNNE F J The anatomy of the bronchial tree Brit M J 1 495 1939

7 JACKSON C L and HUBER J F Correlated applied anatomy of the bronchial tree and lungs with a system of nomenclature Dis of Chest 9 1 8 1943

8 BOYDEN E A Intrahilar and related segmental anatomy of the lung Surgery 18 706–731 1945

9 GRANT J C D Method of Anatomy Baltimore 1948 The Williams and Wilkins Co

10 OVERHOLT R H and LANGER I A new technique for pulmonary segment resection Surg, Gynec & Obst 84 257 1947

11 SCANNELL J G (a) A study of variations of the bronchopulmonary segments in the left upper lobe J Thoracic Surg 16 530–537 1947 (b) A study of variations of the bronchopulmonary segments of the right upper lobe J Thoracic Surg 17 232 237 1948 (c) An anatomic approach to segmental resection J Thoracic Surg 18 64 1949

12 WISHART D L S Bronchography in bronchiectasis in children Ann Otol Rhin & Laryng 46 404 1947

13 JACKSON C L Report of the Committee on Nomenclature Tr Am Broncho-Esophagol Soc pp 183 188 1948

14 GRAY H Anatomy of the Human Body 25th ed Philadelphia 1948 Lea & Febiger

15 BROCK R C The nomenclature of bronchopulmonary anatomy Thorax 5 222 1950

16 BOYDEN E A A critique of the international nomenclature on bronchopulmonary segments Dis of Chest 23 266–269 1953

17 METRAS H L Arbre Bronchique Paris 1948 Vigot Frères

18 FOSTER CARTER A F and HOYLE C The segments of the lungs a commentary on their investigation and morbid radiology Dis of Chest 11 511 564 1945

19 SAYÉ L Tuberculosis Traqueobroncopulmonar Buenos Aires 1950 Guillermo Kraft Limitada

II. PHYSIOLOGY AND PATHOLOGY

3

Functional Anatomy of the Lung*

LEROY D VANDAM, M.D., *Boston, Massachusetts*

A GREAT many new and important observations regarding pulmonary function have been made. It has been the author's experience however that many reports dealing with the physiology of the lungs neglect the anatomic substratum on which function depends. While anatomy has been underemphasized by some it is worth while to recall that the lungs possess an anatomic structure which not only subserves efficient respiration but also provides an efficient defense against infection and injury. It seems imperative then that function of the lungs be reviewed in an anatomic setting since nowhere with one possible exception[1] is there readily at hand a review of this nature. In the discussion which follows the anatomic structures of the lung will be considered individually.

Primary Lobule. Before entering into a discussion of specific features of the lung reference will first be made to the basic unit of the lung known as the primary lobule. This is advisable in order to establish the terminology which will henceforth be recurrent in this review. The concept of the primary lobule is the result of the painstaking reconstructions of William Snow Miller and early forebears. It will be seen in Figure 1 that the bronchi repeatedly divide until the small end portion of the air conducting system the terminal bronchiole is formed. This is an important landmark for respiratory gas exchange is carried out beyond this point. Alveoli are present in the walls of the next subdivision the respiratory bronchiole and there is subsequent partition into alveolar ducts atria saccules and finally alveoli. The primary lung lobule comprises an alveolar duct and all of its offshoots. Primary lobules are grouped to give rise to larger units secondary and tertiary lobules which become macroscopically visible. A larger entity of significance is the lung segment several of these segments make up a lobe of the lung.

Larynx. Ordinarily the larynx is not mentioned in connection with pulmonary physiology. Occupying a commanding position at the entrance to the air passages the larynx might well be implicated in respiratory exchange. Most people call the larynx the voice box, yet to paraphrase Negus[2] a moment's reflection will reveal that many species with no voice at all have elaborately developed larynges. In his monograph on the comparative anatomy of the larynx Negus pointed out that the larynx is primarily a valve of the respiratory tract. Originally a sphincter to guard the pulmonary outgrowth of the pharynx against inundation the adult human larynx has evolved to the point where it is a muscular organ having the capacity for constriction and dilatation (Fig. 2.) Analysis of the functions of the larynx uncovers the role played in respiration circulation and maintenance of intrathoracic pressure.

Those who have directly observed the larynx during vocal cord movements will remember that the vocal cords fluctuate with respiratory movements. During inspiration the glottis is widened and during expiration narrowed. Acting as a narrow portal, the larynx participates in the development of the negative intrapleural pressure which is so vital for cardiac filling and output. A relative obstruction to the entry of air provides for a greater suction effect with consequent dilatation and filling of the intrathoracic vessels. In expiration the reverse takes place with compression and passage onward of the blood already in the vessels. Whether the movements of the vocal cords assist in the process of gas distribution in the alveoli is as yet an unanswered question. It is said that a tracheostomy will result in an elevation of the respiratory rate, perhaps on the basis of carbon

* Reprinted with changes from *Anesthesiology* 13: 133, 141, 1952.

dioxide accumulation Too many intangibles enter into the tracheostomy situation for conclusions to be drawn, but it would be interesting to make controlled respiratory and circulatory measurements in such a case

From the standpoint of defense against infection and the regulation of intrathoracic pressure, the larynx has other functions For a cough to be productive, air is entrapped and positive pressure accumulated before the expulsive efforts of the respiratory muscles are instituted After a short inspiration the laryngeal sphincter is closed, whereupon the intrinsic and extrinsic muscles of the chest forcibly contract This is the Valsalva maneuver which eventuates in an elevated intrathoracic pressure In coughing the larynx suddenly opens and the accumulated positive pressure fulfills the purpose of the tussive reflex To raise intrathoracic pressure for bearing down purposes, the larynx is kept closed to allow the abdominal muscles to contract against a fixed diaphragm The dire consequences of prolonged positive intrathoracic pressures have been evident in several reports concerning "bedpan deaths"[4] Beecher[5] has recently called attention to the relative ineffectiveness of cough when an endotracheal tube maintains the patency of the larynx or when the chest is open during thoracic surgery Similarly, a patient with a tracheostomy finds it difficult to expel secretions

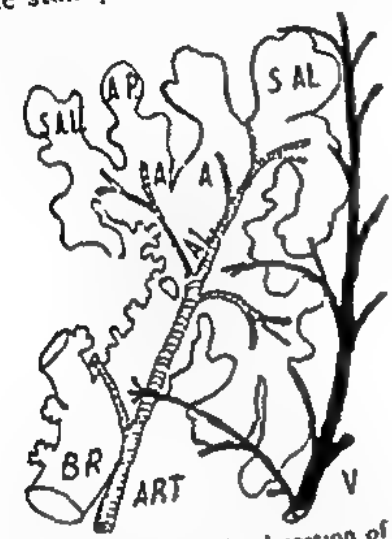

FIG 1 Schematic longitudinal section of the lung beyond the terminal bronchiole A primary lobule comprises an alveolar duct (D AL) atria (A) alveolar saccules (S AL) and pulmonary alveoli (A P) A respiratory bronchiole (B R) with alveoli in its walls usually branches into several ducts It can be seen that the pulmonary artery (ART) is always closely associated with the bronchial passages while the pulmonary vein (V) is situated as far removed from the bronchioles as possible (Redrawn from William Snow Miller The Lung second edition Courtesy of Charles C Thomas Publisher Springfield Illinois)

FIG 2 Dissection of the larynx of a man to illustrate the musculature The ddator components consisting of the posterior cricoarytenoid muscle (PCA) and the sphincteric group of muscles are pictured In the latter classification are the aryepiglottic (AE) interaryteno d (IA) lateral cricoarytenoid (LCA) and thyroarytenoid (TA) muscles H = hyoid bone and E = epiglottis (Redrawn from Comparative Anatomy and Physiology of the Larynx V I Negus Grune and Stratton Inc)

The stronger vocal portion of the larynx is made up of the ventricular bands or so-called false cords That this is so may be apparent in Figure 3 The ventricular bands are capable of effectively denying entrance to the glottis as any anesthesiologist who has witnessed laryngospasm will readily testify

Tracheobronchial Tree The tracheal tree originates just below the cricoid cartilage of the larynx approximately at the level of the sixth cervical vertebral body The point of bifurcation of the trachea is marked by the angle of Louis or the fourth to fifth thoracic vertebral body Not only is the right main stem bronchus more directly continuous with the trachea, but it is larger so that it is not uncommon for foreign bodies to lodge or endotracheal tubes to be advanced into the right side of the bronchial tree Both trachea and bronchi have in their walls partial cartilaginous rings the apparent function of which is to

maintain patency and allow for changes in caliber at the same time Without support the air passages might collapse during inspiration and there would be little rationale for the presence of smooth muscle unless the rings were incomplete If the cartilages are weakened

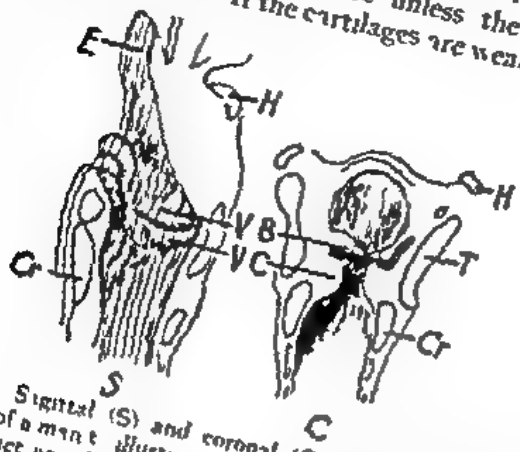

FIG 3 Sagittal (S) and coronal (C) sections of the larynx of a man illustrate the valves The vocal cords (V C) act as inlet valves while the ventricular bands (V B) or false cords perform as outlet valves The latter are more muscular hence more efficient CR = cricoid cartilage T = thyroid cartilage and H = hyoid bone (Redrawn from Comparative Anatomy and Physiology of the Larynx V L Negus Grune and Stratton Inc)

as in prolonged pressure from goiter at some times happens that the trachea collapses after thyroidectomy

The respiratory passages are with a few exceptions lined from the nostrils to terminal bronchioles by a ciliated columnar epithelium with many interspaced mucus secreting goblet cells A good many measurements of ciliary activity have been made but those of Hilding[6] are most intriguing and appropriate from a practical viewpoint Hilding has demonstrated in the intact frontal sinus of the dog as well as in isolated hens trachea that cilia moving plugs of mucus are capable of generating negative pressures up to 40 mm of water Occluding masses of mucus were passed through these trachea by ciliary action while the lower end was connected with a water manometer Under the continued traction of cilia, mucous plugs were attenuated into fine films which burst easily with slight manipulation of the experimental preparation The latter observation corresponds nicely with the clinical observation that atelectasis is sometimes relieved by relatively inconsequential therapeutic means Certainly lack of ciliary force is not to be underestimated as a factor in atelectasis In the administration of anesthesia possible depressant effects of preoperative medication and anesthetics on ciliary activity must be reckoned with in the prevention of postoperative pulmonary complications Virulent bacteria and aspirated necrotizing in-

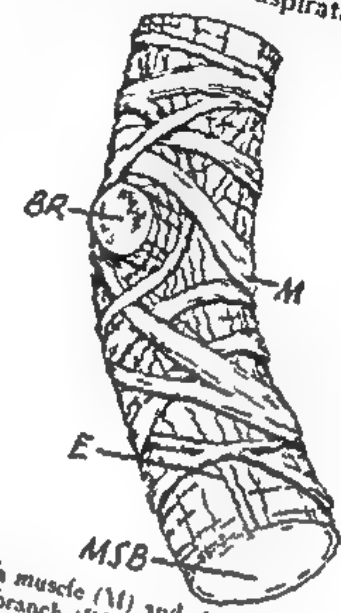

FIG 4 Smooth muscle (M) and elastic fibers (E) at a place where a branch (BR) is given off the main stem bronchus (M S B) The smooth muscle with a spiral type of arrangement can effect changes in the length and caliber of the bronchus The elastic fibers are essentially longitudinal in direction (Redrawn from William Snow Miller The Lung second edition courtesy of Charles C Thomas Publisher Springfield Illinois)

testinal or gastric contents by destroying the protective respiratory epithelium with its cilia may clearly bring about overwhelming infection This is probably in part the explanation for the origin of acute laryngotracheal bronchitis or the aspiration pneumonia seen after periods of unconsciousness

Vasculature of the Lung Although there are repeated clinical reminders of the fact few think of the lungs as muscular organs In 1822 Reisseisen[7] carefully dissected the smooth muscle of the trachea and others[8] have since elaborated on his description of the smooth muscle The basic plan of distribution is that of a branched tubular network, neither longitudinal nor circular, extending outward around the tracheobronchial tree (Fig 4) as far as the alveoli There is associated with the muscle an interwoven elastic layer (Fig 4) so that in essence a myo-elastic coating for the air passages exists in the walls between the mucosa and cartilage Although the muscle is most

developed and concentrated about the larger passages it is far greater in proportion to the size of the lumen of the bronchiole In the latter location the so-called bronchospasm of asthma or the bronchospastic response to histamine irritant or parasympathomimetic drugs can literally shut off air exchange Even if smooth muscle does not extend over the alveoli as does the elastic tissue it extends as far as the alveolar sacs where in cross section it resembles tiny sphincters

The physiology and pharmacology of the muscle of the lungs has been somewhat confused by conflicting animal experiments but in general this muscle reacts as does smooth muscle elsewhere in the body Indeed if it is remembered that the lungs are in the embryo an outgrowth of the foregut the lung muscle proves to be similar to that of the bowel Movements of the bronchi can be observed with ease through the bronchoscope as well as radiographically with opaque media There are transmitted movements from the heart and great vessels and twisting and turning movements to accommodate the lungs to varying capacities of the thorax During inspiration the bronchi increase in length and breadth Part of the increased length may be the result of descent of the hilus of the lung but the major change is the aftermath of smooth muscle relaxation and the pull of negative intrapleural pressure In expiration a reversal takes place with consequent diminution in caliber Whether these changes in caliber are passive as some assert or neurogenic in origin is of small moment Morphologically the smooth muscle is abundantly innervated by the autonomic nervous system Further more it is alleged that the bronchi evince peristaltic movements which approach a state called tracheobronchial vomiting when foreign matter is being expelled

With the foregoing resume a number of practical points come to mind For one thing as Macklin[3] pointed out it may be absurd to speak of the anatomic dead space as a fixed entity based on cast preparations in cadavers It is a variable space and Douglas and Haldane[4] have shown that it can be augmented as much as four times during strenuous exercise From a pharmacologic standpoint since the bronchial muscles are active in cough it seems reasonable to assume that opiates affect the cough reflex at several levels A well known observation is that opium derivatives after a brief stimulatory phase inhibit smooth muscle Hence, morphine has the inherent possibility of dulling central perception, depressing the medullary phase of the cough reflex and peripherally inhibiting cilia and smooth muscle The bronchial muscles are under autonomic nervous regulation and there is abundant evidence both clinical and experimental that sympathomimetic drugs create bronchodilatation and parasympathomimetics the reverse[5] In the latter connection, the anesthetist is aware that several agents cyclopropane curare and pentothal for example, tend to foster bronchoconstriction

Innervation of the Lung The nervous supply to the lung is of importance with the advent of attempts to interrupt the nerves either temporarily or permanently in disease states Nervous influence in bronchial asthma has always been more than suspect while diffuse vasospasm of neurogenic origin has been held responsible for some of the signs and symptoms of pulmonary embolism[6] Recently the problem of interrupting afferent pain pathways has confronted those who find obliged to treat sufferers with inoperable pulmonary disease[7] At the present time results of operation for the several entities mentioned have been inconclusive[8] The fault may well lie in the nerve distribution which does not lend itself readily to dissection without compromising other vital functions

In general the innervation of the lungs is almost identical with that of the heart[9] Sympathetic motor fibers arise in the first five thoracic segments and proceed to the pulmonary plexus by way of the sympathetic ganglions or cardiac nerves Parasympathetic motor fibers from the vagus arising below the inferior laryngeal nerve in a number of filaments also traverse the mediastinum to reach the pulmonary plexuses The latter, which are found anterior and posterior to the hilus not only receive a dual supply but are interconnected with one another unilaterally and bilaterally as well as with the cardiac plexuses Familiarity with the complex distribution of the autonomic nervous system clarifies in part the difficulty encountered in completely denervating the lungs or in selectively sectioning either autonomic division One of the most interesting reports is that of Klassen[10] who sectioned the vagus on one side with the result

that pain sensation from the tracheobronchial passages as well as the cough reflex was uni lateral obtunded However, when both vagi were severed below the inferior laryngeal nerves there arose the undesirable sequela m

of the interstitial tissues In the latter categor are the trachea bronchi great vessels, nerves and supporting elements Luschka designated the pulmonary arteries as the vasa publica and the bronchials as the vasa privata or nutri

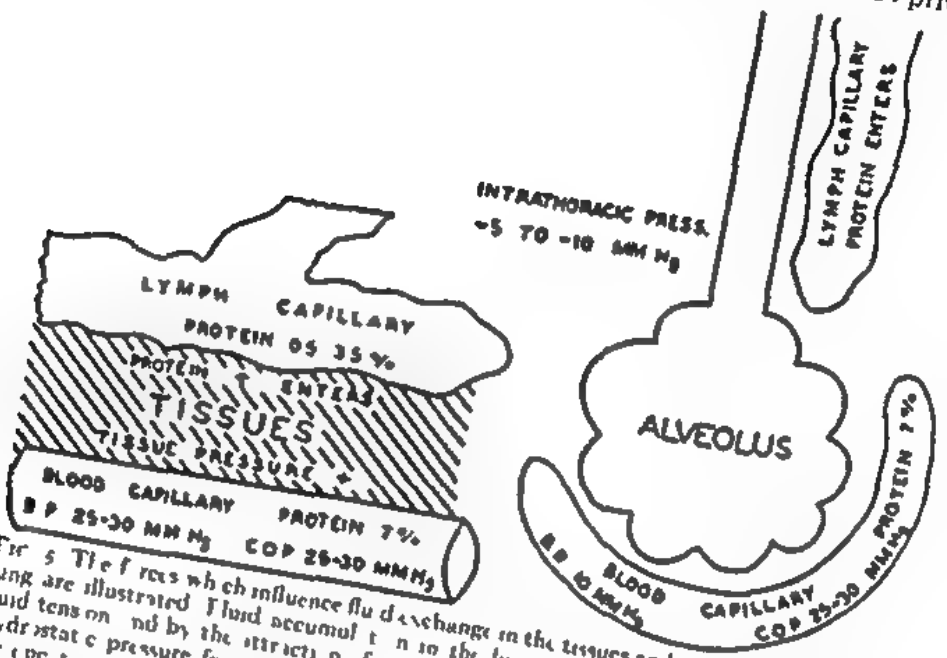

Fig 5 The forces which influence fluid exchange in the tissues and in the alveoli of the lung are illustrated Fluid accumulation in the lung is aided by the absence of tissue fluid tension and by the attraction of negative intrathoracic pressure Fortunately the hydrostatic pressure forcing fluid out of the capillaries is more than counterbalanced by the tissue pressure (Reprinted by permission of the author and publishers from Cecil Kent Drinker Pulmonary Edema and Inflammation Cambridge Mass Harvard University Press 1945)

he gastrointestinal tract usually associated ith extensive vagotomy Furthermore bron hospasm in asthmatic patients thus treated was not alleviated Since autonomic ganglions are to be found throughout the interstitial tissues it is not unlikely that bronchospasm is the result sometimes of intrinsic reflexes A similar situation prevails in the denervated smooth muscle of the bowel To summarize what seems to be fairly certain about nervous activity it can be said that the sympathetics dilate the bronchi constrict the bronchial arteries and decrease secretion while the para sympathetics perform oppositely

Blood Supply to the Lungs The dual blood supply to the lungs has always intrigued the anatomist and lately the physiologist The pulmonary arteries with a low blood pressure subserve for respiratory gas exchange while the bronchial arteries with a systemic pressure are concerned with the nutritional maintenance

The pulmonary arteries like the cerebral and coronary vessels seem to be very little under neurogenic influence, but more under the regulation of circulating metabolic gases like oxygen and carbon dioxide Recent experiments suggest that concentrations of the same gases in the alveoli may regulate the caliber and resistance to passage of blood through pulmonary vessels If this is so the absence of cyanosis when there is blood flow through non aerated pulmonary tissue is explainable On the whole pulmonary arterial tone is low a circumstance which provides for a little resistance in the lesser circuit and a greater ability to adapt to changing blood volumes Drinker has pointed out that the lungs because of their aeriform nature lack the capacity to develop a pressure in the interstitial tissues which in other parts of the body decreases the tendency toward edema formation It is fortunate, from the latter standpoint, that

the hydrostatic driving force in the pulmonary capillaries is relatively low mean pressure equal to 10 mm of mercury and counteracted by a blood oncotic pressure equal to 25 to 30 mm of mercury In other words the tendency toward fluid release from the capillaries is

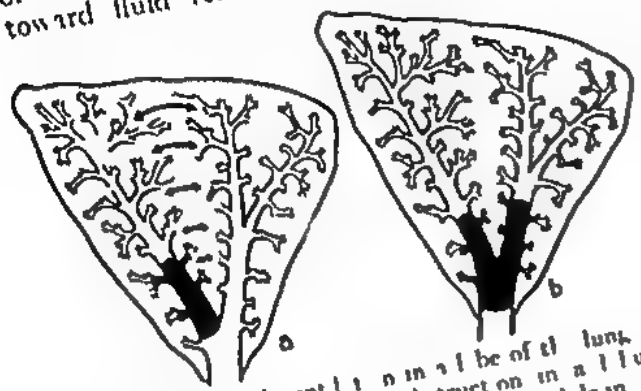

FIG 6 Collateral ventilation in a lobe of the lung In figure a where there is obstruction in a lobular bronchus collateral ventilation is effective while in b blockage of the main bronchus prevents collateral ventilation (Reprinted by permission of the authors and publishers from Alley R D and Lindskog G E Pharmacologic Factors Influencing Collateral Respiration Possible Relation to the Etiology of Pulmonary Complications Annals of Surg 128 497 508 (Sept) 1948)

overbalanced by forces which effect the opposite result (Fig 5) Furthermore the lymphatics of the lung with a distribution down to the terminal bronchioles play a great part in the resorption of fluid [19]

The bronchial arteries have a diverse anatomic origin Usually the left lung receives two of these vessels and the right one from the aorta internal mammary or intercostal arteries To reiterate the normal purposes of the bronchial arteries is nutritive for the interstitial tissues Therefore the usual extent of distribution is no farther than the terminal bronchioles Bronchial veins excluding those to the mediastinum drain into the pulmonary venous system and thence to the left auricle The possibility that bronchial venous contamination of oxygenated pulmonary venous blood might lead to arterial oxygen unsaturation has been the impetus for a number of studies on the bronchial circulation [21] More over since the bronchial vessels are under neurogenic regulation and the mean arterial pressure is high, it has been thought that this system of vessels might be implicated in paroxysmal types of pulmonary edema of central origin It is admittedly difficult to measure bronchial artery blood flow in man and not much easier in animals However Bruner and Schmidt[22] have estimated the maximal flow through the bronchial arteries of the dog to be not more than 1 per cent of the cardiac output and in average circumstances much less The minor nature of this figure suggests that there is little likelihood of implicating the blood flow of the bronchial artery in the genesis of paroxysmal pulmonary edema Similarly contamination of pulmonary venous blood with the above estimated bronchial blood flow is hardly sufficient to change significantly the oxygen tension of arterial blood

In pathologic situations the bronchial artery achieves a greater significance Wounds of the lung or pathologic erosions involving the bronchial artery are more likely to be fatal because of existing systemic blood pressure in these vessels It is small wonder that pulmonary arterial occlusion by embolus seldom eventuates in frank infarction for the bronchial arteries maintain nutrition [23] As Liebow and co-workers[24] have shown in most pathologic occlusions of the pulmonary artery, the bronchial arteries by extensive collateral production take over the respiratory function of the pulmonary artery In some types of congenital heart disease with cyanosis in which there is pulmonary atresia stenosis or reduced pulmonary arterial blood flow extensive collateral circulation from the bronchial and other systemic vessels often supplies the lungs with blood for oxygenation [25]

Collateral Ventilation in the Lungs There is another defensive mechanism in the lungs which has not yet been accorded general recognition, and that is the concept of collateral ventilation During the course of experimental studies of atelectasis Van Allen and Lindskog[26] noticed that obstruction of smaller bronchi did not as expected uniformly produce lobular or segmental collapse Measurements of air flow soon revealed that the blocked pulmonary substance was being fed collaterally by air from adjacent lobules (Fig 6) Further investigation established the fact that collateral ventilation as it was designated was present during quiet respiration to the extent that at least 10 per cent of the ordinary ventilation to the obstructed tissues was supplied Others[28] have not only measured collateral ventilation in human beings but have also estimated its magnitude to be at least 40 per cent of the normal air flow It is apparent that there must

the hydrostatic driving force in the pulmonary capillaries is relatively low mean pressure equal to 10 mm of mercury and counteracted by a blood oncotic pressure equal to 25 to 30 mm of mercury In other words the tendency toward fluid release from the capillaries is

FIG 6 Coll ter l ve ul r n n l be of the lung In figure A shows that an obstruction in a l l ular bronchus collateral ventilation is effective n l ln B blockage of the m n bronc l s prevents collateral vent lati n (Reprinted by perm n n f the auth rs and publ shers from Alley R D and Lindal E G I Pharmacologic I actors I l uencing Collateral Respira t n Possible Relation to the Ent l gy of Pulmonary Complications Annals of Surg 128 497 508 (Sept 1948)

overbalanced by forces which effect the opposite result (Fig 2) Furthermore the lymphatics of the lung with a distribution down to the terminal bronchioles play a great part in the resorption of fluid [9]

The bronchial arteries have a diverse anatomic origin Usually the left lung receives two of these vessels and the right one from the aorta internal mammary or intercostal arteries To reiterate the normal purposes of the bronchial arteries is nutritive for the interstitial tissues Therefore the usual extent of distribution is no further than the terminal bronchioles Bronchial veins excluding those to the mediastinum drain into the pulmonary venous system and thence to the left auricle The possibility that bronchial venous contamination of oxygenated pulmonary venous blood might lead to arterial oxygen unsaturation has been the impetus for a number of studies on the bronchial circulation [10] More over, since the bronchial vessels are under eurogenic regulation and the mean arterial pressure is high, it has been thought that this system of vessels might be implicated in paroxysmal types of pulmonary edema of central origin It is admittedly difficult to measure bronchial artery blood flow in man and not much easier in animals However, Bruner and Schmidt [11] have estimated the maximal flow through the bronchial arteries of the dog to be not more than 1 per cent of the cardiac output and in average circumstances much less The minor nature of this figure suggests that there is little likelihood of implicating the blood flow of the bronchial artery in the genesis of paroxysmal pulmonary edema Similarly contamination of pulmonary venous blood with the above estimated bronchial blood flow is hardly sufficient to change significantly the oxygen tension of arterial blood

In pathologic situations the bronchial artery achieves a greater significance Wounds of the lung or pathologic erosions involving the bronchial artery are more likely to be fatal because of existing systemic blood pressure in these vessels It is small wonder that pulmonary arterial occlusion by embolus seldom eventuates in frank infarction for the bronchial arteries maintain nutrition [12] As Liebow and co-workers [13] have shown in most pathologic occlusions of the pulmonary artery, the bronchial arteries by extensive collateral production take over the respiratory function of the pulmonary artery In some types of congenital heart disease with cyanosis in which there is pulmonary stenosis or reduced pulmonary arterial blood flow, extensive collateral circulation from the bronchial and other systemic vessels often supplies the lungs with blood for oxygenation [14]

Collateral Ventilation in the Lungs There is another defensive mechanism in the lungs which has not yet been accorded general recognition, and that is the concept of collateral ventilation During the course of experimental studies of atelectasis Van Allen and Lindskog [15] noticed that obstruction of smaller bronchi did not, as expected uniformly produce lobular or segmental collapse Measurements of air flow soon revealed that the blocked pulmonary substance was being "fed" collaterally by air from adjacent lobules (Fig 6) Further in vestigation established the fact that collateral ventilation, as it was designated, was present during quiet respiration to the extent that at least 10 per cent of the ordinary ventilation to the obstructed tissues was supplied Others [16] have not only measured collateral ventilation in human beings but have also estimated its magnitude to be at least 40 per cent of the normal air flow It is apparent that there must

be communication between peripheral units of the lung for maintenance of the aforementioned type of ventilation On an embryologic basis it was not to be expected that collateral channels would be present for the lungs develop by a process of repetitive budding and subdivision Most morphologists including Miller [2] now agree that there are such channels instead of the artefacts originally thought to be demonstrated [2] Probably the pathways for collateral exchange are identical with Kohn's pores known to pathologists for a long time

The clinical significance of collateral air flow may be at least as important as collateral circulation Apparently lung function is preserved not only in the circulatory but in the respiratory sphere as well The effectiveness of cough is enhanced by collateral intralobar air channels can be expected to result in an extension of atelectasis and infection It is probable that many measures directed toward minimizing postoperative pulmonary complications conserve collateral ventilation Thus avoidance of tight abdominal binders minimizing wound pain encouraging cough deep breathing and early ambulation all abet the lungs natural defenses

SUMMARY

The foregoing review has been an attempt to present succinctly some of the aspects of the anatomic substratum of pulmonary function and defense Inherent in this discourse has been the theme that pulmonary function is intimately related to structure The lungs possess a wealth of natural defenses Most measures designed to prevent pulmonary complications merely support the lung s natural ability to maintain a normal status

REFERENCES

1 CHURCHILL, E D Segmental and lobular physiology and pathology of lung *J Thoracic Surg* 18 279–293 1949
2 MILLER W S The Lung Springfield Ill 1947 Charles C Thomas
3 NEGUS V E The Comparative Anatomy and Physiology of the Larynx New York 1949 Grune and Stratton
4 MCGUIRE J GREEN R S et al Bed pan deaths *Am Prac & Digest of Treat* 1 23 28 1950
5 BEECHER H K Principles problems, practices of anesthesia for thoracic surgery *Arch Surg* 62 206–238 1951
6 HILDING A C Some further experiments in production of negative pressure in trachea and frontal sinus by ciliary action *Ann Otol Rhin & Laryng* 54 725 738 1945
7 REISSEISEN F D Ueber den Bau der Lungen Berlin 1822
8 MACKLIN C C The musculature of bronchi and lungs *Physiol Rev* 9 1–60 1929
9 JACKSON C Bronchoscopy and Esophagoscopy 2nd ed Philadelphia 1927 W B Saunders Company
10 DOUGLAS G D and HALDANE J S Capacity of air passages under varying physiological conditions *J Physiol* 45 235 238 1912
11 DETAKATS G BECK W D and FENN G K Pulmonary embolism—an experimental and clinical study *Surgery* 6 339–36– 1939
12 MORTON D R KLASSEN K P and CURTIS G M Clinical physiology of human bronchi pain of tracheobronchial origin *Surgery* 28 699–704 1950
13 PHILLIPS E W and SCOTT W J M Surgical treatment of bronchial asthma *Arch Surg* 19 1425 1456 1929
14 BRAEUCKER, W Der Brustteil des Vegetativen Nervensystems und Seine Klinisch Chirurgische Bedeutung *Beitr z Klin Tuberk* 56 1–65 192
15 KLASSEN K P MORTON D R and CURTIS G M Physiological evaluation of vagus section for bronchial asthma *J Thoracic Surg* 20 552 570 1950
16 DEBURGH D Physiology of the bronchial vascular system *Harvey Lect* 31 234 236 1935
17 LUSCHKA H Die Anatomie des Menschen I Abt, II Tubingen 1863
18 DIRKEN M N J and HEEMSTRA H Alveolar oxygen tension and lung circulation *Quart J Exper Physiol* 34 193 211 1948
19 DRINKER C K Pulmonary Edema and Inflammation *Cambridge Mass* 1945 Harvard University Press
20 COURTICE, F C Absorption of fluids from lungs and pleural cavities *Proc Roy Australasian Coll Phys* 4 77 83 1949
21 BRUNER H D and SCHMIDT C F Blood flow in bronchial artery of anesthetized dog *Am J Physiol* 148 648–666 1947
22 BRUNER H D The bronchial artery in pulmonary infarction *North Carolina M J* 8 306–310 1947
23 LIEBOW A A HALES M R HARRISON W, BLOOMER W and LINDSKOG G E Genesis and functional implications of collateral circulation of lungs *Yale J Biol & Med* 22 637–650 1950
24 BING R J VANDAM L D and GRAY F D JR Physiological Studies in congenital heart disease results of preoperative studies in patients with tetralogy of Fallot. *Bull. Johns Hopkins Hosp* 80 121 141 1947
25 VAN ALLEN C M LINDSKOG G E and RICHTER H G Collateral respiration transfer of air collaterally between pulmonary lobules *J Clin Invest gation* 10 559 500, 1931
26. BAARSMA D R DIRKEN M N J and HUIZINGA, E Collateral ventilation in man. *J Thoracic Surg* 17 252–263 1948
27 LOOSLI C G Interalveolar communication in normal and pathological mammalian lungs. *Arch Path* 24 743 1937

4

Normal Physiology of Respiration

ARTHUR A. SIEBENS, M.D., *New York, New York*

Associate Professor of Physiology, State University of New York College of Medicine at New York City

OXYGEN and carbon dioxide are vital constituents of the internal environment. The abundance of one is essential to life and the accumulation of the other is incompatible with survival. Extracellular gas composition is maintained within critical limits by the replacement of oxygen at the rate of its use and by the elimination of carbon dioxide at the rate of its production. This ceaseless exchange of gases between the living organism and its environment makes up the subject of respiration.

The fundamental problem with respect to this exchange in a multicellular organism is the establishment of adequate gaseous communication between the individual cell and the atmosphere. This is accomplished by two circulatory systems—one for air and the other for fluid, a paired organ specialized for bringing a broad expanse of circulating fluid into intimate contact with air, and a fluid borne carrier compound capable of taking up and releasing oxygen and carbon dioxide. A discussion of respiration falls logically, therefore, into subheadings dealing with (1) the pumping of air to and from the alveoli, (2) the transfer of oxygen and carbon dioxide between blood and air in the lungs, (3) characteristics of transport between the lungs and extracellular fluid and (4) the circulation of blood. The regulation of these interrelated phases in accordance with the needs of the organism is a fifth major topic.

Movement of gases is common to the four phases just enumerated. The force producing this movement is pressure. A pressure difference between the atmosphere and the alveoli causes air to flow in and out of the lungs. Oxygen passes from alveolus to pulmonary capillary and carbon dioxide from capillary to alveolus along pressure gradients. Blood circulates through the lungs and systemic circuits because the pressures in the pulmonary artery and aorta exceed those in the pulmonary and caval veins. And finally, the exchange of gases between corpuscle and plasma and between plasma and interstitial fluid is a function of the pressure differences. The relationship between pressure, flow and resistance is therefore basic to gas exchange. It applies to the flow of air in the respiratory passages, the flow of blood in the circulatory system and the transfer of oxygen and carbon dioxide across the alveolar capillary membrane.

THE RESPIRATORY PUMP

Air flows into the lungs through the open glottis whenever intrapulmonary air pressure falls below atmospheric pressure. Flow ceases when these two pressures are equal and reverses itself when alveolar pressure exceeds atmospheric. These fluctuations are the result of alternate expansion and contraction of the internal dimensions of the thorax, cyclic variations which, in turn, are attributable to lengthening and shortening of the intercostal muscles and diaphragms. The activity of these striated muscles then is normally essential for exchange of gases between the lung and atmosphere.

Static Measurements. Transpulmonary pressures. During quiet breathing, contraction of respiratory muscles is characteristic of inspiration only, the return of these muscles to their pre-inspiratory length being unassociated with contraction of antagonists. It follows therefore that inspiration is opposed by forces which, in the absence of active contraction of muscles, restore the thorax to its original dimensions. The elasticity of the lung is among these forces. Indeed, the dimensions of the lung thorax system during muscular relaxation represent an equilibrium between the elastic recoil of the lungs, a force directed inwardly, and the elastic attributes of the parietes, a force directed outwardly. Quiet breathing is accomplished by intermittent displacement of this equilibrium during inspiration.

A pressure difference between the inside and outside of the lung surfaces is the force which keeps the lung expanded This difference is created during procedures on the open chest by raising the intrapulmonary pressure above the extrapulmonary or atmospheric pressure It exists during normal breathing because subatmospheric pressure outside the lung surfaces is below the pressure within the lungs If continuity between the atmosphere and the outside of the lung is established either from within by rupture of visceral pleura or from without by perforation of the chest wall this pressure difference is eliminated and the lung collapses An expanded state is maintained normally because the lungs enclosure is sealed

The force required to maintain the lungs expansion increases with inflation Representative figures for the transpulmonary pressure difference in the expiratory position are 4 cm of water as contrasted to 16 cm of water in the inspiratory position During the respiratory cycle therefore there occur pressure fluctuations between the atmosphere and the extrapulmonary intrathoracic structures arising from the elastic attributes of the lung This respiratory pump operates normally at subatmospheric pressures a circumstance favoring the influx of blood from the periphery to the thorax Preservation of this effect is among the advantages of respirators incorporating a negative phase

Much interest has been expressed within recent years in measuring how much transpulmonary pressure increases as lung volume increases The term compliance has been introduced in defining the elastic attributes of the lung Specifically compliance is the change in lung volume measured when the breath is being held produced by an increase in transpulmonary pressure of 1 cm of water Normal values range from 0 09 to 0 33 L per cm of water increase in pressure difference between inside and outside of the lung Oral and intraesophageal pressures are usually measured in actual practice the former being atmospheric and equivalent to intrapulmonary and the latter being subatmospheric and proximate to pleural or extrapulmonary Stiffening of the lung or decreased compliance i e smaller volume changes per unit pressure increase is found in heart disease such as congestive failure and mitral stenosis and in diseases of the lung such as the pulmonary granulomas

Lung Volumes Because expiration proceeds independently of muscular effort the equilibrium position of the lung-chest system varies little during quiet breathing despite sizeable fluctuations in inspiration The volume of air contained in the lungs at the end of a

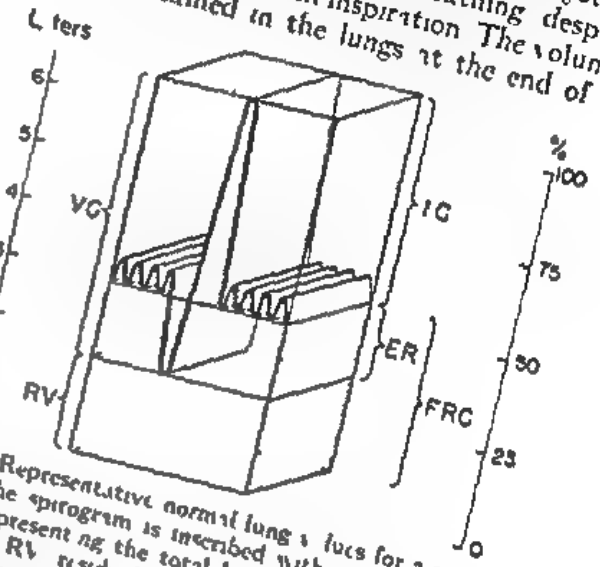

FIG 1 Representative normal lung volumes for a young man The spirogram is inscribed with a volumetric figure representing the total lung capacity VC vital capacity RV residual volume IC inspiratory capacity ER expiratory reserve FRC functional residual capacity

normal expiration is therefore a relatively stable quantity Because of its reproducibility this end expiratory volume or *functional residual capacity* is a useful point from which to measure other volumes Thus the *expiratory reserve* formerly known as the supplemental air is the volume which can be expired from the lungs from the end-expiratory position and the *inspiratory capacity* which includes the tidal volume plus what was formerly referred to as the complemental air is the volume which can be inspired from this position

Measurements of these two volumes and their sum the *vital capacity* are usually made from a spirogram an ink record relating time on the horizontal axis with change in lung volume on the vertical axis Figure 1 represents such a record inscribed within a three dimensional or volumetric schema of the *total lung capacity* It is clear from such a diagram that the vital capacity inspiratory capacity and expiratory reserve are changes in lung volume rather than actual volumes of air in the lungs These latter can be calculated only after the volume of air which cannot be voluntarily expelled the *residual volume* has been measured Normal values for these volumes

4

Normal Physiology of Respiration

ARTHUR A. SIEBENS, M.D., *New York, New York*

Associate Professor of Physiology, State University of New York College of Medicine at New York City

OXYGEN and carbon dioxide are vital constituents of the internal environment. The abundance of one is essential to life and the accumulation of the other is incompatible with survival. Extracellular gas composition is maintained within critical limits by the replacement of oxygen at the rate of its use and by the elimination of carbon dioxide at the rate of its production. This ceaseless exchange of gases between the living organism and its environment makes up the subject of respiration.

The fundamental problem with respect to this exchange in a multicellular organism is the establishment of adequate gaseous communication between the individual cell and the atmosphere. This is accomplished by two circulatory systems—one for air and the other for fluid—a paired-organ specialized for bringing a broad expanse of circulating fluid into intimate contact with air, and a fluid borne carrier compound capable of taking up and releasing oxygen and carbon dioxide. A discussion of respiration falls logically, therefore, into subheadings dealing with: (1) the pumping of air to and from the alveoli; (2) the transfer of oxygen and carbon dioxide between blood and air in the lungs; (3) characteristics of transport between the lungs and extracellular fluid; and (4) the circulation of blood. The regulation of these interrelated phases in accordance with the needs of the organism is a fifth major topic.

Movement of gases is common to the four phases just enumerated. The force producing this movement is pressure. A pressure difference between the atmosphere and the alveoli causes air to flow in and out of the lungs. Oxygen passes from alveolus to pulmonary capillary and carbon dioxide from capillary to alveolus along pressure gradients. Blood circulates through the lungs and systemic circuits because the pressures in the pulmonary artery and aorta exceed those in the pulmonary and caval veins. And finally, the exchange of gases between corpuscle and plasma and between plasma and interstitial fluid is a function of the pressure differences. The relationship between pressure, flow, and resistance is therefore basic to gas exchange. It applies to the flow of air in the respiratory passages, the flow of blood in the circulatory system, and the transfer of oxygen and carbon dioxide across the alveolar capillary membrane.

THE RESPIRATORY PUMP

Air flows into the lungs through the open glottis whenever intrapulmonary air pressure falls below atmospheric pressure. Flow ceases when these two pressures are equal and reverses itself when alveolar pressure exceeds atmospheric. These fluctuations are the result of alternate expansion and contraction of the internal dimensions of the thorax, cyclic variations which, in turn, are attributable to lengthening and shortening of the intercostal muscles and diaphragms. The activity of these striated muscles, then, is normally essential for exchange of gases between the lung and atmosphere.

Static Measurements. Transpulmonary pressures. During quiet breathing, contraction of respiratory muscles is characteristic of inspiration only, the return of these muscles to their pre-inspiratory length being unassociated with contraction of antagonists. It follows therefore that inspiration is opposed by forces which, in the absence of active contraction of muscles, restore the thorax to its original dimensions. The elasticity of the lung is among these forces. Indeed, the dimensions of the lung-thorax system during muscular relaxation represent an equilibrium between the elastic recoil of the lungs, a force directed inwardly, and the elastic attributes of the parietes, a force directed outwardly. Quiet breathing is accomplished by intermittent displacement of this equilibrium during inspiration.

A pressure difference between the inside and outside of the lung surfaces is the force which keeps the lung expanded This difference is created during procedures on the open chest by raising the intrapulmonary pressure above the extrapulmonary or atmospheric pressure It exists during normal breathing because subatmospheric pressure outside the lung surfaces is below the pressure within the lungs If continuity between the atmosphere and the outside of the lung is established either from within by rupture of visceral pleura or from without by perforation of the chest wall this pressure difference is eliminated and the lung collapses An expanded state is maintained normally because the lungs enclosure is sealed

The force required to maintain the lungs expansion increases with inflation Representative figures for the transpulmonary pressure difference in the expiratory position are 8 cm of water as contrasted to 16 cm of water in the inspiratory position During the respiratory cycle therefore there occur pressure fluctuations between the atmosphere and the intrapulmonary intrathoracic structures arising from the elastic attributes of the lung This respiratory pump operates normally at subatmospheric pressures a circumstance favoring the influx of blood from the periphery to the thorax Preservation of this effect is among the advantages of respirators incorporating a negative phase

Much interest has been expressed within recent years in measuring how much transpulmonary pressure increases as lung volume increases The term compliance has been introduced in defining the elastic attributes of the lung Specifically compliance is the change in lung volume measured when the breath is being held produced by an increase in transpulmonary pressure of 1 cm of water Normal values range from 0 09 to 0 33 L per cm of water increase in pressure difference between inside and outside of the lung Oral and intraesophageal pressures are usually measured in actual practice the former being atmospheric and equivalent to intrapulmonary and the latter being subatmospheric and proximate to pleural or extrapulmonary Stiffening of the lung or decreased compliance i e smaller volume changes per unit pressure increase is found in heart disease such as congestive failure and mitral stenosis and in diseases of the lung such as the pulmonary granulomas

Lung Volumes Because expiration proceeds independently of muscular effort the equilibrium position of the lung-chest system varies little during quiet breathing despite sizeable fluctuations in inspiration The volume of air contained in the lungs at the end of a

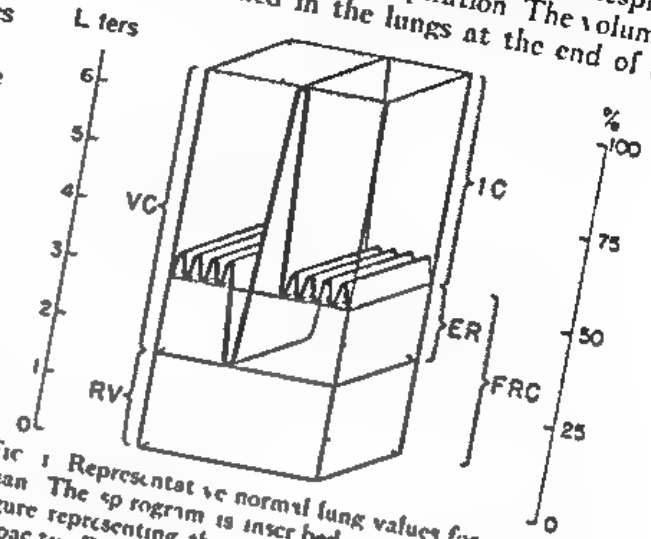

FIG 1 Representative normal lung values for a young man The spirogram is inscribed with a volumetric figure representing the total lung capacity VC vital capacity RV residual volume IC inspiratory capacity ER expiratory reserve FRC functional residual capacity

normal expiration is therefore a relatively stable quantity Because of its reproducibility this end expiratory volume or *functional residual capacity* is a useful point from which to measure other volumes Thus the *expiration reserve* formerly known as the supplemental air is the volume which can be expired from the lungs from the end expiratory position and the *inspiration capacity*, which includes the tidal volume plus what was formerly referred to as the complemental air is the volume which can be inspired from this position

Measurements of these two volumes and their sum the *vital capacity*, are usually made from a spirogram an ink record relating time on the horizontal axis with change in lung volume on the vertical axis Figure 1 represents such a record inscribed within a three dimensional or volumetric schema of the *total lung capacity* It is clear from such a diagram that the vital capacity inspiratory capacity, and expiratory reserve are changes in lung volume rather than actual volumes of air in the lungs These latter can be calculated only after the volume of air which cannot be voluntarily expelled the *residual volume* has been measured Normal values for these volumes are

Normal Physiology of Respiration

ARTHUR A. SPEECE, M.D., New York, New York

Associate Professor of Physiology, State University of New York College of Medicine at New York City

OXYGEN and carbon dioxide are vital constituents of the internal environment. The abundance of one is essential to life and the accumulation of the other is incompatible with survival. Intracellular levels in the range in which certain critical limits in the replacement of oxygen at the rate of its use and the elimination of carbon dioxide at the rate of its production. The overall exchange by the organism is common and interwoven between the homeostasis of respiration. It goes on to take up the subject of respiration in the environment as problem with respect to this exchange in a multicellular organism. The fundamental problem of respiration is establishment of adequate gaseous exchange between the individual cell and the atmosphere. This is accomplished by two mechanisms. One lot is employed the other lot. Part of the system is specialized for bringing a broad expanse of circulating fluid into intimate contact with air, and a fluid to be carried to the pound capable of taking up and releasing oxygen and carbon dioxide. A discussion of respiration falls logically under three headings, dealing with: 1) the purpose of respiration, 2) the transfer of oxygen and carbon dioxide between blood and air in the lungs, 3) the interstitial fluid and between the lungs and extracellular fluid and 4) the circulation of blood. The regulation of these interrelated phases in accordance with the needs of the organism is a fifth major topic.

Movement of gases is common to the four phases just enumerated. The force producing this movement is pressure. A pressure difference between the atmosphere and the alveoli causes air to flow in and out of the lungs. Oxygen passes from alveolus to pulmonary capillary and carbon dioxide from capillary to alveolus along pressure gradients. Blood circulates through the lungs and systemic circuits because the pressures in the pulmonary arteries and aorta exceed those in the pulmonary and venal veins. And finally, the exchange of gases between aerospace and plasma and between plasma and interstitial fluid is a function of the pressure differences. The relationship between pressure, flow and resistance is, therefore, basic to gas exchange. It applies to the flow of air in the respiratory passages, the flow of blood in the circulatory system and the transfer of oxygen and carbon dioxide across the alveolar capillary membrane.

THE MECHANISMS OF AIR

Air flows into the lungs through the open glottis whenever intrapulmonary air pressure falls below atmospheric pressure. Flow ceases when these two pressures are equal and reverses itself when alveolar pressure exceeds atmospheric. These fluctuations are the result of alternate expansion and contraction of the thoracic cavity. These fluctuations are attributable to internal dimensions of the cavity, which, in turn, are attributable to lengthening and shortening of the intercostal muscles and diaphragm. The activity of these skeletal muscles, then, is normally essential for exchange of gases between the lung and atmosphere.

Static Measurements. *Transpulmonary pressures.* During quiet breathing, contraction of respiratory muscles is characteristic of inspiration only, the return of these muscles to their prespiratory length being unassisted with contraction of antagonists. It follows, therefore, that inspiration is opposed by forces which, in the absence of active contraction of muscles, restore the thorax to its original dimensions. The elasticity of the lung is among these forces. Indeed, the dimensions of the lung thorax system during muscular relaxation represent an equilibrium between the elastic recoil of the lungs, a force directed inwards, and the elastic attributes of the parietes, a force directed outwards. Quiet breathing is accomplished by intermittent displacement of this equilibrium during inspiration.

included in Table 1 together with formulas used in computing a normal figure from age sex and height according to the data of Baldwin Cournand and Richards [2] As in most physiologic measurements variation around mean values is considerable Correspondingly marginal departures from predicted figures need not indicate abnormality

This discussion of the respiratory pump has thus far considered *static* measurements only e transpulmonary pressures when the breath is being held or pulmonary volumes at sustained levels of inspiration or expiration Gas exchange however depends upon *dynamic* relationships i e volume change per unit of time or *ventilation*

Measurements during Air Flow When air is flowing into the lungs the change in transpulmonary pressure required to inflate the lung is greater for any degree of inflation than when the breath is being held This is true because additional force is necessary both to produce air flow and to overcome the viscous resistance of the tissues deformed by respiratory movements The transpulmonary pressure during breathing is therefore, the sum of three forces the two just mentioned plus the force required to stretch the lung Since the latter can be known from measurements of compliance and if the total pressure is measured when viscosity is a relatively small factor the transpulmonary pressure required to produce a given flow rate may be approximated closely Representative figures are 2 cm of water at flow rates of 1 L per minute when the lungs are in the end expiratory position [3]

Pressure in any system is directly related to flow and resistance i e an increase in flow and/or resistance is associated with an increase in pressure Accordingly the transpulmonary pressure increases either when flow rates increase as during exercise or when resistance increases Resistance is affected predominantly by the diameter of the airways Moreover the relationship between diameter and resistance is an exponential one a given change in diameter producing not a commensurate change in resistance but one of considerably greater magnitude Diameter also influences the pattern of flow through tubes flow tending to become turbulent rather than laminar with progressive narrowing turbulence is itself a circumstance impeding flow For these reasons the internal diameter of airways is critical to the forces required for ventilation This diameter is affected not only by the dimensions of supporting cartilage the tone of smooth muscles mucosal secretions and inflammation but in the non cartilagenous tubes also by the elastic network in which these are suspended The strands of this network are under progressively increasing tension during the course of inspiration Accordingly, resistance to air flow a function of airway diameter, diminishes during inspiration [4]

It is on the inspiratory side of the end-expiratory position then that resistance to air flow and the transpulmonary pressures required for ventilation are least The patient with pathologically narrowed airways breathes most easily therefore and commonly performs his optimal maximum breathing capacity in a position of partial inspiration Furthermore in diseases characterized by the loss of elastic tissue within the lung the only mechanism available to the patient for maintaining a normal distending tension on non cartilagenous airways is elevation of the end expiratory position This consideration plus the fact that loss of elastic tissue shifts the normal lung thorax equilibrium position outwardly are a part of the explanation both for the augmented functional residual capacity and the increasingly slowed course of expiration (flattening slope on spirogram prolonged timed vital capacity) characteristic of emphysema

Metabolic Cost of Breathing The forces required for ventilation are produced by muscular contractions the energy for which is ultimately provided by oxygen The metabolic cost of breathing has been estimated to be 0 5 ml of oxygen per L of ventilation [5] or about 1 per cent of the total energy requirement of a normal resting individual This figure increases as ventilation increases or as the forces required for ventilation increase Low compliance and high resistance both add to the metabolic requirements for respiration These are circumstances therefore detracting from the body s economy in maintaining a vital function Although precise measurements are lacking their magnitude in obstructive pulmonary disease has been estimated to be of considerable importance [6]

Dead Space The output of the respiratory pump is subject to wide variations ranging from approximately ½ L at rest to 120 liters during severe exercise to 200 L for brief bursts

TABLE 1

QUANTITATIVE DATA PERTAINING TO THE PHYSIOLOGY OF RESPIRATION

The Respiratory Pump

	Age, 16–34*	Age, 35–60*	Age, 61–80*	Age, 21.3 ± 3.41†
Lung Volumes, L.				
Vital capacity	3.8–5.0	3.3–5.2	2.3–5.4	5.18 ± 0.68
Total lung capacity	Vit cap 38%	Vit cap 46%	Vit cap 1.6‡	
Residual lung cap	20%	21%	38%	
Compliance, L. per cm. of water‡				
0.09–0.33				
Ventilation, L. per square meter of body surface area				
At rest	3.1–4.4	2.6–4.0	3.2–4.9	7.36 ± 1.33
Max. breathing cap.	83–160	66–144	48–130	160.0 ± 19.5

Exchange of Gases between Blood, Lungs and Atmosphere

Representative Figures for Composition of Respiratory Gases in Atmosphere, Lungs and Blood

	H_2O		O_2		CO_2		N_2		Total	
	Vols. %	Pressure mm Hg	Vols. %	Pressure mm Hg	Vols. %	Pressure mm Hg	Vols. %	Pressure mm Hg	Vols. %	Pressure mm Hg
Room Air	Assumed dry		20.93	159.41	0.04	0.3	79.03	600.6	100	760
Tracheal Insp. Air	6.2	47	19.77	149.76	0.14	0.3	74.10	564.0	100	760
Expired Air	6.2	47	15.30	116.00	3.90	29.7	74.65	567.3	100	760
Alveolar Air	6.2	47	13.66	103.00	5.34	40.0	74.00	560.0	100	760
Arterial Blood			20.00	95.00	42.00	40.0	0.98	560.0		
Mixed Venous Blood			14.45	45.00	52.00	46.0	0.98	560.0		

Arterial Blood Gas Analysis, Approximate Normal Values

	O_2	CO_2
Saturation, %	94–98	
Content, vols. %	Dependent on Hb	46–54
Pressure, mm Hg	88–108	38–42

Distribution Ratios

Dead space	Less than 30% of total volume
Venous admixture	Less than 8% of cardiac output

Oxygen Consumption, cc. per minute per square meter of body surface area

Age, 16–34*	Age, 35–60*	Age, 61–80*	Age, 21.3 ± 3.41†
120–180	118–165	100–164	174 ± 32.4

Gas Exchange Ratio (R or RQ)

Approximately 0.78 to 0.88

Diffusion

Diffusing capacity at rest	10–30
Maximal diffusing capacity	50–80

The Circulatory Pump

Flow or Cardiac Output (L. per square meter of body surface area)

Approximately 2.3 to 3.0

Pressures, Approximate, S/D

Right ventricle	25/2
Pulmonary artery	25/8
Left ventricle	98/6§
Brachial artery	120/70

* BALDWIN et al. Fifty two male hospital patients without heart or lung disease. *Medicine*, 27: 243, 1948.

† GRAY et al. One hundred male medical students. *J. Clin. Investigation*, 29: 688, 1950.

‡ BRAUNSWOLD et al. Three male patients without cardiovascular disease. *Circulation*, 12: 60, 1955.

included in Table 1 together with formulas used in computing a normal figure from age, sex and height according to the data of Baldwin, Cournand, and Richards.[2] As in most physiologic measurements, variation around mean values is considerable. Correspondingly, marginal departures from predicted figures need not indicate abnormality.

This discussion of the respiratory pump has thus far considered *static* measurements only, i.e., transpulmonary pressures when the breath is being held or pulmonary volumes at sustained levels of inspiration or expiration. Gas exchange, however, depends upon *dynamic* relationships, i.e., volume change per unit of time or *ventilation*.

Measurements during Air Flow. When air is flowing into the lungs, the change in transpulmonary pressure required to inflate the lung is greater for any degree of inflation than when the breath is being held. This is true because additional force is necessary both to produce air flow and to overcome the viscous resistance of the tissues deformed by respiratory movements. The transpulmonary pressure during breathing is therefore, the sum of three forces, the two just mentioned plus the force required to stretch the lung. Since the latter can be known from measurements of compliance and if the total pressure is measured when viscosity is a relatively small factor, the transpulmonary pressure required to produce a given flow rate may be approximated closely. Representative figures are 2 cm. of water at flow rates of 1 L. per minute when the lungs are in the end expiratory position.[3]

Pressure in any system is directly related to flow and resistance, i.e., an increase in flow and/or resistance is associated with an increase in pressure. Accordingly, the transpulmonary pressure increases either when flow rates increase, as during exercise, or when resistance increases. Resistance is affected predominantly by the diameter of the airways. Moreover the relationship between diameter and resistance is an exponential one: a given change in diameter producing not a commensurate change in resistance but one of considerably greater magnitude. Diameter also influences the pattern of flow through tubes, flow tending to become turbulent rather than laminar with progressive narrowing. Turbulence is itself a circumstance impeding flow. For these reasons the internal diameter of airways is critical to the forces required for ventilation. This diameter is affected not only by the dimensions of supporting cartilage, the tone of smooth muscles, mucosal secretions and inflammation but in the non-cartilagenous tubes also by the elastic network in which these are suspended. The strands of this network are under progressively increasing tension during the course of inspiration. Accordingly, resistance to air flow, a function of airway diameter, diminishes during inspiration.[4]

It is on the inspiratory side of the end-expiratory position then that resistance to air flow and the transpulmonary pressures required for ventilation are least. The patient with pathologically narrowed airways breathes most easily, therefore, and commonly performs his optimal maximum breathing capacity in a position of partial inspiration. Furthermore, in diseases characterized by the loss of elastic tissue within the lung the only mechanism available to the patient for maintaining a normal distending tension on non-cartilagenous airways is elevation of the end expiratory position. This consideration plus the fact that loss of elastic tissue shifts the normal lung thorax equilibrium position outwardly are a part of the explanation both for the augmented functional residual capacity and the increasingly slowed course of expiration (flattening slope on spirogram, prolonged timed vital capacity) characteristic of emphysema.

Metabolic Cost of Breathing. The forces required for ventilation are produced by muscular contractions the energy for which is ultimately provided by oxygen. The metabolic cost of breathing has been estimated to be 0.5 ml. of oxygen per L. of ventilation,[5] or about 1 per cent of the total energy requirement of a normal resting individual. This figure increases as ventilation increases or as the forces required for ventilation increase. Low compliance and high resistance both add to the metabolic requirements for respiration. These are circumstances, therefore, detracting from the body's economy in maintaining a vital function. Although precise measurements are lacking their magnitude in obstructive pulmonary disease has been estimated to be of considerable importance.[6]

Dead Space. The output of the respiratory pump is subject to wide variations, ranging from approximately 2 L. at rest to 120 liters during severe exercise to 200 L. for brief bursts

of maximal voluntary hyperventilation. The effectiveness of this pump in gas exchange is measured, however, not by such figures of total ventilation but by the proportion of the total which contributes to an exchange of gases between the alveoli and the atmosphere. It is essential, therefore, to distinguish between ventilation of tubes leading to alveoli, whether these be normal passages or respiratory equipment, and ventilation of the alveoli themselves.

The volume of the tracheobronchial tree in the adult, about 150 cc., is relatively fixed. In a normal inspiration of 500 cc., therefore, only 350 cc. are delivered to alveoli, the balance merely filling channels to the gas exchanging surfaces. As tidal volume decreases from 500 cc. to 400 cc., for example, the volume of air filling the dead space remains constant whereas that delivered to alveoli is curtailed by 100 cc. Unless respiratory rate changes, therefore, alveolar ventilation will suffer. In terms of body economy, the most effective ventilation

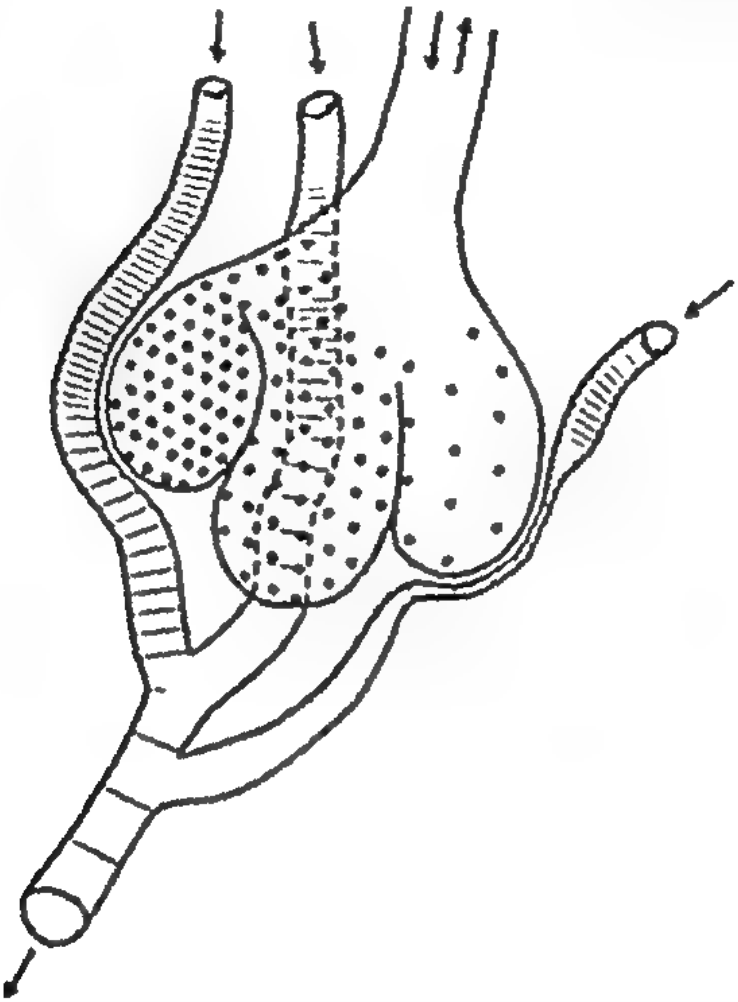

FIG. 3. Schematic representation of variations in distribution of air and blood in the lungs. The central alveolus is well perfused and ventilated; its carbon dioxide content (black dots) is normal and the blood in its capillaries becomes well oxygenated. The alveolus to the right is well ventilated but poorly perfused; less carbon dioxide diffuses into it than in the normal instance and less oxygen diffuses out of it. Because its carbon dioxide content is almost normally low, more like that in inspired air, its contents contribute a dead space like effect to the composition of expired air. The blood in its capillary, however, is normally oxygenated. The alveolus on the left is poorly ventilated but well perfused. Its carbon dioxide content and pressure are higher than normal and its oxygen content and pressure are low. Blood in its capillary is poorly oxygenated. The saturation of blood in the common collecting vessel is reduced by this venous admixture effect.

is that which provides alveolar ventilation commensurate with metabolic requirements at a minimum dead space ventilation

The "dead space" referred to in the preceding paragraphs, being the volume of oral, pharyngeal and tracheobronchial airways, is an anatomic concept The common physiologic attribute of the structures included is that they do not participate in gas exchange Alveoli making no or a poor contribution to gas exchange by reason of attenuated or absent capillaries also contribute a dead space-like effect Moreover, this effect is conceivably enhanced under circumstances, such as high rates of flow in and out of the lungs, precluding homogeneous distribution of gases within the alveoli i e, circumstances in which the concentration of gases immediately adjacent to the alveolar wall is different from that at the alveolar orifice Because of these effects, the more comprehensive concept of dead space incorporates functional considerations The three methods used for making this measurement employ physiologic technics Two, however, those associated with Fowler[8] and Pappenheimer,[9] measure a volume more or less co-extensive with the anatomic dead space The third, the method of Riley and associates[10] includes the functional characteristics enumerated Figures obtained by its application are therefore usually higher than those obtained by the other technics During quiet breathing in normal individuals the volume of the physiologic dead space (V_T) does not exceed 30 per cent of the tidal volume (V_D)

The fundamental concept of the Riley method is that alveolar air is diluted by dead space or room air in proportion to the volume of the dead space If, therefore one measures the composition of alveolar air and that of expired air, the difference in the concentration or partial pressure of a given gas is the dilution factor This factor less than 30% in normal persons breathing quietly multiplied by the tidal volume is the volume of the physiologic dead space It represents the amount of room air which, if mixed with the appropriate volume of alveolar gas would give a tidal volume with the composition of expired air Carbon dioxide is the reference gas employed, for its pressure in alveolar gas, being equal to that in arterial blood, can be established from blood gas analysis

Distribution *Venous admixture* Poorly perfused alveoli, as described previously, produce a dead space-like effect detectable by measurements on expired air Similarly, poorly ventilated alveoli have an effect on blood leaving the lungs detectable by analyses of arterial blood The nature of this effect is discussed in greater detail later It is brought out here because it is conceptually analogous to the dead space effect Arterial blood can be conceived of as a mixture of two streams, one being in equilibrium with a representative alveolar gas and the other being mixed venous blood The relative proportions of these two streams is a function both of direct right to left shunts by-passing the lungs as well as of blood perfusing poorly ventilated alveoli Normally, this venous admixture component does not amount to more than 6 per cent of the cardiac output

Physiologic dead space and venous admixture, therefore, reflect the relationship between alveolar ventilation and perfusion, or between the *distribution* of gas and blood to the alveoli Figure 2 is a schematic presentation of the effects of different ventilation-perfusion relationships on the composition of expired air and arterial blood

GAS EXCHANGE BETWEEN ALVEOLI AND PULMONARY CAPILLARIES

Oxygen and carbon dioxide cross the fluid and cellular layers separating alveolar gas from pulmonary capillary blood by *diffusion* This is entirely a passive process, the alveolar cells do not secrete the respiratory gases Diffusion occurs when there is a difference in the pressures of these gases on the two sides of the membrane

Partial Pressure of Oxygen in Alveolar Air On the alveolar side of the membrane is a mixture of gases The pressure of a given gas in such a mixture is the product of the concentration of this gas and the pressure of the mixture Excluding rare gases, alveolar air contains four gases under atmospheric pressure One of these is the water vapor which saturates the intrapulmonary atmosphere The partial pressure of water vapor at body temperature, 37°C, is 47 mm Hg This figure must be subtracted from atmospheric pressure in calculating the sum ~713 mm Hg at a barometric pressure of ~760 of the pressures of carbon dioxide, nitrogen and oxygen About ~9 per cent of the alveolar gas is nitrogen, the

of maximal voluntary hyperventilation The effectiveness of this pump in gas exchange is measured, however, not by such figures of total ventilation but by the proportion of the total which contributes to an exchange of gases between the alveoli and the atmosphere It is essential, therefore, to distinguish between ventilation of tubes leading to alveoli, whether these be normal passages or respiratory equipment, and ventilation of the alveoli themselves

The volume of the tracheobronchial tree in the adult, about 150 cc, is relatively fixed In a normal inspiration of 500 cc, therefore, only 350 cc are delivered to alveoli, the balance merely filling channels to the gas exchanging surfaces As tidal volume decreases from 500 cc to 400 cc, for example, the volume of air filling the dead space remains constant whereas that delivered to alveoli is curtailed by 100 cc Unless respiratory rate changes, therefore, alveolar ventilation will suffer In terms of body economy, the most effective ventilation

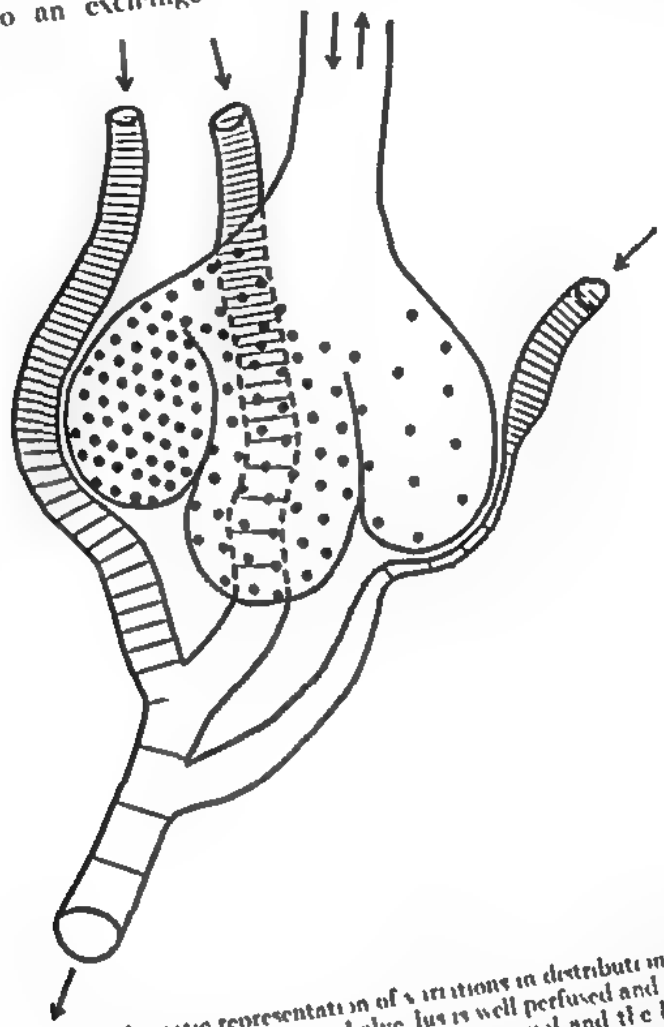

FIG 2 Schematic representation of variations in distribution of air and blood in the lungs The central alveolus is well perfused and ventilated its carbon dioxide content (black dots) is normal and the blood in its capillary becomes well oxygenated The alveolus to the right is well ventilated but poorly perfused, less carbon dioxide diffuses into it than in the normal instance and less oxygen diffuses out of it Because its carbon dioxide content is abnormally low (more like that in inspired air) its contents contribute a dead space like effect to the composition of expired air The blood in its capillary however is normally oxygenated The alveolus on the left is poorly ventilated but well perfused Its carbon dioxide content and pressure are higher than normal and its oxygen content and pressure are low blood in its capillary is poorly oxygenated The saturation of blood in the common collecting vessel is reduced by this venous admixture effect

is that which provides alveolar ventilation commensurate with metabolic requirements at a minimum dead space ventilation

The dead space referred to in the preceding paragraphs being the volume of oral pharyngeal and tracheobronchial airways is an anatomic concept The common physiologic attribute of the structures included is that they do not participate in gas exchange Alveoli making no or a poor contribution to gas exchange by reason of attenuated or absent capillaries also contribute a dead space like effect Moreover this effect is conceivably enhanced under circumstances such as high rates of flow in and out of the lungs precluding homogeneous distribution of gases within the alveoli i e circumstances in which the concentration of gases immediately adjacent to the alveolar wall is different from that at the alveolar orifice Because of these effects, the more comprehensive concept of dead space incorporates functional considerations The three methods used for making this measurement employ physiologic techniques Two however those associated with Fowler's and Pappenheimer's measure a volume more or less co-extensive with the anatomic dead space The third the method of Riley and associates includes the functional characteristics enumerated Figures obtained by its application are therefore usually higher than those obtained by the other techniques During quiet breathing in normal individuals the volume of the physiologic dead space (V_D) does not exceed 30 per cent of the tidal volume (V_T)

The fundamental concept of the Riley method is that alveolar air is diluted by dead space or room air in proportion to the volume of the dead space If therefore one measures the composition of alveolar air and that of expired air the difference in the concentration or partial pressure of a given gas is the dilution factor This factor less than 30 in normal persons breathing quietly multiplied by the tidal volume is the volume of the physiologic dead space It represents the amount of room air which if mixed with the appropriate volume of alveolar gas would give a tidal volume with the composition of expired air Carbon dioxide is the reference gas employed for its pressure in alveolar gas being equal to that in arterial blood can be established from blood gas analysis

Distribution Venous admixture Poorly perfused alveoli as described previously, produce a dead space-like effect detectable by measurements on expired air Similarly poorly ventilated alveoli have an effect on blood leaving the lungs detectable by analyses of arterial blood The nature of this effect is discussed in greater detail later It is brought out here because it is conceptually analogous to the dead space effect Arterial blood can be conceived of as a mixture of two streams one being in equilibrium with a representative alveolar gas and the other being mixed venous blood The relative proportions of these two streams is a function both of direct right to left shunts by passing the lungs as well as of blood perfusing poorly ventilated alveoli Normally this venous admixture component does not amount to more than 6 per cent of the cardiac output

Physiologic dead space and venous admixture therefore reflect the relationship between alveolar ventilation and perfusion or between the distribution of gas and blood to the alveoli Figure 2 is a schematic presentation of the effects of different ventilation perfusion relationships on the composition of expired air and arterial blood

GAS EXCHANGE BETWEEN ALVEOLI AND PULMONARY CAPILLARIES

Oxygen and carbon dioxide cross the fluid and cellular layers separating alveolar gas from pulmonary capillary blood by *diffusion* This is entirely a passive process the alveolar cells do not secrete the respiratory gases Diffusion occurs when there is a difference in the pressures of these gases on the two sides of the membrane

Partial Pressure of Oxygen in Alveolar Air On the alveolar side of the membrane is a mixture of gases The pressure of a given gas in such a mixture is the product of the concentration of this gas and the pressure of the mixture Excluding rare gases alveolar air contains four gases under atmospheric pressure One of these is the water vapor which saturates the intrapulmonary atmosphere The partial pressure of water vapor at body temperature 37°C is 47 mm Hg This figure must be subtracted from atmospheric pressure in calculating the sum 713 mm Hg at a barometric pressure of 760 of the pressures of carbon dioxide nitrogen and oxygen About 79 per cent of the alveolar gas is nitrogen the

of maximal voluntary hyperventilation The effectiveness of this pump in gas exchange is measured, however, not by such figures of total ventilation but by the proportion of the total which contributes to an exchange of gases between the alveoli and the atmosphere It is essential therefore, to distinguish between ventilation of tubes leading to alveoli, whether these be normal passages or respiratory equipment, and ventilation of the alveoli themselves

The volume of the tracheobronchial tree in the adult, about 150 cc, is relatively fixed In a normal inspiration of 500 cc, therefore, only 350 cc are delivered to alveoli, the balance merely filling channels to the gas exchanging surfaces As tidal volume decreases from 500 cc to 400 cc, for example, the volume of air filling the dead space remains constant whereas that delivered to alveoli is curtailed by 100 cc Unless respiratory rate changes therefore, alveolar ventilation will suffer In terms of body economy, the most effective ventilation

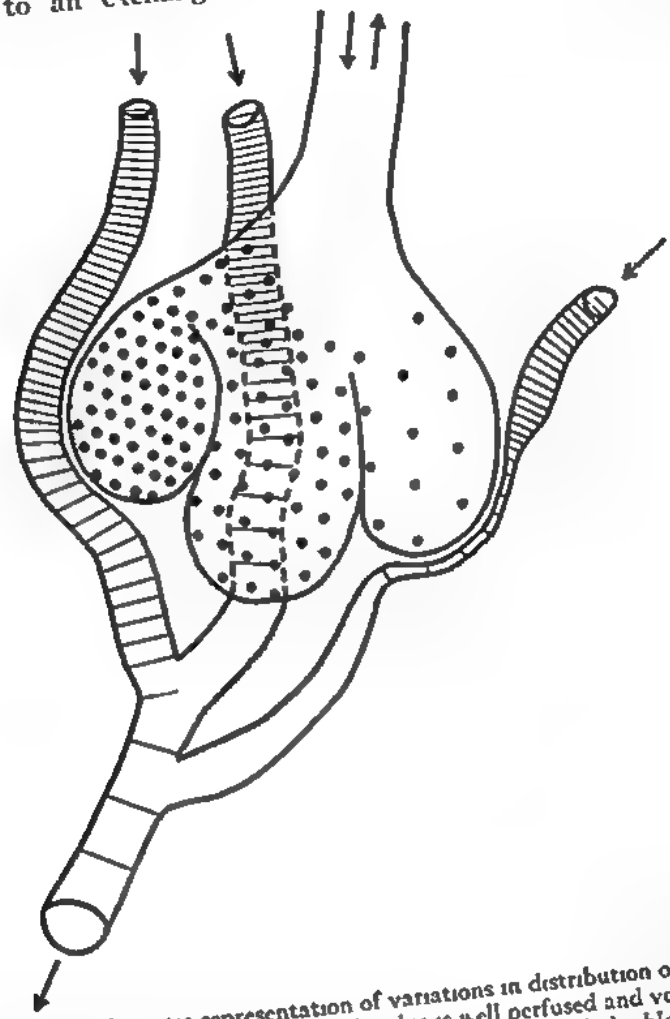

FIG 2 Schematic representation of variations in distribution of air and blood in the lungs The central alveolus is well perfused and ventilated its carbon dioxide content (black dots) is normal and the blood in its capillary becomes well oxygenated The alveolus to the right is well ventilated but poorly perfused less carbon dioxide diffuses into it than in the normal instance and less oxygen diffuses out of it Because its carbon dioxide content is abnormally low (more like that in inspired air) its contents contribute a dead space like effect to the composition of expired air The blood in its capillary, however is normally oxygenated The alveolus on the left is poorly ventilated but well perfused Its carbon dioxide content and pressure are higher than normal and its oxygen content and pressure are low blood in its capillary is poorly oxygenated The saturation of blood in the common collecting vessel is reduced by this venous admixture effect

exchange but Barcroft correctly maintained this tissue played only a passive role Today s measurements are sufficiently accurate to define this basic physiologic process clearly and in consequence to identify patterns of respiratory disease previously unrecognized

The A a Difference It is informative in studies of respiratory disease to measure the difference between the pressure of oxygen in alveolar gas ($P_{A_{O_2}}$) and arterial blood ($P_{a_{O_2}}$) The magnitude of this A a difference is proportional to the difference between alveolar ($P_{A_{O_2}}$) and pulmonary capillary ($P_{c_{O_2}}$) oxygen pressures as well as to the difference between the latter and arterial oxygen pressure ($P_{a_{O_2}}$) The A a difference is therefore the sum of two component differences one being the *membrane component* and the other what has been referred to as the *venous admixture* component The identification of these two is the basis for distinguishing between low arterial oxygen pressures attributable to alveolar capillary block produced by such diseases as the pulmonary granulomas and those due to excessive anatomic or physiologic right to left shunts

Membrane Component and Diffusing Capacity The membrane component at a given rate of oxygen transfer depends upon the thickness of the membrane or the distance oxygen must diffuse in passing into the blood the permeability of the membrane to oxygen and the area of the membrane Increases in thickness and permeability are in effect increases in resistance When resistance is augmented normal rates of oxygen flow across the membrane can be maintained only by increases in the force the alveolar-capillary oxygen pressure difference producing this flow In alveolar capillary block this augmented force commonly results from a fall in capillary and arterial oxygen pressure and a small elevation of alveolar oxygen pressure achieved by increased ventilation

The diffusing capacity is the rate of oxygen flow across the membrane divided by the membrane component Figures for the diffusing capacity are the cc of oxygen traversing the membrane per mm Hg oxygen pressure difference between its two sides Normal values at rest are approximately 10 to 30 With exercise the diffusing capacity increases and reaches a maximum when oxygen consumption approximates 1 200 cc/min [12] Normal values for the maximal diffusing capacity in young male adults range from approximately 50 to 80 [12 13]

It was stated previously that the area of the alveolar capillary membrane is one of the determinants of the membrane component This simply means that if the blood gas interface is extensive a smaller pressure suffices to drive a given volume of oxygen across the membrane per minute than if this interface is minute Accordingly pulmonary resection reduces the maximal diffusing capacity whereas procedures such as decortication which allow the alveolar-capillary bed to expand increase the maximal diffusing capacity [13] The increase in diffusing capacity with exercise is interpreted to reflect broadening of the membrane and the curtailment with aging[14] narrowing of this bed By the same token patients with emphysema characterized by rupture of alveolar septa would be expected to have a reduced maximal diffusing capacity

Having defined the membrane component and having indicated its bearing on normal and pathologic respiration one should allude briefly to the difficulties of its measurement The Riley technique[15] for determining arterial carbon dioxide and oxygen pressures within the physiologic range is the crux of measuring physiologic dead space venous admixture and diffusing capacity the paramount importance of this technical contribution is therefore obvious The more stringent difficulties are the following It is impossible in measuring the pressure of oxygen in pulmonary capillaries to obtain an appropriate sample of blood It is possible however to create circumstances under which arterial blood differs minimally from pulmonary capillary blood i e circumstances under which the venous admixture component of the A a difference is reduced to very low values For reasons indicated in the next section this requirement is met when the concentration of oxygen in inspired air is reduced sufficiently to lower arterial oxygen tens on to about 40 mm Hg The further requirement of producing an A-c gradient sufficiently large to be relatively insensitive to errors in analytic procedures is met by exercising the subject The membrane component and the diffusing capacity for oxygen therefore are measured somewhat accurately in

partial pressure of this gas therefore being approximately 563 mm Hg The pressure of carbon dioxide and oxygen make up the balance of about 150 mm Hg Because carbon dioxide diffuses readily its pressures on the two sides of the membrane at the end of the pulmonary capillary are equal Forty mm Hg the partial pressure of carbon dioxide in arterial blood ($P_{a_{CO}}$) is therefore a mean value for the pressure of carbon dioxide in alveolar air ($P_{A_{CO}}$) By this process of elimination the partial pressure of oxygen in alveolar air can be estimated to be 110 mm Hg

Alveolar Equation This figure is an estimate because the concentration of nitrogen is approximated rather than measured This concentration could be precisely computed if the volume of alveolar gas remained constant This is not the case however for the volume of oxygen removed from alveolar gas exceeds the volume of carbon dioxide added to alveolar gas the respiratory quotient (CO_2 output/O_2 consumption) or gas exchange ratio (R) is not 1 0 but about 0 80 The total volume of alveolar gases therefore decreases somewhat as a result of exchanges with arterial blood Consequently the concentration of nitrogen a gas which is neither added to nor removed from alveolar air increases the extent of this increase being proportional to the gas exchange ratio Determining this ratio is therefore essential for accurately measuring the partial pressure of oxygen in alveolar air

After one takes into account the effect of these volume changes the partial pressure of oxygen in alveolar air (P_{A_O}) is simply a function of its pressure in air entering the alveoli (P_{I_O}) and of its loss to arterial blood This latter can be computed from the gas exchange ratio (R) and the amount of carbon dioxide added to alveolar air For example if 5 6 cc of CO_2 are added to 100 cc of alveolar air and the gas exchange ratio is 0 80 7 0 cc of oxygen per 100 cc of gas must have been lost to arterial blood Since the air entering the alveoli contains only a negligible quantity of carbon dioxide its concentration or partial pressure in alveolar gas represents the amount added In summary if one knows the partial pressure of oxygen in inspired air (P_{I_O}) the gas exchange ratio (R) and the composition of alveolar gas with respect to carbon dioxide ($P_{A_{CO}}$) one can calculate the alveolar oxygen partial pressure (P_{A_O}) The alveolar equation reproduced in one of its forms below is a statement to this effect

$$P_{A_O} = P_{I_{O_2}} + \frac{F_{I_O} \times P_{A_{CO}} \times (1 - R)}{R} - \frac{P_{A_{CO}}}{R}$$

The middle term on the right hand side of the equation corrects for intraalveolar volume changes and accordingly becomes 0 when R is 1 0 The term to the far right reflects the loss of oxygen from alveolar gas to arterial blood To substitute numerical values the partial pressure of oxygen in saturated air entering the alveoli (P_{I_O}) is (760 − 47) times the concentration (F_{I_O} − 2093) of oxygen in the atmosphere Other normal values have been given above

$$P_{A_O} - (760 - 47) \times 2093 + \frac{2093 \times 40 \times 20}{80} - \frac{40}{80}$$

$$P_A - 149 + 2 - 50$$

$$P_{A_O} = 101$$

The pressure of oxygen on the alveolar side of the membrane under these circumstances therefore is 101 mm Hg Oxygen will diffuse into pulmonary capillary blood until the pressure there equals this figure

The relationships expressed in the alveolar equation are basic The only way an organism can raise its alveolar and arterial oxygen pressure when in a given environment in a given metabolic state is to lower the pressure of carbon dioxide in its alveoli this can be accomplished by increasing its rate of venti [illegible] carbon dioxide retention pressure increasing alveolar oxygen pressures is change to an environment in which the inspired mixture is richer in oxygen

The alveolar equation is important not only for the fundamental relationships it expresses but because it defines alveolar oxygen pressures in measurable terms Lack of such a definition and the requisite technics was the basis of one of the century epic physiologic controversies Haldane interpreting his data to indicate that alveolar epithelium had a secretory function in alveolar capillary gas

exchange but Barcroft correctly maintained this tissue played only a passive role Today s measurements are sufficiently accurate to define this basic physiologic process clearly and in consequence to identify patterns of respiratory disease previously unrecognized

The A a Difference It is informative in studies of respiratory disease to measure the difference between the pressure of oxygen in alveolar gas ($P_{A_{O_2}}$) and arterial blood ($P_{a_{O_2}}$) The magnitude of this A a difference is proportional to the difference between alveolar ($P_{A_{O_2}}$) and pulmonary capillary ($P_{c_{O_2}}$) oxygen pressures as well as to the difference between the latter and arterial oxygen pressure ($P_{a_{O_2}}$) The A a difference is therefore the sum of two component differences one being the *membrane component* and the other what has been referred to as the *venous admixture* component. The identification of these two is the basis for distinguishing between low arterial oxygen pressures attributable to alveolar capillary block, produced by such diseases as the pulmonary granulomas and those due to excessive anatomic or physiologic right to left shunts

Membrane Component and Diffusing Capacity The membrane component at a given rate of oxygen transfer depends upon the thickness of the membrane or the distance oxygen must diffuse in passing into the blood the permeability of the membrane to oxygen and the area of the membrane Increases in thickness and permeability are in effect increases in resistance When resistance is augmented normal rates of oxygen flow across the membrane can be maintained only by increases in the force the alveolar-capillary oxygen pressure difference producing this flow In alveolar capillary block this augmented force commonly results from a fall in capillary and arterial oxygen pressure and a small elevation of alveolar oxygen pressure achieved by increased ventilation

The diffusing capacity is the rate of oxygen flow across the membrane divided by the membrane component Figures for the diffusing capacity are the cc of oxygen traversing the membrane per mm Hg oxygen pressure difference between its two sides Normal values at rest are approximately 10 to 30 With exercise the diffusing capacity increases and reaches a maximum when oxygen consumption approximates 1 200 cc /min [12] Normal values for the maximal diffusing capacity in young male adults range from approximately 50 to 80 [12 13]

It was stated previously that the area of the alveolar capillary membrane is one of the determinants of the membrane component This simply means that if the blood gas interface is extensive a smaller pressure suffices to drive a given volume of oxygen across the membrane per minute than if this interface is minute Accordingly pulmonary resection reduces the maximal diffusing capacity whereas procedures such as decortication which allow the alveolar-capillary bed to expand increase the maximal diffusing capacity [11] The increase in diffusing capacity with exercise is interpreted to reflect broadening of the membrane and the curtailment with aging[14] narrowing of this bed By the same token patients with emphysema characterized by rupture of alveolar septa would be expected to have a reduced maximal diffusing capacity

Having defined the membrane component and having indicated its bearing on normal and pathologic respiration one should allude briefly to the difficulties of its measurement The Riley technique[9] for determining arterial carbon dioxide and oxygen pressures within the physiologic range is the crux of measuring physiologic dead space venous admixture and diffusing capacity the paramount importance of this technical contribution is therefore obvious The more stringent difficulties are the following It is impossible in measuring the pressure of oxygen in pulmonary capillaries to obtain an appropriate sample of blood It is possible however to create circumstances under which arterial blood differs minimally from pulmonary capillary blood i e circumstances under which the venous admixture component of the A-a difference is reduced to very low values For reasons indicated in the next section this requirement is met when the concentration of oxygen in inspired air is reduced sufficiently to lower arterial oxygen tension to about 40 mm Hg The further requirement of producing an A-c gradient sufficiently large to be relatively insensitive to errors in analytic procedures is met by exercising the subject The membrane component and the diffusing capacity for oxygen therefore are measured somewhat

most subjects only when the arterial oxygen pressure is artificially reduced and the metabolic rate is considerably elevated The alternative technic whereby the diffusing capacity of oxygen is calculated from that of a foreign gas carbon monoxide [6] does not share these somewhat rigorous requirements

A final problem arises from the fact that the measured membrane component is a pressure difference at a selected point the end of the pulmonary capillary The pressure difference across the membrane is in fact constantly changing as the venous blood flows along the capillary and becomes progressively arterialized At normal levels of saturation in normal subjects this change virtually ceases before the end of the capillary for the gas tension in blood comes into equilibrium with that in the alveoli At low levels of saturation however and during a state of increased metabolic activity this equilibrium is not achieved and a measurable end gradient results Because there are an infinite number of gradients it is necessary in defining the characteristics of the membrane to derive a mean gradient This is usually done from the oxy

mean gradient

Differentiating the Causes of Hypoxia The

oxygen pressure is detectable by solving the alveolar equation Excessive direct right to left shunts (congenital heart defects pulmonary A V fistula) are the only causes of a hypoxia which persists in spite of large elevations in

increases of venous admixture due to regional hypoventilation with regionally lowered alveolar oxygen pressures and abnormalities of diffusion attributable to decreased permeability of the alveolar capillary membrane In both defects the oxygenation of arterial blood becomes normal as alveolar oxygen pressure is increased The most definitive basis of distinction between these two entities is the diffusing capacity values being low in a pure diffusion defect and normal in an abnormality purely of distribution

GAS TRANSPORT

Dissolved Oxygen The oxygen that diffuses into pulmonary capillary blood exists there both in solution within the plasma and in combination with hemoglobin The amount in solution is proportional to the alveolar oxygen pressures increasing by 0 003 cc of oxygen per 100 cc of blood for every mm Hg increase in oxygen pressure If the $P_{A_{O_2}}$ is 100 mm Hg the amount dissolved is therefore 0 3 cc per 100 cc of blood or in a circulating blood volume of 6 L 18 cc of oxygen The fact that this concentration is only about one sixtieth of that in normal blood highlights the relative importance of hemoglobin as an oxygen carrier It is pressure however that is the basis of gas exchange although the volume of dissolved oxygen is small its pressure is normally high It is this force which drives oxygen into the extracellular fluid and to the cells themselves Hemoglobin serves as an effective store of oxygen combining with it in the lungs when plasma oxygen pressure rises and releasing it to the plasma as pressure falls

Oxyhemoglobin Dissociation and Association The amount of oxygen combined with hemoglobin does not increase linearly as the plasma pressure rises and falls The way this amount actually varies is described by the oxyhemoglobin dissociation curve (Fig 3) This curve is the plot of a fraction per cent saturation on the vertical axis against the oxygen pressure to which hemoglobin in red blood cells is exposed The numerator of the fraction is the volume of oxygen in combination with hemoglobin at the oxygen pressure of plasma and the denominator is the volume combined (capacity) when blood is exposed to atmospheric oxygen pressure Every gram of hemoglobin so exposed takes up 1 34 cc of oxygen a normal capacity (hemoglobin of 15 gm per 100 cc of blood) therefore being 20 1 cc per 100 cc of blood or 20 1 volumes per cent

The dissociation or association curve rises steeply up to a saturation of about 80 per cent [illegible] Hg and (Fig 3) pressure from 0 to 45 mm Hg raises the volume of oxygen bound by hemoglobin to 80 per cent of the capacity or conversely that progressive falls in oxygen pressure below 45 mm result in the dissociation of large volumes of oxygen Thus a fall in pressure from 45 to 25 mm Hg

produces a fall in saturation from 80 to 46 5 per cent whereas an equal change (20 mm Hg) in pressure from 45 to 65 is associated with an increase in saturation only from 80 to 90 7 per cent conversely, lowering the pressure from 100 to 80 mm Hg for example results in the dissociation of a small volume of oxygen and a drop in saturation only from 97 2 to 94 3 per cent

Saturation is Pressure These characteristics of hemoglobin are patently advantageous to the organism Saturation remains relatively high despite considerable fluctuations in alveolar oxygen pressure Moreover as oxygen pressure drops in the tissues a large flux of oxygen dissociates to meet metabolic requirements

This curve also explains one of the reasons why measurements of arterial oxygen tension are more informative in the higher levels of oxygenation than are measurements of saturation The pressure scale being more expanded than the saturation scale permits a more precise definition of oxygenation For this same reason pressure values derived from saturation and normal curves are inexact in the normal ranges though more accurate in the lower portion of the curve If a precise value for arterial oxygen pressure is required there is therefore no alternative to a direct measurement

Level of Oxygenation and Effect of Venous Admixture Because small changes in content or saturation are associated with large changes in pressure when the subject is well oxygenated a relatively small venous admixture which lowers the saturation slightly nevertheless produces a large pressure change At pressure values of about 40 mm Hg however when the dissociation curve is steep identical venous admixtures produce relatively little pressure drop For example if the alveolar and pulmonary capillary oxygen pressures are 100 mm of Hg (flat part of curve Fig 3) an admixture of venous blood amounting to 6 per cent of the cardiac output results in a fall in saturation from 97 to 94 5 per cent and a change in pressure from 100 mm Hg to 86 mm Hg If the capillary pressure is 40 mm Hg however the same venous admixture decreases the saturation from 74 5 to 73 0 producing a pressure drop of only about 1 0 mm Hg By varying oxygenation it is possible therefore to reduce the effect of a 6 per cent venous admixture on arterial oxygen pressure from 14 mm Hg to 1 0 mm Hg This effect is the basis of the method employed for measuring the diffusing capacity described in the preceding section The magnitude of the venous admixture component of the A a difference is sensitive to arterial oxygenation The A a difference is predominantly the venous admixture component at high levels of oxygenation and predominantly a membrane component at low levels

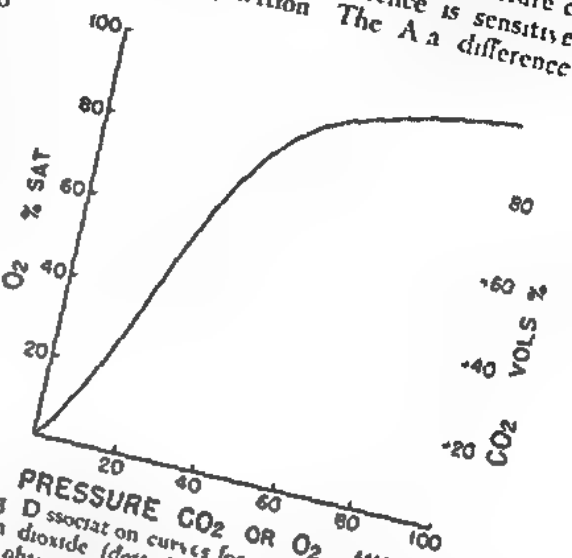

FIG 3 Dissociation curves for oxygen (solid line) and carbon dioxide (dotted lines) Upper carbon dioxide curve obtained when hemoglobin is reduced lower when hemoglobin is oxygenated (Data from PETERS and VAN SLYKE Quantitative Clinical Chemistry Baltimore 1935 Williams and Wilkins)

Effect of CO_2 and pH The dissociation curve is lowered or shifted to the right by increases in acidity of the blood (lowered pH) and by increases in carbon dioxide content This displacement signifies that at any pressure value less oxygen can be combined with hemoglobin than when the acidity and carbon dioxide content are less An increase in carbon dioxide content and a small fall in pH are precisely the changes occurring in the tissues Under these circumstances particularly during exercise with an increase in lactic acid production more oxygen is gained by the tissues from hemoglobin at a given oxygen pressure than would be the case in the absence of these changes By the same token the loss of carbon dioxide and increase in alkalinity taking place in the lung increase the oxygen carrying capacity of hemoglobin thereby enhancing its effectiveness in supplying tissues.

CO_2 Dissociation, Effect of Oxygenation Just as carbon dioxide and pH affect oxygen transport so, reciprocally, does oxygenation of hemoglobin affect carbon dioxide transport As shown in Figure 3, the CO_2 dissociation curve for blood containing reduced hemoglobin is above that for oxygenated blood, indicating a higher content for any P_{CO_2} The loss of oxygen from hemoglobin in the tissues, therefore, increases the blood's carbon dioxide carrying capacity and the oxygenation of hemoglobin in the lungs promotes the loss of carbon dioxide to the alveolar gases

Effects of Uneven Ventilation on O_2 and CO_2 Content Poor oxygenation of peripheral arterial blood attributable to the perfusion of poorly ventilated alveoli (high venous admixture) is commonly not associated with elevated carbon dioxide levels A comparison of the dissociation curves for oxygen and carbon dioxide (Fig 3) is helpful in explaining the reason for this apparent discrepancy Hyperventilation of alveoli produces a fall in $P_{A_{CO_2}}$ and a rise in $P_{A_{O_2}}$ Because the oxygen curve progressively flattens local elevation of $P_{A_{O_2}}$ increases the oxygen content of the corresponding pulmonary capillaries minimally Such blood does little, therefore, to compensate for the lowered content of the stream from poorly ventilated alveoli Inevitably, therefore, abnormally large regional variations in alveolar ventilation produce a lowering of arterial oxygen content On the other hand a fall in $P_{A_{CO_2}}$ effectively reduces the CO_2 content of the corresponding capillaries (Fig 2) Blood from hypoventilated areas, high in CO_2 content, is diluted by this stream, the resultant flow being more nearly normal in composition Considerable venous admixture need not, therefore, be associated with abnormal CO_2 contents

Respiration and pH Because carbon dioxide an acid when in solution, is excreted primarily by the lungs the respiratory apparatus is essential for maintaining normal acid base balance Less than 1 per cent of the body's daily output of acid is excreted by the kidneys, the balance appearing in the breath The degrees of blood acidity compatible with life are relatively narrow, ranging from approximately pH 7 0 to pH 7 8 Ventilatory insufficiency can be noxious, therefore, not only because of the effects of high concentrations of carbon dioxide and low concentrations of oxygen in the blood, but also because of increased acidity

Alveolar Ventilation, P_{CO_2}, and pH The acidity of the blood is proportional to the ratio, normally 20/1, of bicarbonate ion to carbonic acid, this latter being in equilibrium with dissolved CO_2 or P_{CO_2}

$$pH = pK + \log \frac{(HCO_3^-)}{H_2CO_3}$$

$$H_2CO_3 \rightleftarrows H_2O + CO_2$$

The value for P_{CO_2} is established by the relationship between the rate of carbon dioxide production in the tissues and the rate of its delivery to the atmosphere Alveolar ventilation, the mechanism of this delivery, is regulated primarily by the effect of P_{CO_2} itself on the respiratory center Thus, preservation of the optimal relationship between ventilation and pH is in part attributable to their common sensitivity to P_{CO_2}

Acidity Is Proportional to a Ratio It has been repeatedly emphasized that pH or acidity and alkalinity of blood is the function of a ratio as described in the Henderson Hasselbalch equation above So long as both numerator and denominator change proportionately, a normal pH can be associated with increases or decreases in carbon dioxide content or P_{CO_2} Both determinations must be made in order to calculate pH By the same token, a knowledge of pH and either of the other two variables enables one to calculate the third It is the practice in some laboratories to calculate P_{CO_2} from measurements of CO_2 content and pH rather than to determine P_{CO_2} directly

Regulation of Ventilation In addition to its sensitivity to P_{CO_2}, the respiratory pump is driven by falls in pH and by hypoxia The latter stimulus acts via chemoreceptors in contrast to the effect of carbon dioxide which is directly on medullary nerve cells Because of this difference in the site of action of these stimuli lack of responsiveness to one does not imply insensitivity to the other Thus the patient with advanced emphysema and carbon dioxide retention who exhibits no ventilatory response to P_{CO_2} is nevertheless driven by hypoxia and may stop breathing during its alleviation

A number of other stimuli contribute to the regulation of ventilation is The additive effect of all of these, however, fails to induce venti

latory rates comparable to those voluntarily produced during performance of the maximum breathing capacity The ventilatory response to exercise cannot be explained by changes in blood gas composition or pH cross circulation experiments have demonstrated that the stimuli for this response are not blood borne but are probably neurogenic in Thus although departures from normal gas concentrations institute ventilatory changes directed toward the restitution of the normal gaseous environment these are not sufficient to explain some of the commonest and most pronounced respiratory responses

CIRCULATION

Tissue Requirements Arterial Venous Differences and Flow In a normal resting subject 100 ml arterial blood contains about 20 0 ml of oxygen and 49 0 ml of carbon dioxide whereas the mixed venous blood contains about 15 4 ml oxygen and about 53 1 ml of carbon dioxide These values change as tissue requirements increase during exercise the arterial venous difference increasing Although a small proportion of this increase with respect to oxygen is due to the elevated alveolar P_O and to the polycythemia of exercise most is attributable to a fall in the oxygen content of mixed venous blood each volume of blood yields more oxygen to the tissues This increment is not however sufficient to satisfy the added requirements the rate of flow or cardiac output is also increased These two means of meeting tissue needs flow and extraction are reciprocally related high rates of flow as in hyperthyroidism associated with small arterial venous differences and relatively fixed rates as in mitral stenosis being compensated by large differences

Systemic and Pulmonic Circuit Differences The oxygen lost to the tissues is replaced in the lungs. Because the outputs of the right and left ventricles are equal flow through the lungs equals that through the tissues both being proportional to the oxygen requirements A salient difference between these two circuits however is the pressure under which this flow occurs Pulmonary artery systolic pressures do not normally exceed 30 mm of Hg and diastolic pressures about 10 mm Hg as contrasted to about 120 and 80 mm Hg in the aorta Normal mean pressures are approximately 20 mm Hg in the lungs as compared to about 100 systemically Since flows are equal these figures reveal a five-fold difference in the resistance of these two circuits

One of the reasons for this difference is that the pulmonary vessels are approximately at atmospheric pressure whereas those in the periphery are subject to tissue pressures A second reason is that the systemic vessels in particular the arterioles can sustain the lumenal changes requisite to a high resistance to fluid flow

Lability of Pulmonary Vessels Thinness of the pulmonary vessel walls does not imply however that the pulmonary vascular tree is completely lacking in malleability The probable reasons pulmonary artery pressures do not normally rise during exercise and augmented flow are that additional vessels open or that patent vessels enlarge the increase in diffusing capacity with exercise indicating an enlarged alveolar capillary bed is probably related to the former in Moreover hypoxia increases pulmonary pressures independently of a change in cardiac output, a further demonstrating the lability of the pulmonary vascular bed Although this network is not fixed in therefore the factors with the exception of hypoxia which influence its dimensions are less well established than are those regulating the dimensions of the systemic vessels

Steady State and the Fick Principle As stated previously tissue oxygen requirements are the product of flow times the oxygen lost from a given volume of blood to tissues or gained by a given volume from alveolar gas The amount lost from alveolar gas can be measured at the mouth from ventilation and the differences in the oxygen concentration of inspired and expired air oxygen lost to tissues per volume of blood can be established from samples of arterial and mixed venous blood With this information flow can be calculated (Fick principle)

It is the basis of this principle that the metabolic requirements of tissue cells can be precisely measured from the exchange of gases between the organism and the atmosphere Over a given period of time the technic is valid provided ventilation maintains an alveolar gas of constant composition diffusion progresses at a uniform rate circulation continues evenly and metabolism of cells remains unchanged This ideal "steady state" is probably seldom realized As a concept it does however, illus

trate the intimate relationship between the pulmonary and circulatory processes maintaining the gaseous composition of the internal environment Indeed, respiration is approached comprehensively, both in its normal and pathologic aspects, only when it is conceived as a problem in cardiopulmonary interrelations

REFERENCES

1 FRANK, N R, MEAD, J, SIEBENS, A A and STOREY C F Measurements of pulmonary compliance in 70 healthy young adults *J Appl Physiol*, in press

2 BALDWIN, E DEF COURNAND A and RICHARDS, D W JR Pulmonary insufficiency I Physiological classification, clinical methods of analysis, standard values in normal subjects *Medicine*, 27 243 1948

3 FRY, D L EBERT R V, STEAD, W W and BROWN C C The mechanics of pulmonary ventilation in normal subjects and in patients with emphysema *Am J Med*, 16 80, 1954

4 MEAD, J and WHITTENBERGER, J L Physical properties of human lungs measured during spontaneous respiration *J Appl Physiol*, 5 779 1952

5 NEILSEN M Die Respirationsarbeit bei Korperruhe und bei Muskel Arbeit *Skandinav Arch J Physiol* 74 299 1936

6 OTIS A B The work of breathing *Physiol Rev*, 34 449 1954

7 ROSSIER, P H and BUHLMANN A The respiratory dead space *Physiol Rev* 35 860 1955

8 FOWLER, W S Lung function studies II The respiratory dead space *Am J Physiol*, 154 405, 1948

9 PAPPENHEIMER, J R, FISHMAN, A P and BORRERO L M New experimental methods for determination of effective alveolar gas composition and respiratory dead space in anesthetized dogs and in man *J Appl Physiol*, 4 855 1952

10 RILEY R L COURNAND A and DONALD K W Analysis of factors affecting partial pressures of oxygen and carbon dioxide in gas and blood of lungs theory and methods *J Appl Physiol*, 4 77–101, 102 120, 1951

11 COMROE, J H, FORSTER, R E, DUBOIS, A B, BRISCOE, W A and CARLSEN, E The Lung Chicago, 1955 Year Book Publishers, Inc

12 RILEY, R L, SHEPARD R H, COHN, J E, CARROLL, D G and ARMSTRONG, B W Maximal diffusing capacity of the lungs *J Appl Physiol*, 6 573 1954

13 SIEBENS A A and FRANK, N R Diffusing capacity at exercise in patients with alterations in area of pulmonary capillary bed *Am J Physiol*, 179 673 1954

14 COHN, J E, CARROLL, D G, ARMSTRONG, B W, SHEPARD, R H and RILEY, R L Maximal diffusing capacity of lung in normal male subjects of different ages *J Appl Physiol*, 6 588, 1954

15 BRINKMAN, G L, JOHNS, C J, DONOSO, H and RILEY, R L A modification of the method of Riley, Proemmel and Franke for determination of oxygen and carbon dioxide tensions in blood *J Appl Physiol*, 7 340, 1954

16 KROGH, M Diffusion of gases through the lungs of man *Am J Physiol*, 49 271, 1914–15

17 LILIENTHAL, J L, RILEY, R L, PROEMMEL, D D and FRANKE, R E An experimental analysis in man of the oxygen pressure gradient from alveolar air to arterial blood *Am J Physiol*, 147 199 1946

18 GRAY, J S Pulmonary Ventilation and Its Physiological Regulation, Springfield, Ill 1950 Charles C Thomas

19 KAO F F and RAY, L H Regulation of cardiac output in anesthetized dogs during induced muscular work *Am J Physiol*, 179 255 1954

20 SIEBENS A A, SMITH, R E and STOREY, C F The effect of acute hypoxia on pulmonary vessels in man *Am J Physiol*, 180 428, 1955

21 WEARN, J T, ERNSTENE, A C, BROMER, A W, BARR, J S, GERMAN, W J and ZSCHIESCHE L J The normal behavior of the pulmonary blood vessels with observations on the intermittence of the flow of blood in the arterioles and capillaries *Am J Physiol*, 109 236, 1934

5

Pathologic Physiology of Respiration

HURLEY L. MOTLEY, M.D., *Los Angeles, California*

From the Cardio-Respiratory Laboratory, University of Southern California School of Medicine, Los Angeles, Calif.

THE essential features of respiration are related to the maintenance of normal tissue oxygen tension and to the adequate removal of carbon dioxide at all times. The adequacy of the blood gas exchange can be studied during both rest and exercise from measurements on lung volumes, arterial blood and the expired air. One set of measurements provides information on the bellows action of the chest and lungs regarding the ability of the individual to move air in and out of the lungs in adequate volumes. The other set of measurements provides information on the blood gas exchange regard[illegible] of oxygen [illegible]

c[illegible] extent and type of disturbed function [illegible] information in the individual case regardless of the etiology. No single test is satisfactory for the accurate and complete clinical evaluation of the extent of pulmonary function impairment.

Oxygen may be administered by several methods providing a normal arterial blood saturation, but a saturation of 96 per cent or more does not insure an adequate removal of carbon dioxide if (1) alveolar aeration be inadequate either because of a pulmonary minute ventilation too small or a tidal air volume too shallow, or (2) to perfusion of blood through poorly or non-ventilated alveoli of the lungs. When the respiratory gas exchange is inadequate and treatment is required, the two main factors to be considered are (1) an inspired oxygen partial pressure (pO_2) of sufficient magnitude to saturate the arterial blood to the normal level of 96 to 98 per cent and (2) an adequate minute ventilation to provide a sufficiently uniform alveolar aeration to blow off the carbon dioxide.

LUNG VOLUME MEASUREMENTS

Information regarding the efficiency of the chest and lungs as a bellows may be obtained from spirogram tracings and from the residual air capacity measurement.[1] The total vital capacity, the timed vital capacity for three seconds and the maximal breathing capacity are obtained from rapid spirogram tracings on the 13½ L. respirometer.* Total vital capacity is obtained both in the supine and standing positions. A marked reduction in the total vital capacity in the standing position as compared to the supine position indicates the presence of severe pulmonary insufficiency. The timed vital capacity for three seconds in the standing position is obtained by having the patient take in as deep a breath is possible, hold the breath momentarily and then on command blow the air out of the lungs as rapidly as possible. The volume exhaled in the first three seconds from the exact beginning of expiration is called the three second timed vital capacity. The timed vital capacity for three seconds is normally the same as the predicted total vital capacity. The timed vital capacity for three seconds is an important measurement of vital capacity, as this is the maximal effective portion which can be used with a respiratory rate of 15 or more per minute (a rate of 15 per minute requires four seconds per breath and one second is allowed to breathe in). Vital capacity is commonly measured by having the individual take a deep breath and then blow out all of the air as far as possible. Vital capacity may be taken, however, by having the individual first blow the air out of the lungs as far as possible and then take in as deep a breath as possible. In the normal individual there is no significant difference between the two methods, but in some patients with pulmonary disease a better vital capacity measurement may be obtained

* Warren E. Collins Co., Boston, Mass.

by the second method In either procedure the volume difference is measured between maximal inflation and maximal deflation of the lung, and no good clinical evidence exists that measuring the volume difference between maximal deflation followed by maximal inflation is not just as valid The level of the diaphragm may shift with position and activity The measurement of vital capacity in separate steps (the sum of inspiratory reserve and expiratory reserve) is subject to error with shifts in the level of the diaphragm and is unsatisfactory

The maximal breathing capacity (MBC) reveals the largest volume of air which an individual is able to move in and out of the lungs in a given short unit of time (twelve to fifteen seconds) but is expressed as L per minute The individual is instructed to breathe as deeply and as rapidly as possible for twelve seconds (never longer than fifteen seconds), and the rate and depth varied in successive trials (not less than three) to obtain the maximal value The 13½ L. respirometer was developed to provide a mechanical recorder with minimal breathing resistance for deep, fast breathing and to permit quick accurate determinations of the MBC value (five to ten minutes) [2] When the rate and depth of breathing are properly varied, one obtains the greatest MBC of which the subject is capable and the learning factor as such is not a significant feature The degree of bronchospasm is measured quantitatively by comparing the MBC before and immediately after one bronchodilator treatment

In men a maximal breathing capacity of 120 L per minute indicates no significant degree of pulmonary emphysema present, if the maximal breathing capacity is less than 40 L per minute the presence of a significant degree of emphysema is indicated [3] A maximal breathing capacity between 40 and 120 L per minute is indeterminate with respect to the presence or absence of a significant degree of pulmonary emphysema The spirogram tracings in emphysema characteristically reveal prolonged exhalation time, evidence of air trapping after a few deep breaths in rapid succession as during the maximal breathing capacity test involving rapid voluntary respiratory movements, the lungs are kept filled with more air than normal (high inspiratory level) which elevates the tracing of the rate and depth of breathing on the record and indicates increased breathing resistance

The shape of the spirogram tracings as observed on the rapidly moving kymograph drum (32 mm in twelve seconds) reveals characteristic features of the expiratory flow The slow, prolonged exhalation curve indicates obstruction to the air flow, and the failure of the exhalation curve on the tracing to return to the beginning level indicates air trapping Satisfactory spirogram tracings can be obtained usually in five to ten minutes, a slightly longer time period is required to evaluate the degree of bronchospasm, since the bronchodilator should be administered over a period of at least ten minutes Measurements obtained from spirogram tracings are useful in evaluating the response to treatment, in following the clinical course of a disease by obtaining serial spirogram tracings at intervals, in screening tests for surgery in detecting anesthetic risks, in eliminating poor risks in workers exposed to lung irritants and environmental dust hazards and in providing information on other types of problem cases Spirogram tracings represent simple pulmonary function tests that provide a tremendous amount of information of the status of an individual's lungs [2] Normal spirogram tracings of the three-second timed vital capacity and the maximal breathing capacity indicate the presence of normal lung elasticity, the absence of obstruction, good movement of the diaphragm and the absence of a significant degree of pulmonary emphysema

The residual air normally occupies about 25 per cent of total lung capacity being slightly less in the younger age group (20 per cent for adults under thirty-five years of age) and slightly more for individuals over sixty years of age (30 per cent) Data obtained in this laboratory from studies on 100 patients with normal spirogram tracings (including the total vital capacity, the timed vital capacity for three seconds, the maximal breathing capacity and the shape of the exhalation curve) with an age range of sixteen to seventy years indicate that the increase in residual air capacity is of small magnitude even with the aging process and normally does not exceed 35 per cent of total lung capacity [4] It is realized that many individuals have residual air volumes which represent more than 35 pe cent of total lung capacity who are still workin

and report no pulmonary complaints, but this does not mean that their lung volumes are normal any more than a blood pressure of 210/140 is considered normal even though the patient has no complaints and may work for many years with the elevated pressure There is a very large breathing reserve in a normal lung as attested by the fact that many individuals with one good lung can get along remarkably well following a pneumonectomy

Residual air capacity can be accurately measured using the oxygen open circuit method[1] allowing the patient to breathe 100 per cent oxygen for seven minutes with collection of all the expired air during the breathing period in a large gasometer If the alveolar sample contains more than 1 5 per cent nitrogen after breathing oxygen for seven minutes, impairment in the uniformity of air distribution in the lung exists Small samples of the air in the gasometer are analyzed for the per cent of nitrogen, and the total volume of nitrogen washed out during the seven-minute period of breathing is computed from the total measured volume and the sample analysis The volume of air in the lungs required to contain the volume of nitrogen washed out can then be calculated, after making suitable corrections for the nitrogen diffusing from the blood during the seven minute period of oxygen breathing The residual air capacity plus the vital capacity equal total observed lung capacity (TLC) for the individual case and in pulmonary emphysema the TLC value may be the normal predicted, increased or decreased Wide individual variations have been noted for the total lung capacity in patients with pulmonary emphysema[2] for in some cases the total lung capacity may be increased as much as 40 per cent above the normal predicted and in other cases decreased more than 50 per cent below the normal predicted The total lung capacity may be normal increased or decreased in an individual case, hence the ratio of the residual air to total lung capacity is most important, as this corrects for changes in total lung volume and permits proper evaluation of the degree of the pulmonary emphysema Pulmonary emphysema has been classified on a quantitative basis by expressing the residual air as the per cent of total lung capacity If the residual air occupies less than 35 per cent and more than 25 per cent of total lung capacity a slight but insignificant degree of pulmonary emphysema may exist If the residual air occupies 35 to 45 per cent of total lung capacity, a moderate but significant degree of pulmonary emphysema exists, from 45 to 55 per cent an advanced or severe degree of pulmonary emphysema exists, and above 55 per cent an advanced or very severe degree of pulmonary emphysema exists In some cases the degree of pulmonary emphysema present as determined by the physiologic method was very poorly correlated with the x-ray films and even the physical examination was misleading Accurate residual air measurements remove the uncertainty of the evaluation of the amount of emphysema present and provide information valuable in clinical management of the individual case[3]

A numerical ventilation factor (VF) has been used to evaluate the efficiency of the chest and lungs as a bellows from the average of (1) the timed vital capacity for three seconds (2) the maximal breathing capacity and (3) the residual per cent of total lung capacity, all three expressed as per cent of the normal predicted on a basis of 100 per cent for the normal[4] The ventilation factor provides a single figure value of the patients ability to use the chest and lungs as a bellows for aerating the alveoli and this figure has been found to be well correlated with the arterial pCO_2 by direct tension measurements[5] and the inspired alveolar pO_2 difference in mm Hg[6] calculated by direct tension measurements of arterial pO_2 and pCO_2 and the expired air pCO_2 If the ventilation factor is decreased as low as 25 per cent of the normal predicted, dyspnea is usually present at rest A low ventilation factor indicates a poor anesthetic risk

In general, when respiratory complaints are present in pulmonary emphysema the pathologic changes responsible are very extensive The large pulmonary reserve in man often obscures clinical or roentgenologic detection in the presence of severe emphysema, obvious clinical symptoms being a late manifestation and so often is found in pulmonary fibrosis and emphysema

Newer research techniques of promise providing information on the status of air flow in the lung include pulmonary compliance tests as described by Mead and associates[7] Pulmonary compliance on the distensibility of the lung is obtained from recording of two variables (lung volume and intrapleural pres-

sure from the esophagus) simultaneously on an oscilloscope in the form of a loop, and the volume determination is divided by the pressure determination to get the compliance value (normal 150 to 250 ml per cm water pressure) The use of the nitrogen meter[8] for obtaining nitrogen exhalation curves appears very promising, but as yet more studies are needed regarding the practicability and reliability of both test and apparatus

OXYGEN TRANSPORT IN THE LUNG

The direct determination of the oxygen tension[9] (pO_2) and carbon dioxide tension (pCO_2) in the arterial blood has been most helpful in studying the transport of oxygen across the lung to the blood[10] The difference between the mean oxygen partial pressure (pO_2) of inspired air (150 mm Hg at sea level) and that of the alveolus is referred to as the aeration gradient (normal 50 mm Hg) and the difference between the mean oxygen partial pressure of the alveolus and that of the arterial blood is designated as the transfer gradient (normal 5 mm Hg) Elevation of the transfer gradient indicates changes in the alveolar arterial oxygen gradient from all causes including diffusion defect with increased resistance in the pulmonary membrane, shunting of blood through non ventilated areas and impaired alveolar aeration and perfusion Factors interfering with the oxygen respiratory gas exchange are primarily those related to mixing and dilution, diffusion, shunting and distribution

Decreased ventilation (reduction in vital capacity, maximal breathing capacity, the timed vital capacity single or combined) increased residual air or increased ratio of residual air to total lung capacity (pulmonary emphysema), impaired diffusion, shunting and poor distribution are the factors most often responsible for the lowering of the arterial blood oxygen saturation Normally there is a predictable relationship between the arterial pO_2 and the per cent saturation as given by standard charts showing the blood oxygen hemoglobin dissociation curve in relation to the pH However, in chronic pulmonary disease in which there is venous admixture or [illegible] of the lung perfused but not [illegible] ratio may no longer hold as blood [illegible] the ventilated [illegible] blood gas [illegible] occurs only [illegible] which [illegible] contact with th[illegible] nus where venous admixture or shunting of a sufficient degree, the arterial blood oxygen saturation will not be 100 per cent saturated even on oxygen breathing and in the presence of a quite high arterial blood pO_2 tension In order for all of the blood to be saturated (all hemoglobin combined as oxyhemoglobin), intimate contact with the red blood cell and the alveolar gas is required, as the red cells normally pass through the capillaries of the lung in single file There are normally 4 to 5 million red blood cells per cu mm and with a total blood volume of about 5 L many million red blood cells must come in close contact with the alveolar gas in the lung capillaries so that all of the hemoglobin may be combined as oxyhemoglobin and thus provide 100 per cent saturation When a significant degree of venous admixture is present (perfusion without ventilation), unsaturation results even though the oxygen tensions be quite high in arterial blood as a result of exposure of ventilated alveoli to high oxygen tension A high oxygen tension in the blood does not insure complete saturation of all the red blood cells because there is not an adequate opportunity for the intimate contact required to insure that all of the hemoglobin will be combined with oxygen to form oxyhemoglobin

The aeration gradient (the difference between the inspired pO_2 and the mean alveolar pO_2) is increased by a high residual air volume, hypoventilation, retained secretions impairing alveolar aeration and bronchospasm with a resulting lowering of the alveolar pO_2 and in turn the arterial blood oxygen saturation Hyperventilation may lower an elevated aeration gradient to normal and decrease the alveolar pCO_2 Increased resistance for the movement of oxygen across the pulmonary membrane constitutes a true diffusion difficulty and lowers the arterial pO_2 and the oxygen saturation Changes in the pulmonary membrane affecting oxygen diffusion are independent of pulmonary emphysema which may or may not be present

Most venous admixtures of a severe degree occur in congenital cardiac anomalies and arteriovenous fistulas[11] of the lung with very high mean gradients of pressure between the alveoli and arterial blood (transfer) also seen in the presence of diffusion difficulties as beryl[illegible] [illegible] [illegible]eolar aeration and perfusion [illegible] factor) constitutes a common [illegible] the di[illegible]

cause of the elevation of the transfer gradient in chronic pulmonary disease being by far the most common factor[8] Fibrosis produces various degrees of impairment of air circulation to the alveoli (there is a loss of lung elasticity and a narrowing of the bronchioles) so that although perfusion may be present for some alveoli, ventilation may be inadequate or absent Alveoli which are perfused but not aerated represent circulatory pathways which are small shunts[12] and lower the arterial blood

alveolar capillaries may be obliterated to a greater or lesser extent resulting in ventilation without perfusion and the alveoli so involved are functional dead space Hyperventilation can improve the oxygen transfer only in those alveoli that are poorly ventilated but still perfused with blood The distribution factor is commonly involved in such chronic pulmonary conditions as fibrosis and emphysema and may be present in various degrees where there is obstruction to alveolar aeration as in atelectasis consolidation of the lungs retained secretions or fluids and bronchospasm [12]

The normal movement of the diaphragm with the intercostal muscles provides a bellows to pump air in and out of the lungs in sufficient quantities to supply the necessary amount of oxygen and to remove effectively the carbon dioxide produced by metabolic processes In the normal individual this bellows like action of respiration provides a fairly uniform alveolar aeration although usually a small number of alveoli are more fully aerated than the others (that is a small percentage of the alveoli are relatively hyperventilated and a small percentage hypoventilated) However the preponderance of the alveoli are normally ventilated thus providing an adequate oxygen intake and carbon dioxide output even though the cardiac output may be increased three times or more with exercise Impairment of the bellows action of the chest and lungs because of pathologic changes may severely alter the blood gas exchange as a result of defective alveolar aeration Impairment of the function of efferent nerves from the respiratory center to the respiratory muscles loss of lung elasticity by fibrosis narrowing of the bronchioles by fibrosis spasm or secretion emphysema or chest deformities are factors interfering with the normal use of the chest and lungs as a bellows

Measurements on arterial blood are obtained both at rest and immediately after one minute of step-up exercise (thirty steps on an 8 inch stool) A drop in the arterial blood oxygen saturation of 5 to 10 per cent or more below the resting level with mild exercise indicates severe disability An increase in the exercise oxygen saturation above the resting level indicates less disability than implied by the resting level measurement In general the exercise saturation tends to decrease in severe emphysema but this is not always the case, and in pulmonary fibrosis without emphysema a marked drop in exercise arterial blood oxygen saturation frequently occurs The saturation of the blood perfusing the lung during exercise may not be decreased even though the oxygen uptake is markedly decreased and this indicates the inability to increase the pulmonary blood flow adequately during the exercise proportionate to the test although the blood that gets through comes in contact with aerated alveoli and may be normally saturated In some cases of emphysema the hyperventilation (as measured by the minute ventilation volume) may be adequate to maintain the normal sea level difference in providing a mean alveolar pO_2 of 100 mm Hg The mean inspired alveolar pO_2 difference correlates well with the ventilation factor in a large series of cases[8] Intermittent positive pressure breathing (IPPB) with compressed air[10] restores the arterial blood saturation to normal or near normal in many cases of emphysema by improving the ventilation in the poorly aerated alveoli as compared to the ambient breathing and constitutes a valuable test as to the cause

the ventilatory approach with IPPB and even on 100 per cent oxygen breathing the arterial blood is not 100 per cent saturated In some cases the drop in the exercise saturation as compared to the resting results from inadequate alveolar aeration and this can be demonstrated by performing the step-up exercise using IPPB on compressed air to increase alveolar aeration If the exercise drop is due to increased resistance in the alveolar-capillary membrane the IPPB will have no effect but breathing 30 per cent oxygen in nitrogen during

sure from the esophagus) simultaneously on an oscilloscope in the form of a loop and the volume determination is divided by the pressure determination to get the compliance value (normal 150 to 250 ml per cm water pressure) The use of the nitrogen meter[8] for obtaining nitrogen exhalation curves appears very promising but as yet more studies are needed regarding the practicability and reliability of both test and apparatus

OXYGEN TRANSPORT IN THE LUNG

The direct determination of the oxygen tension[9] (pO_2) and carbon dioxide tension (pCO_2) in the arterial blood has been most helpful in studying the transport of oxygen across the lung to the blood [illegible] The difference between the mean oxygen partial pressure (pO_2) of inspired air (150 mm Hg at sea level) and that of the alveolus is referred to as the aeration gradient (normal 50 mm Hg) and the difference between the mean oxygen partial pressure of the alveolus and that of the arterial blood is designated as the transfer gradient (normal 5 mm Hg) Elevation of the transfer gradient indicates changes in the alveolar arterial oxygen gradient from all causes including diffusion defect with increased resistance in the pulmonary membrane shunting of blood through non ventilated areas and impaired alveolar aeration and perfusion Factors interfering with the oxygen respiratory gas exchange are primarily those [illegible] d capacity maximal breathing capacity the timed vital capacity single or combined), increased residual air or increased ratio of residual air to total lung capacity (pulmonary emphysema) impaired diffusion shunting and poor distribution are the factors most often responsible for the lowering of the arterial blood oxygen saturation Normally there is a predictable relationship between the arterial pO_2 and the per cent saturation as given by standard charts showing the blood oxygen hemoglobin dissociation curve in relation to the pH However in chronic pulmonary disease in which there is venous admixture or areas of the lung perfused but not ventilated this ratio may no longer hold as blood by passes the ventilated areas and blood gas exchange occurs only with the blood which comes in contact with the alveoli Thus where there is venous admixture or shunting of a sufficient degree, the arterial blood oxygen saturation will not be 100 per cent saturated even on oxygen breathing and in the presence of a quite high arterial blood pO_2 tension In order for all of the blood to be saturated (all hemoglobin combined as oxyhemoglobin) intimate contact with the red blood cell and the alveolar gas is required as the red cells normally pass through the capillaries of the lung in single file There are normally 4 to 5 million red blood cells per cu mm and with a total blood volume of about 5 L many million red blood cells must come in close contact with the alveolar gas in the lung capillaries so that all of the hemoglobin may be combined as oxyhemoglobin and thus provide 100 per cent saturation When a significant degree of venous admixture is present (perfusion without ventilation) unsaturation results even though the oxygen tensions be quite high in arterial blood as a result of exposure of ventilated alveoli to high oxygen tension A high oxygen tension in the blood does not insure complete saturation of all the red blood cells because there is not an adequate opportunity for the intimate contact required to insure that all of the hemoglobin will be combined with oxygen to form oxyhemoglobin

The aeration gradient (the difference between the inspired pO_2 and the mean alveolar pO_2) is increased by a high residual air volume, hypoventilation retained secretions impairing alveolar aeration and bronchospasm with a resulting lowering of the alveolar pO_2 and in turn the arterial blood oxygen saturation Hyperventilation may lower an elevated aeration gradient to normal and decrease the alveolar pCO_2 Increased resistance for the movement of oxygen across the pulmonary membrane constitutes a true diffusion difficulty and lowers the arterial pO_2 and the oxygen saturation Changes in the pulmonary membrane affecting oxygen diffusion are independent of pulmonary emphysema which may or may not be present

Most venous admixtures of a severe degree occur in congenital cardiac anomalies and arteriovenous fistulas[11] of the lung with very high mean gradients of pressure between the alveoli and arterial blood (transfer) also seen in the presence of diffusion difficulties as beryllosis Unequal alveolar aeration and perfusion (the distribution factor) constitutes a common

all reflexes and direct stimuli acting on the respiratory center The normal function of the respiratory center depends on an adequate oxygen supply, and if the oxygen lack be severe enough, the respiratory center will fail completely The respiratory center tends

TABLE 1

MEASUREMENTS OF ARTERIAL BLOOD OXYGEN SATURATION CARBON DIOXIDE CONTENT AND pH ON AIR AND AFTER SIX MINUTES OF 99 4 PER CENT OXYGEN BREATHING IN TEN PATIENTS WITH SEVERE PULMONARY EMPHYSEMA AND HYPOXEMIA*

Case	Residual Air Per cent of Total Lung Capacity	Air Breathing			Oxygen Breathing Six Minutes		
		O_2 Saturation %	CO_2 Content Volumes %	pH	O_2 Saturation %	CO_2 Content Volumes %	pH
1	52 8	85 3	63 1	7 50	94 5	64 9	7 44
2	54 9	90 0	49 6	7 46	100 0	49 8	7 43
3	50 8	91 3	51 1	7 52	98 8	51 3	7 42
4	66 6	66 2	68 5	7 33	100 0	68 9	7 23
5	61 5	87 8	49 1	7 41	100 0	49 9	7 35
6	56 2	85 0	41 8	7 58	91 0	43 0	7 37
7	59 8	83 8	49 2	7 46	99 8	52 1	7 35
8	59 2	62 3	63 7	7 37	100 0	65 1	7 29
9	62 1	87 3	55 3	7 45	97 4	56 5	7 37
10	59 4	92 6	50 6	7 45	98 8	51 2	7 42

* Oxygen saturation based on arterial oxygen content and capacity on Van Slyke and cuvette double scale Waters-Conley oximeter CO_2 content on Van Slyke and pH on Cambridge glass electrode Note the greater degree of respiratory acidosis present in the most severe cases of hypoxemia during oxygen breathing

to acquire or develop tolerance with a lowered sensitivity to changes which develop slowly as a decreasing pO_2 and an increasing pCO_2 commonly present in chronic pulmonary insufficiency If the fall in the blood oxygen tension occurs slowly very low levels may frequently be reached with little direct stimulating effect on the respiratory center, also a similar mechanism applies in reverse for carbon dioxide which may gradually increase in the blood to a level at which the respiratory center becomes refractory to concentrations that were formerly effective However in severe hypoxemia if the oxygen saturation in the arterial blood be suddenly lowered and the drop be of sufficient magnitude or if the carbon dioxide tension of the blood be elevated markedly an increase in respiration or minute ventilation may occur although the sensitivity of the response is markedly reduced in relation to the magnitude of the stimulus normally effective

Patients needing artificial respiration to supplement ambient breathing already have an elevated arterial blood pCO_2 so that the further use of carbon dioxide in oxygen (as 5 or 7 per cent) is not physiologic [13] The use of 5 per cent carbon dioxide would only increase the acidosis of the subject in need of artificial respiration Studies of arterial blood before treatment in patients needing artificial respiration reveal decreased oxygen tensions arterial oxygen unsaturation, increased carbon dioxide content, increased pCO_2 and decreased arterial blood pH It is a popular misconception that carbon dioxide mixtures are valuable in the treatment of respiratory depression or asphyxia Mixtures of carbon dioxide as high as 25 per cent have been advocated for use in artificial respiration on the assumption that a respiratory center too depressed to respond to 5 per cent carbon dioxide would respond to a higher concentration In the asphyxiated patients the blood carbon dioxide level is above normal so that the carbon dioxide no longer acts as a respiratory stimulus in fact it may be a depressant In dogs subjected to experimental severe acute hypoxia 5 per cent carbon dioxide produced respiratory depression and 15 per cent carbon dioxide produced even more profound respiratory and circulatory depression when administered in the same stages of hypoxia [14]

Adequate removal of carbon dioxide depends on the minute ventilation and the uniformity of alveolar aeration and perfusion If the respiration is depressed the carbon dioxide increases and the pH of the arterial blood decreases (respiratory acidosis) Present concepts indicate that there is no rational basis for the use of carbon dioxide in asphyxia and that such a procedure is not only contraindicated but dangerous Recently an experimental study was reported indicating that even in carbon monoxide poisoning, the addition of CO_2 to oxygen does not appear

the exercise should give a normal saturation If a shunt exists the blood will be unsaturated during exercise on the high oxygen breathing mixture, even after breathing 100 per cent oxygen The above tests provide information as to the nature of the arterial blood oxygen unsaturation

REGULATION OF CARBON DIOXIDE IN THE BODY

Information on the status of carbon dioxide is obtained from actual measurements of the minute ventilation in L per minute, respiratory rate, tidal volume, the arterial pH direct on a glass electrode, the arterial CO_2 content, the CO_2 combining power and the direct tension measurement of arterial pCO_2 The direct measurement of the arterial blood pH on a glass electrode apparatus is the most practical single test to provide quickly accurate information concerning the exact status of acidosis or alkalosis and this also serves as a very useful guide in regulating treatment procedures in either acidosis or alkalosis The CO_2 combining power and even the arterial CO_2 content cannot be relied upon in many cases of chronic pulmonary disease especially with emphysema because of wide individual variations observed when correlated with direct measurements of the arterial blood pH Numerous published reports emphasize the importance of evaluating the status of carbon dioxide to prevent the development of respiratory acidosis as in prolonged surgical procedures especially chest operations even in the presence of a normal arterial blood oxygen saturation provided by an anesthesia machine with oxygen but with an inadequate alveolar ventilation to blow off the CO_2

An elevated arterial CO_2 content (normal 48 5 volumes per cent at sea level) indicates impaired alveolar aeration and warns of the possibility of respiratory acidosis developing during infections or a depressed respiration by sedative drugs, anesthetics, high oxygen breathing or by any other means Drowsiness, stupor or coma, characteristic symptoms in respiratory acidosis, appears to be related to pH changes rather than the absolute level of the CO_2 content or pCO_2 The mental status correlated with arterial blood studies over a twelve-week period in a patient with a very severe degree of pulmonary insufficiency complicated by infection was related to pH changes rather than the absolute level of the CO_2 content or pCO_2 Patients with chronic pulmonary disease and an advanced degree of pulmonary function impairment with hypoxemia may occasionally become drowsy, stuporous, delirious, unconscious, and even die from respiratory acidosis when subjected to high concentrations of oxygen by catheter, mask or tent, a phenomenon attributable to the development of a high pCO_2 and a low pH from a depressed respiration previously being maintained partly reflexively from the carotid bodies by the hypoxic stimulation The respiratory center apparently becomes tolerant to increased carbon dioxide so the latter has no further stimulating effect In such a patient a sudden change to high oxygen breathing decreases the minute ventilation by removing part of the reflex stimulation of the respiration center from the carotid bodies which are stimulated by the low oxygen saturation of the blood The high oxygen breathing relieves the arterial blood oxygen unsaturation and removes the stimulus from the carotid bodies and the total minute ventilation decreases in some cases to a critical level unless supported by mechanical aids as IPPB The data given in Table 1 reveal the rapid onset of respiratory acidosis, which can be demonstrated in some cases of severe pulmonary emphysema even after short (six-minute) periods of high oxygen breathing as measured by changes in the pH and CO_2 content However, as previously pointed out the direct determination of the arterial blood pH reveals the exact status of the acidosis or alkalosis at the time regardless of what the oxygen or CO_2 content, pCO_2 or CO_2 combining power may be

An increase in carbon dioxide tension of the blood normally constitutes a strong stimulus to the respiratory center, primarily by direct action, with a resulting increase in pulmonary ventilation (such as seen normally when a mixture of 5 per cent CO_2 with air or oxygen is breathed for a short interval) Other afferent impulses which stimulate the respiratory center reflexively and increase pulmonary ventilation are the Hering Breuer reflex from the lung alveoli, low blood oxygen saturation with stimulation of carotid and aortic bodies painful stimulation of peripheral nerves, changes in the systemic blood pressure and the influence of higher cerebral centers The rate and depth of breathing and the minute ventilation volume represent the resultant of

all reflexes and direct stimuli acting on the respiratory center The normal function of the respiratory center depends on an adequate oxygen supply, and if the oxygen lack be severe enough, the respiratory center will fail completely The respiratory center tends

TABLE 1

MEASUREMENTS OF ARTERIAL BLOOD OXYGEN SATURATION CARBON DIOXIDE CONTENT AND pH ON AIR AND AFTER SIX MINUTES OF 99 4 PER CENT OXYGEN BREATHING IN TEN PATIENTS WITH SEVERE PULMONARY EMPHYSEMA AND HYPOXEMIA*

Case	Residual Air Per cent of Total Lung Capacity	Air Breathing			Oxygen Breathing, Six Minutes		
		O_2 Saturation %	CO_2 Content Volumes %	pH	O_2 Saturation %	CO_2 Content Volumes %	pH
1	52 8	85 3	63 1	7 50	94 5	64 0	7 44
2	54 9	90 0	49 6	7 46	100 0	49 8	7 43
3	50 8	91 3	51 1	7 52	98 8	51 3	7 45
4	66 6	66 2	68 5	7 33	100 0	68 9	7 23
5	61 5	87 8	49 1	7 41	100 0	49 9	7 35
6	56 2	85 0	41 8	7 58	91 0	43 0	7 37
7	59 8	83 8	49 2	7 46	99 8	52 1	7 35
8	59 2	62 3	63 7	7 37	100 0	65 1	7 29
9	62 1	87 3	55 3	7 45	97 4	56 5	7 37
10	59 4	92 6	50 6	7 45	98 8	51 2	7 42

severe cases of hypoxemia during oxygen breathing

to require or develop tolerance with a lowered sensitivity to changes which develop slowly as a decreasing pO_2 and an increasing pCO_2 commonly present in chronic pulmonary insufficiency If the fall in the blood oxygen tension occurs slowly very low levels may frequently be reached with little direct stimulating effect on the respiratory center, also a similar mechanism applies in reverse for carbon dioxide which may gradually increase in the blood to a level at which the respiratory center becomes refractory to concentrations that were formerly effective However in severe hypoxemia if the oxygen saturation in the arterial blood be suddenly lowered and the drop be of sufficient magnitude or if the carbon dioxide tension of the blood be elevated markedly an increase in respiration or minute ventilation may occur although the sensitivity of the response is markedly reduced in relation to the magnitude of the stimulus normally effective

Patients needing artificial respiration to supplement ambient breathing already have an elevated arterial blood pCO_2 so that the further use of carbon dioxide in oxygen (as

treatment in patients needing artificial respira

blood pH It is a popular misconception that carbon dioxide mixtures are valuable in the treatment of respiratory depression or asphyxia Mixtures of carbon dioxide as high as 25 per cent have been advocated for use in artificial respiration on the assumption that a respiratory center too depressed to respond to 5 per cent carbon dioxide would respond to a higher concentration In the asphyxiated patients the blood carbon dioxide level is above normal so that the carbon dioxide no longer acts as a respiratory stimulus in fact it may be a depressant In dogs subjected to experimental severe acute hypoxia 5 per cent carbon dioxide produced respiratory depression and 15 per cent carbon dioxide produced even more profound respiratory and circulatory depression when administered in the same stages of hypoxia [12]

Adequate removal of carbon dioxide depends on the minute ventilation and the uniformity of alveolar aeration and perfusion If the respiration is depressed the carbon dioxide increases and the pH of the arterial blood decreases (respiratory *acidosis*) Present concepts indicate that there is no rational basis for the use of carbon dioxide in asphyxia and that such a procedure is not only contraindicated but dangerous Recently an experimental study was reported indicating that even in carbon monoxide poisoning the addition of CO_2 to oxygen does not appear advantageous oxygen alone being preferable [14] The Council of Physical Medicine and Rehabilitation of the *American* Medical Associa-

American Red Cross now recom- tators en

and carbon dioxide

ACID-BASE BALANCE

The maintenance of a normal acid-base balance depends principally on the buffer system of the blood and the respiratory segment of the acid-base balance, although quite narrow normally responds rapidly to correct for sudden changes in CO_2. The ratio of $\frac{H_2CO_3}{BHCO_3}$ in the blood in the bicarbonate system is normally 1 20. The concentration of carbonic acid in the arterial blood can be rapidly decreased by hyperventilation increasing alveolar aeration and lowering alveolar pCO_2 and in turn the arterial pCO_2 which is practically the same as the alveolar pCO_2. The blowing off of carbon dioxide from the lungs tends to restore the normal ratio of $\frac{H_2CO_3}{BHCO_3}$ (1 20) and a normal pH when the carbonic acid is increased by fixed acids, a reaction which occurs much more rapidly than can be accomplished by the excretion of acid in the kidneys. The pH is not dependent on the total carbonate or alkali reserve (a term used to designate the total quantity of carbon dioxide in the plasma bound as bicarbonate). The ratio of $\frac{H_2CO_3}{BHCO_3}$ may be 1 20, but the quantity of each could be three times the normal value (3 60 with a ratio of still 1 20 and a normal pH). The volume of carbon dioxide combined at 40 mm. Hg in the plasma is the carbon dioxide combining power (commonly used clinically as the measure of the available alkali), however, this measurement does not provide directly the concentration of either total carbon dioxide or bicarbonate in the blood, hence the shortcomings of this measurement in many cases of chronic pulmonary disease of long standing. The pCO_2 of the arterial blood is a function of alveolar aeration and responds quickly to changes in pulmonary ventilation and in the presence of a normal buffer base an abnormal bicarbonate content may result. Alterations in the acid-base balance are common in chronic pulmonary disease and such disturbances may involve shifts in the blood buffer base and pCO_2 in opposite directions with variable pH values so that in a given case the only way to be certain of the pH is the direct measurements on arterial blood using a glass electrode. A poor correlation of the arterial CO_2 content and the pCO_2 with the pH has been observed by direct measurements of these values in

TABLE II

MEASUREMENTS* ON ARTERIAL BLOOD AT REST AND THE VENTILATION FACTOR IN THIRTY CASES OF SEVERE PULMONARY INSUFFICIENCY

Case No.	pH	CO_2 Content (vol %)	pCO_2 (mm Hg)	O_2 Saturation (%)	Ventilation Factor (%)
1	7 48	50 3	45 6	89 [illegible]	38 6
2	7 49	45 4	32 4	91 9	38 7
3	7 41	55 7	56 7	74 6	30 7
4	7 43	45 5	33 6	92 2	38 8
5	7 48	44 9	39 4	89 5	34 9
6	7 49	61 3	40 7	91 8	32 8
7	7 47	54 9	44 0	90 2	45 9
8	7 43	63 2	55 [illegible]	82 0	29 7
9	7 51	49 4	34 7	93 7	35 0
10	7 47	58 7	36 5	94 6	32 3
11	7 49	54 0	45 5	90 4	39 8
12	7 46	46 [illegible]	42 8	84 9	42 8
13	7 45	53 7	47 0	87 5	33 8
14	7 47	54 1	42 1	89 1	34 2
15	7 42	51 8	49 4	90 9	24 0
16	7 47	52 8	40 6	93 0	36 0
17	7 44	42 3	27 4	91 9	37 0
18	7 55	49 7	46 5	91 6	37 8
19	7 41	60 2	55 0	86 7	27 5
20	7 45	45 5	47 4	86 [illegible]	41 8
21	7 46	45 6	46 0	93 0	21 6
22	7 44	56 1	53 8	82 1	32 8
23	7 45	48 4	46 2	92 0	40 7
24	7 38	52 0	53 5	85 4	39 4
25	7 33	68 5	72 0	66 2	23 0
26	7 41	49 1	40 7	87 8	31 5
27	7 58	41 8	47 1	85 0	39 6
28	7 43	44 6	44 1	91 6	41 4
29	7 46	49 2	61 1	83 8	28 9
30	7 37	63 7	64 [illegible]	62 3	26 8

* pH Glass electrode direct, CO_2 Cont, Van Slyke manometric, pCO_2 direct tension measurement (Riley bubble method), O_2 saturation from Van Slyke content and capacity Ventilation factor (V F) approximates on a percentage basis the efficiency of the lungs as a bellows, and the value is determined from the average of three measurements, all expressed as per cent of the normal predicted, namely, the three second vital capacity, the maximal breathing capacity and the residual air capacity as per cent of total lung capacity

cases of severe pulmonary insufficiency, in which with an arterial blood pH range of 7.40 to 7 46 the CO_2 content varied from 42 to 62 volumes per cent and the pCO_2 from 27

to 61 mm Hg (Table II) These data demonstrate that in chronic pulmonary disease the direct determination of arterial blood pH is the only accurate measurement of the exact status of acidosis or alkalosis in an individual case The Cambridge glass electrode pH meter is about the size of a portable electrocardiograph machine and permits quick measurements of pH Arterial puncture of the brachial or femoral artery is usually an easy procedure with a B & D Cournand type needle A small amount of heparin is used in the luer lok syringe to keep the blood from coagulating before the transfer of the blood to the Cambridge glass electrode without contact with air using the 1 cc Van Slyke blood pipette

Although the arterial pCO_2 may be elevated in emphysema, the arterial pH is usually in the normal range in the absence of cardiac failure or respiratory depression of drugs, anesthetics infections or other acute changes The arterial pCO_2 is a function of alveolar aeration and by direct measurement arterial pCO_2 correlates well with the ventilation factor [2]

VENTILATION MEASUREMENTS

The expired air from the patient is studied with respect to the minute ventilation (total volume of air breathing during a test period of three to five minutes) the total oxygen uptake and the percent of oxygen extracted from the inspired air breathed The minute ventilation is measured with respect to the number of L per minute per square meter of body surface area If the minute ventilation as L. per minute per square meter body surface area is below the normal range (2 6 to 3 8 at rest and 8 to 10 5 with step-up exercise for

gives the average tidal volume, and the effective tidal volume that actually reaches the alveoli may be calculated from the expired pCO_2 and the arterial pCO_2 The data from two sets of resting measurements obtained at the same study period about two hours apart are given from a patient in Table III showing the effect of the minute ventilation and tidal volume on the blood gas exchange one a rapid shallow type (Rest I) and the other more nearly normal (Rest II) Note that the dead space ventilation is about the same in both but that the effective tidal ventilation is almost doubled in Rest II with marked differences noted in the

tion evaluation The one-minute step-up exer-

TABLE III
EFFECT OF VENTILATION VOLUMES ON BLOOD GAS EXCHANGE

Measurements	Rest I	Rest II
1 Respiratory rate per min	23 3	17 3
2 Minute ventilation L./min	5 26	8 34
3 Tidal volume ml	226	482
4 Effective tidal volume * %	55 0	65 0
5 Effective tidal volume, ml	124	315
6 Effective tidal ventilation L./min	2 89	5 45
7 Dead space ventilation L./min	2 37	2 89
8 Oxygen content vol %	16 88	19 40
9 Arterial blood oxygen saturation %	83 4	92 5
10 CO_2 content vol %	45 33	41 02
11 pH	7 46	7 54
12 pCO mm Hg	40 8	30 7
13 pO_2 mm Hg	63 1	106 6

* Calculated from the expired pCO_2 and arterial pCO_2

cise test (thirty steps on an 8-inch stool in one minute) has been standardized with respect to the normal range [1] In some cases of marked pulmonary insufficiency the exercise minute ventilation may be inadequate in proportion to the step up test requirement In general, the minute ventilation as a single measurement is often indeterminate as revealed from extensive statistical studies on a large series of cases The minute ventilation along with the data provided from the expired air gas analysis pro-

uptake tends to be in the normal range regardless of the degree of pulmonary insufficiency,[1] hence, is of little value in pulmonary disability evaluation On the other hand, the measurement of step-up exercise oxygen uptake is a very significant value A marked reduction in the exercise oxygen uptake (normal range 500 to 600 ml per min per square meter body surface area) in the presence of an adequate minute ventilation reflects the inability of the individual to expand the pulmonary bed and

increase the pulmonary blood flow or to increase the cardiac output from the right heart to the elevated level representing a normal response proportionate to the degree of exercise given If the normal amount of oxygen is removed from the expired air during the one minute step up exercise an increased blood flow is necessary If the oxygen uptake is normal during exercise this indicates that the pulmonary blood flow is increased in proportion to the degree of exercise and that the pulmonary vascular resistance is not significantly altered A decreased oxygen uptake during step up exercise in the presence of an adequate minute ventilation indirectly indicates increased pulmonary vascular resistance without the necessity of catheterizing the right heart to measure mean pulmonary arterial pressure and the cardiac output

The per cent of oxygen extracted from the inspired air breathed is a measure of the lung ventilation efficiency and this figure is used to determine the oxygen uptake along with the pulmonary ventilation volume measurement Normally 4 to 5 per cent of the oxygen is extracted from the inspired air at rest and 5 to 6 per cent during the step up exercise Thus if a patient is removing only 2 5 per cent of the oxygen from the inspired air during exercise twice the normal volume of air would be required for breathing disease the per cent of chronic pulmonary oxygen extracted from the inspired air is usually decreased somewhat but this measurement is usually indeterminate as to the degree of pulmonary function impairment present unless the decrease is of a very marked extent Exercise ment with hyperventilation may result in a very low abnormal value which might be normal if the individual were breathing at a lower volume rate A patient with a severe degree of pulmonary insufficiency may have hypoventilation present during the step-up exercise and show a normal per cent of oxygen extracted but the total oxygen uptake would be decreased markedly

After the valve cycles expiration occurs as a passive deflation produced primarily by the elasticity of the lungs and the chest wall structures The cycling of the respirator valve follows the patient s pattern of breathing Factors to be considered in using IPPB are related to the shape and duration of mask pressure applied at the mouth namely the time relationship of inspiration and expiration the cycling rate and the magnitude of pressure applied (maximal minimal and mean) [1 4] The most desirable type of mask pressure curve to apply to the mask or intratracheal tube is a gradually increasing pressure during inspiration and rapidly dropping to atmospheric early in expiration expiratory time equal to inspiratory time and most of the mean mask pressure is exerted during the inspiratory period This type of intermittent positive pressure breathing provides a high peak mask pressure effective in overcoming breathing resistance yet the mean mask pressure for the entire respiratory cycle is low so that normally no deleterious effects are produced on the pulmonary circulation The use of intermittent positive pressure breathing for prolonged periods does not produce distention of the lungs or increase the amount of residual air even in patients with far advanced degree of pulmonary emphysema [7] The instantaneous flow rate of respiratory appliances should be high above 100 L per minute so as to meet the flow needs of the acute asthmatic or cardiac patients otherwise increased negative intrathoracic pressure may develop during inspiration with subjective dyspnea

In the postoperative phase the arterial blood oxygen saturation may be quite satisfactory from oxygen given by a catheter mask or tent but the accompanying decreased ventilation results in an inadequate elimination of CO_2 and respiratory acidosis develops unless mechanical respiratory assistance is provided by intermittent positive pressure breathing (IPPB) The IPPB increases pulmonary ventilation and may be safely given using the Halliburton Bennett or the Emerson breathing units* with maximal peak pressure settings of 10 to 20 cm of water IPPB five to ten minutes out of every hour or half hour may be adequate during the critical period or as otherwise indi

PRESSURE BREATHING

Intermittent positive pressure breathing (IPPB) consists of an active inflation of the lungs during inspiration with a regulated positive pressure from the cycling valve providing a maximal peak pressure at the mouth adjustable usually from 10 to 20 cm of water

* Hallibarton IPPB unit made by Duncan Oxygen Therapy Co Duncan Okla Bennett IPPB unit made by V Ray Bennett Los Angeles Calif Emerson IPPB unit made by J H Emerson Co Cambridge Mass

cated to keep respiratory acidosis from developing. The effectiveness of IPPB has been demonstrated for increasing alveolar aeration in cases with severe degree of pulmonary insufficiency with obstructive elements. The use of 60 per cent helium and 40 per cent oxygen with IPPB and bronchodilators is helpful in some cases to facilitate aeration around and beyond secretions and to carry bronchodilators to the area of spasm in the bronchioles and to provide a high inspiratory pO_2. In order for the patient effectively to cough up secretions, gas must be delivered beyond the location of the secretion. The great diffusibility of helium facilitates the carrying of the gas and bronchodilator substance to the site of the spasm and plugging in the bronchioles so as to treat the bronchospasm effectively and to move the air beyond the secretion in the bronchioles thus enabling the patient to expectorate more effectively. The use of helium with oxygen (not less than 30 per cent oxygen) has been found most helpful in cases of severe emphysema during acute episodes of pulmonary infection with marked plugging of the bronchioles aggravated by bronchospasm (status asthmaticus may be markedly benefited by the IPPB treatments).

PULMONARY VASCULAR RESISTANCE

In normal individuals during exercise the cardiac output from the right heart may increase three times or more above the resting level without an increase in the pulmonary artery pressure because the pulmonary vascular resistance is decreased. A gas breathing mixture containing low concentrations of oxygen (such as 10 per cent oxygen in nitrogen) produces a rapid lowering of the partial pressure of oxygen and per cent saturation in the arterial blood in man (acute hypoxia) elevates the pulmonary artery pressure (constricts pulmonary arterioles) and increases pulmonary vascular resistance. In patients with chronic pulmonary disease the pulmonary artery pressure is usually elevated during mild exercise, although the cardiac output may be increased only 2 or 3 L. per minute, which in some cases represents the maximal response above the resting level of which the individual is capable. The inability to increase the pulmonary blood flow during exercise in a normal manner constitutes one of the major factors producing disability in chronic pulmonary disease. When the pulmonary blood flow is inadequate during exercise, the oxygen uptake from the lung is reduced, less oxygen is available for the body tissues and an oxygen debt develops. An adequate pulmonary blood flow is necessary to maintain normal gas exchange in the lungs both during rest and exercise. The blood must also contain sufficient hemoglobin to carry an adequate quantity of oxygen to the tissues.

SUMMARY

The physiology of respiration with reference to pulmonary disease has been discussed as related to the maintenance of a normal oxygen tension in the blood supplying the tissues and the adequate removal of carbon dioxide both during rest and exercise. Frequently patients with chronic pulmonary disease receiving oxygen therapy have normal saturations in the arterial blood, but this does not insure that carbon dioxide is blown off properly unless the alveolar aeration is maintained at an adequate level.

The important clinical aspects of respiration discussed are concerned with the maintenance of a normal respiratory state and include lung volume measurements, oxygen transport across the lung, carbon dioxide regulation, acid base balance, ventilation measurements, intermittent positive pressure breathing and pulmonary vascular resistance.

REFERENCES

1. Motley H. L. The use of pulmonary function tests for disability appraisal including evaluation standards in chronic pulmonary disease. *Dis. of Chest* 24: 378, 1953.
2. Motley H. L. Clinical pulmonary physiology in Detection of early lung function changes in industrial exposure. *Indust. Med.* 22: 262-267, 1953.
3. Motley H. L., Gordon B., Lang, L. P. and Theodos P. A. Impairment of pulmonary function in anthracosilicosis. *Arch. Indust. Hyg. & Occupational Med.* 1: 133, 1950.
4. Motley H. L. Data to be published.
5. Darling, R. C., Cournand A. and Richards D. W. Jr. Studies on intrapulmonary mixture of gases an open circuit method for measuring residual air. *J. Clin. Investigation* 19: 609, 1940.
6. Motley H. L. and Smart R. H. Pulmonary emphysema physiological factors in diagnosis and new advances in therapy. *J. Am. Geriatrics Soc.* in press.
7. Mead J., Frank R. V., Lindgren, I., Gaensler, E. A. and Whittenberger, J. L. A technic for the measurement of pulmonary compliance and resistance, its application to normal patients and patients with mitral stenosis. *Clin. Research Proc.* 1: 116, 1953.

increase the pulmonary blood flow or to increase the cardiac output from the right heart to the elevated level representing a normal response proportionate to the degree of exercise given If the normal amount of oxygen is removed from the expired air during the one-minute step-up exercise an increased blood flow is necessary If the oxygen uptake is normal during exercise, this indicates that the pulmonary blood flow is increased in proportion to the degree of exercise and that the pulmonary vascular resistance is not significantly altered A decreased oxygen uptake during step up exercise in the presence of an adequate minute ventilation indirectly indicates increased pulmonary vascular resistance, without the necessity of catheterizing the right heart to measure mean pulmonary arterial pressure and the cardiac output

The per cent of oxygen extracted from the inspired air breathed is a measure of the lung ventilation efficiency and this figure is used to determine the oxygen uptake along with the pulmonary ventilation volume measurement Normally 4 to 5 per cent of the oxygen is extracted from the inspired air at rest and 5 to 6 per cent during the step up exercise Thus if a patient is removing only 2 5 per cent of the oxygen from the inspired air during exercise, twice the normal volume of air would be required for breathing to furnish the oxygen In chronic pulmonary disease the per cent of oxygen extracted from the inspired air is usually decreased somewhat, but this measurement is usually indeterminate as to the degree of pulmonary function impairment present unless the decrease is of a very marked extent Excitement with hyperventilation may result in a very low abnormal value, which might be normal if the individual were breathing at a lower volume rate A patient with a severe degree of pulmonary insufficiency may have hypoventilation present during the step up exercise and show a normal per cent of oxygen extracted, but the total oxygen uptake would be decreased markedly

PRESSURE BREATHING

Intermittent positive pressure breathing (IPPB) consists of an active inflation of the lungs during inspiration with a regulated positive pressure from the cycling valve providing a maximal peak pressure at the mouth adjustable usually from 10 to 20 cm of water After the valve cycles expiration occurs as a passive deflation produced primarily by the elasticity of the lungs and the chest wall structures The cycling of the respirator valve follows the patient's pattern of breathing Factors to be considered in using IPPB are related to the shape and duration of mask pressure applied at the mouth, namely, the time relation of inspiration and expiration, the cycling rate and the magnitude of pressure applied (maximal, minimal and mean) [15 16] The most desirable type of mask pressure curve to apply to the mask or intratracheal tube is a gradually increasing pressure during inspiration and rapidly dropping to atmospheric early in expiration expiratory time equal to inspiratory time, and most of the mean mask pressure is exerted during the inspiratory period This type of intermittent positive pressure breathing provides a high peak mask pressure effective in overcoming breathing resistance, yet the mean mask pressure for the entire respiratory cycle is low, so that normally no deleterious effects [illegible] The [illegible] tention of the lungs or increase the amount of residual air even in patients with far advanced degree of pulmonary emphysema [17] The instantaneous flow rate of respiratory appliances should be high, above 100 L per minute, so as to meet the flow needs of the acute asthmatic or cardiac patients, otherwise increased negative intrathoracic pressure may develop during inspiration with subjective dyspnea

In the postoperative phase the arterial blood oxygen saturation may be quite satisfactory from oxygen given by a catheter, mask or tent, but the accompanying decreased ventilation results in an inadequate elimination of CO_2 and respiratory acidosis develops unless mechanical respiratory assistance is provided by intermittent positive pressure breathing (IPPB) The IPPB increases pulmonary ventilation and may be safely given using the Halliburton, Bennett or the Emerson breathing units* with maximal peak pressure settings of 10 to 20 cm of water IPPB five to ten minutes out of every hour or half hour may be adequate during the critical period or as otherwise indi [illegible]

cated to keep respiratory acidosis from developing. The effectiveness of IPPB has been demonstrated for increasing alveolar aeration in cases with severe degree of pulmonary insufficiency with obstructive elements. The use of 60 per cent helium and 40 per cent oxygen with IPPB and bronchodilators is helpful in some cases to facilitate aeration around and beyond secretions and to carry bronchodilators to the area of spasm in the bronchioles and to provide a high inspiratory pO_2. In order for the patient effectively to cough up secretions gas must be delivered beyond the location of the secretion. The great diffusibility of helium facilitates the carrying of the gas and bronchodilator substance to the site of the spasm and plugging in the bronchioles so as to treat the bronchospasm effectively and to move the air beyond the secretion in the bronchioles thus enabling the patient to expectorate more effectively. The use of helium with oxygen (not less than 30 per cent oxygen) has been found most helpful in cases of severe emphysema during acute episodes of pulmonary infection with marked plugging of the bronchioles aggravated by bronchospasm (status asthmaticus may be markedly benefited by the IPPB treatments).[9]

PULMONARY VASCULAR RESISTANCE

In normal individuals during exercise the cardiac output from the right heart may increase three times or more above the resting level without an increase in the pulmonary artery pressure because the pulmonary vascular resistance is decreased.[18] A gas breathing mixture containing low concentrations of oxygen (such as 10 per cent oxygen in nitrogen) produces a rapid lowering of the partial pressure of oxygen and per cent saturation in the arterial blood in man (acute hypoxia), elevates the pulmonary artery pressure (constricts pulmonary arterioles) and increases pulmonary vascular resistance.[19] In patients with chronic pulmonary disease the pulmonary artery pressure is usually elevated during mild exercise, although the cardiac output may be increased only 2 or 3 L. per minute which in some cases represents the maximal response above the resting level of which the individual is capable. The inability to increase the pulmonary blood flow during exercise in a normal manner constitutes one of the major factors producing disability in chronic pulmonary disease. When the pulmonary blood flow is inadequate during exercise the oxygen uptake from the lung is reduced, less oxygen is available for the body tissues and an oxygen debt develops. An adequate pulmonary blood flow is necessary to maintain normal gas exchange in the lungs both during rest and exercise. The blood must also contain sufficient hemoglobin to carry an adequate quantity of oxygen to the tissues.

SUMMARY

The physiology of respiration with reference to pulmonary disease has been discussed as related to the maintenance of a normal oxygen tension in the blood supplying the tissues and the adequate removal of carbon dioxide both during rest and exercise. Frequently patients with chronic pulmonary disease receiving oxygen therapy have normal saturations in the arterial blood, but this does not insure that carbon dioxide is blown off properly unless the alveolar aeration is maintained at an adequate level.

The important clinical aspects of respiration discussed are concerned with the maintenance of a normal respiratory state and include lung tent positive pressure breathing and pulmonary vascular resistance.

REFERENCES

1. MOTLEY, H. L. The use of pulmonary function tests for disability appraisal including evaluation standards in chronic pulmonary disease. *Dis. of Chest* 24: 378, 1953.
2. MOTLEY, H. L. Clinical pulmonary physiology II. Detection of early lung function changes in industrial exposure. *Indust. Med.* 22: 262-267, 1953.
3. MOTLEY, H. L., GORDON, B., LANG, L. P. and [illegible]
4. [illegible]
5. DARLING, R. C., COURNAND, A. and RICHARDS, D. W., JR. Studies on intrapulmonary mixture of gases: an open circuit method for measuring residual air. *J. Clin. Investigation* 19: 609, 1940.
6. MOTLEY, H. L. and SWART, H. H. Pulmonary emphysema: physiological factors in diagnosis and new advances in therapy. *J. Am. Geriatrics Soc.* in press.
7. MEAD, J., FRANK, R. N., LINDGREN, I., GAENSLER, E. A. and WHITTENBERGER, J. L. A technic for the measurement of pulmonary compliance and resistance: its application to normal patients and patients with mitral stenosis. *Clin. Research Proc.*, 1: 116, 1953.

8 FOWLER, W S Lung function studies III Uneven pulmonary ventilation in normal subjects and in patients with pulmonary disease *J Applied Physiol*, 2 283, 1949

9 RILEY, R L, PROEMMEL, D D and FRANKE, R E A direct method for determination of oxygen and carbon dioxide tensions in blood *J Biol Chem*, 161 121, 1945

10 MOTLEY, H L and TOMASHEFSKI, J F Effect of high and low oxygen levels and intermittent positive pressure breathing on oxygen transport in the lungs in pulmonary fibrosis and emphysema *J Applied Physiol*, 3 189, 1950

11 MOTLEY, H L Pulmonary function measurements *Am J Surg*, 88 103, 1954.

12 MOTLEY, H L The use of oxygen in comatose states *Bull New York Acad Med*, 26 479, 1950

13 IVY, J H, GRODINS, F S, ADLER, H F and SNAPP, F E Studies on asphyxia, effect of carbon dioxide inhalation on an anoxic animal *J Aviation Med*, 18 577, 1947

14 PACE, N STRAJMAN, E and WALKER, E L Acceleration of carbon monoxide elimination in man by high oxygen pressure *Science*, 111 652, 1950

15 MOTLEY, H L, COURNAND, A, WERKO, L, DRESDALE, D, HIMMELSTEIN, A and RICHARDS, D W, JR. Studies of intermittent positive pressure breathing as a means of administering artificial respiration in man *J A. M A*, 137 370, 1948

16 COURNAND, A, MOTLEY, H L, WERKO, L and RICHARDS, D W, JR Physiological studies of the effects of intermittent positive pressure breathing on cardiac output in man *Am J Physiol*, 152 162, 1948

17 MOTLEY, H L, LANG, L P and GORDON, B Use of intermittent positive pressure breathing combined with nebulization in pulmonary disease *Am J Med*, 5 853, 1948

18 RILEY, R L, HIMMELSTEIN, A, MOTLEY, H L, WEINER, H M and COURNAND A Studies of the pulmonary circulation at rest and during exercise in normal individuals and in patients with chronic pulmonary disease *Am J Physiol*, 152 372, 1948

19. MOTLEY, H L, COURNAND, A, WERKO, L, HIMMELSTEIN, A and DRESDALE, D The influence of short periods of induced anoxia upon pulmonary artery pressures in man *Am J Physiol*, 150 315, 1947

6

Hematologic Role of the Lung

HOWARD R BIERMAN M D *Duarte, California*

From the C ty of Hope Med cal Center Duarte Cal f

THE primary function of the lungs in man is the transfer of oxygen from the inspired air to the arterial blood together with the excretion of carbon dioxide from the venous blood in the expired air Among the many other physiologic functions of great importance is the hemopoietic role of the lung which has recently received renewed attention This chapter is primarily concerned with the participation of the lungs in the maintenance of a normal number of circulating formed blood elements including erythrocytes leukocytes and platelets

The crucial location of the pulmonary circulation literally at the crossroads of the vascular system appears to provide the lungs with the capacity of producing important changes in the volume of blood and its constituents by means of relatively small changes in pulmonary function This appears to hold true for the gaseous content of plasma and hemoglobin and for electrolyte equilibrium of the blood The role of the lung in regulating the number of cellular constituents in blood appears to have received little attention until recently Large rapid fluctuations in the number of circulating formed elements which have been reported to occur indicate a prodigious yet facile reservoir which under some circumstances may cause an increase or decrease of 100 per cent within a few seconds A review of both the old as well as the more recent findings is both feasible and meaningful in the light of newer techniques of vascular catheterization with central and rapid sampling of blood together with improved accuracy in the determination of the number of formed elements

PHYSIOLOGY OF PULMONARY CIRCULATION

Erythrocytes The erythrocyte serves primarily as a hemoglobin container whose integrity is essential for effective oxygen and carbon dioxide transport and for ion exchange An intact cell membrane is necessary to retain the hemoglobin with in the erythrocyte stroma so as to provide an oxygen hemoglobin dissociation curve in a state favorable for the exchange of both oxygen and carbon dioxide [1]

The lungs contribute in an important way under other circumstances to a more sustained stimulus for erythrocyte production Prolonged states of hypoxia are followed by an increased regenerative activity of the bond marrow and subsequent compensatory increase in the number of circulating erythrocytes This occurs with chronic states of arterial oxygen desaturation The consequence of this state of affairs is an increase in the total blood volume attributable largely to an increase in red cell volume [2] In this fashion the lungs may contribute to a sustained increased product on of erythrocytes in the bone marrow There is no [illegible] is followed by compensatory polycythemia remains to be elucidated

A reduction in the concentration of effective hemoglobin and in the number of erythrocytes may occur through the intervention of the lungs This may occur as a consequence of the influences of noxious fumes (lead nitrite) or by the operation of a removal mechanism [illegible] attributed to possible counting errors the magnitude of the changes are often far in excess of such errors In some instances both in the normal and the leukemic individual the white cell count may vary 400 or 500 per cent from the or gnal level within a few hours

Leukocytes may accumulate in the capillaries of many organs under specific circumstances and, similarly, leukocytes may be released from these storage sites by the proper stimuli Clark,[5] Sandison[6] and Lowit[7] believed that the leukopenias were due to disintegration of leukocytes in the circulation Arneth[8] concluded that the profound leukopenia observed following the injection of foreign proteins, bacteria and certain drugs were due to widespread destruction of cells which were replaced by young cells from the hematopoietic centers Similar findings were reported by Aschenheim [9]

The concept of leukopenia being caused by sequestration into various organs is well established [10] The organs and mechanisms involved, however, have not yet been defined Momouye[11] found the capillaries of the bone marrow, lungs and intestines to be those chiefly involved Nye and Barrs[12] found the lungs, liver and, to a lesser extent, the spleen to be concerned in this process Ewing,[13] similarly to Andrewes,[14] reported the trapping of leukocytes in the liver and lung following the intravenous administration of bacteria Wells[15] believed the liver and spleen to be predominantly involved, while Doan[16] emphasized the role of the spleen in the leukopenic states Silverman[17] believed that leukopenia was attributable to mechanical filtration of leukocytes induced by endothelial swelling of the capillary wall Seyderhelm and Oestrich[18] injected leukocytes tagged with Congo red into rabbits These cells were taken up by the liver when injected into the splenic artery or portal vein If injected into an ear vein, they accumulated in the lungs Garrey and Bryan[3] believed that the liver and lungs were the main sites of sequestration of leukocytes and that the role of the spleen was less significant

It is apparent that any mechanism which functions to control the level of the circulating leukocytes must have the ability to act either rapidly or slowly, to perform continuously or intermittently and to remove or contribute formed elements directly into the circulation as the situation dictates These criteria of sequestration sites can best be met by those organs which are exposed to large volumes of actively circulating blood The heart, lungs and great vessels receive more of the circulating blood per unit time than other organs The lungs, which had received relatively little attention from this viewpoint, appeared to be the most promising site to examine

EVIDENCE FOR REMOVAL AND RELEASE OF LEUKOCYTES BY THE LUNG

Removal of Leukocytes after Blood Transfusion It has been commonly observed that although whole blood transfusions from normal donors will raise the erythrocyte count, there is no coincident rise in leukocyte number [19] Minot and Isaacs[20] transfused 450 cc of whole blood from a patient with chronic lymphatic leukemia (95 6 per cent lymphocytes, 89 000 per cu mm) into a patient in an advanced stage of lymphosarcoma who had 992 lymphocytes/cu mm At the conclusion of the transfusion the lymphocyte blood count in the recipient was increased to 3 600 Thirty minutes later the lymphocyte number had returned to 1,759/cu mm , by calculation the lymphocyte count should have risen to 12,000/cu mm No satisfactory clue to account for the missing lymphocytes was offered

The pulmonary circulation of non leukemic man has been shown to be capable of removing billions of leukocytes infused from leukemic donors [21] (Fig 1) Whole blood transfusions containing up to 140 billion leukocytes were given intravenously within two to ten minutes When large numbers of leukemic leukocytes were injected into the femoral artery, they successfully traversed the capillary bed of the lower extremity without alteration, as shown by frequent samples of femoral vein blood during the transfusion, yet they were selectively removed by the pulmonary capillary bed as they reached the lung and failed to appear in the arterial blood in significant numbers Weisberger and Heinle [22] and Ambrus et al [23] showed that the lungs of rabbits and rats also function similarly in withdrawing intravenously infused leukocytes During the first hour after infusion of leukocytes tagged with P 32 the activity was found primarily in the lungs Within three hours most of the radioactivity was found in the liver and spleen It is difficult, however, to ascertain whether this radioactivity represented radiophosphorus in the intact leukocyte or P 32 which had been released from the white cell by diffusion or cell destruction

Removal of Leukocytes in Cross Transfusion Studies The pulmonary circulation is also capable of removing leukocytes from the

peripheral circulation in man for as long as twenty five to thirty five hours during interarterial cross transfusion [21] (Fig 2) The continuous removal of leukocytes without change in blood flow suggests that intravascular margination of leukocytes or mechanical filtration are not solely responsible Calculations showed the number of leukocytes removed during these periods was far in excess of the amount of cell mass the pulmonary circulation could accommodate over this period of time, there must be a mechanism and route whereby the cells could be withdrawn from the circulation and a pathway for the draining of these cells or debris from the lungs [24] Some of these cells may be destroyed, others stored or excreted in the sputum and still others may make their way back into the circulation by way of the intrapulmonary lymphatics or blood vessels It is not known which of these three

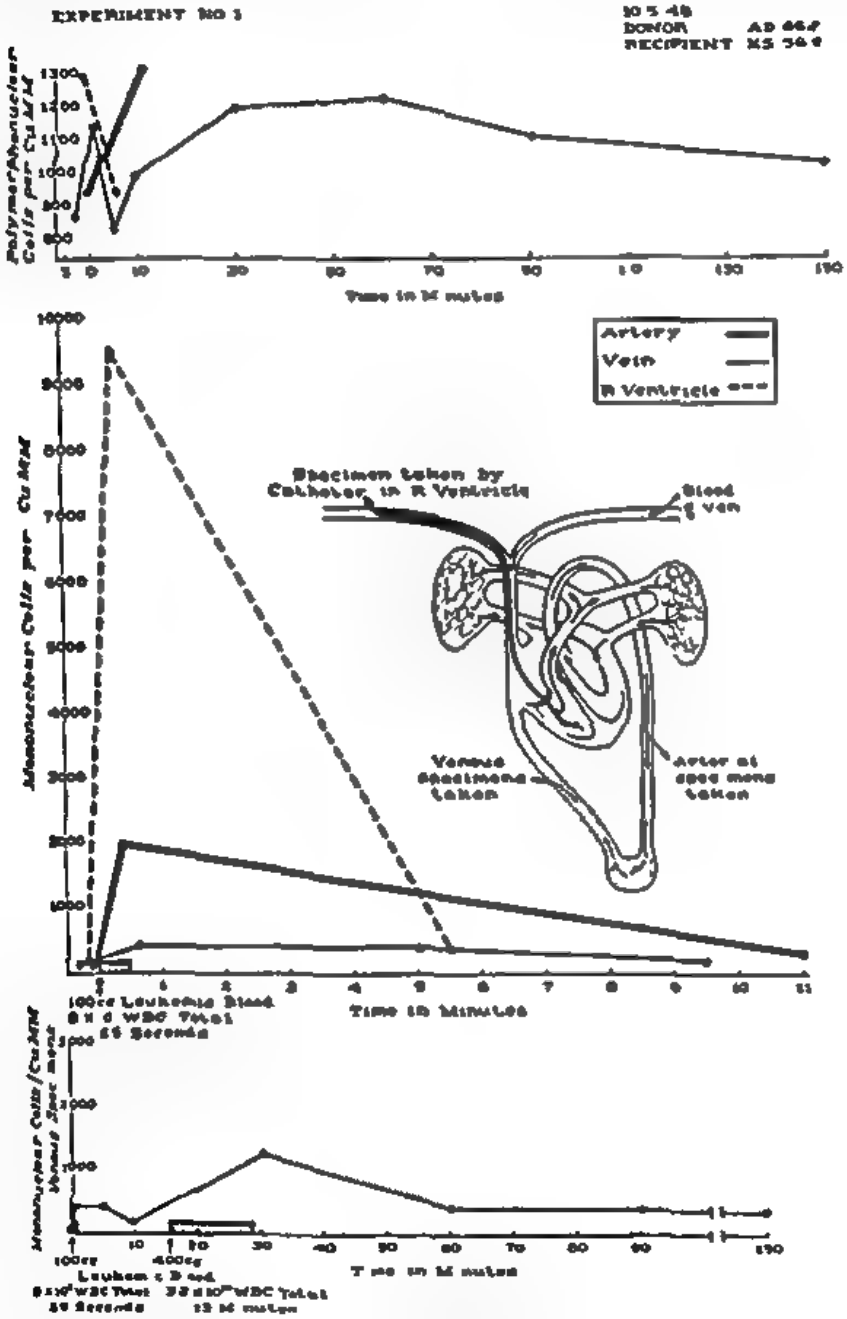

FIG 1 Infusion of leukocytes from leukemic donor Note marked discrepancy between samples taken from the venous and arterial sides of the lung (From Lanman et al *Blood* 5 1099 1950 [21])

methods are primarily involved or their relative importance in the total picture of leukocyte removal in the lungs "

Changes in Leukocyte Levels during Respiratory Movements Repeated observations of the leukocyte levels of blood sampled simul

arterial blood during normal inspiration and an increase with expiration The granulocyte is involved almost exclusively The magnitude of the fluctuations was greater and more consistent in the arterial than in the venous samples These findings suggest that there is an

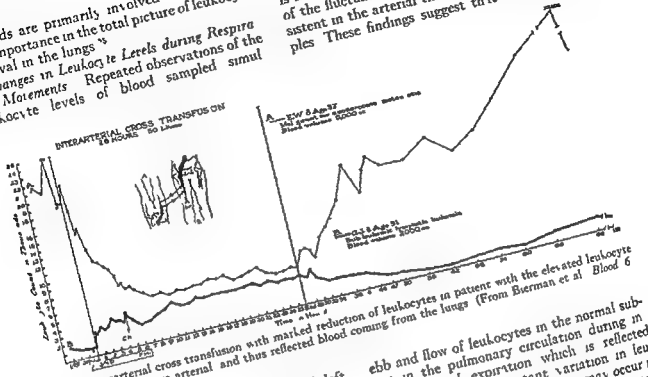

FIG 2 Interarterial cross transfusion with marked reduction of leukocytes in patient with the elevated leukocyte level All samples were arterial and thus reflected blood coming from the lungs (From Bierman et al *Blood* 6 487 1951 *a*)

taneously from the right ventricle and left ventricle or aorta frequently revealed significant differences " At times the leukocyte counts in the venous blood exceeded that in the arterial blood and a few moments later the arterial content of white cells was greater than that from the right ventricle This frequent change in cell count on either side of the pulmonary circulation suggested some alteration of the number of leukocytes of blood passing through the lungs

It was subsequently found that the arterial leukocyte count decreased significantly with a slight rise in the venous blood samples obtained from the right ventricle or pulmonary artery immediately after the initiation of the Valsalva maneuver (Fig 3) This discrepancy persisted until toward the end of the forced expiration when the venous leukocyte level also fell The leukocyte counts returned to their control levels after the Valsalva was released During the Mueller maneuver which is the physiologic counterpart of inspiration both the venous and arterial leukocyte level exhibited an increase Simultaneous leukocyte counts of both venous and arterial blood during prolonged inspiration and expiration similarly revealed a fall in leukocyte number in the

ebb and flow of leukocytes in the normal subject in the pulmonary circulation during inspiration and expiration which is reflected peripherally by a constant variation in leukocyte level The alterations that may occur in this mechanism under other physiologic and pathologic conditions remain to be elucidated

The Influence of Pharmacologically Active Substances Histamine The rapid intravenous administration of histamine phosphate in doses of 0 1 to 0 3 mg (as base) over a thirty to sixty second period causes a prompt decrease initially in the peripheral arterial blood leukocyte number in the non leukemic subject which is reflected twenty to ninety seconds later in blood from the right ventricle or peripheral vein although not as profound as in the arterial blood " This leukopenia persists for forty to 120 seconds where upon the number of leukocytes in the arterial and venous blood increases simultaneously until the original level is regained The leukopenia precedes the symptoms of dyspnea flushing and headache so commonly associated with the intravenous administration of histamine These findings demonstrate that the intravenous administration of histamine results in the transient sequestration of leukocytes within the pul

monary circulation until the peripheral arterial level of leukocytes falls Subsequently the circulating level of leukocytes returns toward normal

The administration of histamine under identical conditions to most patients with lymphocytic leukemia fails to produce any significant change in leukocyte number in either the arterial or venous blood * Occasionally however transient leukopenia in the lymphocytic leukemic patient has been observed Patients with monocytic leukemia respond in the same manner as non leukemics and patients with granulocytic leukemia respond with a rise in leukocyte number The data suggest that the pulmonary leukocyte removal mechanism in patients with lymphocytic leukemia and granulocytic leukemia does not respond to histamine in the normal manner

In the past the fall in white cell count associated with intravenous histamine has been attributed to the pooling of the leukocytes in the capillaries of the spleen liver and other splanchnic areas as a result of a fall in blood pressure It is evident from these studies that the majority of cells do not pass the pulmonary circulation during the initial phase of intravenous histamine administration and that the lungs are mainly responsible for the prompt leukopenia albeit temporary

Epinephrine The leukocytosis following epinephrine will be discussed in detail in the section on platelets

Saccharated iron oxide The intravenous administration of saccharated iron oxide occasionally was found to be accompanied by granulocytopenia * An investigation of the influence of this material upon the circulating leukocytes was undertaken * The intravenous infusion of saccharated iron oxide in doses of 400 mg or over and administered at a rate in excess of 100 mg per minute resulted in arterial leukopenia which generally preceded that noted in the venous blood by at least one to two full circulation times The leukopenia at 1 minute became progressively more profound and prolonged the larger the doses employed and the longer the duration of infusion When the venous blood was sampled proximal to where the iron was injected all specimens collected during the period of administration and which consequently contained the largest amounts of iron promptly clotted within the collecting tubes despite an excess of heparin All other specimens showed no such tendency There was no significant alteration in the platelet counts

In two patients with lymphocytic leukemia leukopenia was not obtained until repeated in



FIG 3 Profound reduction in leukocyte number in the arterial blood a substanous with a forced exp ra t on (From B erwin et al Blood 7 538 1952))

sections of iron had been administered for a total of 300 and 1 000 mg It appears that saccharated iron oxide administered intravenously is capable of stimulating the withdrawal of leukocytes within the pulmonary circulation in non leukemic individuals Two patients with monocytic leukemia responded in the same manner as did non leukemics showing prompt leukopenia following the intravenous administration of colloidal iron

The Influence of Foreign Materials Olitzki Leibowitz and Berman[11] observed profound leukopenia following the injection of dysentery bacilli in two splenectomized animals Olitzki also found the polymorphonuclear leukocytes

sequestered in the rabbit lungs during leukopenia resulting from typhoid vaccine Some tolerance to the effect of pyrogens upon the leukocytes was suggested However, this tolerance is apparently not related to the presence of circulating antibodies, behaved spasmodically and was reminiscent of the development of tolerance for fever

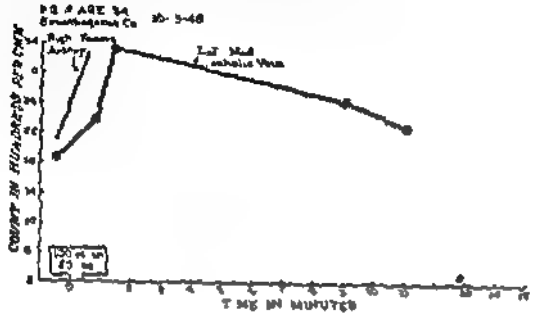

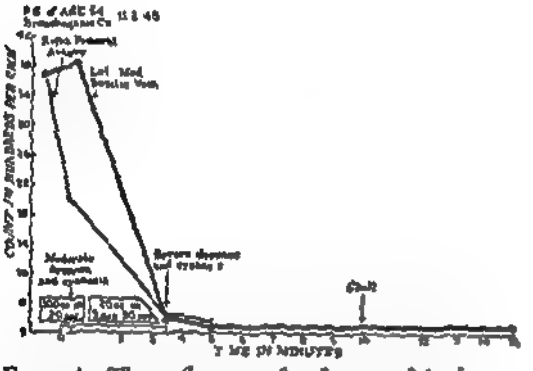

FIG 4A The influence of infusion of leukemic leukocytes upon the eosinophil level in patient P G The other granulocytes acted in a similar fashion The lymphocytes were too few in number to produce significant changes

FIG 4B A repeat of study illustrated in Fig 4A eighteen days later Note marked eosinopenia occurring promptly after start of infusion associated with pulmonary edema

Dudgeon and Goadby[33] studied the tissue reactions in rabbits following intravenous injections of massive doses of India ink, colloidal silver, and both live and dead Staphylococcus aureus They found that the particulate matter injected intravenously caused an accumulation of polymorphonuclear leukocytes in the lung capillaries They also found an agglomeration of platelets about these particles With live or dead Staph aureus some of the platelets were completely removed with the bacteria during phagocytosis with movement through the alveolar walls There was phagocytosis of the inert particles by the endothelial cells of the lungs, liver and spleen, and the platelets were assumed to be restored to the circulation

Changes in Leukocyte Level Produced in Anaphylactoid States Pulmonary infarction, infections and metastatic lesions of the lung are often associated with leukocytoses of an extreme degree, yet occasionally patients with severe pulmonary infections will develop marked leukopenic states Goldscheider and Jacob,[34] Bruce,[35] Andrewes[14] and Schilling[36] found that the lungs were filled with excessive amounts of leukocytes during leukopenia associated with anaphylaxis in rabbits and guinea pigs, and Webb[37] reported a similar finding in dogs Andrewes[14] demonstrated that the pulmonary circulation of animals is capable of removing vast numbers of white cells with other immunologic stimuli In a study of the accumulation of leukocytes in the lungs of rabbits following the administration of typhoid vaccine Wells[16] concluded that the cells did not mass in the pulmonary capillary bed However, his conclusions were based upon the counts of blood samples obtained by slashing the lung parenchyma with a razor blade The microscopic sections of the lung capillaries contained excessive quantities of leukocytes but these data were apparently ignored in his conclusions As Webb pointed out seven years later, blood obtained from "lung slashing" is mainly from the larger blood vessels, and the pulmonary capillaries, where the cells are sequestered are not sampled adequately

When pulmonary edema occurred during the course of a rapid transfusion of large numbers of leukemic white cells into humans the pulmonary removal mechanism not only prevented passage of the infused cells but also removed great numbers of the white cells of the recipient. This was observed in two instances in the first of which the initial study had been performed with the same recipient and donor two weeks previously (Fig 4A and B) During the first study there was no untoward reaction and the leukocyte count was essentially unchanged The second transfusion was accompanied by [illegible] of pulmonary edema

The leukopenia observed in the second patient was also associated with the same symptoms during a similar but initial transfusion of

blood from a patient with myelogenous leukemia

In the first case a plausible explanation is one of sensitization of the recipient to the same donor's blood after a two-week period[38] In the second patient the donor's blood had an inordinately large number of disrupted cells the products of which may have been responsible

Samter, Kofoed and Pierper[39] described the eosinotactic property of the lungs of guinea pigs following anaphylactic shock This property of the lungs to produce eosinophilia upon intraperitoneal implantation into a normal recipient was not shared by the intestines uterus gallbladder liver or skin The lungs of normal or sensitized (but not reinjected) guinea pigs produced a significant but limited increase in the number of circulating eosinophils This cosinotactic factor was largely inactivated by incubation at 58°c for forty minutes

It has been known that the lung is one of the major shock organs in both lesser animals and man That it is also a site for the development of the eosinotactic factor presumably at the point of the antigen antibody reaction is now being realized

Chew and Lawrence[40,41] found that pyrogenic substances and the antileukocytic sera have identical effects and lung findings if they are administered intravenously intraperitoneally or into the left ventricle Both an antileukocytic and antilymphocytic serum also caused prompt leukopenia and neutropenia within five minutes following intracardiac injection A one week transient period of tolerance developed and acted similarly to the pyrogen tolerance[4] Many of these findings were obtained in dogs rabbits guinea pigs and rodents

The Effects of Tissue Extracts Doan and his associates[42] while studying the decrease in leukocyte count following the injection of crude nucleic acid extracts in rabbits noted that the lungs as well as the spleen were sites of removal Refined preparations of nucleic acids did not cause leukopenias as did the crude materials This observation suggests that unrefined tissue extracts can stimulate the lungs to remove cells since in some studies Doan observed leukopenia despite partial and total splenectomy[42]

Weisberger and Heinle[22] have shown that material from destroyed leukocytes can cause prompt and profound leukopenia upon intravenous injection in rats and rabbits The mechanism whereby such infusions of cellular debris initiates the removal of leukocytes by the pulmonary circulation involves the consideration of multiple pulmonary emboli by cellular particulate material as well as the cell constituents both immunologic and chemical Similar studies in man have shown this leukopenia to be initially and primarily arterial in nature[43]

EVIDENCE FOR PRODUCTION OF PLATELETS IN THE LUNG

Howell and Donahue[44] showed that the arterial blood of dogs contains more platelets than blood from the right ventricle This discrepancy existed in most but not all observations and was interpreted as evidence to indicate that the lungs of dogs produce and release platelets into the arterial blood Megakaryocytes were shown to be present in large numbers within the dog lung and were presumed to be the source of the platelets

Fidlar and Waters[45] employing the heart lung preparation of the dog were unable to find supporting evidence for platelet production in the lung However as they themselves pointed out the heart lung preparation may be unsuitable for such an investigation Only one fourth or less of the circulating blood volume of the dog was used for the perfusion and an initial rise in arterial platelet number was not sustained

The administration of plasma obtained from a patient with idiopathic thrombocytopenic purpura into a volunteer free of any blood dyscrasia resulted in a prompt and profound fall in platelet level in the recipient's venous blood for two to four days[47] When both arterial and right ventricular blood were sampled during such an infusion the findings in the venous blood confirmed those of Harrington et al but the platelet level of the arterial blood was maintained for approximately eight to eleven hours and then fell to coincide with that in the venous blood (Fig 5) The lungs therefore must act either as a reservoir or as a site of production of platelets The large numbers of platelets leaving the lungs for a prolonged period make it seem likely that new platelets were produced in the lungs under these circumstances Whether the platelets are manufactured from megakarocytes in the lung in man as Howell postulated in the dog is

questionable in view of the relative paucity of megakaryocytes in the human lung It is more plausible that some other mechanism for platelet formation is involved

The platelet count was found to rise promptly, exceeding the normal limits immediately after the start of a cross transfusion [24] (Fig 6) Similar findings were observed after transfusions of granulocytic leukemic blood It has again been suggested[25 45 43] that some white cells are trapped and broken up in the lungs with the release of leukocyte fragments which are recognized as platelets on the smear These fragments appear to be morphologically identical with the classic description of platelets

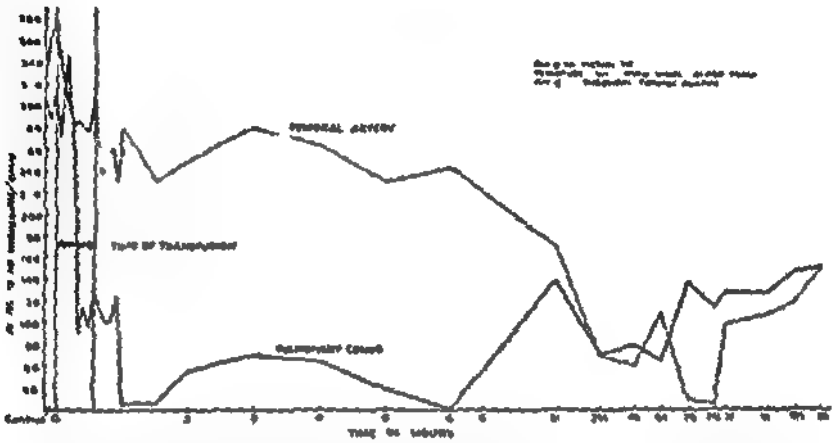

FIG 5 Maintenance of arterial platelet number despite marked thrombocytopenia in the venous blood induced by the infusion of blood obtained from a patient with idiopathic thrombocytopenic purpura

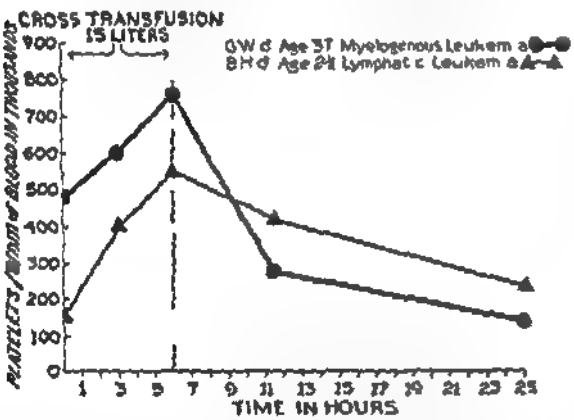

FIG 6 Increase in arterial platelet number in both donor and recipient during arterial cross transfusion

The lung contains a large amount of thromboplastin Potent extracts which possess the ability to produce prompt clotting can be derived from lungs of both animals and man Whether the lung manufactures platelets or thromboplastin, or just stores platelets or thromboplastin like material has not been clarified

Abnormal forms of platelets are frequently found in the blood in the leukemias and chronic thrombocytopenias and in other conditions in which there is great alteration in myeloid tissues [60] The lungs of patients with granulocytic leukemia and Hodgkin's disease are often excessively filled with megakaryocytes [61 62] Repeated auricular punctures in leukemic patients have shown a greater number of megakaryocytes in blood from the right auricle than from the peripheral circulation an indication that some may be arrested in the pulmonary capillaries Ara[63] and Polettini[64] found that the entire contents of the vessels of the lung in some conditions may be made up of platelets

leukocytosis and thrombocytosis which is commonly attributed to a splenic contraction [19 55 56] but is more likely from a pulmonary source [57] However, a similar increase in leukocytes and platelets has been observed in the same patients following splenectomy[58] and more recently the role of the spleen following epinephrine administration has been questioned [59] Hemoconcentration [60] expulsion of leukocytes from lymph nodes[61] and redistribution of the formed elements of the blood have been suggested to explain these findings but no specific site or organ has been designated as an additional source of platelets

When the effects of intra arterially administered epinephrine on splenic vessels were

studied arteriographically, the splenic artery exhibited marked contraction shortly after it arose from the celiac artery ■ There was an absence of the normal small vessel pattern commonly seen without epinephrine It would appear therefore that the flow of blood to the spleen had been markedly decreased or occluded at the point of constriction within ten to thirty seconds after epinephrine administration which persisted for one to two minutes

The spleen of dogs and cats and man have been observed to decrease in size following epinephrine administration intravenously or intra arterially [illegible] ■ but there is little evidence that this decrease in size in man is actually caused by active contraction of the capsule The human spleen is provided with a fibro elastic coat (tunica albuginea) which gives off numerous small fibrous bands or trabeculae in all directions and which upon uniting constitute the framework of the spleen This fibro elastic coat the sheaths of the vessels and the trabeculae are composed of elastic fibrous tissue There is a small amount of non striped muscular fibers in man but in negligible amounts compared to the dog and other animals It is stated that the distribution of these muscle fibers throughout the spleen explains how the spleen can so quickly alter its volume but the data for such a conclusion are based almost exclusively upon studies in the dog [illegible] The amount of muscular tissue in the human spleen is not sufficient to cause the marked shrinkage of the spleen size observed following epinephrine A more likely explanation appears to be an epinephrine induced rise in arterial blood pressure accompanied by spasm of the splenic artery resulting in decreased arterial blood flow to the spleen with emptying of the vascular bed through the venous channels thus depleting the spleen of blood which is accompanied by a decrease in size of the spleen The role of active capsular contraction appears to be minor in man

Anoxia causes an increase in number of circulating platelets and a decrease in coagulation time Asphyxia in kittens is also accompanied by thrombocytosis [63] While it has been suggested that this increase is due to anoxic stimulation of megakaryocytic production in the marrow which may be so in chronic hypoxia the prompt and marked increases that are observed following the inception of acute hypoxia occur too rapidly for such a mechanism In all probability there are at least two mechanisms operating under the conditions of anoxia—one for the acute changes and one for the slower more chronic varieties

EVIDENCE FOR BIOCHEMICAL FUNCTION OF THE LUNG IN HEMATOLOGY

Prothrombin Plasma prothrombin concentration is less in the left ventricle than in the right ventricle of dogs [64] Arteriovenous sampling of the head liver spleen, intestine, kidney and hind limbs shows no significant differences This decrease in plasma prothrombin content during passage through the pulmonary capillaries has been attributed to platelet production in the lungs as suggested by Howell and Donahue The reasoning behind this conclusion is that the disintegration of platelets releases thromboplastin which in the presence of calcium changes prothrombin to thrombin This suggestion would appear to implicate platelet breakdown in the lungs equally with platelet formation

Iron Storage Iron given intravenously ■ taken up by the lungs in large quantities initially and then is gradually released to other sites such as the spleen and liver [65]

Histamine and Histaminase The histamine content of granulocytic leukemic blood has been shown to reach levels up to 2 3 mg per 100 cc [66] Code found that the granulocyte contained the major portion of the histamine in the blood and also noted that the platelet layer occasionally contained histamine This was also reported by Thiersch [67] Code attributed the histamine content of platelets to contamination from the granulocytes but the histamine content of the platelet could also be an inherent characteristic if it were a fragment of the myeloid cell [68] The lung contains large quantities of histamine and histaminase Since the hematologic effects of histamine are focused in the lung the importance of histaminase in the different responses observed in the leukemic and non leukemic patients bears consideration Despite the extremely high histamine content of the leukocytes in granulocytic leukemia the plasma content is negligible This is evidence against intravascular destruction of leukocytes or the prompt destruction and binding of the released histamine or in activation perhaps by histaminase

The lung may serve as a portal of entry of water into the circulation The hemolysis and hemoglobinuria that follows drowning if the patient survives further endangers the subject

In fresh water drowning the contents of the left ventricle are dilute while in salt water drowning the reverse is true The exact mechanism of transport of water across the alveolar and capillary wall is obscure [68]

The lung may act as a route of excretion of leukocytes via the alveoli and sputum The alveoli of the lung usually contain granulocytes which appear to be intact yet there are numerous other cells which are in various stages of disrepair Interestingly enough the sputum of patients with lymphocytic leukemia contains large numbers of granulocytes with few granulocytes in the peripheral blood

The capability of the lungs as an excretory channel is great, but little is known regarding the permeability of the pulmonary capillaries, alveolar walls and other membranes for the transport of substances other than the usual respiratory gaseous components

SUMMARY

The pulmonary circulation is involved in the hematologic system as a portal of entry for stimulating and noxious gases The erythrocytes, leukocytes and platelets are all involved in the dynamic physiology of the pulmonary circulation The lungs may also act as a prodigious and facile reservoir for leukocytes and platelets and under specific circumstances both for the withdrawal of these elements from the circulation or for prompt delivery into the circulation The lungs apparently are involved in the production of platelets as well as in their storage The mechanisms whereby these changes are induced remain to be clarified

REFERENCES

1 BEST C. H and TAYLOR N B Physiological Basis of Medical Practice 5th ed Baltimore 1950 William Wood and Co

2 BARCROFT J and STEPHENS J G Observations upon the size of the spleen J Physiol 64 1–23 1927

3 GARREY W E and BRYAN W R Variations in white blood cell counts Physiol Rev 15 597 638 1935

4 STURGIS C C and BETHELL F H Quantitative and qualitative variations in normal leukocytes Physiol Rev 23 279–301 1943

5 CLARK E R CLARK, E L and SWENSON E A The contraction of arterioles of various sizes and the passivity of venules and capillaries Am J Physiol 105 19 1933

6 SANDISON J C. Observations on the circulating blood cells, adventitial (Rouget) and muscle cells endothelium and macrophages in the transparent chamber of the rabbit s ear Anat Rec 50 355–379 1931

7 LÖWIT M Studien zur Physiologie und Pathologie des Blutes und der Lymphe Jena 1892 G Fischer

8 ARNETH J Die qualitative Blutlehre Leipzig 1920 W Klinkhardt

9 [illegible]

10 [illegible] various modes of production J A M A 16 478 1941

11 MOMOEDA S Nagasaki igakkai zassi 6 851 1928 7 1 1929

12 NYE R N and BARRS V R Distribution of granular leucocytes in normal rabbits Fol ab nemat 47 402 409 1932

13 EWING J Toxic hypoleucocytosis New York M J 61 257 263 1895

14 ANDREWES F W The Croonian lectures on the behaviour of the leukocytes in infection and immunity Lancet 2 [illegible] 1910

15 WELLS C W Leucopenia and leucocytosis in rabbits J Infect Dis 20 219, 1917

16 DOAN C A Neutropenic state its significance and therapeutic rationale J A M A 99 194 202 1932

17 [illegible]

18 [illegible] exper Med 56 503 510 1927

19 WINTROBE M M Clinical Hematology Philadelphia 1951 Lea & Febiger

20 MINOT G R and ISAACS R Transfusion of lymphocytes their rapid disappearance from peripheral circulation of man J A M A 84 1713 1925

21 LANMAN F T BIERMAN H R and BYRON R L Jr Transfusion of leukemic leukocytes in man hematologic and physiologic changes Blood 5 1099 1950

22 WEISBERGER A S HEINLE R W SOYRAASLI J P and HANNALI R Transfusion of leukocytes labelled with radioactive phosphorus J Clin Investigation 29 336 1950

23 [illegible] The sequestration and visceral circulation of leukocytes in man Ann New York Acad Sc in press

26 BIERMAN H R Kelly K H CORDES F L PETRAKIS N L KASS H and SHIPIL E L The influence of respiratory movements upon the [illegible] Blood [illegible] 622 1952

27 [illegible]

28 BIERMAN L P and LITTMAN A The hematological response of leukemic and nonleukemic patients to intravenous histamine J Cancer Res 12 248 49 1952

29 BROWN E B MOORE C V, REYNAFARJE C and SMITH D E Intravenously administered saccharated iron oxide in treatment of hypochromic anemia therapeutic results potential dangers and indications *J A M A* 144 1084 1089 1950

30 WHITE L P BIERMAN H R, KELLY K H BYRON R L JR The immediate hematological effects of intravenous saccharated iron oxide *Blood* 7 897–903 1952

31 OLITZKI L LEIBOWITZ J and BERMAN M Further investigations on the chemistry toxicity and other bacterial properties of different fractions of dysentery bacteria *Brit J Exper Path* 18 305 1937

32 OLITZKI L Antileucopenic tolerance of rabbits and antibody formation in the course of treatment with typhoid vaccine *Acta med orient* 8 103 1949

33 DUDGEON L S and GOADSBY H K The examination of the tissues and some observations on the blood platelets of rabbits at intervals of five minutes and later after intravenous inoculations of Staphylococcus aureus and Indian ink *J Hyg*, 31 247 256 1931

34 GOLDSHEIDER A and JACOB P Ueber die Variationen des Leukocytose *Ztschr f klin Med* 25 373 1895

35 BRUCE D On the disappearance of the leukocytes from the blood after injection of peptone *Proc Roy Soc London* 55 295 1894

36 SCHILLING V Das Knochenmark als Organ mit Funktion des Markenparenchyms and Leukocytose *Deutsche med Wchnschr* 51 516 1925

37 WEBB R A The mechanism of anaphylactic leucopenia in dogs *J Path & Bact* 27 79 1924

38 CUMLEY R W and IRWIN M R Individual specificity of human serum *J Immunol* 46 63–70 1943

39 SAMTER M KOFOED M and PIFFER W A

40

Antileukocytic serum *J Immunol* 30 301 1936

41 CHEW W B and LAWRENCE J S Antilymphocytic serum *J Immunol* 33 271 1937

42 BENNETT I L and BEESON P B The properties and biologic effects of bacterial pyrogens *Medicine* 29 365 400 1950

43 DOAN C A ZERFAS L G WARREN S and AMES O A study of the mechanism of nucleinate-induced leucopenic and leucocytic states with special reference to the relative roles of liver spleen and bone marrow *J Exper Med* 47 403 1928

44 BIERMAN H R KELLY K H and CORDES F Unpublished data

45 HOWELL W H and DONAHUE D D The production of blood platelets in the lungs *J Exper Med* 65 177 214 1937

46 FIDLAR E and WATERS F T The origin of platelets *J Exper Med* 73 299 307 1941

47 HARRINGTON W J SPRAGUE C C MINNICH V MOORE C V AULVIN R C and DUBACH R Immunologic mechanisms in idiopathic and neonatal thrombocytopenic purpura *Ann. Int Med* 38 433 1953

43 SCHWALBE E Die Blutplättchen [illegible] ihr Bau und ihre Genese *Ergebn d allg Path*, 8 150–195 1902

50 TOCANTINS L M The mammalian platelet in

51 M

52 BUNTING C H Blood platelets and megakaryocytes in Hodgkin's disease *Bull Johns Hopkins Hosp* 22 114 116 1911

53 ARA A Aportacion hematologica sobre la megacariocitosis y la plaquetemia *Rev de med y cir de la Habana* 40 1 32 1935

54 POLETTINI B Sul comportamento delle piastrine nel sangue di animali normali e di animali en istato di choc anafilatico *Patologica* 10 209–215 1918

55 FREY W Zur Frage der Funktionellen Milzdiagnostik Mittels Adrenalin *Ztschr f d ges exper Med* 3 416–440, 1914

56 BANCROFT J De Stellung der Milz im Kreislaufsystem *Ergebn d Physiol* 25 816–818 1926

57 BIERMAN H R KELLY K H CORDES F L BYRON R L JR POLIEMUS J A and RAPPOPORT S The release of leukocytes and platelets from the pulmonary circulation by epinephrine *Blood* 7 683–692 1952

58 LUCIA S P, LEONARD M E and FALCONER E H The effect of the subcutaneous injection of adrenalin on the leukocyte count of splenectomized patients *Am J M Sc*, 194 35 43 1937

59 BIERMAN H R BYRON R L JR and KELLY K H The role of the spleen in the leukocytosis following the intra arterial administration of epinephrine *Blood* 8 153–164 1953

60 SCHENK P Effect of epinephrin on blood *Med Klin* 16 2–9 1920

61 WALTENHOFER G Leukocytosis under epinephrine treatment *Deutsches Arch f klin. Med* 135 208 1921

62 WRIGHT C S DOAN C A BOUHONCLE B A and ZOLLINGER R M Direct splenic arterial and venous blood studies in the hypersplenic syndromes before and after epinephrine *Blood* 6 195 212 1951

63 CESARIS DEMEL A *Haematologica* 5 104 1924

64 ANDRUS W DEW LORD J W JR. and KAUER, J T Studies on the fate of plasma prothrombin *Science* 91 48–50 1940

65 ANDERSSON N S E Experimental and clinical investigations into the effect of parenterally administered iron *Acta med Scandinav* Suppl 241 1–71 1950

66 CODE C R Histamine in blood *Physiol Rev* 32 47 65 1952

67 THIERSCH J B Histamine and histaminase in chronic myeloid leukaemia of man I Histamine in the blood of chronic myeloid leukaemia II Histamine and histaminase in the blood of cases of myeloid leukaemia under and after deep x ray treatment *Australian J Exper Biol & M Sc* 25 73–74 75–77 1947

68 RATH C E Drowning hemoglobinuria *Blood* 8 1099 1953

Pathogenetic Concepts

DAVID M SPAIN, M D, *New York, New York*

From the Department of Laboratories of Beth El Hospital Brooklyn N Y, and the Department of Pathology, Columbia University College of Physicians and Surgeons New York N Y

THE use of antibiotics in the prevention and treatment of suppurative inflammation of the lung, the advent of specific chemotherapy in tuberculosis, the use of streptokinase and streptodornase in pleural collections and the development of such procedures as bronchospirometry and pulmonary arterial catheterization in the study of pulmonary function have necessitated a re evaluation of our concept of the pathogenesis and the complications of many forms of pulmonary disease The pathology of this disease has to some extent been outmoded It is doubtful whether any recent graduate from medical school can or will ever understand the real nature of pneumococcus pneumonia and its complications unaltered by modern therapy Careful study of the numerous resected portions [illegible] and processes [illegible] his attention on lungs from apparently healthy young individuals who have died suddenly from violence More exact concepts of pathogenesis have emerged from these studies of early and incipient lesions It is within this framework that some of the aspects of pulmonary disease as related to the practice of medicine will be discussed It is difficult in a brief report to review the entire field Attention therefore will be directed to such entities as post traumatic and postoperative pulmonary changes, obstructive pneumonitis, lung abscess, bronchiectasis, fibrosis of the lung and pleura emphysema and some aspects of pulmonary tuberculosis

SOME ASPECTS OF TUBERCULOSIS

In the classic concept of tuberculosis there was a clear difference concerning the degree and significance of lymph node involvement as it occurred in the childhood type of tuberculosis (primary infection) and the adult form (exogenous reinfection or endogenous exacerbation) In the former, lymph node involvement was usually pre eminent The lymph nodes were large and associated with considerable caseation necrosis Endobronchial tuberculosis as a consequence of this was not uncommon In adults lymph node involvement was relatively insignificant and consequently endobronchial tuberculosis secondary to it was rare The development of endobronchial tuberculosis as a complication of lymph node tuberculosis appears to be occurring proportionately to a greater degree in adults in recent years In two recent reports[1,2] perforation of caseous hilar lymph nodes into the bronchi of adults has been stressed In one of the reports thirty eight recent bronchial perforations and eighty one residual perforations were found in 1,228 bronchoscoped adults with pulmonary tuberculosis However, it is doubtful whether lymph node penetration into the bronchi is as important a factor in the pathogenesis of adult pulmonary parenchymal tuberculosis as some have stated[3] In this country at least the majority develop pulmonary parenchymal tuberculosis either from endogenous exacerbation of pre existing parenchymal disease or from a new or primary infection caused by tubercle bacilli inhaled directly into the parenchyma from without Because of the public health measures which have delayed and frequently prevented exposure of individuals to significant doses of tubercle bacilli until young adulthood or later, many of the current cases of adult tuberculosis are the result of recent primary infections This probably accounts for the reported increase in the number of cases of adult tuberculosis with caseous lymph nodes that involve the bronchi One may conjecture that chemotherapy combined with surgical resection may be permitting us to see this complication relatively more

frequently Bronchial involvement secondary to hilar and peribronchial lymph node tuberculosis presents such variations as endobronchial tuberculous with exuberant granulation tissue, bronchial fistulas, focal scars, partial and complete stenosis, diverticulas and broncholiths When endobronchial tuberculosis heals with scar formation, the wall becomes rigid and the lumen narrowed The partial obstruction hinders the normal cleansing mechanism of the involved pulmonary segment and predisposes to suppurative inflammation and bronchiectasis It is possible that a relatively greater incidence of bronchiectasis on this basis may be seen as a consequence of untreated adult endobronchial tuberculosis The more obvious complication is the direct dissemination of tubercle bacilli into the area of lung supplied by the involved bronchus with the onset of segmental tuberculous pneumonia Occasionally obstructive emphysema is a prominent complication

Perhaps no other problem in recent years relative to the therapy of tuberculosis has raised as much of a controversy as the method of treating the isolated subapical necrotic focus which persists after intensive and prolonged chemotherapy This lesion often persists without any clinical manifestations of the disease A number of years ago studies[4] on these isolated necrotic foci clearly demonstrated that significant numbers of these lesions communicated intermittently or persistently with the bronchial tree This was in contrast to what had been previously reported by others However, there is no doubt that at present that these foci communicate with one or more bronchi A necrotic focus may represent an original area of caseous pneumonia which has not completely liquefied, it may represent an incompletely healed cavity with inspissation of the caseous material or it may represent a "tuberculoma" These lesions are potentially dangerous because it is unusual for them to resorb and difficult for them to organize or to slough completely so that viable tubercle bacilli can persist in them for long periods and eventually be disseminated Because these areas are hardly ever irrevocably sealed off from the bronchial tree, reopening may occur despite any form of nonsurgical therapy The ultimate disposal of these necrotic areas presents a major problem Closely related is the unsolved question pertaining to those factors responsible for the liquefaction of the necrotic caseous material It is well known that in some cases this necrotic material will liquefy almost immediately while in others solid isolated necrotic foci may persist for years, and then for reasons not completely understood, suddenly liquefy with the discharge of tubercle bacilli into the communicating bronchi Some[4] claim that liquefaction results from the action of proteolytic enzymes released from lysed polymorphonuclear leukocytes that infiltrate the area Others[5] believe that the enzymes responsible for liquefaction of the lesions are derived from the tubercle bacilli or the products of the inflammation

Many of these lesions which did not show any alteration following adequate and prolonged chemotherapy were then resected Study of them provided further proof of the concept that these were potentially harmful lesions since they communicated with bronchi Furthermore cavities and foci of necrosis were found that were previously unsuspected from the x ray picture and clinical examinations It was also demonstrated that streptomycin promoted healing with an increase in the extent of epithelialization at the bronchocavitary junction[6] Although this is a manifestation of healing it has its adverse effects An epithelial lining at the bronchocavitary junction could prevent complete closure by interfering with the approximation of the opposing granulation tissue surfaces This, at least theoretically, increases the danger of those isolated solid, necrotic, or partially cavitary foci

The problem became even more complicated when bacteriologic studies performed on these resected isolated lesions (previously treated with chemotherapy) revealed that the acid fast bacilli could be stained on smears (obtained from these necrotic foci) but too often failed to grow on artificial culture media and in many instances were no longer pathogenic for the suitable experimental animal[7] Thus the "burning" question of the day concerns the viability of these organisms If dead, perhaps resection is not as frequently justified At this stage of inconclusive and conflicting evidence it would seem prudent to regard these bacteria if not actively alive, as at least sound asleep rather than dead This is consistent with the demonstrated biologic behavior of other single cells Some pathogenic bacteria as well as cancer cells from experimental tumors

FIG 1 Section showing acute necrotizing inflammation of bronchiolar wall Hematoxylin and eosin, × 100

may be lyophilized, frozen and kept in this apparently dormant state for long periods of time (years) only to be rejuvenated and then under proper conditions to produce infection or malignant growths Although the most recent studies are in favor of viability, the final answer must await more careful bacteriologic, biologic, genetic and biochemical investigations Upon this determination will depend the most rational form of treatment of the persistent caseous focus.

At the operating table the surgeon frequently notes more disease in the lungs than was anticipated from the x ray picture The question arises of how much lung to resect Should the subapical necrotic focus alone be resected or is it necessary to remove the entire lobe because some nodules are present in the lower portions of the lobe? An important determining factor in the behavior of a tuberculous lesion is its location in the lung All other factors being equal, the higher the lesion is located in the lobe the less is the chance for healing Posture is of considerable importance in pulmonary tuberculosis[4] For instance in cattle, tuberculosis flourishes best at the posterior basal regions of the lungs This area, however, is actually the highest portion in a four legged animal Untreated hematogenous miliary tuberculosis in adults as it progressed will eventually reveal more numerous, more necrotic and larger lesions in the higher portions of the lung whereas in infants who are not upright animals, this does not take place It is believed that the difference in intravascular oxygen tension at various levels in the lung may be an important reason for this postural differentiation At any rate, it may be necessary to resect only the necrotic focus in the upper portion of the lobe and then reasonably expect the lower lesions to heal with proper medical therapy

With the prolongation of life as a result of chemotherapy, tubercle bacilli over a period of many years may at varying intervals spill from these recalcitrant necrotic foci The bronchial and peribronchial lesions that result may remain subclinical These multiple lesions may heal with the subsequent development of peri bronchiolar fibrosis and bronchiolar narrowing with the production of obstructive emphysema In some cases the process may be sufficiently extensive so that significant cardiorespiratory insufficiency is present

One sees with relatively greater frequency an increase in the number of thin wall cavities either after or during chemotherapy Many of these thin walled cavities are found to be lined with a fibrous wall with no evidence of active tuberculous inflammation At times there are spotty areas of new epithelium These [illegible] tary junc [illegible] ication [illegible] cavity [illegible] ll valve is slit like and [illegible] manner This in some cases results in marked distention of the cavity because of the development of positive pressure within it This type of alteration in treated tuberculosis is known as the healed opened cavity

COMPLICATIONS OF SUPPURATIVE INFLAMMATION (ABSCESS AND BRONCHIECTASIS)

Two of the main consequences of suppurative inflammation of the lungs are bronchiectasis and lung abscess Many theories have been advanced for the pathogenesis of bronchiectasis Among these are the ones concerned with congenital or developmental de-

fects, distention of the bronchi by cough, destruction of the bronchial wall by necrotizing inflammation, obstructive mechanisms, atelectasis and fibrous retraction The validity of all or some of these theories is still a matter of dispute, but one undeniable fact remains, and that is the importance of suppurative pneumonia in the development of bronchiectasis That so many cases of bronchiectasis have followed the suppurative streptococcic and staphylococcic pneumonias which may complicate pertussis measles etc is of major importance That bronchiectasis so seldom appears after pneumococcic pneumonia is also of significance In pneumococcic pneumonia, although atelectasis may be present as well as temporary obstruction with exudate of the smaller ramifications of the bronchial tree, there is usually no necrotizing inflammation of the lungs The bronchial tree is only mildly inflamed and remains intact This is in contrast to the pneumonias associated with childhood diseases In these pneumonias the bronchial walls are often involved in an acute necrotizing process The development of bronchiectasis is to a great extent dependent upon the destruction of the bronchial musculo elastic layer (Fig 1) Whether or not this destruction be-

elastic layer is destroyed it is replaced permanently by fibrous tissue It has been demonstrated that this process takes place rapidly within a matter of weeks from its inception The decrease in recent years in the incidence of new cases of bronchiectasis is most likely attributable to early and effective chemotherapy of these suppurative pneumonias This has limited the degree of bronchial necrosis and further attests to the importance of suppurative necrotizing pneumonia as a leading factor in the development of bronchiectasis Any infection of the lung which terminates in suppurative necrotizing pneumonia is basic to the pathogenesis regardless of what other associated mechanisms may be present whether these be obstruction traction atelectasis or retraction Once bronchiectasis has developed and it does so rapidly (it is not a creeping process that develops over a period of years) a sequence of events takes place determined by the degree, type and location of the bronchiectasis The dilated and altered bronchi which are often lined with squamous and non ciliated epithelium favor the retention of secretions within the lung Since the retained secretions are an excellent culture media, repeated infections occur with varying degrees of pneumonia which undergo organization The untrammeled course of bronchiectasis with repeated episodes of pneumonia eventuates in a contracted functionless lung or segment of lung This consists of fibrous tissue, varying degrees and stages

Focal and diffuse areas of atelectasis and emphysema may be present

In a review of 200 consecutive postmortem examinations on patients with bronchiectasis (prior to the advent of antibiotics and in whom resection was not performed), it was found that the cylindrical form of bronchiectasis offered a more favorable prognosis than the saccular form[8] This is understandable because it is easier for exudate to stagnate in the saccular type Another factor of importance was the location of the bronchiectasis All other conditions being constant, bronchiectasis that was limited to the upper portion of the upper lobe ran a less hectic course than bronchiectasis in other regions Cylindrical bronchiectasis that

drain well The main clinical import of bronchiectasis in this location was that of its confusion clinically with tuberculosis Only if bronchiectasis was bilateral and widely distributed did sufficient obstructive emphysema arise to be clinically significant Associated

mistaken for atypical forms of fibrosis of the lung bronchial asthma with infection, etc In these 200 cases the average age was 58 5 years of whom 44 per cent died directly from bronchiectasis or its complications In 75 per cent there was multiple lobe involvement Diffuse bronchiolectasis was present in thirty eight cases Lower lobes were the site of bronchiectasis twice as often as upper lobes Cylindrical and saccular forms occurred with equal frequency and were often present together in the same case

Is bronchiectasis *reversible?* Perhaps the question can be resolved if one separates bronchiectasis into functional and anatomic types *Functional or relative* bronchiectasis may result *from* the collapse or compression of the lung with the consequent crowding and foreshortening of the *bronchi* This is a relative dilatation with no anatomic alteration in the bronch[illegible]

will then disappear However, if there is necrosis in the bronchial wall, particularly in the muscular and elastic layers with dilatation of the bronchi (an anatomic alteration), the process soon becomes irreversible[9,10]

The complications of untreated or ineffectively treated bronchiectasis are recurrent pneumonitis with organization, spread of infection to other parts of the lung, abscess formation pulmonary hemorrhage, brain abscess, empyema and, rarely, amyloidosis The development of prominent bronchopulmonary arterial shunts in bronchiectasis offers a possible explanation for some of the altered circulatory dynamics that arise in this condition[11] It is a factor that must be considered in the evaluation of the findings in pulmonary function and arterial catheterization studies

The other main complication of suppurative pulmonary disease is lung abscess Lung abscess may develop from the aspiration of infected or foreign material from obstruction of the bronchial tree, from liquefaction necrosis of a primary suppurative pneumonia (Friedlander's bacillus pneumococcus type V, staphylococcus, etc), from infected emboli, rarely from secondary infection in a pulmonary infarct, from secondary infection of congenital cysts and emphysematous bullae,[12] from a penetrating injury of the chest wall or from intra abdominal infection that penetrates the diaphragm The pathogenic organisms involved are usually multiple are frequently anaerobic and are occasionally associated with various fusospirochetes Of all these mechanisms the onset of lung abscess secondary to aspiration is the most frequent

Any individual ordinarily has certain defense mechanisms which permit him to keep out or rid his upper and lower respiratory tracts of noxious material These include an active reflex system (sneezing coughing, gagging), etc To function effectively these depend on an intact central nervous system and muscular apparatus (chest walls, diaphragm) In addition to this the ciliated and mucin producing epithelial lining of the upper and lower respiratory tract is an effective means for the trapping and the constantly sweeping out of foreign material from the respiratory tract Consciousness therefore is an important factor in maintaining the integrity of this reflex system During such periods as surgical anesthesia postoperative states, alcoholic stupor traumatic shock, cerebral injuries with coma many elements of the respiratory tract defense and cleansing system are impaired Particularly if poor oral hygiene is present, the aspiration of food particles and saliva laden with bacteria and saprophytes, will then lead to suppurative pneumonia, and one of its complications pulmonary abscess In many instances, one may rub a tongue depresser against the wall of the pharynx of an individual with a lung abscess and find there is a completely absent or markedly depressed gag reflex It has also been observed that during periods of sleep it is possible to drop lipiodol into the open mouths of the sleepers and, on x ray examination the following morning find lipiodol present in the parenchyma of the lungs This indicates that inadequacies exist in these protective mechanisms under certain conditions

The aspiration type of lung abscess is characteristically located in the periphery of the lung and is segmental in distribution Localization of these abscesses in the different pulmonary segments can usually be related to the posture of the individual If the person is in a supine position and infectious material is aspirated the most direct route would be into the superior segment of the lower lobe When the patient is on his side, the most direct route for aspirated material would be into the bronchi of the posterior segment of the lower lobe or the axillary branches of the anterior segment Occasionally, areas of involvement are seen which are not so readily explained

Early in the course of a lung abscess there is an overlying fibrinous pleuritis This partially seals off that portion of the pleura from the remainder of the pleural space This in addition to the peripheral and segmental distribution of the abscess, has been the anatomic basis for the one stage surgical treatment of lung abscess With the use of chemotherapy and antibiotics, many cases of suppurative pneumonia

do not proceed to the stage of lung abscess If an acute lung abscess is present, it may be aborted so that it does not become chronic and with adequate drainage, it may become completely obliterated However, in many instances this is not the case An abscess develops which at first is thin-walled, may or may not be loculated, and may communicate freely with more than one branch of the bronchial tree The inner lining of this abscess consists of a pyogenic membrane and granulation tissue which may be friable and bleed moderately As the abscess becomes chronic, the granulation tissue is transformed into a dense fibrous wall, and the surrounding parenchyma consists of organizing pneumonia with some bronchiectasis Large blood vessels may be present in the scar tissue and superficially located in relation to the cavity lumen On occasion, serious hemorrhage may occur from ulceration of these vessels The lining of the cavity may consist partially or entirely of granulation tissue, squamous epithelium or, in rare instances of a ciliated one layered mucus-producing epithelium

The dense, rigid, fibrous wall of the abscess impedes collapse with total obliteration Complete healing is also prevented because the granulation tissue may be covered with squamous epithelium Residual cavities, therefore, are frequent sequelae and act as potential reservoirs for the accumulation of secretions and thus provide an excellent soil for the growth of bacteria This serves as a source for contamination of other parts of the lung and for the recurrence of acute inflammation in the cavity

Residual lung abscess cavities occur much more frequently than is generally recognized It constitutes an important late sequela of lung abscess which must be considered in the approach to the primary treatment of lung abscess

The differentiation of an aspiration abscess from an infected cyst of the lung may at times be very difficult Even in the presence of the entire previous history it may be impossible Pulmonary cysts usually have poorly demonstrable anatomic communications with the bronchial tree in contrast to lung abscess Pulmonary cysts are more often centrally located A bronchiectatic abscess usually contains cartilagenous and muscular elements in its wall Lung abscess associated with bronchogenic carcinoma is usually secondary to obstructive pneumonitis and less frequently caused by necrosis and infection within the tumor itself The latter situation is often confusing clinically, especially when a small peripheral carcinoma with central necrosis and infection simulates a small cavity in the periphery of the lung Such cases have been observed for long periods before carcinoma was seriously entertained as the diagnosis of choice Usually in this type of case a segment of the wall of the cavity is irregular and thickened This represents irregular necrotic tumor in the wall of [illegible]

sis and brain abscess In most cases of brain abscess pleural adhesions are present and the route of spread is usually through the vertebral venous system

ATELECTASIS AND ACUTE NON AERATION OF THE LUNG

Probably no other diagnosis related to pulmonary disease has been abused as much as that of atelectasis It is constantly being made when opacities are seen in roentgenograms of the chest in such situations as postanesthetic states, barbiturate narcosis, chest wall injuries, prolonged rest in the supine position, poliomyelitis, bronchial asthma pulmonary infections with retention of thick, tenacious mucus or exudate, and aspiration of foreign material or foreign bodies Yet, postmortem examination of the lungs in such conditions most often fails to reveal what is correctly defined as atelectasis This discrepancy is probably due to a misinterpretation of the actual alterations that usually transpire in the lungs in the aforementioned conditions Atelectasis, correctly defined, refers to the incomplete expansion of the [illegible]

later periods of life The usual mechanism which is thought to produce collapse of lung parenchyma is absorption of the alveolar air after the bronchus to a particular region has been obstructed The other mechanism, compression of the lung, may be produced by alterations in the pleura, diaphragm or chest wall In the former mechanism, bronchial drainage is impaired, while in the latter it is not, unless, associated intrapulmonary disease is present In microscopic sections the walls of the alveoli, alveolar ducts and respiratory

bronchioles are closely opposed to form slit-like spaces with the walls often paralleling each other The alveolar capillaries appear to be dilated, but it has been shown that less blood flows through an atelectatic lung than a normal expanded one

The findings[13] of congestion, edema and some reduction in the size of lung, with an infiltration of inflammatory cells in dogs with obstructed bronchi, would indicate that in many instances shadows appearing in the chest roentgenograms are at first primarily caused by congestion and edema The reduction in the size of the lungs and the inflammatory exudate appear somewhat later Within thirty-six hours it was necessary to consider the process as pneumonia

Sudden massive collapse of a lung or any portion thereof cannot be adequately explained on the basis of resorption of gas behind a blocked bronchus Many hours must elapse before resorption would be complete Massive collapse in sudden postoperative atelectasis is more readily attributable to a ball valve type of obstruction which permits egress of gas during expiration but no ingress during inspiration In a short period of time all the gas will be emptied from the lung and collapse will be complete If the obstruction persists, edema and inflammation will appear Some observers claim that massive collapse of the lung can best be explained through a neurogenic mechanism This has never been completely substantiated

Experimental observations indicate that the development of the edema is due to anoxia The alveolar capillaries depend for their oxygen supply upon the alveolar gas If this is shut off or reduced, the alveolar capillaries are deprived of sufficient oxygen and the capillary endothelium becomes more permeable This permits fluid and cells to accumulate in the alveolar spaces Another explanation offered for the development of edema, following bronchial obstruction is a mechanical one It is claimed, with absorption of gas distal to the obstruction, that a negative pressure is exerted on the alveolar capillaries with the resultant sucking of fluid from the capillaries into the alveolar spaces It would seem from most experimental and clinical evidence that the former explanation is the most important and valid one In some experimental studies obstruction of the larger bronchi has produced real atelectasis without edema However, in these studies the bronchi were obstructed through an open chest and after the lung was collapsed from the pneumothorax created by the procedure

In all of these conditions one of the most important defense mechanisms necessary to maintain adequate aeration of the lungs, that is, collateral ventilation, is interfered with Maintenance of adequate collateral ventilation is dependent upon a proper functioning neuromuscular apparatus as well as the patency of the smaller bronchioles In both experimental studies and in clinical experience congestion and edema developed very early from multiple causation Any subsequent reduction in the size of the lung (atelectasis) would then be superimposed on this pre-existing edema and congestion

The sum total of the final picture, depending on the duration and circumstances involved, is a combination of congestion, edema fluid, inflammatory cell infiltration and varying degrees of reduction in size of the lungs due to the absorption of gas Without antibiotic therapy this is the ideal background for the development of pneumonia Simple collapse of the lungs, as in compression atelectasis following artificial pneumothorax in which none of the above factors are operating, and in particular in which the bronchial drainage is not impaired does not predispose toward infection But it is important to note, despite the terminology employed, whether this be atelectasis, wet atelectasis, collapse of the lung, edema or atelectatic pneumonia, what the mechanism and pathogenesis of the lesion is and what the ultimate consequences might be The use of the term, acute non aeration of lung, is suggested to describe these x ray picture shadows because it is non specific and yet recognizes the fundamental functional and anatomic alteration that is present In any individual situation of this sort it is difficult to be certain

[illegible]

CHRONIC OBSTRUCTIVE PNEUMONITIS

Chronic obstruction of the bronchus leads to changes in the parenchyma Unfortunately, the term "atelectasis" has been indiscriminately applied to these changes The use of the term "atelectasis" persists despite reported observations that have carefully detailed the changes as not being those of atelectasis The most important cause of chronic bronchial ob-



FIG 2 Section showing an area of acute non aeration following trauma to the chest Intra alve [illegible] red blood cells and some mononuclear cells are present Hematoxy[illegible]

FIG 3 Section showing [illegible]

struction is carci[illegible] carcinoma in its early stages does not produce complete obstruction At the stage at which there is incomplete obstruction, there is interference with the normal defense or cleansing mechanism of the lung This impairment consists of mechanical obstruction, destruction of ciliated epithelium and muscular elastic layer of bronchus As a result, infection flourishes in the particular segment of the lung involved This infection may consist of such changes as suppurative pneumonia, bronchiectasis and/or lung abscess with organization of this pneumonia Recurrences of pneumonia with repeated organization eventually produces a contracted fibrotic and chronically inflamed segment or lobe of lung This is the characteristic picture of chronic obstruction in the bronchial tree, and should be regarded as chronic pneumonitis rather than as atelectasis By the time the bronchus is completely obstructed, these changes have all taken place and one is usually dealing with a functionless area of lung The question of whether or not some air has been resorbed to produce superimposed atelectasis is quite irrelevant Bronchial adenoma, foreign body, mucus inspissation and broncholiths, etc, will produce the same picture of obstructive pneumonitis On occasion, there may be suddenly engrafted on this partial obstruction, hemorrhage, edema or necrosis of tissue, which then for a period of time completely obstructs the bronchus Associated with this gradual organizing pneumonitis there may then develop acute non-aeration consisting of an admixture of edema and collapse (Fig 3)

From a diagnostic and pathogenetic viewpoint it should be recognized that in this antibiotic era it is entirely possible for suppurative pneumonia to resolve almost completely despite the persistence of the bronchial obstruction However, inevitably infection will recur in this same segment of the lung Ob-

struction is only one cause of unresolved and organized pneumonia When an area of pneumonia *fails* to resolve, it should be *realized* that there is an underlying reason for this One of the most *important reasons has already* been mentioned namely, obstruction of the bronchus In other instances failure *to resolve* is based upon an underlying *and often previ* ously unrecognized bronchiectasis, *primary* suppurative pneumonias *such as Friedlander's,* unrecognized tuberculous *pneumonia,* lipoid *pneumonia, etc In recent years* there has been discussion of an entity which has been called cholesterol pneumonitis In the author s opinion this merely represents an excessive accumulation of lipids (*cholesterol in macro* phages) in an area of organized *pneumonitis* from whatever the cause *Some in the past have referred to this as a* ' golden pneumonia " This is in no way different than lipid accumu lation that is seen in chronic salpingitis or the high cholesterol content of the exudate in chronic empyema *Endogenous accumulation* of lipids in chronic inflammation is not unusual *and should not be regarded as a distinct entity* in itself

FIBROSIS OF THE LUNG AND PLEURA

Discrepancies are frequently noted between the degrees of lung involvement shown by the roentgenogram and the severity of the subjective symptoms of the patient With the advent of pulmonary functional studies such as bronchospirometry pulmonary arterial cathe terization discrepancies were still observed between the degree of functional impairment and the degree of involvement on the x ray picture It is also well known that there is often very little correlation between cardio *respiratory insufficiency* that is observed in silicotics and the degree of pulmonary involve ment *as seen both on the roentgenograph* and at postmortem examination An analysis of postmortem *examinations on a great variety* of pulmonary conditions however indicate that it is the pattern and *the distribution of* the fibrosis of the lungs rather than the quan titative degree of fibrosis that is more closely correlated with the severity of both the objec tive and subjective clinical manifestations

These patterns of fibrosis will to a great extent determine the degree and type of ventilatory (air-flow), respiratory (gas ex change at alveolar interspace) and combined *ventilatory* and respiratory and cardiopul *monary* disturbances An understanding of *the means,* whereby the different patterns of *fibrosis* disturb pulmonary function, *would to* a great measure explain apparent discrep *ancies between the degree of both subjective* and objective pulmonary disturbances in the *patient and that which is seen on the roentgeno* graphic picture The status of pulmonary func *tion at any given* time depends on the dynamic interplay of the *anatomic* alterations caused by *fibrosis variations of blood* supply in volume and *composition,* the condition of neuromuscu lar apparatus *of the chest* and the chemical stimulation of the *brain centers*

In many disease entities several different *patterns* of fibrosis may coexist The destruc tive effects of inflammatory and neoplastic processes on the pulmonary parenchyma are well known Aside from these effects probably the most significant results of damage to the lungs are secondary to the alterations associ ated with *fibrosis* It is *this fibrosis of* the lung which results from various forms of injury *and disease that very often determines* the functional potential of the patient Fibrosis of the lung may be distributed in *five different* [illegible] parenchyma [illegible] ies of [illegible] n the etiologic agent and the associated *disease* [illegible] fibrosis which [illegible] of diseases the most outstanding sequella is obstructive emphysema This may be diffuse or local Very often in diffuse obstructive emphysema there is minimal fibrosis in the alveolar walls [illegible] and

explained as secondary to the obstructive [illegible] tention without the necessity of invoking primary degeneration of the lung parenchyma (Fig 4)

The second pattern of pulmonary fibrosis is that which occurs in interstitial tissues of the alveolar walls This produces primarily a dis turbance of diffusion of gases across the alveolar [illegible] One of the classical [illegible] ccurs [illegible] brosis [illegible] and

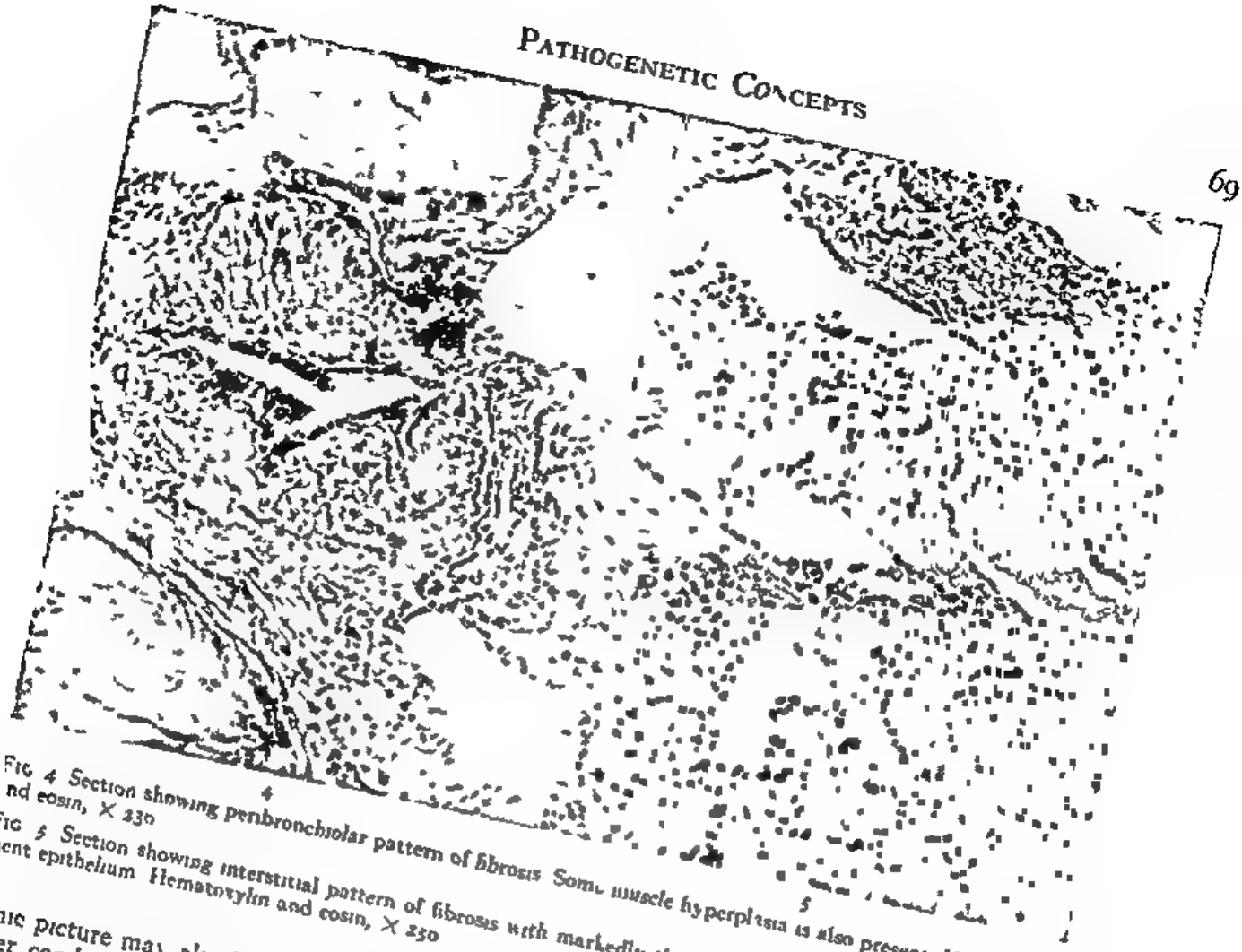

FIG 4 Section showing peribronchiolar pattern of fibrosis Some muscle hyperplasia is also present Hematoxylin and eosin, × 230

FIG 5 Section showing interstitial pattern of fibrosis with markedly thickened alveolar walls lined with prominent epithelium Hematoxylin and eosin, × 230

tomic picture may also be subacute In many other conditions the fibrosis is also predominantly in the interstitium of the lungs Among these are scleroderma, beryllium poisoning and bauxite pneumoconiosis This type of fibrosis not only causes a respiratory type of disturbance but it also increases the viscosity of the ructural framework of the lung and thereby ntributes to a ventilatory disturbance as ll (Fig 5)

Another pattern of pulmonary fibrosis is enchymal or intra-alveolar This is a com form and is often secondary to organization of any suppurative pneumonia, Friedlander's pneumonia, lipoid pneumonia and radiation pneumonia The degree of functional impairment is almost quantitatively related to the size of the area involved and, to some extent, to the degree of secondary compensatory distention emphysema

Fibrosis or sclerosis of the pulmonary vascular bed is a fourth pattern, and is seen in such entities as organization of multiple arterial emboli or thrombi, pulmonary schistosomiasis, foreign body emboli in the pulmonary vasculature, etc Organization of multiple pulmonary emboli has been mistaken for pulmonary arteriosclerosis associated with so-called primary pulmonary hypertension

A well recognized form of fibrosis is that related to the pleura This may result from organization of the exudate which develops secondary to acute or chronic pyogenic empyemas, tuberculous empyema or traumatic hemothorax The fibrinous, serofibrinous, fibrinopurulent exudate or blood present in these conditions becomes organized, and a fibrotic pleural envelope develops, which contracts and constricts the underlying lung parenchyma This eventually interferes with both the ventilatory capacity of the lungs and also with the flow of blood to the underlying involved area. A secondary effect is the development of distention emphysema in the uninvolved area

and/or in the contralateral lung Sometimes in extensive and *long standing pleural* involvement the fibrous tissue may extend along the interlobular septa into the lung parenchyma *This has the additional effect of diminishing* the elasticity of the lung and hence further compromises ventilation

With the development of the surgical procedure whereby these fibrotic pleural envelopes may be removed (decortication) and the lung re-expanded it has become increasingly important to determine the amount of return to normal function that may occur after re expansion of a long standing compressed lung Present studies seem to indicate that complete restoration of function does not occur despite complete anatomic re expansion This may be accounted for by the fact that in most cases *with fibrotic pleural envelopes there is associ*ated underlying parenchymal disease Best results would be obtained when the fibrotic pleural envelopes have appeared secondary to traumatic hemothorax and when there was no associated pulmonary disease The re expansion of the lung will prevent the progression of distention emphysema in the contralateral lung A distinct line of cleavage may be obtained in many instances between this pleural envelope which consists of organized exudate or blood and the underlying pleura The peel (organized exudate) that is stripped from the visceral pleural surface often has adherent to it the outer layers of the pleura which contain elastic tissue Failure to remove or prevent fibrothorax in children may result in extensive chest deformity

EMPHYSEMA

Emphysema may be classified into three types First senile emphysema in which there is supposedly an alteration in the composition and elasticity of the alveolar walls with attenuation and degeneration of these walls leading to fusion of many of the alveolar spaces *There is no enlargement* of the lung and no
ent n the bronchial
clinical
of fact
many no longer regard this form of emphysema as a distinct entity

The second type is compensatory anatomic distention emphysema This is seen after destruction resection compression or fibrous *contracture of portions* of the lung The remaining lung tissue distends in order to fill in the abandoned space It is therefore compensatory only in an anatomic sense because any overdistention of the lung leads to functional impairment

The most important form of emphysema is the third type and has been called by various observers obstructive idiopathic large lung emphysema or degenerative lung disease This may be diffuse or localized Early stages of this form of emphysema are reversible provided the obstruction has not been in existence to the extent that the integrity of the alveolar wall or its elasticity is permanently impaired

In obstructive emphysema large bullae *(giant air cysts—pneumatoceles) may form* One of the mechanisms responsible for the development of these bullae is a chronic organ*izing constrictive bronchiolitis or peribron*chiolitis which stiffens the walls and narrows the lumens of the bronchioles [14] In those instances in *which the muscular and elastic* tissues are damaged and replaced the mechanism which normally regulates the tone of the wall and the caliber of the tube *is impaired or* destroyed The total effect is an abnormal narrowing of the bronchioles While inspiratory expansion of the contiguous parenchyma *would* partly open these to permit the passage of air unusual inspiratory force would be required because of the constricting lesions In the succeeding expiration the caliber of the bronchioles would be reduced below normal partly because of the constricting *lesions and* partly because of the loss of the masculo-elastic tonus This would delay the emptying of pulmonary lobules which in consequence *would be distended As the chronic* constrictive process increases during months or years the functional effect would be aggravated *and as* the distention of the alveolar tissue increases and the expiratory deflation becomes further retarded the distended lobules *occupying* increasing space would tend during expiration to exert pressure against the walls of the enclosed bronchioles and possibly to stretch them In this way a vicious circle is set up until eventually the bronchiole structurally and functionally becomes quite *insufficient* especially during expiration thus operating as a check valve The chronically distended
d oxygen
es
ty

of the constrictive bronchiolar lesions account in a large measure for the multiplicity of bullae The presence of tenacious mucus in the bronchial passages might aggravate the mechanisms described The origin of these chronic bronchiolar lesions is speculative but many of these individuals give a history of chronic bronchial catarrh At any rate, once these bullae develop, they extend to the point where they may rupture, with the formation of spontaneous pneumothorax, or else as they enlarge, they may compress and embarrass adjacent areas of lung parenchyma At time of rupture the tension of a pleural fibrous adhesion may prevent the bronchopleural fistulas from closing and permit the pneumothorax to continue If a large blood vessel is in an adhesion which may be torn in the sudden collapse of the lung, serious bleeding may take place

Spontaneous pneumothorax associated with rupture of emphysematous bullae is usually not associated with infection in the pleural space unless an underlying pneumonitis is present at the time of rupture This is in contrast to spontaneous pneumothorax which in previous years was frequent in pulmonary tuberculosis Spontaneous pneumothorax associated with tuberculosis is either secondary to the rupture of a bulla (emphysema secondary to the fibrosis of tuberculosis) or is the result of a perforation of a tuberculous cavity or necrotic parenchymal focus into a non obliterated pleural space The pleural space is almost always infected in spontaneous pneumothorax associated with tuberculosis

Bullae are devoid of any epithelial lining and the inner surface consists of compressed alveolar walls and perhaps some granulation tissue There may be more than one opening of the bronchial tree but these are not easily discernible On occasion these bullae may become infected during the course of pneumonia and simulate lung abscesses, bronchiectatic abscess cavities or infected developmental bronchogenic cysts On occasion following infection a bulla disappears entirely as a result of obliteration of all its bronchial communications so that the absorption of gas without any access to new air causes it to obliterate Occasionally a bulla may rupture interstitially with the dissection of gas into the tissue spaces of the lung This is called interstitial emphysema Although many use the term "bulla" and "bleb" interchangeably their original conception and pathogenesis are entirely different The bulla as has been described previously, is the result of dilatation, degeneration and destruction of alveolar walls with large air sacs present within the pulmonary parenchyma (intra alveolar distention) A bleb however is produced by direct trauma to the lung or from the rupture of a bulla with dissection of the gas into the interstitial tissue planes It may then appear within the layers of the pleura and protrude as a blister on the surface of the lung

Recent studies indicate there is an increase in the amount of muscle in the small bronchioles and alveolar ducts in emphysema The relationship of this to bronchospasm, an important factor in this disease, is considerable There is also an increase in the bronchial pulmonary venous collateral circulation in emphysematous lungs The significance of this regarding the further progression of the condition and its relationship to the impairment of cardiorespiratory function await further study

Diffuse obstructive emphysema is of major concern to the surgeon because it is a vital factor in evaluating the pulmonary reserve of the patient There are two problems involved first, the amount of anatomic distention emphysema which will follow removal of considerable portions of the lung and, secondly, the amount of obstructive emphysema already present in the remaining lung Advanced stages of diffuse obstructive emphysema lead to marked ventilatory impairment, pulmonary hypertension and cor pulmonale

REFERENCES

1 ISELIN H and SUTER F The role of perforation of hilar lymph nodes into the bronchial tree of [illegible]

bronchogenic tuberculosis *Am Rev Tuberc* 67 440 1953

4 MEDLAR E M Pathogenetic concepts of tubercu [illegible]

5 W [illegible]

1951

6 AUERBACH O and KATZ H L The effect of streptomycin therapy on the bronchocavitary junction and its relation to cavity healing *Tr Nat Tuberc A* 217 1952

7 STEENKEN W WOLINSKY E PRATT S P and

COSTIGAN, W J Effect of antibacterial agents on chronic pulmonary tuberculosis in rabbits *Tr Nat Tuberc A*, 218, 1953

8 SPAIN, S M Unpublished data

9 ERB, I H Pathology of bronchiectasis *Arch Path*, 15 357, 1933

10 SPAIN, D M and LESTER, C W Time element in the development of irreversible bronchiectasis *J Pediat*, 32 415, 1948

11. LIEBOW, A A, HALES, M R and LINDSKOG, G E Enlargement of the bronchial arteries and their anastomoses with the pulmonary arteries in bronchiectasis *Am J Path*, 25 211, 1949

12 ROTHSTEIN, E Infected emphysematous bullae *Am Rev Tuberc*, 69 287, 1954

13 SPAIN, D M Acute non aeration of the lungs—edema versus atelectasis *Dis of Chest*, in press.

14 SPAIN, D M and KAUFMAN, G The basic lesion in chronic pulmonary emphysema. *Am Rev Tuberc*, 68 24, 1953

III. DIAGNOSIS

8

Diagnostic Methods

LOUIS L. FRIEDMAN, M.D., *Birmingham, Alabama*

From the Friedman Diagnostic Clinic, Birmingham, Alabama

THERE are certain clinical and laboratory procedures which, if applied intelligently, will help establish accurately and rapidly the correct diagnosis of bronchopulmonary disease (BPD). No effort will be made to evaluate the relative importance of the various procedures recommended. The value of any diagnostic procedure depends upon its timely utilization, correct interpretation and proper integration with the total clinical picture. During the past two decades encouraging progress has been made in the surgical and medical management of acute and chronic BPD. Through an intelligent and prompt utilization of new and perfected technics and measures, we are now able to offer favorable prognosis for survival and possible cure in many bronchopulmonary (BP) illnesses which were previously considered inevitably fatal, or which doomed a patient to chronic invalidism and eventual death. Unwarranted delay or actual failure to establish the correct diagnosis may deprive patients of the benefits of successful therapeutic intervention in remedial conditions. It is true, however, that on occasion even the most astute clinician is unable to solve some of the more difficult diagnostic problems following careful study. This situation is to be expected and excused. There is, however, no apology for ignorance of, or failure to utilize all existing and available clinical and laboratory diagnostic aids in conducting an investigation of a BP complaint.

DIAGNOSTIC METHODS

History and Physical Examination

Routine History. This should consist of the following: (1) chief complaint, (2) history of present illness, (3) system review, (4) past history, (5) family history, (6) marital history, (7) social history. Logical investigation of each case should begin with a brief, clear statement of the patient's chief complaint followed by a detailed and accurate history obtained in a friendly and leisurely manner in the sequence outlined. The final recorded history should be an integrated, simple word-picture of the information supplied spontaneously by the patient and to which has been added the examiner's objective observations. Each symptom requires careful evaluation. The differential characteristics of those which are especially referable to the lungs deserve painstaking study and correlated interpretation. Particular emphasis should be placed on such symptoms and observations as cough, sputum, hemoptysis, dyspnea, orthopnea, wheezing, cyanosis, pain in the chest, hoarseness, fever, chills, loss of weight, nature of onset and progress of the illness, seasonal, diurnal, climatic and geographic variations, relation to previous illness and method of obtaining relief. These symptoms and observations when present require careful quantitative and qualitative evaluation of their characteristics so that each may be assigned its relative significance. For example, the symptom of cough will have no significant value unless analyzed carefully and its special characteristics assessed properly. The differential characteristics of each symptom and observation should be evaluated with diligence. In this manner the correct diagnosis may be suspected, or established, while the integrated history of the present illness is being recorded. The history of the present illness should not be recorded in final form until the physician has conducted a detailed system review. This practice provides an opportunity for the examiner to seek the answers to questions which may develop additional pertinent facts or re-emphasize the significance of previously obtained information. The patient's negative or affirmative reply to a simple routine question in the

system review, which on the surface seems entirely unrelated to the respiratory organs may frequently supply the clue in a difficult diagnostic problem

Frequently the existence of acute or chronic BPD masquerades behind a curtain of bizarre symptoms In these circumstances the most experienced examiner may be misled and remain ignorant of the true nature of the disease even after the history of the present illness and system review have been elicited This information may be clarified or the correct diagnosis suspected while obtaining the past history Pulmonary tuberculosis bronchiectasis and other chronic BP diseases such as fungus infections may be suggested by a past history of recurrent or frequent pleurisy atypical pneumonia periodic loss of weight and energy without obvious reasons recurrent bouts of fever and night sweats of undetermined origin The recent history of an operative procedure such as a tonsillectomy tooth extraction or any infection of the mouth tonsils nasal or oral pharynx may focus attention on the possibility of a lung abscess A history of amebic dysentery in the past may actually suggest the etiologic agent responsible for the abscess Pulmonary embolism infarction and metastatic abscesses may be suspected if the examiner obtains a

complicated in its convalescent stage by pneumonia or a prolonged cough should invite consideration of bronchiectasis as a diagnostic possibility Pulmonary abscess bronchiectasis and chronic pneumonitis should be considered when one elicits a history of esophageal stricture carcinoma cardiospasm chronic alcoholism general debility recent general anesthesia or coma History of the prolonged use of oily nose drops and oily cathartics requires the inclusion of lipoid pneumonia in the differential diagnosis Recent intense radiation therapy of a lesion in the region of the thorax should lead one to suspect radiation pneumonitis This complication is especially frequent following roentgen ray therapy for carcinoma of the breast History of chronic renal failure should invite consideration of uremic pneumonitis These are but a few examples of the obvious value of a carefully obtained past history

The strictly personal elements in a patient s history frequently acquire added significance when interpreted in the light of the family and marital history This is especially true of contagious diseases such as pneumonia and tuberculosis or when a hereditary tendency is uncovered to support the possible diagnosis of asthma or cancer In obtaining the family history the examiner should not accept unequivocally the patient s diagnosis of familial illnesses He should attempt to confirm all diagnoses supplied by the patient especially those which may influence his ultimate decision This objective may be attained by ascertaining and evaluating the signs and symptoms personally or by obtaining the information directly from the physician who established the diagnosis in question Unless extreme caution is exercised in this respect many serious errors will be committed Investigation of every diagnosis in this fashion will prove many to be misleading and still others to be completely erroneous Similarly patients frequently attempt to conceal confirmed diagnoses in order to avoid what they consider a social onus This is especially true of pulmonary tuberculosis

Finally the examiner should obtain the patient s social history Such diseases as silicosis asbestosis byssinosis pneumoconiosis of soft coal workers bagassosis Shaver s disease diatomaceous earth pneumoconiosis and arc welder s disease may be suspected from the patient s occupational history Geographic location may necessitate consideration of coccidioidomycosis, histoplasmosis echinococcal disease and other less common conditions Psittacosis should be included in the differential diagnosis of patients exposed to members of the parrot family pigeons and other fowl known to harbor the responsible virus In general all personal habits which may be of significance in the final evaluation of the case should be noted carefully

An orderly correlated history obtained in this fashion will suggest the diagnosis in many instances before the physical examination or any other procedures are completed In a substantial number of cases however the examiner will be distressed at the apparent lack of assistance gained from even the most assiduously recorded history No matter how often this unfortunate situation occurs the physician must never consciously lower the recognized standards of a satisfactory history

As it so often happens the first manifestation of carelessness will be rewarded by a missed diagnosis Those of us who have experienced this misfortune will never again be satisfied with an abbreviated record of a patient s illness The apparent bonanzas of diagnostic short cuts have a notorious habit of backfiring at the wrong time to the complete embarrassment of the would be beneficiaries and to the detriment of the unfortunate patient Th s latter observa tion applies with equal significance to all elements of the patient s examination history physical and laboratory The physician not the clerical helper or nurse should obtain the history

Physical Examination Physical examina tion of the patient suspected of suffering from BPD must be performed in each case No matter how incontrovertibly the evidence in the patient s history points to a specific BPD omission of the slightest detail in the physical examination is fraught with danger In gen eral the physical findings will confirm or disprove the impressions gained from the patient s clinical history Quite often a routine examination will reveal significant physical findings in an organ or organs other than the one to which the history has directed the examiner s attention Imagine the physician s surprise when a disease process is located in the left lower lobe of the lung of a patient com plaining of anorexia nausea vomiting and epigastric pain In this and similar circum stances the examiner will find it necessary to supplement the original history with new and added information obtained by re interroga tion of the patient A majority of diseases involving the lung are localized to that organ but a signif cant minority are merely reflections of a remote or systemic disorder This very fact again emphasizes the necessity of a complete phys cal examination even in those instances which do not appear to warrant detailed study D scovery of phlebothrombosis or thrombo phlebitis in an extremity will establish an etiologic background for pulmonary embolism or infarction It will also facilitate the institu tion of proper prophylactic measures to avoid further possibly fatal accidents Dependent edema venous engorgement and tender hepatic enlargement will incriminate the heart as the responsible organ rather than the lungs in a patient complaining of cough blood tinged sputum and dyspnea Observations obtained by physical examination in such instances facilitate evaluation and correlation of the clinical history A distant lymph node draining sinus a skin lesion or an enlarged prostate may be significant when examined histopathologically or bacteriologically Club bing of the fingers and toes may lead to a sus picion and subsequent confirmation of existing BPD

Clinical and Laboratory Aids

When the history and physical examination are complete and correlated the diagnosis is often apparent There are however a signifi cant number of BP diseases which can be diagnosed only with the assistance of routine and highly specialized clinical and laboratory diagnostic procedures Familiarity with all of these procedures is an essential part of the armamentarium of those physicians specializ ing in diseases of the chest These methods however should be equally familiar to all engaged in the practice of medicine and its various specialties Knowledge of these pro cedures will enable the physician to establish a diagnosis with greater frequency rapidity and accuracy Additionally realization of his own limitations will prompt him to offer the patient the advantages of more specialized consulta tion study if indicated In general all of the following diagnostic measures should be con sidered as secondary aids to be utilized only after a complete history has been obtained and a thorough physical examination has been performed

Hematologic Studies Hematologic studies are frequently of assistance but are rarely of significance in diagnosing BPD A normal red count or one manifesting some degree of anemia is of no particular importance Poly cythemia on the other hand is a significant laboratory finding since it may be responsible for BPD which was not suspected before examination of the blood Erythrocytosis when associated with pulmonary disease usually signifies chronic oxygen lack It may accompany such clinical entities as Ayerza s disease emphysema far advanced cystic disease or any other condition interfering with adequate oxygenation of the red cells Erythro cytosis is a rather constant finding in pulmo nary hemangioma (arteriovenous fistula) Ery thremia or polycythemia vera is commonly accompanied by pulmonary signs and symp-

toms The total white blood count and differential characteristics are useful in determining the existence and type of infection For example, one may expect a normal total white blood count with primary atypical pneumonia of undetermined etiology A definite leukocytosis, however, with a left shift is typical of pneumococcic pneumonia The total white blood count and differential generally contribute only limited assistance in helping to establish specific diagnoses in BPD It is true, nevertheless, that the finding of an eosinophilia may be the first clue in such diseases as Loeffler's syndrome, Hodgkin's disease or echinococcal disease involving the lungs Some degree of eosinophilia has been reported in silicosis, but the author does not believe that the total white blood count or differential is of particular diagnostic significance in this disease entity or in tuberculosis When leukemic processes involve the pulmonary tissue, the total white blood count and differential are helpful Aside from Hodgkin's disease, a study of the white blood cells does not contribute much to the diagnosis or evaluation of the other lymphomas Although it is true that the routine hematologic study of a patient is not commonly decisive in the ultimate evaluation and diagnosis of BPD, it should never be omitted It may occasionally be helpful and practically diagnostic Also, it should be remembered that a rising or falling total white blood count and a shifting Schilling hemogram have the same prognostic value in BP infections as they do in other infectious diseases

Examination of the Urine Although the author does not recall a single instance of BPD in which this examination was diagnostic, it should, nevertheless, continue to be a routine laboratory procedure because of its value in considering the differential diagnosis Renal tumors may be suspected from an association of hematuria and pulmonary metastases

Stool Examination In Loeffler's syndrome the discovery of Strongyloides stercoralis, Ascaris lumbricoides, Necator americanus or other ova in the stool is of great assistance When Endamoeba histolytica cysts or trophozoites are found in the feces, the etiology of a lung abscess may be suspected and subsequently proved These are but a few examples in which examination of the stool for parasites may yield important diagnostic information The detection of occult blood in the stool may reveal the source of pulmonary metastasis

Serologic Test for Syphilis Rarely is this test of any diagnostic significance in BPD

Sputum Examination This is one of the most reliable and important procedures and should be utilized routinely in every case of undiagnosed BPD Suitable specimens for examination may be obtained from ordinary expectorated material When the amount of sputum raised is insufficient or unsatisfactory, material for examination may be obtained by pulmonary lavage or bronchoscopic aspiration of the trachea and accessible bronchi Micro- [illegible] stained

results if strong clinical evidence [illegible] incriminates the lungs and points to a certain disease Repeated careful examinations are mandatory when tuberculosis is suspected A concentrated twenty-four hour sputum speci- [illegible] the procedure of choice The type of [illegible] the organism, then the spu[illegible] Fresh unstained [illegible] attempting [illegible] histolytica

An unstained specimen [illegible] ith either a 10 per cent solution of potassium hydroxide or sodium hydroxide is also the procedure of choice when a fungus infection is being considered When echinococcal disease of the lungs is suspected, the diagnosis may be established by identification of the hooklets or membrane of the cyst in a properly stained specimen Since the advent of effective antibiotic therapy, sputum typing is no longer as important as previously in lobar or bronchopneumonia

If sputum examination would end with a search for the responsible pathogenic microorganism, it would be incomplete The gross and other stained and unstained microscopic characteristics of the BP excreta must be studied in order to secure the maximum diagnostic benefits from this source Identification of fat globules will in itself confirm or suggest the diagnosis of lipoid pneumonia Loeffler's syndrome or asthma may be suspected when the predominating cellular elements are eosino-

phils Identification of elastic fibrils and Charcot Leyden crystals make the latter possibility more probable The recognition of larvae of A lumbricoides indicates an ascaris pneumonitis If bronchogenic carcinoma is suspected, properly prepared specimens should be examined for cancer cells

The gross characteristics of the sputum must be studied carefully as this part of the examination frequently suggests the diagnosis For example, a frothy, rust colored sputum, with or without bloodstreaking invites a diagnosis of pulmonary edema while a three-layered sputum is suggestive of bronchiectasis Pulmonary tuberculosis, bronchiectasis and neoplasm are among the diagnoses to be considered in the presence of varying degrees of hemoptysis Foul smelling sputum should make one suspect lung abscess or bronchiectasis Prune juice-colored expectoration may signify lobar pneumonia while amebic abscess of the lung may be characterized by sputum with the appearance of anchovy sauce When the gross characteristics of the sputum are similar to fluid obtained by thoracentesis, a broncho pleural fistula is likely Accidental discovery of a broncholith may be the answer to a difficult diagnostic problem Characteristic sulfur granules mean actinomycosis while the presence of Curschmann's spirals and Laennec's pearls are suggestive of asthma Determination of the twenty-four hour sputum volume is very helpful in suspected cases of bronchiectasis, lmonary abscess and bronchopleural fistula

Gastric Contents This method of study ould be employed whenever the bacteriologic sults of sputum examination by stain and ulture for the tubercle bacillus are consistently egative while all clinical evidence, nevertheess, is to the contrary It is frequently the only method of establishing the diagnosis The results of guinea pig inoculation will decide the significance of acid fast bacilli recovered from gastric washings Pathogenicity of the organism may be determined in this fashion Examination of fasting gastric contents is especially valuable in attempting to establish a diagnosis of pulmonary tuberculosis in the aged, the debilitated and in very young children

Blood Cultures Early in the course of lobar or bronchopneumonia, and before a chemotherapeutic or antibiotic agent has been employed, the blood culture may be positive Isolation of the responsible organism in the blood stream is confirmatory but not diagnostic Blood cultures are generally of limited value in the diagnosis of BPD The results of this study, however, influences the prognosis

Skin Tests In many obscure BP conditions the diagnosis may be suggested by the nature of the patient's response to a measured, minute skin test dose of antigen obtained from a specific microorganism This test is especially valuable in such diseases as tuberculosis, coccidioidomycosis, blastomycosis, histoplasmosis and other fungus diseases In some instances a negative result, however, is of far more clinical significance than a positive reaction Physicians should be thoroughly familiar with the correct technic of performing the test and the criteria for proper interpretation When echinococcal disease of the lungs is suspected, Casoni's intradermal test is specific All asthmatics should be tested for possible allergic response to suspicious antigens both for diagnostic purposes and therapeutic potentialities

Sedimentation Rate For many years this determination has been practically a routine procedure in the study of some chronic pulmonary diseases Its popularity far exceeds its diagnostic value, but may be attributed to its questionable prognostic significance and ease of accomplishment It is a non-specific laboratory test of limited value which should be interpreted only in the light of the total clinical and laboratory picture

Precipitin and Complement fixation Tests These procedures are valuable in the diagnosis of virus and fungus diseases When significant positive results are obtained, they may be considered diagnostic In some instances, as for example in blastomycosis and coccidioidomycosis, a rising or falling titer is of prognostic as well as diagnostic value

Roentgenologic Examination No examination of the lungs is complete without roentgenologic study of the chest An erect, postero-anterior view should be a routine procedure for all patients suspected of having BPD A good lateral view of the chest may be as important as the postero-anterior examination In some clinics it is a routine procedure Frequently lesions are recognized on the lateral view which are not even suspected after the most careful interpretation of the postero-anterior film Economic considerations permitting, and if time, equipment and personnel are available, the lateral view should be routine

in the diagnosis of BPD Roentgenologic examination of the lungs is unquestionably one of the most valuable of all diagnostic procedures but under no circumstances should it be considered a substitute for the routine history and physical examination The value of a chest roentgenogram may be realized only if its significance is made contingent on the history, physical examination and other clinical and laboratory procedures Although roentgenographic examination of the chest is of tremendous importance in the diagnosis of BPD, it may be overemphasized By itself it is rarely diagnostic Generally, a chest roentgenogram underestimates the amount and extent of actual pulmonary disorder It does, however, permit early detection of silent and unsuspected lesions and is essential for careful follow-up examination Therein lies its greatest contribution to the study of BPD Serial roentgenograms are excellent prognostic guides On occasion, the results of physical examination of the lungs are more informative than the roentgenogram More frequently, however, the roentgenogram will reveal a BP lesion even after the most competent diagnostician has rendered a negative opinion based on physical examination This unfortunate shortcoming of physical diagnosis in the recognition of BPD may be overcome through increased utilization of routine roentgenographic examination of the lungs

Fluoroscopy This study of the lungs is very valuable in determining mobility and other dynamic features of the chest during various phases of respiration

Examination of Pleural Fluid and Gases Whenever the presence of a pleural effusion is confirmed, a specimen must be obtained for diagnostic purposes as soon as possible. Unless specifically indicated, air should not be introduced into the pleural cavity during or following diagnostic aspiration Part of the fluid obtained should be consigned for bacteriologic examination If a specific diagnosis is suspected, special stains cultures and other bacteriologic studies should be ordered For example if one suspects a tuberculous effusion, then a guinea pig inoculation is indicated Fluid which has developed synpneumonically, or metapneumonically, should be examined for pneumococci If one suspects a malignancy, part of the specimen should be examined histopathologically for neoplastic elements The type of leukocyte, if present, can be determined from a stained smear while searching for pathogenic bacteria In this way the inflammatory nature of an effusion may be detected Sufficient fluid should be obtained to determine the specific gravity or protein content These examinations are valuable in differentiating an exudate from a transudate Before withdrawing the aspirating needle, 10 cc of 1 per cent methylene blue, or some other suitable dye may be instilled if a bronchopleural fistula is suspected In the presence of this complication the sputum will have a bluish discoloration within twelve to twenty four hours, or sooner following injection This is a very valuable diagnostic aid which offers incontrovertible evidence when positive Where facilities for gas analyses are available, the existence of a bronchopleural fistula may be suggested by determination of the carbon dioxide and oxygen content of gas obtained from the pleural cavity This time-consuming procedure is usually unnecessary and merely of academic interest

Macroscopic examination of the fluid obtained by thoracentesis is not a very reliable procedure, but odor, viscosity and color may suggest certain diagnostic possibilities and additional methods of study For example, a pale straw colored fluid obtained from the right hemithorax may suggest congestive failure with hydrothorax Milky, thin fluid invites a diagnosis of chylothorax which may be confirmed by staining with Sudan III and chemical analysis of its fat content A blood tinged, or frankly bloody fluid suggests pulmonary infarction trauma, congestive heart failure, tuberculosis, pulmonary or pleural neoplasm and other possibilities Foul smelling fluid may suggest an anaerobic infection or a colon bacillus From this brief discussion the diagnostic importance of fluid in the pleural cavity should be obvious The examiner must be prepared to obtain every possible assistance from the complete investigation of this easily available pathologic material

Endoscopic Studies Bronchoscopy is not employed with sufficient frequency in the diagnosis of BPD Yet, it affords the clinician a possible opportunity to visualize the lesion directly Material for bacteriologic and histopathologic examination may be obtained in this manner The appearance of some lesions is almost diagnostic In any unexplained BPD this examination should be performed without procrastination as it is relatively harmless The physician should not hesitate to submit his

patient to this examination for the expected benefits are far more numerous than the possible dangers Bronchoscopic examination should be considered in all cases of obscure and atypical BP lesions In this way more cases of BP cancer will be discovered in an operable and possibly remedial stage

Esophagoscopy may be a very valuable procedure in differentiating between esophageal disease and BPD Frequently esophageal disease is discovered to account for secondary BP complications as in stricture and carcinoma of the esophagus or cardiospasm

Bronchography The introduction of a radiopaque substance into the tracheobronchial tree is a simple usually safe and valuable diagnostic procedure A history of sensitivity to iodine however precludes its use It is of unparalleled value in patients suspected of having bronchiectasis and may also be employed to demonstrate bronchial occlusions cystic disease and pulmonary cavitation The method of choice in carrying out this examination is one of individual preference Following instillation of a suitable radiopaque solution into the tracheobronchial tree immediate fluoroscopic and indicated roentgenographic examination should be performed

Miscellaneous Uses of Radiopaque Material When a sinus tract appears to communicate with the lung or the pleural cavity a radiopaque solution may be used to outline the tract and to localize the communication In positive instances the radiopaque material can be demonstrated in the lungs fluoroscopically and roentgenologically This procedure is especially useful in thoraco abdominal actinomycosis with sinus tracts

Biopsy of Lesion for Histopathologic and Bacteriologic Study When a diagnosis cannot be established by sputum examinations or other simple laboratory techniques biopsy of available pathologic material may be performed The tissue should then be examined by the proper histopathologic and bacteriologic methods Material for biopsy may be obtained from the local pulmonic lesion or from other sites if the BPD is part of a systemic illness Suitable specimens may be obtained bronchoscopically Bronchial adenomas have a tendency to bleed freely following biopsy This is only a minor complication and should not be considered a contraindication to the procedure The bronchoscopist must be well trained before securing the biopsy specimen and is required before the operative procedure is undertaken to determine carefully the possible existence of a thoracic aneurysm Accidental biopsy of the aorta or other great vessels may be a rather embarrassing complication When material for biopsy is bronchoscopically inaccessible the author has unhesitatingly performed innumerable punch biopsies of pulmonary lesions situated at respectable distances from vital structures If a Vim Silverman biopsy needle is used sufficient material of diagnostic quality may be obtained without any more serious sequelae than transient blood spitting The advisability of punch biopsy in suspected malignancies nevertheless remains controversial Aspiration biopsy is not as satisfactory since material obtained in this fashion is usually insufficient for adequate histopathologic examination although it is quite frequently suitable for bacteriologic study Material for study may also be obtained by means of a transthoracic lung biopsy utilizing an intercostal approach It is a relatively simple technical procedure The surgical risk is minimal while the information obtained from this study is usually reliable and definitive When pulmonary tissue is not available for histopathologic or bacteriologic examination or has been found non diagnostic other accessible sites should be considered In such instances one may conceivably establish the diagnosis from a lymph node skin lesion draining sinus or from any other suitable site If it appears that the pulmonary disease represents a metastatic lesion biopsy of the original focus is preferable Suspected leukemic infiltrations of the lung may be confirmed by aspiration or biopsy of the sternal bone marrow in addition to examination of the peripheral blood When the possibility of a fungus infection is being considered a Hotchkiss McManus stain should be used Histopathologic and bacteriologic examination of tissue obtained by biopsy is a reliable method of establishing an etiologic diagnosis quickly and irrefutably

Diagnostic Pneumothorax and Pneumoperitoneum Pneumothorax is an excellent method of distinguishing between pulmonary and extrapulmonary lesions Pneumoperitoneum has little place in the diagnosis of BPD unless diagnostic pneumothorax fails to reveal the exact location of a lesion in the region of the diaphragm

Thoracoscopic Examination After a diagnostic pneumothorax has been established

it is a relatively minor surgical procedure to examine the contents of the pleural cavity with the thoracoscope This sometimes permits direct visualization of the lesion for purposes of surgical evaluation and diagnosis Biopsy specimens may be obtained in this manner for histopathologic and bacteriologic examination

Electrocardiogram This procedure has only limited value in the diagnosis of BP diseases As in the case of cor pulmonale it may reflect cardiac and pericardial complications secondary to the BPD If the investigation however has been conducted correctly and in logical sequence the information obtained from the electrocardiogram will be of confirmatory rather than diagnostic importance When the differential diagnosis rests between pulmonary embolism and coronary occlusion however, it is diagnostic Low voltage in the presence of massive pleural effusion is only of academic interest

Venous Pressure and Circulation Time Venous pressure and circulation time determinations are of definite value in helping to differentiate between cardiac disease and BPD In the presence of cardiac failure the venous pressure is elevated commonly This is not usually the case in BPD On occasion primary or metastatic tumors in the thorax will obstruct the venous return from one part of the body or another but not symmetrically as one would expect in cardiac decompensation This latter observation together with other available evidence, such as collateral circulation will usually decide the issue

Determination of the circulation time in BPD is of questionable value In chronic fibrotic diseases of the lung associated with dyspnea the circulation time is frequently accelerated A prolonged circulation time is a [illegible]

after all available diagnostic procedures have been utilized then a test dose of deep roentgen ray therapy is indicated Response to this form [illegible] lymphoblastomas [illegible] possibilities [illegible] enous or in tracardiac injection of a radiopaque substance will frequently differentiate vascular tumors of the thorax from other pulmonary lesions It may also be used to help outline non vascular tumors The diagnosis of pulmonary arteriovenous fistula can be established by this examination It is not without danger, however, and requires highly trained technical assistance and rather involved apparatus Therefore it is not recommended as a routine procedure Iodine sensitivity must be considered as in bronchography

Exploratory Thoracotomy If all other examinations are non diagnostic the physician is justified in recommending exploratory thoracotomy in properly selected cases When BP malignancy is suspected exploratory thoracotomy should not be delayed In the hands of a competent thoracic surgeon this procedure carries no greater risk than an exploratory laparotomy and may eventuate in a cure

Physiologic Studies of Pulmonary Function Pulmonary function studies in general have little diagnostic value in the study of BPD However indicated studies to determine pulmonary ventilation and diffusion are important in evaluating the functional status of the lungs Cardiac and pulmonary catheterization have diagnostic and prognostic value

Radioactive Isotopes Administration of radioactive iodine may be used to confirm the existence of pulmonary metastases from carcinoma of the thyroid To date there is no record of other radioactive substances being used in the diagnosis of BPD

COMMENTS

Some BP diseases may be encountered which will require the supplementary utilization of other indicated and highly specialized procedures in order to establish the correct diagnosis For example gastroscopic examination determination of the alkaline phosphatase blood level or a retrograde pyelogram may be necessary in some instances

As a rule orderly investigation and intelligent utilization correct interpretation and careful selection of indicated clinical and laboratory procedures enumerated herein will be rewarded by a prompt and accurate diagnosis of existing BPD

To render a patient the best possible service the physician must be thoroughly familiar with and willing to practice the proper and acceptable methods of orderly investigation Sincere cooperation between the internist surgeon radiologist pathologist and possibly other specialists is also imperative in the diagnosis of BPD

9

Bacterial Examination of Sputum

I D Bobrowitz, M D, *New York, New York*

In the diagnosis and treatment of pulmonary disease the clinical roentgenologic and bacteriologic findings must be considered and correlated All of these methods are important with the sputum examination of decisive significance in the management of pulmonary disease In this discussion the first section will be devoted to sputum findings in chronic pulmonary tuberculosis and non tuberculous pulmonary conditions will then be reviewed

CHRONIC PULMONARY TUBERCULOSIS

Tubercle bacilli in the sputum has important diagnostic therapeutic and prognostic implications The absolute diagnosis in cases of pulmonary infiltration of undetermined etiology, the evaluation of the activity or clinical significance of known tuberculous lesions the indications for treatment and appraisal of the effectiveness of the therapeutic measures are all related to the bacteriologic findings

In the search for tubercle bacilli the method of examination can vary Included in the different means of diagnosis are the direct smear concentration culture and guinea pig inoculation The daily output of tubercle bacilli will determine the sensitiveness of these bacteriologic methods The ascending order of sensitivity in the detection of tuberculosis is as follows —the direct smear concentration of sputum or fasting gastric contents culture of sputum or gastric contents and guinea pig inoculation

METHOD OF FINDING TUBERCLE BACILLI

In practice [redacted] one method proves negative the next more sensitive test is done to find the tubercle bacilli The direct smear is of little value except as an immediate indication if positive that there is a very high output of bacilli and heavily infected sputum Routinely all of our sputum specimens are concentrated for this will reveal many more bacilli than a direct smear If the concentrates are negative or there is little or no expectoration (or an unsatisfactory specimen—nasopharyngeal material) fasting gastric contents are examined The yield of positive results from examination of gastric concentrates is small and under 5 per cent and therefore, except for special cases all of our gastric specimens are routinely cultured With good culture technic even a few bacilli will be demonstrated If gastric and sputum cultures are negative the final (and most conclusive) method of finding tubercle bacilli would be by guinea pig inoculation

The incidence of positive sputum reports will vary directly with the time used for the collection of the sputum The longer the interval for accumulation of sputum the higher the number of positives The routine collection is for a forty eight hour period and in special circumstances three or four days and sometimes more are allowed

When the specimen is being collected all expectoration must be included irrespective of its appearance The patient should be advised to expectorate and not swallow sputum There is no characteristic gross appearance to differentiate the sputum in tuberculosis from other pulmonary conditions Mucopurulent secretions are most common but a sputum that is mucoid or bloody may also be positive Even in the presence of frank hemoptysis the sputum specimen can be positive for tubercle bacilli Tuberculous cavitation is usually associated with a heavy purulent sputum and tubercle bacilli should be found readily in it A purulent sputum persistently negative has a non tuberculous etiology which must be determined Non tuberculous cavitation can be caused by a pulmonary abscess bronchiectatic abscess fungus disease, infected cyst and necrotic neoplasm or infarct

There is natural variation in the number of bacilli expectorated and they are not constantly present in every specimen It is therefore very important in diagnosis to have repeated sputum examinations over a period of

time A valid conclusion about the presence of tuberculosis cannot be made from one or a few negative specimens (smear, concentrate or culture) However, it is usual in active cases of tuberculosis for the sputum examinations to be positive within a short period of time with early diagnosis possible On rare occasion after many negative concentrates and cultures and even months of observation, a single culture

instances bronchoscopic aspiration may yield material positive for tuberculosis In cases of questionable diagnosis, other methods such as laryngeal swabs and tracheobronchial lavage have been used I have had no experience with these procedures Laryngeal swabs have been reported to be 72 per cent as effective as gastric aspiration for detecting tubercle bacilli in chest clinic patients

Not only is it important to have successive examinations of the sputum, but also it is essential to utilize all the different bacteriologic methods in order to have a reliable conclusion in diagnosing tuberculosis Analyzing any one method of sputum examination will show that with the use of only a single test, many cases are missed that are found positive as the tests are repeated Although sputum smears and concentrates will reveal a majority of those positive, without the use of gastric aspirations and cultures (and animal inoculations) about 30 to 40 per cent of positive cases would be undiagnosed In fact if all methods of examination are employed persistently, close to 100 per cent of cases of active pulmonary tuberculosis including those of minimal degree can be found positive

In comparative studies of guinea pig inoculations and cultures the value of each method and the advantages and disadvantages of their use in finding tubercle bacilli have been described An adequate amount of material (sediment) prepared properly is required for each test The more tubes of medium planted with each specimen, the more sensitive the results of the cultures In some laboratories two guinea pigs are used for each inoculation Cultures may be lost by contamination and animals may die from different causes before tuberculosis can be diagnosed Although cultures are kept for at least eight weeks from 85 to 90 per cent of those positive will show growth within three to five weeks Guinea pigs are kept six to eight weeks before examined for evidence of tuberculosis However, by tuberculin testing the animals (only tuberculin negative pigs are used) conversion from negative to positive may be noted within three weeks which is a very important diagnostic consideration The appearance of palpable lymph glands in the groin of the pig in about three or more weeks is also an early diagnostic sign Cultures are easy to do while a proper animal set-up requires larger facilities and greater handling cost Although the most sensitive method of finding tubercle bacilli is by guinea pig inoculation from a practical point of view, in expert hands, cultures are not much less efficient than animal inoculation In our hospital laboratory cultures are done routinely and guinea pig inoculation is used only on occasion in special cases for diagnosis and evaluation of therapy

VALUE OF GASTRIC ANALYSIS

The value of "gastrics" will depend on the method used to obtain the fasting gastric contents and the rapidity with which the material is examined It is most desirable to do the aspiration as soon as the patient has awakened To diminish stomach peristalsis, it is essential for the patient to have nothing by mouth and to rest as much as possible before the test. This will permit evacuation from the stomach of all swallowed sputum It is most important to have an immediate laboratory examination because with any delay the changes of finding tubercle bacilli will be diminished because of a substance in the stomach juices normally present which inhibits bacillary growth The exact nature of this inhibitive substance is not known although it has been considered to be the hydrochloric acid or the gastric lipase or pepsin in the presence of the acid In any case, if there is to be a delay in examination of the gastric contents then to maintain viable bacilli the specimen should be neutralized and kept refrigerated

IMPORTANCE OF POSITIVE CULTURES

The importance of positive cultures in the handling of pulmonary tuberculosis has not been a settled issue This matter has been the subject of special study and the main conclusions reached in this investigation will be presented In these patients all the concentrates were negative and only the cultures were

positive The significance of cultures is related to many factors (1) frequency of positive reports (2) type of pulmonary infiltration (3) roentgenologic changes in the tuberculosis (4) correlation with collapse procedures or surgical therapy

The incidence of roentgenologic modifications of any kind (improvement or progression) is related to the frequency of positive cultures Thus alteration of the tuberculous lesion is quite rarely associated with a single positive culture it occurs in a minority of patients with occasional positive reports and takes place in almost every case with a majority of positive cultures

Correlation of the frequency of positive cultures and prognosis is shown by follow up studies of patients discharged from the New York City Municipal Sanatorium Most unsatisfactory results with progression of the lesion rehospitalization or change from negative to positive sputum occur in patients with positive cultures compared to those with negative findings before discharge The highest breakdown rate is evident in patients with a majority of positive cultures compared to those with only an occasional or single positive report

Soft and cavitary pulmonary tuberculous lesions by their very nature will show much roentgenologic change These modifications are closely correlated with positive cultures In lesions of a fibroproductive nature there will often be no alteration with an occasional positive but progression can occur when the cultures are persistently positive

Regression or resolution of pulmonary tuberculosis can occur in the form of absorption of soft infiltrations closure of cavitation or an increase in fibrosis These changes can be associated with positive cultures Roentgenologic improvement of the tuberculosis indicates that the lesion is still unstable or active When the disease reaches a point of real stability however the cultures will become and remain negative

Progressive tuberculous changes with an increase in the extent of the lesion the appearance of cavitation or enlargement of preexisting cavities could be associated with positive cultures In patients with a majority of cultures positive the most frequent roentgen change was progression

The importance of positive cultures is emphasized not because of their appearance at the time of actual progression but particularly as they can antedate the roentgenologic findings by many weeks or even months This warning of impending change in the lesion is of special significance in patients with infiltration of soft or mixed nature equivocal cavitation or questionable progression Persistently positive cultures are as significant as positive sputum concentrates in evaluation of the tuberculous picture and therapeutic indications Positive cultures sometimes even antedate symptoms which may not appear until progression is evident

There is considerable value in the correlation of cultures with the collapse therapy and surgical procedures used in tuberculosis In the non resectional types of treatment (pneumothorax pneumoperitoneum or thoracoplasty) the cultures usually show a gradual conversion over a period of months until healing is established and then they remain negative In resectional surgery (segmental resection lobectomy or pneumonectomy) there is an immediate postoperative change (if adequate resection has been done) with conversion of positive to negative cultures In pneumothorax and thoracoplasty (less so in pneumoperitoneum) the infiltration is not easily visible and the cultures are an important indication of the effectiveness of therapy and help in evaluation of the tuberculosis With well established pneumothorax or pneumoperitoneum or after thoracoplasty the reappearance of positive cultures could mean the presence of reactivated tuberculosis in the operative or collapsed side or contralateral lung or they could precede the appearance of a new lesion or indicate premature re expansion of the collapsed lung In resectional cases the postoperative finding of positive cultures could indicate active residual disease in the operative side or contralateral lung or endobronchial tuberculosis or tuberculosis in the bronchial stump In other words if the treatment is successful the cultures become and continue negative

The entire question concerning cultures has been dealt with at length because they are of considerable importance in the management of tuberculosis and to judge prognosis and therapy on the basis of concentrates alone is injudicious Many roentgenologic changes can take place with only the cultures positive and all concentrates negative The sensitivity of

cultures ■ such that they are the final bacteriologic specimens to become negative and often the first to warn of active unstable tuberculosis The changes in the tuberculous lesion occur at a gradual or rapid pace and each positive culture is not necessarily associated at the same time with alteration in the infiltration but with the total positive reports resolution or progression will be evident With the use of cultures proper determination of the patient ■ status is therefore possible These bacteriologic findings must however be combined with clinical and roentgenologic data With careful observation repeated laboratory studies and serial roentgenograms proper handling of the patient can be accomplished

The utilization of cultures in management of tuberculosis is recommended by the National Tuberculosis Association [16] To classify a patient as inactive requires (besides stability of the lesion and lack of cavitation) the sputum to be negative not only by concentration but also by culture or animal inoculation during a period of at least six months

NON TUBERCULOUS BRONCHOPULMONARY INFECTIONS

The sputum examination is of vital importance in the diagnosis and treatment of the different bronchopulmonary diseases The sputum analysis should consist of (besides determination of gross characteristics) a Gram smear general culture and antibiotic sensitivity test The results from this work up are available in the usual infections within a period of twenty four hours With an accurate bacteriologic diagnosis and the antimicrobial agent of choice indicated proper treatment can be initiated without delay This plan ■ possible because of the availability of many antimicrobials and their known effectiveness in the various infections If antibiotic sensitivity tests are impractical or unavailable at least isolation of the predominant organisms in the sputum will permit appropriate treatment Sometimes patients are treated without sputum analysis with change from one antibiotic to another until the right one or combination of drugs proves effective A clinical trial of this kind may take time and the delay may be dangerous to the patient s ultimate recovery also the prolonged illness can entail economic hardships Moreover because of the possibility of resistance of the patient s organisms to one or more antimicrobials cross resistance and allergic sensitivity to the drugs serious infection with fungi or bacteria from alteration of the normal bacterial flora and gastrointestinal or other disturbances it is essential to keep the number of drugs to a minimum and to utilize the most effective agent when treatment ■ initiated

For good sputum results an adequate specimen collected properly is essential To eliminate mouth organisms [illegible]

permanganate or other antiseptic solution) The sputum container must be sterile and the patient instructed about raising fresh sputum from the chest and expectorating into the bottle The patient can furnish a specimen of sputum raised on awakening or early in the morning (when there ■ usually more expectoration) or the sputum can be obtained fresh during the physical examination In either case the sputum should be kept refrigerated until it can be examined Stasis of unrefrigerated sputum will yield secondary organisms putrefactive bacteria yeasts or fungi that may contaminate and ruin the culture and antibiotic sensitivity tests It is therefore advisable to have the bacteriologic examination done without delay There may be no sputum available in patients too young too sick too old or uncooperative or those with a dry cough In these circumstances tracheal swabs (or having the patient cough with a sterile applicator placed above the base of the tongue in line with the droplet spray from the larynx) can be a satisfactory way to obtain enough material for smear culture and antibiotic sensitivity tests

Pneumonias The sputum examination can reveal the exact etiologic cause in the various specific lobar pneumonias namely pneumococcic Friedlander s (Klebsiella) staphylococcic hemolytic streptococcic and influenzal With the proper antibiotic a specific effect is possible with full rapid control of the infection and prevention of complications such as chronic suppuration abscess or empyema In most pneumonias more than one antimicrobial ■ usable and there may be varying sensitivity of the organisms to the different drugs sputum culture and antibiotic sensitivity tests then provide direct answer for the most effective agent If these tests are not possible at least a

Gram smear will indicate the organism causing the pneumonia, and appropriate therapy will thereby be achievable The gross appearance of the sputum is not always characteristic in the different pneumonias and reliance should be placed on bacteriologic diagnosis With resolution of the pneumonia the sputum clears losing its rusty appearance and purulence until all expectoration is eliminated If there is progression of the disease or delayed resolution the sputum will continue or again increase in amount and may be rusty and purulent once more In any unresolved pneumonia it is most important to search for tubercle bacilli Friedlander s bacillus streptococci staphylococci anaerobes and fungi (also tumor cells) The sputum will also change in character and increase in amount if lung abscess forms

The sputum examination in primary atypical viral pneumonia reveals no predominating bacteria and the organisms present are those usually found in the upper respiratory tract The isolation of the virus from the sputum or blood stream is not an easy or practical procedure Complement fixation or serologic procedures and cold agglutinin tests have been used in diagnosis Secondary organisms of clinical significance can be present in the sputum and these would respond to therapy

Sputum analysis can be of help in the diagnosis of lipoid pneumonia (following the use of iodized oil or mineral oil) by showing the fat particles or droplets The sputum findings are important in evaluating the need of surgery as this condition often occurs in elderly patients and resembles carcinoma

Bronchopneumonia may be primary with no predisposing cause but more often is secondary as a complication of childhood infections (measles pertussis) chronic diseases (chronic bronchitis bronchiectasis) epidemics (respiratory infection and influenza) or occurs terminally in debilitated or senile patients Sputum examination can reveal many kinds of bacteria However one organism may predominate and sputum culture and antibiotic sensitivity tests are indicated so that proper antimicrobial therapy can be instituted

Lung Abscess The sputum examination is of significant importance in lung abscess Before the lesion drains there is little sputum and later there is considerable expectoration of characteristically foul pus With lung destruction the sputum shows small lung tissue fragments and elastic fibers Sputum analysis is also valuable in differential diagnosis to rule out tuberculosis fungus disease and neoplasms which can resemble lung abscess

Lung abscess can be putrid or non putrid and due to aerobic or anaerobic bacteria In any case usually more than one organism is involved The bacterial flora will depend on the etiologic factors involved in the abscess formation In abscess due to aspiration (anesthesia coma postoperative (tonsils teeth etc) the organisms especially anaerobes capable of putrid abscess formation are those usually inhabiting the mouth tonsils and nasal passages These include hemolytic streptococci spirochetes fus form bacilli vibrios and gram negative bacilli In non putrid aerobic infections the organisms include pneumococci staphylococci and streptococci In abscesses secondary to embolization the bacteria found in the sputum will depend on the source of the thrombus The postpneumonic abscesses are more often due to specific organisms such as Friedlander s bacillus type III pneumococcus staphylococcus or streptococcus Infections contiguous to the lungs (mediastinum esophagus subdiaphragmatic pleural) can be responsible for abscess formation with the particular organisms involved Lung abscess occurs in about 10 per cent of neoplasms due to bronchial obstruction and secondary infection With trauma to the lung infection can be brought in from the outside In the non specific abscesses a multitude of organisms are involved In these some bacteria which are ordinarily non pathogenic in combination or in symbiosis become virulent

In every lung abscess the sputum work up should include Gram smear aerobic and anaerobic cultures and antibiotic sensitivity test With this information the proper therapeutic regimen can be advised

Acute Bronchitis The sputum at first is clear and tenacious later abundant and mucopurulent finally mucoid and then stops entirely Bacteriologic examination will show mixed flora although there may be predominance of a particular organism

In acute laryngotracheobronchitis prompt treatment is necessary because of the marked toxemia edema of the larynx and subglottic areas and obstructive bronchial secretions The sputum most commonly shows Staphylococcus aureus or hemolytic streptococcus

although occasionally *Hemophilus influenzae* is found and even viral etiology has been considered

Chronic Bronchitis This is rarely a primary independent infection and is usually secondary to other conditions being associated with emphysema neoplasm bronchiectasis tuberculosis fungus disease cardiac decompensation etc *Chronic bronchitis* is particularly common in the aged and exacerbations are frequent during the winter months Because the pulmonary reserve is poor and any intercurrent infection can be fatal in some clinics antibiotic prophylaxis has been considered in the elderly to prevent the respiratory episodes The bronchitis is hazardous in emphysema as the purulent material narrows the bronchi and the poor tussive mechanism and lack of good bronchial drainage aggravate the diminished pulmonary function It is imperative to control and eliminate the bronchial infection as soon as possible The sputum examination (smear culture and antibiotic sensitivity test) will determine the choice of the most effective antimicrobial agent The antimicrobials are indicated even though the patient has no fever or evidence of acute illness

The sputum in chronic bronchitis will vary Between the intercurrent exacerbations it may be small in amount mucoid or mucopurulent With a new acute infection it will increase and be purulent greenish or even foul and occasionally blood streaked If the bronchitis is associated with cardiac decompensation (especially mitral stenosis) the sputum may be hemorrhagic and contain heart failure cells In putrid bronchitis the sputum will be fetid (like abscess) but microscopic examination will not show elastic fibers Bacteriologic examination will show a mixed flora of bacteria but there is usually a preponderance of one kind of organism

Bronchiectasis Bronchiectasis is related etiologically to bronchial obstruction and bronchial infection It follows pneumonia chronic bronchitis hilar lymph node obstruction foreign body aspiration atelectasis and infection with pleurisy and is associated with other pulmonary diseases such as tuberculosis tumor abscess and fungus infection

The sputum varies in amount depending on the severity of the bronchiectasis the presence of intercurrent infection and weather conditions Cough and expectoration are increased during acute infections cold damp weather and by postural drainage

The sputum will vary in type from mucopurulent to thick purulent and from light yellow to heavy greenish yellow It characteristically forms three layers on standing (bottom layer of pus and cellular debris middle layer of mucus and pus and a top frothy mucoid layer) This layering also occurs in lung abscess or

reveal a mixed flora of gram positive and gram negative organisms Sputum analysis is always advisable in bronchiectasis to rule out the

tests will indicate the antimicrobial agent to be used Such medical treatment is employed palliatively in patients ineligible for surgery or for preoperative preparation The definitive treatment in bronchiectasis is surgical removal of the involved area Specific antimicrobial agents will usually result in definite clinical improvement This amelioration may be only temporary Either recurrent or new infection takes place or the bacterial flora may change with other predominant strains of organisms apparent The sputum tests should therefore be repeated to guide proper therapy

Allergic Bronchial Disease The most important sputum finding in allergic bronchial disease is the presence of eosinophils The [illegible] and more than

re is usually characteristic sputum—thick tenacious greyish white mucoid material Bronchial infection is a common complication of asthma and the allergy may be associated with sensitivity to the bronchitis— infective asthma " If there is much secondary infection there will be considerable sputum of a mucopurulent or purulent character

Although the sputum will contain a mixed flora there is usually a predominant organism It is very important to do sputum studies with smear culture and antibiotic sensitivity tests so that the appropriate antimicrobial can be used from the beginning In this manner the bronchial infection can be cleared. Because of the hazard of drug sensitivity in these allergic

individuals a clinical trial with different antimicrobial agents is not desirable

Influenza This is of two types, the mild winter grippe epidemics and the severe pandemic infections In mild influenza the sputum has no unusual characteristics In the severe form there is an overwhelming virulent involvement of the lungs with a viral toxic agent or infection due to different predominant organisms, particularly the Streptococcus hemolyticus, pneumococcus, influenzal bacillus or Staph aureus These pneumonias are characterized by considerable hemorrhagic edema of the lungs or marked bacterial invasion and suppuration The sputum is bloody or purulent, with enormous numbers of the predominant organism

Lung Cyst Pulmonary cysts which are ordinarily air-bearing or partially filled with clear secretions not infrequently become infected They then contain purulent material and an acute illness results which resembles lung abscess The sputum examination is important for bacteriologic diagnosis and the

geotrichosis, cryptococcosis, moniliasis, histoplasmosis and aspergillosis The presence of the fungus in the sputum does not always mean it is pathogenic Some fungi are saprophytic, common inhabitants of the respiratory tract, or secondary invaders which accompany other diseases such as tuberculosis, bronchiectasis and lung abscess Other fungi, like monilia, are more prevalent in sputum after much use of antibiotics

To make the diagnosis it is important to collect fresh sputum after preliminary preparation (cleansing teeth and gums and throat gargle) The fungi can be found by direct examination, culture or animal inoculation Direct examination includes a fresh slide or cover glass preparation of sputum or a Gram smear To be significant the fungi must be found persistently and abundantly in sputum (with other etiologic agents excluded) Culture methods are of great value in the isolation and identification of fungi Specific or special media are employed for this purpose Animal inoculation determines the pathogenicity of the fungi For this either sputum or a saline suspension of the pure culture is used and results are usually rapidly available

If the sputum is inadequate, gastric contents can be aspirated for direct examination and culture Examination of the sputum is an important method of diagnosis in fungus disease However, in addition there are usable skin tests and complement fixation, precipitin

must be
and x ray

features of the illness Fungus disease can resemble tuberculosis, lung abscess and other bacterial infections In any obscure case of chronic lung lesion or chronic pulmonary suppuration particularly with sputum negative for tubercle bacilli, a fungus condition must be considered

Neoplasm In competent laboratory hands studies for tumor cells will be positive in a majority of cases of neoplasm From a bacteriologic point of view the sputum findings will vary with the degree of bronchial infection and bronchial obstruction Thus there can be little or abundant sputum, with gradations from mucoid mucopurulent, purulent to even foul expectoration At some time in almost half of the cases there will be blood in the sputum With considerable bronchial obstruction there is severe secondary infection and chronic pulmonary suppuration, and the sputum findings resemble that found in lung abscess and bronchiectasis On occasion with necrosis of the neoplasm, small tumor particles may be found in the sputum The sputum examination can also provide information about the effective antimicrobial agents that could help the infection Such therapy would be used on a preoperative basis or for palliation in individuals ineligible for surgery

Infarction In typical infarction in a patient with no previous lung infection and a nonseptic embolus, the sputum will be composed mainly of mucoid bloody material and few bacteria If there is pre-existing pulmonary infection or the embolus is septic or breakdown of the infarcted area is associated with secondary infection, there will be much sputum composed of blood mixed with purulent material and many bacteria Control of the infection is urgent in these usually seriously ill patients Sputum analysis will indicate the appropriate antimicrobial agent

REFERENCES

1 SMITH, C R Tubercle bacilli in stomach contents of healthy normal adults exposed to tuberculosis *Am Rev Tuberc*, 50 330 1944

2 BELGOROD, S H and SCHAIN, P Pitfalls of the gastric examination for tubercle bacilli *Quart Bull, Sea View Hosp*, 4 182, 1939

3 ORDWAY, W H, MEDLAR, E M and SASANO, K T Routine application of concentration, culture and guinea pig inoculation for the demonstration of tubercle bacilli in tuberculosis cases under treatment *Yale J Biol & Med*, 15 353 1953

4 FELD, D D The significance of tubercle bacilli in gastric contents *Am Rev Tuberc*, 50 481, 1944

5 BOBROWITZ, I D Round densities within cavities *Am Rev Tuberc* 50 305, 1944

6 WOODRUFF, C E and HOWARD, W L The importance of the tuberculin test in the differential diagnosis of pulmonary lesions *Am Rev Tuberc*, 63 140, 1951

7 FREIMAN, D G and PINNER, M Routine examination of sputum for acid fast bacilli *Am Rev Tuberc*, 59 449 1949

8 LANDE F and DIXON, R F Comparative study of guinea pig inoculation and cultures for demonstration of tubercle bacilli *Am J Clin Path*, 8 93, 1944

9 BOBROWITZ I D and LEON, J L Standard sputum requirements *Quart Bull, Sea View Hosp*, 3 444, 1938

10 KRAMER C H Effect of human gastric juice on tubercle bacilli with special reference to diagnosis of active pulmonary tuberculosis *Am Rev Tuberc*, 53 385, 1946

11 SCHWARTING, V M Inhibitive effect of gastric lavage on tubercle bacilli *Am J Clin Path* 15 234, 1945

12 BOBROWITZ, I D The significance of positive cultures *Dis of Chest*, 16 600, 1949

13 ABELES, H The significance of positive cultures in apparently adequately treated patients with pulmonary tuberculosis *Am Rev Tuberc*, 58 308, 1948

14 CHANG, R Prognostic significance of occasionally positive sputum after adequate treatment of tuberculosis *Am Rev Tuberc*, 58 303 1948

15 BOBROWITZ, I D The value and limitations of sputum, gastric and culture examinations in pulmonary tuberculosis *Bull New York M Coll., Flower & Fifth Ave Hosps*, 4 1, 1951

16 Diagnostic Standards and Classification of Tuberculosis National Tuberculosis Association, 1950 edition

17 CLIFFORD, R The sputum—Its Examination and Clinical Significance New York 1932 Macmillan

18 CONANT, N F, MARTIN, D S, SMITH, O T, BAKER, R D, CALLAWAY, J L Manual of Clinical Mycology Philadelphia, 1945 W B Saunders Co

19 CHAVES, A D, PEIZER, L R and WIDELOCK, D A comparative study of the effectiveness of laryngeal swabs and gastric aspiration for the detection of tuberculosis in chest clinic patients *Am Rev Tuberc*, 67 593, 1953

20 BATY, J M and KREIDBERG, M B Acute laryngotracheobronchitis *M Clin North America*, 36 1279 1952

21 McVAY, L V, JR and SPRUNT, D H Antibiotic prophylaxis in chronic respiratory diseases *Arch Int Med*, 92 833, 1953

Lung Biopsy in Disseminated Pulmonary Disease

HENRY P CLOSE M D, *Philadelphia, Pennsylvania*

From the Medical Service Veterans Administration Hospital Philadelphia Pennsylvania

THE term disseminated pulmonary disease is applied to cases in which chest roentgenographic examination shows lesions scattered throughout both lungs Some patients presenting these findings are discovered in surveys and are asymptomatic, while others seek medical advice with symptoms of pulmonary disease Chest roentgenograms are not diagnostic Disseminated pulmonary disease, regardless of etiology, may have a similar distribution and configuration of the x ray lesions Bronchoscopic examinations of these patients with cytologic and bacteriologic studies of aspirated secretions may provide a diagnosis of carcinoma, tuberculosis or some bacterial or fungous infection Skin tests may in some cases suggest the presence of histoplasmosis coccidioidomycosis tularemia blastomycosis or toxoplasmosis but even when positive these may be unrelated to the lesions under investigation

In the majority of patients disseminated pulmonary disease remains undiagnosed following the usual clinical studies These patients are subjected to interval chest roentgenograms Several diagnoses are suggested and a period of watchful waiting ensues No one can deny that adequate treatment of a patient requires

inciple

They

it all

The patient shares the physician s uncertainty about his future He is not told when he can return to work and no positive report can be given if necessary for compensation purposes

Physicians readily accept the urgency of performing an exploratory thoracotomy on patients with unilateral lesions suspected of being neoplastic It is not widely realized however, that biopsy is equally important in patients with undiagnosed disseminated pulmonary disease

BIOPSY TECHNICS

A variety of biopsy technics have been used Liver biopsy, peripheral node biopsy or bone marrow biopsy may provide a histologic diagnosis if the disseminated pulmonary disease is associated with a systemic condition Biopsy of scalene lymph nodes has been suggested by Daniels[1] for the diagnosis of intrathoracic disease These nodes are part of the chain of deep mediastinal nodes and likely to be involved in the same pathologic process If the disseminated pulmonary disease cannot be diagnosed by the usual clinical studies and the patient does not present associated involvement of other organs, a lung biopsy should be performed

Needle biopsy of the lung [illegible]

plicated by hemorrhage or pneumothorax and it does not provide sufficient tissue for histologic and bacteriologic study, or chemical analysis Direct biopsy of the lung through the usual open thoracotomy readily provides adequate tissue for examination but it is too drastic a procedure for many patients with pulmonary insufficiency The method of Klassen[2] for pulmonary biopsy gives equally good results with little or no morbidity and very little discomfort In a recent report[3] this technic was used in eighty seven cases with no mortality or complications The Klassen procedure is performed under local anesthesia through an intercostal incision The wound is closed without the usual uncomfortable drainage tube and patients are out of bed on the day of operation and leave the hospital on the third postoperative day

1

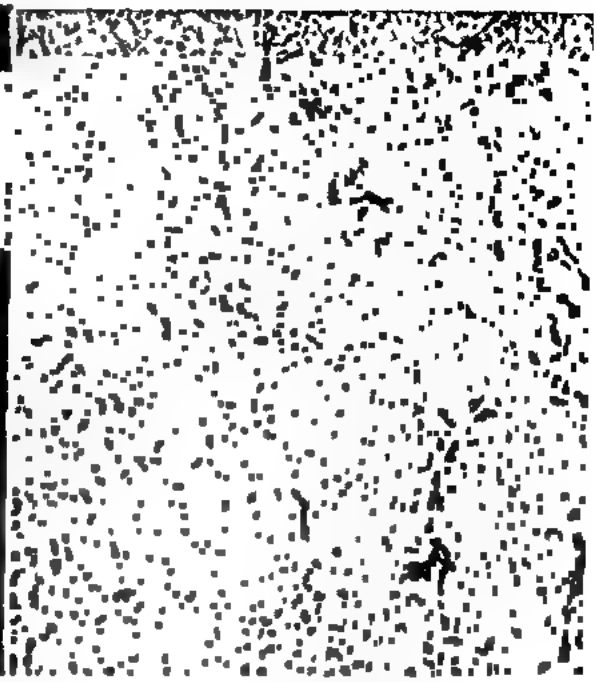

2

FIG 1 Case 1 Posterior-anterior roentgenogram of the chest showing enlarged hilar shadows and disseminations infiltrations and fibrosis throughout both lungs

FIG 2 Case 1 Photomicrograph of lung section showing a great accumulation of lipophages The alveoli septa are still visible although compressed by the large numbers of lipid laden cells within the alveolar spaces Diagnosis was lipoid pneumonitis, × 200

[illegible]

CASE REPORTS

CASE I. T P, a fifty-three year old white male, was admitted to the Philadelphia Veterans Administration Hospital in July, 1953 He gave a history of having had a "cigarette cough" for many years and a productive cough, progressive dyspnea and weight loss during the past two years Walking 10 or 15 feet brought on a state of collapse Physical examination showed advanced pulmonary osteoarthropathy and an emphysematous chest with crepitant rales throughout both lungs Chest roentgenogram (Fig 1) showed disseminated [illegible]

The tuberculin test was positive The patient improved after treatment with antibiotics, [illegible]

2) revealed a diagnosis of lipoid pneumonitis.

Comment. This patient had not been exposed to any exogenous sources of oil such as oily nose drops or mineral oil laxatives The tissue changes could be the result of nonspecific infections with secondary tissue destruction with histiocytes taking up cholesterol and lipid substances. This case probably represents a form of endogenous lipoid pneumonitis Although an exact etiologic diagnosis could not be established, we felt justified in giving the patient cortisone which brought about further improvement in his condition

CASE II J. C, a twenty-nine year old white male, gave a history of working in a beryllium steel plant in 1942 for only four weeks In 1945 while in the Army he complained of dyspnea and cough on exertion These symptoms be- [illegible] was hospital- [illegible] sis [illegible] at that time Cortisone was administered and temporary improvement was noted. He was admitted to the Philadelphia Veterans Administration Hospital in November, 1953, complaining of severe dyspnea on exertion The tuberculin test was negative Laboratory studies, including liver function tests, were normal. His vital capacity was 2,130 cc in three seconds, and his maximal breathing



3 4

FIG 3 Case II Poster or anter or roentgenogram of the chest showing fine nodular densities scattered throughout both lungs

FIG 4 Case II Photomicrograph of lung section reveals two granulomas and fibros s The granulomas are composed of ep thelo d cells and giant cells Diagnosis was focal granulomas and f brosis × 200

capacity was 70 L/min , 63 per cent of his expected normal Chest roentgenogram (Fig 3) revealed disseminated lesions throughout both lungs This patient was well informed concerning his condition and had filed a pension claim insisting that he had sarcoidosis which had developed in the Army A lung biopsy was performed Microscopic section (Fig 4) of lung revealed focal granulomas and fibrosis These findings were consistent with a diagnosis of berylliosis or sarcoidosis Some of this tissue was sent to Dr Harriet Hardy of Boston for beryllium analysis It showed 2 22 μg of beryl lium per 100 gm of tissue This finding made a *specific diagnosis in this case of delayed beryl* lium granulomatosis

Comment The diagnosis of berylliosis provided a sounder basis for cortisone therapy and showed that the patient s disability resulted from an industrial hazard and was not incurred in military service

CASE III E E a thirty six year old white male was in good health until 1937 when acute rheumatic fever developed while he was in military service He states that after four months of bedrest he recovered and was re turned to duty In 1942 he noticed shortness of breath while on marches but he did not report to sick call and subsequently went overseas In 1943 following hospitalization for injuries received in a motorcycle accident, he was told that he had heart disease and was reassigned to light duties The shortness of breath became progressively worse and he began to suffer from excessive fatigue after exertion He was discharged from the Army but was able to

turned to work with instructions to take digitalis A few months later fatigue malaise and progressive shortness of breath again devel oped In February 1954 he became febrile and was admitted to the Philadelphia Veterans Administration Hospital

Physical examination showed a well devel oped white male in no apparent discomfort Scattered crepitant rales were heard at the bases of both lungs On percussion the left border of the heart was just outside the mid clavicular line A grade 3 systolic murmur was heard in the third left interspace There was a split aortic second sound No diastolic murmur was heard An electrocardiogram showed auricular fibrillation with a well controlled ven

5

6

FIG 5 Case III Posterior anterior roentgenogram of chest showing fine nodular densities scattered throughout both lungs and enlarged pulmonary artery segment

FIG 6 Case III Photomicrograph showing vascular sclerosis (pigment bearing macrophages within alveolar spaces) Special stains demonstrated pigment to be iron × 110

tricular rate of 70 per minute and right axis deviation Phonocardiograms recorded a faint systolic murmur at all valve areas No diastolic murmur was recorded Roentgenogram of the chest (Fig 5) revealed disseminated lesions scattered throughout both lung fields A heart study showed left auricular, right ventricular and pulmonary artery segment enlargement

His venous pressure was 45 mm of water The arm to tongue circulation time was twenty two seconds The white blood count was 11 000/cu mm with 70 per cent neutrophils, sedimentation rate was 41 mm per hour Antistreptolysin titer was 48 and antihyaluronidase titer 512 Other laboratory studies were not significant

The patient improved on bedrest and his temperature, white blood count and sedimentation rate returned to normal It was believed that the patient had rheumatic heart disease, probably with recent activity He also had some disseminated pulmonary disease The possibility of hemosiderosis was questioned because of the lack of severity of the heart disease and absence of the diastolic murmur of mitral stenosis It was thought that this patient might have some primary pulmonary disease contributing to his symptoms Sputum studies were negative for acid fast bacilli Skin tests for tuberculin, coccidioidin and histoplasmin were negative

A lung biopsy was performed May, 1954 Microscopic section of lung (Fig 6) showed congestion with iron laden macrophages

Comment The specific diagnosis obtained [illegible] primary pulmonary disease that would have been a contraindication to cardiac surgery

SUMMARY

1 The importance of performing a lung biopsy in the presence of undiagnosed disseminated pulmonary disease is discussed

2 Cases are presented to demonstrate the usefulness of this procedure

REFERENCES

1 DANIELS A C Method of biopsy useful in diagnosing certain intrathoracic diseases *Dis of Chest* 16 360–366 1949

2 KLASSEN K P ANLYAN A J and CURTIS G M *Biopsy of diffuse pulmonary lesions. Arch Surg.* 59 694–704 1949

3 PRIOR, J A KLASSEN K P and ANDREWS N C Diagnosis of diffuse pulmonary lesions. *Transactions National Tuberculosis Association Forty Ninth Annual Meeting* 1953 pp 109–112

11

Bronchoscopy

F. Johnson Putney, M.D., *Philadelphia, Pennsylvania*

Since the bronchoscope is a speculum similar to those used in various other fields of medicine to observe cavities and passages which are not otherwise visible, its limitations restrict the bronchologist in the portion of the tracheobronchial tree that is accessible to in-

smaller bronchi and peripheral radicals cannot be seen. Telescopic inserts now enable the bronchologist to view previously hidden portions of the bronchial tree, but large segments still remain beyond his vision. Although these latter areas are not amenable to direct inspection, secretions and exudates can be obtained from these regions for bacterial and cytologic examinations. To be of value this material has to be collected from the precise subdivision leading to the disease. The examiner must be thoroughly conversant with intrabronchial anatomy in relation to the involved bronchopulmonary segment as localized on the roentgenogram to accomplish this.

CONTRAINDICATIONS

The contraindications to bronchoscopy are few. Moribund patients and those with severe or advanced cardiac failure, untreated myasthenia gravis and lesions of the cervical spine in which hyperextension of the head might lead to compression of the spinal cord are not suitable candidates. Bronchoscopy should be avoided during critical pulmonary bleeding but should not be postponed too long and can be done with reasonable safety forty-eight hours after the acute bleeding episode has subsided. When performed soon after active bleeding, valuable information can be obtained, and bronchoscopic localization is often helpful in detecting the lobe or subdivision from which the blood originates. If one waits until there is complete subsidence of pulmonary bleeding, bronchoscopy may reveal nothing and the value of the examination in this respect is lost.

VALUE AND INDICATIONS

The greatest usefulness of bronchoscopy lies in diagnosis, and when positive and concrete evidence is uncovered the diagnosis is established. When a partial or complete obstructive lesion such as obstructive emphysema or lobar atelectasis is seen on the roentgenogram, bronchoscopic observation generally uncovers the cause. In these conditions appropriate treatment through the bronchoscope may, at times, be curative.

It is only within the past twenty-five years that bronchoscopy has come into general use and it is now an integral part of the examination of patients with pulmonary symptoms. Seldom is bronchoscopy necessary before the patient has had a complete medical examination and study, and if the patient has a chronic cough, a chest roentgenogram should always precede bronchoscopic investigation. The radiologist interprets shadows on the roentgen films and generally reaches accurate conclusions but because of this fact the nature of

examination.

Bacteriologic study of secretions obtained bronchoscopically has proved valuable in diagnosing some of the fungous diseases which exhibit variable and inconclusive roentgeno-

nostic methods, the bronchoscopic findings may furnish the clue needed to make the diagnosis In indeterminate chest lesions in which the diagnosis remains in doubt after all methods have been exhausted exploratory thoracotomy becomes necessary

Negative roentgen findings do not always rule out pulmonary disease In some cases the roentgenogram is normal yet serious trouble is present Chronic cough, hemoptysis, persistent wheezing and at times unrelieved dyspnea are symptoms requiring endoscopic investigation, and the diagnosis commonly becomes evident when one looks into the bronchial tree

Bronchoscopy is always indicated in any case of chronic persistent cough with or without expectoration The possible presence of carcinoma of the lung must always be seriously considered, even though the patient often attributes the cough to smoking Unfortunately carcinoma of the lung is not limited to males nor to those individuals past middle age and may remain asymptomatic or produce atypical symptoms and roentgen findings so that the earliest and most significant symptom of chronic cough cannot be neglected

Surgical treatment of carcinoma of the lung has continued to progress, and if patients with this disease are to have their chances of survival improved, early diagnosis remains essential Bronchoscopic biopsy has retained a prominent place in the diagnosis but when a lesion is accessible for biopsy the surgeon finds repeatedly that the carcinoma is inoperable by virtue of extension or metastasis or both It is the minute lesion located in the smaller bronchi in which curative results can be anticipated, and cytologic study of secretions from the involved bronchus has established a diagnosis in many instances when the lesion is beyond bronchoscopic vision In reviewing 488 cases of carcinoma of the bronchus Clerf, Herbut and Nealon[1] noted that the diagnosis was made by biopsy in 31 5 per cent and by cytologic examination of bronchial secretions in 56 per cent, making a total of 87 5 per cent diagnosed by bronchoscopic and cytologic means Even though there was a high percentage of positive diagnoses, pulmonary resection could be performed in only 42 per cent of the cases with a 27 per cent survival rate over a five-year period While these figures are excellent in comparison with others, they need to be improved—emphasizing the fact that the curability of bronchogenic carcinoma is proportionate to the resectability rate which in turn is directly related to early diagnosis

In some peripherally placed lesions it is possible to make the diagnosis by [illegible] treated as such until proved otherwise Dependency cannot be placed upon cytologic examination alone and in the face of negative studies equivocal chest lesions in which carcinoma is suspected but not proved require surgical exploration Occasionally false positive cytologic reports are obtained but operation must be unnecessarily performed in the infrequent case of this kind in order to establish the diagnosis definitely and to rule out malignancy

Bronchoscopic observation is valuable to the surgeon in determining the exact site and extent of the tumor While tissue for biopsy or positive cytologic cell findings may not be obtained, fixation and rigidity of the involved bronchus offers presumptive although unconfirmed evidence of malignancy Extension into the mediastinum as evidenced by immobility and broadening of the carina indicates inoperability When the tumor is found to invade the trachea, it becomes necessary for the surgeon to plan his approach to include tracheal excision and reconstruction The observation of laryngeal paralysis is likewise important in determining operability, although Ochsner[4] has reported a successful pneumonectomy with a six and one-half-year survival in a patient having recurrent nerve paralysis

A positive diagnosis of adenoma of the bronchus or trachea can be made in over three-fourths of the cases by examination of tissue removed at bronchoscopy for microscopic study The only other method of positive diagnosis is by surgical exploration Because the adenoma is usually covered by intact mucous membrane the characteristic cells do not exfoliate and are not recovered in the sputum or bronchial secretions Adenoma presents a characteristic bronchoscopic appearance of a smooth, non ulcerated reddish mass which bleeds easily and occasionally is pedunculated The differential diagnosis between adenoma and carcinoma may be difficult, but the selection of proper therapy is dependent upon accurate distinction

Tracheobronchial tuberculosis is identified

by bronchoscopic examination not only when the sputum persistently contains acid fast bacilli in spite of adequate antituberculous therapy, but also when the sputum becomes negative under treatment yet the patient fails to improve Bronchoscopy provides a means of obtaining tissue for microscopic examination and bronchial secretions for acid fast study In the presence of stenosis secretion containing acid fast organisms may pool behind the obstruction and aspiration of this material may reveal the causative organism whereas examination of sputum which originated above the stricture had consistently been negative In tracheobronchial tuberculosis localized inflammation and edema of the mucosa about the involved bronchial orifice, the location and extent of pus, the presence of ulcerations and granulations, obstructive lesions and stenosis may be observed directly In addition in cases of bilateral tuberculosis one may obtain information regarding the source of the positive sputum and collect separate specimens from infected areas in each lung for examination to ascertain in which one activity exists Bronchoscopy should always be performed prior to pulmonary surgery for tuberculosis to determine the presence or absence of tracheobronchial disease The results of specific therapy in tuberculous bronchial lesions can be better evaluated by direct visualization during and after the course of treatment

Hemoptysis is a symptom of pulmonary disease requiring bronchoscopic investigation Besides carcinoma and tuberculosis a common cause of bleeding is bronchiectasis While the diagnosis can be made by clinical, roentgenologic and bronchographic examinations all patients with bronchiectasis whether active bleeding is present or not should have at least one bronchoscopic examination to rule out complicating factors, such as a foreign body which may have been aspirated in childhood and remained unrecognized or bronchial obstruction from a stricture or broncholith producing subsequent infection and bronchiectasis below the point of obstruction

Bronchoscopy is a necessary procedure in any case of unexplained hemoptysis, for often direct evidence of a lesion that will account for the bleeding can be found By tracing the blood to its point of origin a small lesion might be discovered, so that tissue or secretion can be obtained directly from the lesion or involved area thereby establishing an etiologic diagnosis which otherwise would not be possible In a study of 200 cases of hemoptysis Moersch[4] found that the cause could not be determined in 75 per cent in spite of various diagnostic procedures, and when the etiology was unknown, it was his opinion that a serious pulmonary lesion would not develop subsequently

Hemoptysis occurs in various forms of obstructive pneumonitis and middle lobe syndrome The latter may be confused with pulmonary tuberculosis in younger individuals and carcinoma in older people, consequently bronchoscopy is valuable in differentiation A frequent finding in obstructive middle lobe pneumonitis is pressure from an enlarged lymph node at the middle lobe orifice or the presence of a broncholith

As a precautionary measure bronchoscopy should be employed in cases of chronic lung abscess, and even though the diagnosis is evident by physical and roentgen means the etiology is often obscure Formerly, pulmonary abscess commonly followed operative procedures particularly under general anesthesia and about the head and neck, but now the most frequent cause is bronchogenic carcinoma When a tumor becomes necrotic in the center, liquefaction occurs and an abscess cavity forms especially if the draining bronchus is blocked by tumor Aspiration of secretion from the abscess area may reveal the presence of tumor cells In acute inflammatory abscesses early treatment by bronchoscopic drainage and opening of the obstructed bronchus produces improvement and along with antibiotic therapy may be curative Chronic abscess cannot be cured by this means, although established when needed, surgical treatment can be performed with less risk

One definite indication for bronchoscopy is in cases of stridor or wheezing respirations of unexplained etiology It must always be remembered that wheeze means partial obstruction and, until the cause has been found, every avenue of approach should be exhausted Tracheal and bronchial obstruction may produce symptoms of marked respiratory embarrassment without visible roentgenogologic changes, and the underlying cause may be detected only by visualization through

the bronchoscope The causes of bronchial obstruction are numerous and in addition to intrinsic lesions such as tumors, foreign bodies, strictures and stenoses extrinsic compression of the trachea or bronchus may be observed from tumors, enlarged lymph nodes, vascular lesions or anomalies

A superior mediastinal mass with displacement of the trachea on the roentgenogram may be due to substernal thyroid enlargement, but when dyspnea is present, bronchoscopy commonly reveals the true cause In my experience substernal goiter rarely leads to significant dyspnea, and a thorough study is necessary to find the cause of the shortness of breath On occasion lipoma, adenoma, carcinoma, lymphoma and tracheobronchial tuberculosis have been uncovered on bronchoscopic investigation

Compression of the main bronchi from other extrinsic bronchial lesions may lead to obstructive signs and dyspnea Mediastinal lymph node enlargement from metastatic carcinoma occurs frequently, but lesions of the lymphoma group, chiefly Hodgkin's disease, while less frequently encountered may be responsible for compression stenosis At times definite endobronchial involvement with ulceration and fungation exists, and in these instances the lymphomatous disease generally remains limited to the chest Difficulty in obtaining sufficient tissue for histologic examination is the chief problem and since these lesions closely resemble carcinoma clinically, the distinction is not easy unless histologic confirmation can be obtained

Congenital anomalies are one of the principal causes of respiratory obstruction in infants and are responsible in many cases for respiratory emergencies Holinger et al [2] have stressed the need for correlation of the history, fluoroscopic, roentgenographic, bronchographic and bronchoscopic findings It is not uncommon to have a young child admitted to the hospital with a diagnosis of atelectasis of the lung which is found on subsequent study to be due to bronchial compression, either partial or complete, from anomalies of the heart and great vessels

hibited unrecognized obstructive emphysema from vascular pressure

In children with respiratory difficulty bronchoscopy is a safe procedure provided no anesthesia is used, oxygen is administered the instruments are small enough to prevent trauma, and the examination is carried out in a short time Congenital anomalies that are suspected on the roentgenogram can be proved by bronchoscopic observation, which may reveal agenesis of the lung with or without a rudimentary bronchus, congenital webs, abnormal constrictions or bifurcations Fibrocystic disease of the pancreas is manifested by respiratory symptoms in many cases, and when bronchoscopy is carried out, obstruction from secretion and inflammation is found

ROLE IN THERAPEUSIS

While the role of bronchoscopy in treatment is secondary to that in diagnosis it has proved helpful in the treatment of certain cases of bronchial adenoma, tuberculous tracheobronchitis, bronchial asthma stenosis of the bronchus and atelectasis In addition bronchoscopy is unsurpassed for the removal of foreign bodies It remains the only means by which this can be accomplished other than by exploratory thoracotomy When the foreign body is peripherally located in the smaller subdivisions of the bronchi fluoroscopic guidance is essential provided the object is radiopaque In these instances the use of a magnetic instrument is limited because of the problem of making contact with the foreign body lodged in a distal pulmonary segment

When a broncholith projects into the bronchial lumen producing bronchial obstruction it may erode through the mucous membrane and, if so can be removed bronchoscopically It is unwise to incise an intact mucous membrane over the broncholith in order to extract it Difficulty arises in removing the entire broncholith because of its fragmentary nature and usually portions have to be withdrawn piecemeal in order to overcome the obstruction and allow ventilation to the distal lung

Stenosis of the bronchi with suppurative changes beyond the obstruction are thoracic surgical cases and are best handled by this means In contrast, benign tracheal stenosis comprises a complicated problem, for the surgical approach has proved far from ideal Even though repeated and prolonged endoscopic dilatation is required, this offers the best and safest method of treatment at the present time

In tracheobronchial tuberculosis endoscopic

applications of cauterizing agents may aid healing but far greater benefits are obtained with specific antimicrobial and antibiotic therapy Granulation tissue which is causing bronchial obstruction should be extirpated and an attempt made to keep it at a minimum so that suppuration and atelectasis does not develop below this point When a stricture or stenosis forms as the end result of the healing process dilatation by means of bronchoscopic bougienage may keep the bronchus patent and prevent subsequent suppuration and bronchiectasis in the distal lung After bronchiectasis develops surgical excision of the involved pulmonary segment is inevitable

In some cases of bronchial asthma and occasionally in chronic bronchitis the large bronchi become blocked by thick tenacious secretion creating pneumonitis and signs of atelectasis At bronchoscopy blockage to the bronchus may be observed and after secretion is aspirated and patency restored marked improvement in the respiratory symptoms takes place and the fever subsides This complication is particularly prone to start in the subdivisions of the lower lobe bronchi In certain other cases of intractable asthma in which the patient is unable to cough up his own secretions due either to inability to secure sufficient tussive squeeze or to bronchial collapse bronchoscopic suction affords relief by elimination of retained secretions

When there are respiratory complications of fibrocystic disease of the pancreas in children obstruction may develop from extremely thick and viscid secretions along with a thickened granular mucosa Bronchoscopic aspiration leads to symptomatic improvement but may have to be repeated to maintain bronchopulmonary drainage and enable the antibiotic agents to better exert their effect

Bronchoscopy is a primary requisite in the treatment of postoperative atelectasis especially after operations in the thoracic cavity There can be no question but that massive atelectasis should receive immediate bronchoscopic treatment The lesser forms of postoperative pulmonary atelectasis with generalized patchy involvement throughout one or both lungs may clear up under conservative treatment provided the patient is not sedated and efforts are made to induce cough and get rid of retained secretions If after twenty four to thirty six hours under this regimen there has been no appreciable response bronchoscopic treatment should be promptly carried out

Regurgitated material aspirated into the lung should be removed as soon as possible to prevent pulmonary collapse and ultimate infection Although bronchoscopy is useful in clearing up infantile atelectasis of a severe degree most newborn infants can completely aerate their lungs in a comparatively short period of time Tracheal aspiration will commonly be sufficient to remove secretion from the airway but when there is collapse of a lobe or lung bronchoscopic treatment is indicated

Benign tumors of the bronchi are not encountered frequently and while it is possible to remove them through the bronchoscope by cutting snaring or diathermy when they are attached by a small base endoscopic excision does not cure suppurative disease distal to the lesion after irreversible changes have taken place

Since the bronchial adenoma habitually has its smallest projection into the bronchus and a larger non visible extension extrabronchially, it is usually best dealt with by operation which as a rule does not have to be as radical as that for carcinoma However there are certain cases representing a small proportion of the total in which the growth can be adequately removed and handled by bronchoscopic means for the tumor is relatively slow growing and metastasizes late Excision of a small pedunculated lesion in one of the main bronchi can be accomplished by endoscopic means and following electrocauterization of the base the patient may remain well for many years In older individuals when the tumor is located near the carina and an exploratory thoracotomy cannot be performed for physical and medical reasons bronchoscopic treatment may afford considerable relief and allow the patient to live out his normal span of life The problem becomes more complicated when bronchial obstruction leads to atelectasis and bronchiectasis In this type of case the only definitive treatment must be surgical excision when the patient s condition permits

SUMMARY

Although bronchoscopy is used in the treatment of certain pulmonary conditions this phase remains secondary to its aid in diagnosis The information gained by bronchoscopy is

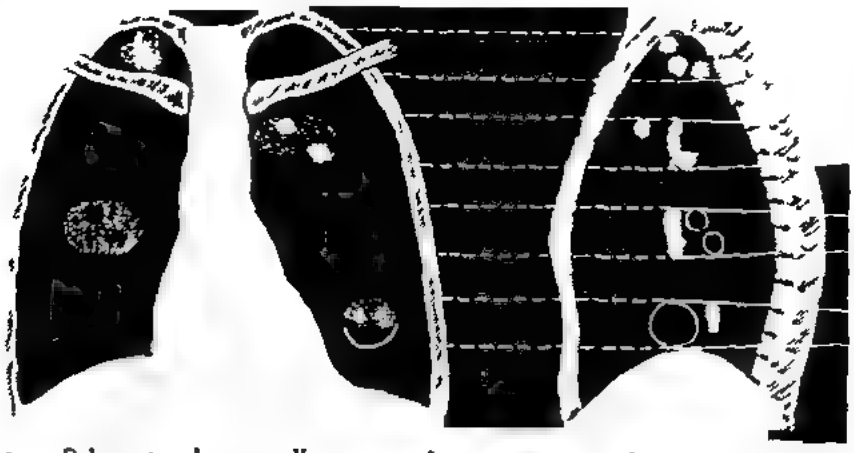

FIG. 1 Schematic drawing illustrating the summation and superimposition of radiopacities and radiolucencies in the roentgenogram (Modified from Chaoul)

estimated that under optimal conditions a radiopaque shadow as small as 2 mm in size can be discernible in the roentgenogram It is extremely important to note that in this order of magnitude most of the finer structures of the lung e g, bronchioles with associated vascular and lymphatic vessels connective tissue septa (alveolar acinar or lobular walls) are much less than 2 mm in thickness[2] It is apparent therefore that the finer lung structures which are observed in the roentgenogram must be a summation of these "subvisible" or microscopic components to produce the finer lines, lacework or reticular pattern of radiopacity as contrasted with the air in the surrounding lung In other words this roentgenographic picture depends on two variable factors which may act independently or concertedly, namely, the amount of air adjacent to the radiopaque structures and the thickness of these structures

Furthermore, visibility, as it pertains to the roentgenogram being a subjective phenomenon (obviously influenced by the training and past [illegible]

fuzzy, irregular, (2) density, i e, presence of calcification (radiopacity being more easily discernible than radiolucency), (3) structure and configuration of the radiopacity, e g, linear, tubular, mosaic, solid round, wedge, homogeneous, (4) technical and miscellaneous factors which include characteristics of x ray machine, focus, object, films, distance, processing, (5) *patient characteristics of size, age, condition, thickness of thoracic wall*

It is not surprising, therefore, that not only is there a wide variation in the appearance of normal chest roentgenograms of different individuals, but also variations in appearance of the same individual s normal chest may occur when taken at various times under different conditions Despite improvements in equipment and standardization many of the foregoing problems cannot be resolved in the foreseeable future

In the absence of more definitive criteria we are obliged to rely upon the impressions and considered opinions of qualified individuals based on their controlled experience using the best technical facilities and a modicum of standardization

DESCRIPTION OF ROENTGEN FINDINGS

Since no classification is available that is entirely satisfactory, we shall use certain descriptive roentgen characteristics as guide posts for our discussion[3] (Table 1) Obviously a lesion can be manifested by just one roentgen finding or by a combination of several of these findings It should also be noted that the superimposition of densities makes it difficult at times to characterize properly the roentgenographic appearance

A Radiopacities

[illegible] (Fig 7A)

normal lung structure for which the *anatomic* term bronchovascular markings is used Abnormal linear radiopacities range from mere accentuation of the normal pattern to marked

thickening and irregularity with superimposed streaks, bands or strands These striae may be localized or widespread in distribution, vary in density, and conform to the usual arboreal lung structure or deviate markedly from it If they extend to the periphery of the lung they occasionally assume a fine reticular architecture In some conditions transition phases exist between the linear and miliary radiopacities so that the boundary line between the two forms is not sharp In the localized types the density in question may be a gradation from the linear to a disc or plaque-like form

TABLE I
CHARACTERISTICS OF ROENTGEN FINDINGS

I Increased Densities (Radiopacities) (Fig 2)	II Decreased Densities (Radiolucencies) (Fig 3)
A Form and size 1 Linear 2 Miliary 3 Nodular (round or blotchy) 4 Segmental or lobar configuration 5 Contour (peripheral mediastinal diaphragmatic)	A Form and size 1 Linear 2 Miliary (?) 3 Cyst like or cavitary 4 Segmental (?) or lobar 5 Contour
B Degree of density	B Degree of radiolucency
C Homogeneity or structural pattern	C. Structural pattern

D Position and distribution (single or multiple)
E Effects on adjacent area (changes in spatial relationships) (Fig 4)
1 Immediate local area
2 General thoracic structures
F Additional information gleaned from special roentgen techniques
1 Modification by physiologic maneuvers and changes in position
2 Special procedures
G Roentgenographic evolution of the process (stationary progressive or regressive)
H Associated roentgen findings (thoracic or extrathoracic)

2 Submiliary, miliary and granular (Fig 2B) These comprise densities which range in size from the just visible to a few millimeters in diameter The lesions may be few or very numerous and typically widely distributed They exist as individual lesions or as localized groups in cluster formation, which in turn are symmetrically or asymmetrically distributed The size and density of the punctate shadows may be uniform or varied Furthermore, they may be so poorly defined as to merge with the fine septal markings

3 Nodular (Fig 2C) These are divided into the more or less rounded lesions which are fairly well circumscribed, and the blotchy or patchy areas with ill defined margins The size ranges from less than a centimeter to several centimeters in diameter The lesions may be single or multiple, localized or widely scattered The shadows may appear homogeneous or mottled, dense or hazy

ciated changes in spatial relationships of the intrathoracic structures sometimes occur The degree of opacity varies from a hazy or ground-glass to a very dense appearance either homogeneous or mottled

5 Peripheral contour (Fig 2F) Included in this group are those lesions which border or involve the mediastinum, diaphragm or thoracic wall and which encroach upon or obscure the adjacent pulmonary field These vary from a small localized density, for example in the costophrenic sinus or hilus to a massive density involving an entire hemithorax (Fig 4A) Frequently the edges of the shadows bordering on the lung field are sharply defined and have characteristic contours such as concavity, convexity, lobulation, etc In other cases this 'free' edge is poorly defined and appears serrated or brush like

B Radiolucencies

1 Linear Streaks of decreased density are projected through the lung field when air escapes into the soft tissues of the chest wall as in subcutaneous emphysema Radiolucent linear bands are also occasionally seen in such conditions as cylindric bronchiectasis and consolidation

2 Miliary (?) size Such radiolucencies are theoretically possible and have been described, but for practical purposes no criteria exist for the roentgen differentiation from the normally aerated lung

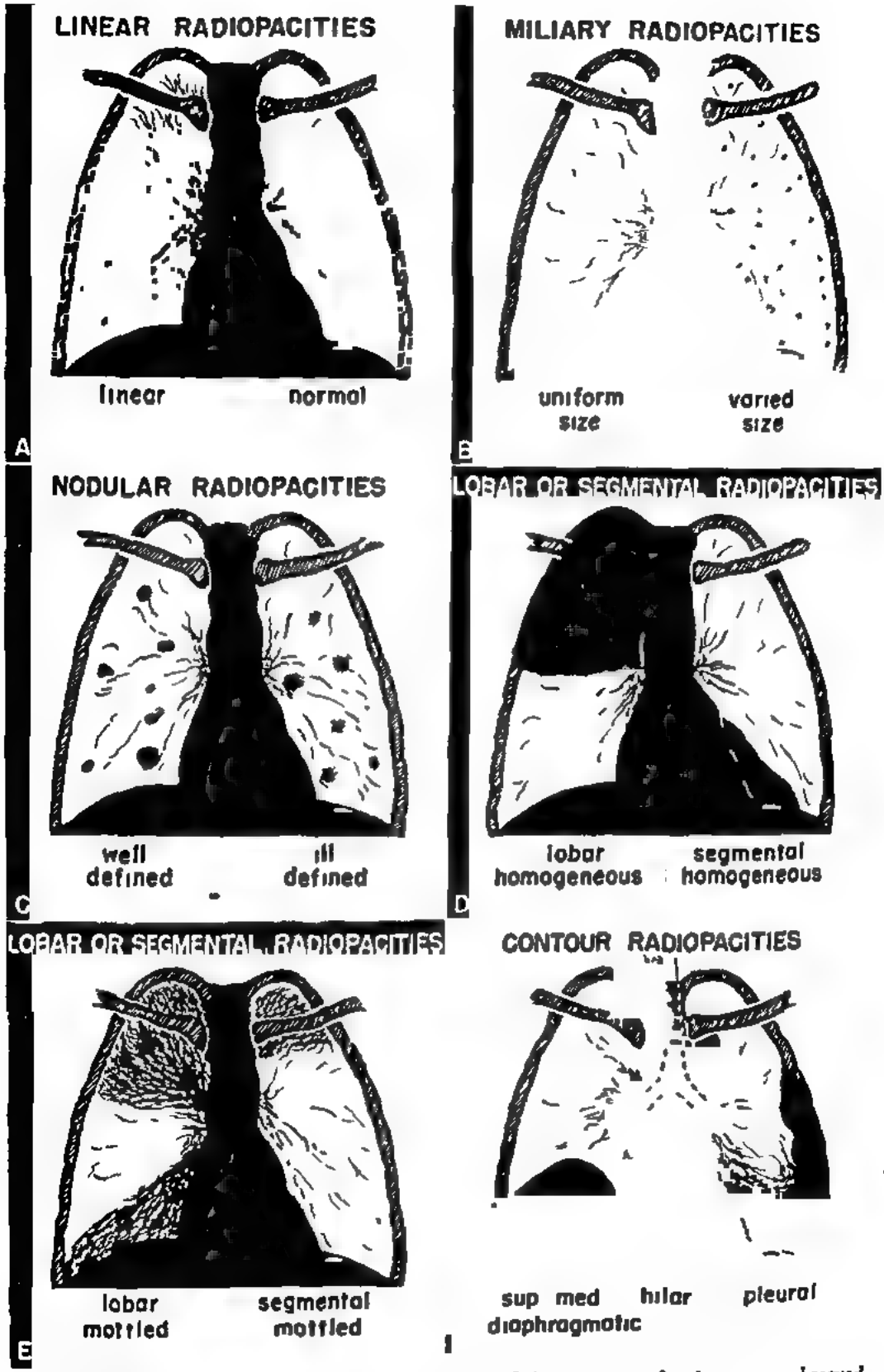

FIG 2 Schematic composite drawings illustrating the different types of radiopacities observed in the roentgenogram

3 Cavitary or cyst like (Fig 3A, B and C) These lesions range from less than 1 cm to several centimeters in diameter They may be single or multiple, unilateral or bilateral and are practically always delineated by a sur-

form structural patterns of various types

4 Conforming to a segment(?), lobe or entire lung (Fig 4B to 4F) Except for the unusual cases of pulmonary embolism without infarction this finding is observed only in various types of emphysema Frequently there are concurrent roentgen findings of changes in spatial relationships Obstructive emphysema of a segment, although occurring pathologically, is seldom demonstrated on the roentgenogram because the changes are not obvious or because the overlying lung markings obscure the hyperaeration

5 Peripheral contour (Fig 3D to 3F) When adjacent to the thoracic wall, mediastinum or diaphragm, these lesions may take the form of sharp radiolucent zones of various widths or localized radiolucent pockets of various sizes and shapes with or without fluid levels They are invariably bounded by radiopacities as, for example, in peripheral pneumothorax the visceral pleura shows up as a very fine linear density forming the boundary of the collapsed lung

C Effects on Adjacent Area (Changes in Spatial Relationships (Fig 4)

The mediastinum, diaphragm, thoracic wall and lungs possess varying degrees of pliability Because of this property certain changes in spatial relationships of the thoracic structures occur whenever abnormal differences in intrathoracic pressure exist as a result of disease processes

1 Immediate local area The effect of a lesion on the immediate adjacent area may be nil or take the form of crowding or spreading of the adjacent linear lung markings and may be associated with decreased or increased radiolucency

2 General thoracic structures Changes in spatial relationships may be slight or very pronounced In addition to changes in distribution of the lung markings over a wide area, the following changes may occur singly or in combination increase or decrease in the thoracic or hemithoracic volume, widening or narrowing of the intercostal spaces and corresponding changes in the direction of the ribs mediastinal shift, elevation or depression of the leaves of the diaphragm, displacement of the lung roots, displacement of the interlobar fissures

D Additional Information Gleaned from Special Roentgen Technics

These include (1) certain physiologic maneuvers such as forced respiratory movements[4] (Valsalva's and Muller's), coughing, sniffing may change the roentgen appearance of the lesion in question and so aid in diagnosis (For example, the Valsalva maneuver tends to decrease the amount of blood in the pulmonary vessels and so differentiation can at times be made between engorged vessels and masses in the lung roots) (2) Changing the position of the patient, for example to the supine or apical lordotic or lateral recumbent will often give valuable additional roentgen information (3) Such special procedures as body section roentgenography, angiography, induced pneumothorax stereoscopy or bronchography are often necessary to demonstrate the nature of the lesion which may not be apparent on the conventional roentgenograms

E Roentgenographic Evolution of the Process

The evolution of the roentgen finding can only be evaluated by follow up roentgen studies or from previous roentgenograms, this is important and may, in fact, be decisive Two features can be ascertained in these studies namely the stability of the lesion (whether stationary, progressive or regressive), and the time-change relationship (whether hours, days, weeks, months or years)

Since a definitive diagnosis cannot be made solely on the roentgen findings correlation with pertinent clinical and laboratory data is imperative for proper analysis of the roentgenogram in order to confirm the initial impression or to arrive at a final diagnosis This information may be summarized as follows (1) clinical history exposure geography, occupation, age sex and race, and response to chemotherapy, and antibiotics, (2) clinical findings pulmonary, extrathoracic, cardiovascular, respiratory functional studies, (3) sputum and bronchial secretions smears, cultures, animal inoculation, cytologic studies, (4) gastric washings, (5) lymph node biopsy,

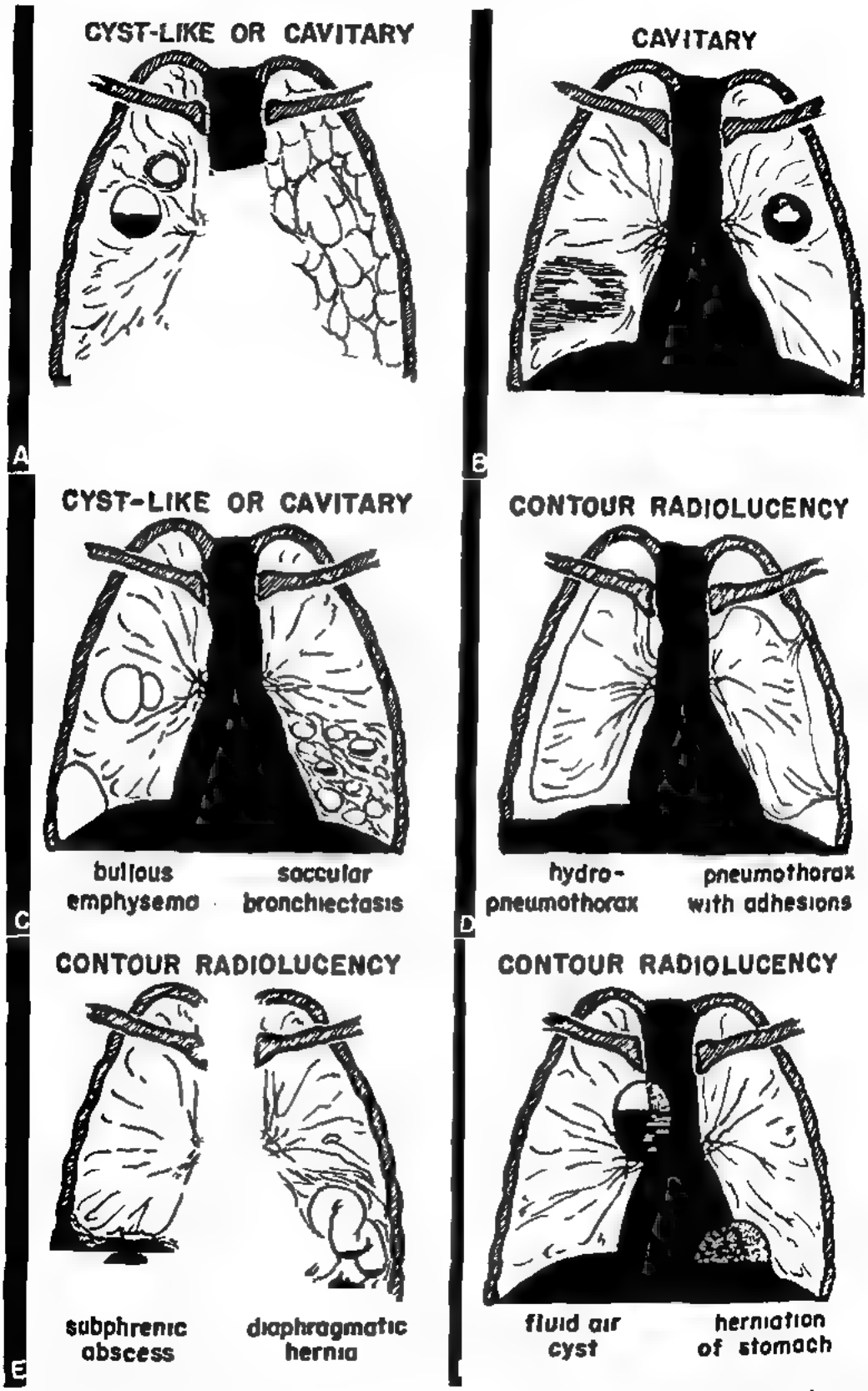

FIG 3 Schematic composite drawings illustrating the different types of radiolucencies observed in the roentgenogram

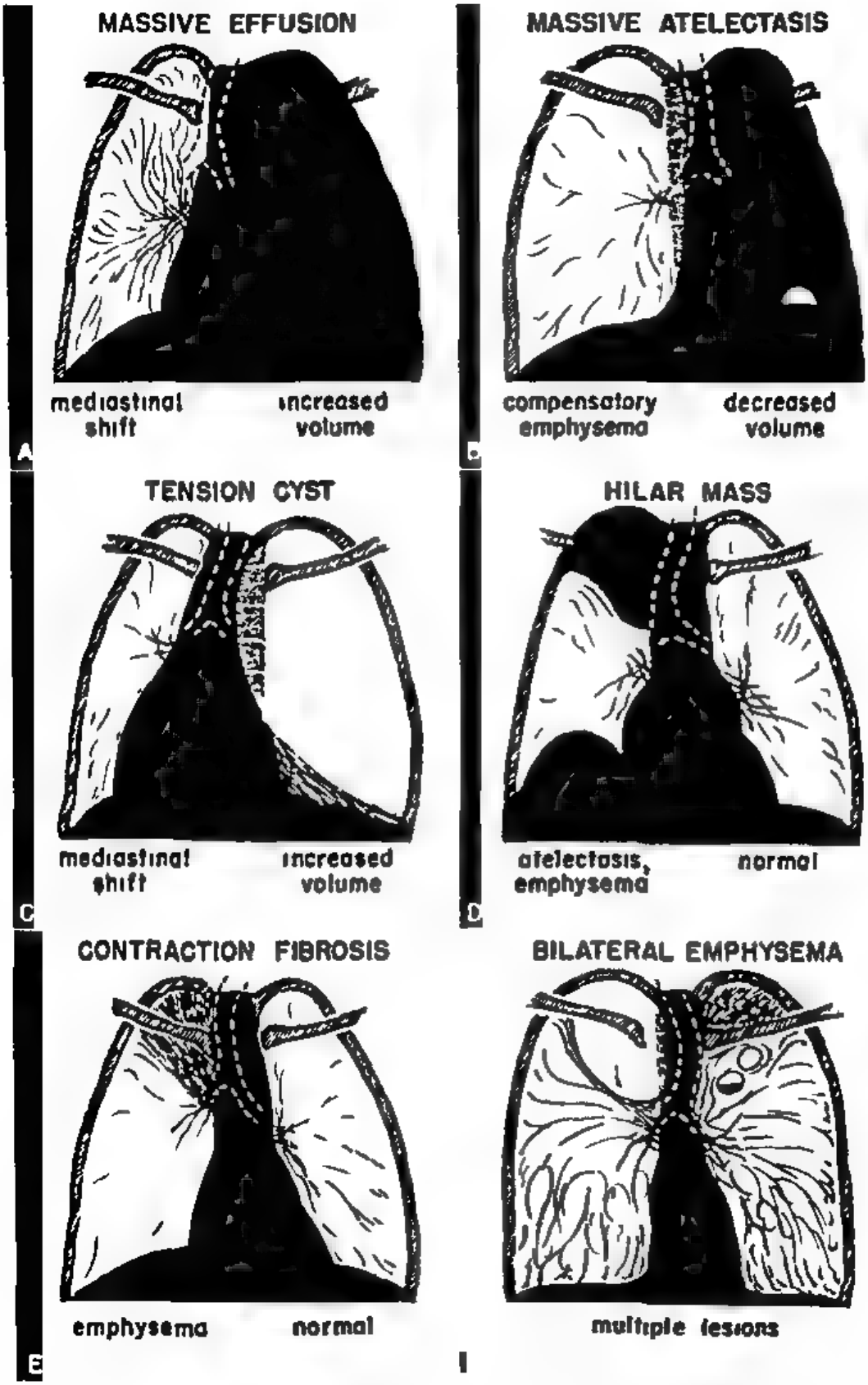

FIG. 4. Schematic composite drawings illustrating changes in spatial relationships and multiple lesions observed in the roentgenogram.

(6) pleural fluid cytology, bacteriology, type of fluid, (7) bronchoscopy biopsy, aspiration, (8) blood studies peripheral smear, bone marrow smear, culture, sedimentation rate blood chemistry, (9) serologic and agglutina tion tests, (10) skin tests (11) surgical pro cedures induced pneumothorax, induced pneu moperitoneum, thoracoscopy, thoracotomy

Obviously not all of this information is neces sary or readily obtainable in every case In some cases just a few additional facts may be sufficient to establish the diagnosis, in other cases even after exhausting the entire gamut of clinical procedures and laboratory tests a definitive diagnosis still cannot be made In the majority of organic lesions the final diagnosis can be made only by pathologic study of the tissues

LESIONS PRODUCING RADIOPACITIES

A Linear Radiopacities

Inflammatory Acute bronchitis Measles whooping cough other viral disease Chronic bronchitis	Neoplastic lymphangitic spread Primary bronchogenic carcinoma Metastatic neoplasm Malignant lymphoma and leukemia
Cardiovascular Pulmonary hypertension Passive pulmonary congestion	Storage diseases Collagen diseases Idiopathic pulmonary fibrosis
Lung dusts (pneumoconiosis) Silicosis Asbestosis etc	

Accentuated linear radiopacities are due to the following factors which may act singly or more usually in some combination,[8] further more they may be a prelude to the development of other types of radiopacities (1) Dilatation or engorgement of the pulmonary vessels (2) interstitial or peribronchial inflammatory infiltration, (3) accumulation of bronchial secretions, (4) interstitial deposition of en dogenous or exogenous foreign material, (5) lymphatic neoplastic infiltration, (6) dila tation or engorgement of the lymphatic vessels, and (7) interstitial and peribronchial fibrosis

From a pathologic point of view, except for reversible cases, a sequel or common denomi nator of practically all the foregoing conditions is a greater or lesser degree of fibrosis involving the interstices of the lung Distribution, loca tion extent and age of the fibrosis along with the invariably associated emphysema atelec tasis, bronchiectasis and disturbance of pul monary circulation add to the complexities of the roentgenogram Those cases in which the fibrosis has no known etiology have been termed idiopathic pulmonary fibrosis

Linear radiopacities in themselves are usually insufficient to explain the underlying patho- ses but when coupled with other lead nos a basis The following comments are mind

1 *Dilatation or engorgement of pulmonary vessels* (1) Active pulmonary congestion In acute inflammatory conditions the pulmonary vessels dilate or become engorged In mild cases these changes may be insufficient to pro duce recognizable changes in the roentgeno gram e g in cases of acute bronchitis th roentgenogram of the chest frequently within normal limits However, in more seve cases or in progressive cases engorgeme frequently leads to exudation into the int stitial tissues, termed by some authorities peribronchial infiltration (2) Pulmonary hyper tension In pulmonary hypertension due to primary pulmonary arteriosclerosis or second ary to lung parenchymal lesions as emphysema or fibrosis there is enlargement of the hilar vessels as well as the arterial branches radiating into the lung fields resulting in accentuation of the lung markings As a rule the hilar prominence due to the dynamically dilated pulmonary vascular roots is sharply defined in contradistinction to passive pulmonary con gestion where the edges are indistinct (3) Passive pulmonary congestion This is basically due to increased pressure in the pulmonary veins e g, cardiac disease Associated roentger findings such as enlarged heart with or withou characteristic pathologic configuration wi help in the diagnosis

2 *Interstitial or peribronchial inflammato infiltration* (1) Acute inflammations involvi primarily the interstitial tissues e g as atyp cal viral or interstitial pneumonia cause creased markings because of the accumulat of inflammatory exudates in the interstitial sues and are usually associated with miliary or larger densities (2) In more chronic inflamma tory conditions such as bronchitis the accen tuation of the markings is due not only to interstitial inflammatory infiltration but also interstitial or peribronchial fibrosis, further

more the findings are altered by superimposition of other conditions such as emphysema and bronchiectasis

3 *Accumulation of bronchial secretions* Replacement of air in the bronchial tubes by secretion produces increased linear densities Alveolar filling and atelectasis may occur as sequelae

4 *Interstitial deposition of endogenous or exogenous substances* This is observed in hemosiderosis, storage diseases and pneumoconiosis In the early stages it is problematical whether the deposit or the associated fibrosis is the cause of the increased linear densities In cases such as silicosis the accentuation of the linear markings is seen only in the early phases of the disease, the evolution is usually progressive and leads to further fibrosis and obstructive phenomena manifested by additional radiopacities and radiolucencies These cases are frequently susceptible to superimposed acute or chronic infection or tuberculosis which adds to the roentgen findings With less innocuous dusts, e g, siderosis the fibrosis may be minimal and not necessarily progressive and in these cases the roentgenograms show, in addition to a fine reticular linear pattern superimposed punctate densities which are apparently primarily due to the deposited material rather than the fibrosis

5 *Lymphatic neoplastic infiltration* Malignant cells may infiltrate lymphatics and occasionally produce linear radiopacities radiating outward from the hilus to the periphery of the involved segment, lobe or lung as in primary bronchogenic carcinoma, metastatic carcinoma (of stomach, breast etc) malignant lymphomas and leukemias Subsequently small nodular infiltrations make their appearance along the thickened streak densities Associated roentgen findings for example a primary lesion outside the chest or involvement of the osseous system may help in the diagnosis

6 *Dilatation or engorgement of the lymphatic vessels* Many of the conditions described previously can lead to engorgement of lymphatic channels and stasis of lymphatic flow These engorged vessels are best seen in the peripheral portions of the lung bases and are not consonant with the normal linear markings

B *Single or Few Radiopaque Strands and Plaques*

Included here are linear streaks or band like radiopacities which are few in number, more localized in character and do not conform to the normal bronchovascular markings Very often the previous history or evaluation of preceding roentgenographic findings will determine the original cause of the linear radiopacity The pathologic examination of these bands, especially if fibrotic, frequently cannot divulge the nature of the original lesion These usually fall into three groups (1) *Focal, disc or plaque like atelectasis* due to stenosis or plugging of small bronchi This produces radiopaque bands running parallel with the bronchovascular markings They are single or multiple and are most frequently located in the bases They may be reversible and rapidly transient or irreversible as a result of organization and fibrosis (2) *Fibrous scars* following granulomatous lesions, suppurations or infarcts These also are manifested by radiopaque streaks or bands or lines and may be localized in any part of the lung (3) *Localized pleural bands and thickenings* such as thickened interlobar fissures peripheral pleural thickening pericardial diaphragmatic and mediastinal pleural adhesions as the result of inflammatory processes The nature of these lesions can be frequently ascertained on the roentgenogram from their location or from their peaked or tent-like configuration

C *Submiliary, Miliary, Granular Radiopacities*

Inflammatory Miliary tuberculosis Bronchiolitis Lobular bronchopneumonia Viral or atypical pneumonia Mycoses Tularemia Cardiovascular and renal Interstitial or lobular edema	Lung dusts (pneumoconiosis) Neoplastic Miliary carcinomatosis Malignant lymphoma and leukemia Pulmonary adenomatosis Sarcoidosis Storage diseases

The underlying pathologic process is due to either of the following singly or in combination (1) Interstitial accumulation or deposition of fluid, inflammatory products, foreign substances or neoplastic cells (2) Alveolar involvement (from several alveoli to groups of acini) by filling with fluid inflammatory products or neoplastic cells, or by loss of air content, or by a combination of both, e g, lobular or capillary bronchopneumonia lobular atelectasis

Both processes give rise to radiopacities in the range of several millimeters and their size or distribution alone cannot determine which of these two types is present This interstitial or alveolar phase may progress to a more ad-

are usually of different sizes apparently the result of multiple metastatic episodes On the other hand in miliary tuberculosis there is a tendency toward uniformity in size and density of the radiopacities Other associated roentgen findings will often suggest the diagnosis e g , in *sarcoidosis a bilateral hilar lymphadenopathy* is frequently present which is usually quite evident on the roentgen examination, in mitral stenosis there are characteristic changes in the cardiac silhouette and hilar enlargement from vascular engorgement

D Nodular (Round or Blotchy) Radiopacities

Solitary	Multiple
Inflammatory	Inflammatory
Tuberculoma	Tuberculosis
Mycoses	Bronchopneumonia
Lung abscess	Lung abscesses
Neoplastic malignant	Mycoses
Primary peripheral carcinoma	Neoplastic malignant
Malignant lymphoma	Metastatic
Metastatic neoplasm	Malignant lymphomas
Pleural tumor	Pulmonary adenomatosis
Neoplastic benign	Cardiovascular and renal
Hamartoma etc	Lung infarcts
Fluid cyst	Arteriovenous fistula
Parasitic	Pulmonary edema
Congenital	Fluid cyst
Cardiovascular	Parasitic
Infarction	Congenital
Arteriovenous fistula	Multiple atelectasis
Small encapsulated pleural fluid	Lung dust diseases
Fibrin body	Blast injuries
Chest wall lesions	Irritating vapors or gases

While there are many exceptions the acute inflammatory conditions and pulmonary edema are usually *blotchy in configuration or have ill* defined edges The chronic inflammatory, granulomatous or lung dust diseases may be either well defined or poorly defined The primary peripheral and secondary metastatic malignant lesions, fluid cysts, as well as *encapsu* lated interlobar effusions are more apt to be well circumscribed

1 Tuberculoma Tuberculomas include the "healed" peripheral initial lesions of tuberculosis, inspissated tuberculous cavities and inactive reinfection foci In all these cases the *shadow is fairly well circumscribed and spheroidal* or oval in configuration For the most part tuberculomas are clinically silent and found on routine roentgen examination in any portion of the lung fields Calcification is frequently present but may be very minimal in extent

As a general rule the presence of calcification in intrathoracic lesions indicates benignity A distinction however, must be made between calcification in a pathologic specimen and so called "calcific density" observed in the roentgenogram In cases in which the calcification is ext however, tion may even with special technics such as spot views Bucky technic or body section roentgenography On occasion densities simulating calcification may be produced by other substances as in lung dust diseases It might also be mentioned here that occasionally *carcinoma of a* retrosternal thyroid may be calcified or malignant tumors invading the mediastinum may surround and incorporate old calcified hilar or mediastinal lymph nodes giving the impression of being calcified

of a single nodule is extremely rare The my cotic infections may mimic any number of here losis not here- atory

studies

3 Benign or malignant neoplastic nodules Most benign neoplasms unless calcified e g radiologic or ctive and the logic studies have various

forms such as spheroidal, ovoid or lobulated In the case of secondary metastatic neoplastic nodules there is no characteristic *radiologic* finding which will indicate the site or type of the primary tumor In the evolution of these

diseases the growth may be slow or rapid and The no ary mo nary adenomatosis as distinguished from the single peripheral type of primary nodular carci noma is usually multiple and shows a rela tively slow growth with eventual coalescence of the nodules to involve large areas of the lung although it simulates repeated episodes of chronic pneumonitis the presence of copious watery sputum in the later stages suggests the diagnosis[8] Malignant lymphomas occur very rarely as single nodules and only occasionally as multiple nodules

4 *Cysts* Parasitic infestation such as the echinococcus is rare in the United States There frequently is peripheral calcification of the cyst The presence of satellite cysts may produce more distinctive findings

Congenital fluid lung cysts are usually sharply defined although if infection super venes a fuzzy outline results The shape of the cyst may change with change in position of the patient and with respiration[9] There are no inal of

5 *Pulmonary infarct* The size and shape of the infarct varies Despite the frequently de

pleural reaction although this may not al ways be evident in the roentgenogram Over a period of time infarcted areas show a slow gradual de crease in size until either resolution occurs or scar replacement results Infarcts may be multiple in cardiac failure or from embolic phenomena Superimposed congestion pulmonary edema and infection usually obscure the infarcts and make roentgen diagnosis difficult or impossible

6 *Pulmonary arteriovenous fistula* Under favorable conditions the fistula shows changes in size during the Valsalva and Muller maneu vers This may be solitary but it usually ap pears as a conglomeration of round shadows and sometimes there is an obvious vascular connection with the hilar vessels The common site is in the lung base A definitive diagnos s may be made by angiocardiography

7 *Fibrin bodies* Fibrin bodies are usually associated with hydropneumothorax and may at times be confused with lung nodules

8 *Encapsulated pleural fluid* Occasionally small collections of pleural fluid especially in the interlobar fissures have a shape that simu lates an intrapulmonary nodular lesions Spe cial views such as the lordotic or lateral recum bent and also body section roentgenography will help to locate the lesion in the pleura

9 *Pulmonary edema* Pulmonary edema may occur in blotches or ill defined areas in both bases or dependent areas In more advanced cases these blotchy areas coalesce into diffuse, mottled densities which at times assume a characteristic butterfly appearance adjacent to the hila in the inner two-thirds of the lung fields the peripheral lung fields remaining well aerated or relatively uninvolved Irritating gases or vapors may result in blotches of radiopacities in both lung fields as in pul monary edema

10 *Pneumonias* Many of the problems of inflammations of the lung which were never satisfactorily resolved within the field of pathology have been carried over in part or whole to the field of roentgenology Frequently infection and inflammation are used as synony mous terms and such terms as atypical pneu monia radiation or allergic pneumonitis are often misused because no roentgen or patho logic criteria exist for their diagnosis Further more the terms pneumonitis or interstitial pneumonitis have certain connotations but no sharp boundaries separating them from other inflammations of the lung and to use these terms in radiologic language further confuses the nomenclature The situation becomes worse when specific etiology as viral or bacterial is coupled with roentgen diagnosis

In smaller lesions roentgen differentiation between inflammatory exudation edema or atelectasis is often impossible In addition the superimposition or summation of numerous shadows simulates confluency or coalescence when such is not the case Oblique or other views can seldom resolve this difficulty Therefore it is best to describe as accurately as possible the roentgen findings as to loca tion extent size and shape or configuration without attempting in smaller lesions to denote underlying pathology as pneumonia or small anatomic structures as lobules or acini Follow up roentgen studies or evolu

tionary appraisal of the process can further aid the clinician by noting complications as obvious atelectasis, cavity formation or pleurisy

In atypical pneumonia there are blotchy radiopacities which pathologically are assumed to consist of areas of interstitial or alveolar exudation edema and atelectasis This includes a large miscellaneous group of pulmonary infections due to viral, bacterial or unknown etiology

Loeffler's syndrome is supposedly an allergic pneumonitis of non infectious nature It shows evanescent patches or blotches of radiopacity associated with increased eosinophils in the blood and sputum and few or no clinical symptoms These blotches do not conform to bronchopulmonary segments and are believed to be edematous areas

In some cases of acute inflammatory processes even though the alveoli are still not flooded with exudate the presence of pleural pain may reflexly or otherwise interfere with proper respiratory movements and aeration of the lung particularly of the basal segments This results in hypoaeration of these segments which further reduces the radiolucency and contrast of the pulmonary fields

E Radiopacities Conforming to Segmental or Lobar Configuration

Inflammatory	Atelectasis associated with fibrosis
Atypical or viral pneumonia	Bronchiectasis
Coalescent bronchopneumonia	Tuberculosis
Lobar pneumonia	*Atelectasis obstructive*
Pulmonary abscess	Bronchial mucus plugs edema etc
Tuberculosis	Inflammatory stricture granulation tissue
Mycoses	Neoplasm
Malignant neoplasm	Cardiovascular
Primary carcinoma	Pulmonary edema
Pulmonary adenomatosis	Pulmonary infarction
Malignant lymphomas	

Densities of segmental or lobar configuration are due to filling of the air spaces with fluid, inflammatory products or neoplastic cells, or are due to atelectasis Various combinations of both alveolar filling and atelectasis can occur While pathologically there is usually no difficulty in differentiating areas of exudation or edema from atelectasis, the roentgen differentiation may be very difficult or impossible unless definite decrease in volume is demonstrable in the roentgenogram

If there is uniform filling of all the alveoli in a bronchopulmonary segment or lobe there is no appreciable change in volume and the roentgen density produced is homogeneous, e g, pneumococcal lobar pneumonia Since the introduction of the sulfanilamides and antibiotics this type of consolidation is only occasionally observed on roentgenographic studies

When there is unequal or irregular filling of the alveoli interspersed with groups of well aerated alveoli there is again no appreciable change in volume of the affected portion of the lung however, the roentgen density produced is heterogeneous or mottled e g coalescing bronchopneumonia

Should there be unequal or irregular filling of the alveoli interspersed with groups of well aerated and groups of atelectatic alveoli again there is a mottled density produced however, there is also a variable decrease in volume of the involved segment or lobe e g, in bronchial adenoma the nature of the obstruction is such that it leads to a variable degree of atelectasis associated with infection

If there is uniform atelectasis of all the alveoli in a bronchopulmonary segment or lobe a dense homogeneous radiopacity results with a definite decrease in volume of that portion of the lung e g, rapidly developing complete bronchial obstruction from any cause Since in practically all types of obstructive atelectasis there is some alveolar fluid present it is obvious that the amount of fluid will determine the extent of the decrease in volume This accounts for the terms dry or wet atelectasis to imply amount of fluid present

In chronic inflammatory conditions in addition to the factors discussed previously there is also a variable degree of fibrosis with contraction of the involved area producing a mottled radiopacity with decrease in volume of the segment or lobe These changes are associated with bronchiectasis Although the term bronchiectasis by definition signifies merely dilation of the bronchi the medical usage usually implies the secondary addition of infection with inflammatory and fibrotic changes involving not only the components of the bronchial wall but also the adjacent lung

Here the dilation is irreversible The associated pulmonary changes are frequently marked but may be minimal in some stages of bronchiectasis The roentgenogram in the latter cases may appear essentially normal

F Contour Radiopacities Bordering the Thoracic Wall

Pleural effusion	Pleural tumor
Inflammatory	Pleural thickening
Tuberculosis	Lesions of the chest wall
Pneumonia	Inflammatory
Subphrenic abscess	Tumors
Cardiovascular or renal	
Heart failure	
Azotemia	
Neoplastic	
Metastatic	
Primary	
Traumatic	

1 *Pleural fluid* The nature of the fluid cannot be determined radiologically Depending on the amount of fluid, the roentgen appearance ranges from a thin ribbon like radiopacity along the lateral chest wall with partial obliteration of the normal costophrenic sinus to a marked radiopacity of practically the entire hemithorax with displacement of the heart and mediastinum toward the sound side The degree of shift of the mediastinum is influenced by the presence or absence of underlying obstructive atelectasis or by mediastinal fixation In massive pleural effusion the con

the pleural space Once air is introduced into the pleural cavity a horizontal air fluid level will be visible only if the central roentgen ray is parallel to the level By changing the position of the patient with respect to the axis of the central ray, the pleural fluid, with or without the presence of air in the cavity, confers a diffuse haziness over the entire hemithorax in the roentgenogram with a loss of the characteristic curvilinear or linear boundaries Loculation of the pleural fluid prevents mobility and the fluid then assumes various shapes from round or oval to bizarre configurations with frequent extensions into the fissures Loculated fluid may appear flattened against the adjacent thoracic wall

2 *Tumors of the pleura* Pleural neoplasms give rise to abnormal, dense, peripheral contours at times suggesting nodular or massive shadows The exact location of these nodules or masses on the pleural surface or in the periphery of the lung can usually be determined by special tangential views Usually pleural fluid is present and thoracentesis is necessary either with or without the introduction of air to uncover the pleural masses

3 *Pleural thickening* This may vary from a thin dense band simulating a small amount of fluid to marked thickening with contraction of the entire hemithorax producing in the roentgenogram a veiling, hazy effect over the entire lung field The frequently present underlying pulmonary disorder may be partly or completely obscured

4 *Thoracic wall lesions* Localized inflammatory or neoplastic lesions of the skin, ribs and soft tissues appear radiographically as round or oval densities sharply demarcated or ill defined By proper projection their peripheral origin can usually be ascertained

G Contour Radiopacities Bordering the Diaphragm

High position	Abnormal contour
Right sided eventration	Fluid
Right sided paralysis	Tumor
Subphrenic disorder	Tenting
Herniation of solid viscus	Mammillation

Accumulations of pleural fluid or inflammatory products, although uncommon, do occur on the diaphragmatic surface and the contour may be irregular or smooth The radiopacities produced are often indistinguishable from a high diaphragm or from subdiaphragmatic solid densities Pleural fluid between the lung base and the diaphragm need not be encysted and in such cases may flow to other parts of the hemithorax with change in the position of the patient In cases of subphrenic abscess, in addition to elevation of the diaphragm, the roentgenograms also show some fluid in the costophrenic angle on the same side, later a gas shadow with a fluid level may make its appearance below the diaphragm Tumors of the diaphragm are rare, induced pneumothorax or pneumoperitoneum will help to differentiate them from mammillation herniation, basal pulmonary tumors and subdiaphragmatic tumors

H Contour Radiopacities Bordering the Mediastinum

Anterior Mediastinum	Malignant Neoplasm
Retrosternal thyroid	Lymphomas
Thymic enlargement or tumor	Bronchogenic carcinoma
Teratoma	Secondary metastatic
Benign dermoid	Lung dust diseases
Malignant	Sarcoidosis
Malignant lymphoma	Posterior Mediastinum
Middle Mediastinum	Tumors of nerve tissue
Inflammatory	Cysts
Primary tuberculosis	Bronchial
Mycoses	Gastroenterogenous
Infectious mononucleosis	Esophagus—achalasia
Other acute and chronic infections	Spine
Cardiovascular	Inflammation
Passive pulmonary congestion	Tumors
Pulmonary hypertension	Marked deformities
Congenital heart disease	Lesions occurring in any mediastinal division
	Aneurysms
	Loculated mediastinal fluid

Many lesions of the mediastinum often give similar shadows which produce mediastinal widening or encroach on either or both lung fields The position of the lesion in the mediastinum is helpful in the differential diagnosis The mediastinum for the purpose of this discussion is divided into anterior middle and posterior divisions as follows the region of the hilus and heart form the middle mediastinum, the region anterior to the heart and trachea is designated the anterior mediastinum, the region posterior to the heart and trachea is designated posterior mediastinum Some pathologic conditions which apparently originate in one mediastinal division may extend into an adjacent division Furthermore there are disease processes which may be found in any of the divisions

1 *Anterior mediastinum* Masses in the anterior mediastinum are usually well demarcated and for the most part benign Substernal thyroid usually shows some compression effect on the trachea and may be partly calcified Unlike other mediastinal masses in this region the retrosternal thyroid may move synchro

[illegible]

adults the rare thymoma may occur anywhere in the anterior mediastinum, this lesion may be benign or rarely malignant Dermoids are usually rounded however, they may occasionally be irregular or lobulated in appearance the periphery or the inner mass is frequently calcified, they may contain formed elements such as teeth and fatty substances may give a layering effect Other teratomas are occasionally malignant Pericardial cysts are rare and usually are located in the cardiophrenic region

2 *Middle mediastinum* Since the size and confi[illegible]

[illegible]

ous

sion

and abnormal is wide and indefinite This is conducive to the radiographically silent development of lesions in this region A great many pathologic conditions (e g, inflammatory, cardiovascular, neoplastic, dust disease) produce hilar vessel engorgement and/or mediastinal, paratracheal and bronchopulmonary lymphadenopathy however these changes frequently do not produce any recognizable abnormal hilar shadows In most malignant lesions by the time obvious shadow differences are recognizable the lesion is already far advanced

Enlargement of the hilus due to marked dilatation of the major pulmonary vessels frequently simulates hilar mass or lymphadenopathy, changes in the cardiac silhouette and in the vascular pattern in the pulmonary fields will usually clarify the situation

Lymphadenopathy may cast a very slight or indefinite shadow, or at the other extreme may produce large lobulated masses which project unilaterally or bilaterally from the mediastinal surface onto either or both lung fields The mediastinal pleura overlying the enlarged lymph nodes or other mediastinal lesions may have smooth well defined edges but if the inflammatory or neoplastic process penetrates the lymph node capsule and mediastinal pleura, it may invade and extend into the adjacent lung giving radiating or irregular margins to these shadows

There are several important differential points in the diagnosis of obvious hilar lymph node enlargement In children the most common cause is primary tuberculosis whereas other conditions are uncommon On the other hand in adults malignant lymphomas, especially Hodgkin's disease predominate these

lesions may be unilateral or bilateral and when bilateral the enlargement is usually asymmetric Obvious hilar lymph node enlargement in reinfection tuberculosis is rare although calcified tuberculous nodes are very common Sarcoidosis shows bilateral fairly symmetric hilar involvement rarely are such nodes calcified In silicosis gross hilar node enlargement may be extensive, the nodes may be calcified and may at times be of the egg shell type In addition there are extensive parenchymal changes in silicosis Bronchogenic carcinoma as a cause of obvious hilar lymph node enlargement without other lung parenchymal signs is rare Carcinoma of the esophagus as a cause of obvious hilar lymph node enlargement is very rare

3 *Posterior mediastinum* (1) Tumors of nerve tissues are paravertebral in location and sharply demarcated Pressure erosion in the region of the intervertebral foramina or pedicles may occur Usually nerve tumors are benign and slow growing (2) Congenital bronchial or gastroenterogenous cysts are uncommon The bronchial cysts are parahilar in location or in the posterosuperior aspect of the mediastinum Such cysts are usually well delineated They may occasionally connect or communicate with the bronchial tree or gastrointestinal tract in which case lipiodol or barium studies may be of help (3) In esophageal achalasia the markedly dilated redundant fluid filled esophagus frequently projects to the right simulating a large tumor barium studies reveal the nature of the lesion Parenthetically it is a good general rule in all suspected mediastinal lesions to study the esophagus with the aid of a barium meal (4) The problem of deformities and other lesions of the spine which simulate mediastinal contour radiopacities can usually be resolved by proper roentgen studies of the spine

4 *Lesions occurring in any mediastinal division* (1) Aneurysms are found in any segment of the thoracic aorta but are most frequent in the ascending portion and arch Calcification is found in both leutic and arteriosclerotic varieties although when found in the ascending aorta they are more probably syphilitic in nature Angiocardiography may be necessary for differential diagnosis from mediastinal masses (2) Loculated mediastinal fluid may occur anteriorly or posteriorly Such cases are difficult to differentiate from mediastinal masses If air is also present it offers the same diagnostic problems as gas fluid pockets in other parts of the chest

LESIONS PRODUCING RADIOLUCENCIES

A *Radiolucent Streaks and Bands*

1 *Subcutaneous emphysema* In subcutaneous emphysema the air is projected through the lung fields and appears as radiolucent streaks These streaks do not conform to the normal lung architecture and are also visible in the soft tissues of the lateral chest wall and cervical region

2 *Bronchi under certain conditions* In some cases of cylindric bronchiectasis with pneumonitis or certain cases of consolidations in which the bronchi remain patent, radiolucent bands may be discernible because of contrasting densities between the air-containing bronchial lumina and the thickened bronchial wall with surrounding inflammation Obviously the bronchial lumina more frequently are not discernible because of retained secretions or inflammatory products

B *Cavitary or Cyst like Radiolucencies*

Inflammatory cavitation	Saccular bronchiectasis
Lung abscesses gangrene	Vesicular emphysema
Suppurative bronchopneumonia	Bullae blebs pneumatoceles
Friedländer's pneumonia	Air cysts
Tuberculosis	Congenital
Mycoses	Echinococcus
Infarction with cavitation	
Neoplastic cavitation	
Bronchogenic	
Hodgkin's	

1 *Cavitation* The underlying pathologic process is always a necrosis of tissue which appears radiopaque until the necrotic material is evacuated through the bronchial tree at which time it acquires a radiolucent appearance The radiolucent zone is associated with some surrounding contrasting pathologic process the external boundary of which may be sharply circumscribed or diffusely hazy and of variable thickness The inner boundary is either regular or irregular in outline and may have a characteristic horizontal gas-fluid level Should the cavity refill completely it will again appear radiopaque Cavitation single or multiple can occur in many conditions and the differential

H Contour Radiopacities Bordering the Mediastinum

Anterior Mediastinum	Malignant Neoplasm
Retrosternal thyroid	Lymphomas
Thymic enlargement or tumor	Bronchogenic carcinoma
Teratoma	Secondary metastatic
Benign-dermoid	Lung dust diseases
Malignant	Sarcoidosis
Malignant lymphoma	Posterior Mediastinum
Middle Mediastinum	Tumors of nerve tissue
Inflammatory	Cysts
Primary tuberculosis	Bronchial
Mycoses	Gastroenterogenous
Infectious mononucleosis	Esophagus—achalasia
Other acute and chronic infections	Spine
Cardiovascular	Inflammation
Passive pulmonary congestion	Tumors
Pulmonary hypertension	Marked deformities
Congenital heart disease	Lesions occurring in any mediastinal division
	Aneurysms
	Loculated mediastinal fluid

Many lesions of the mediastinum often give similar shadows which produce mediastinal widening or encroach on either or both lung fields The position of the lesion in the mediastinum is helpful in the differential diagnosis The mediastinum, for the purpose of this discussion is divided into anterior, middle and posterior divisions as follows the region of the hilus and heart form the middle mediastinum, the region anterior to the heart and trachea is designated the anterior mediastinum, the region posterior to the heart and trachea is designated posterior mediastinum Some pathologic conditions which apparently originate in one mediastinal division may extend into an adjacent division Furthermore there are disease processes which may be found in any of the divisions

1 *Anterior mediastinum* Masses in the anterior mediastinum are usually well demarcated and for the most part benign Substernal thyroid usually shows some compression effect on the trachea and may be partly calcified Unlike other mediastinal masses in this region the retrosternal thyroid may move synchronously with the trachea on deglutition Thymic enlargement is primarily a problem in children, characteristic configuration of sail like shadows and effect on the trachea may be helpful In adults the rare thymoma may occur anywhere in the anterior mediastinum, this lesion may be benign or rarely malignant Dermoids are usually rounded, however, they may occasionally be irregular or lobulated in appearance, the periphery or the inner mass is frequently calcified, they may contain formed elements such as teeth, and fatty substances may give a layering effect Other teratomas are occasionally malignant Pericardial cysts are rare and usually are located in the cardiophrenic region

2 *Middle mediastinum* Since the size and configuration of the normal hilus and contiguous mediastinum offer a wide range of expression, obviously the borderline between normal and abnormal is wide and indefinite This is conducive to the radiographically silent development of lesions in this region A great many pathologic conditions (e g, inflammatory, cardiovascular, neoplastic, dust disease) produce hilar vessel engorgement and/or mediastinal, paratracheal and bronchopulmonary lymphadenopathy, however, these changes frequently do not produce any recognizable abnormal hilar shadows In most malignant lesions, by the time obvious shadow differences are recognizable, the lesion is already far advanced

Enlargement of the hilus due to marked dilatation of the major pulmonary vessels frequently simulates hilar mass or lymphadenopathy, changes in the cardiac silhouette and in the vascular pattern in the pulmonary fields will usually clarify the situation

Lymphadenopathy may cast a very slight or indefinite shadow, or at the other extreme, may produce large lobulated masses which project unilaterally or bilaterally from the mediastinal surface onto either or both lung fields The mediastinal pleura overlying the enlarged lymph nodes or other mediastinal lesions may have smooth well defined edges, but if the inflammatory or neoplastic process penetrates the lymph node capsule and mediastinal pleura, it may invade and extend into the adjacent lung giving radiating or irregular margins to these shadows

There are several important differential points in the diagnosis of obvious hilar lymph node enlargement [11] In children the most common cause is primary tuberculosis whereas other conditions are uncommon On the other hand, in adults malignant lymphomas especially Hodgkin's disease predominate, these

lesions may be unilateral or bilateral and when bilateral the enlargement is usually asymmetric Obvious hilar lymph node enlargement in reinfection tuberculosis is rare although calcified tuberculous nodes are very common Sarcoidosis shows bilateral fairly symmetric hilar involvement rarely are such nodes calcified In silicosis gross hilar node enlargement may be extensive the nodes may be calcified and may at times be of the egg shell type In addition there are extensive parenchymal changes in silicosis Bronchogenic carcinoma as a cause of obvious hilar lymph node enlargement without other lung parenchymal signs is rare Carcinoma of the esophagus as a cause of obvious hilar lymph node enlargement is very rare

3 *Posterior mediastinum* (1) Tumors of nerve tissues are paravertebral in location and sharply demarcated Pressure erosion in the region of the intervertebral foramina or pedicles may occur Usually nerve tumors are benign and slow growing (2) Congenital bronchial or gastroenterogenous cysts are uncommon The bronchial cysts are parahilar in location or in the posterosuperior aspect of the mediastinum Such cysts are usually well delineated They may occasionally connect or communicate with the bronchial tree or gastrointestinal tract in which case lipiodol or barium studies may be of help (3) In esophageal achalasia the markedly dilated redundant fluid filled esophagus frequently projects to the right simulating a large tumor barium studies reveal the nature of the lesion Parenthetically it is a good general rule in all suspected mediastinal lesions to study the esophagus with the aid of a barium meal (4) The problem of deformities and other lesions of the spine which simulate mediastinal contour radiopacities can usually be resolved by proper roentgen studies of the spine

4 *Lesions occurring in any mediastinal division* (1) Aneurysms are found in any segment of the thoracic aorta but are most frequent in the ascending portion and arch Calcification is found in both leutic and arteriosclerotic varieties although when found in the ascending aorta they are more probably syphilitic in nature Angiocardiography may be necessary for differential diagnosis from mediastinal masses (2) Loculated mediastinal fluid may occur anteriorly or posteriorly Such cases are difficult to differentiate from mediastinal masses If air is also present it offers the same diagnostic problems as gas fluid pockets in other parts of the chest

LESIONS PRODUCING RADIOLUCENCIES

A *Radiolucent Streaks and Bands*

1 *Subcutaneous emphysema* In subcutaneous emphysema the air is projected through the lung fields and appears as radiolucent streaks These streaks do not conform to the normal lung architecture and are also visible in the soft tissues of the lateral chest wall and cervical region

2 *Bronchi under certain conditions* In some cases of cylindric bronchiectasis with pneumonitis or certain cases of consolidations in which the bronchi remain patent radiolucent bands may be discernible because of contrasting densities between the air containing bronchial lumina and the thickened bronchial wall with surrounding inflammation Obviously the bronchial lumina more frequently are not discernible because of retained secretions or inflammatory products

B *Cavitary or Cyst like Radiolucencies*

Inflammatory cavitation Lung abscesses gangrene Suppurative bronchopneumonia Friedlander's pneumonia Tuberculous Mycoses Infarction with cavitation Neoplastic cavitation Bronchogenic Hodgkin's	Saccular bronchiectasis Vesicular emphysema Bullae blebs pneumatoceles Air cysts Congenital Echinococcus

1 *Cavitation* The underlying pathologic process is always a necrosis of tissue which appears radiopaque until the necrotic material is evacuated through the bronchial tree at which time it acquires a radiolucent appearance The radiolucent zone is associated with some surrounding contrasting pathologic process the external boundary of which may be sharply circumscribed or diffusely hazy and of variable thickness The inner boundary is either regular or irregular in outline and may have a characteristic horizontal gas-fluid level Should the cavity refill completely it will again appear radiopaque Cavitation single or multiple occur in many conditions and the differen

diagnosis among septic, tuberculous or neoplastic lesions may be difficult

2 *Saccular bronchiectasis* This may be congenital or acquired, unilateral or bilateral and may involve a segment, a lobe or an entire lung The saccules when empty appear as multiple cyst-like radiolucent spaces surrounded by various degrees of radiopacities as a result of

or have gas fluid levels depending on the amount of retained secretions

3 *Vesicular emphysema (focal emphysema)* On occasion during resolution of pneumonia or bronchial infections, especially in children, temporary, partial block of the smaller bronchi occurs leading to transient and reversible single or multiple foci of obstructive emphysema which have the appearance of cyst like or vesicular radiolucencies within the area of clouding

4 *Blebs bullae and pneumatoceles* These are thin walled radiolucencies which rarely contain fluid and are associated with pulmonary fibrosis Depending upon their number and distribution and the condition of the surrounding lung parenchyma, these radiolucencies assume a round, oval, pyramidal or polyhedral configuration The mechanism of their production is apparently on the basis of obstructive emphysema Overlying lung parenchyma may partially obscure these radiolucencies Occasionally the condition is progressive with the development of "vanishing lung" In large pneumatoceles the involved portion of the lung is increased in volume and the adjacent lung shows crowding of the bronchovascular markings, and if the pneumatocele is very large, there may be changes in spatial relationships of the entire hemithorax or chest

5 *Congenital lung air cysts* Those fluid cysts which communicate with the bronchial tree or pleural cavity may be partially or completely evacuated producing a radiolucent zone usually with a well defined wall If the wall is very thin, an air cyst cannot be differentiated from a bulla or a pneumatocele radiographically If the cysts become infected, the radiologic appearance is such that they cannot be differentiated from abscess cavities

6 *Echinococcus cyst* The echinococcus cyst may partially evacuate into a bronchus to produce a gas fluid level configuration Proper examination of the evacuated material will reveal the pathognomonic scolices

C *Radiolucencies Conforming to a Segment(?), Lobe or Entire Lung*

These include obstructive emphysema, compensatory emphysema bilateral emphysema and pulmonary embolism without infarction

The term emphysema simply signifies overinflation and dilatation of the pulmonary alveoli This implies that there must exist criteria for (1) normal alveolar size, from the microscopic point of view, (2) normal intra alveolar pressure, from the functional point of view, (3) normal gross appearance, from the pathologic or radiologic point of view Unfortunately such criteria are not too well defined

Radiologically the essence of the definition i e, overinflation of alveoli can only be expressed by the concept of increased radiolucency However, the degree of radiolucency is only a subjective impression which is difficult to measure roentgenographically Furthermore, the degree of radiolucency depends on such variables as patient characteristics and x ray technical factors as mentioned previously In addition other associated pulmonary, pleural or cardiovascular changes may decrease or even obscure the radiolucency The associated changes in spatial relationships of the thoracic structures although very important for the diagnosis of emphysema are also difficult to evaluate except in extreme cases

Such descriptive terms as compensatory emphysema or senile emphysema are very often misnomers or have no suitable criteria For example, compensatory emphysema obviously does not signify a physiologic compensation [11] Here there is purely a physical rearrangement of distensible lung as a result of changes in intrathoracic or intrapulmonary pressure It is conceivable that this overdistention may actually decrease the physiologic efficiency of the involved portion of the lung

With these points in mind it is not surprising therefore, to find marked discrepancies in the correlation of the clinical, pathologic and roentgen findings in problems of emphysema

1 *Obstructive emphysema* A most important condition causing radiolucency or hyperaeration of a lobe or lung is emphysema due

to partial bronchial obstruction by means of a ball valve type of mechanism Both inspiratory and expiratory films may be needed to demonstrate this finding In pronounced cases of unilateral obstructive emphysema the expiratory film is much more informative showing a definite increase in the radiolucency of the obstructed lobe or lung depression of the ipsilateral diaphragm and a shift of the mediastinum toward the sound side In bronchial obstruction of this type the series of events starts with slight emphysema and then progresses to pronounced emphysema From this point of maximum hyperaeration there is a gradual or rapid loss of air eventually leading to obvious atelectasis of the obstructed lobe or lung The site and degree of obstruction may be relatively easy to determine only at both extremes of emphysema and atelectasis The transitional phases between these two extremes may be very difficult or impossible to evaluate either as to site or degree of obstruction even with films taken on inspiration and expiration

2 *Compensatory emphysema* Secondary to fibrotic contraction of one hemithorax massive obstructive atelectasis or surgical resection of a substantial portion of lung tissue the contralateral lung distends and becomes hyperaerated This ballooned lung may even extend across the midline into the opposite hemithorax If the atelectasis or fibrotic contraction is localized to a segment or lobe the adjacent or surrounding lung may show increased radiolucency as a result of physical rearrangement this may be less definitive or obvious than in the case of involvement of an entire lung

3 *Bilateral emphysema* Without discussing the types or mechanism of development obvious bilateral hyperaeration shows an increase in the radiolucency of both lung fields with or without increase or decrease in the lung markings Increase in the volume of the thorax and depression of both leaves of the diaphragm are frequent accompaniments The increased radiolucency is apparently due to some loss of parenchymal lung tissue (including a decrease of the vascular bed) coupled with an increase in the air content of the lungs As a result of these changes plus a decrease in the systemic venous return the heart assumes a more elongated and narrowed configuration which obscures the frequently present right ventricular enlargement

4 *Pulmonary embolism without infarction* A radiolucent segment or lobe is possible when large emboli involve branches of the pulmonary artery without infarction The mechanism apparently involves the plugging of the major vessels near the hilus with emptying of the blood from its tributaries in the segment beyond therefore resulting in a decrease in the linear shadows normally cast on the roentgenogram is

D *Contour Radiolucencies Bordering the Thoracic Wall Mediastinum and Diaphragm*

Bordering the thoracic wall	Gas-fluid pockets
Pneumothorax and hydropneumothorax	Abscess
Spontaneous	Hydropneumothorax
Inflammatory	Congenital cysts
Induced	Bordering the diaphragm
Bronchopleural fistula	Paralysis of the left diaphragm
Traumatic	Eventration of left diaphragm
Bordering the mediastinum	Diaphragmatic hernias (hollow viscus)
Mediastinal emphysema	Pneumoperitoneum
Lung hernia	Subphrenic abscess
Hernia of viscus (hollow)	

1 *Thoracic wall* Introduction of air into the potential pleural space results in a peripheral zone of radiolucency without lung markings bounded by the chest wall or mediastinal surface and the fine curvilinear density of the visceral pleura of the partially collapsed lung Air may enter the pleural space as a result of conditions which may or may not be evident on the roentgenogram Very minor degrees of pneumothorax are frequently overlooked and are best demonstrated with expiratory films If the pneumothorax is extensive and of the tension type (ball valve mechanism) there is not only an increase in radiolucency of the hemithorax with lack of pulmonary markings but also depression of the ipsilateral leaf of the diaphragm compression atelectasis of the underlying lung and even possibly a mediastinal shift to the contralateral side Fluid may initially be present with pneumothorax or may appear later depending on the type of underlying lesion Synechia of the pleura may also be present initially or may develop subsequently The presence of these adhesive bands leads to localized areas of radiolucency which in combination with fluid and underlying lung disease produces bizarre distortions

of the lung, mediastinum or diaphragm The resulting loss of the normal landmarks makes the evaluation of the roentgen findings more difficult Pneumothorax or hydropneumothorax trapped in unusual locations may at times be difficult or impossible to differentiate from intrapulmonary conditions, as pneumatoceles, "vanishing lung" cavity, or extrapulmonary conditions as diaphragmatic herniation of a hollow viscus

2 *Mediastinum* (1) Mediastinal emphysema is characterized by a radiolucent band bounded by the mediastinal pleura on one side and by the mediastinal structures on the other side (2) Lung "herniations" usually occur anterior to the heart with displacement or protrusion of the pleura across the midline by the ballooned lung into the opposite hemithorax, less commonly across the midline in the retrocardiac region, and rarely across the posterior part of the upper mediastinum Radiographically it appears as a curvilinear density with the convexity toward the opposite hemithorax (3) The problem of herniation of a hollow viscus as mentioned before, is usually resolved by barium studies (4) Gas fluid

3 *Diaphragm* Paralysis of the left leaf of the diaphragm, eventration with gaseous distention of a hollow viscus beneath and diaphragmatic hernia of a hollow viscus at times simulate other radiolucent intrathoracic lesions Barium studies are frequently necessary to differentiate these

CONCLUSIONS

Despite the lack of specificity of roentgen signs, roentgenology of the chest is a most important method of recording and evaluating organic intrathoracic lesions The present lack of specificity will be reduced to a minimum only after a sufficient number of controlled cases, complete with clinical, laboratory and pathologic data, are made available for proper statistical analysis In the meantime the drawbacks resulting from the lack of specificity can be reduced by making greater use of the best available roentgen methods

Acknowledgment For the preparation of illustrations the authors are indebted to Miss Shirley Baty

REFERENCES

1 NEWELL, R R and GARNEAU, R The threshold visibility of pulmonary shadows *Radiology*, 56 409–415, 1951
2 MILLER, W S The Lung, 2nd ed Springfield, Ill, 1947 Charles C Thomas
3 COCCHI U In SCHINZ, H R et al Roentgen Diagnostics vol III, pp 2758–2790 New York, 1953 Grune & Stratton
4 WESTERMARK, N Roentgen Studies of the Lungs and Heart Univ of Minn Press, 1948
5 RABIN, C B In Golden s Diagnostic Roentgenology, vol I, pp 192Z 193F Baltimore 1952 Williams & Wilkins Co
6 FLEISCHNER, F HAMPTON, A O and CASTLEMAN, B Linear shadows in the lung *Am J Roentgenol* 46 610–618, 1941
7 CULVER, G J, CONCANNON J P and MACMANUS J E Pulmonary tuberculomas *J Thoracic Surg*, 20 798–822 1950
8 ABELES H and CHAVES, A D The significance of calcification in pulmonary coin lesions *Radiology*, 58 199–203 1952
9 KING, J C and CARROLL, D S Pulmonary adenomatosis *Radiology*, 55 669–680, 1950
10 ROBBINS L L The roentgenologic appearance of bronchiogenic cysts *Am J Roentgenol*, 50 321–333 1943
11 TWINING, E W In SHANKS S C and KERLEY, P Textbook of X-Ray Diagnosis 2nd ed, part II Respiratory System Philadelphia, 1951 W B Saunders & Co
12 RIGLER, L G Pulmonary embolism without infarction *Am J Roentgenol*, 60 460–465 1948

13

Fluoroscopy

CHARLES B STORCH, M D, *Brooklyn, New York*

WHILE fluoroscopy as a series of fleeting glimpses should rarely be considered sufficient in itself to establish a diagnosis it does provide a valuable and often necessary preliminary to the more leisurely and detailed film examination particularly when such a complex mass of moving parts as the chest is involved Its main advantages over filming are observation of motion (i e active physiology) and the most advantageous positioning of the patient for subsequent roentgenograms

THE EXAMINATION

In preparation for examination the patient is placed behind the fluoroscopic screen facing the examiner with the x ray tube behind him His chest touches the screen to avoid excessive magnification and hence distortion The patient is stripped to the waist but may wear a light weight gown

The physician s main preparation is accommodating his eyes to the situation The subject of dark adaptation has been dealt with in detail elsewhere Suffice it to say here that the examiner s eyes are ready when he can see the medium sized pulmonary vessels as a fine reticulated pattern adjacent to the hilar shadows This pattern will appear most prominent in the middle lung field gradually fading out and disappearing as the vessels approach the lung peripheries In this connection it should be mentioned that the day is already present when with the use of apparatus employing image intensification more accurate fluoroscopy can be performed even though no attempt be made at previous dark adaptation

The fluoroscopist s examination will be most rewarding if a definite plan is followed (1) general survey of the chest (2) positioning and localization (3) detailed survey and (4) observation of diaphragmatic and mediastinal movements

General Survey The first rapid survey is with wide open shutters the entire chest being visible The butterfly shaped hilar shadows are noted as landmarks the patient s left hilus normally being a little higher than the right Conversely the left diaphragm will normally appear somewhat lower than the right (which is pushed upward by the liver to about the level of the sixth rib anteriorly)

Under normal circumstances both lung fields will be equally illuminated and the reticulated pattern of the branching pulmonary artery as noted will appear prominent in the inner third of each lung field fading out toward the peripheries

The mediastinal shadow presents a problem in anatomy for it is composed of a number of structures the normal shape of which must be familiar to the examiner if abnormality is to be detected

Ordinarily this first rapid gross survey will not reveal abnormal opacities but since the examiner must pass judgment on the shadows he does see he must be aware of the criteria for a visible lesion and the normal shadows which may be confused with abnormality

The Visible Lesion It must be (1) large enough (2) dense enough and (3) viewed from the most advantageous angle

1 Usually unless the lesion is at least about ½ inch in its greatest diameter it cannot be seen fluoroscopically

2 The lesion may have grown considerably larger than ½ inch but still not be visible because it is not dense enough to cast a definite shadow as sometimes occurs in pneumonia early tuberculosis or neoplastic metastasis (although the x ray film may show up the disease in such instances)

3 The problem discussed here is of a shadow with such a density so that in one view its margins fade out gradually whereas in another view its margins end abruptly A spindle shaped shadow is one type in mind In one projection the fading margins are present in the other it is only seen as a circle When such

a lesion is present in the lung parenchyma, physiologically, the eye finds it more difficult to see when so viewed that its margin is not sharp but fades out It becomes easier to see as the patient is rotated and an appearance of a solid ball is projected so that the distinction between normal and abnormal is sharp and abrupt

Confusing Normal Shadows The *nipple* is seen as a nodular shadow above the faint haze cast by the base of the breast Because of possible confusion with a nodular type lesion, the examiner must confirm the presence of nipple If the breast is moved and the nodular shadow moves with it the shadow is the nipple, if it does not so move, it is not the nipple and calls for further investigation The *vertebral borders of the scapula* must be recognized as such if they are not to be confused with lobar consolidations *Overlying neck muscles* may shadow the apices of the lungs, manipulation of these muscles by hand should clear up the field, although special apical roentgenograms must be resorted to occasionally *An opacity in the base of the neck* may appear either on the film or fluoroscopically to be present in the lung apex Again to clear the dilemma, the patient is placed behind the screen, and after locating the questionable shadow the examiner attempts to grasp it with his fingers If he can then manipulate it so that movement of the questionable shadow is visible on the screen, the presence of the lesion in the neck (rather than lung apex) is confirmed *Chondral cartilage calcifications* are sometimes seen as multiple shadows Fluoroscopic confirmation comes from viewing their movement with the ribs on respiration [illegible]
may be due
of the dorsa
due to the spinal shadow, the examiner fixes his gaze on the questionable portion of the mediastinal shadow and rotates the patient to either side A *spinal* shadow becomes obvious with this maneuver

Positioning and Localization If a suspect opacity has been noted on the general survey, positioning must be done before detailed examination can take place This is simply to say that the most advantageous position for viewing the abnormality is determined so that [illegible]

Exact localization of the lesion can, of course, be determined by taking a number of x ray films, but the fluoroscope can often accomplish the same end with relatively greater speed The lesion has been seen in two dimensions length and breadth, now it must be pin pointed in terms of depth Is it in the anterior or the posterior lung field? Several methods may be used

First, if an object (lesion) is placed between a source of light (tube) and a surface upon which its shadow can be cast (screen), the shadow will be larger and hazier the further the object is from the shadow surface, conversely, a smaller and more distinct shadow will result the closer the object is to the shadow surface Fluoroscopically applied, if the abnormal opacity appears smaller and more sharply demarcated when the patient faces the examiner than when he is turned with his back to the screen, the lesion may be assumed to be in the anterior field The reverse situation indicates posterior localization (Fig 1)

Secondly, one may picture a circle, such as a clock face laid flat, 12 o'clock represents the posterior field, 6 o'clock the anterior If this circle (representing the patient) is rotated in clockwise fashion, an object (lesion) in the "12" area will move from left to right—in the same direction as does the spine, an object in the "6" (anterior) area will move from right to left (Fig 2)

Fluoroscopically, this "law of the circle" not only establishes anterior or posterior field but also can be carried a step further to approxi [illegible]

about the same speed as the rotated patient will advise the fluoroscopist of a peripherally located lesion, while a slow moving lesion should be deep seated

Finally, normal thoracic movement may be put to diagnostic use It will be important to determine whether a lesion adjacent to a *rib* is free or attached to the rib During inspiration the ribs move upward and the diaphragm descends, the expanding lungs following this descent. Hence if the lesion follows the downward movement of the lung on inspiration, it is within the lung, if it moves upward, following the ribs it should be adherent to the rib

Detailed Survey. If the first general examination yielded negative results, a detailed survey follows immediately. Even if a lesion is discovered and localization and positioning takes place, a more intimate scrutiny will now be necessary.

The shutters are narrowed to increase contrast, and, starting with the lung apices, the screen is moved down section-by-section, examination of each area including a comparison of left and right sides. Deep inspiration will show air entry by increased illumination,

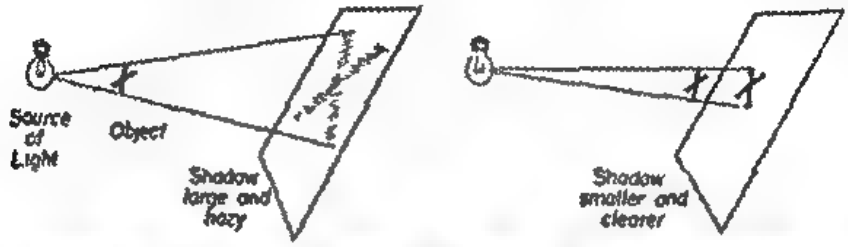

posteriorly

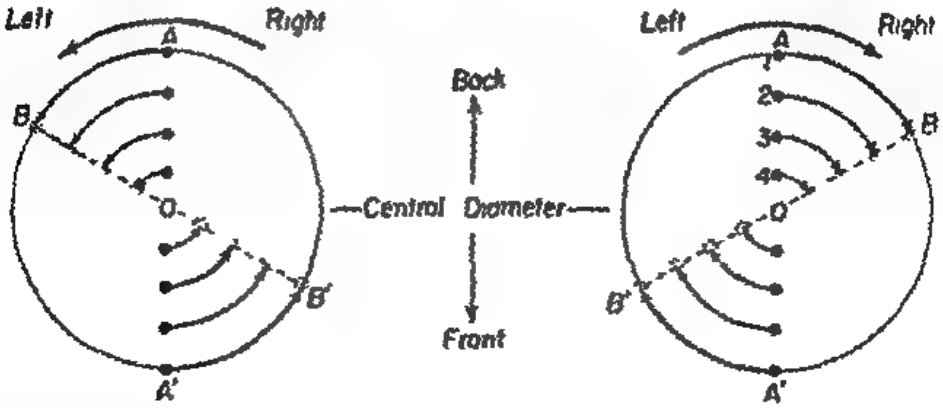

FIG. 2. The circle itself should represent the patient. A the patient and A the sternum. All structures in the posterior half of the chest rotate in the same direction as A. Structures anteriorly rotate with A.

FIG 3 Sharp indentat on (B) found in the r ght d aphragm produc ng cusp (A) th is is a normal variant

sometimes the patient is requested to cough for this purpose The supraclavicular areas sub clavicular the mid lung fields and lung bases are studied for abnormalities in this fashion

At the base of the lungs the diaphragms are now observed and it should be noted that certain variations in contour are normal (It has already been mentioned that the right diaphragm is normally higher than the left) Furthermore a sharp indentation in the nor mally smooth curve of the right hemidia phragm (Fig 3) may be caused simply by a fibrotic band while under other circumstances the left hemidiaphragm—normally low—may be raised by the stomach air bubble or by splenic flexure of the colon The stomach air bubble is recognized fluoroscopically by its round contour and absence of inner haustral markings splenic flexure by haustral markings within air distended loops Both conditions must be distinguished from eventration of the diaphragm

As a matter of fact the careful examiner will always observe the subdiaphragmatic area particularly studying the stomach air bubble (Fig 4) Normally the magenblase is thin walled when filled with air fitting snugly beneath the diaphragmatic cusp If however with the patient in upright position space of

carcinoma of the cardia of the stomach Again however normal shadows must be considered one must rule out the distorting effect of thickened mucous membrane of the stomach and impingement of the liver heart splenic flexure and in some individuals the spleen Ordinarily a pear shaped magenblase means normal secretion while a spherical air bubble [illegible] fasting patient)

Problems D termining fluid levels Since fluid levels may show up fluoroscopically in any part of the chest it is imperative that the examiner be able to ascertain with certainty whether the questionable shadow line actually is fluid or represents a density of some other nature The procedure is simple A glass partly filled with water will show a horizontal line representing the fluid level parallel to the floor No matter how the glass is tilted the fluid level will remain parallel to the floor On the contrary a non fluid horizontal line on the glass itself (e g a dried ring left by a previous fluid) will tilt when the glass is tilted The same principle applies fluoroscopically If a shadow is seen on the chest with a horizontal straight edge at top which gives rise to suspicion of fluid (as seen in pleural effusion or in an abscess cavity) the patient should be tilted in various direc tions and the effect of such tilting on the sus pect shadow line observed (Fig 5)

With the patient in the frontal position this method will not always give satisfactory results Observation laterally may discover a fluid level not otherwise seen (as for example in the posterior costophrenic sinus) At times the findings will be more clearly made if the rays are used horizontally with the patient in a supine position

Infiltrations or lymph nodes versus blood vessels On occasion it will be important to [illegible]

Valsalva maneuver can be put to advantage With intra alveolar pressure thus increased the pulmonary vessels are compressed with consequent decreased degree of filling and on the fluoroscopic screen the radiating pattern of these vessels becomes thinner and less pronounced [2] Lymph nodes and hilar glands on the contrary are not affected in this fash on by such increase in pressure largely retaining their size shape and prominence and thus the d stinction is made Additionally with the Valsalva maneuver the narrowing and fading

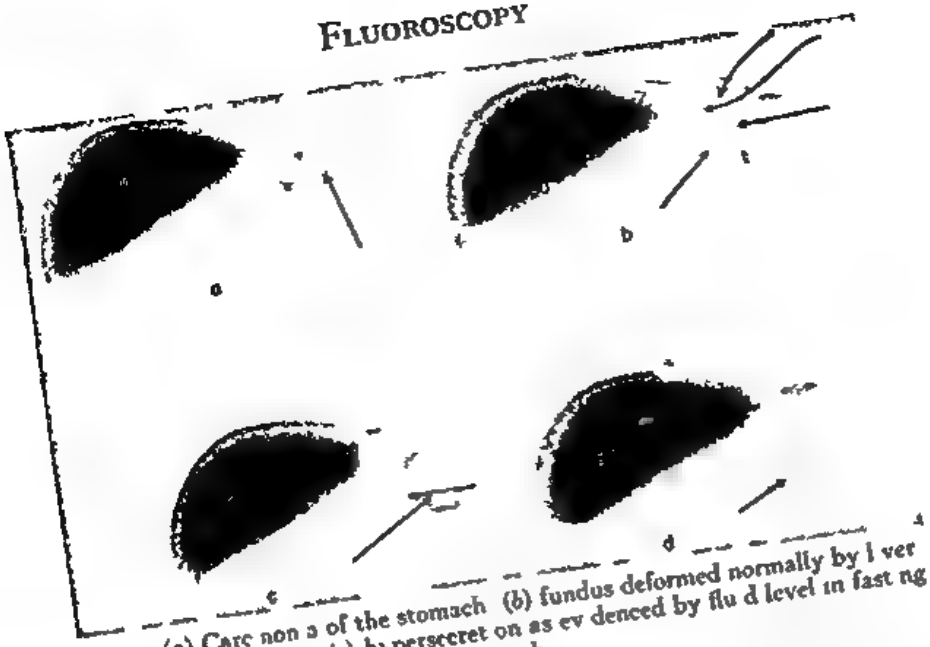

FIG 4 (a) Carcinoma of the stomach (b) fundus deformed normally by liver splenic flexure heart (c) hypersecretion as evidenced by fluid level in fasting stomach (d) normal pear shaped stomach

out of hilar vessels frequently reveals large glands formerly covered and hidden

To further distinguish blood vessels from lymph nodes rotation can be used If the patient is turned a blood vessel shadow may elongate or disappear whereas little or no change in shape will be noted with lymph nodes or glands

Pseudocavity This is in effect a normal shadow which may be confused with a disorder but its occurrence is common enough both fluoroscopically and on the x ray film that it warrants special mention Fortuitous combinations of overlapping shadows of normal blood vessels sometimes produce the appearance of a cavity The distinction between real and apparent is easily made by rotating the patient behind the fluoroscopic screen A true cavity will move and continue to be seen as the patient rotates while a pseudocavity due to blood vessel overlap will quickly disappear

Observation of Diaphragmatic and Mediastinal Movements Closely allied with the detailed survey this part of the fluoroscopic examination is of paramount importance for the chest physician or surgeon for actual function or the lack of it can be seen and this is often important in making a diagnosis

Diaphragmatic movements We have already noted how the up and down diaphragmatic movements during respiration can be visualized fluoroscopically Lack of such movement however is sometimes difficult to detect because the moving rib shadows create the optic illusion of diaphragmatic movement The degree of movement if there is movement at all can be determined by the following simple procedure The shutters are narrowed so that only the diaphragmatic cusp shadows and a small illuminated area of lung above them are seen This space (aerated lung) is watched not the diaphragms When the patient inspires the space should become larger as the lung fills with air and pushes the diaphragms down on expiration the space should become smaller (the diaphragms rising) (Fig 6) With experience, the observer can determine whether the movements are normal increased or decreased If the space does not change with respiration there is no diaphragmatic movement (paralysis)

(An even simpler method is to provide a stationary landmark as a point of reference by the examiner placing his finger on the screen atop the diaphragmatic shadow one need only observe whether the shadow moves away from the fingertip on respiration—and how much or whether it remains stationary)

Lack of movement however may not be pathologic Some individuals customarily breathe without diaphragmatic excursions if asked to sniff however they will show a short jerky movement of the diaphragm which rules out paralysis

Diminished diaphragmatic movements While increased movements as a persistent flutter may accompany epidemic encephalitis in



FIG 5 A shadow in right lung field to be tested for fluid level B patient leaning toward right and left reveals horizontal shadow remaining parallel to floor thereby confirming presence of fluid level



FIG 6 A space between diaphragm and upper shutter smaller (expiration) B space between diaphragm and upper shutter large (inspiration) C, space between diaphragm and upper shutter neutral position

fluenza and cardiospasm associated with hypocalcemia decreased diaphragmatic movements are usually of more specific diagnostic value The decrease may be on either or both sides *It may be of subdiaphragmatic or intrathoracic* origin (an important point in pneumonia) The ultimate in decreased movement is of course paralysis

A paralyzed diaphragm can be diagnosed by the previously mentioned methods including the sniff test and the examiner should also be aware of so-called paradoxic movements (Kienbock's phenomenon) which is indicative of one sided paralysis (Fig 7) On inspiration the normal hemidiaphragm will descend in normal fashion while the abnormal side will *simultaneously rise because the increased* intra abdominal pressure is transmitted to the paralyzed hemidiaphragm pushing it upward On expiration the mechanism works in reverse This phenomenon is noted occasionally in atelectasis and in some inflammatory lung lesions With correction of the condition the

lung the

lung frequently spreads metastatically to involve the phrenic nerve and since the phrenic nerve exercises control over diaphragmatic movement diaphragmatic rise and paralysis *ensues Opinion on the operability of such* cases is divided but the important point for the examiner is that if a patient with cancer of the lung is fluoroscoped and the diaphragm in question is seen high and presents evidence of paralysis (Kienbock's phenomenon) phrenic nerve involvement must be suspected

Paralysis of the phrenic nerve has been said *to be the cause for eventration of the* diaphragm The nerve paralysis may be only partial and diaphragmatic movements may or may not be present in such case but the involved diaphragm will be raised high Since the condition usually occurs on the left side it may be confused with simple raising of a normal diaphragm by bowel or gastric air distention (The left diaphragm lies directly against the intestine and can be pushed up thus

by gas but the right diaphragm will not be seen to rise from such cause since the liver intervenes) The differential diagnosis can usually be made by watching for diaphragmatic movement The eventrated diaphragm presents evidence of paralysis (Kienbock s phenomenon)

Mediastinal movements These movements are of obvious value in examination of the heart but since the latter could well be a monograph in itself and has been described in essentials elsewhere[1] we shall confine ourselves to a brief discussion of mediastinal movements associated with pulmonary disease

Significant changes in mediastinal movement are sideways These shifts sometimes easy sometimes hard to detect are observed by a technic similar to that used in examining for the up and down movements of the diaphragm The fluoroscopic shutters are narrowed so that the examiner sees only the mediastinal shadow with a long narrow segment of illuminated lung on either side On inspiration these segments of aerated lung should become larger the mediastinal shadow contracting This contraction is normally bilaterally equal i e the mediastinum should not be displaced toward one or the other side If on inspiration the visualized lung segment on the left enlarges and the segment on the right decreases the mediastinum is shifting to the right (or vice versa) The shift may also occur on expiration In either instance a pathologic condition is indicated Having the patient take short deep breaths will exaggerate the movement

On *inspiration* mediastinal shift toward one lung means that that lung has decreased intrathoracic pressure (i e it is not receiving the full complement of air that the other side is getting) This occurs for example in bronchostenosis of one side and in marked bullous emphysema where blockage of the smaller bronchi obstructs free entry of air On *expiration* mediastinal shift away from one lung indicates some such condition as emphysema with a ball valve type of obstruction which does not allow normal egress of air (i e the affected lung is retaining more air than the normal lung) In all instances pathologic mediastinal movement is *away from* the lung with greater intrathoracic pressure (showing as enlarged illuminated lung area on the fluoroscopic screen) *toward* the lung with less pressure (showing as decreased less illuminated lung area on the screen)

Fluoroscopic study to determine if a mediastinal mass is pulsating is somewhat more difficult and demands experience The shutters are narrowed down on the abnormal shadow to avoid secondary radiation The difference be-

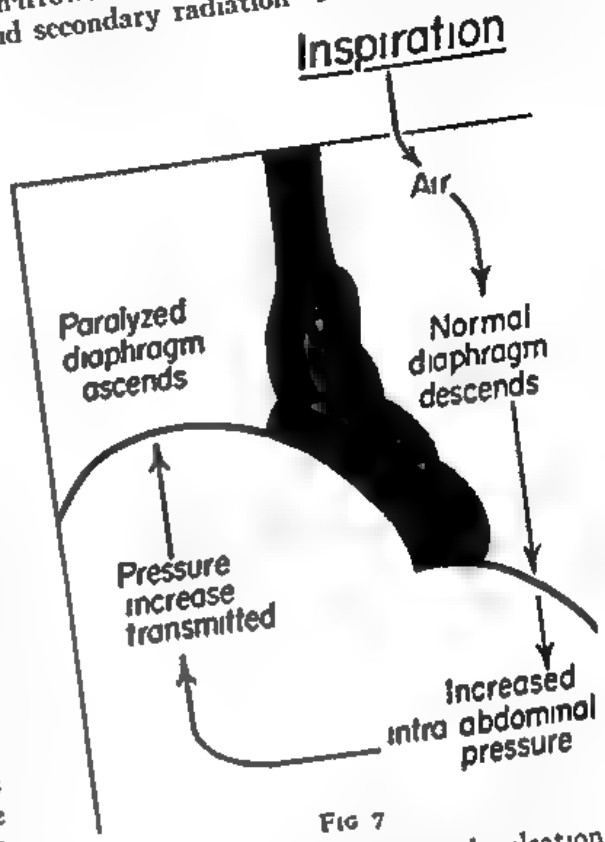

FIG 7

tween expansile and transmitted pulsation can only rarely be seen fluoroscopically

Examination of the mediastinum should also include study of the esophagus Detailed study[1] of the subject is beyond the scope of this portion however and we can only say here that the examiner must be familiar with the normal course of the tract normal variations and impinging structures before he can hope to understand pathologic manifestations on the fluoroscopic screen

SPECIFIC PATHOLOGY

Fluoroscopic observation of certain pathologic conditions in the chest has been discussed in connection with various maneuvers and phases of the examination Following is a brief exposition of how the examiner may specifically investigate some of the more commonly encountered disease processes in the chest by the use of fluoroscopy

Tracheal Deviations The trachea like the esophagus should be examined as part of the

FIG 8 Mass deforming trachea and rising with deglutition is apt to be substernal thyroid

chest survey and, again, the normal course and variations should be familiar to the examiner An example of normal deviation which may be confused with a disorder is the slight deviation to the right (with the patient in the frontal position) as the trachea passes behind and to the right of the aortic arch Pathologic angulation must be distinguished from such normal variations, substernal thyroid is often implicated, and the diagnosis must be confirmed by further study

Fluoroscopic examination will also give clues to the firmness and resistive powers of the trachea [3] The Valsalva maneuver is utilized to this end (or, alternatively, having the patient cough) With intratracheal pressure increased in this fashion tracheomalacia will be visualized by wide dilation of the previously narrowed segment Conversely, the Muller experiment on expiration (or asking the patient to sniff) will demonstrate softening of the tracheal wall by marked narrowing of the involved area In either instance the malacia may be one-sided and visualized as eccentric In any event conclusive evidence of softening of the tracheal *rings is a serious prognostic sign of possible* tracheal collapse and sudden death, and in such case fluoroscopic findings give a clear indication for operation Substernal thyroid may be implicated, or long-existing goiter or mediastinal tumor

Substernal Thyroid Substernal thyroid manifests itself fluoroscopically as a mass in the upper mediastinum, adjacent to and very likely angulating the trachea Other conditions can produce the same appearance, so that confirmation is needed Tracheomalacia as a concomitant finding (noted previously) gives some degree of additional evidence To clarify the diagnosis further, the patient is asked to swallow If the suspect shadow rises with the swallow, then falls back, the observer can assume that the mass is adherent to the trachea (Fig 8) Substernal thyroid is the most common condition showing these features

One important point should be mentioned in connection with the swallowing maneuver The physician may experience difficulty in seeing the abnormal shadow rise on deglutition This may be laid in large part to the expectation of seeing a very pronounced movement whereas in reality the rise is small One can test this by placing his finger on the larynx and swallowing, the rise is perhaps no more than ¼ inch, even though it can be felt quite distinctly The same "finger test" as mentioned earlier, then, can be used here The examiner's finger (as a stationary point of reference) is placed on the screen at the inferior border of the shadow in question The patient swallows If the shadow moves up and away from the finger, no matter how small, the movement should be clearly seen, and the diagnosis of adherent mass is made

Subdiaphragmatic Abscess versus Primary Intrathoracic Pneumonia A common radiographic finding in postoperative patients is a pneumonic process in the lower lungs Here the joint radiographic-fluoroscopic study can determine with considerable accuracy whether the involved lung area suffers lymphatic extension from a subdiaphragmatic abscess or whether a pneumonia of intrathoracic origin is present The following points give clues (1) In subdiaphragmatic abscess, diaphragmatic movements become restricted at an early date, with the diaphragm eventually raised and fixed Although decreased movements also occur (but not always, and to a less obvious extent) in primary intrathoracic pneumonia, rarely does the diaphragm become as rigidly

fixed (2) In subdiaphragmatic abscess, the pneumonic process is visualized as closely adhering to the diaphragmatic outline In a primary pneumonia the pathologic shadow is not so closely confined to the diaphragm, greater hilar involvement is noted on the

monia that extends through the pleural lymphatics to the lung, hence, pleural effusion with obliteration of the costophrenic sinus on the diseased side often occurs—a sign less commonly observed with primary intrathoracic pneumonia (4) Accumulation of air and a

from subdiaphragmatic air space without fluid level occurring in laparotomy patients[6] Most

is normally about 20 cm If this distance increases, a subdiaphragmatic abscess must be suspected of pushing the liver down Obviously this finding must be assessed in relation to other findings, the liver may be enlarged, or some other structure may be displacing the liver downward

Atelectasis The fluoroscope offers the opportunity for certain specific observations in diagnosing this condition The pulmonary arteries, as shadows radiating out from the hila, on inspiration normally fan out and greatly separate When a lung is partially collapsed

Abnormal lack of the normal fanning movement can be more clearly seen by comparison with the changing pattern in the uninvolved lung areas

Atelectasis of the right middle lobe, particularly, may not be seen when the patient is in the frontal position because the upper lobe overlaps it anteriorly, the lower lobe posteriorly Moreover, compensatory emphysema

of opaque shadow, caused by air paucity), this mixture of hyperillumination and diminished illumination produces the illusion of normal lung However, if the patient steps forward 6 inches and leans back so that the back of the head touches the back panel (lordotic position), the upper lung separates from the lower lung, allowing the middle lobe

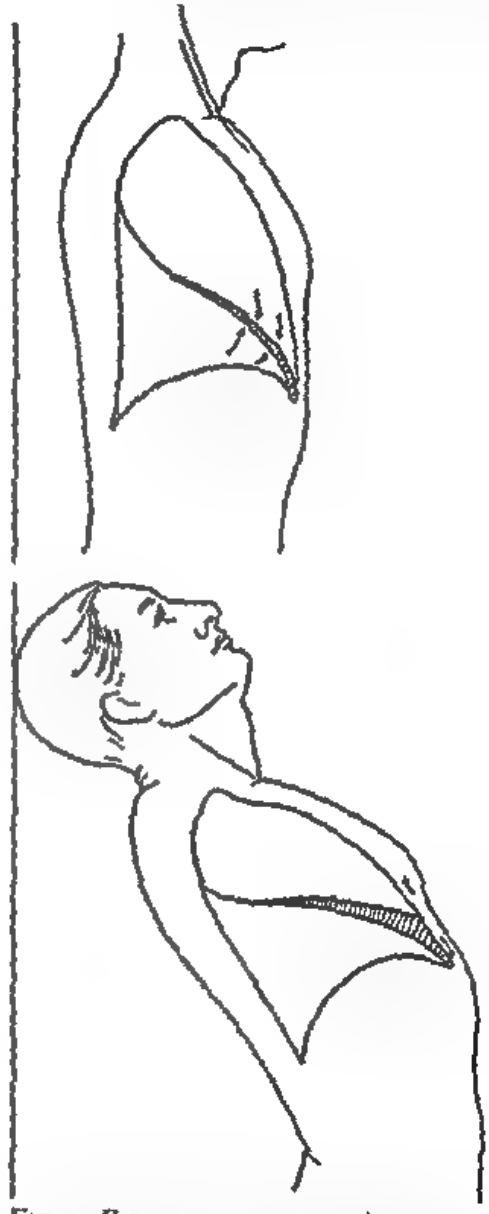

FIG 9 Patient in conventional position, the atelectatic middle lobe is obscured Patient in lordotic position, the atelectatic middle lobe becomes obvious

out that the x rays pass through more thicknesses (i e, a greater density) of atelectatic tissue, thus making the abnormal shadow more distinct (Fig 9)

In atelectasis as well as emphysema when air cannot freely move in and out of the lung area the blood vessel shadows cannot spread or fan together in normal fashion rather on respiration they will closely follow the rise and fall of the diaphragm We can say then that whenever the middle lobe is obstructed and the short fissure is fluoroscopically visible this short fissure will move up and down with the diaphragm

Emphysema The lack of normal fanning motion of the blood vessel pattern during respiration as seen in atelectasis is a phenomenon also occurring in any disease process which causes obstructive emphysema (e g bronchial tumor) so that this sign alone is not sufficient The actual atelectatic shadow as an increased density must be seen before the diagnosis is fully established In emphysema the involved area will show as increased illumination or diminished density

Pneumothorax A clear space visualized between lung and ribs shows the presence of air and thus establishes the diagnosis of pneumothorax This space may often be seen fluoroscopically when it is incomplete since examination with the conventional frontal position may fail to turn up a small pocket of air between the lung and chest wall hidden by overlapping normal lung (i e a pocket situated *posteriorly* with normal lung in front) Rotating the patient is of course the answer to this problem Even then a very small pocket of air will be difficult to see Fortunately a simple procedure will be of quite definite aid in such instances The patient is asked to exhale The lung becomes smaller making the pocket appear relatively greater in size and easier to see Here again rotation of the patient during exhalation is important

An important point in diagnosing pneumothorax has already been made If there is mediastinal shift on respiration it is toward the side where intrathoracic pressure is lower, if there is fixed displacement rather than simply shift on respiration again the displacement is toward the side with decreased pressure

An additional sign is the peculiar heart flutter associated with the condition and which has to do with air reaching the mediastinal surface It can be observed fluoroscopically

Pleural Effusion Fluid collection in the chest when present in sufficient amounts may be seen in the frontal examination of the patient When present in small amounts the fluid will collect in the trough or lowest part of the chart i e the posterior costophrenic angle With the patient in the conventional frontal position the dome of the diaphragm obscures its presence Various maneuvers are useful in demonstrating this small amount of fluid hidden in the posterior recess The patient may be asked to lie down in the supine position and unless loculated by adhesions the fluid may be expected to flow upward—producing an opaque shadow in the involved hemithorax—previously clear when the patient was upright Turning the patient into oblique positions while he is supine is also helpful In the erect position turning the patient into a true lateral position also may demonstrate the fluid—by opacification of the posterior costophrenic angle

The tube may also be raised and the patient turned with his back to the screen so that the deep posterior costophrenic sinus may be viewed without being obscured by the dome of the diaphragm The image is thus projected downward on the screen and if significant findings are noted roentgenograms can be taken in the same fashion

This method can likewise be used to view lung parenchyma deep down behind the diaphragmatic dome and not usually visualized on frontal examination Moreover the principle can be varied to meet the needs of the situation e g with the patient in the frontal position the tube can be *lowered* to project apical lesions above the clavicle

Pulmonary Fibrosis General multifocal fibroid reactions within the lungs have been ascribed to tuberculosis bronchiectasis syphilis radiation therapy asthma pneumoconiosis and scleroderma Whatever the etiology, fluoroscopy can at least establish the presence of such processes through the observation of typical movements With normal respiration diaphragmatic rise with expiration is slower (so-called lag) than the descent on inspiration In pulmonary fibrosis this lag is accentuated in exaggerated cases indeed, diaphragmatic paralysis may occur

With pulmonary fibrosis certain mediastinal

and tracheal clues are obtainable The mediastinum, paradoxically, appears wider with inspiration, narrower with expiration Widening of the tracheal air space may occur and is diagnostically significant

SUMMARY AND CONCLUSIONS

The writer would add but three brief concluding remarks First, the examination will be worthless if the examiner s eyes are not properly accommodated to the examination milieu The fluoroscopic image is so rapid, the shadows so often far from clear cut the mass of complex detail in this situation such a problem in separating the diagnostic wheat from the chaff, that the eyes must operate physiologically at an optimum level

Secondly, the fluoroscope is a potentially dangerous instrument not only to the patient and the examiner, but also to attendant nurses and students The necessary precautions should be known and observed The widespread use of the machine makes this rather obvious point worth emphasizing

Finally, diagnostic proficiency comes only with considerable practice The examiner will profit from taking advantage of every examination performed and carrying it out properly As in any field of medicine, experience and acquaintance with the normal will prove invaluable in recognizing the abnormal

In summary, it has been pointed out that while fluoroscopy must usually be considered an adjunct to film examination, it does have certain advantages (1) it is a truly in vivo examination the diagnostic possibilities of seeing functioning parts in motion, normal and abnormal, being obvious, (2) the mobility of the method and the rapidity with which it can be carried out provide an opportunity to determine the most profitable angle for viewing pathologic conditions thus "setting up," as it were, the roentgenographic examination and avoiding the taking of time-consuming multiple x ray films

Preparation of patient and examiner has been briefly described, and a recommended plan of fluoroscopic examination of the chest presented in some detail (1) general survey, (2) positioning and localization (3) detailed survey and (4) observation of diaphragmatic and mediastinal movements The criteria for visibility of lesions have been defined and solutions for some special examinational problems offered

Short descriptions of the fluoroscopic findings in a few of the more commonly encountered chest conditions have been given, and an attempt has been made to include differential diagnostic aspects

REFERENCES

1 STORCH C. B Fundamentals of Clinical Fluoroscopy New York 1951 Grune & Stratton
2 WESTERMARK N Roentgen Studies of Lung and Heart Minneapolis 1948 University of Minnesota Press

14

Radiographic Technics

IRVING J KANE, M D, *New York, New York*

MORE than half a century ago Roentgen's discovery of the x-ray led early observers to comment on the degree to which imagination contributed to the interpretation of physical signs in the chest The limitations of physical examination are now better understood, but those of the conventional chest roentgenogram still need to be emphasized These limitations are in effect indicated by the varied x ray technics currently used in the diagnosis of chest disease Such a variety of procedures and the fundamental differences in their principles also

of increasing complexity, calling attention to ordinary procedures which are often neglected, as well as those that require special equipment

Current technics in x ray examination of the chest might best be considered on the basis of their contribution to (1) detection of disease, (2) differential diagnosis, (3) localization for surgical resection (4) evaluation of therapy, (5) estimation of function While the various technics generally serve more than one such purpose they all tend to supplement each other

The *conventional chest x ray* used for routine examination and for survey purposes is also referred to as a postero-anterior (p a) x ray The latter designation always indicates the direction in which the x rays travel through the body to the recording film Properly taken such a film serves admirably for scouting purposes and through deductive interpretation yields considerable information

For present purposes it must suffice to call special attention to those areas of the chest roentgenogram in which disease is frequently obscured or easily overlooked namely, the lung apices and retroclavicular regions the parahilar or lung root regions, the retrocardiac, anterior mediastinal and retrodiaphragmatic regions These areas of the ordinary chest x ray might be referred to as 'danger zones for at all times they demand the observer s most critical attention The slightest suspicion offered by history, symptoms or physical examination warrants their special investigation

Apart from its place in the initial detection of disease the conventional postero-anterior chest x ray serves as a standard for following the

revealed the disease It must also be emphasized that the disappearance of a lesion on the ordinary x ray picture does not exclude the persistence of clinically significant disease in that lung In other words, before or after treatment the conventional chest x ray may and often does fail to reveal the true extent of a lung disease or the degree of its persistence Every experienced thoracic surgeon knows this

While it is necessary to confirm the disappearance of pulmonary lesions by special x ray technics before abandoning therapy and to verify the extent of a disease before undertaking its resection, such confirmation does not imply the supplementary use of ordinary lateral or oblique chest x rays Instead the specific technic required in each case must be determined by the nature of the original disease

Stereoscopic chest x rays in any position offer one basic advantage to all observers that of examining two pictures taken from slightly different angles At times one of these may reveal information which is otherwise obscured by a rib or an overlying shadow Except for this it must be recognized that stereoscopic impressions are highly subjective and dependent on a variable personal factor Even with practice not everyone can achieve the same degree of stereoscopy If two films are to be

1A 1B 2

FIG 1 A conventional chest x ray showing rounded shadow in right lower lung associated with elevation of the anteromedial segment of the diaphragm An unrelated large thyroid adenoma is seen extending out from the superior mediastinum on the right B ordinary lateral chest x ray confirming elevation of anteromedial segment of the right diaphragm and proving the lower lung shadow to be the result of right middle lobe atelectasis

FIG 2 Special lateral chest x ray This was taken with the right side of the chest against the film the right arm extended up alongside the head the left arm and shoulder depressed downward and back to a maximum degree Slight rotation further helps to project the lower shoulder away from the mediastinum

taken in a single position, there is generally greater advantage to taking each one from a different direction, e g, one from the back and another from the front In the lateral position taking one film from the right and one from the left allows better definition of lesions in either lung and on either side of the mediastinum

When attempting to see around a shadow such as the heart, even the oblique views will offer more advantage than stereoscopy or the [illegible] o pro- prob- ended

Beyond the conventional (p a) chest x ray additional films should be taken only as indicated by the specific nature of the information sought

The ordinary *lateral chest x ray* is generally one of the most disappointing views When requested as a routine supplement to the conventional (p a) chest x ray it very frequently constitutes an economic waste This fact is not surprising if one considers that all the shadows of the opposite lung as well as those of the mediastinum are superimposed on the area being studied It is therefore suggested that the ordinary lateral chest x ray be used only for specific purposes such as the demonstration of interlobar fluid, of middle lobe (Fig 1) or lingula disease, of anterior segment (upper lobe) or anterior mediastinal disease and for the study of the barium filled esophagus and its displacement by cardiac or mediastinal conditions

To overcome the effect of both shoulders on the visibility of the upper mediastinum and the lung apex on either side, a *special lateral chest x ray* can be obtained (Fig 2) This is based on a variation in the position and projection of the shoulder structures, one being projected upward and the other down and back Frequently neglected, this type of lateral chest x ray offers a continuity in the visibility of the trachea and esophagus from the neck down into the mediastinum The slight obliquity of the position has no significant effect on the appearance of these structures since the arc of their rotation is much less than the displacement of the peripheral structures of the thorax

In contrast to its limitations under the conditions of conventional radiography it will be noted later that the lateral position is of paramount importance in special radiographic procedures like bronchography and planigraphy (tomography)

At this point attention should be called to an ordinary x ray technic which is commonly referred to under a misnomer, namely, the "*lateral recumbent chest x ray*" Taken literally



3A 3B

FIG 3 A conventional chest x ray showing rounded shadow in left lower lung associated with pleural changes B conventional chest x ray taken in left lateral recumbent position proves that the shadows in the lower chest are due to pleural fluid in a freely communicating space This is evidenced by a shifting of the shadows up along the lateral chest wall and over the lung

referred to as a postero-anterior (or antero-posterior) chest x ray taken in the right or left lateral recumbent position Too often for gotten this simple technic helps distinguish pleural fluid from pleural thickening provided the fluid is not loculated (Fig 3) In the presence of a free pleural space the shifting of interlobar fluid with change in position helps distinguish it from parenchymal disease Similarly, change in shape with change in position helps to differentiate cystic tumors (e g bronchogenic enterogenic pericardial) from solid tumors Even with a diaphragmatic hernia a chest x ray taken in the lateral recumbent position may suggest the correct diagnosis when a gastrointestinal series and a diagnostic pneumoperitoneum have failed to do so (Fig 9)

Inspiration and *expiration chest x rays* offer much of the information ordinarily gained by fluoroscopy With such pictures the dynamic changes accompanying respiratory movements of the thorax and diaphragm can be studied leisurely and filed for future comparison

Thus in conjunction with the ordinary inspiration chest x ray an expiration film may be expected to demonstrate (1) the occurrence of mediastinal swing or rotation (Fig 4), (2) the extent of diaphragm motion or paralysis (3) the degree to which air is moved by each lung or the degree to which it is trapped in obstructive emphysema (Fig 4), (4) the presence of unsuspected pneumothorax, (5) the cystic or fluid nature of a pulmonary or mediastinal condition (Fig 5) and (6) the extent of mobility of a diaphragmatic hernia To combine both pictures on one film through double exposure with or without a Birath Kallquist grid sacrifices too much parenchymal information

Valsalva and *Muller chest x rays* are occasionally useful in determining the vascular nature of a pulmonary or mediastinal shadow The Valsalva maneuver consists of forced expiration against a closed glottis whereas the Muller maneuver consists of forced inspiration against a closed glottis In the former instance air pressure within the thorax is increased with consequent reduction of blood volume in the right auricle the pulmonary vessels and left side of the heart Conversely, in the Muller test a strongly negative intrathoracic pressure or suction effect is produced with progressive overdistention of the right auricle the pulmonary vessels and the left side of the heart These pressure changes are classical in their effects on heart size and shape but their influence on mediastinal and pulmonary vessels is less dramatic

The effect of these procedures varies with the understanding and cooperation of the patient and the length of time the intrathoracic pressures are sustained before each x ray exposure Training the patient under fluoroscopic observation and supervision of the technic by a

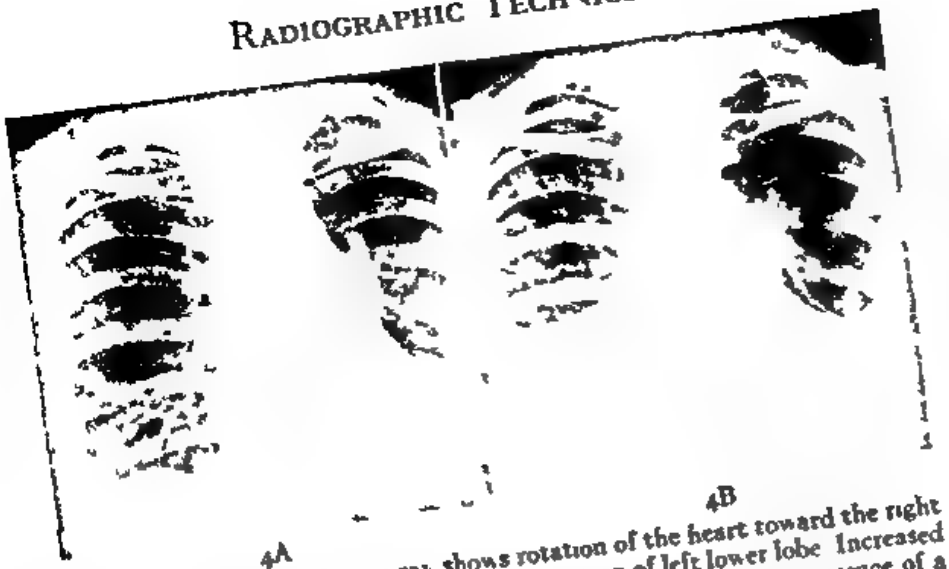

4A 4B

FIG 4 A, inspiration chest x ray shows rotation of the heart toward the right anterior oblique position and suggests contraction of left lower lobe Increased density of the left lung root region is also noted indicating the presence of a tumor These observations associated with evidence of left upper lobe emphysema suggest the presence of bronchogenic carcinoma obstructing the lower lobe bronchus and stenosing the upper lobe bronchus (This deductive interpretation was confirmed by bronchoscopy and subsequent necropsy) B, expiration chest x ray emphasizing the presence of obstructive emphysema in the left upper lobe The heart is seen to rotate back toward midline as a result of the relative equalizing effect of expiration on the pull of the contracted left lower lobe Thus the tumor in left lung root region is more clearly revealed

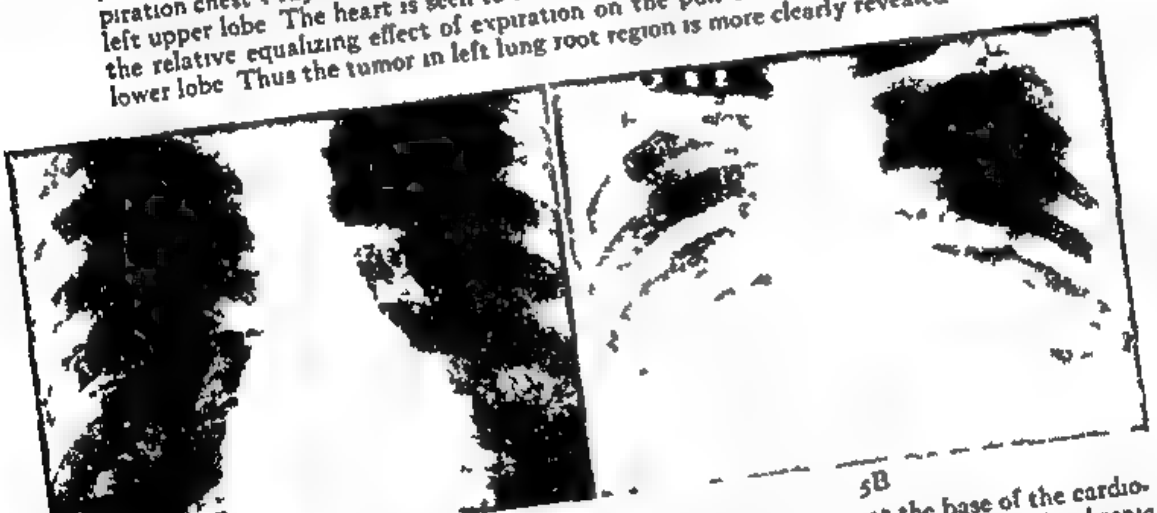

5A 5B

FIG 5 A inspiration chest x ray shows a widening of the mediastinum at the base of the cardiovascular silhouette B expiration chest x ray shows an expanding shadow in the cardiophrenic angle above the right diaphragm This change in the mediastinal outline corresponding with the expiratory change in intrathoracic pressure suggested an intercommunicating cyst of the pericardium (proved surgically)

physician are therefore essential to its success However, even with ideal cooperation the value of this procedure is limited in the presence of thromboses

Another useful variation of the conventional roentgenogram is that referred to as a *lordotic chest x-ray* This depends on an altered angle of projection and is taken in the anteroposterior position with the patient standing away from the film but leaning back so that the base of his cervical spine rests on the x-ray film holder His thoracolumbar spine is then in extreme lordosis, thus accounting for the name of this position The proper execution of this technic requires a supple patient and a careful technician

An alternate term, "apical lordotic chest x ray," is sometimes applied to the same procedure This is less desirable since it implies unnecessary limitation to the usefulness of this position Furthermore, it should be realized that the visibility of lesions in the anterior

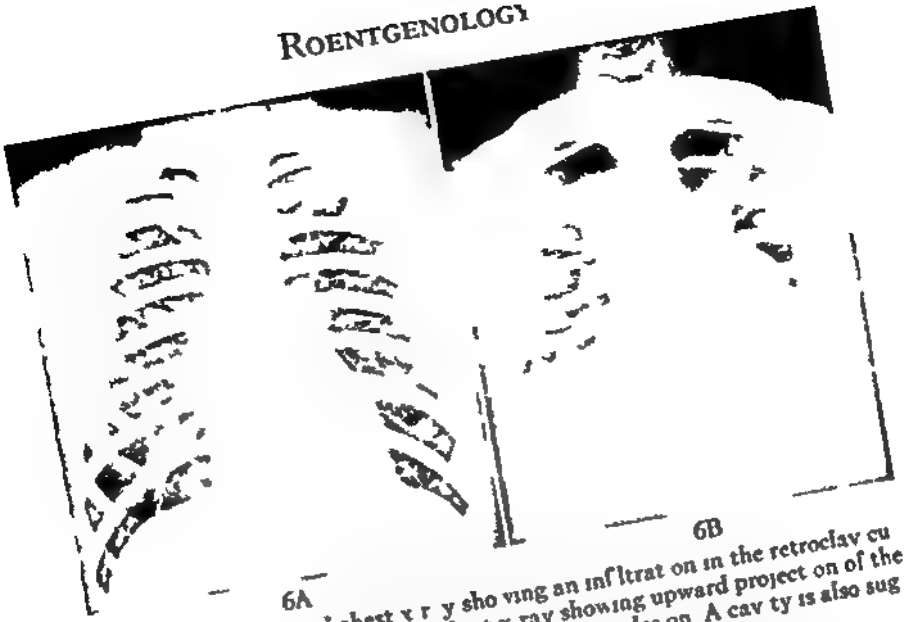

6A 6B

FIG 6 A conventional chest x r y sho ving an inf ltrat on in the retroclav cu lar reg on on the left B lordot c chest x ray showing upward project on of the clav cles w th improved vis b l ty of the underly ng les on A cav ty is also sug gested just above the lung root shadows on the same s de

portion of the lung apices may actually be impaired in this position rather than improved Conversely lesions lower down in the chest behind the clavicles (Fig 6) or in front of the lung root and cardiac shadows may be projected into clearer view As with all frontal chest roentgenograms the scapulas must be rotated forward to either side in order not to project over the lung fields

The *oblique chest x rays* customarily taken in the postero-anterior position with the right or left breast against the film are referred to respectively as right or left anterior obliques Each would correspond in general appearance to posterior oblique views taken from the opposite sides (e g right anterior oblique resembles left posterior oblique and so forth) The most familiar use of the oblique positions is in outlining the esophagus and cardiovascular silhouette and in estimating the size of the cardiac chambers

For pulmonary studies these views dissociate the lungs into four vertical quadrants consisting of anterolateral and posterolateral sectors on each side From the right and left anterior oblique projections it is possible to obtain unopposed views of each of these vertical quadrants and to see around the cardiac silhouette

The value of these positions in special x ray technics will be noted later Except for cardiac studies the ordinary oblique chest roentgenogram is of use chiefly to those who must attempt to dissociate complex shadows without the facility for more satisfactory methods such as planigraphy (tomography)

The *grid filtered chest x rays* are most frequently referred to as Bucky or Potter Bucky pictures These pictures are obtained by interposing a lead grid between the patient and the film The misguided technics customarily employed in obtaining so-called Bucky chest x rays have usually involved unnecessary overexposure and the use of a moving grid As a result clinicians and radiologists have frequently been discouraged from ordering grid filtered chest x rays

While the thin wafer grid of the Lysholm type serves to reduce the fogging effects of secondary x ray radiation (Fig 7) it has virtually no effect on object to-film distance The increase in object to film distance imposed by use of the moving lead grids of the Potter Bucky type is more objectionable in its effect on definition than is the faint visibility of lines noted with the latest type of stationary (Lysholm) grid In spite of the excellent quality of today s ordinary chest x ray the general use of a stationary wafer grid might be expected to lead to its further improvement

Another important diagnostic procedure is the *barium swallow* or *esophagogram* No study of the mediastinum is complete without fluoroscopic or radiographic examination of the esophagus Whether investigating symptoms of mediastinal distress (Fig 8A) or the possibility

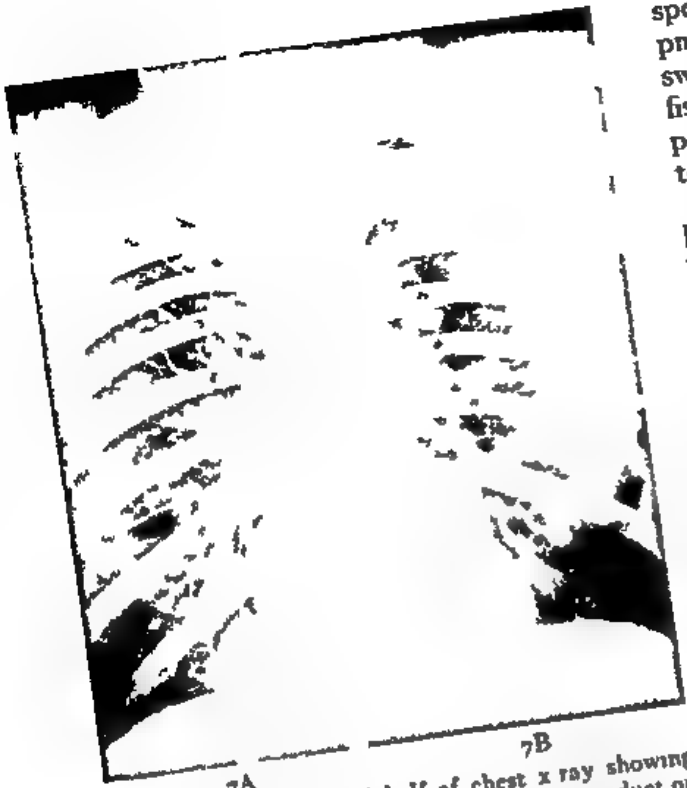

7A 7B

FIG 7 A grid filtered half of chest x ray showing improved contrast and def nition due to reduct on in secondary x ray radiat on B oppos te h lf of chest showing the difference in the x ray p cture when taken without the use of a lead f lter

special attention is advisable where aspiration pneumonitis appears due to difficulty in swallowing or where an esophagotracheal fistula is suspected For investigating the latter possibility a spoonful of lipiodol is preferable to a barium suspension

The information gained by observing a barium swallow is both direct and indirect The former relates to the presence of intrinsic esophageal disease (e g tumor, spasm, stric ture diverticulum) while the latter is based on extrinsic influences affecting its function or its position (e g, tumor pressure, constriction by a vascular ring displacement by cardiac enlargement)

A *gastrointestinal x ray series* and *barium enema x rays* may also be required to differ entiate a diaphragmatic hernia (Fig 9) from other shadows in the lower lungs In addition to a paraesophageal hiatus hernia the stomach may be involved in rupture through a con genital defect in the diaphragm However all barium studies may fail to demonstrate a diaphragmatic hernia when it includes only omental tissue

A technic which requires some caution and experience rather than special equipment is *diagnostic pneumothorax* Although the sur geon s skill has minimized the hazards of thoracotomy and all but eliminated the need of aspiration pneumonitis (Fig 8B) this pro cedure should never be neglected However,

8A 8B

FIG 8 A esophagram showing a large d vert culum ar s ng from the lower esophagus thus explaining the patient s retrosternal d stress B esophagram showing an overflow of bar um with aspirat on into the tracheobronchial tree due to swallowing d ff culty wh ch accompan ed a neurologic disorder

9A 9B 9C

peritoneum or gastrointestinal x ray series)

10A 10B

FIG 10 A conventional chest x ray showing large tumor in right upper chest B diagnostic pneumothorax Collapse of supporting lung results in sagging of tumor Change in shape resembling a sac of fluid suggested the diagnosis of a large bronchogenic cyst (proved by resection)

for diagnostic pneumothorax it may be well to review some of its aspects for those occasions on which it might still prove useful If a small pneumothorax is to be induced the needle should be inserted some distance from the lesion under investigation so as not to traumatize it or contaminate the pleural space Aside from demonstrating the cystic nature of a tumor by its resulting change in shape (Fig 10), pneumothorax helps to distinguish pulmonary from extrapulmonary lesions providing the surrounding pleura is not adherent

A similar procedure which involves the introduction of air for tissue contrast is *diagnostic pneumoperitoneum* Following this x rays taken in the upright position outline the undersurface of the diaphragm and help to [illegible] (Fig 11) from a local area on the amount of air used and its postural localization in relation to the site of hernia Diagnostic pneumoperitoneum can also fail to demonstrate a hernia which is completely surrounded by incarcerating adhesions

Diagnostic pneumomediastinum is another

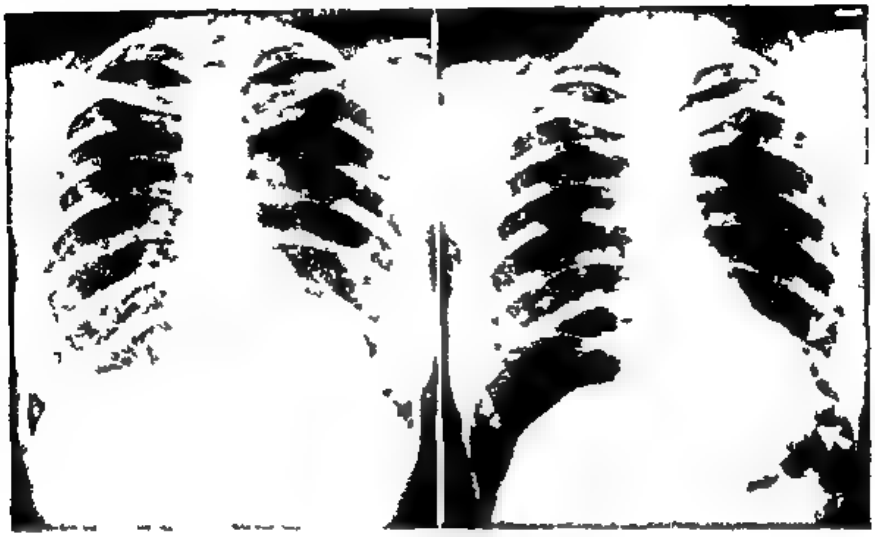

11A 11B

FIG 11 A conventional chest x ray showing a large tumor in the left lower chest B diagnostic pneumoperitoneum The tumor is dissociated from the abdominal organs by the subdiaphragmatic air thus excluding hernia and proving the shadow to be located above the diaphragm (proved on removal to be a cystic neurilemmoma)

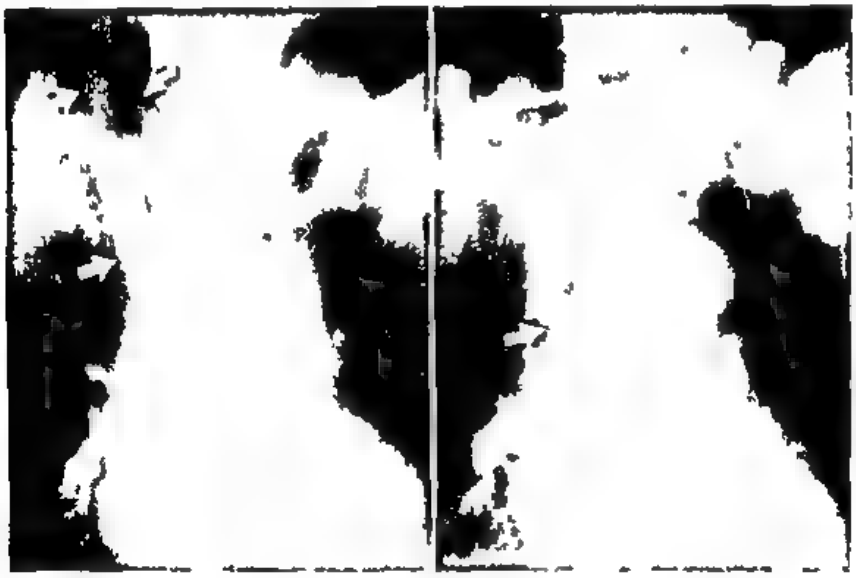

12A 12B

technic which depends on the introduction of air contrast for the separation of tissues and the identification of their shadows Introduced presacrally according to the method of Ruiz Rivas,[12] air ascends through the intercommunicating alveolar tissue spaces of the body to outline the surfaces of the diaphragm and some of the cardiovascular structures of the mediastinum To obtain any appreciable information from such air in the mediastinum this procedure must be combined with sectional radiography (Fig 12)

Sectional radiography is a method of study which has received increasing attention during the past decade Referred to by many terms, such as planigraphy, tomography, laminagraphy, stratigraphy and body section roentgenography, it has also been characterized as a method of bloodless dissection This procedure can be performed without difficulty in most offices which have standard x ray equipment

Thus the shadows from a selected plane in the body fall on constant points of moving film, whereas shadows from above and below this level are projected onto constantly changing points of the film The latter are consequently blurred or "erased" from view With this technic lesions ordinarily obscured by overlying bone soft tissue or other shadows become easily visible and their characteristics become more readily apparent

Planigraphy reveals more clearly than other x-ray methods the presence of calcification within a tumor, thus helping to differentiate "tuberculomas" of lung and mediastinum from other tumors It also helps to dissociate the complex lung root shadows and to distinguish between lymph node, tumor and normal pulmonary vessels (Fig 13) This technic is very useful, too, in demonstrating the cause of obstructive pneumonitis when beyond the view of the bronchoscopist In such instances it often helps to distinguish between an eroding calcified tuberculous lymph node and a small bronchogenic carcinoma

In tuberculosis, sectional radiography may help not only to detect an unsuspected cavity (Fig 14) but also may demonstrate a much wider distribution of disease than suggested by the conventional chest x rays Applied to the lateral position this procedure offers the most accurate means for determining the segmental localization of tuberculosis as well as other parenchymal diseases Sectional radiography is equally important in evaluating the results of medical therapy for tuberculosis since it can reveal a persistence of disease when there is no longer any evidence of such on the ordinary chest x ray

Among other important indications for planigraphy is the investigation of bone disease in the upper thoracic spine, ribs and sternum This x ray technic is also helpful in showing the true extent of bullous transformation of lung tissue and in distinguishing peripheral bleb formations from suspected pneumothorax

tion of the trachea and main bronchi it is secondary to bronchoscopy

The only accurate method for determining the presence or extent of bronchiectasis is *bronchography* While new media are constantly being tested the iodized oils such as lipiodol and iodochloral® continue to serve as standard materials for this procedure Umbradil and more recently dionisil have been available as water soluble iodized substances offering as advantages the rapid absorption of their shadows Aside from somewhat less satisfactory contrast and the need for rapid coordination of its bronchial instillation with the x ray exposure, a substance like umbradil gives a false impression of the residua which remain in the lungs The same precautions should be observed with reference to overfilling of the bronchial tree as with iodized oils for while sufficient data may not yet be available in human beings, it appears that the base substance used in preparations like umbradil is retained for a considerable period after its iodine content has been absorbed The same temporary influence on pulmonary function may therefore be expected as occurs following the use of iodized oils

In most instances the degree to which characteristic residua persist following iodized oil bronchography should offer no difficulty in observing the course of the underlying disease Excessive retention of such oil can usually be prevented by adequate cough control during bronchography, by avoiding cough depressants, by avoiding delays in one position during intrabronchial instillation, by avoiding use of too much oil, by prompt postural drainage and by administration of an ephedrine compound to prevent the trapping effects of bronchospasm following the procedure

For dissociation and identification of the bronchi, as well as accurate localization of their diseases, the lateral chest x ray is the most important one in bronchography The oblique views which rank next in importance are usually not essential if good lateral pictures are available The frontal (p-a) chest x ray is a necessary complement to the lateral view



FIG. 13 A conventional chest x ray of the right lung showing an area of density associated with a ring like shadow overlying the fourth anterior intercostal space and suggesting tuberculous or cystic lung disease B sectional roentgenogram (planigram) through the right lung of same individual reveals tumor mass (arrow) associated with enlargement of the adjacent bronchopulmonary lymph nodes This suggested bronchogenic carcinoma (proved by resection)

FIG 14 A conventional chest x ray of the right upper lung showing irregular infiltrations overlying the outer portion of the second anterior intercostal space B sectional roentgenogram (planigram) through a corresponding area of right upper lung reveals an unsuspected tuberculous cavity

for together they reveal the three-dimensional changes in the bronchial tree and permit better correlation of the bronchogram with the conventional chest x ray

In addition to the generally accepted indications for bronchography in diagnosis and localization of suspected bronchiectasis there are a few other conditions in which this procedure is very helpful The first of these is hemoptysis due to clinically unsuspected or so-called "dry" bronchiectasis In such instances although bronchoscopy is negative,

15A 15B 15C

bronchography can establish the diagnosis Another indication is the differentiation of tumor shadows due to ball like fibrosis (to be published) from those due to malignancy Still another indication is in demonstrating the persistence of a residual cavity following therapy for lung abscess (Fig 15) In these cases bronchography is the only reliable method for revealing the source of a persistent cough repeated hemoptysis or recurrent infections

Perhaps one of the most dramatic technics in diagnostic roentgenology is *angiocardiography* This procedure has proved to be a very valuable method for the study of cardiovascular abnormalities and their differentiation from other mediastinal conditions Although some of its purposes in the diagnosis of congenital heart lesions are now better served by cardiac catheterization it can be a helpful supplement to the study of such conditions

Angiocardiography is a reliable means of demonstrating arteriovenous aneurysms in the lung and differentiating vascular shadows in the lung roots The same may be said of those shadows which are due to aberrant pulmonary veins However in many of these latter conditions planigraphy can prove equally useful and more acceptable to the patient In spite of the low mortality of angiocardiography the unpleasantness of the experience coupled with its exacting requirements in equipment personnel and teamwork makes this a procedure to be used only where other methods cannot serve adequately It is the only diagnostic x ray procedure which is advisedly performed in a hospital

Fluoroscopy has been discussed in the preceding chapter Nevertheless some comment on its relation to the foregoing technics seems warranted For historical technical and economical reasons the fluoroscope was widely used by itself in the early decades following Roentgen s discovery However it should now be considered only as an adjuvant to diagnostic roentgenography The value of fluoroscopy in chest diagnosis is primarily to determine the functional aspects of a disease process and its influences especially with reference to the heart mediastinum and diaphragm Although as indicated previously a good deal of such information can be recorded by inspiration and expiration roentgenograms fluoroscopy

[illegible] d expense

[illegible] ted
[illegible] tter
[illegible] s of

good fluoroscopy such as adequate dark adaption the use of a Lysholm grid and the

choice of minimum object-to-film distances this procedure should not be relied on as a means of detecting or excluding pulmonary disease Second the fluoroscope is an instrument with ultimately lethal potentialities to the physician who uses it It should therefore be handled accordingly observing the utmost precautions against the cumulative effects of exposure to its radiation It is noteworthy to observe that as time passes and knowledge increases the so-called safe or tolerance dose to repeated x ray exposure comes closer and closer to zero

SUMMARY

This review in itself constitutes a summary of an extensive subject and is therefore intended to serve only as a means of briefly orienting the reader to the current applications of diagnostic chest roentgenology

REFERENCES

Ruiz Rivas M Diagnost co rad olog co el neumor r non tecnica original *Arch espan urol* 4 228 233 1948

2 Idem Generalized subserous emphysema through a s ngle puncture *Am J Roentgenol* 64 723 734 1950

SEGMENTAL LOCALIZATION

With the increasing skill of the surgeon in resecting small portions of lungs conserving tissue and function came the greatest incentive to further anatomic studies of the sublobar segments and their radiographic localization

The chart shown in Figure 16 outlines the radiographic density of each lobe and segment as it would appear if involved by a consolidating process It should be understood that the x ray shadow of a bronchopulmonary segment cannot be correlated with its surface anatomy alone since it represents the sum of its three-dimensional density The reference numbers designating each of the segments and their corresponding bronchi (Fig 17) indicate the order in which they arise from the lobar bronchi

When localizing lesions with the aid of this chart consideration must be given to the normal variation in size of the segments and especially to such complicating influences as atelectasis fibrosis and emphysema In localizing disease which involves part of or more than one segment it is also necessary to consider the varying extent to which the adjoining segments overlap each other

In addition to recognizing the common lobes which are subdivided into pulmonary segments it is well to be familiar with the accessory lobes which may be encountered Although the writer has seen one pair of lungs which were divided into eleven clearly defined lobes with fully developed pleural fissures it is more frequent to find that even the five which are commonly described are not always separated by a fissure

The accessory lobes shown in Figure 18 are those which can often be recognized by the presence of some degree of fissure formation Two of these accessory lobes (b and c) incorporate individual lung segments The third (a) includes a variable portion of the upper lobe and occurs only on the right side

The azygos lobe (a Fig 18) derives its name from the fact that its separating fissure results from a developmental aberrance in the course of the azygos vein with a consequent infolding of parietal and visceral pleura This lobe is seen on about 1 per cent of chest roentgenograms and is recognized by the lateral convexity of its fissure and the visibility of the azygos vein The latter is frequently misplaced due to embryologic arrest in its descent

The accessory lobe designated as b in Figure 18 was first described by Deve in 1900 It represents a subdivision of the lower lobe by a horizontal fissure This occurs more frequently in the right lung than in the left and may appear on a level with but posterior to the familiar horizontal fissure which separates the right upper lobe from the right middle lobe The posterior horizontal fissure of Deve occurs as a fully developed pleural fold in about 5 per cent of lungs and as a partially developed fissure in about 22 per cent This accessory lobe includes the apical (superior) segment

The careful interpretation of lateral bronchograms as well as the other views presupposes a thorough knowledge of the bronchopulmonary segments and their alterations by disease To assist in identification of the segmental bronchi and in localization of their diseases the illustrations in Figure 17 have been reproduced from Brock s excellent monograph The superimposition of bronchi in the frontal views may be seen to preclude their accurate identifica

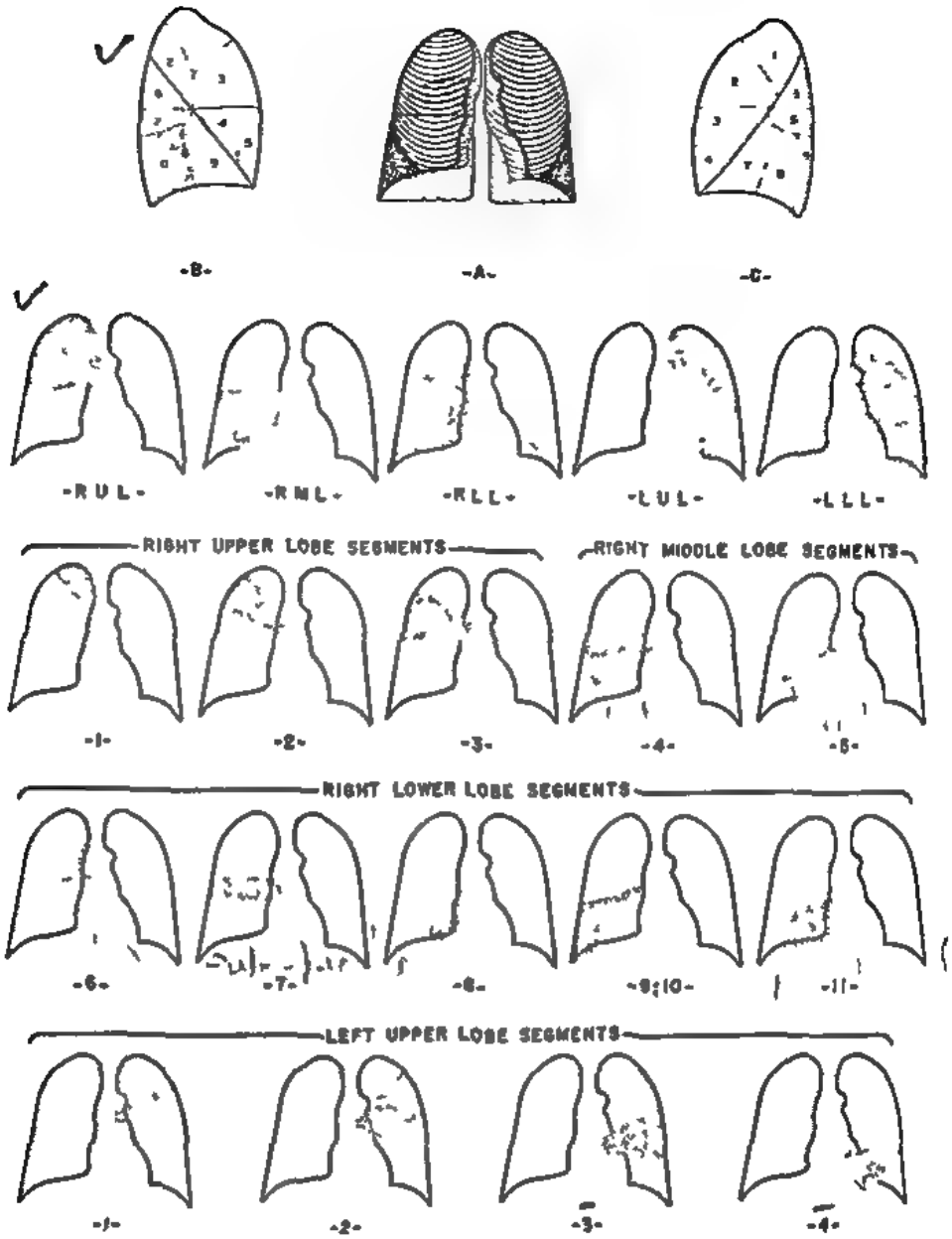

segment The difference in number of segments [illegible] accounted for by combination of apical and posterior segments in the left upper lobe and absence of the median basal segment in the left lower lobe (See corresponding bronchi in Figure 17) *Right upper lobe segments (R U L).* (1) *apical,* (2) *posterior,* (3) *anterior. Left upper lobe segments (L U L)* (1) apical posterior, (2) anterior *Right middle lobe* [illegible]

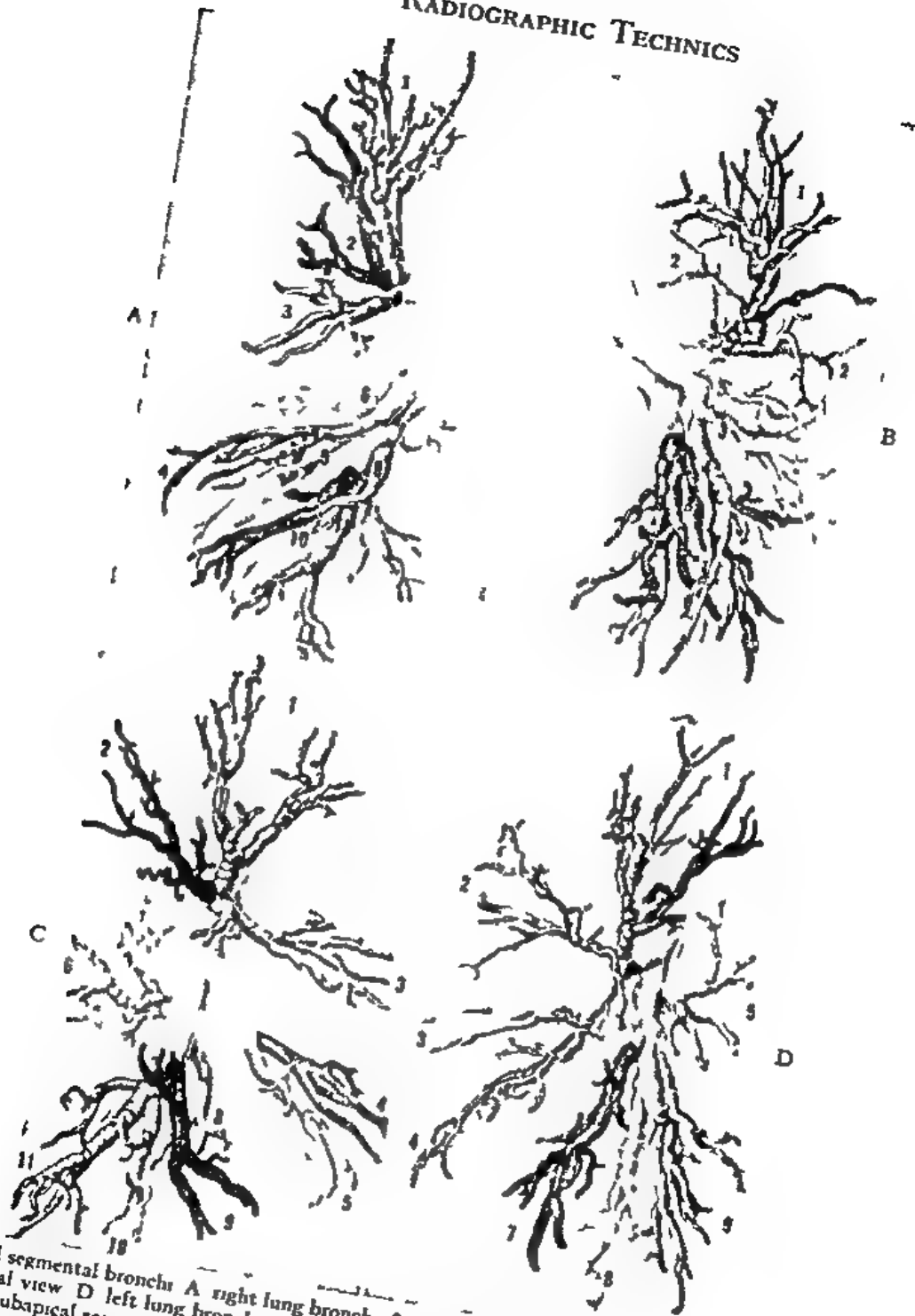

FIG 17 Lobar and segmental bronchi A right lung bronchi frontal view B left lung bronchi frontal view C, right lung bronchi lateral view D left lung bronchi lateral view Each bronchus is similarly shaded in the frontal and lateral views The subapical segment bronchi which occur in 50 per cent of lower lobes are not shown in these drawings, thus accounting for the absence of numbers 6 and 7 in the left and right lungs, respectively *Right upper lobe segments* (1) apical (2) posterior (3) anterior *Left upper lobe segments* (1) apical posterior (2) anterior *Right middle lobe segments* (4) lateral (5) medial *Lingula segments of L U L* (3) superior (4) inferior *Right lower lobe segments* (6) apical (superior) (7) subapical (50 per cent of cases) (8) median basal, (9) anterior basal, (10) lateral basal (11) posterior basal *Left lower lobe segments* (5) apical (superior) (6) subapical (50 per cent of cases) (7) anterior basal (8) lateral basal (9) posterior basal (From BROCK, R C. Anatomy of the Bronchial Tree New York, 1947 Oxford University Press)

tion However, the degree to which they are separated on the lateral views makes this the most valuable for bronchographic localization The oblique views which are not presented here may serve as a useful supplement in some instances

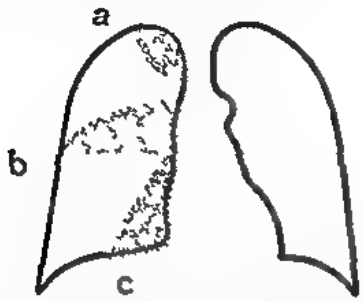

FIG 18 Three of the more common accessory lobes (a) Azygos lobe, (b) Devé's lobe, (c) inferior accessory lobe

REFERENCES

1 BENDICK, A J and WESSLER, H Azygos lobe of the lung *Am J Roentgenol*, 20 1, 1928
2 BOYDEN, E A Intrahilar and related segmental anatomy of lung *Surgery*, 18 706 1945
3 BROCK, R C The Anatomy of the Bronchial Tree New York, 1947 Oxford University Press
4 CHAMBERLAIN, J M and KLOPSTOCK H Further experiences with segmental resection in tuberculosis *J Thoracic Surg*, 20 843 1950
5 CHURCHILL, E D and BELSEY, R Segmental pneumonectomy in bronchiectasis *Ann Surg* 109 481, 1939
6 EWART, W The bronchi and pulmonary blood vessels London, 1889 J & A Churchill
7 FELSON, H and FELSON, H Localization of intrathoracic lesions by means of postero-anterior roentgenogram *Radiology*, 55 363 1950
8 FOSTER CARTER, A F Anatomy of bronchial tree *Brit J Tuberc*, 36 19 1942
9 JACKSON, C L, and HUBER, J F Correlated applied anatomy of bronchial tree and lungs with system of nomenclature *Dis of Chest*, 9 319, 1943
10 KANE, I J Segmental localization of pulmonary disease *Radiology*, 59 229 1952
11 KANE, I J Segmental postural drainage in pulmonary disease *Dis of Chest* 23 418 1953
12 KRAMER, R and GLASS A Bronchoscopic localization of lung abscess *Ann Otol, Rhin & Laryng.*, 41 1210 1932
13 NEIL J H, FILMOUR, W and GWYNNE, F J Broncho pulmonary segments *M J Australia* 2 165, 1937
14 NELSON, H P Segmental drainage of lungs *Brit M J*, 2 251, 1934
15 RIGLER L G Density of central shadow in diagnosis of intrathoracic lesions *Radiology*, 32 316, 1939
16 SINGER, J J and GRAHAM, E A The newer treatments of bronchiectasis *J A M A* 19 390, 1922
17 TEMPLE, H L and EVANS J A Bronchopulmonary segments *Am J Roentgenol*, 63 26 1950

15

Bronchography

ARTHUR J CRACOVANER, M D, *New York, New York*

THERE is some difference of opinion in whose province the performance of the bronchogram belongs—the roentgenologist, laryngologist, endoscopist, chest physician or the thoracic surgeon As a matter of fact it matters little who does the bronchogram as long as he becomes proficient in the procedure and has the proper equipment There are many methods of obtaining a bronchogram If the doctor will accustom himself to one of these according to his particular setup, and if he is able to obtain adequate results, it is of no consequence who does the procedure

It is important for the student of bronchography to acquaint himself with the anatomy of the bronchial tree and to recognize the various bronchi and segments in the bronchogram It would be well to study the charts that have been made available by Jackson and Huber

INDICATIONS FOR BRONCHOGRAPHY

Bronchography is especially indicated whenever bronchiectasis is suspected Actually bronchography is the only way one can make a certain diagnosis of bronchiectasis The smaller bronchi are outlined so that their dilatation is demonstrated The present treatment of bronchiectasis includes resection of the diseased portion of the lung It is necessary, therefore, not only to establish the presence of dilatation of the bronchi in a certain area but also to confirm the lack of pathologic conditions in normal portions of the lung In other words the extent of disease must be demonstrated, bronchography can do this It is best to bronchoscope these patients first in order to rule out any obstruction to the bronchi and to aspirate exudate that might interefere with proper filling of the branch bronchi

In the bronchogram obstructive lesions show a blockage of the flow of the contrast medium Partial obstruction to the bronchus is demonstrated by narrowing Tumors, abscesses, cysts, bronchostenosis, pulmonary cavities and bronchial fistulas can be revealed, confirmed and localized by bronchography It may be difficult to outline an abscess because the mucosa lining the bronchus may be edematous However, an abscess may be recognized by abnormal distribution and rearrangement of the bronchi that surround it

Tuberculosis is no longer considered a contraindication to the use of the procedure Of course, it would not be wise to do a bronchogram in the presence of acute disease with fever, evidence of spread, etc , but if the information obtained from a bronchogram is essential, the examination can be done without fear of complications In these days of segmental resection for localized tuberculosis it is important to demonstrate the exact extent of disease and the areas that are normal Following artificial pneumothorax it may be necessary to determine the condition of the bronchi in a lung or a part of a lung that will not expand Then too, it may be important to know the condition of the bronchi when a lung appears to have cleared and the patient is about to be declared an arrested case

CONTRAST MEDIA

We prefer to use lipiodol as the contrast medium Recently water soluble solutions have been used, but we have had relatively little experience with these preparations They are rather quickly absorbed, and the material readily invades the alveoli which obscures the picture unless the arrangement is such that x-rays can be taken immediately Water-soluble contrast media are very irritating to the mucous membrane of the bronchi, producing cough which is not easily controlled even with an excessive use of the anesthetic Water soluble preparations are more viscid than lipiodol and cannot be used in lungs with limited function The roentgen contrast is less than with lipiodol However, the water soluble media are

absorbed within four hours, and if a repeat bronchogram is necessary, it can be done soon instead of waiting a week or two when lipiodol is used *Lipiodol may remain in the lung for* several weeks

Recently an oily suspension of water soluble medium has been used This reduces somewhat the amount of irritation to the mucosa but also delays the absorbability of material Norris and Stauffer report good results using dionosil aqueous® which is less irritating to the mucosa and is not as readily absorbed into the alveoli

Lipiodol should be used at body temperature If it is too warm, it is more readily absorbed, "floods" the alveoli and obscures the picture

A Lipiodol®-sulfanilamide suspension, now widely used abroad, has recently become available here as Visciodol® According to Salinger and Houghton reporting on 7,000 cases, Visciodol® while retaining the blandness of Lipiodol®, affords unusual radiopacity, marked absence of alveoli penetration and rapid clearing Burrascano, Pesiri, Cohen, *et al* have also reported favorably

PREPARATION OF THE PATIENT

The bronchographic examination may be performed on outpatients as well as hospitalized patients Occasionally we encounter a reaction to the local anesthetic This is greatly reduced by proper premedication which is only possible if the patients are institutionalized We prefer, therefore, to have our patients hospitalized although with proper care the examination may be performed on ambulatory cases

The patient is asked to omit the meal directly before the procedure He is also asked *to undergo postural drainage just before* the examination if he has a great deal of exudate in the lungs If postural drainage does not clear his lungs sufficiently, it is best to bronchoscope the patient and thoroughly aspirate the material before doing the bronchogram However, we have found on occasion that the patient is more irritable after a bronchoscopy and is unable to withhold coughing so that a satisfactory bronchogram cannot be obtained In this case the examination may have to be repeated

An ambulatory patient should be given a barbiturate about an hour before and codeine a half hour before the procedure The hospitalized patient is given nembutal 1½ gr 2 hours before, and another 1½ gr 1 hour before and codeine ½ hour before the bronchogram is done If the patient is likely to salivate a great deal or has a great deal of exudate, atropine is added to the codeine The premedication reduces the possibility of reaction to the local anesthetic and decreases the cough

ANESTHESIA

There are a number of local anesthetics used in this work—cocaine 4 per cent cocaine 10 per cent, pontocaine® 1 per cent or 2 per cent, butyn® 2 per cent, xylocaine, etc For a long while we have had satisfactory results using a combination of 10 per cent cocaine and 2 per cent pontocaine which gives a solution of 5 per cent cocaine and 1 per cent pontocaine The anesthesia must be given slowly in small amounts and with sufficient intervals between applications to obtain adequate results The larynx and pharynx are sprayed with the anesthetic and then instilled with a laryngeal syringe into the trachea The patient is asked to lean on one side and then the other to insure the dropping into each main bronchus Small amounts are used but enough instilled to anesthetize the patient sufficiently to prevent coughing We find the use of laryngeal applicators to the pyriform sinuses unnecessary and the use of anesthesia by aerosol unsatisfactory The latter requires further instillations of anesthesia and is a waste of time

VARIOUS METHODS OF BRONCHOGRAPHY

There are a number of ways of obtaining a satisfactory bronchogram Each depends on the facilities available at the hospital or office in which it is done The operator should choose a method suitable to his setup and training and stay with it, for the more one is accustomed to doing one method the better results will be obtained

Supraglottic or Passive Method This is the simplest method and is probably used a great deal in ambulatory patients who come to the doctor's office The patient is in a sitting position He is anesthetized The tongue is held out with a piece of gauze and lipiodol is dripped from a laryngeal syringe placed at the base of the tongue The patient is asked not to swallow and not to cough He is asked to keep breathing or "pant like a dog" The lipiodol gradually runs around the epiglottis into the larynx and trachea Another method of instilling the lipiodol is to drip it from a laryngeal cannula directly into the trachea under indirect vision

with a laryngeal mirror Both lungs are filled by tilting the patient first to one side, leaning forward then backward and then tilting to the other side and repeating the movements About 10 to 15 cc of lipiodol is used and films taken in the erect position This is rather a blind method but is frequently satisfactory if one is interested in only the lower lobes and is not especially concerned about the upper lobes

If one wishes to outline the upper lobes the procedure is best done under fluoroscopic guidance so as to make sure to fill these areas adequately One lung at a time should be done because of superimposition when taking lateral films However the patient does not usually care to return for another session and one is inclined to do both sides at the same sitting Oblique films usually help in avoiding the effect of superimposed areas

In outlining the upper lobes the lipiodol is instilled and the patient is placed in a recumbent position with the head lower than the trunk and turned to one side with the body almost prone In this way the lipiodol will enter the upper lobe The other side is outlined in a similar manner The right middle lobe is filled while the patient is in an erect position and leaning forward and to the right The filling is watched through the fluoroscope and when proper outlining has been accomplished films are taken in the reclining or erect positions according to the facilities Anteroposterior lateral and oblique views are taken in order to demonstrate all branches About 20 cc of lipiodol is used

Deep breathing helps to spread the lipiodol to the small branches and it is important that the patient refrain from coughing Lipiodol should not be used in great quantities and should not be instilled with pressure because it will tend to flood the alveoli It is not necessary to fill the entire bronchial column Covering the walls of the bronchi with a faint outline of lipiodol is sufficient for any study and is more satisfactory Fluoroscopy should not be prolonged because the films must be taken as soon as possible after the instillation before flooding takes place

Another method of filling the upper lobes is to have the patient seated and after tilting to one side to fill the lower lobe he is brought forward so that the body and head are placed between his knees This fills the upper lobe The posterior portion of the lung is filled by leaning backward almost in a supine position This is repeated on the other side The method is useful when a tilt table is not available

The patient is asked to cough under postural drainage technic after the x rays are taken

The supraglottic method is a simple one but not always satisfactory since it may be difficult to outline all the branches Even under fluoroscopic guidance the lipiodol cannot always be properly directed

Transglottic Method This is perhaps the best method A catheter is used for the instillation of the lipiodol and the course of the latter can be directed more adequately It is a better way of filling the upper lobes

The patient is anesthetized and in addition one side of his nose is sprayed A No 16 rubber catheter is passed through the nose to the pharynx The tongue is held with a piece of gauze and under deep breathing the catheter is slipped through the larynx into the trachea The catheter may be directed into the larynx with the help of a laryngeal mirror and a long curved forceps If a preliminary bronchoscopy is performed the catheter may be inserted through the nose and directed with the help of a direct laryngoscope A coude catheter with its firm end that is directed to one side is especially good for the procedure since it is more easily placed in the selected branches The catheter is fastened to the nose with adhesive so that it is not coughed out Additional anesthesia may be administered through the catheter if necessary

The patient is placed on a fluoroscopic table if possible a tilt table The lipiodol is instilled on one side and the head of the table lowered The lipiodol is seen to pass into the upper portions of the lung The patient is turned on his side to an almost prone position Lipiodol is slowly instilled at intervals during the maneuvers No coughing or deep breathing is encouraged If possible spot films are taken in various positions The other lung is filled in a similar manner and films taken These may be supplemented by taking additional views with the patient in the erect position Fluoroscopy should not be prolonged because of the tendency of the lipiodol to enter the alveoli and obscure the picture.

Subglottic Method This is mentioned in order to be condemned By this method the trachea or cricothyroid membrane is punctured

with a needle and lipiodol instilled Subcutaneous emphysema may follow this procedure It is an unnecessary risk

Bronchoscopic Method Lipiodol may be instilled through the bronchoscope at the time bronchoscopy is done A small spiral tipped tube may be used to place lipiodol into the branch bronchi In this way one or two selected branches or areas may be filled when it is impor [illegible]

available

BRONCHOGRAPHY IN CHILDREN

A considerable amount of patience time teamwork and good fortune is necessary in order to obtain adequate bronchograms in a child The actual procedure is very similar to that performed in adults but is shunned by many of us because it is so extremely trying and time-consuming However the more one does the easier it becomes to accomplish what one sets out to do

Various methods of anesthesia may be used in children Under four years of age it is possible to do a fast study under no anesthesia at all Above the age of four years a bronchogram may be done under local anesthesia Pontocaine xylocaine or butyn which are less toxic than cocaine may be used in lesser strengths and in smaller amounts and may be given by spraying or by nebulization After spraying with the tongue out the anesthesia is dropped on the base of the tongue and allowed to enter the larynx trachea and bronchi Either the supraglottic (passive) method or the transglottic (catheter) method may be used The catheter should not be too large as it must not interfere with adequate airway in the glottis Direct or indirect laryngoscopy may be necessary to insert the catheter If required additional anesthesia may be given through the catheter Premedication in the form of a barbiturate and/or codeine and atropine should be administered in doses as required according to the age of the child Fluoroscopic control may be used the lipiodol distributed by assuming the aforementioned positions and the de-

is a great aid in diagnosing and often essential in treating various pulmonary conditions Some like to do a bronchogram under general anesthesia and in young children who are difficult to manage this may be the better way

DANGERS IN BRONCHOGRAPHY

Sensitivity to local anesthesia is the most frequent difficulty encountered but premedication and anesthesia in small amounts will help to alleviate this trouble Iodism occasionally is encountered but a history of this is usually obtained The use of ACTH recently has been reported successful Constant observation and as little lipiodol as possible should be used in patients with limited lung capacity Infrequently lipoid pneumonia and the formation of granuloma are reported, but again these may be avoided by using as little lipiodol as possible Do not insert lipiodol under pressure and avoid overfilling Postural drainage is most important after the procedure Of course in the presence of an acute infection it would be unwise to perform a bronchography In general relatively few dangers are involved in this procedure and with extra precautions and extreme care the majority of them can be avoided

REFERENCES

ATWELL, R J and PEDERSEN R L Water soluble contrast medium for bronchography *Dis of Chest* 18 535 1950

COHEN M H HENTAL, W and BRANDENSTEIN L Evaluation of iodoron B in bronchography *Dis of Chest* 21 286 1952

EE [illegible]AN F G Bronchography in the infant and very young child *Ann Otol Rhin & Laryng* 60 83 1951

GORDON J ZINN W H BROOK, R and PRATT P C Bronchography as an aid in pleurisy Surgical treatment of pulmonary tuberculosis *J Thoracic Surg* 22 109 1951

JACKSON C L and HUBER J F *Dis of Chest* 9 319 1943

MES [illegible] DH [illegible]

NOR [illegible] th diones *Ann* [illegible] 1954

PARK, F H CRONIC, H and CRONK, G Prevention of iodism in bronchography by use of ACTH *Dis of Chest* 24 219 1953

RABINOWITZ, P and HARPER, I S H Bronchography in pulmonary tuberculosis *Dis of Chest* 19 66 1951

RIGLER, L The Chest Chicago 1947 Year Book Publishers.

STORRS, R P., McDONALD, J R and GOOD, C Lipoid granuloma of the lung following bronchography with iodized oil *J Thoracic Surg* 18 561 1949

16

Angiocardiography

ISRAEL STEINBERG M D New York New York

From the Departments of Radiology and Medicine The New York Hospital Cornell Medical Center New York Aided by a grant from the Mallinckrodt Chemical Works

IN 1938 a practical method of visualizing the chambers of the heart the pulmonary circulation and the great blood vessels during life (now called angiocardiography) was introduced[1] This was followed by detailed descriptions of the opacified cardiovascular structures in health and disease so that in the ensuing sixteen years the importance of angiocardiography in clinical medicine has become established[2-4]

METHOD

Angiocardiography is a roentgen method of visualizing the cardiovascular structures It is

tion is achieved by the use of a special Teetle stopcock unit of 12 gauge a special 50 cc Luer lock syringe with 12 gauge tip and injection of the contrast substance with the arm elevated during inspiration[2] Sodium urokon® (sodium acetrizoate) 70 per cent, has been found to be the contrast medium of choice with the least side effects and reactions[5] The dose of sodium urokon for children is 1 cc per kg of body weight for adults depending on weight it is between 35 and 50 cc

For angiocardiography of pulmonary disease in the adult full size 14 by 17 inch films are necessary In such cases a standard stereo casette shifter may be used and will provide two films per injection The circulation time in pulmonary disease is usually normal unless there is heart failure or cor pulmonale Accordingly exposures at 2 5 and 6 5 seconds after the beginning of the injection will in the majority of instances allow study of the pulmonary arterial and venous circulations For children and adults of small stature the Fairchild 9 by 9 inch roll film casette[6] or the new 12 by 12 inch F X R magazine[7] will provide multiple (two per second) films during opacification of the cardiovascular system

The erect postero anterior (frontal) view is the best position for visualizing the pulmonary arterial and venous systems (Fig 1) The lateral view is particularly desirable in localiz

artery There should be no hesitation to give a second injection to secure lateral or oblique views fatality has rarely occurred during angiocardiography for the study of pulmonary disease

CONGENITAL ANOMALIES OF THE PULMONARY CIRCULATION

The role of the congenital pulmonary vascular anomalies in pulmonary disease is just beginning to be appreciated Angiocardiography by delineating the pulmonary arterial and venous circulations makes possible the clinical recognition during life of many obscure anomalies Diagnosis can then be followed by definitive treatment

Absence of a Main Branch Pulmonary Artery Either the right or left main branch of the pulmonary artery may be congenitally absent and the diagnosis of this newly recognized entity can often be made by conventional roent

opposite lung is hypoplastic and poorly vascularized (Fig 2A) The angiocardiographic study (Fig 2B) demonstrates absence of the right pulmonary artery and the circulation of the overdistended left lung Other studies utilizing rapid serial roentgenography disclosed that the bronchial arterial circulation alone was responsible for the right lung vasculature

Experience in three cases indicates that ab-

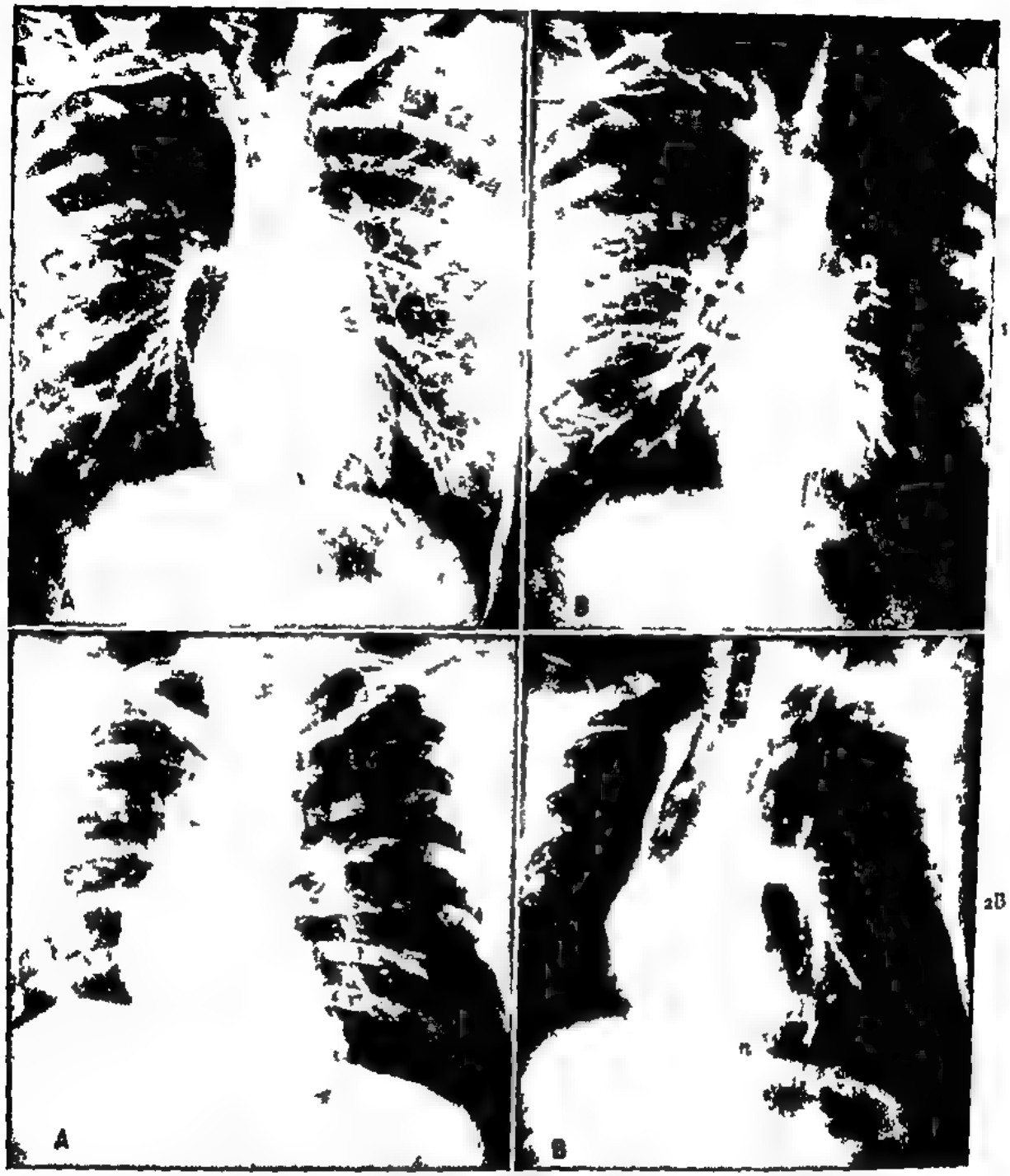

FIG 1 The normal frontal angiocardiogram (twenty year old woman) A opacification of right subclavian and innominate veins superior vena cava right atrium and ventricle pulmonary artery (main stem right and left branches) and pulmonary arterial tree is seen B the pulmonary venous system (arrow points to right inferior pulmonary vein) the left atrium and ventricle and the aorta are visualized

FIG 2 Congenital absence right pulmonary artery (twenty four year old man) A conventional x ray There is displacement of the heart trachea and mediastinum toward the right Right lung is hypoplastic and vasculature is almost absent B angiocardiogram reveals an absent right pulmonary artery

sence of a main branch pulmonary artery is usually discovered during routine chest x ray survey The condition may be mistaken for a mediastinal tumor Limited experience indicates that this anomaly requires no treatment and that the prognosis is good However these patients must be kept under observation for the occurrence of pneumonia in the normal lung may raise havoc with the gaseous exchange processes

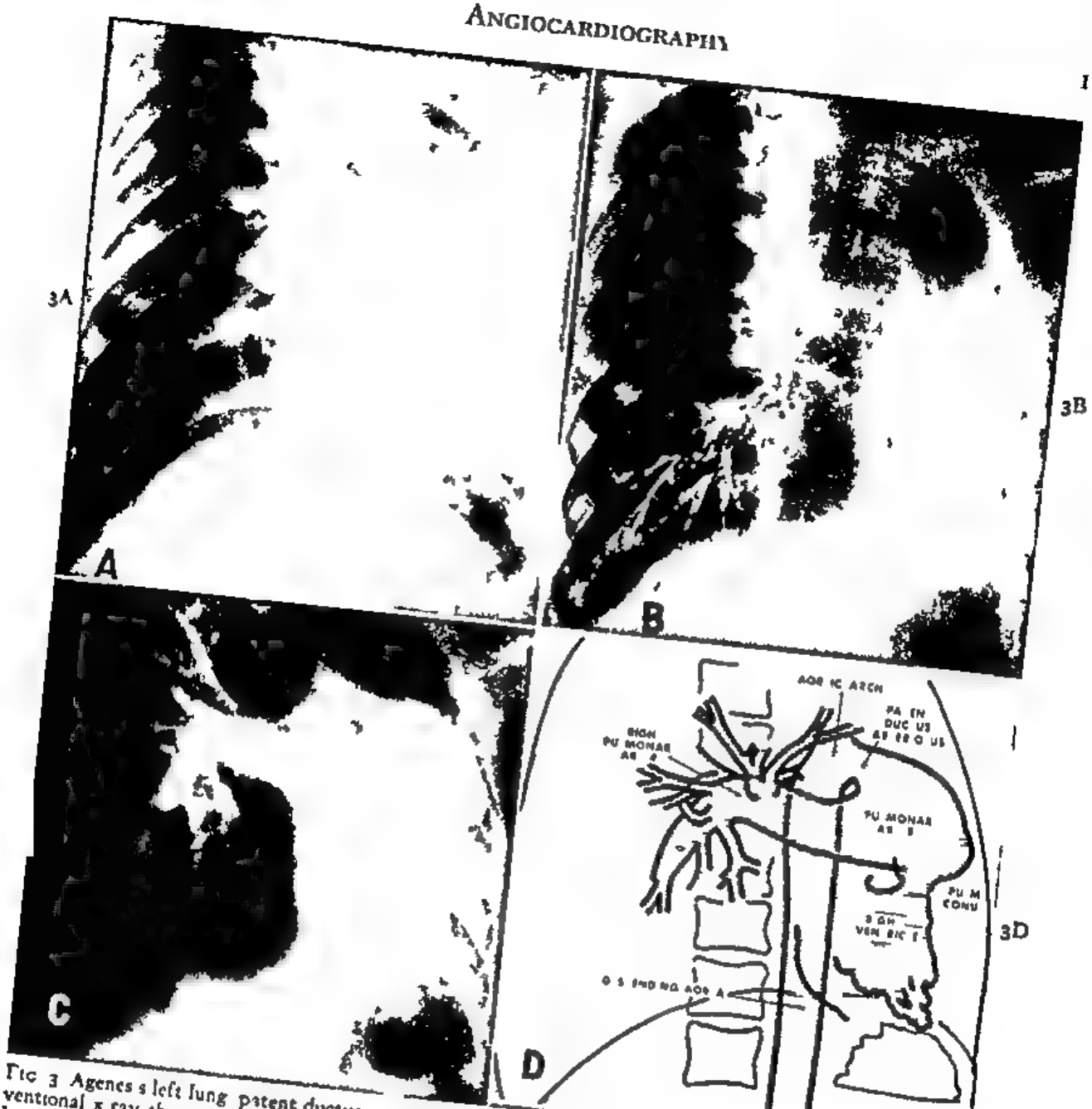

FIG 3 Agenesis left lung patent ductus arteriosus with reversal of flow (twenty two
ventional x ray shows opaque lower two-thirds left lung field
heart into left thorax Aerated left upper
gram demonstrates absent
enlarged right heart a huge
Simultaneous opacification o
From Lukas et al New Eng

Absence of a main branch pulmonary artery also occurs in lung agenesis The diagnosis of agenesis of a lung and differentiation from an acquired fibrothorax depends upon the demonstration by bronchography or bronchoscopy of a congenitally absent bronchus The diagnosis should be suspected if there is an opaque shrunken thorax containing the mediastinal structures heart and great blood vessels (Figs 3A 3B) In a twenty two year old patient in addition to absence of the left pulmonary artery (Figs 3C, 3D) there was also a markedly enlarged pulmonary artery and right branch due to pulmonary hypertension and a patent ductus arteriosus with reversal of the blood flow This complication makes ligation of the

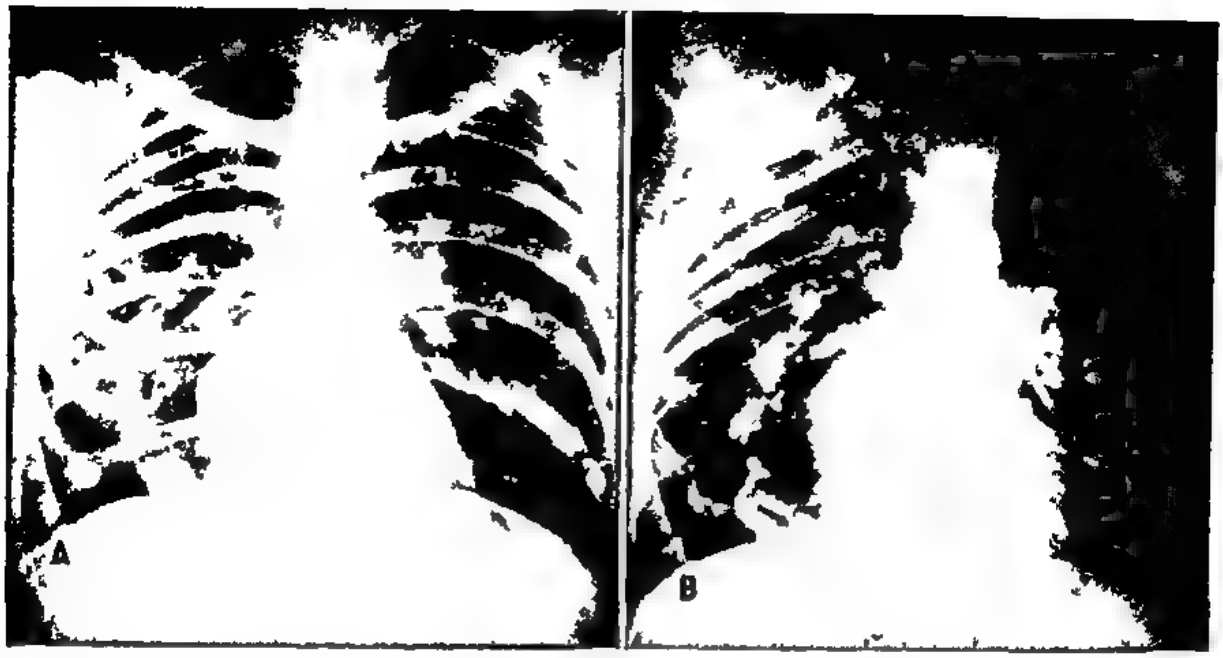

4A 4B

FIG 4 Anomalous right pulmonary vein entering inferior vena cava (twenty two year old man) A conventional x ray reveals a crescentic shadow in lower part right lung The right atrium is somewhat enlarged B angiocardiogram at time of left heart filling shows the crescentic shadow to be the right pulmonary vein (arrow) which enters the inferior vena cava Courtesy of Paul B Hoeber Inc [8]

ductus hazardous [12] Recently, Maier and Gould[13] reported tracheal compression by the remaining pulmonary artery in an infant with agenesis of the lung This mechanism may explain the cause of death early in life In the adult agenesis of the lung unless complicated by a congenital cardiovascular anomaly or pulmonary disease, is compatible with life

Anomalous Insertions of Pulmonary Veins In 1949 partial anomalous insertion of the right pulmonary vein into the inferior vena cava was diagnosed during life by angiocardiography and cardiac catheterization [14] Since then recognition of totally anomalous pulmonary drainage into the right atrium and its tributaries has also become possible Diagnosis of these conditions is important for the reanastomosis of pulmonary veins into the proper atrium in specially selected cases may be life-saving [15]

Figure 4A is the classic conventional roentgenogram of a patient with a right pulmonary vein draining into the inferior vena cava The crescentic broad vascular channels of the anomalous right pulmonary vein converging toward the cardiohepatic angle and inferior vena cava is clearly identified by the angiocardiogram (Fig 4B) No treatment is indicated in such a case for the anomalous pulmonary venous circulation involves only one lung and there are no cardiovascular complications In such instances the patient is often asymptomatic and the condition is usually discovered after routine chest x ray survey

On the other hand patients with partial anomalous pulmonary venous drainage complicated by a large interatrial septal defect pulmonic stenosis or acquired rheumatic heart disease with mitral stenosis may be seriously

tients suspected of having totally anomalous pulmonary venous drainage When the anomalous pulmonary veins insert into the left innominate vein a characteristic roentgen picture results (Fig 5A) The abnormal mediastinal and hilar shadows have been likened to a 'figure of eight' [16] a 'dumbell silhouette' [17] a 'mediastinal mustache' [18] and a 'cottage loaf' [19] On angiocardiography (Fig 5B) the widened mediastinal and hilar shadow on the left is seen to be due to the dilated common pulmonary venous trunk (persistent left superior vena cava) inserting into the left innominate vein, while on the right side, it is due to the dilated superior vena cava, enlarged because of the increased blood flow from the left innominate vein The patient whose

roentgenograms are illustrated in Figure 5 was mistakenly diagnosed as having a lymphoma and given roentgen therapy at another hospital This is the oldest (aged forty-two) recorded case in the literature Polycythemia, residual left hemiplegia and congestive heart failure precluded corrective surgery

Another patient with total insertion of pulmonary veins into the superior vena cava and right atrium had an associated atrial septal defect (in total anomalous pulmonary venous drainage this must exist for life) [18] The conventional chest roentgenogram suggested the diagnosis because of an anomalous appearing pulmonary vessel at the right base (Fig 6A) Angiocardiography confirmed the diagnosis of anomalous drainage of the pulmonary veins In addition, a newly recognized sign, a filling defect, at the site of insertion of the anomalous veins into the right atrium and ventricle was present (Fig 6B) The filling defect is due to the turbulence created by the anomalous pulmonary venous blood flow Surgical exploration, by Dr Laurence Miscall, verified the presence of a common venous channel inserting into the right atrium and superior vena cava Reinsertion of the pulmonary veins into the left atrium could not be done because of the underdeveloped left atrium and appendage (estimated as being one-tenth normal size) [19]

Anomalous Pulmonary Vessels from the Aorta The surgical importance of anomalous systemic blood vessel insertions into the lung[20] and their relation to sequestration of the lung have recently been reviewed [21] Through the courtesy of Dr Herbert C Maier a patient with anomalous abdominal aorta branches piercing the right diaphragm and inserting into the lung was studied Figure 7 is a roentgenogram of a young patient who was disabled because of dyspnea Angiocardiographic study (Figs 7B, 7C) reveals the heart to be rotated into the right thorax while the right pulmonary arterial tree is hypoplastic Figure 7D shows two branches of the abdominal aorta (arrow) piercing the right diaphragm and entering the lung At operation, Dr Maier ligated and divided the two aberrant arteries Complete relief from the incapacitating dyspnea resulted and the patient was able to return to full physical activity In this case, surgical treatment was done probably before infection and cystic degeneration of the lung (sequestration) occurred

Pulmonary Arteriovenous Fistulas A few years ago the existence of pulmonary arteriovenous fistulas was unknown Since the advent of safe exploration of the lungs, angiocardiography, body section radiography and the fluoroscopic recognition of change in size of these lesions with respiratory maneuvers (Mueller and Valsalva), many cases have been recognized [22] Pulmonary arteriovenous fistulas are of congenital origin and are closely related to hereditary hemorrhagic telangiectasis (Rendu-Osler-Weber's disease) Untreated cases of pulmonary arteriovenous fistulas run the risk of vascular thrombosis in that they may have unsaturated blood and polycythemia Other complications are brain abscesses[23] and fatal hemoptysis [24] For these reasons surgical excision of the pulmonary arteriovenous fistulas, especially if isolated and uncomplicated, even in the absence of signs and symptoms, is advocated At this center, a left upper lobectomy in one sibling and segmental resection of the apical segment of the right lower lobe in the other were done in two sisters who had pulmonary arteriovenous fistulas even though they were asymptomatic [25] The curative and preventative features of this type of prophylactic surgery far outweigh the small operative risk

Figure 8A shows the conventional roentgenogram of a patient who on routine chest x-ray showed the characteristic roentgen finding of pulmonary arteriovenous fistulas A nodular parenchymal shadow at the right base connected with the pulmonary artery and an afferent vessel (a pulmonary vein) was present at its lower pole and proceeded toward the left atrium Physical examination disclosed a vascular bruit There was no polycythemia or cyanosis Angiocardiography (Fig 8B) clearly visualized the lesion and localized the arteriovenous fistula in the posterior basilar segment of the right lower lobe At operation Dr Frank Glenn found that ligation of the bronchial vessels was necessary to eliminate the bruit and thrill of the arteriovenous fistula and so lobectomy was done The patient made an uneventful postoperative recovery This too, is an example of prophylactic thoracic surgery

PULMONARY INFECTIONS

In pulmonary infection angiocardiography is mostly of academic interest. Verification of the presence of extensive pulmonary circulatory involvement, especially in the more chronic

FIG. 8. Total anomalous pulmonary venous drainage inserting into the superior vena cava and right atrium (sixteen year old schoolgirl). A. conventional x-ray reveals an enlarged right heart and increased pulmonary vasculature. Arrow points to a prominent right inferior pulmonary vein. B. angiocardiogram at 2½ seconds shows a filling defect of the superior vena cava and right atrium at site of anomalous pulmonary venous insertion. The right ventricle and pulmonary artery are enlarged.

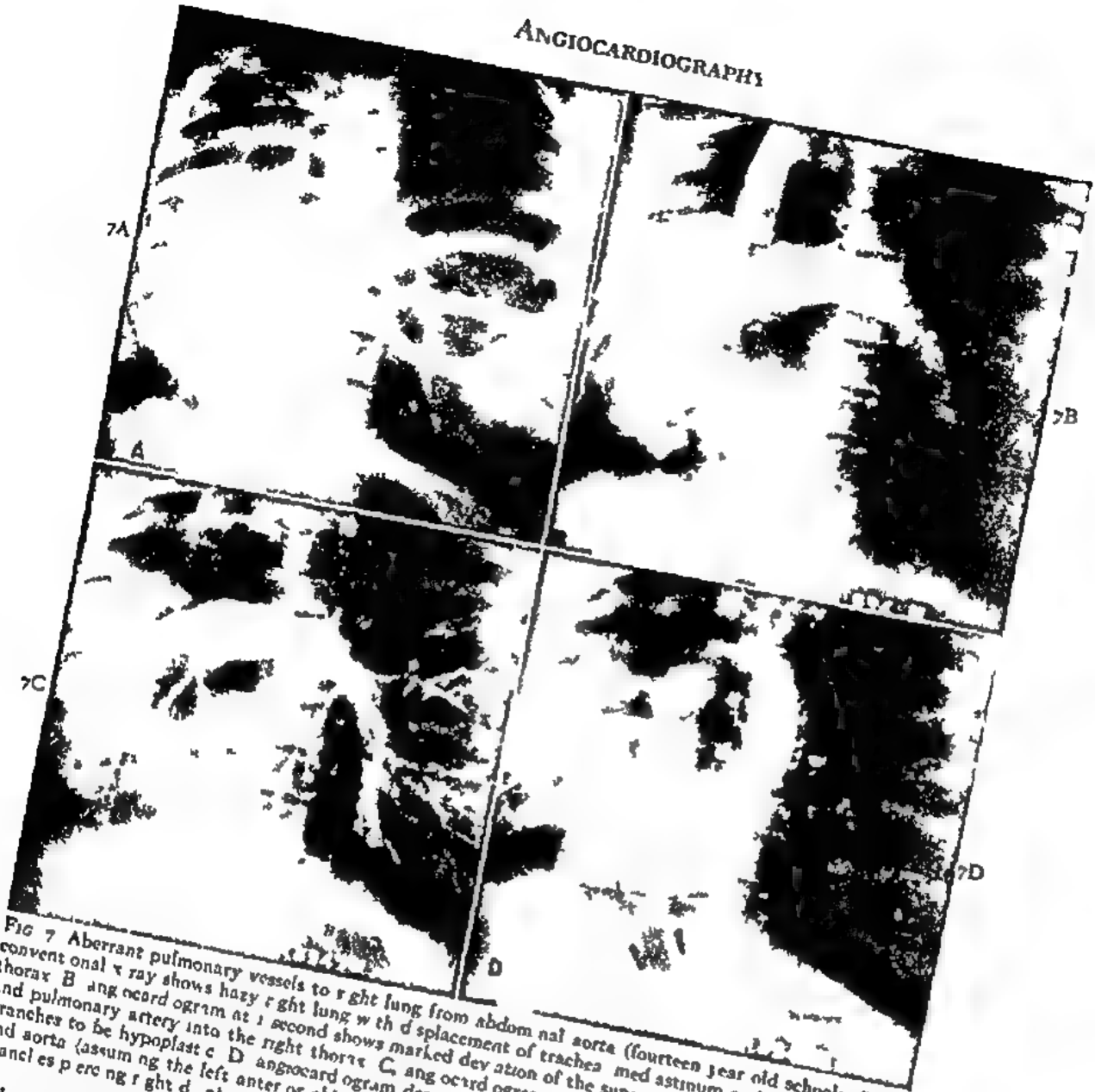

FIG 7 Aberrant pulmonary vessels to right lung from abdominal aorta (fourteen year old schoolgirl) A conventional x ray shows hazy right lung with displacement of trachea mediastinum and heart into right thorax B angiocardiogram at 1 second shows marked dilatation of the superior vena cava the right heart and pulmonary artery into the right thorax C angiocardiogram reveals the right pulmonary artery and branches to be hypoplastic D angiocardiogram demonstrates deviation and rotation of the left ventricle and aorta (assuming the left anterior oblique position) Arrows point to two anomalous abdominal aorta branches piercing right diaphragm into the lung

lung diseases can be obtained However abnormal diagnostic pulmonary vascular patterns have as yet not been recognized

In pulmonary tuberculosis varying degrees of pulmonary avascularity depending upon the amount of lung tissue involved can be seen by angiocardiography In the fibrothorax which sometimes follows the healing of pulmonary tuberculosis (Fig 9) striking cardiovascular distortion may be shown Similarly in the collapse measures formerly commonly used in treatment of pulmonary tuberculosis (artificial pneumothorax pneumoperitoneum thoracoplasty and phrenicolysis) a common feature has been diminution and deformity of the pulmonary vasculature Thoracoplasty in particular is probably especially effective by decreasing overdistention of the opposite lung (Fig 9)

In bronchiectasis and lung abscess very little abnormality in the pulmonary vascularity can be demonstrated angiocardiographically until

8A

8

9A

9B

FIG 8 Pulmonary arteriovenous fistula posterior basal segment right lower lobe (fifty four year old asymptomatic man) A conventional x ray shows the characteristic rounded density just above right diaphragm Afferent pulmonary arterial and efferent pulmonary arteriovenous connections are present B angiocardiogram clearly identifies the aneurysm with its vascular connections

FIG 9 Left fibrothorax (tuberculous) treated by thoracoplasty (forty two year old woman) A angiocardiogram reveals marked tracheal mediastinal and cardiac displacement (fibrothorax) which resulted after re-expansion of an ineffective pneumothorax for far advanced pulmonary tuberculosis No left pulmonary artery was seen and there was marked overdistention of the right lung and pulmonary arterial tree B angiocardiogram following left thoracoplasty The position of the pulmonary artery became more central and the right lung and pulmonary arterial circulation returned to a more normal position

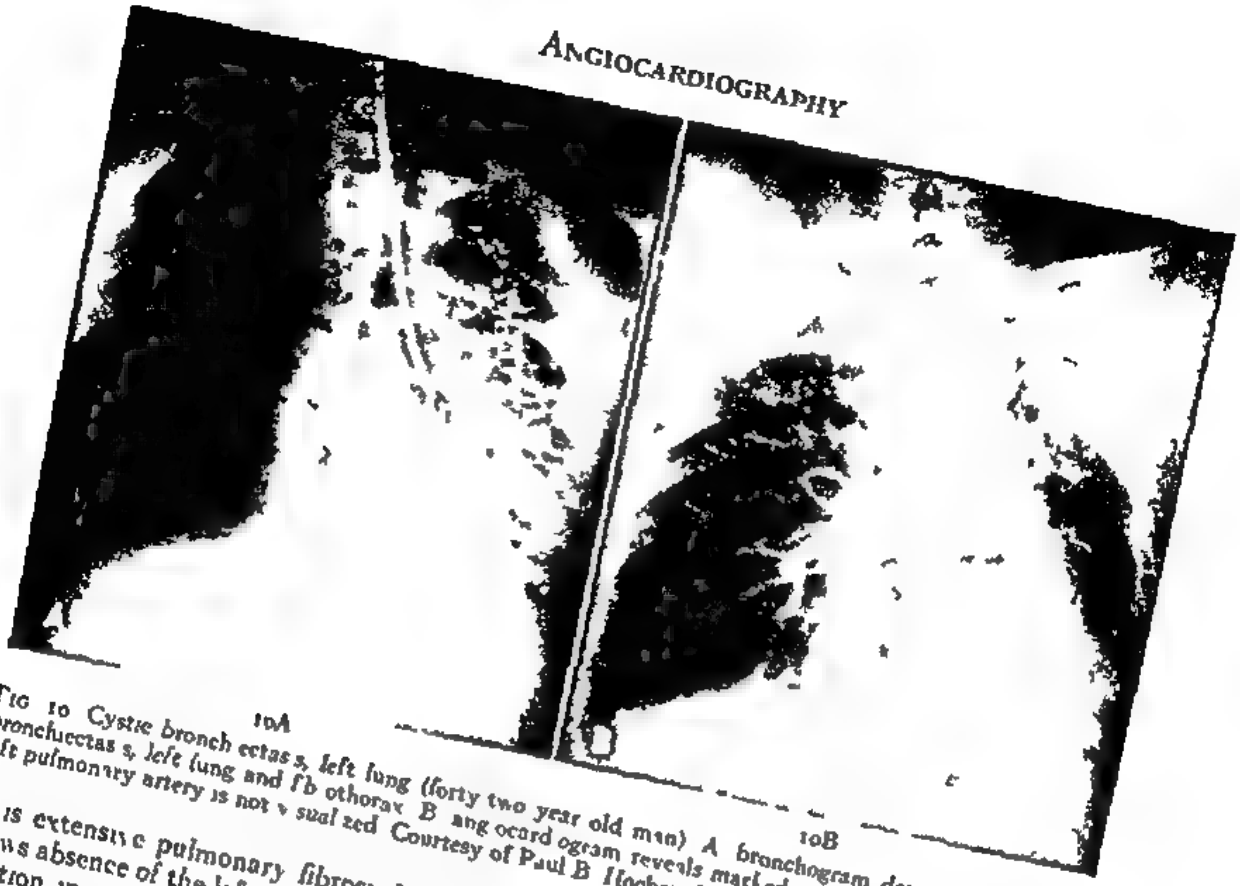

10A 10B

FIG 10 Cystic bronchiectasis, left lung (forty two year old man) A bronchogram demonstrates cystic bronchiectasis, left lung and fibothorax B angiocardiogram reveals marked rotations of the heart The left pulmonary artery is not visualized Courtesy of Paul B Hoeber Inc

there is extensive pulmonary fibrosis Figure 10 shows absence of the left pulmonary arterial circulation in a patient with unilateral cystic bronchiectasis associated with fibrothorax of the left lung

PULMONARY FIBROSIS

Pulmonary fibrosis is not uncommon in lung disease It follows many pulmonary chronic infections like tuberculosis, bronchiectasis and lung abscess It occurs in the pneumoconioses varying from the fine granulations of anthracosis to the coarse nodulations of silicosis in granulomatous lung disease (Boeck's sarcoid) and in the collagen diseases that affect the lung such as scleroderma In such cases the effect of the fibrosis in obliterating the pulmonary vascular bed and causing pulmonary hypertension and cor pulmonale must be kept in mind One of the earliest signs in the development of pulmonary hypertension is enlargement of the pulmonary artery and branches Detection of enlargement of the pulmonary artery and branches may be difficult by conventional roentgenography but easily accomplished by angiocardiography Angiocardiography by demonstrating the large size of the pulmonary artery and main branches may therefore give the first hint of the development of pulmonary heart disease Such was the case in an elderly woman with progressive pulmonary fibrosis (Fig 11A) in whom enlargement of the hilum was thought to be due to either sarcoid involvement of the hilar lymph nodes or the development of a pulmonary neoplasm Angiocardiography (Fig 11B) however disclosed an enlarged pulmonary artery and branches which reflected the pulmonary hypertension and the compensated cor pulmonale which had developed secondary to the pulmonary fibrosis Visualization of an unfolded arteriosclerotic aorta also ruled out the presence of an aortic aneurysm

DIFFERENTIATION OF PULMONARY MEDIASTINAL AND HILAR MASSES FROM ANEURYSM

Enlargement or aneurysm of the great vessels (superior vena cava pulmonary artery and aorta) may because of their hilar and mediastinal locations simulate pulmonary or mediastinal disease An example of enlargement of the superior vena cava (right and persistent left) is present in Figure 5 wherein completely anomalous pulmonary veins drain into the left innominate vein Enlargement of the pulmonary artery and branches secondary to p

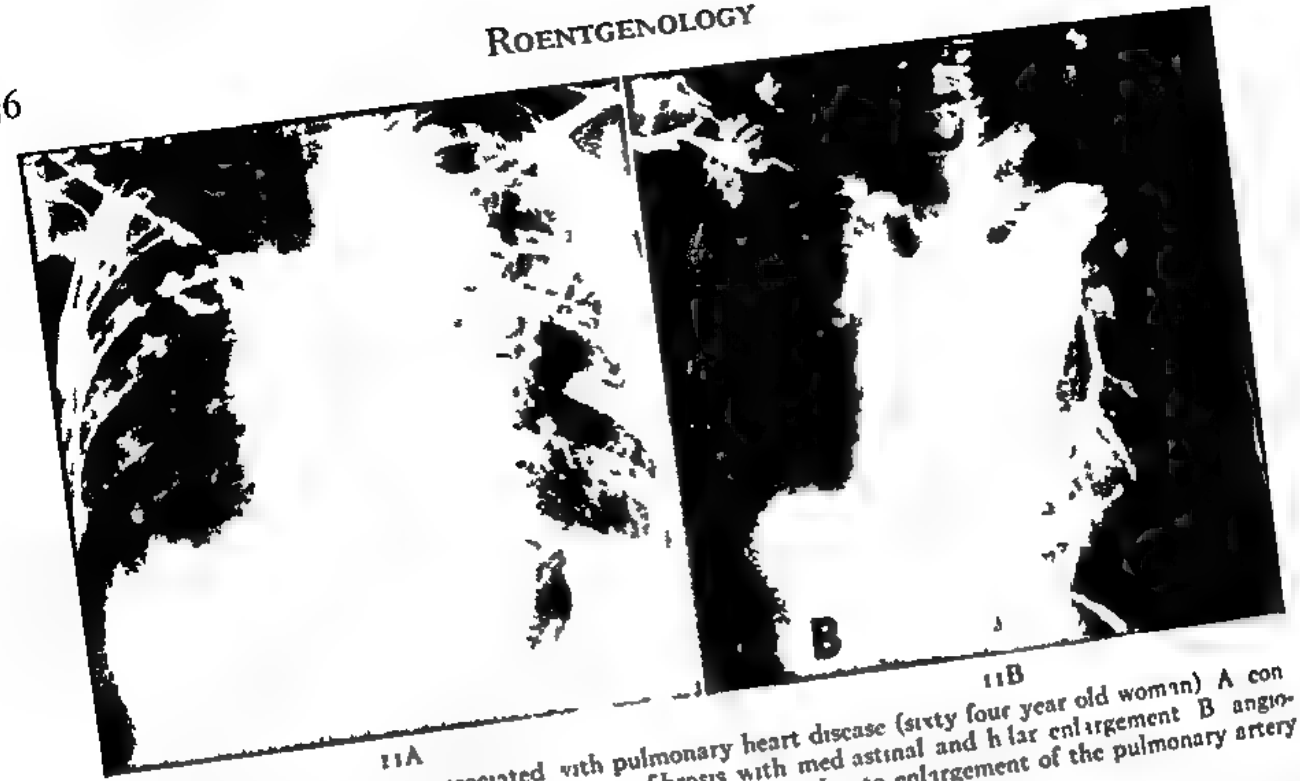

11A 11B

FIG 11 Pulmonary fibrosis associated with pulmonary heart disease (sixty four year old woman) A conventional x ray shows widespread pulmonary fibrosis with med astinal and h lar enlargement B angiocardiogram reveals the med astinal and hilar widening to be due to enlargement of the pulmonary artery and branches (compensated cor pulmonale)

monary fibrosis is seen in Figure 11 Syphilitic aortic aneurysms are fortunately becoming rare Because of their intimate hilar and mediastinal situation they may compress or occlude major bronchi causing pulmonary suppuration and fibrosis and simulate lung cancer In such instances angiocardiography by revealing the aneurysm will establish the diagnosis and make thoracotomy unnecessary [22–26]

MISCELLANEOUS PULMONARY DISEASES

In varied pulmonary disease angiocardiography has demonstrated during life pulmonary vascular lesions which previously could only be suspected from conventional roentgenography Here again angiocardiography is mostly of academic value in that it provides a better understanding of the pathologic process Absent pulmonary vasculature beginning abruptly in major or segmental pulmonary arteries has been demonstrated in patients having a pulmonary embolus [3] In another patient with a chondroma occluding the right lower lobe bronchus markedly diminished circulation was present Following bronchoscopic removal of the tumor the right lower lobe circulation returned to a normal state [3] In contrast to the decreased circulation in chronic pneumonitis that is associated with bronchiectasis chronic lung abscess and aspiration pneumonia (which probably reflects the degree of fibrosis that accompanies the chronic pneumonia), the pulmonary circulation in acute pneumonia remains unaltered

Marked deformity of the pulmonary artery, branches and tree secondary to the pulmonary changes may occur in thoracic deformity, especially kyphoscoliosis [16] In generalized emphysema a "winter tree" pattern with wiry secondary and tertiary branches may be seen [3] Characteristic crowding together of lobar or segmental pulmonary arterial vessels can also be seen in atelectasis (Fig 12) In pleural mesothelioma deformity of the main pulmonary artery is a feature of the diffuse malignant type [27] In diffuse metastatic neoplastic involvement of the lung no vascular abnormality is seen Metastatic involvement of the mediastinal structures however, may result in deformity of the great vessels (superior vena cava and pulmonary arterial) and be recognized after angiocardiography [3]

BULLOUS EMPHYSEMA

Bullous emphysema is believed to be due to localized subpleural vesicular emphysema which arises within the lung parenchyma from a conglomeration of distended vesicles The bullae may vary in size from small air sacs to huge balloon like structures involving a whole

FIG. 12 Two cases of atelectasis right and left upper lobes of the lung due to bronchial carcinoma A angiocardiogram reveals crowded right upper lobe circulation (arrow) in an atelectatic right upper lobe due to bronchial cancer B atelectasis due to carcinoma occluding the left upper lobe bronchus Arrow points to filling defect caused by destruction of the apical posterior segmental branch of the left ascending pulmonary artery In both instances surgical resectability can be predicted by the angiocardiogram

14A

14B

15A

15B

FIG. 14. Superior vena caval syndrome due to cancerous obstruction and invasion of superior vena cava (forty-nine year old man). A, conventional x-ray shows widening of anterosuperior mediastinum. No pulmonary disease was demonstrated by x-ray and thoracotomy. B, angiocardiogram revealing intraluminal superior vena cava obstruction and deformity due to cancer primary in right lung (proved at necropsy).

16A

16B

17A

17B

FIG. 16. Complete left pulmonary artery occlusion by cancer of lung (fifty seven year old man). A, frontal angiocardiogram reveals an absent left pulmonary artery (arrow) due to cancer involvement. B, left anterior oblique angiocardiogram demonstrates the absent left branch (arrow) at bifurcation of the main pulmonary artery.

FIG. 17. Partial occlusion left pulmonary artery by lung cancer (fifty three year old man). A, angiocardiogram shows deformity (arrow) and reduction in size of left pulmonary artery. B, lateral angiocardiogram shows the dwarfed left pulmonary artery and site of narrowing (arrow) produced by the cancer.

FIG 18 Polypoid invasion superior vena cava following right pneumonectomy for cancer of lung (fifty one year old male) Angiocardiogram reveals polypoid deformity of the superior vena cava (arrow) due to recurrence of cancer

or most of both lungs Symptoms may be lacking and the condition revealed by routine chest x ray examination Patients with extensive bullae especially those with associated generalized emphysema fibroid tuberculosis bronchiectasis and pulmonary fibrosis of varied etiologies may on the other hand be quite dyspneic and totally disabled They are also liable to have spontaneous pneumothorax

emphysema is often a progressive disease which is liable eventually to destroy enough lung structure to produce what has been termed the vanishing lung To cope with such an eventuality surgical excision of bullae before they have become massive and require lobectomy is being advocated [28,29]

Angiocardiography has been found useful to assess the state of the pulmonary circulation in bullous emphysema Often the conventional chest x ray (Fig 13A) fails to reveal the true extent of the bullae for lung markings from neighboring lung tissue may be seen through the transparent air sacs Opacifying the pulmonary circulation (Fig 13B) will often clearly delimit the bullae as they are devoid of circulation Furthermore the crowding of the pulmonary circulation toward the bases as shown in Figure 13B demonstrates the degree of compression of functioning lung tissue Angiocardiography in bullous emphysema may therefore be used as a guide to the selection of the cases suitable for surgery Functional reexpansion of the lung and return of the lung and the pulmonary circulation to its proper location has followed surgical excision of bullae Marked symptomatic improvement permitting the patient to return to work has resulted [29]

LUNG CANCER

cent there was involvement of the great blood vessels (superior vena caval and pulmonary arterial systems) In almost one-half of these (42 per cent) the invasion or occlusion of the pulmonary artery and the superior vena cava system was at major sites which made it doubtful that surgical attack might affect cure [40]

Invasion of the superior vena cava by lung cancer is shown in Figure 14 Occlusion of the superior vena cava with resultant collateral circulation through the vena azygos system is seen in Figure 15 In addition the cancer has occluded the right pulmonary artery proximal to its bifurcation into the ascending and descending branches Occlusion of the left pulmonary artery as it emerges from the main stem pulmonary artery is demonstrated in Figure 16 Marked deformity with obstruction of the left pulmonary artery at the hilum is depicted in Figure 17 In contrast to the foregoing serious major vessel involvement lobar (Fig 12A) and segmental (Fig 12B) pulmonary arterial involvement are favorable signs for operation [9,40,41]

Angiocardiography may also prove useful in assessing the results of radiation and surgical treatments Figure 12A is the x ray of a patient who had atelectasis of the right upper lobe due to carcinoma involving the bronchus He refused operation and was treated by x radiation Angiocardiography following completion of the course of treatment showed complete reexpansion of the right upper lobe and he has been free of evidence of recurrence for three years On the other hand a patient who

had a pneumonectomy because of right lung cancer (Fig 18), soon began to show clinical evidence of superior vena cava obstruction (superior vena cava syndrome) Angiocardiography revealed recurrence of the cancer in the right thorax with superior vena cava invasion

Superior vena cava and major pulmonary artery invasion stenosis and occlusion are not pathognomonic of lung cancer Similar lesions have been produced by lymphoma and syphilitic aneurysm [342] Segmental and lobar pulmonary artery derangement also occurs in many pulmonary diseases (infection fibrosis emphysema) Accordingly assessment of the role of the vascular lesions must only be made when cellular or biopsy proof of lung cancer is available, Only then will the information provided by angiocardiography aid the surgeon to plan the attack on the neoplasm

REFERENCES

1 ROBB G P and STEINBERG I A practical method of visualization of the chambers of the heart the pulmonary circulation and the great blood vessels in man *J Clin Investigation* 17 507 1938

2 ROBB G P and STEINBERG I Visualization of the chambers of the heart pulmonary circulation and the great blood vessels in man a practical method *Am J Roentgenol* 41 1 17 1939

3 DOTTER, C T and STEINBERG I Angiocardiography New York 1951 Paul B Hoeber Inc

DOTTER C T and STEINBERG I Angiocardiography in congenital heart disease *Am J Med* 12 219–237 1952

STEINBERG I Angiocardiography in diseases of the chest *Dis of Chest* 24 477 478 1953

STEINBERG I DOTTER C T and GLENN F Myxoma of the heart roentgen diagnosis during life in three cases *Dis of Chest* 24 509–521 1953

7 DOTTER C T WETCHLER, M S and STEINBERG I Contrast substances for angiocardiography study of side effects *Radiology* 60 691–698 1953

8 DOTTER, C T STEINBERG I and TEMPLE H L Automatic roentgen ray roll film magazine for angiocardiography and cerebral arteriography *Am J Roentgenol* 62 355 358 1949

9 STEINBERG I DUBILIER W and IVANS J A New twelve inch roll film magazine for rapid serial roentgenography *Radiology* in press

10 STEINBERG I DOTTER, C T and LUKAS D S Congenital absence of a main branch of the pulmonary artery *J A M A* 152 1216–1218 1953

11 LUKAS D S DOTTER, C T and STEINBERG I Agenesis of the lung and patent ductus arteriosus with reversal of flow *New England J Med* 249 107 109 1953

12 LUKAS D S ARAUJO J and STEINBERG I The syndrome of patent ductus arteriosus with reversal of flow *Am J Med* 17 298–310 1954

13 MAIER, H C and GOULD W J Agenesis of the lung with vascular compression of the tracheobronchial tree *J Pediatrics* 43 38–42 1953

14 DOTTER, C T HARDISTY N M and STEINBERG I Anomalous right pulmonary vein entering the inferior vena cava report of two cases diagnosed during life by angiocardiography and cardiac catheterization *Am J M Sc* 218 31 36, 1949

15 SEPULVEDA G, LUKAS D S and STEINBERG I Anomalous drainage of pulmonary veins clinical physiologic and angiocardiographic features *Am J Med* in press

16 SNELLEN H A and ABBERS T H The clinical diagnosis of anomalous pulmonary venous drainage *Circulation* 6 831 816 1952

17 GARDNER, F and GRAY S Persistent left superior vena cava draining pulmonary veins *Brit Heart J* 15 305 317 1953

18 KEITH J D ROWE R D VLAD P and O HANLEY S H Complete anomalous pulmonary venous drainage *Am J Med*, 16 23 38 1954

19 WHITAKER, W Total pulmonary venous drainage through a persistent left superior vena cava *Brit Heart J* 16 177 188 1954

20 FINDLEY C W and MAIER H C Anomalies of the pulmonary vessels and their surgical significance *Surgery* 29 604–641 1951

21 BRUWER, A J CLAGETT O T and McDONALD J R Intralobar bronchopulmonary sequestration *Am J Roentgenol* 71 731 761 1954

22 SLOAN R D and COOLEY R N Congenital pulmonary arteriovenous aneurysm *Am J Roentgenol* 70 183 210 1953

23 STERN W L and NOFFZIGER H C Brain abscess associated with pulmonary angiomatous malformation *Ann Surg* 138 521 531 1953

24 ISRAEL, H I and GOSFIELD E Fatal hemphysis from pulmonary arteriovenous fistula report of a case in a patient with hereditary hemorrhagic telangiectasia *J A M A* 152 40–41 1953

25 GLENN F HARRISON C S and STEINBERG I Pulmonary arteriovenous fistula occurring in siblings *Ann Surg* 138 886–891 1953

26 STEINBERG I and ROBB G P A visualization study of fibrothorax identification of the cardiovascular structures *Radiology* 33 291 298, 1939

27 ROBB G P and STEINBERG I Visualization of the chambers of the heart the pulmonary circulation and the great blood vessels in man summary of method and results *J A M A* 114 474 480 1940

28 STEINBERG I McCOY H I and DOTTER G T Angiocardiographic findings in pulmonary tuberculosis *Dis of Chest* 19 510–562 1951 Angiocardiography in artificial pneumothorax *Am Rev Tuberc* 62 353 359 1950

29 McCOY H I STEINBERG I and DOTTER G T Angiocardiographic findings in thoracoplasty artificial pneumoperitoneum and phrenicotomy *J Thoracic Surg* 21 149 158, 1951

30 MAUBER P H IVANS J A and STEINBERG I Scleroderma relation of pulmonary changes to esophageal disease *Ann Int Med* 40 92 110, 1954

31 ROBB, G P and STEINBERG, I Visualization of the chambers of the heart and the thoracic blood vessels in pulmonary heart disease a case study *Ann Int Med*, 13 12 45, 1939

32 STEINBERG I and ROBB G P Mediastinal and hilar angiography in pulmonary disease *Am Rev Tuberc*, 33 557-569 1938

33 STEINBERG, I, ROBB, G P and ROCHE, U J The differential diagnosis of mediastinal tumor and aortic aneurysm value of contrast cardiovascular visualization *New York State J Med* 40 1168 1178, 1940

34 STEINBERG, I and DOTTER, C. T The differentiation of mediastinal tumor and aneurysm value of angiocardiography *Brit J Radiol*, 22 567-572, 1948

35 STEINBERG, I, DOTTER, C T and ANDRUS, W D Angiocardiography in thoracic surgery *Surg, Gynec & Obst*, 90 45-59, 1950

36 DUBILIER, W, STEINBERG, I and DOTTER, C T Kyphoscliosis angiocardiographic findings *Radiology*, 61 56-59 1953

37 FINBY, N and STEINBERG, I Roentgen aspects of pleural mesothelioma *Radiology*, in press

38 NACLERIO, E and LANGER, L. Pulmonary cysts special reference to surgical treatment of emphysematous blebs and bullae *Surgery*, 22 516-524, 1947

39 [illegible]

40 [illegible] angiocardiographic findings in one hundred consecutive proved cases *Arch Surg*, 64 10-19, 1952

41 DOTTER C T, STEINBERG, I and HOLMAN C. W. Lung cancer operability angiocardiographic study of fifty three consecutive proved cases of lung cancer *Am J Roentgenol*, 64 222-238, 1950

42 ROBERTS, D J, DOTTER, C T and STEINBERG, I Superior vena cava and innominate veins angiocardiographic study *Am J Roentgenol*, 66 341-352, 1951

17

Reliability of Chest Radiography

J. YERUSHALMY, Berkeley, California

From the Division of Biostatistics, School of Public Health, University of California, Berkeley, California

THE reliability of interpretation of chest roentgenograms is one of the most valuable tools available to the clinician and surgeon in the diagnosis and treatment of pulmonary disease. Much of the progress in medical diagnosis and a great share of the advances in surgery are traceable to the discovery and development of roentgenology.

Radiography fulfills its functions best when it is used as a diagnostic aid, that is, as an instrument for providing valuable evidence of disease which must be integrated with other clinical and laboratory findings. In practice, however, it sometimes happens that the interpretation of a roentgenogram is accepted as definitive and decisive, and is relied upon as a sole guide in diagnosis and treatment. Such a course of action overlooks the limitations and errors inherent in any human activity.

Observer error is known to exist in the perception of objects which are much more tangible than an x-ray shadow. Considerable variation may therefore be expected in radiographic interpretations and in other clinical methods and procedures. Indeed, when put to the test, all are found to exhibit variability of much greater magnitude than had previously been suspected.[1-4] Our knowledge of subjective errors in clinical medicine and in the different diagnostic tests is, however, meager. Because the problem can be more easily studied in radiography, more precise data are available in this than in the other fields of medicine.

One of the benefits which result from the demonstration and quantitative evaluation of observer error in chest radiography is that it provides a stimulus for devising methods to reduce its magnitude. From a long range point of view, these call for fundamental studies relating to film interpretation, the perception and classification of shadows, which ultimately will lead to greater consistency and reliability. More immediate results, however, have already been attained by utilizing present knowledge. Thus it was demonstrated that, at least in case-finding activities, the undesirable effects of false diagnosis can be reduced significantly by the employment of dual reading of all survey roentgenograms. This procedure has been adopted as the method of choice by many forward looking agencies conducting such activities. Whether an extension of dual reading can be useful in clinical radiography and in its application to surgery has not yet been tested objectively, but it can be inferred indirectly from the other studies. It is, however, likely that the studies have had some beneficial effect on clinical radiography because of the stimulus they provide for increased use of consultation and multiple interpretation in the more difficult cases.

GENERAL CONSIDERATIONS

Evaluation studies of diagnostic procedures are of relatively recent origin, and neither methodology nor terminology have been stabilized. It is important, therefore, to define the various terms used, or at least to clarify their meaning sufficiently to avoid gross misunderstanding. Accordingly, the following statements are presented as explanatory notes on the meaning of some of the terms as they will be used in this discussion. These should not be considered as precise definitions.

Diagnosis. The process of identifying a disease by consideration of history, symptoms, physical signs and results of special tests. It is derived by a process of integration and utilization of all pertinent facts in a given case. Diagnosis in this sense was rarely if ever the subject of evaluation studies.

Diagnostic Test. A test, the findings of which are useful as aids in diagnosis, or as a means for distinguishing between individuals

who may possess a certain disease or condition and those who are free from the disease or condition In general it is the diagnostic test which is being evaluated in most studies on "diagnosis"

Validity of a Diagnostic Test The correlation between the findings of a diagnostic test and the presence or absence of the disease or condition in the individuals examined The validity of a diagnostic test cannot be established by the use of the test alone, it must depend on additional examinations, tests and data provided by sources other than the diagnostic test under study

Reliability of a Diagnostic Test The ability of the test to reproduce its findings and to provide consistent results in repeated examinations The reliability of a given test can be studied independently of the results of other tests and other sources of information The determination of the reliability of a diagnostic test is a prerequisite to the evaluation of its validity

The studies on radiography of the chest, which are summarized in this chapter, relate primarily to the reliability of interpretation and not to its validity In other words, interest is focused on the ability of the chest roentgenogram to detect abnormal shadows, rather than on whether a person with an abnormal shadow in his chest x-ray has the specific disease Moreover, since the presence or absence of an abnormal shadow is revealed only by the impression which it makes on the mind of the person reading the film, the problem turns to the reliability of x-ray interpretation and is concerned primarily with the reproducibility of interpretation of chest roentgenograms

As a consequence of the foregoing, the terms "positive" and "negative" have the following meaning Positive persons who have roentgenographic evidence of inflammatory disease Negative persons who do not have roentgenographic evidence of inflammatory disease

For the purpose of these studies it does not matter what the clinical picture of the individual is The latter fact can be established by the employment of several tests, of which the x-ray is only one, although a very important one Our concern is to determine whether the data derived from the roentgenogram are reliable This, of course, is the first requisite in order that its validity can be tested

It may be important to indicate here that two factors contribute to the unreliability of x-ray interpretation, as indeed to that of most diagnostic tests These are false positives and false negatives A test which provides a high proportion of false positives is said to be of poor specificity, while one which misses many positives, and thus yields many false negatives, is said to be of poor sensitivity

The studies on the reliability of interpreta

and classification of pulmonary shadows, (3) evaluation of change—serial roentgenograms, (4) benefits of dual reading

DETECTION OF LESIONS—PRESENCE OR ABSENCE

One of the more important activities in radiology relates to the separation of positives and negatives, that is, the identification of persons who possess roentgenographic evidence of disease, and those who are free from such evidence This activity is performed by the radiologist in his daily practice, as well as in photofluorographic surveys which are conducted on a large scale It is in the latter

x-rays were interpreted independently by five different readers[9] It became apparent that the multiple readings posed significant problems even in the simplest of activities, namely, that of separating the group into positives and negatives Consider, for example, the results obtained from the interpretation by five physicians of the large 14 by 17 inch celluloid roentgenograms as shown in Table 1

This table shows the distribution of 1,256 roentgenograms according to the number of positive readings which were obtained by five readers For example, in 1,125 cases all the readings were negative In twenty-seven cases all the five readings were that of positive, in forty-seven cases there were one positive and four negative readings, etc It is obvious, first, that it is not possible to answer with any degree of conviction the simple question of how many positives there are in the group Should we consider all the 131 individuals who had at least one positive reading, or possibly only the twenty-seven with five positive readings?

Indeed how can we be sure that the 1,125 with five negative readings are negative? Had we subjected the films to another reading it is very likely that some of them would have been called positive In fact a set of one hundred 14 by 17 inch x rays which when selected were thought to contain one third positives was interpreted independently twenty times The more readings that were obtained, the smaller the group became in which all the readings were negative At last count after twenty interpretations only sixteen of the set of 100 roentgenograms were called negative in all twenty readings On the other hand in only seven cases were all the twenty readings in agreement on positive

These simple facts illustrate that observer errors which accompany the interpretation of roentgenograms for the presence or absence of a lesion are of disturbing magnitude The variability is a result of two factors which should be studied separately that of over reading or false positives and under reading or false negatives Estimates of the magnitude of these two factors may be obtained from a study of 1 807 photofluorograms (70 mm) which were interpreted independently ten times.[7] It was possible to establish with reasonable certainty that the set contained thirty roentgenologically positive films that is on these thirty films there was unanimous opinion by seven expert radiologists and phthisiologists that they showed evidence of inflammatory disease requiring clinical study In a similar way it was established that the set contained 1 760 roentgenologically negative films * It was thus possible to determine for each reader how many of the thirty positive films he missed and how many false positive diagnoses he made on the 1 760 negatives

As a result of the ten interpretations of the photofluorograms it was found that on the average a competent and experienced physician misses in a single reading as many as 32 2 per cent of the positive films and provides false positive diagnoses on 1 7 per cent of the negative films These results are not limited to the 70 mm photofluorograms Similar findings were noted for other film sizes including the 14 by 17 inch celluloid roentgenograms

These findings bring into focus one serious practical problem which results from observer error in chest radiography When a photofluorographic survey is being conducted in a community or in a hospital and the films are interpreted by a competent radiologist or a chest specialist approximately one-third of the persons whose photofluorograms contain evidence of inflammatory disease are being told that they are free from disease while over 3 per cent of the negatives are being told that their x rays indicate possible disease The seriousness of the problem for the former is obvious The situation however is not unimportant for the latter group they are being subjected to inconvenience expense and psychologic trauma before they are satisfied that the original positive diagnosis was false

TABLE 1*

DISTRIBUTION OF 14 BY 17 INCH ROENTGENOGRAMS ACCORDING TO NUMBER OF POSITIVE READINGS IN FIVE INDEPENDENT INTERPRETATIONS

Number of Positive Readings	No of Films	Per cent of Films
0	1 125	89 6
1	47	3 7
2	23	1 8
3	17	1 4
4	17	1 4
5	27	2 1
Total	1 256	100 0

* From BRELO C C. et al J A M A 133 359, 1947

Many people have the conviction that from a practical point of view the problem may not be as serious as the foregoing results indicate It is argued that the positive films which are missed may not be the important ones and that all clinically significant lesions are being detected by all competent readers This point has not yet been entirely settled since it is difficult to obtain reliable information on the subsequent follow up of persons whose lesions might not have been detected in a single

* There were in addition seventeen films in which the opinion of the special panel was divided The corresponding photofluorograms were eliminated from the study

ing The results of one study[8] are very suggestive, and indicate that clinically active lesions may be overlooked in a single reading and that the frequency with which false negative diagnoses are given on such lesions is no smaller than that for inactive lesions The study, however, is based on only a small number of active lesions It must be confirmed by more extensive investigations before the results can be accepted

DESCRIPTION AND CLASSIFICATION OF PULMONARY SHADOWS

Much more serious discrepancy than that found in studies on detection of lesions was found in evaluating the reliability of describing and classifying roentgenographic shadows The task, of course, is much more difficult, and the unreliability should have been expected It is surprising, therefore, that until recently practitioners in this field were convinced that they were able to interpret a lesion not only for its probable significance at the moment but also as to its possible prognosis In fact, a large segment of physicians practicing in this field still believe that they can do it

As a result of the demonstration of the magnitude of unreliability in x-ray interpretation, a group of three radiologists—Drs W Edward Chamberlain, R R Newell and Leo Rigler—has undertaken to investigate the reliability of describing and classifying pulmonary lesions These men attempted to develop more reliable methods for accomplishing this task because they realized that any significant, lasting progress and improvement in roentgenographic interpretation is dependent on the development of a reliable method of describing and classifying lesions

The results of their investigations were extremely disappointing They had tested nearly all methods of describing and classifying lesions now in common use They had demonstrated, beyond a doubt, that it is not possible to determine the probable activity of a lesion from a single roentgenogram When one radiologist calls a lesion active, a second, equally competent radiologist is likely to disagree with him in nearly 50 per cent of the cases Nor is the description of a lesion in terms such as "hard," "fibrotic," "exudative," "productive," etc , any more discriminating Disagreements as high as 55 per cent were noted in the words and symbols used by the radiologist in his daily practice of interpreting films

It may be of interest to quote here from a recent paper reporting on the work of this group[9]

"The present writers appear to have failed in this project of finding a reliable classification of the roentgenographic appearance or quality of a tuberculous pulmonary lesion It is believed that reasonable degrees of tenacity and resourcefulness were used in the attempt It was disappointing to find that many conferences and much practice, together and apart, failed to increase reliability and agreement to a useful degree

"Analysis shows that the amount of agreement was statistically significant, i e, that differences in structure of the shadows were really being perceived Nevertheless, the agreement was quantitatively insufficient for the purpose envisaged, namely, validation of a classification by long time clinical studies

"The more subjective judgments of activity (intuitive) appeared to be about as reliable as description and classification of the objective appearance of the lesion on the film

"Success in classification (diagnosis) seems not to be attained by instructing the reader to 'mark it only if you feel sure' To do this results either in an increase in disagreement or merely in an overwhelming reduction in the number of useful diagnoses ventured The percentages of agreement and disagreement depend on how broadly agreement is defined But the more generous one's definition of agreement, the less sharp the classification and the less use it will have for clinical purposes

"In discussing this research with others, radiologists and chest specialists, the writers find a general unwillingness to believe that descriptions of pulmonary lesions are as unreliable as were found in the present study The present writers have become accustomed to this skepticism and believe that only those who have themselves made duplicate readings of a series of films can come to appreciate the hard fact of their own unreliability

"Even yet the conviction survives that the qualitative appearance of a lesion as seen on a chest film must have clinical significance The present investigators believe that further effort should be made to find ways to bring out in optimal degree all of the information that may actually be there"

EVALUATION OF CHANGE—SERIAL ROENTGENOGRAMS

Serial roentgenograms of the chest are utilized in case management for the purpose of assessing the course of disease in a patient with pulmonary disease In the course of study of the patient considerable information becomes available in addition to data provided by the roentgenograms The latter, however, are considered to provide the most reliable estimates of change in extent and character of the lesion The main changes occurring in a pulmonary lesion are usually reflected in changes in its roentgenographic shadows Serial roentgenograms have therefore been accepted with a great degree of confidence as objective tests of the progress of the disease and its activity It is not uncommon that the evaluation of change as perceived by a comparison of serial chest x-ray films is relied upon almost exclusively in case management The findings that the interpretation of serial roentgenograms are also grossly inconsistent were, therefore, even more unexpected than those relating to a single roentgenogram

A comprehensive analysis of the reliability of interpretation of serial roentgenograms was conducted with the cooperation of six competent physicians—three radiologists and three phthisiologists [10] They interpreted 150 pairs of 14 by 17 inch anteroposterior roentgenograms taken on patients with proved tuberculosis at three monthly intervals Each physician classified the 150 pairs in only three groups whether on the basis of a comparison of the first and second film there had been, in his judgment, a "change for the better," a "change for the worse," or that the lesion "remained substantially unchanged"

After a lapse of some time, and without knowledge of the results of the first interpretation the same pairs of roentgenograms were reinterpreted by the same readers in the same manner This provided a total of twelve independent interpretations on each pair Since two readings were made by each physician, it as possible to study the consistency of each reader with himself (intra individual), as well as to compare the interpretations of each with those of the other five physicians (inter-individual) The main findings of this study are shown in Table II

It may be seen that there was a total of 8,931 comparisons between individual readers These are obtained in the following manner For each film pair, four comparisons are available for each pair of readers For example, the first reading of reader A can be compared to the first and second readings of reader B, and the second reading of A can similarly be compared to the two readings of B Since there are fifteen ways of comparing the six readers against each other, a total of sixty comparisons of one-against-another is available for every pair of films For the entire group of 150 film pairs a total of 60 multiplied by 150, or 9 000 comparisons, is available *

TABLE II*

PERCENTAGE OF DISAGREEMENTS BETWEEN READERS (INTER INDIVIDUAL) AND FOR AN INDIVIDUAL READER WITH HIMSELF (INTRA INDIVIDUAL) IN INTERPRETING 150 FILM PAIRS

Comparisons	Inter individual		Intra individual	
	No	Per cent	No	Per cent
Disagreements	2 686	30 1	192	21 5
Agreements	6 245	69 9	701	78 5
Total	8 931	100 0	893	100 0

* From JERUSHALMY, J et al Am Rev Tuberc, 64 225 1951 [10]

These comparisons can be either agreements, that is the two readers classified the pair in the same way, or they are in disagreement In all there were 2 686 comparisons which were in disagreement These represent 30.1 per cent of all the comparisons between readers (inter-individual) A similar method showed that there were 192 cases in which a reader disagreed with himself These represent 21 5 per cent of all comparisons of a reader with himself (intra individual) It can therefore be stated that *in judging a pair of x ray films for evidence of progression, regression or stability of disease, two competent and experienced physicians are likely to disagree with each other in nearly one-third of the cases, and a single reader is likely to disagree with himself in about one fifth of the film pairs*

* There were not exactly 9 000 comparisons because occasionally a reader designated a film pair as of non diagnostic quality These comparisons were left out The total number of usable comparisons was 8 931

While the majority of disagreements were of a single degree, that is, where one reader called the pair "no change," while the other called it either "better" or "worse," instances of complete reversal from better to worse were not uncommon In fact, as a result of this study it may be stated that when a reader compares a pair of roentgenograms and decides, on the basis of the comparison, that the lesion is getting better or worse, the chances are that in approximately 10 per cent of the cases another equally competent reader will use the opposite classification to describe the same pair, and the same reader is likely to reverse his original diagnosis completely in approximately 7 per cent of the readings of the same set of film pairs

This demonstrated unreliability of interpretation of serial roentgenograms is, in many respects, more serious than the unreliability of interpreting single roentgenograms because of its wide use in the practice of chest diseases Many an important clinical decision affecting the patient often rests on the interpretation of change as seen on two films taken at two periods of time The revelation of the insecure founda- [illegible] which it sometimes rests serves to [illegible] of

out many observations, [illegible]
comparison of serial roentgenograms of the chest

BENEFITS OF DUAL READING

The demonstration of unreliability of interpretation of single roentgenograms, and of serial chest x rays, has stimulated investigations on the development of methods for reducing the undesirable effects of false diagnosis One obvious method is that of submitting all roentgenograms to more than one interpretation The tests have been confined primarily to the evaluation of dual reading of single roentgenograms in mass radiography To a more limited extent, the method of dual reading has been investigated for serial x rays and its application in clinical practice It may be well to present the results separately

Dual Reading of Single Photofluorograms The procedure of dual reading in mass radiography involves the following steps The set of photofluorograms is first interpreted by one reader who selects all the films which in his judgment show evidence of inflammatory disease requiring further clinical study Later the same set is reinterpreted in the same way by the same or another reader, *without knowledge of the results of the first reading* This procedure may be expected to reduce the number of false negatives, that is, the number of cases with radiographic evidence of disease which are interpreted as negative The reason for this is that the missing of a positive lesion often is the result of an accidental oversight on the part of the reader It may therefore be expected that the probability that the same lesion will be missed on two independent occasions will be greatly reduced

However, the method of dual reading has also an undesirable feature It increases the proportion of false positives, that is cases in which negative photofluorograms are called positive The importance of this feature cannot be minimized since it is a source of great inconvenience to the patient Methods have therefore been sought which attempt to retain the benefits of dual reading without incurring its disadvantages

The study of dual reading is based on the survey of 1,807 individuals, mentioned previously, in which there were thirty roentgenologically positive and 1,760 roentgenologically negative cases [7] They were interpreted ten times by experienced and competent physicians A measure of the unreliability of interpretation may be judged from the fact that none of the readers selected all the thirty positives At most, a single reader detected twenty-two of the thirty, and it was as low as seventeen of the thirty for one reader Similarly, the number of false positives varied with the readers from fifteen to forty six On the average, a reader selected 20 3 of the thirty positive films and missed nearly one-third of them, he gave false positive diagnoses for 29 7 of the 1,760 negative films

The addition of a second reading detected on the average 3 3, or approximately one-third of the 9 7 positive photofluorograms missed by the original reader However, the second reading added 27 8 additional false positives Photofluorograms which were interpreted as positive in two independent readings had a high probability of being truly roentgenologically positive This happened on the average in nineteen cases and 17 1 of these proved to be truly positive

On the basis of this study it may be stated that if a set of photofluorograms is submitted

to dual readings a large number will be called negative on both readings and a small number will be called positive on the two independent interpretations These films will have a high degree of reliability, and disposition of these cases can be accomplished with a great degree of confidence The cases in which the two readings are in disagreement call for special treatment in order to reduce the disadvantages of false positives

In the study referred to these cases were submitted to a third interpretation by another reader and by a panel of readers It was found that by accepting the verdict of this third interpretation as a basis for action it is possible to retain much of the benefit of dual reading and at the same time to eliminate many of the additional false positives which result from dual reading The results of this study are shown in Table III which presents the benefits and disadvantages of the various methods of dual reading The figures have been extrapolated to represent a survey in which there are 100 positives among approximately 6,000 photofluorograms

It may be seen that a single reader detects sixty eight of the 100 truly positives and misses thirty two He bothers unnecessarily, ninety nine individuals that is he gives false positive diagnoses on 1 7 per cent of the truly negatives When the films are submitted to dual reading seventy nine of the 100 positive films will be detected in one or the other of the readings However the number of false positives will increase to 192 or nearly twice as many as in a single interpretation The two readings will *both* be positive in sixty three instances fifty seven of which will represent truly positives The table also shows what may be expected when the cases of disagreement are subjected to another interpretation either by a panel of three or by a single reader

It may be seen that either of the methods is effective The method of choice seems to be

TABLE III*

COMPARISON OF SINGLE READING WITH DIFFERENT METHODS OF DUAL READING†

Method of Reading		Survey of 5 967 Persons Containing			
		100 Truly Positives		5 867 T Negatu	
		No of Truly Positives Detected	No of Truly Positives Missed	Falsely Diag As Pos tr	
				No	Per c (c/5 f × 1c
		a	b	c	d
Single reader		68	32	99	1 7
Two readers (one or the other)		79	21	192	3 3
Two readers (both agreed)		57	43	6	0 1
Panel of three two readers in agreement plus review of disagreements when the decision of the panel was	Positive by unanimous opinion	75	25	72	1 2
	Positive by at least one reader	78	22	107	1 8
Panel of one two readers in agreement plus review of disagreements by a single reviewer	Average of five performers	74	26	83	1 4
	Average of two best performers	78	22	99	1 7

* From YERUSHALMY J et al *Am Rev Tuberc* 61 443 1950 1

† Number of truly positives detected and number of truly negatives diagnosed falsely as positive in a *hypothetic* 70-ml survey of a group of 5 967 persons This is an extrapolation from a real group of 1 790 persons presenting 30 truly positive films to a group sufficiently large to present an even 100 truly positives (exclusive of questionable films)

that which utilizes a single reader for reviewing all films in which the two readings are in dis [illegible]

with contradictory diagnoses are reviewed by a competent reader (with knowledge of the results of the previous readings) Only those which are considered positive on this third interpretation are referred for further clinical study Such a procedure detects 30 per cent of the truly positives missed by a single reader [illegible]

roentgenograms[11] was made on the same material utilized in the study on serial roentgenograms previously mentioned[10] This, it will be recalled, consisted of 150 film pairs taken on patients with proved tuberculosis at three monthly intervals

For the purposes of evaluating the benefits and disadvantages of dual reading it was necessary to determine for each film pair the probable true situation with regard to change This was accomplished by submitting the film [illegible]

which it was possible to obtain a unanimous [illegible]

on the remaining 142 film pairs As a result of group discussion these 142 pairs were placed in the following groups sixty three as representing roentgenologic evidence for better, fifty nine for no change and twenty for worse

With this information about the probable true status of each pair it is possible to investigate the relative merits of single and dual reading in serial roentgenograms It should be noted that such percentages of false diagnoses as were found represent understatements, since the eight pairs which were left out of the study are the most difficult Even in this somewhat easier set of 142 film pairs a single reader was found to be correct in his interpretations 80 8 per cent of the time and to give a wrong diagnosis approximately one of five times

When serial roentgenograms are interpreted by two readers they may be considered as falling in two main groups one in which the two readings are identical and the other in which the two interpretations conflict The major findings of the study are that in the first group the correct diagnoses are attained 94 2 per cent of the time In other words, *when two readers place a film pair in the same category, there is a very high probability that that category is the true one*

For films in the second group, no definite action with regard to the film pair is possible since the interpretations are conflicting These represent 29 7 per cent of film pairs These may be submitted to a third interpretation or it may be more desirable to consider them as *roentgenologically undetermined*

The results of the study may be restated as follows The major advantage of dual reading of serial roentgenograms is that it identifies approximately two-thirds of the pairs for which the diagnosis can be given with a great degree of confidence These represent the two-thirds of the film pairs which will have identical diagnoses in the two interpretations

The procedure of dual reading also identifies the remaining one third as the problem pairs that is those with conflicting diagnoses It is of course, possible to proceed in this case as in the case of dual reading of single roentgenograms and submit these to a third interpretation There is one slight difference in that the third interpretation does not always agree with one of the previous two—it may produce the third diagnosis When the third interpretation agrees with a previous one, that diagnosis will be the correct one in two-thirds and incorrect in about one-fifth of these questionable cases In the remaining there will be no workable diagnosis since all three interpretations will be given in the three readings

COMMENT

It is apparent from the foregoing that the interpretation of a chest roentgenogram is not as reliable as desired for the more exacting tasks of diagnosis and treatment Although these studies have been conducted mainly on material relating to mass radiography, it is very likely that in clinical radiology the problem of observer error may also be serious In fact the study on serial roentgenograms came very close to simulating practical day to-day activities in clinical radiology and phthisiology The results of that study suggest that prob-

lems of similar magnitude may be expected in other phases of clinical radiology It is therefore important to consider methods for reducing as much as possible the probabilities of false diagnosis in clinical practice

The problem would not have been so acute if it were possible to determine beforehand which roentgenograms present difficult diagnostic problems If it were possible to separate the easy from the difficult cases then at least on the former diagnosis could be given with confidence It has been shown however that it is not possible to identify which roentgenograms are easy and which are difficult of diagnosis a reader was unable to agree with other readers or with himself as to which of the pairs of films were difficult In fact it often happens that disagreement is greater on films thought to be easy of diagnosis than on those which were initially considered to be difficult

It is this inability to determine *a priori* which of the roentgenograms present difficult diagnostic problems which is so disturbing because the insecurity and doubt must now relate to *all roentgenograms* The radiologist or chest specialist who expresses an opinion on any *roentgenogram* must be prepared to be contradicted by his colleagues a significant proportion of the time

It is in this area of separating the easy from the difficult roentgenograms that the procedure of dual reading may be expected to make the greatest contribution in clinical radiography When the roentgenograms are interpreted independently by two different readers they are separated immediately into two groups (1) those in which the two interpretations are identical and (2) those with conflicting diagnoses For the first group the agreed upon diagnosis can be given with great confidence The probability that the roentgenologic diagnosis is wrong on this group is very slight The procedure thus salvages a relatively large proportion of roentgenograms from uncertain and doubtful diagnosis and action

The procedure also identifies the second group as those difficult of diagnosis With respect to these the best action probably is to leave them for the moment as *roentgenologically indeterminate* that is to admit that on the evidence available roentgenography can contribute little to the diagnosis of these cases This seems to be a small price to pay for the greater assurance and confidence in the roentgenographic diagnosis of the much larger group of roentgenograms.

It may be important to indicate that an essential feature of dual reading is that the two interpretations be accomplished *independently* without knowledge of the results of the other interpretation Group consultation never attains the required degree of objectivity

SUMMARY

Observer error in chest radiography is of such magnitude as to create special problems in diagnosis and treatment. A review of recent studies on the subject reveals the following

1 In interpreting a set of photofluorograms for presence or absence of a lesion a competent and experienced physician misses in a single reading as many as 32 2 per cent of the positive films and provides false positive diagnosis on 1 7 per cent of the negative films

2 Classification of pulmonary lesions on the basis of roentgenographic appearance is not very reliable It is not possible to determine reliably the probable activity of a lesion from a single roentgenogram

3 In judging a pair of serial roentgenograms for evidence of progression regression or stability of disease two competent and experienced physicians are likely to disagree with each other in nearly one-third of the cases and a single reader is likely to disagree with himself in about one-fifth of the pairs

4 The undesired effects of false diagnosis may be reduced considerably by the application of dual reading In mass radiographic projects this procedure detects one-third of the lesions missed by a single reader

5 It is suggested that dual reading may be useful in clinical radiology The main contribution results from the fact that the procedure identifies about two-thirds of the roentgenograms for which the diagnosis can be given with confidence The remaining may be considered as *roentgenologically indeterminate* until further evidence is obtained

REFERENCES

1 BELK W P and SUNDERMAN F W A survey of the accuracy of chemical analysis in clinical laboratories *Am J Clin Path* 17 853 861 1947

2 BARWIN H Pseudodiaphragmatic *New England J Med* 232 691-697 1945

3 PERLOFF H H and SCHNEEBERG N G The problem of thyroid carcinoma *Surgery* 29 4 1951

4 COCHRANE, A L, CHAPMAN, P J and OLDHAM, P D Observers' errors in taking medical his-

5

6

parison of the effectiveness of various roentgenographic and photofluorographic methods *J A M A*, 133 359 1947

7 YERUSHALMY, J, HARKNESS J T, COPE, J H and KENNEDY, B R The role of dual reading in mass radiography *Am Rev Tuberc*, 61 443 1950

8 ZWERLING, H H, MILLER, E R, HARKNESS J T and YERUSHALMY, J The clinical importance of lesions undetected in a mass radiographic survey of the chest *Am Rev Tuberc* 64 249 1951

of serial chest roentgenograms in estimating the progress of disease in patients with pulmonary tuberculosis *Am Rev Tuberc*, 64 225, 1951

11 YERUSHALMY, J The reliability of chest roentgenography and its clinical implications *Dis of Chest*, 24 133 1953

18

Clinical Differentiation between Pulmonary and Cardiac Disease

SIMON DACK, M.D., New York, New York

djunct Physician for Cardiology The Mount Sinai ospital, New York, New York

THE unique position of the pulmonary circulation between the right and left sides of the heart leads commonly to involvement of the lungs when there is disturbed cardiac function and to cardiac failure when there is chronic pulmonary disease. This creates a problem in differential diagnosis, and indeed it may often be difficult to assess which is the primary disturbance when heart and lung disease co-exist as they frequently do. Furthermore, the development of cardiac disease in a patient with pulmonary disease will aggravate the pre-existing pulmonary insufficiency and, similarly, the development of pulmonary disease will aggravate pre-existing cardiac or coronary insufficiency.

A wide variety of symptoms and signs are common to both cardiac and pulmonary disease. The symptoms include dyspnea, orthopnea, cough, chest pain, hemoptysis and diminished exercise tolerance. The physical and other clinical signs include fever, wheezing respirations, tachycardia or pulmonary rales, pleural effusion, cyanosis, clubbing of the digits, tachycardia and signs of right heart strain and failure.

CLASSIFICATION OF CARDIOPULMONARY DISEASES

For the purpose of simplicity and clarity in differential diagnosis the patients with cardiac disease may be divided into two broad groups (1) congestive heart failure due to left ventricular failure from any cause, (2) mitral stenosis with or without signs of congestive heart failure.

The patients with pulmonary disease and insufficiency may be divided into five broad groups (1) restriction of the pulmonary vascular bed, due to such diseases as silicosis, pulmonary fibrosis from any cause. Of course in this group there is often an element also of obstructive emphysema. (2) Bronchospastic disorders leading to alveolar hypoventilation. This group includes acute and chronic bronchial asthma and obstructive emphysema. In this group, too, there are mixed factors responsible for the pulmonary and cardiac insufficiency, since there is usually some fixed vascular resistance and restriction of the pulmonary vascular bed. (3) Alveolar capillary block with impaired diffusion of gases across the alveolar-capillary membrane. This may occur in diffuse pulmonary fibrosis, sarcoidosis, berylliosis, miliary tuberculosis, lymphangitic carcinoma, scleroderma and Rich-Hamman's disease. (4) Acute inflammatory lesions and infections of the lung such as pneumonia, lung abscess and bronchiolitis. (5) Pulmonary embolism and infarction.

These various groups of cardiac and pulmonary diseases may be analyzed and compared from the standpoint of (1) symptoms and signs and (2) clinical laboratory tests.

CLINICAL SYMPTOMS AND SIGNS

Etiology and Pertinent Clinical Background

In patients with cardiac insufficiency one can generally obtain a history and detect the clinical signs of hypertensive, arteriosclerotic or rheumatic heart disease. In such a patient the occurrence of respiratory difficulty is generally produced by left ventricular failure and pulmonary congestion but an associated lung disease must be excluded. It must be borne in mind that in patients with mitral stenosis particularly, the respiratory difficulty may be produced by a functional or organic alveolar-capillary block and an erroneous diagnosis of pulmonary disease will be made

unless the classical murmurs and other physical and x-ray signs of mitral stenosis are recognized

In pulmonary disease with vascular restriction there is often a history of industrial exposure (silicosis) or other associated findings may [illegible]
and [illegible]
pulm
signs of pure right heart failure

In the bronchospastic diseases there are two principal syndromes The first is the classical extrinsic allergic asthma, often starting early in life, and frequently associated with other allergic manifestations The second is pulmonary emphysema which generally starts in the middle years of life with episodes of wheezing with no detectable allergen (intrinsic asthma) Chronic infection supervenes, leading to the clinical picture of "asthmatic bronchitis," with ultimate pulmonary emphysema This is the natural history of so-called "idiopathic obstructive pulmonary emphysema" In either case, the end result ultimately leads to cor pulmonale

The *alveolar capillary block group is characterized* by an insidious onset and progression of dyspnea and marked tachypnea There may be a history of industrial exposure (beryllosis, asbestosis) Skin lesions are always noted if the lung involvement is due to scleroderma and in lymphangitic carcinoma a primary focus elsewhere may be evident Fever is a dominant clinical feature of miliary tuberculosis

In the acute inflammatory group there are usually clinical signs of acute infection, such as fever or leukocytosis However, it must be borne in mind that in older patients fever may not occur or may be mild In such patients with chronic bronchitis and emphysema the clinical signs of pneumonitis may simulate those of acute pulmonary edema

Pulmonary embolism and infarction should be suspected in any patient who develops acute respiratory symptoms following a surgical procedure or in association with signs of peripheral venous thrombophlebitis or thrombosis

Dyspnea Dyspnea at rest and on exertion is the predominant symptom of both cardiac and pulmonary insufficiency It may be impossible to differentiate the two conditions by the character or severity of the breathing difficulty However, several differentiating *features may be observed*

Dyspnea due to pulmonary congestion and edema is often paroxysmal, predominantly nocturnal and worse in the supine position Although this may be true also of bronchial asthma, the latter diagnosis should be considered when wheezing respirations are the prominent features of the respiratory distress On the other hand, wheezing may also occur in pulmonary congestion due to mitral stenosis With the exception of acute pulmonary edema the increased effort of the dyspneic patient with cardiac disease is exerted during inspiration rather than expiration

The restricted pulmonary vascular bed group (Group A) is characterized by dyspnea and tachypnea with marked decrease in exercise tolerance This may be clinically indistinguishable from congestive failure due to cardiac disease In the bronchospastic or emphysema group, however, there may be several distinguishing features The patient usually exhibits an emphysematous or barrel chest although this may occasionally be absent The chest is hyperresonant and the breath sounds diminished There are marked wheezes and rhonchi and the expiratory phase is generally labored and prolonged It should be borne in mind, however, that although paroxysmal nocturnal dyspnea is not as common as in heart disease it may occur in emphysema Also, the patient may be more comfortable in the orthopneic position just as the patient with congestive failure

In acute allergic bronchial asthma the attacks of dyspnea and wheezing are more common in the summer than winter, are unrelated to exertion and are separated by free periods during which the patient is asymptomatic

The alveolar capillary block group is characterized by increasing severity of tachypnea and hyperventilation at rest which becomes tremendously aggravated during mild exercise In contrast to the heart failure and emphysematous patients, the patients in this group are as comfortable lying flat as sitting erect and the dyspnea is not significantly relieved in the orthopneic position

[illegible] Since most [illegible] low [illegible] d feet in congestive heart failure is generally cool pale and moist Dependent edema is absent unless there is associated right heart failure Digital clubbing is absent except in cases of congenital heart disease with right to left shunt and cyanosis These observations apply also to

pulmonary disease with restricted vascular bed in which low output failure occurs

In the emphysema group however cor pulmonale is generally associated with high output failure and the skin and extremities are usually warm in contrast to the heart disease group Clubbing may occur in any type of pulmonary disease particularly those with chronic anoxemia It is also commonly seen in bronchiectasis carcinoma and lung abscess even in the absence of anoxemia

Cyanosis Cyanosis is a rough clinical indication of the degree of arterial and capillary blood oxygen unsaturation Cyanosis is not a striking feature of congestive heart failure unless there is a complicating pulmonary factor such as pulmonary edema infarction or pneumonia which results in impaired distribution of gases into the alveoli and impaired diffusion of gases through the alveolar-capillary wall Cyanosis may also appear if left ventricular failure is associated with marked reduction of cardiac output e g shock with slowing of the peripheral circulation and increase in oxygen extraction Similarly in severe heart failure there may be cyanosis due to increased extraction of oxygen from the capillary blood resulting in markedly unsaturated blood in the subcapillary venous plexus

In mitral stenosis without heart failure cyanosis is uncommon However the organic vascular changes in the alveoli may result in impaired diffusion and disturbed gaseous exchange similar to that seen in the alveolar-capillary block group When there is marked reduction in cardiac output in mitral stenosis at rest or after exercise cyanosis may appear due to increased oxygen extraction as described previously in the case of low output failure

Of course the most marked degree of cyanosis in heart disease is seen in congenital lesions with right to left shunt such as tetralogy of Fallot

In bronchospastic pulmonary disease and emphysema cyanosis is common but generally only in the advanced cases usually in those followed by cor pulmonale and right heart failure Complicating pulmonary infection may increase the severity of the cyanosis It is of importance to remember that cyanosis may be only slight early in the disease but even at this time there will be a significant reduction in arterial oxygen saturation and increase in cyanosis during exercise

In the alveolar capillary block group cyanosis may be absent in early cases but progresses insidiously and is usually easily recognizable when the disease is diagnosed It is present at rest and becomes markedly accentuated on mild exercise

Cyanosis is common of course in acute inflammatory conditions of the lung such as severe pneumonia and bronchiolitis in massive pulmonary embolism and in A V fistulas of the lung

Hemoptysis In left ventricular failure and pulmonary edema there is generally no frank hemoptysis but the sputum is usually pinkish and frothy If the sputum is frankly bloody, one must rule out pulmonary infarction or mitral stenosis In the latter condition the bloody expectoration is usually small or moderate in amount and is generally intermittent Much less commonly the pulmonary hemorrhage may be massive in mitral stenosis It may occur without any evidence of acute pulmonary edema since it is generally caused by rupture and bleeding from dilated and congested peribronchial veins

In pulmonary disease frank hemoptysis is generally absent in the cases of restricted vascular bed and alveolar-capillary block It is also absent in the emphysema group except following a severe coughing spell which may produce bleeding from the upper respiratory tract Of course it may occur in acute pneumonias and is a characteristic sign of pulmonary infarction

Pleural Effusion Left ventricular failure may be accompanied by pleural effusion when there is associated right heart failure It is usually bilateral and when it is unilateral it is generally right sided A unilateral left sided pleural effusion is due to underlying lung or pleural disease more often than to cardiac failure so much so that search for such conditions should be carried out even when known heart disease is present Cardiac failure may also result in an interlobar effusion which may be isolated to one fissure and simulate intrapulmonary infiltration or tumor Such a phantom or vanishing tumor will disappear following treatment for congestive heart failure

Pleural effusion is rare in chronic pulmonary disease It may occur in acute pneumonia due to associated acute pleurisy It is common course in pulmonary embolism with [illegible] in which it is often [illegible]

involves the costophrenic sinuses The fluid may be bloody in appearance but more often than not it is clear and non sanguineous (as in heart failure), resulting from a secondary pleural reaction to the underlying infarction

CLINICAL LABORATORY TESTS

Venous Pressure and Circulation Times The venous pressure is elevated in congestive heart failure when there is right sided failure from any cause but may be normal in pure left heart failure and pulmonary edema The arm to lung circulation time is usually prolonged the prolongation depending upon the degree of pulmonary venous congestion and slowing However in the occasional cases of high output failure (A V fistula hyperthyroidism, beriberi etc) in which the circulation time is shortened, it may appear normal even after heart failure supervenes The venous pressure will be elevated in such cases

In pulmonary disease with restriction of the vascular bed the venous pressure and circulation time remain normal and increase only in the advanced stage when cor pulmonale develops In the bronchospastic disorders the circulation time generally remains normal or becomes shortened owing to increased [illegible] output associated [illegible] cor pulmonale [illegible] the circulation [illegible] remain within the range of normal or become only slightly prolonged The venous pressure, however, rises with the advent of cor pulmonale It may even be slightly elevated in the absence of frank signs of heart failure This combination of elevated venous pressure and rapid, normal or only slightly prolonged circulation time is the characteristic finding in patients with dyspnea due to pulmonary emphysema rather than cardiac failure except when the failure is of the high output type

It is apparent that the circulation time may help to differentiate the high output type of heart failure of emphysema, in which it is rapid from the low output failure of the restricted vascular bed group, such as silicosis, and from ordinary left ventricular failure in which it is moderately to markedly prolonged

X ray Examination The x ray examination of the chest is one of the most useful and practical aids in differentiating heart and lung disease The scope and length of this chapter do not permit a detailed description of the x ray appearance of the heart and lungs in the various diseases under discussion However it can be stated that, in general the teleoroentgenogram in congestive heart failure due to the common types of heart disease will demonstrate enlargement of the heart It is very unusual to observe normal heart size and configuration in patients with symptoms suggesting the presence of heart failure The heart chambers involved in the enlargement and the cardiac configuration will depend on the nature of the underlying heart disease and the severity and stage of the heart failure In mitral stenosis for example, the characteristic left atrial enlargement will be seen In hypertensive and coronary heart disease and in aortic valve disease there will be variable degrees of left ventricular enlargement The latter is unusual in pulmonary disease, except when it is accompanied by arteriosclerotic or hypertensive heart disease

In pulmonary disease the heart size will be normal except in the advanced stages with cor pulmonale, when the right [illegible] nary artery [illegible] diseases of [illegible] alveolar capil [illegible] diffuse mottling typical of the various infiltrative pulmonary lesions may be seen, diffusely distributed in both lungs In the emphysema group the characteristic findings are a small elongated vertical heart silhouette depressed diaphragm widened intercostal spaces increased anteroposterior diameter and hyperillumination of the lungs

In pneumonia and pulmonary infarct [illegible] typical lung [illegible] conditions [illegible] shadows a [illegible] lateral pleural effusion should make one suspect the presence of pulmonary infarction

Serial x ray examination of the chest is also of value for the confirmation of the diagnosis of pulmonary congestion due to cardiac failure The disappearance of the abnormal pulmonary findings following treatment for heart failure generally points to vascular congestion rather than intrinsic pulmonary disease This applies as well to the vanishing or phantom tumor which represents an interlobar pleural effusion which disappears following heart failure treatment

The Electrocardiogram The scope of this discussion also precludes a detailed discussion of the electrocardiographic differences in the

various types of heart and lung disease. It is evident that in the heart failure group there may be several basic types of electrocardiographic abnormality depending upon the nature of the underlying heart disease Thus, the electrocardiogram may indicate the presence of left ventricular strain or hypertrophy, myocardial damage, myocardial ischemia or infarction, etc Such changes are not generally seen in pulmonary disease unless there is coincidental cardiac disease

In the pulmonary disease group as a whole, the electrocardiogram usually remains normal except in the late stages of cor pulmonale, which is associated with signs of right ventricular hypertrophy and strain and occasionally right bundle branch block This should make one suspect the presence of pulmonary heart disease, provided one has excluded valvular disease or a congenital lesion associated with right ventricular hypertrophy

The electrocardiogram may be exceedingly valuable in the differential diagnosis of pulmonary infarction and posterior myocardial infarction Signs of acute right ventricular strain should make one suspect pulmonary infarction These include prominent S-waves in leads 1, aVL and left sided precordial leads, prominent R-waves in aVR and V-1 and inverted T waves in leads 3 and V-1 to V-3 In addition the T-waves may have the typical peaked and "staircase" appearance Unfortunately, this classical pattern of acute cor pulmonale appears only in up to 30 per cent of cases, whereas in the other cases the electrocardiogram shows merely non-specific changes involving the ST and T-waves It must also be pointed out that this classical pattern of acute cor pulmonale has been observed occasionally in acute right heart failure secondary to other types of pulmonary disease, such as pneumonia in a patient with chronic emphysema

Another electrocardiographic finding which is receiving increasing attention and may be helpful in differential diagnosis is the so-called "pulmonary P-wave (P pulmonale) Since right ventricular hypertrophy secondary to lung disease is often associated with right atrial dilatation and hypertrophy, the P-waves often become altered and assume a characteristic configuration, which is quite different from that seen in other types of heart disease

The pulmonary P-wave is characteristically tall, peaked P-wave, generally found in leads 2, 3, aVF and the right sided precordial leads The altered P-wave is due to right atrial hypertrophy, which results in downward and anterior deviation of the vector forces produced by atrial excitation This contrasts with the so-called P mitrale in mitral stenosis which is associated with left atrial hypertrophy In mitral stenosis and other forms of heart disease associated with left atrial dilatation the P-wave is usually broad, widened, notched and often bifid, due to delayed activation of the enlarged left atrium Furthermore, the largest P-waves are generally found in leads 1, aVL and the left-sided precordial leads, because the atrial vector forces are deviated to the left.

Although overlapping and exceptions are not infrequent, the presence of a pulmonary P-wave should make one suspect the presence of right atrial dilatation or hypertrophy The most frequent cause will be found to be chronic pulmonary disease, but a congenital heart lesion or tricuspid valve involvement must be excluded

Blood Hemoglobin and Hematocrit In heart disease and congestive heart failure the blood hemoglobin and hematocrit remain normal except in congenital heart disease with right to left shunt and polycythemia due to arterial oxygen unsaturation Variable degrees of anemia may develop if there is complicating infection or hemodilution with increased plasma volume On the other hand, if shock is associated with the heart failure, hemoconcentration may lead to increased hemoglobin and hematocrit

These tests are normal in the pulmonary diseases of ventricular failure unless there is complicating emphysema In the emphysema group there is polycythemia with increased hemoglobin content and hematocrit, due to hypoxia The hematocrit may be a more sensitive index of the degree of polycythemia than the hemoglobin level, since complicating bronchopulmonary infection may result in lowering of the hemoglobin level and a masking of the degree of polycythemia The hematocrit in such patients will remain increased In the alveolar-capillary block group there may also be a progressive increase in hemoglobin and hematocrit as the disease and associated hypoxia progress

Arterial Oxygen Saturation Significant unsaturation of the arterial blood oxygen at rest rarely occurs in congestive heart failure except when there is associated pulmonary edema, in-

farction or infection which result in impaired alveolar gaseous exchange However, the arterial oxygen tension may be significantly reduced long before the oxygen content is affected This may occur in mitral stenosis in the absence of heart failure because there may be impaired alveolar diffusion in the mitral lung secondary to vascular changes in the alveolar wall A small degree of anoxemia will not be detected by the measurement of arterial oxygen saturation alone, the arterial oxygen tension must be measured also

In the bronchospastic disorders and emphysema however, arterial oxygen unsaturation is common particularly in the advanced stages and when cor pulmonale develops The unsaturation becomes very marked after exercise Similarly in the alveolar capillary block group arterial oxygen unsaturation develops early and becomes very marked during exercise

Cyanosis may not be a true index of the degree of arterial oxygen unsaturation since it may occur in congestive failure even when the arterial oxygen content is normal As was stated previously, cyanosis in heart failure may be produced by peripheral factors Thus reduced venous oxygen saturation may result from slowing of the peripheral blood flow, increased extraction of oxygen in the tissues and, therefore, increased oxygen unsaturation in the peripheral capillary and venous bed

Arterial and Venous CO_2 Content In gen [illegible]

failure mitral stenosis and the alveolar capillary *block group of pulmonary diseases In* the pulmonary emphysema group on the other hand the alveolar hypoventilation leads not only to arterial oxygen unsaturation but also to elevation of arterial CO_2 tension and content

While the determination of the venous CO_2 content is not as valuable as the arterial blood CO tension as a reflection of blood gas exchange and CO elimination nonetheless as a practical measure the venous CO_2 values may [illegible]

such as the administration of alkaline medication (sodium bicarbonate) recurrent vomiting repeated mercurial diuresis causing hypochloremic alkalosis or primary aldosteronism, a marked elevation of venous CO_2 content may be a rough clinical indicator of the presence of *respiratory acidosis in patients with pulmonary* emphysema and cor pulmonale This contrasts with a normal or slightly reduced CO_2 content *(respiratory alkalosis) seen in congestive heart* failure and pulmonary disease with alveolar capillary block

Lung Function Studies Lung volumes The vital capacity in heart disease is reduced relative to the degree of heart failure and pulmonary congestion The *various components of* the total capacity and the vital capacity are reduced symmetrically As the heart failure increases there *may be a slight relative increase* in residual volume The decreased lung volumes are due to increased blood volume in the lungs with reduced distensibility, increased heart size in general and of the left atrium in particular (mitral stenosis), and further pulmonary compression by pleural effusion or ascites if present

In the pulmonary diseases associated with restricted vascular bed and alveolar-capillary block there is observed a uniform reduction in all lung volumes with a normal residual volume to total capacity ratio However, in the presence of emphysema the vital capacity is reduced, the total capacity is normal or increased but the residual volume is distinctly increased resulting in an increased residual volume to total capacity ratio

The maximum breathing capacity, which measures the bellows function of the lungs is impaired in heart failure but a significant reduction is observed only as pulmonary congestion increases This is in marked contrast *to pulmonary disease with emphysema* in which a marked reduction of the maximum breathing capacity is one of the *physiologic* hallmarks of the disease In heart failure there is absence of significant airway obstruction or increased air and tissue viscance, *whereas* a marked increase in total resistance of the tracheobronchial tree with trapping of a r in *the spirogram characteristically* occurs in bronchospastic disorders with emphysema or asthma The reduced maximum breathing capacity in heart failure is due in part to the muscular fatigue associated with low cardiac output This together with the hyperventilation which is common in heart failure results in slight to moderate reduction in *breathing* reserve In pulmonary disease without emphysema there is no airway obstruction and the

maximum breathing capacity is normal or slightly reduced

Pulmonary compliance and resistance Pulmonary resistance (air turbulence and viscance) is increased in heart failure, the increase being more marked as congestive failure progresses This may occur even when conventional ventilatory studies remain normal Pulmonary compliance (a measure of the 'stretchability of the lung) is definitely reduced in cardiac patients in whom mitral stenosis is the predominant lesion because of the congestive and anatomic changes which occur in the lung The reduction becomes much greater when heart failure ensues The reduced compliance is associated with increased rigidity and stiffness of the lung and this becomes especially apparent during exercise

In pulmonary disease with capillary bed restriction the pulmonary compliance would be expected to be reduced if there is associated fibrosis of the lung but airway resistance is not significantly increased Similarly the alveolar capillary block group is associated with increased rigidity of the lung producing marked reduction in pulmonary compliance in the absence of significant increase in airway resistance In contrast to this emphysema is associated with a marked increase in airway and pulmonary resistance with only a moderate reduction in compliance

It is apparent from a perusal of the previously mentioned lung function studies that aside from the simple spirometric measurements (vital capacity and maximum breathing capacity) most of the other indices are not available to the majority of practitioners unless there is access to a cardiopulmonary laboratory They have been discussed however not so much for the sake of academic completeness but to provide a better understanding of some of the underlying changes in cardiopulmonary physiology produced by heart and lung disease

For the practicing physician the maximum breathing capacity in the absence of severe debilitation will be exceedingly useful in establishing the presence or absence of ventilatory insufficiency due to bronchospastic disorders emphysema or fibrothorax As opposed to the marked reduction in maximum breathing capacity in cor pulmonale due to these conditions, there is only a moderate reduction in patients with congestive heart failure or alveolar capillary block

CONCLUSION

It is quite apparent from the entire discussion presented in this chapter that a thorough knowledge of the clinical manifestations and physiologic changes in cardiac and pulmonary lesions is essential for their clinical differentiation Indeed the very differences in the various types of pulmonary disease, e g, emphysema as opposed to alveolar capillary block have tremendously different physiologic, clinical, therapeutic and prognostic implications Since there is a great deal of overlapping of symptoms and findings in lung and heart disease, as evidenced by the necessity of such a chapter as many as possible of the individual diagnostic criteria should be used to arrive at the most logical and definitive diagnosis

SELECTED REFERENCES

1 ALTSHULE M D Physiology in Diseases of the Heart and Lungs. Cambridge 1949. Harvard University Press
2 BALDWIN E DEF COURNAND A and RICHARDS D W Jr Pulmonary insufficiency III A study of 122 cases of chronic pulmonary emphysema Medicine 28 201 1949
3 COURNAND A Some aspects of the pulmonary circulation in normal man and in chronic cardiopulmonary diseases Circulation 2 641 1950
4 HARVEY R M FERRER M I RICHARDS D W Jr and COURNAND A Influence of chronic pulmonary disease on the heart and circulation Am J Med 10 719 1951
5 RICHARDS D G B WHITEFIELD A G W ARNOTT W M and WATERHOUSE J A H The lung volumes in low cardiac output syndromes. Brit Heart J 13 391 1951
6 FRANK R D N CECIL D W GAENSLER E A and ELLIS L B Ventilatory studies in mitral stenosis a comparison with findings in primary pulmonary disease Am J Med 15 6 1953
7 CARROLL D COTTS J F and RILEY R L Pulmonary function in mitral disease distribution and diffusion characteristics in resting patients J Clin Investigation 32 510, 1953
8 BADER M E and BADER R A The work of breathing Am J Med 18 851 1955
9 BADER M E BADER R A and DACK S Alterations in lung function and anatomy in heart failure with particular reference to mitral stenosis Dis of Chest 28 141 1955

19

Effect of Chronic Pulmonary Disease on the Heart

MAXWELL L. GELFAND, M.D., *New York, New York*

As far back as the eighteenth century the medical profession was aware of the fact that chronic lung disease could ultimately influence cardiac function.[1] The frequency of such occurrence and the degree of involvement continued to be a matter of controversy for many years thereafter. In the past two decades, however, renewed interest in this field has succeeded in accumulating a mass of evidence which has established beyond any doubt the fact that long standing disease of the pulmonary tissue can and does affect the heart both anatomically and physiologically. It does so in a characteristic manner and to such an extent that it has come to be known by a special connotation, i.e., cor pulmonale or pulmonary heart disease.

DEFINITION

Strictly speaking pulmonary heart disease or cor pulmonale are terms that should be applied to hypertrophy of the right ventricle, with or without failure, which results from diseases of the lungs, pulmonary vascular tree or thoracic cage. In a broader sense they are also being employed by some to include the right ven- [illegible]

(2) mitral stenosis, with left ventricular failure.[2] The latter concept is misleading to the clinician, despite the fact that an increased resistance to blood flow through the precapillary portion of the lungs also exists in these primary cardiac conditions. For the purpose of clarification and in order to obviate any confusion, cor pulmonale is herewith defined as that type of heart disease in which right ventricular hypertrophy results solely from diseases of the lungs, pulmonary vessels or thoracic cage.

ETIOLOGY AND INCIDENCE

The etiology of pulmonary heart disease is manifold, as has been shown by the numerous studies of postmortem material, and its incidence varies with the area from which these reports emanate and the enthusiasm of the

TABLE 1*
INCIDENCE OF RIGHT VENTRICULAR HYPERTROPHY IN 6,770 NECROPSIES

	Causes of Death		
	Incidence	Right Heart Failure	Others
Emphysema	30/101	20	[illegible]
Bronchiectasis	17/80	6	11
Asthma	14/24	9	5
Tuberculosis	7/92	3	4
Carcinomatosis	5/42	3	2
Embolism	5/103	4	1
Arteritis	4	4	[illegible]
Unknown cause	4	2	2
Primary carcinoma	3	0	3
Kyphoscoliosis	3	2	1
Secondary carcinoma	2	1	1
Chronic cystic disease	2	1	1
Fibrosis	2	0	2
Organized int. pneumonia	2	1	1
Asbestosis	1	0	1
Hemosiderosis	1	1	0
Total	111	57	54

* Taken from McKeown.[3]

writer. Generally speaking, however, at the present time, it is much more common than heretofore, and all are agreed that it occurs more frequently in males than females in a ratio of more than four to one, particularly in the older age group from fifty to seventy years. The causes of cor pulmonale have been well tabulated by McKeown[3] in England and by Spain and Handler[4] in this country, and to the latter series the present author has added a few cases either encountered personally or found in the more recent literature. (Tables 1

and (c) From Table II it can readily be seen that in the third group, which concerns us most, consisting of diseases of the lungs in which there are anatomic alterations of the pulmonary parenchyma, pulmonary emphysema is the common denominator It is this

TABLE II

I Anatomic alterations of the thoracic cage
  A Kyphoscoliosis
  B Thoracoplasty
II Anatomic alterations of the pulmonary vascular system
  A Main pulmonary arteries
    1 Intrinsic disease of the large pulmonary arteries such as gummatous or cicatric pulmonary arteries
    2 Pressure on the large pulmonary vessels such as aneurysm arising from the base of the aorta
  B Pulmonary arterioles
    1 Primary pulmonary arteriosclerosis or thrombosis obliterans (Ayerza's disease)
    2 Schistosomiasis of the pulmonary vessels
    3 Polyarteritis
    4 Lupus erythematosus
    5 Sickle cell anemia
    6 Recurrent pulmonary embolism
    7 Thrombosis of the pulmonary artery
III Anatomic alterations of the pulmonary parenchyma
  A Primary alterations of the pulmonary parenchyma
    1 Primary pulmonary emphysema with or without fibrosis
    2 Primary pulmonary disease with secondary emphysema and fibrosis
      1 Pulmonary tuberculosis
      2 Pneumoconiosis
        (a) Chronic silicosis
        (b) Anthracosis
      3 Bronchiectasis
      4 Bronchial asthma
      5 Acute interstitial fibrosis
      6 (Multiple cysts of the lungs
  C. Systemic disease with secondary pulmonary parenchymal involvement
    1 Sarcoidosis
    2 Scleroderma

underlying condition, with its disturbed pulmonary physiology, that is responsible for the production of increased tension in the pulmonary circuit and ultimate right ventricular hypertrophy

PATHOGENESIS

The manner in which emphysema produces this effect is by no means a settled question, and in order to explain the pathogenesis many factors have been considered. These include (1) anoxia, (2) anatomic obliteration of the pulmonary vascular bed, (3) retention of carbon dioxide with subsequent respiratory acidosis, (4) pulmonary vascular sclerosis (5) vascular shunts between the systemic and pulmonary circulation, (6) overfilling of the heart, (7) polycythemia, (8) compression of the capillaries by the increased intra alveolar pressure occurring during the respiratory cycle, and (9) diffuse fibrosis of the lungs There is no doubt that many of these exist at one time or other during the course of the disease, and very likely all contribute in some degree to the production of pulmonary hypertension From work recently reported,[9] however, it appears that the increased pressure in the pulmonary circuit is most probably due in the main to a combination of anoxia and anatomic obliteration of the pulmonary vascular bed, and that the others play a secondary role If the foregoing is true—and it can hardly be challenged—the frequently posed question why all cases of emphysema do not result in cor pulmonale still awaits an answer It is possible that occupational, constitutional, endocrine and neurogenic components may play a significant part in determining who may or may not develop this disease It must be remembered, however, that any case of obstructive emphysema regardless of its underlying cause is potentially able in the proper setting to develop the required pathologic stimulus which will lead eventually to an increased tension in the pulmonary circuit and to right ventricular enlargement

Formerly cor pulmonale was recognized purely on clinical grounds or at autopsy, but at present, with the newer techniques of cardiac catheterization at our disposal, this type of heart disease can be diagnosed long before overt signs of right ventricular failure present themselves With these methods permitting direct measurement of the pressures permitting direct pulmonary artery and right ventricle, a definite set of values has been obtained for normal human beings (Table III) In most cases of pulmonary emphysema, numerous workers employing the cardiac catheterization approach have demonstrated a distinct elevation of the pressures within these cavities Bloomfield et al[10] in 1946 reported an increase in the systolic pressure within the right ventricle in four of six patients with chronic pulmonary emphysema Bordin and his co-workers[11] a few years later showed that in all their twenty-four cases of chronic diffuse pulmonary emphysema the pulmonary diastolic pressure was distinctly elevated, and in the majority of their patients

the pulmonary systolic pressure was also above normal In addition, these authors demonstrated that there was no correlation between the severity of the emphysema, as estimated by the ratio of residual air to total lung volume, and the elevation of the pulmonary arterial

TABLE III
NORMAL VALUES FOR PULMONARY ARTERIAL AND RIGHT VENTRICULAR PRESSURE

Reference	No of Subjects	Right Ventricular Systolic (mm Hg)		Pulmonary Arterial Diastolic (mm Hg)	
		Average	Range	Average	Range
Bloomfield R A et al J Clin Investigation 25 639 1946	14	25	18 30		
Cournand A Bull New York Acad Med 23 27 194	4	25		8	
Dexter L et al J Clin Investigation 26 554 1947	3	26	20–32	10	8 12
Motley H L et al Am J Physiol 150 315 1947	5	22		6	
Riley R L et al Am J Physiol 152 372 1948	3	20		9	
Borden C W Minnesota Med 31 1218 1948	2	20 1	11 26	8 8	6 11

pressure In their group it was also noted that the pulmonary tension was much higher in those who recovered from right heart failure than in those who were never in failure Harvey et al[4] in 1951 studied both pulmonary and cardiac function in forty eight cases of chronic pulmonary disease, of which twenty four were diagnosed as chronic pulmonary emphysema, eight patients were considered as suffering from silicosis and emphysema, ten were labeled instances of diffusion fibrosis in whom the physiopathologic pattern was characterized by interference of oxygen diffusion across the alveolocapillary membrane, and four were assigned to a miscellaneous group, of whom two apparently presented multiple embolization into the pulmonary arterial tree and two primary pulmonary vascular disease These writers found that the degree of pulmonary hypertension and increased pressure in the right ventricle depended predominantly on the degree of oxygen unsaturation or anoxia and on the extent of the anatomic alterations in the pulmonary vascular bed produced by the disease process itself They also demonstrated a greater pulmonary hypertension in patients with cor pulmonale while in congestive failure than when in a state of compensation Many such patients presented a reversibility of their congestive failure, with long periods of remission, thus indicating a more hopeful prognosis than had heretofore been predicted in the congestive phase of cor pulmonale Furthermore, the authors demonstrated an elevated pressure in the pulmonary artery and right ventricle in many who had shown no x ray evidence of any enlargement of these chambers nor electrocardiographic abnormalities concomitant with right ventricular hypertrophy In re-evaluating the cardiac output they found it to be either elevated, normal or low, depending upon the degree and type of the underlying pulmonary involvement In chronic pulmonary emphysema, with marked anoxia and hypervolemia, they observed a high output and believed the increased blood volume to be responsible A similar finding was also evident in patients with diffusion fibrosis without hypervolemia and in such instances the high output was ascribed to the continuous activity of the disease rather than to a change in blood volume which did not exist In the silicotic group in which anoxia did not play an important role in the production of increased pulmonary tension but in which the predominant etiology was the anatomic obliteration of the vascular bed, the cardiac output was either low or normal In the majority of instances of cor pulmonale the cardiac output is high, and in a few cases it may even be normal or low This supports the work of previous observers and also indicates that, since pulmonary emphysema is not a static disease, the findings of one investigator may be entirely different from those of another simply because the determinations were obtained during different phases of the disease in the same patient or at various stages in different patients

These physiologic observations noted by means of cardiac catheterization offer absolute proof that the heart is definitely involved in chronic pulmonary diseases The fact that increased tension in the pulmonary artery and right ventricle can be demonstrated by this method long before overt signs of cor pulmonale appear has led many to believe that the only confirmatory method of diagnosing cor pulmonale antemortem is by means of this technic

Such a procedure, however, is far from a simple one either for the patient or for the physician It is highly technical, requires special training and is not completely without danger Fortunately, it is not the only method available There is a distinct clinical picture, classic radiologic findings and characteristic electrocardiographic alterations that are of great assistance in the recognition of this type of heart disease

CLINICAL PICTURE

The clinical syndrome of cor pulmonale may be divided into two major phases an early pulmonary phase in which the manifestations of the underlying pulmonary disease predominate, and the later cardiac stage characterized by the disturbances produced directly by the hypertrophy of the right ventricle and the increased tension in the lesser circulation The signs and symptoms of the pulmonary phase are (1) cough (2) cyanosis (3) dyspnea, (4) clubbing of the fingers (5) diminished expansion of the chest and an increase in its anteroposterior diameter, (6) fixation of the diaphragm and (7) polycythemia The outstanding features of the second stage are (1) engorged neck veins, (2) enlarged and tender liver (3) generalized edema and (4) increased venous pressure The transition from one phase to the other is extremely difficult to detect since cough, cyanosis and dyspnea the preliminary signs of heart failure are also indicative of the underlying pulmonary disease However, an increase in the intensity of these findings or the appearance of orthopnea suggests the onset of right heart strain It is known that patients with emphysema breathe more comfortably lying down whereas those with cardiac dyspnea are relieved by sitting upright A positive hepatojugular reflux elicited by pressure over the right upper quadrant long before hepatic enlargement is felt is another early indication of cardiac failure in this type of heart disease Cardiac hypertrophy cannot be detected by the usual means of physical examination since the underlying emphysema interferes with the percussion note obtained Regular sinus rhythm and normal blood pressure are the usual occurrence in chronic cor pulmonale but occasionally an ectopic rhythm may be heard Accentuation of the second pulmonic sound is a constant feature and this in addition to the systolic murmur frequently audible over the pulmonic area, suggests the existence of increased intrapulmonary tension In the compensated stage of this disease, before overt signs of failure appear these two later findings plus an increase in cyanosis and the development of polycythemia are often the only manifestations of cardiac involvement.

CIRCULATORY FUNCTION STUDIES

Various studies of circulatory function have been performed by Oppenheimer and Hitzig who have shown the findings to be normal in uncomplicated pulmonary heart disease In the early stages of pulmonary heart disease associated with right ventricular enlargement with compensation they are also normal But when myocardial insufficiency sets in, these measurements become abnormal Incipient right heart failure is characterized by the presence of a normal initial venous pressure and a varying rise in this pressure during compression of the right upper quadrant of the abdomen The arm to-lung circulation (ether) time may or may not be prolonged, and the lung to-tongue circulation time (saccharin time minus ether time) is normal In frank isolated right heart failure, however there is a high initial venous pressure, with considerable rise upon right upper quadrant compression a prolonged arm to-lung time, and a relatively normal lung to-tongue time In mild cor pulmonale the circulating blood volume may be normal, but in severe cases with arterial anoxia and polycythemia it is increased and indicates decompensation

X RAY

Another link in the chain of evidence in favor of the clinical diagnosis of cor pulmonale is the characteristic cardiac silhouette seen roentgenographically, indicating hypertrophy of the right ventricle and dilatation of the pulmonary artery In 1923 Dutlen summarized the significant x ray appearances of the heart in emphysema He noted cardiac enlargement transversely to the right, prominence of the inferior right border which is separated from the right auricle above by a groove prominence of the pulmonary arch with forceful pulsation there and at the lower right cardiac border and elongation of the outline of the right ventricle in the lateral views. These observations were subsequently confirmed by

the pulmonary systolic pressure was also above normal In addition, these authors demonstrated that there was no correlation between the severity of the emphysema, as estimated by the ratio of residual air to total lung volume, and the elevation of the pulmonary arterial

TABLE III
NORMAL VALUES FOR PULMONARY ARTERIAL AND RIGHT VENTRICULAR PRESSURE

Reference	No of Subjects	Right Ventricular Systolic (mm Hg)		Pulmonary Arterial Diastolic (mm Hg)	
		Average	Range	Average	Range
Bloomfield R A et al *J Clin Investigation* 25 639 1946	4	25	18–30		
Cournand A *Bull New York Acad Med* 23 27 194	4	35		8	
Dexter L et al *J Clin Investigation* 26 554 1947	3	26	20–32	10	8 12
Motley H L et al *Am J Physiol* 150 315 1947	5	22		6	
Riley R L et al *Am J Physiol* 152 372 1948	3	20		9	
Borden C W *Minnesota Med* 31 1218 1948	12	20 1	11 26	8 8	6 11

et al[5] in 1951 studied both pulmonary and cardiac function in forty eight cases of chronic pulmonary disease, of which twenty-four were diagnosed as chronic pulmonary emphysema, eight patients were considered as suffering from silicosis and emphysema, ten were labeled instances of diffusion fibrosis in whom the physiopathologic pattern was characterized by interference of oxygen diffusion across the alveolocapillary membrane, and four were assigned to a miscellaneous group, of whom two apparently presented multiple embolization into the pulmonary arterial tree and two primary pulmonary vascular disease These writers found that the degree of pulmonary hypertension and increased pressure in the right ventricle depended predominantly on the degree of oxygen unsaturation or anoxia and on the extent of the anatomic alterations in the pulmonary vascular bed produced by the disease process itself They also demonstrated a greater pulmonary hypertension in patients with cor pulmonale while in congestive failure than when in a state of compensation Many such patients presented a reversibility of their congestive failure with long periods of remission, thus indicating a more hopeful prognosis than had heretofore been predicted in the congestive phase of cor pulmonale Furthermore, the authors demonstrated an elevated pressure in the pulmonary artery and right ventricle in many who had shown no x ray evidence of any enlargement of these chambers nor electrocardiographic abnormalities concomitant with right ventricular hypertrophy In re evaluating the cardiac output they found it to be either elevated, normal or low, depending upon the degree and type of the underlying pulmonary involvement In chronic pulmonary emphysema, with marked anoxia and hypervolemia, they observed a high output and believed the increased blood volume to be responsible A similar finding was also evident in patients with diffusion fibrosis without hypervolemia and in such instances the high output was ascribed to the continuous activity of the disease rather than to a change in blood volume, which did not exist In the silicotic group in which anoxia did not play an important role in the production of increased pulmonary tension but in which the predominant etiology was the anatomic obliteration of the vascular bed the cardiac output was either low or normal In the majority of instances of cor pulmonale the cardiac output is high and in a few cases it may even be normal or low This supports the work of previous observers and also indicates that, since pulmonary emphysema is not a static disease, the findings of one investigator may be entirely different from those of another, simply because the determinations were obtained during different phases of the disease in the same patient or at various stages in different patients

These physiologic observations noted by means of cardiac catheterization offer absolute proof that the heart is definitely involved in chronic pulmonary diseases The fact that increased tension in the pulmonary artery and right ventricle can be demonstrated by this method long before overt signs of cor pulmonale appear has led many to believe that the only confirmatory method of diagnosing cor pulmonale antemortem is by means of this technic

Such a procedure however is far from a simple one either for the patient or for the physician It is highly technical requires special training and is not completely without danger For tunately it is not the only method available There is a distinct clinical picture classic radiologic findings and characteristic electro- cardiographic alterations that are of great assistance in the recognition of this type of heart disease

CLINICAL PICTURE

The clinical syndrome of cor pulmonale may be divided into two major phases an early pulmonary phase in which the manifestations of the underlying pulmonary disease pre dominate and the later cardiac stage charac terized by the disturbances produced directly by the hypertrophy of the right ventricle and the increased tension in the lesser circulation The signs and symptoms of the pulmonary phase are (1) cough (2) cyanosis (3) dyspnea (4) clubbing of the fingers (5) diminished expansion of the chest and an increase in its anteroposterior diameter (6) fixation of the diaphragm and (7) polycythemia The out standing features of the second stage are (1) engorged neck veins (2) enlarged and tender liver (3) generalized edema and (4) increased venous pressure The transition from one phase to the other is extremely difficult to detect since cough cyanosis and dyspnea the preliminary signs of heart failure are also indicative of the underlying pulmonary dis ease However an increase in the intensity of these findings or the appearance of orthopnea suggests the onset of right heart strain It is well known that patients with emphysema breathe more comfortably lying down whereas those with cardiac dyspnea are relieved by sitting upright A positive hepatojugular reflux elicited by pressure over the right upper quad rant long before hepatic enlargement is felt is another early indication of cardiac failure in this type of heart disease Cardiac hyper trophy cannot be detected by the usual means of physical examination since the underlying emphysema interferes with the percussion note obtained Regular sinus rhythm and normal blood pressure are the usual occurrence in chronic cor pulmonale but occasionally an ectopic rhythm may be heard Accentuation of the second pulmonic sound is a constant feature and this in addition to the systolic murmur frequently audible over the pulmonic area suggests the existence of increased intra pulmonary tension In the compensated stage of this disease, before overt signs of failure appear these two later findings plus an increase in cyanosis and the development of poly cythemia are often the only manifestations of cardiac involvement

CIRCULATORY FUNCTION STUDIES

Various studies of circulatory function have been performed by Oppenheimer and Hitzig who have shown the findings to be normal in uncomplicated pulmonary disease In the early stages of pulmonary heart disease associated with right ventricular enlargement with com pensation they are also normal But when myocardial insufficiency sets in these meas urements become abnormal Incipient right heart failure is characterized by the presence of a normal initial venous pressure and a varying rise in this pressure during compression of the right upper quadrant of the abdomen The arm to-lung circulation (ether) time may or may not be prolonged and the lung to- tongue circulation time (saccharin time minus ether time) is normal In frank isolated right heart failure however there is a high initial venous pressure with considerable rise upon right upper quadrant compression a prolonged arm to-lung time and a relatively normal lung to-tongue time In mild cor pulmonale the circulating blood volume may be normal but in severe cases with arterial anoxia and polycythemia it is increased and indicates decompensation

X RAY

Another link in the chain of evidence in favor of the clinical diagnosis of cor pulmonale is the characteristic cardiac silhouette seen roent genographically indicating hypertrophy of the right ventricle and dilatation of the pulmonary artery In 1923 Detlen summarized the sig nificant x ray appearances of the heart in emphysema He noted cardiac enlargement transversely to the right, prominence of the inferior right border which is separated from the right auricle above by a groove, prom inence of the pulmonary arch with forceful pulsation there and at the lower right cardiac border and elongation of the outline of the right ventricle in the lateral views These ob- servations were subsequently confirmed by

many other workers Parkinson and Hoyle[11] in an excellent clinical and radiographic study of the heart in eighty patients with advanced emphysema noted that changes in the root and larger branches of the pulmonary artery were the most frequent x ray signs of right heart involvement This finding was rarely demonstrable in the frontal view but was best visualized in the right oblique position In the left oblique view the right ventricle could be detected only in a small proportion of cases Rigler and Hallock[12] and Gelfand[13] also emphasized the need of all four standard positions particularly the oblique to demonstrate enlargement of the right ventricle and pulmonary artery in cases of pulmonary emphysema Robb and Steinberg[14] demonstrated by contrast angiocardiography an enlargement of the right ventricle and pulmonary artery in a case of pulmonary heart disease Employing the same technic Sussman Steinberg and Grishman[15] obtained similar results in twenty four of twenty eight cases of emphysema thus indicating a high percentage of cardiac involvement in chronic emphysema It is now generally agreed that the first x ray sign of right cardiac enlargement is prominence of the pulmonary arch i e the middle arch on the left cardiac border forming the outflow tract The hypertrophy progressively continues and presents itself later as an enlargement of the lower part of the right ventricle the inflow tract Because of these specific radiographic characteristics of the heart in cor pulmonale it is frequently stated that next to cardiac catheterization the most accurate method of diagnosing cor pulmonale is the x ray

ELECTROCARDIOGRAPH

The electrocardiograph is an extremely useful tool for the detection of right ventricular hypertrophy and thus in cor pulmonale in which enlargement of the right ventricle is an outstanding feature this modality should be of considerable value While it is agreed that in the early stages of the disease when the pulmonary resistance is not three times the normal the changes on the electrocardiogram may be minimal nevertheless an acquaintance with the electrocardiographic patterns which suggest right heart strain will prove very rewarding

The earlier writers reported the following changes in emphysema and cor pulmonale (1) right axis deviation (2) RST depression with inverted T waves in leads II and III (3) deep S waves in all standard limb leads and (4) P wave abnormalities consisting of tall and notched P in leads II and III These alterations are not specific for right ventricular enlargement for they may occur in normal as well as in vertical hearts with left ventricular hypertrophy The introduction of multiple unipolar precordial and extremity leads however, have added additional information permitting of a [illegible] of right ventricu [illegible] yield complexes consisting of a small q and tall R with or without a small s wave On the average the peak of R is about 0 02 second earlier when the precordial lead is over the right ventricle than when over the left In [illegible] hypertrophy however Wilson [illegible] eyers[16] [illegible] m the right side of the precordium V_1 and V_2 the QRS complex is chiefly an R wave with an occasional antecedent small q wave and the s wave is either absent or relatively small The [illegible] all with an upright T wave There is a p[illegible] time interval between the beginning of the QRS complex and the onset of the intrinsicoid deflection in V_1 generally between 0 03 to 0 04 second which is greater than is seen in V_5 and V_6

An additional precordial lead V_3R in which the exploring electrode is placed on the right chest at a point corresponding to V_3 position on [illegible] Meyers[16] [illegible] in and his [illegible] ious right ventricular hypertrophy not confirmed by the other precordial leads In such instances it yielded a small q a tall R and an inverted T wave in contrast to a small r and deep S normally obtained An alteration in the unipolar limb lead VR in which there is a tall R preceded by a small q is an additional electrocardiographic pattern indicative of right ventricular enlargement The final pattern that may be seen in this type of heart disease is right bundle branch block either of the incomplete or complete variety In the former there is a double peaking of the R wave in V_1

and a relatively broad S wave in V_6 with the duration of the QRS for 11 second or less In the latter the total duration of the QRS is 0 12 second or longer the peak of the final R wave in lead V_1 is later in time than the peak of the R wave in V_5 and the R waves in the leads from the right side of the precordium are more prominent coarsely notched and double peaked without any Q waves preceding them Demonstration of any of these aforementioned electrocardiographic deviations furnishes conclusive evidence of right sided myocardial involvement

Thus it is apparent from the foregoing discussion that chronic diseases of the lung—more commonly chronic pulmonary emphysema and pulmonary fibrosis either individually or together as may sometimes occur—produce increased tension in the pulmonary artery and right ventricle with ultimate hypertrophy of the right heart Although previously this hypertension was suspected by indirect means at present it can be accurately measured by cardiac catheterization Its clinical counterpart is chronic cor pulmonale and this syndrome can now be more frequently and accurately recognized on the basis of the following criteria (1) the existence of chronic lung disease (2) the absence of any other cardiac disease (3) the development of an increase in the dyspnea or cyanosis already present (4) the appearance of orthopnea (5) accentuation of the second pulmonic sound with or without a murmur over the pulmonic area (6) a positive hepatojugular reflux, (7) radiographic demonstration of cardiac enlargement and (8) an electrocardiographic pattern of right ventricular hypertrophy,

TREATMENT

Successful therapy of cor pulmonale depends upon a proper understanding of the physiopathologic factors responsible for its development In pulmonary emphysema when obstruction due to bronchospasm and uneven distribution of air in the alveoli are the fundamental disturbances aerosolized bronchodilators oxygen and antibiotics are the most powerful weapons to bring relief When hypercapnia develops in association with anoxia or when the two are present concomitantly Harvey et al [20] suggest the use of a mechanical means of maintaining adequate alveolar ventilation while oxygen is being supplied They believe that treatment with these artificial respirators should be systematized and given over a long period of time When frank signs of congestive heart failure appear they recommend in addition to digitalis low salt diet and diuretics judicious phlebotomy to overcome the existing polycythemia The beneficial effect of digitalis in this type of heart disease is questioned by some since most of these patients have a high cardiac output

In pulmonary fibrosis the primary difficulty is an interference with the oxygen diffusion along the pulmonary alveolar capillary membrane and therapy here consists of the administration of oxygen by the usual clinical means the giving of antibiotics and prescription of marked limitation of activity When the fibrosis is due to a granuloma cortisone and corticotropin (ACTH) have been suggested in an attempt to limit the cellular proliferation responsible for the fibrosis Usually most of the patients in this group die from pulmonary insufficiency long before signs of right heart failure develop but when the latter do appear the treatment is the same as for all others in congestive failure

Early diagnosis and correct understanding of the altered physiology of cor pulmonale will result in proper therapy which will prolong life in this crippling disease

REFERENCES

1 SENAC M de Traité de la Structure du Coeur de Sont Action et de ses Maladie and ed Paris 1783

2 DEXTER, L. LEWIS B M HAINES F W GORLIN R and HOUSSEY C J Chronic cor pulmonale without hypox a *Bull New England M Center* 14 69 1952

3 MCKEOWN F The pathology of pulmonary heart disease *B ti Heart J.*, 14 25 1952

4 SPAIN D M and HANDLER, B J Chron c cor pulmonale sixty cases stud ed at necropsy *Arch Int Med* 77 37 1946

5 HARVEY R N FERRER, M I RICHARDS D W JR and COURNAND A Influence of chronic pulmonary d seise on the heart and c rculat on *Am J Med* 10 719 1951

6 BLOOMFIELD, R A LAUSON H D COURNAND A BREED F S and RICHARDS D W JR. Recording of right heart pressures in normal subjects and in pat ents with chron c pulmonary disease and var ous types of card oc rculatory d seise *J Cl n Invest* 25 639 1946

7 BORDEN C. W WILSON R H LEBERT R V and WELLS H S Pulmonary hypertens on in chronic pulmonary emphysema *Am J Med.*, 8 501 1950

8 BRILL, I C, Clinical manifestations of the various types of right sided heart failure (cor pulmonale) *Ann Int Med*, 13 513 1939

9 OPPENHEIMER [illegible] S and HITZIG W M Use of circulatory measurements in evaluating pul [illegible]

10 D [illegible]

Leipzig 1923

11 PARKINSON J and HOYLE C The heart in emphysema *Quart J Med* 6 59 1937

12 RIGLER L G and HALLOCK P Chronic cor pulmonale *Am J Roentgenol* 50 453 1943

13 GELFAND M L Cor pulmonale in long standing bronchial asthma *Am J Med* 10 27 1951

14 ROBB G P and STEINBERG I Visualization of the heart and the thoracic blood vessels in pulmonary heart disease a case study *Ann Int Med*, 13 12 1939

15 SUSSMAN M L STEINBERG M F and GRISHMAN A Contrast visualization of the heart and [illegible]

16 [illegible] tial variations of the ventricular surfaces and the form of the ventricular electrocardiogram in leads from the precordium and the extremities. *Tr A Am Physicians* 56 258 1941

17 GOLDBERGER A An interpretation of axis deviation and ventricular hypertrophy *Am Heart J* 28 621 1944

18 MEYERS G B KLEIN H A and STOFER B E The electrocardiographic diagnosis of right ventricular hypertrophy *Am Heart J*, 35 1 1948

19 KOSSMAN C E BERGER, A R BRUMLIK J and BRILLER S A An analysis of causes of right axis deviation based partly on endocardial potentials of the hypertrophied right ventricle *Am Heart J* 35 309 1948

20 HARVEY R M FERRER, M I and COURNAND A The treatment of chronic cor pulmonale *Circulation* 7 932 1953

Pulmonary Diseases Secondary to Heart Diseases

NATHANIEL E REICH, M D, *Brooklyn New York*

PULMONARY complications are a frequent occurrence during the course of many heart diseases and are of vital concern to the thoracic surgeon as well as to the internist and chest specialist Our rapidly expanding knowledge in both fields makes it imperative to establish the correct diagnosis if treatment is to be effective Several congenital cardiac defects acute and chronic inflammations of the heart and aorta degenerative lesions of the coronary arteries and aorta and primary neoplasms of the heart are capable of producing a variety of pulmonary complications

CONGENITAL CARDIAC LESIONS

Interest in this field has been reawakened since it is now possible to correct a number of congenital cardiovascular lesions by surgical means These include patent ductus arteriosus coarctation tetralogy of Fallot vascular ring anomalies aberrant subclavian artery septal defects, pulmonary stenosis and various transpositions

The only congenital vascular lesions which directly affect the trachea or bronchi by compression are the vascular ring anomalies[1] Other defects such as tetralogy of Fallot produce dyspnea cyanosis clubbing etc but these are due to lack of proper oxygenation of blood because of the existence of abnormal shunts However all infants with cyanosis or dyspnea do not have congenital heart disease A large diaphragmatic hernia congenital air cyst lung anomaly or pulmonary hemorrhage may simulate the signs and symptoms of congenital heart disease In addition to insufficient pulmonary blood flow and congestive failure induced by some congenital lesions subacute bacterial infections may result in embolic infarctions multiple abscesses and bronchopneumonia

Right Aortic Arch This congenital anomaly may sometimes form a vascular ring by the constricting effect of a patent ductus arteriosus or ligamentum arteriosus (*Fig* 1) It produces symptoms in the newborn by pressure on the right upper lobe bronchus thus producing atelectasis obstructive emphysema or recurrent infections (tracheobronchitis or pneumonitis) It may also cause the pulmonary artery to compress the anterior surface of the trachea Symptoms may be initiated later in life owing to traction caused by elongation and posterior displacement of the arteriosclerotic aorta Pulmonary symptoms include dyspnea, cyanosis cough and chest pain Head retraction and stridor may occur in infants X ray studies of the barium filled esophagus reveal an indentation at the level of the third intervertebral space[2] Lipiodol studies in the lateral position delineate anterior tracheal compression just above the carina Angiocardiography (7 second film) usually reveals the exact location of the vascular deformity

When the obstruction produces symptoms the ligamentum arteriosus is divided allowing the pulmonary artery to fall forward[3]

Double Aortic Arch This anomaly occurs when both fourth branchial arteries persist The left (anterior) arch is usually much smaller than the right. The vascular ring produces encroachment upon the trachea and esophagus, resulting in symptoms and diagnostic studies similar to those listed under the right aortic arch Complete relief is afforded by the ligation and extirpation of the left (anterior) portion of the double arch (Fig 1)

Pulmonary Stenosis Pulmonary tuberculosis has been found to occur with greater frequency in the presence of several congenital heart conditions This is especially true of pulmonary stenosis and tetralogy of Fallot Abbott[4] found an incidence of 36 per cent and attributed this to the insufficient pulmonary blood flow This explanation appears likely in view of the fact that tuberculosis seldom occurs in the chronically engorged lungs of

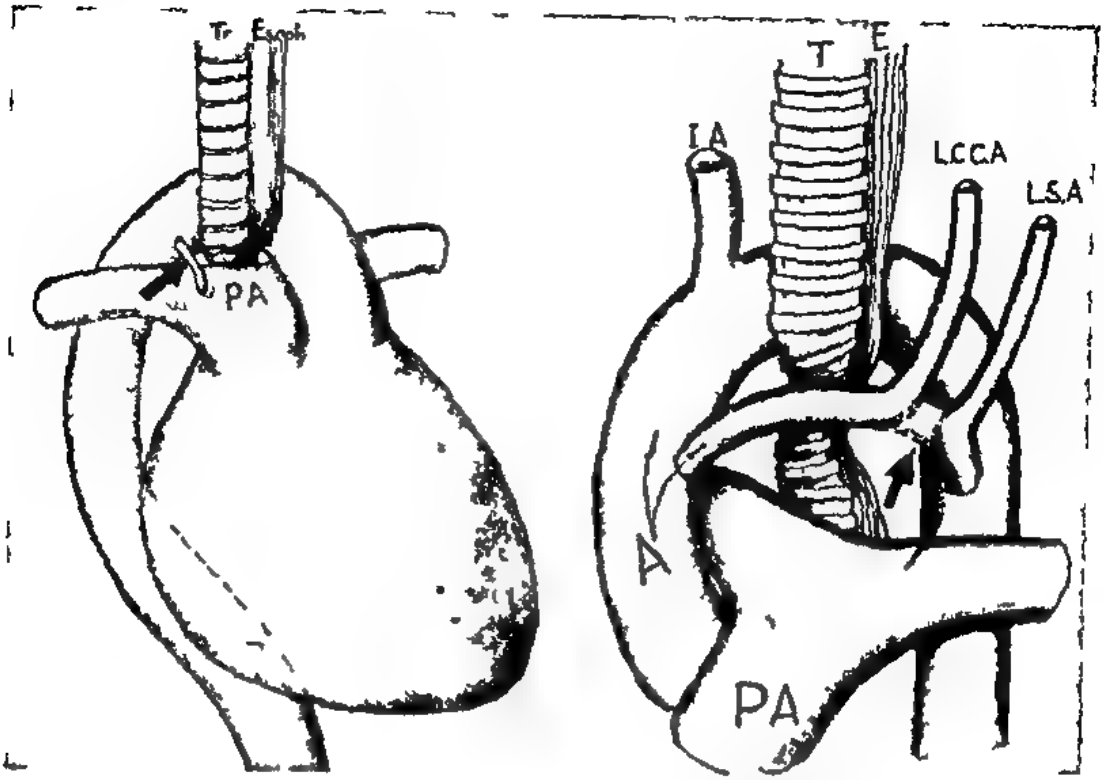

Right Aortic Arch Double Aortic Arch

FIG 1 Vascular ring anomalies

patients with mitral stenosis Superimposed subacute bacterial infections with pulmonary embolization may also occur This results in infarction pneumonitis or lung abscess

The Blalock shunt operation has been employed with success A direct attack on the stenosing tissue by incision or punch operation produces equally satisfactory results in other cases especially in those with an infundibulum

Patent Ductus Arteriosus Ordinarily the higher pressure in the aorta allows a return flow to the pulmonary artery through this abnormal communication Pulmonary congestion may occur eventually if the shunt is of considerable size The most frequent complications are congestive heart failure and subacute bacterial endocarditis The latter results in embolic infarctions of the lung Multiple small abscesses or patchy pneumonitis may ensue

pulmonary hypertension appear during the course of this disease

ACUTE RHEUMATIC FEVER

Rheumatic Pneumonia Rheumatic pneumonia is a rare but integral phase of acute rheumatic fever since the collagen tissue and its ground substance may be affected in any part of the body An incidence of pulmonary involvement has been reported by numerous observers as varying from 2 to 15 per cent of all cases The occurrence would be noted in a much larger percentage if all patients with acute rheumatic fever had chest x rays at frequent intervals but especially at the height of an attack of acute rheumatic fever The pathologic changes consist essentially of irregularly scattered areas of hemorrhagic consolidation Cough and sputum are not prominent features The diagnosis rests on finding signs of transitory or migratory pulmonary exudates This is demonstrable on serial x ray studies (Fig 2) Part of one lobe may be involved or the inflammatory process may extend to all the lobes The lesions clear rapidly following the use of ACTH or cortisone but this is difficult to evaluate because of the evanescent character of the lesions

Pleurisy Pleurisy is probably another man

matic fever it is found in [illegible]

FIG 2 Rheumatic pneumonia A irregularly scattered areas of soft infiltrations throughout both lower lung fields more marked on the left side Onset of pneumonic involvement occurred the previous day B marked diminution in extent and intensity of the infiltrations the following day illustrating the transient nature of the exudates

come to postmortem examination It may occur on either or both sides and usually follows pulmonary or pericardial involvement Characteristically, the initial severe inspiratory pain and friction rub disappear within several days as effusion accumulates Routine roentgenograms demonstrate fluid levels in a high percentage of cases Aspiration is seldom required but shows a clear or cloudy serofibrinous exudate On rarer occasions it may appear hemorrhagic possibly due to the presence of pulmonary infarction Although the fluid is rapidly absorbed adhesions develop occasionally These may be pleuropericardial adhesions which give the cardiac silhouette a scalloped appearance or partially obliterate the pleural space

MITRAL VALVULAR DISEASE

Several pulmonary complications commonly occur following distortion of the mitral valve On rare instances mitral stenosis may be associated with an interauricular septal defect (Lutembacher's syndrome)

Chronic Congestive Failure Mitral valvular lesions especially stenosis may produce early pulmonary congestion As a result of chronic congestive heart failure the lungs become firm dense dry and red brown in appearance There is interstitial edema increased collagen and thickening of the capillary basement membrane These changes thicken the alveolar wall and interfere with gaseous exchange They eventually produce an inelasticity of the lung tissue which seriously interferes with ventilation

Dyspnea orthopnea and cyanosis are major symptoms Hemoptysis occurs in 10 per cent of cases of mitral stenosis due to vascular hypertrophy Although it may appear at any time during the course of the disease it usually denotes an advanced degree of stenosis with increasing pulmonary congestion The blood loss is seldom massive but augurs a dire prognosis Cough is commonly present and when productive the sputum may reveal numerous heart failure cells The sputum is mucoid but may be blood streaked or frankly purulent due to secondary bronchopulmonary infection

Acute Pulmonary Edema This may occur in mitral stenosis and other valvular lesions even when regular sinus rhythm exists It usually follows severe exertion operation, pregnancy rapid digitalization or paroxysmal tachycardia Attacks are precipitated by the added strain on the right heart in the presence of pulmonary congestion Treatment includes digitalization, morphine and atropine oxygen, mercurials and antifoaming agent

sequently surgery may be indicated Remarkable results are constantly being reported by numerous surgeons Commissurotomy or finger fracture of the stenosed valve or anastomosis between the aorta and pulmonary artery or between the right inferior pulmonary vein to the azygos veins will relieve pulmonary hypertension

Rupture Rupture of a papillary muscle of *chordae tendineae* results in an unusually rapid form of pulmonary congestion This may be caused by trauma superimposed subacute bacterial endocarditis or coronary *thrombosis* It produces an extremely loud murmur which is frequently audible at a distance from the chest

Pulmonary Infarction The effects of pulmonary infarction are discussed elsewhere Suffice it to say that this serious complication may result from the discharge of clots from the right auricle during *auricular fibrillation* It is important not to overlook other major causes such as peripheral or pelvic venous thrombosis Early treatment of the primary

pendages is presently employed with success in cases with recurrent embolization (Madden)

BACTERIAL ENDOCARDITIS

The acute and subacute forms of bacterial infections of the valvular and mural endocardium may be caused by many microorganisms However the non hemolytic streptococcus accounts for 95 per cent of all cases In order for emboli to reach the lungs the right heart must obviously be affected Septal defects pulmonary or tricuspid stenosis patent ductus arteriosus tetralogy of Fallot or other combined congenital lesions may also provide a nidus

Pulmonary emboli and infarctions congestion bronchopneumonia or lung abscesses may be encountered The infarctions usually are too small to be visualized on the x ray Pleural effusions or hemorrhages are not uncommonly found Emboli in pulmonary arterial branches may also result in arteritis or mycotic aneurysm Symptoms include cough chest pain dypsnea or bloody expectoration Antibiotics are effective in most cases when properly selected and administered in adequate dosage

ACUTE NON SPECIFIC PERICARDITIS

Acute pericarditis is usually regarded as evidence of serious underlying disease such as rheumatic fever myocardial infarction uremia tuberculosis and pneumonia There is a rare group of disorders which may also produce acute pericarditis However we are primarily concerned with acute non specific pericarditis This type occurs in young males as a rule and has an increasing incidence Frequency of recurrences has been emphasized lately

Invariably there is involvement of the pleura in viral inflammation of the pericardium A pleural lesion must be suspected when the clinical (chest pain dyspnea fever rub) and laboratory findings (electrocardiogram and x ray) of acute non specific pericarditis are accompanied or followed shortly by the onset of a pleural friction rub which may last for days or weeks This may progress to pleural effusion of varying degree (usually small in amount) and finally progressive pleural thickening The aspirated fluid is exudative and non bloody and may be bilateral Pulmonary involvement is uncommon Pleural fluid is demonstrable on the roentgenogram Persistence of fever following improvement of the pericarditis and invariable recovery further suggest this possibility Results with aureomycin chloromycetin® and terramycin® have been equivocal thus far The disease is self limited but aspiration of fluid is indicated when its presence embarrasses cardiac or pulmonary function (Fig 3)

CHRONIC CONSTRICTIVE PERICARDITIS

Chronic constrictive pericarditis is a dense fibrous thickening of the pericardium (Fig 4) which may cause compression of the heart and interfere with normal filling It may completely envelop the heart or produce a band like or other localized strictures It is characterized clinically by the triad of a small quiet heart elevated venous pressure and ascites

The cause is often obscure Although tuberculosis is the most common cause in cases with proven etiology this disease accounts for only 15 per cent of all cases Rheumatic fever pleuropulmonary disease myocardial infarction and neoplastic involvement make up the bulk of all cases (Fig 4)

The lungs usually do not reveal significant congestion or fibrosis unless tuberculosis is the

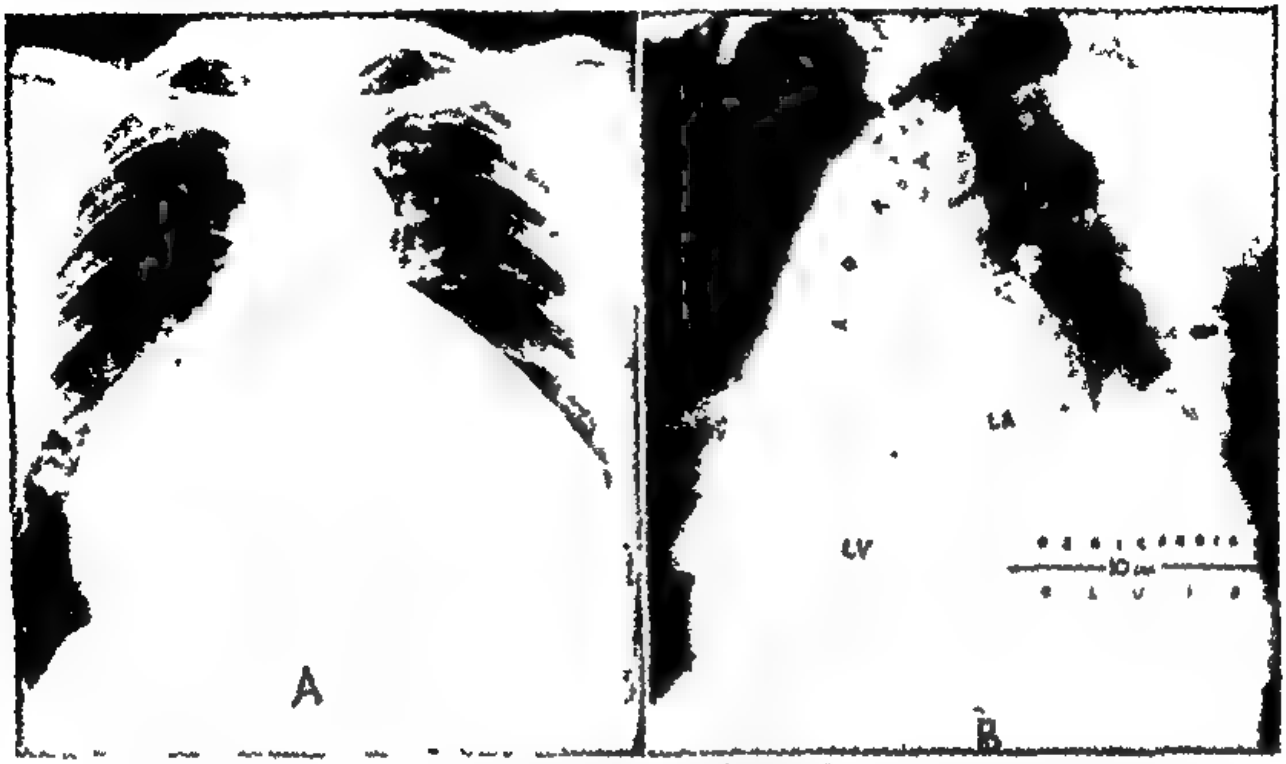

FIG 3 Marked pericardial effusion Reduction of pulmonary function by very marked effusion A, note water-bottle configuration of pericardial effusion B, in left anterior oblique view of angiocardiogram the pericardial effusion is more sharply defined Note posterior compression of lung space

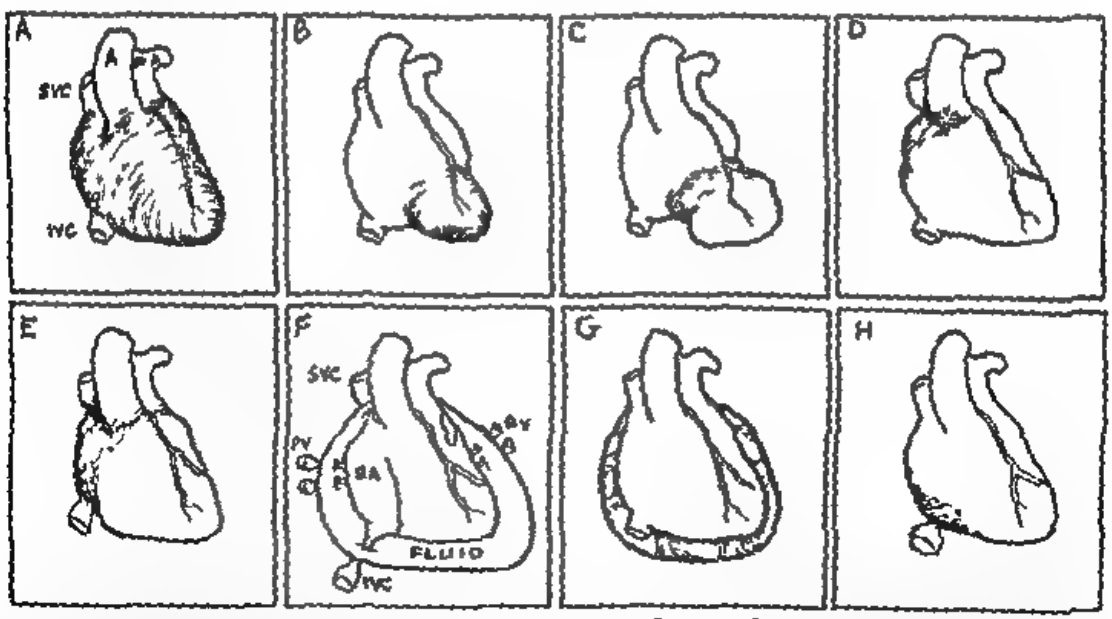

FIG 4 Types of chronic intrapericardial pressure A, complete enveloping scar, B, ventricular scar, note compression with bulge above C band over ventricles D, band around superior vena cava, resulting in superior vena caval syndrome E band over auricles F, tamponade (blood or effusion) note compression of auricular appendages and intrapericardial portions of venae cavae and pulmonary veins G adhesive pericarditis. H band around inferior vena cava resulting in inferior vena caval syndrome (From REICH N E The Uncommon Heart Diseases Springfield, Ill 1954 Charles C Thomas)

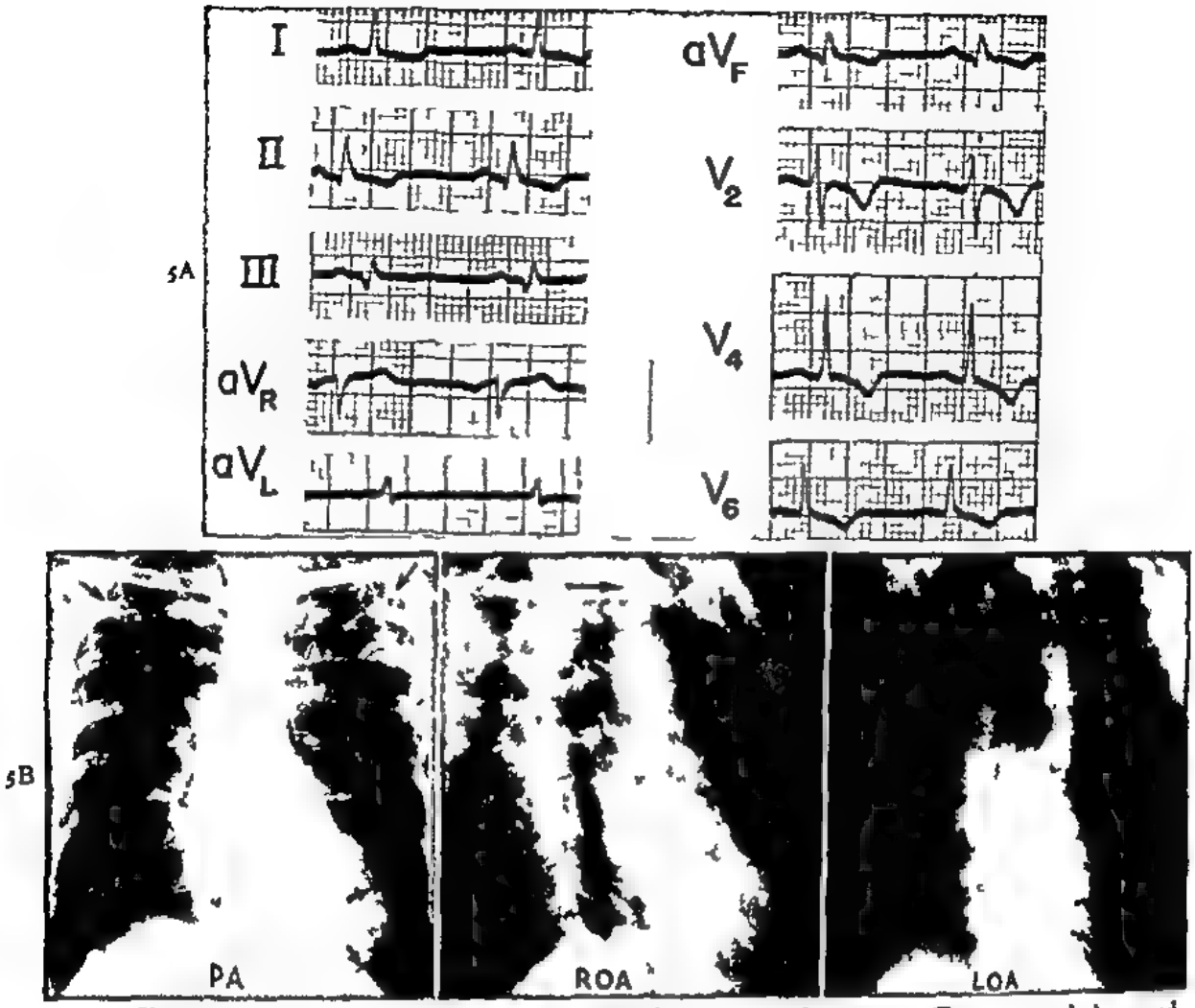

FIG 5 Chronic constrictive pericarditis A electrocardiogram reveals negative T waves and decreased voltage of QRS complexes B x rays reveal chronic tuberculous pericarditis with bilateral apical lung involvement Arrows point to calcification

cause (Fig 5B) Yet pleural adhesions or effusions are fairly common When the constricting pericardial scar is localized mainly over the left auricle, relaxation and filling of this chamber may be seriously interfered with Constriction around the pulmonary vein orifices may result in marked pulmonary engorgement[7] Dyspnea may be due to extensive pleural effusions, pulmonary congestion or decreased vital capacity owing to marked elevation of the diaphragm by ascites The vital capacity was reduced up to 68 per cent of normal in the cases reviewed by Stewart and Heuer[8] Signs of cardiac fixation and evidences of the right heart failure syndrome comprise the cardiac findings The electrocardiogram is characteristic (Fig 5A)

Medical treatment is of little avail when signs of cardiac or pulmonary embarrassment appear Dramatic improvement occurs following decortication of the heart This was first practiced by Cutler as far back as 1924 Streptomycin, PAS and isonicotinic acid derivatives are of value in the treatment of active tuberculous lesions

SYPHILIS

It has been estimated that a quarter of a million Americans have cardiovascular syphilis yet only 2 per cent of these develop aneurysm[9] The unfavorable prognosis of cardiovascular syphilis is well known Aortic valvular lesions are generally considered to be more serious than mitral lesions because they are often caused by neglected syphilis and because of

he poor prognosis When left ventricular ailure ensues pulmonary edema is rapid and latively unresponsive to therapy Syphilitic yocarditis is equally difficult to treat in the age of congestive failure

Saccular aneurysms may reach alarming proportions and may produce symptoms and signs of compression of the lungs bronchi and other structures depending on the direction and extent of their dilation (Fig 6) Aneurysms of the arch are most important because of their greater proximity to respiratory structures Pulmonary signs of atelectasis bronchiectasis and secondary infection may result Tracheal tug may be elicited and left recurrent laryngeal nerve compression may result in hoarseness or aphonia Phrenic nerve involvement may produce paralysis of the diaphragm thereby interfering with oxygenation

The most important of these complications is *atelectasis* Unless the pathologic condition is sufficiently extensive tactile fremitus may be normal revealing no Diminished breath sounds and altered resonance on percussion may be noted Bronchiectasis may ensue from lack of drainage and infection induced by bronchial compression

Endobronchial tumors and other lesions must be differentiated occasionally Bronchography may reveal the true cause of localized obstruction or distortions of the bronchial tree Tomography may exclude endobronchial tumor by delineating cavitation within the aneurysmal mass This is unreliable when the aneurysm is clotted Kymography may show typical expansile pulsations when the aneurysm is unclotted Further differentiation of adenoma, carcinoma and inspissated mucous or granulomatous tissue rarely requires cautious bronchoscopy biopsy or Papanicolaou staining of sputum for tumor cells Serology is positive in approximately 85 per cent of cases Calcification in the wall of the ascending aorta (left anterior oblique view) is characteristically found in approximately half of all cases of luetic aortitis

Antibiotics now have a definitely established position in the treatment of cardiovascular syphilis Aneurysms have been wired and electrocoagulated or surrounded by various cellophanes In certain instances continuity of blood flow may be obtained by the use of vascular grafts

MYOCARDIAL INFARCTION

This condition has already received the direct attention of surgeons Not only are a number of surgical procedures available pertaining to revascularization of the heart but also excision of large myocardial scars and aneurysms is being practiced presently

A number of pulmonary complications is possible in patients suffering from myocardial

infarction They are mistakenly referred to as 'pneumonia' in most instances Five conditions must be considered when lung findings appear following this condition

Pulmonary Edema This dire pulmonary complication is due to acute left ventricular failure, since the left ventricular musculature is most commonly affected by infarction It may be the dominant manifestation of an acute myocardial infarct appearing suddenly within hours to days following an occlusion

Symptoms include thoracic oppression dyspnea orthopnea and cough The attack may be characterized by episodes of paroxysmal nocturnal dyspnea with wheezing respirations and rhonchi Mild pulmonary congestion is common when the dominant manifestation is pain shock or congestive heart failure Basal rales are heard in such cases especially on the right side It may become more severe with noisy respirations when copious white or pink foam appears In advanced cases it may pour out of the oronasal passages and bubbling rales may become audible up to the apices Digitalis oxygen morphine and atropine diuretics and antifoaming agents are employed[8] Anticoagulants are also employed since they affect the ultimate prognosis

Atelectasis It is very common to find a localized patch or patches of crepitant rales at the left lung base coinciding with x ray demonstration of plate like areas of atelectasis However this is found so frequently early in the attack that it is usually considered normal by Wolff and not necessarily indicative of conges [illegible] ig li cates the presence of atelectasis Oxygen and expectorants may be of value in such cases Rebreathing is obviously contraindicated following myocardial infarction

Pneumonia Pneumonia is rarely associated with acute myocardial infarction and yet this diagnosis is made with alarming frequency and treated as such The possibility of other lesions such as localized pulmonary edema pulmonary infarction atelectasis or chronic bronchiectasis must be investigated When there is leukocytosis hyperpyrexia and mucopurulent sputum a therapeutic trial with an antibiotic is indicated

Localized Pulmonary Edema This complication is not uncommon in acute myocardial infarction and is usually bilateral The condition is commonly confused with pneumonia or pulmonary infarction In addition to dullness or flatness and bronchial breathing a shower of fine inspiratory rales is frequently heard The clinical course is usually severe with frank hemopty [illegible] Signs of [illegible] patients [illegible]

Pulmon [illegible] may be due to auricular fibrillation peripheral and pelvic venous thrombosis bacterial endocarditis and right sided mural thrombosis owing to myocardial infarction Emboli may enter any part of the pulmonary arterial system although the right base is commonly affected The sudden onset of chest pain cough and bloody expectoration usually heralds this complication Signs include a patch of crepitant rales dullness and bronchial breathing Pleural pain is present in half of the cases but a rub occurs in only 10 per cent of the cases[1] Effusions are usually minimal and may be clear or sanguineous On rare occasions large recurrent effusions may dominate the clinical picture These effusions seldom require aspiration The icterus index may be slightly elevated on the second or third day due to absorption The electrocardiogram is diagnostic in a large percentage of the cases but x ray investigation is [illegible] ant coagu [illegible] gation [illegible] from the peripheral or pelvic veins is suspected Inferior vena caval ligation produces peripheral edema which may be quite disabling for long periods

DISSECTING ANEURYSM

There has been a marked improvement in the recognition of dissecting aneurysms during the last decade (Fig 7) This has been occa [illegible] nce of the disease on the [illegible] miting the [illegible] ctor have been generally unsuccessful [illegible] gh medial necrosis is recognized as the most important pathologic factor[1] Pulmonary symptoms are rare in the absence of rupture although cough and hemoptysis may occur When not instantly fatal various clinical syndromes may appear depending on the site and extent of dissection or rupture

Twenty per cent of all dissections rupture into the left pleural cavity and present the

FIG 7 Dissecting aneurysm Eventual rupture into the left pleural space with massive hemothorax A roentgenogram prior to rupture B injected specimen

characteristic signs of chest fluid is However fluid in the left pleural cavity must be differentiated from tuberculosis circulatory failure (which seldom affects the left side alone) malignancy of the pleura and Meigs syndrome The aspiration of pure bloody fluid is highly significant for dissection Malignancy may reveal characteristic cells in addition and tuberculosis may show organisms on smear or culture On rare occasions ruptures into the right pleural and retroperitoneal space mediastinum and other structures have been described Massive hemoptysis may indicate rupture directly into the trachea bronchi or lung

Blood replacement and pleural aspiration are indicated Enzymatic agents (tryptar® or streptokinase and streptodornase) are capable of liquefying blood clots prior to aspiration Surgical repair of the site of rupture may be attempted by employing gelatin sponge cuffs or by applying polythene cellophane (PT 300) Occasional cases are known to heal spontaneously

NEOPLASMS

Although primary tumors of the heart are relatively rare metastatic lesions are not uncommon Metastatic lesions may arise from any tissue in the body the most common sources being the trachea breast lung and stomach On rare occasions they may produce the syndrome of chronic constrictive pericarditis Primary neoplasms occur approximately once in every 2 000 cases that come to autopsy [4] The frequency of types has been reported in the following order myxoma sarcoma rhabdomyoma fibroma lipoma angioma cystoma papilloma teratoma and epicardial epithelioma Any heart chamber may be the site of neoplasm but the right side is more commonly involved Therefore pulmonary metastases from primary cardiac malignancies are frequently found

Diagnosis of a primary lesion should be suspected in cases of heart disease of undetermined etiology when (1) roentgenogram shows an unexpected or bizarre heart size or shape (2) there are progressive electrocardiographic changes otherwise unexplained (3) pericardial aspiration reveals red cells and tumor cells and (4) frequently changing arrhythmias and murmurs appear Pedunculated intracardiac tumors may produce intermittent obstruction of valve orifices and simulate valvular lesions The subsequent appearance of metastatic pulmonary lesions with or without pleural involvement should increase the index of suspicion

FIG 8 Syphilis with malignancy in a sixty one year old man Note aneurysmal dilation of thoracic aorta and large bronchogenic carcinoma invading mediastinum with metastases to right upper lung field Autopsy corroboration

FIG 9 Kyphoscoliotic heart disease Marked rachitic spinal deformity in fifty-eight year old woman Severe exertional dyspnea Note spinal curvature toward right eventually producing chronic cor pulmonale Note prominent pulmonary vessels atelectasis at bases with compensatory emphysema

This is especially true when pleural transudates also contain tumor cells or when stained bronchial secretions reveal tumor cells of noncarcinomatous origin (Fig 8)

Treatment may be effective when the tumor is benign and pedunculated Such tumors have been removed from within the heart (Beck, Bailey) The development of a good mechanical heart will permit more extensive surgery Radiotherapy and chemotherapy have produced no known cures thus far, although life may be prolonged in some cases of malignant lymphoma Urethane nitrogen mustard and certain radioactive isotopes have proven of some benefit in appropriate cases

CHRONIC COR PULMONALE

Chronic cor pulmonale is a term applied to hypertrophy of the right ventricle, with or without congestive heart failure Despite a varied etiology which includes a number of pulmonary (Table I), cardiac (Table II) and vascular distrubances (Table III), and bony cage deformities (Table IV), increased resistance and pressure in the pulmonary circuit is the basic mechanism [7] It is significant that when congestive failure supervenes, other pulmonary findings become superimposed on the underlying lung disease process (e g, pulmonary emphysema and other bronchopulmonary diseases)

Kyphoscoliosis, funnel chest and other chest deformities are interesting in that they may also cause hypertrophy and dilation of the right ventricle It is the consensus that the syndrome occurs in about 75 per cent of cases of severe kyphoscoliosis (Fig 9) These deformities may also produce compression atelectasis *or secondary emphysema in addition* to bronchopulmonary infections

The diagnosis of chronic cor pulmonale is based upon the recognition of the underlying causative factor (Tables I to IV) and the discovery of right ventricular enlargement with or without evidences of failure Right sided *failure is recognizable by* the presence of hepatomegaly, dependent edema and ascites elevated venous pressure and prolonged arm to lung circulation time It is important to remember that dyspnea and cyanosis are usually due to the underlying lung or heart disease but may be aggravated in the presence of congestive failure

Roentgenologic studies show (1) an exaggeration of the hilar markings due to enlargement of the pulmonary artery and its major branches (2) enlargement of the right ventricular outflow tract in the left anterior oblique view as

ind
int
pos
ventricle on the retrosternal space; and (3) prominence of the pulmonary segment in the postero-anterior view. (Fig 10A) When decompensation intervenes, (1) the right auricle may become enlarged, (2) there is enlargement of the right ventricular inflow tract as well, (3) the transverse diameter of the heart is further increased in size, (4) the lower lung fields reveal congestive changes or fluid Electrocardiograms show a progressive right ventricular strain pattern (Fig 10B) Pulmonary function tests are employed in the evaluation of the lung status The vital capacity is markedly diminished Dyspnea is out of all proportion to the cardiac state and is mainly due to the associated pulmonary disease

Treatment must be directed at the causative lesion as well as myocardial insufficiency In many disorders, such as kyphoscoliosis, it is unsatisfactory In others, such as patent ductus arteriosus, early surgical intervention results in complete relief When dyspnea and cyanosis occur due to either cardiac or pulmonary fac-

TABLE I
DISEASES OF THE LUNG PARENCHYMA*

1 *Infections*
Acute pneumonitis, chronic bronchitis, bronchiectasis, chronic bronchopulmonary suppuration various virus and rickettsial diseases
2 *Infectious Granulomas*
Tuberculosis, sarcoidosis, fungus infections
3 *Parasitic Diseases*
Chagas disease and schistosomiasis are excellent examples
4 *Allergies*
Bronchial asthma and allergic bronchitis (with secondary emphysema)
5 *Chemical and Physical Irritants*
Dusts fumes, gases, x ray and radium fibrosis (Included are the various pneumoconioses of which silicosis, anthracosis and beryllosis are the most important)
6 *Malignancies*
Extensive primary or metastatic malignancies (Metastatic endolymphatic carcinoma is the most common cause)
7 *Miscellaneous Diseases*
Pulmonary amyloidosis (primary systemic and secondary forms), pulmonary fibrosis and emphysema due to various causes, congenital cystic lung disease massive pulmonary collapse extensive pleural adhesions chronic passive congestion (secondary sclerosis)

* Tables I to IV from REICH N E The Uncommon Heart Diseases Springfield Ill, 1954 Charles C Thomas

TABLE II
PRIMARY HEART DISEASES

1 Mitral valve involvement
   a Mitral stenosis
   b Lutembacher's syndrome (mitral stenosis with interauricular septal defect)
   c Subacute bacterial endocarditis
2 Left ventricular failure due to myocardial infarction, amyloid disease, beriberi, etc, but most frequently due to aortic disease or hypertension (None of these will show right axis deviation but may have pulmonic hypertension right ventricular hypertrophy and failure)
3 Auricular fibrillation (with right auricular thrombus producing pulmonary emboli)
4 Chronic constrictive pericarditis affecting the left auricle
5 Tumor of heart causing mural thrombi and pulmonary embolism
6 Congenital defects (patent ductus septal defects aberrant pulmonary veins)

TABLE III
DISEASES OF THE PULMONARY VASCULAR SYSTEM

1 *Pulmonary Arteries*
   a Embolism
      (1) Phlebothrombosis and thrombophlebitis of the peripheral, abdominal and pelvic veins and the venae cavae (Thromboembolic complications due to myocardial infarction are considered under primary heart disease)
      (2) Embolism due to air, fat and foreign bodies (bullets, etc)
   b Endarteritis obliterans (Ayerza's disease)
   c Aneurysm (syphilis, congenital post stenotic)
   d Thrombosis due to blood dyscrasias
   e Persistent truncus arteriosus
   f Thromboangiitis obliterans lupus erythematosus disseminatus polyarteritis nodosa
   g Congenital and acquired intravascular bands
   h Primary neoplasms of the pulmonary vascular system
   i Neoplastic invasion or compression of larger branches
2 *Pulmonary Veins*
   a Massive infectious endophlebitis
   b Thrombophlebitis migrans
   c Neoplastic invasion or compression of large branches
   d Thrombosis due to blood dyscrasias
   e Aberrant pulmonary veins

TABLE IV
THORACIC BONY CAGE DEFORMITIES

1 Congenital deformities of the chest (funnel or pigeon breast)
2 Kyphoscoliosis due to neuromuscular diseases (e g, poliomyelitis) and bone diseases (e g, rickets)
3 Thoracoplasty
4 Ankylosing spondylarthritis

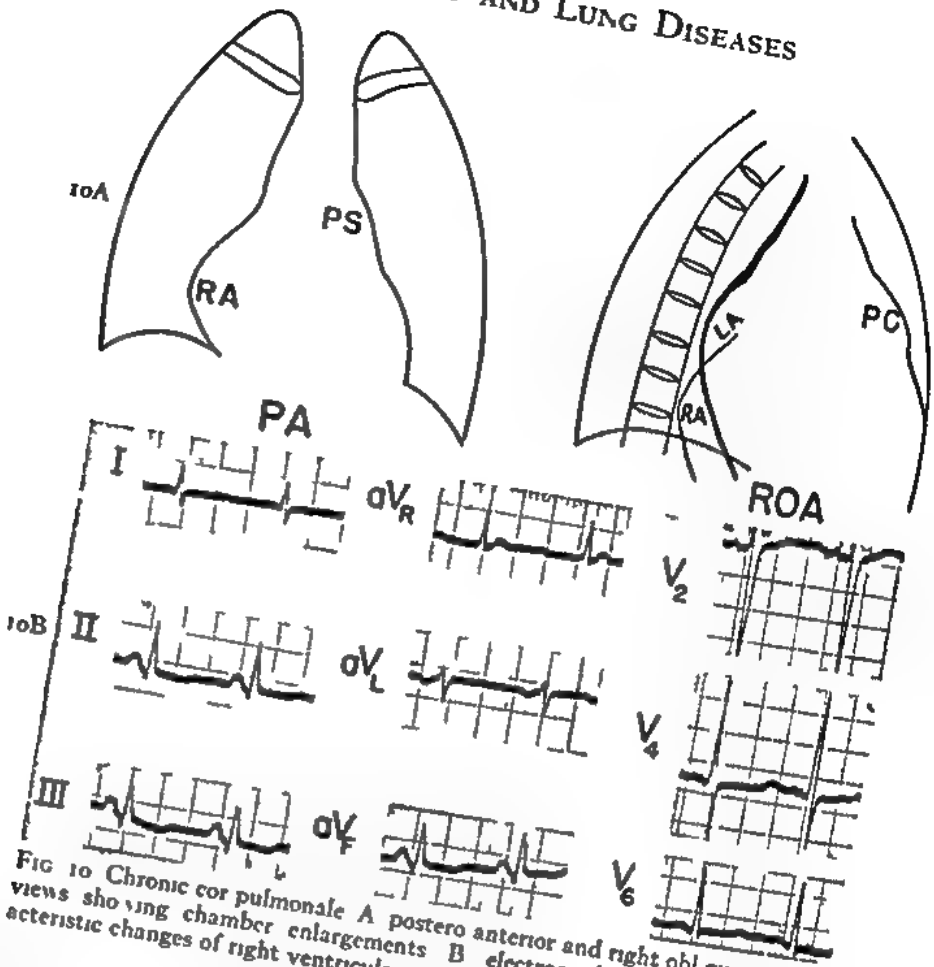

FIG 10 Chronic cor pulmonale A postero anterior and right obl que anterior views sho ving chamber enlargements B electrocardiogram reveals char acteristic changes of right ventricular strain pattern

tors oxygen therapy is indicated Digitalis produces equivocal results in this type of failure but should be given a therapeutic trial Venesection may prove beneficial in the pres ence of high plasma and cell volumes Anti biotics are indicated in the presence of un derlying or intercurrent bronchopulmonary infections Morphine is definitely contraindi cated since it depresses respiratory activity New types of surgical anastomoses are being advocated to relieve pulmonary engorgement in some cases pulmonary to azygos veins (Swan) and various operations for mitral stenosis Orthopedic conditions require correction

SUMMARY

1 The appearance of pulmonary findings during the course of many heart diseases must be evaluated carefully for proper diagnosis, prognosis and therapy

2 Pulmonary complications may appear following certain congenital cardiac defects acute and chronic inflammations of the heart and aorta degenerative lesions of the coronary arteries and aorta, primary neoplasms of the heart and chronic cor pulmonale

REFERENCES

1 REICH N E D seases of the Aorta Springf eld 1949 Cl arles C Thomas
2 NEUHAUSER, E B D Roentgen d agnos s of double aortic arch and otl er anomalies of the great vessels Am J Roentgenol 56 1 1946
3 GROSS R E Surg cal Treatment for Abnormal ties of the Heart and Great Vessels Springf eld Ill 1947 Charles C Thomas
4 ABBOTT M E Atlas of Congen tal Card ac D sease New York 1936 Amer can Heart Associat on
5 REICH N E Protean manifestations of acute rheu matic fever Am Pract 12 645 1947 Acute rheumatic fever in uncommon sites Am Pract., 2 328 1951
6 (a) REICH N E Tl e use of 2-ethylhexanol in acute pulmonary edema Dis of Chest 23 43 1953
(b) REICH N E ROSENBERG B A and METZ, M A new therapy for acute pulmonary edema New York State J Med 52 2647 1952
7 TOWLIN C E et al Recurrent nature of acute benign pericard tis J A M A 149 1215 1952

8 REICH N E et al The Uncommon Heart D seases Springfield Ill 1954 Charles C Thomas
9 STEWART H J and HELLER G J Chron c con strictive pericard t s dynamics of circulat on and results of surg cal treatment *Arch Int Med* 63 504 1939
10 REICH N E Method of applying flask to chest in tract le fremitus *New York State J Med* 39 1654 1939
11 WOLFF L D agnostic impl cat ons of pericard al pleural and pulmonary involvement in card o vascular disease *New England J Med* 244 965 1951
12 SAGALL E L et al Cl nical syndrome in patients with pulmonary embolism *Arch Int Med* 76 234 1945
13 REICH N E Dissecting aneurysm of the aorta a clinico-pathologic correlat on of 19 cases *Clinics* 3 346 1944
14 LYMBURNER R M Tumors of the heart histo-pathological and cl n cal study *Canad M A J* 30 368 1934

VI. EDEMA AND HEMORRHAGE

21

Pulmonary Edema

E J Beattie M D, *Chicago, Illinois*

Pulmonary edema occurs when serous fluid escapes from the pulmonary capillaries into lung tissue, alveoli, bronchioles and bronchi

The clinical picture of pulmonary edema may vary greatly and its recognition is of great importance to the internist In its mildest forms pulmonary edema is readily confused with bronchial asthma Insomnia may be the only symptom As the degree of pulmonary edema worsens, the diagnosis may become more obvious But the differentiation of pulmonary edema from other cardiorespiratory problems may be difficult

Acute pulmonary edema as a complication of surgery is found relatively infrequently at the present time, except in certain patients undergoing cardiac surgery Since pulmonary edema is a very serious complication every effort should be made to prevent its occurrence

Edematous lung tissue is voluminous and heavy, and it will pit when pressed The alveoli and bronchi of the edematous lung contain serous or blood tinged fluid which can be expressed from the cut surface of the lung

Lymph fluid is formed by fluid transuded from the pulmonary capillary into the wall of the alveolus Fluid transuded from the pulmonary capillary can be removed by the lymphatic collecting ducts or the fluid can move into the alveoli and bronchioles and then be expectorated The pulmonary capillaries can reabsorb water and electrolytes but not plasma proteins

RESULTS OF STUDIES

Drinker demonstrated that pulmonary edema develops when lymph fluid forms in the lung faster than it can be removed by the lymphatic system The osmotic pressure of 25 to 30 mm of mercury exerted by the plasma proteins exerts a stronger force to retain fluid in the pulmonary blood vessels than the hydrostatic pressure of 10 mm of mercury tends to transudate fluid into the loose lung parenchyma The negative alveolar pressure on inspiration favors the transudation of fluid from the pulmonary capillaries

Pulmonary edema has been studied from many aspects In the dog Drinker has shown that anoxia will cause an increase in the lymph flow in the lung The fluid is churned to froth in the alveoli and bronchioles thus increasing the anoxia which produces a further leak of fluid from the anoxic pulmonary capillaries. This mechanism is one of the major factors in producing pulmonary edema

By means of cardiac catheter studies Cournand has demonstrated that a considerable increase in pulmonary blood flow can occur in the normal human without change in the pulmonary artery pressure Riley et al demonstrated a decrease in pulmonary artery pressure during exercise by a normal subject The pulmonary artery pressure was found to rise with exercise with no increase in the pulmonary artery blood flow In patients with mitral stenosis and mitral regurgitation (Draper et al) the pulmonary capillary blood pressure was thereby increased and favored the production of pulmonary edema McMichael found that in a normal individual the cardiac output increased 33 per cent when the position was shifted from the erect to the recumbent Liljestrand et al and Nylin found that work caused no increase in heart size and no increase in vital capacity in the normal patient but heart size increased and vital capacity decreased when a normal person shifted from the erect to the recumbent position It has often been stated that pulmonary edema may occur when the left ventricle pumps more blood per minute than the right ventricle, thereby producing pulmonary blood vessel engorgement. Altschule reviewed this problem in 1954 and found no evidence to support this thesis

Eaton found that the lung lymph flow was

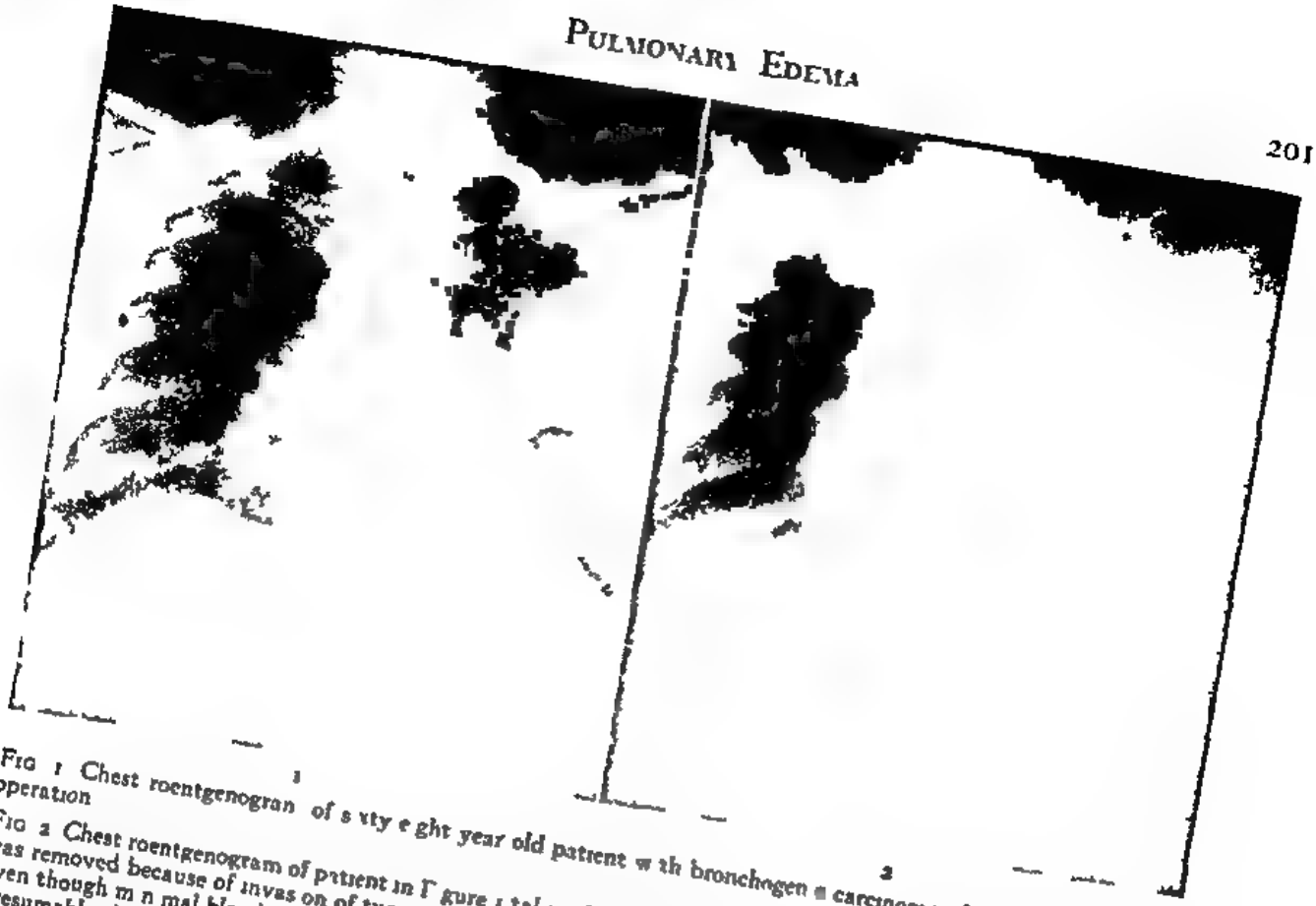

FIG 1 Chest roentgenogram of sixty eight year old patient with bronchogenic carcinoma of the left lung before operation

FIG 2 Chest roentgenogram of patient in Figure 1 taken three days after pneumonectomy Part of the pericardium was removed because of invasion of tumor Intractable pulmonary edema occurred on the first postoperative day even though minimal blood and intravenous fluids were administered Patient died on the third postoperative day presumably due to acute cor pulmonale following pneumonectomy

doubled in forty five minutes following a hemorrhage of 25 per cent of the blood volume in the dog If intravenous saline infusion followed the hemorrhage the lung lymph flow increased markedly but if blood or plasma followed the hemorrhage the lung lymph flow was not elevated Pulmonary edema was found in the dog given excess blood by Beattie et al Altschule et al and Heyer et al showed that intravenous fluids increased heart size and decreased vital capacity Luisada found that intra arterial saline infusions in the normal equal to 230 per cent of the blood volume caused pulmonary edema Pulmonary edema occur with normal or increased body water

I cited the situation in which a normal individual developed acute pulmonary edema following a massive myocardial infarction This is in contrast to the cardiac patient who slowly accumulated excess body water during a period of weeks Edema in the latter instance is probably due to inadequate renal excretion of sodium chloride

In summary the chief factors concerned in the production of pulmonary edema are (1) increased pulmonary capillary permeability usually due to anoxia (2) increased hydrostatic pressure in the pulmonary capillaries and (3) decreased osmotic pressure of the blood The tendency of the nephritic patient with lowered serum proteins to develop pulmonary edema is well known Excess intravenous fluid will exert some of its adverse effects by diluting the blood proteins Altschule has suggested in additional three factors which may be important in the increased transudation of lymph fluid in the lung (1) bronchospasm (2) increased pulmonary blood flow and (3) increased filtering areas in the lungs

ETIOLOGY

Conditions producing passive pulmonary congestion were classified by Lombardo as follows (1) Conditions producing mechanical interference with left ventricular filling for example mitral stenosis tamponade an intrinsic mass in the left atrium and an extrinsic mass compressing the left atrium or pulmonary

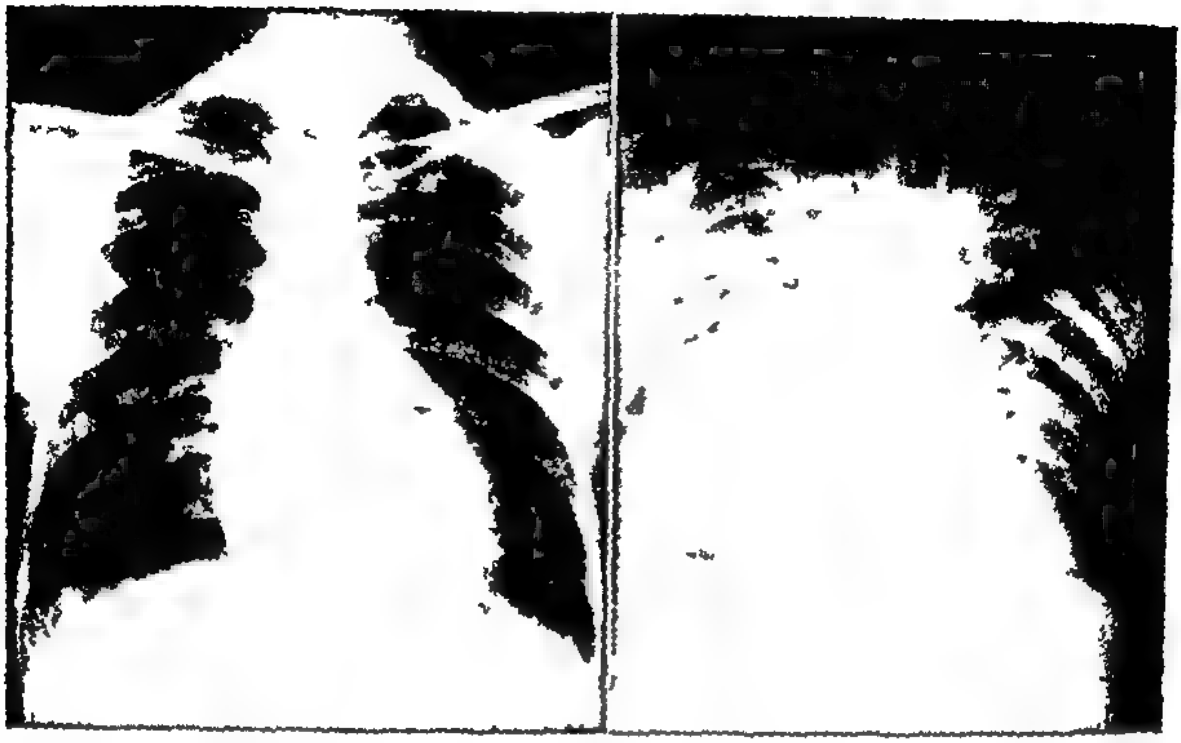

3 4

FIG 3 Chest roentgenogram of cardiac patient before going into acute pulmonary edema

FIG 4 Chest roentgenogram of patient in Figure 3 in acute pulmonary edema

veins (2) Conditions weakening the left ventricle, including structural disorders such as infarction and inflammation, or functional disorders such as anoxia or tachycardia (3) Con

insufficiency and thyrotoxicosis

Pulmonary edema results from an imbalance

SYMPTOMS AND SIGNS

Pulmonary edema can be recognized clinically by (1) onset, gradual or sudden, (2) oppression or pain in the chest, (3) apprehension (4) dyspnea or orthopnea, (5) incessant short cough with copious frothy or blood tinged sputum, (6) pallor (7) perspiration (8) rales throughout lungs, (9) blood pressure and pulse rate elevated in severe cases (10) blood pressure depressed in severe cases

The clinical picture of pulmonary edema varies with the severity of the attack Paroxysmal dyspnea occurs in the patient with hypertension coronary disease or aortic valvular disease This is acute pulmonary edema in mild form A moderately severe form of pulmonary edema can be recognized as cardiac asthma This edema is characterized by asthmatic-type rales in the lungs An associated bronchospasm with this clinical syndrome has been found by Heyer and Plotz The most severe form of edema is clinically recognized as acute pulmonary edema (Figs 1 to 4)

Pulmonary edema may begin gradually or suddenly The patient may complain of op-

have moist rales throughout his lungs pulse rate and blood pressure will be increased in less severe cases but the blood pressure will be decreased in severe cases

TREATMENT

The appearance of acute pulmonary edema is a very serious complication and carries with it a high mortality rate Sonne and Hilden reported in forty two patients with acute pulmonary edema that the systolic blood pressure was above 190 mm of mercury in 73 per cent In this group three patients died In 23 per cent of the cases the blood pressure was under 90 mm of mercury systolic, and in this group three of four patients died Since pulmonary edema is such a serious complication, every effort should be made to prevent its occurrence

The principles of prophylaxis and therapy employed by the internist and those employed by the surgeon operating upon a patient prone to develop pulmonary edema will not be dissimilar However, there may be sufficient blood loss during surgery that administration of blood transfusion to the surgical patient may be necessary whereas the internist would be much less likely to use whole blood as therapy The only exception would be the administration of blood to a patient who developed pulmonary edema secondary to an anemia

The patient to undergo surgery should be examined to note whether a condition exists which predisposes toward pulmonary edema The edematous patient should be rid of his edema Serum proteins, serum electrolytes and hematocrit should be normal Digitalization should be used when needed If the patient be operated upon, a clear airway must be maintained during the operation and in the convalescent period Good intratracheal anesthesia, proper aspiration and an effective cough are most important Bronchoscopy and less often tracheotomy may be necessary The lungs must be kept expanded and atelectasis and pneumonia prevented Postoperatively the patient should turn hourly, and deep breathing and early mobilization should be encouraged

A high concentration of oxygen should be used during the operation with sufficient tidal volume to wash out the carbon dioxide To prevent cardiac arrest anesthesia should be avoided Oxygen should be administered postoperatively

The blood lost during the operation or in the postoperative period should be replaced cubic centimeter for cubic centimeter as the blood is lost If an increased blood volume already exists (as in mitral stenosis) or pulmonary edema is anticipated, the patient will benefit from a blood loss up to 500 cc The patient should never receive more blood than he has lost A damaged heart tolerates an excess of blood very poorly and serious damage may result from a 500 to 1,000 cc overtransfusion If a patient with an increased blood volume is also anemic, it is preferable to give the patient red blood cells without plasma

Intravenous fluids should be administered with caution during surgery and in the postoperative period In general, sufficient saline solution should be given to replace the saline lost Usually salt is retained in the body in the first few days postoperatively so that 500 cc of isotonic saline per twenty-four-hour period should not be exceeded The serum electrolytes and urinary chloride can be measured to estimate the need for sodium chloride If a surgeon restricts saline infusions, he must also be careful not to administer excess glucose solutions intravenously If a patient on a restricted sodium chloride intake receives relatively large amounts of parenteral glucose solutions, the total body water may be increased causing a relatively low sodium concentration This condition (water intoxication, hyponatremia) may have serious results if not recognized and treated It will usually be necessary to administer concentrated sodium chloride In the patient prone to develop pulmonary edema this sequence of events will not be beneficial, and it would have been better to re-establish early administration of oral fluids

If pulmonary edema is feared it is best to elevate the head of the patient as soon as possible This tends to lower the venous return to the right heart and to decrease the output of the right ventricle

If acute pulmonary edema occurs, prompt treatment is essential The head of the patient should be elevated to reduce the venous return to the heart Intermittent tourniquets to the extremities help trap blood in the extremities, further decreasing the effect of blood volume and venous return to the heart The tourniquets will produce anoxia in the extremity whereby serum will leak from the capillaries and further decrease the defective blood volume A phlebotomy of 500 cc of blood may be life-saving Aminophylline is thought to have a direct relaxant effect on the veins which may help diminish the venous return If the patient is not

digitalized, an intravenous digitalis preparation should be given Morphine, 10 mg, should be administered unless there are specific contraindications Morphine will allay the anxiety of a patient and has additional beneficial effects in pulmonary edema not well understood Churchill and Cope found that lungs engorged with blood produced a reflex rise in respiratory rate. It is thought that morphine may have a depressant effect upon the reflexly induced dyspnea

Anoxia must be strenuously treated A snug-fitting face mask should be used with an adequate flow of oxygen Altschule has criticized the use of 100 per cent oxygen, and recommended instead a mask or nasal catheter with an oxygen flow of about 6 L per minute yielding concentrations of 40 to 80 per cent A mask which permits the patient to exhale against an adjustable positive pressure may be helpful at times A positive pressure should start at plus 2 to plus 5 cm of water and the pressure should be lowered 1 cm every one to four hours dependent upon the condition of the patient Excessive positive pressure will interfere with the circulation of the blood through the lung and thus lower the cardiac output

A clear airway must be maintained, cough and aspiration usually suffice In the unconscious patient with a central nervous system injury tracheotomy may be indicated Foaming of the edema fluid in the airway markedly aggravates the respiratory disease Luisada recommended the use of an antifoaming agent and found that vaporized ethyl alcohol was the most beneficial This can be administered by pumping the oxygen source through an ethyl alcohol vaporizer The beneficial effects may be very dramatic

The aforementioned measures should be promptly instituted for acute pulmonary edema Certain additional measures should be instituted to prevent recurrence of the edema The daily sodium chloride intake should be restricted to as low as 200 mg Mercurial diuretics can be used to increase the sodium chloride excretion but care must be taken not to produce hyponatremia Ion exchange resins can be used to remove sodium from the gastrointestinal tract If pleural fluid is interferring with respiration, it should be aspirated It may be necessary to aspirate fluid from the peritoneal cavity The intake of salt free fluid orally need not be restricted if proper restriction of the daily sodium chloride intake is maintained

REFERENCES

1 ALTSCHULE M D, FREEDBERG A S and MCMANUS M J Effects on the cardiovascular system of fluids administered intravenously in man v Function of cutaneous capillaries and lymphatic vessels *Arch Int Med* 80 491, 1947

2 ALTSCHULE, M D and GILLIGAN, D R The effects on the cardiovascular system of fluids administered intravenously in man ii The dynamics of the circulation *J Clin Investigation*, 17 401 1938

3 ALTSCHULE, M D, GILLIGAN, D R and ZAWICHECK, N The effects on the cardiovascular system of fluids administered intravenously in man iv The lung volume and pulmonary dynamics *J Clin Investigation* 21 365 1942

4 ALTSCHULE, M D Acute Pulmonary Edema New York, 1954 Grune and Stratton

5 DOYLE, J T, WILSON, J S, ESTES E H and WARREN, J V The effect of intravenous infusions of physiologic saline solution on the pulmonary arterial and pulmonary capillary pressure in man *J Clin Investigation*, 30 345 1951

6 DRINKER C K Pulmonary Edema and Inflammation Cambridge, 1945 Harvard University Press

7 ELLIS, L B, BLOOMFIELD R A GRAHAM G R, GREENBERG D J, HULTGREN, H N, KRAUS, H, MARESH, G MEBANE, J G, PFEIFFER, P H, SELVERSTONE, L A and TAYLOR, J A Studies in mitral stenosis i The correlation of physiologic and clinical findings *Arch Int Med* 88 515 1951

8 GOLDMAN, M A and LUISADA A A Alcohol oxygen vapor therapy of pulmonary edema results in fifty attacks *Ann Int Med* 37 1221 1952

9 HARRISON, W G, JR. Cerebral spinal fluid pressure and venous pressure in cardiac failure and the effect of spinal drainage in the treatment of cardiac decompensation *Arch Int Med* 53 782 1934

10 HARRISON, T R CALHOUN, J A CULLEN G E, WILKENS, W E and PILCHER C. Studies in congestive heart failure *J Clin Investigation* 11 133 1932

11 HEYER, H E Abnormalities of the respiratory pattern in patients with cardiac dyspnea *Am. Heart J* 32 457, 1946

12 HEYER, H E, HOLMAN J and SHINES, G T Changes in the efficiency and dynamics of respiration in experimental congestion of the lungs. *J Clin Investigation* 26 1185, 1947

13 HILDEN, T On the pathogenesis of acute pulmonary edema *Acta med Scandinav Suppl.*, 234 162 1949–1950

14 LILJESTRAND G E LYSHOLM, E and NYLIN G The immediate effects of muscular work on the stroke and heart volume in man *Scandinav Arch f Physiol*, 80 265, 1938

15 LILJESTRAND, G Regulation of pulmonary arterial blood pressure *Arch Int Med*, 81 162, 1948
16 LOMBARDO, T A and HARRISON, T R Cardiac asthma *Circulation*, 4 920, 1951
17 LUISADA, A A Therapy of paroxysmal pulmonary edema by antifoaming agents *Circulation*, 2 872, 1950
18 LUISADA, A A and CONTRO, S Experimental pulmonary edema following rapid carotid infusion mechanism and therapy *Circulation Res*, 1 179 1953
19 MCGUIRE, J, WESTCOTT, R N and FOWLER, N O Anoxia and human pulmonary vascular resistance *Tr A Am Physicians* 64 404 1951
20 MCMICHAEL, J and SHARPEY SCHAFER, E P Cardiac output in man by a direct Fick method *Brit Heart J*, 6 33, 1944
21 NYLIN, G The relation between volume and stroke volume in recumbent and erect position *Arch f physiol* 69 237 1934
22 NYLIN G On the amount of and change in, the residual blood of the heart *Am Heart J*, 25 598, 1943
23 OPDYKE, D F, DLOHARCO J, DILLON R H, SCHREIBER, R C and LITTLE, R D Study of simultaneous right and left atrial pressure pulses under normal and experimentally altered conditions *Am J Physiol*, 154 258, 1948
24 PAINE, R BUTCHER, H R, SMITH J R and HOWARD F A Observations on the role of pulmonary congestion in the production of edema of the lungs *J Lab & Clin Med*, 36 288, 1950
25 PAINE, R, HOWARD, F A BUTCHER, H R and SMITH, J R Observations on pulmonary lymph flow and edema *Federation Proc*, 8 123, 1949
26 PERERA, G A and BERLINER, R W The relation of postural hemodilution to paroxysmal dyspnea *J Clin Investigation*, 21 626, 1942
27 PLOTZ, M Bronchial spasm in cardiac asthma *Ann Int Med*, 26 521, 1947
28 RILEY, R L, HIMMELSTEIN A, MOTLEY, H L, WEINER, H M and COURNAND A Studies of the pulmonary circulation at rest and during exercise in normal individuals and in patients with chronic pulmonary disease *Am J Physiol*, 152 372, 1948
29 SONNE, L and HILDEN, T Clinical aspects of cardiac asthma and acute pulmonary edema with special reference to blood pressure *Acta med Scandinav* 138 354, 1950
30 SQUIRES, R D, CROSLEY, A P, JR and ELKINTON, J R The distribution of body fluids in congestive heart failure III Exchanges in patients during diuresis *Circulation*, 4 868, 1951
31 STEAD, E A HICKAM J B and WARREN, J V Mechanism for changing the cardiac output in man *Tr A Am Physicians*, 60 74, 1947
32 STEAD, E A and WARREN, J V Cardiac output in man *Arch Int Med*, 80 237, 1947
33 STEAD, E A Renal factor in congestive heart failure *Circulation*, 3 294 1951
34 WARREN, J V, WEEMS H S and STEAD, E A Effect of increasing blood volume and right atrial pressure on the circulation of normal subjects by intravenous infusions *Am J Med*, 4 193 1948

22

Pulmonary Hemorrhage

EDWARD F. PARKER, M D, Charleston, South Carolina

From the Roper Hospital and Department of Surgery of the Medical College of South Carolina Charleston, South Carolina

PULMONARY hemorrhage in the sense in which it is used in this discussion may be defined as hemoptysis originating in the lower respiratory tract which consists of the pulmonary parenchyma, the bronchi and trachea Hemoptysis is defined as the expectoration of blood, regardless of its source Since a patient presenting the complaint of expectoration of blood is usually ignorant of the source of the blood, it is desirable to consider all causes of hemoptysis in a discussion of the subject of pulmonary hemorrhage. A knowledge of all causes is essential in order to determine whether or not the source of bleeding is actually in the lower respiratory tract

Injury or disease of any structure communicating with the naso oro-pharynx and the tracheobronchial tree must be considered in the differential diagnosis of hemoptysis Even the possibility of hematemesis must be kept in mind The patient may be unable to state whether the blood appeared following a cough, vomiting or a clearing of the nose to aspirate any discharge from the nasopharynx Sometimes there is no act such as coughing associated with the appearance of the blood The patient may state that there is merely a sensation of something in the throat, and a simple clearing of it produces the blood

CAUSES

According to most writers the most frequent causes of hemoptysis are tuberculosis bronchiectasis carcinoma, pulmonary abscess and mitral stenosis [1 2] However, there are many other causes and the unusual must always be kept in mind We have seen hemoptysis due to hemorrhage from Wharton's duct in the presence of a stone with no symptoms whatever other than the expectoration of the blood We have also seen hemoptysis from carcinoma of the nasopharynx which defied detection even after many examinations by nasopharyngoscopy

A partial list of the causes of hemoptysis in addition to injuries, may be given best through a classification of pulmonary diseases as presented by King [2] (Table 1)

TABLE 1

A Infections
- 1 Tuberculosis
- 2 Other bacterial
  - Pyogenic, brucellosis and tularemia
- 3 Mycotic
  - Actinomycosis
  - Blastomycosis
  - Coccidioidomycosis and others
- 4 Rickettsial
- 5 Virus
- 6 Parasitic

B Inhalations
- 1 Industrial
  - Silicosis and others
- 2 Other
  - Vomitus and lipiodol
- 3 Thermal

C Neoplasms
- 1 Primary
- 2 Secondary
- 3 Generalized

D Blood diseases
- 1 Leukemia
- 2 Polycythemia
- 3 Sickle cell anemia

E Generalized diseases
- 1 Sarcoidosis
- 2 Loeffler's syndrome
- 3 Rheumatic fever and others

F Fibrosis

G Granulomatosis

H Bronchiolectasis

I Circulatory disturbances
- 1 Pulmonary edema
- 2 Hemosiderosis
- 3 Emboli and infarcts

This classification represents a fairly complete list of pulmonary diseases, but it does not include such diseases as aortic aneurysm or diseases of the esophagus or other structures in the mediastinum which give rise to secondary pulmonary or tracheobronchial disease that may be associated with hemoptysis. It does not include pulmonary vascular diseases such as

arterial aneurysm and arteriovenous fistula Neither does it include the presence of foreign bodies in the tracheobronchial tree or lung or blood dyscrasias

DIAGNOSTIC WORK UP

There are many examinations available at the present time, the use of several of which

TABLE II
DIAGNOSTIC PROCEDURES

1 Routine history and physical examination
2 Routine laboratory studies (blood and urine)
3 Sputum studies
   Character and amount
   Smears and cultures
   Cytological examinations
4 Gastric washings (if no satisfactory sputum available)
   Smears and cultures
5 Fluoroscopy of the chest
6 Roentgenograms of the chest in more than one projection
7 Tuberculin and other skin tests
8 Bronchoscopy
9 Bronchography
10 Rhinoscopy nasopharyngoscopy laryngoscopy
11 Barium swallow upper gastrointestinal series, barium enema
12 Pleural fluid studies
   Character and amount
   Bacteriological examinations
   Cytological examinations
13 Biopsy of lymph nodes
14 Biopsy of pleura
15 Biopsy of lung
16 Angiocardiography and directangiography (aortography)
17 Cardiac catheterization
18 Artificial pneumothorax and pneumoperitoneum
19 Exploratory thoracotomy

usually suffice to establish the diagnosis While a complete history and complete physical examination are absolutely essential in the study of every patient usually one can reach only a tentative diagnosis after their use Nearly always additional examinations are indicated and necessary A complete list of the diagnostic procedures available is shown in Table II

Many of the examinations enumerated are necessary in any given case to ascertain the cause of hemoptysis However it is to be noted that the most basic which are also the simplest for the patient do not require hospitalization These consist of the history and physical examination the sputum and roentgenographic examinations and the cutaneous tests When available examination of the sputum by proper methods and on repeated occasions is of the utmost importance This applies particularly to the diagnosis of fungous tuberculous and neoplastic disease It is possible to establish the unequivocal diagnosis of fungous and tuberculous disease only by bacteriologic methods In recent years it has become possible to establish the diagnosis of carcinoma of the lung by the cytologic method in a high percentage of the cases in which other methods short of exploratory operation and tissue biopsy have failed

It is well to remember that normal roentgenograms of the chest do not exclude the presence of intrathoracic disease Often the diagnosis of bronchiectasis cannot even be suspected from a study of plain films alone Bronchography is essential to determine the presence or absence of bronchiectasis or bronchiolectasis There are also instances of normal roentgenograms occurring in cases with proven carcinoma of a bronchus The neoplasm may not be apparent on a plain x ray film unless it produces a high degree of obstruction of a bronchus In these cases one may actually not see the tumor on the x ray films but rather the evidence of infection atelectasis or more rarely obstructive emphysema beyond the obstructed bronchus

There are observations made on fluoroscopy of the chest which may not be made on roentgenographic studies of the chest alone Of course these concern the motion of the bony thoracic cage the diaphragms the structures in the mediastinum and changes in the degree of aeration of the lungs An attempt to make comparable observations may be made by a study of roentgenographic films made in inspiration and expiration but these should not replace fluoroscopy as a most important method of study

The extreme importance of bronchoscopy in the search for the cause of hemoptysis should be well recognized Bronchography is also necessary in most but not all cases

In cases in which the cause of hemoptysis is at all obscure careful and often repeated endoscopic examinations of the upper respiratory tract are indicated

The roentgenographic studies of the alimentary tract are always indicated when the cause of hemoptysis is obscure when the roentgenograms of the chest are normal or when the possibility of a primary extrathoracic malignant tumor exists Biopsy of readily accessible and often enlarged cervical and axillary lymph

nodes is a most valuable procedure In selected cases biopsy of enlarged mediastinal lymph nodes should be used more often than it is when roentgenograms of the chest are normal except for evidence of mediastinal lymphadenopathy and when all other non-operative diagnostic procedures which are indicated are non contributory or non diagnostic

Adequate and repeated studies of any pleural fluid present are essential Biopsy of the pleura is a simple procedure when the pleural cavity is already obliterated at the site of the operation It may be performed under local anesthesia without resection of a segment of rib In the occasional case it may be the only method by which the correct diagnosis may be established

Biopsy of the lung by needle aspiration is not recommended generally It is used only in cases of obviously inoperable carcinoma in which the tissue diagnosis cannot be established otherwise Biopsy of the lung by open thoracotomy is referred to later as exploratory thoracotomy

Roentgenographic studies of the vascular system have become essential in selected cases These are made by the injection of contrast media either intravenously or intra arterially by needle or by catheter Artificial pneumothorax and artificial pneumoperitoneum as diagnostic procedures are more of historical interest than of practical value today

In an occasional case the pulmonary arterial pressure must be determined by cardiac catheterization The presence or absence of pulmonary hypertension may be a key observation in the consideration of the possibility of the existence of mitral valvular disease

Exploratory thoracotomy has become a diagnostic procedure of the utmost importance It is indicated in cases of possible unilateral intrathoracic neoplasm especially carcinoma with or without hemoptysis in which all non operative and other lesser diagnostic procedures have been utilized to no avail

TREATMENT

The treatment of pulmonary hemorrhage should be directed toward the cause Most often no urgent or immediate treatment is necessary because the bleeding is either never alarming or it ceases spontaneously In other cases usually all that is necessary is the allaying of anxiety and apprehension by the administration of narcotics provided the dosage administered does not lower the normal respiratory rate or depress the cough reflex In cases of severe hemorrhage from the lung if the proper side can be determined artificial pneumothorax may be tried It is believed that it is rarely effective because the degree of collapse of the lung effected is not necessarily associated with decreased pulmonary blood flow, and because the presence of overlying pleural adhesions frequently prevents satisfactory collapse of that portion of the lung in which the hemorrhage is originating Fortunately even massive pulmonary hemorrhages are rarely fatal except in cases of very extensive injury or disease

PROGNOSIS

The prognosis in cases of hemoptysis whether slight or massive varies with that of the disease found to be the cause In many cases however no cause can be found Probably the number of cases with idiopathic hemoptysis is about 10 per cent These deserve extremely careful observation over a period of years Active pulmonary tuberculosis will develop in an occasional case Probably others have bronchiectasis Fortunately most seem to have no recurrence of the hemoptysis thus allowing the diagnosis of probable non specific bronchitis to be made by the process of exclusion

SUMMARY

A brief discussion of pulmonary hemorrhage is presented In particular the possible etiologic factors and the diagnostic technic available for the study of such cases are reviewed

REFERENCES

1 TAYLOR G D Hemoptysis *South M J* 46 11 4 1953
2 PARKER E F Hemoptysis its significance and methods of study *Dis of Chest* 21 677 1952
3 KING D S Roentgenograms of diffuse pulmonary lesions *Am Rev Tuberc* 61 536 1949
4 PRATT THOMAS H R Cytologic diagnosis *South M J* 47 709 1954
5 MORRISCH H J Clinical significance of hemoptysis *J A M A* 148 1461 1952
6 DOUGLAS B F and CARR D T Prognosis in idiopathic hemoptysis *J A M A* 150 764 1952

23

Pulmonary Embolism and Infarction

IRVING S WRIGHT, M D AND WILLIAM T FOLEY, M D, *New York, New York*

PULMONARY embolism is very frequently overlooked or misdiagnosed in clinical practice Surgeons are apt to confuse it with postoperative atelectasis (Case 1) until active thrombophlebitis becomes evident General practitioners are prone to confuse it with virus pneumonia until the patient calls attention to the pain in his leg We have treated two physicians, each of whom had been so diagnosed by their confreres One had "four attacks" before the phlebitis in his saphenous vein was given its proper significance Patients with rheumatic heart disease have been treated for multiple episodes of pneumonia over a period of years until embolization finally has been correctly diagnosed, as in the instance of Case 11 On careful study patients diagnosed as having lung disease proved to have suffered from a myocardial infarction with pulmonary embolism from a mural thrombus

Farmer and Smithwick[1] have reported on 7,343 consecutive surgical admissions In ninety-five of these pulmonary infarction was recognized in twenty five pulmonary infarction was the first indication that phlebitis was present

The terms pulmonary embolism and pulmonary infarction are not synonymous A pulmonary embolism means that a foreign body, most commonly a portion of a thrombus has lodged in a branch of a pulmonary artery with or without changes in the lung tissue supplied by that branch If there is a profound change in the lung tissue which progresses to necrosis, the term infarction is used Emboli in the absence of infarction do not usually produce detectable x-ray changes unless opaque visualization studies are performed If the disturbed area is near the lung surface, however, changes in physical signs will be noted, especially the finding of rales or a pleural friction rub The work of Kjellberg[2] aids in understanding this phenomenon He subjected a series of dogs to artificial pulmonary embolization No roentgenographic changes in the lungs were observed in uncomplicated pulmonary embolism, and no infarction occurred as long as the circulation through the bronchial artery was intact Infarction usually extends to the surface of the lung The irritated pleura reacts by an outpouring of fluid Pleural effusion is thus a frequent finding Blood exudes through damaged capillary walls into alveolar spaces Therefore hemoptysis is a common finding

SYMPTOMS

Pain is often the first and most compelling symptom Two types of pain are encountered (1) that produced by reaction of the pleura overlying the infarction and (2) severe anterior chest pain often indistinguishable from that of myocardial anoxia It sometimes produces "splinting" and difficulty in breathing Some workers believe that this pain is the result of an actual diminution in the coronary flow secondary to the profound disturbances in the local hemodynamics [3,4] Others hold that this is due to pain in the pulmonary artery itself This question has not been settled as yet

Dyspnea is common It is due to the splinting caused by pain

Cough with hemoptysis of slight or marked degree is a most important corroborative sign Without it a diagnosis is very difficult to maintain We have seen patients, however, with convincing evidence of pulmonary embolization without hemoptysis

The emotional reaction may be one of panic and fear of disaster This depends on the patient's whole personality, but the panic reaction is sufficiently common to warrant comment

SIGNS

Fever will depend on the degree of infarction or secondary pneumonitis, and the presence or absence of phlebitis at the site of origin Some fever is usually present and it may be marked

Heart rate and rhythm Tachycardia is present in proportion to the fever Arrhythmias are often present and are responsible for many emboli, especially in rheumatic heart disease Any patient who is fibrillating is a candidate for pulmonary emboli We have seen a patient in normal rhythm have an episode of paroxysmal fibrillation discharge an embolus and revert to normal rhythm in a period of several hours It is our impression that it is the recently formed thrombus or recently propagated new clot superimposed upon the old clot in a heart or vein that embolizes

Stigmata [illegible] the infarct is large enough Over areas of pleural effusion diminished breath and voice sounds will be heard As the effusion increases, flatness develops Careful examination should at least show rales somewhere in the chest to support the diagnosis

FINDINGS

Laboratory Leukocytosis with an increase in polymorphonuclear leukocytes is usually present depending on the presence or absence of phlebitis and pneumonitis The sedimentation rate increases rapidly during the first week

X-ray The presence of a shadow in the lung fields will be found only if some degree of infarction has occurred The shape size and density of the shadow depends on the angle which the infarct makes to the direction of the x rays Thus shadows vary from small, hazy, mottled areas to large, dense segments The classic pie-shaped area while sometimes seen, is not found in the majority of cases Some degree of pleural effusion is usually seen in the x ray films sometime during the course of the illness

Electrocardiographic A large pulmonary embolus by blocking a generous percentage of pulmonary artery flow, produces an increase in pulmonary artery pressure This in turn is reflected in the heart by dilation of the right ventricle and what is termed "right heart strain" The electrical changes are a shift of the axis to the right with clockwise rotation This gives the following changes in the leads

I Deep S, depressed ST
III—Q, elevated ST
aVR—R, elevated ST
aVL—depressed ST, inverted T
aVF—elevated ST
V_1 and V_2—R prominent elevated ST VAT prolonged
V_4 V_5, V_6—ST depressed S marked in V_4 V_6

Variations from this pattern depend on the size and location of the embolus

COMPLICATIONS

Cor pulmonale acute dilation of the right ventricle and pulmonary conus may follow massive pulmonary emboli These changes may produce signs which can [illegible]

[illegible]

[illegible] may also be noted in the second and third interspaces to the left of the sternum The second pulmonary sound may be heard over the area of increased pulsation Gallop rhythm heard best to the left of the sternum may be present

Shock Peripheral circulatory collapse may be present and require emergency measures While we recognize that shock is a variable manifestation most patients we have encountered in shock from pulmonary embolization display cold moist pale hands moist face cyanosis, weak feeble, rapid pulse and hypotension

DIFFERENTIAL DIAGNOSIS

As indicated previously, pulmonary embolism must be kept in mind whenever lung disease is found, otherwise the diagnosis will frequently be missed The development of unexplained hemoptysis tachycardia fever dyspnea cyanosis or jaundice should require the physician to rule out embolization It is most often confused with the following conditions

1 *Pleurisy* Pleurisy is a frequent finding in pulmonary embolism The development of hemoptysis on the second day makes the diagnosis of embolism likely

2 *Pneumonitis* *Viral* The clinical course of virus pneumonia with high fever [illegible] change [illegible]

s
L
n

sputum is usually not the bright red hemoptysis of embolism

3 *Carcinoma* Repeated small emboli may resemble the clinical course of bronchogenic carcinoma. Phlebitis is common in carcinoma. Malignant cells in the sputum is a pathognomonic sign

4 *Congestive Failure.* The sputum in congestive failure is usually rusty, not bright red. The leg edema and cyanosis may resemble that of deep phlebitis Often both conditions are found in the same patient Other findings of cardiac involvement are present, such as enlarged heart, disorders of rhythm, murmurs or increased venous pressure

5 *Atelectasis* Before making a diagnosis of postoperative atelectasis, pulmonary embolus must be carefully considered Often there is an accompanying disc atelectasis secondary to muscle splinting if a pleurisy arises, thus making the differential diagnosis even more difficult.

6 *Mitral Stenosis* The increased pressure in the pulmonary circulation often leads to hemoptysis and may confuse the diagnosis Furthermore, pulmonary emboli are common in mitral heart diseases

PREVENTION AND TREATMENT

In a sense pulmonary embolism may be likened to lightning It strikes most often with great suddenness, and if the patient survives the initial shock, he has a good chance of surviving that particular embolus It is the emboli yet to be delivered that are most to be feared, indeed, many large fatal pulmonary emboli are preceded by small ones As Barker[4] pointed out, if all fatal pulmonary emboli preceded by minor emboli could be prevented, the death rate would be strikingly reduced Autopsy statistics in large series show a rate of 10 per cent pulmonary embolism in this country

For this particular syndrome the best treatment is definitely prevention A review of a large number of case histories has shown that a greater awareness or a more meticulous study on the part of the physician would have alerted him to signs which might have resulted in the initiation of prophylactic measures For example, charts of patients who died from pulmonary embolism have contained notes such as "patient complains of pain in left calf" or "pain in the right groin" or "sudden breathlessness" or a "sharp pain in the right chest" Many other examples could be cited Because these initial signals were of short duration, disappearing within a few days or even hours, their sinister significance was not recognized and steps were not taken to prevent further development of thromboembolic complications As Barnes pointed out fifteen years ago, little could be done except wishful thinking if the pulmonary emboli were arising from the heart If they were arising from the legs, ligation proximal to the site of a recognized thrombophlebitis appeared logical and was the favored method of attack Experience has demonstrated, however, that (1) ligation does not prevent the active thrombophlebitic process from continuing, (2) emboli may and frequently do continue to arise from veins other than those ligated, (3) fatal emboli may arise from thrombi which have formed immediately proximal to the site of ligation even though this may be as high as the inferior vena cava, (4) the late effects of ligation of the femoral, iliac or inferior vena cava veins are often undesirable with serious evidence of venous insufficiency with pain, edema and ulceration Therefore, ligation was found not to be a preventive measure of choice except when it was desirable to eliminate varicose veins, a common site for recurrent thrombophlebitis with secondary emboli

Erb and Schumann[7] reported their experience in 100 cases of fracture of the femur, a condition very frequently complicated by pulmonary embolism Fifty patients were subjected to bilateral femoral vein ligation and fifty were used as controls The mortality rate was not lowered in the surgical group, indeed, the ligation itself was frequently followed by thrombosis in the site proximal to the ligature Pulmonary embolism was increased

That surgical interruption of veins is not a treatment for phlebitis is well illustrated by a patient of ours While in the Army he had a sudden pulmonary embolus Examination disclosed phlebitis in his left leg Left superficial femoral vein ligation was performed In the convalescence from this operation a second pulmonary embolus developed Examination disclosed phlebitis in his right leg This time, in an effort to trap all possible emboli, his inferior vena cava was ligated Subsequently phlebitis developed in his arms and he again

had a pulmonary embolus Since his physician did not wish to tie off the superior vena cava, he was referred to us for long term anti coagulant therapy There have been no further emboli during a period of six years

The advent of anticoagulant drugs permitted a new approach to the problem, which is actually based on the fact that under certain conditions the blood clots too easily and pieces of the original clot break off and travel to the lungs If the original clot could be prevented from forming no such problem would ever arise If such a clot, once formed, could be contained as a small process and allowed to seal itself off instead of propagating a tail which could break loose, the risk would be markedly lessened If emboli once delivered could be prevented from propagating and blocking off more branches of the pulmonary arterial tree, the risk to life would be decreased All of these accomplishments are theoretically possible with the perfect anticoagulant used correctly under favorable conditions All of them have been achieved in varying degree, and often with striking success with the pres ently available anticoagulants Many studies have demonstrated a striking reduction in mortality and morbidity when anticoagulants have been used either prophylactically prior to the first pulmonary embolus or even after the first embolus in the prevention of sub sequent ones.

A summary of the results of several large series of patients with postoperative thrombophlebitis shows the following Once thrombophlebitis has been recognized in the absence of anticoagulant therapy, the risk of pul monary embolism ranges from 4 to 60 per cent Of those patients who have one embolus the risk of death from a subsequent embolus is approximately 20 per cent In contrast, patients with postoperative thrombophlebitis who receive adequate anticoagulant therapy suffer from pulmonary emboli in less than 5 per cent, and the mortality rates are under 1 5 per cent [8] These are indeed striking figures They have been duplicated with heparin, heparin and the coumarin derivatives com bined and the coumarin derivatives alone In obstetric cases[9] the incidence of pulmonary embolism following untreated thrombophlebitis has been reported as ranging from 15 to 35 per cent with a mortality rate of 3 to 5 per cent This low mortality may be associated with the finding of the Committee on Anticoagulants[10] that while the younger patients had nearly as many emboli as older patients, the mortality rate was much lower, probably because of their ability to stand the reaction or shock. In addition, it is probable that more of the pulmonary emboli in obstetric patients arise from pelvic veins of smaller caliber and hence are less likely to be fatal

While it appears that once a thrombus or a pulmonary embolus has been recognized anti coagulant therapy is the most important form of therapy, certain other measures should be borne in mind

When carrying on a physical examination of the chest the physician should scrupulously avoid having the patient inhale deeply or cough since such maneuvers increase the nega tive venous pressure, thus developing a most favorable condition to suck loose the tail of a clot which may then travel into the lungs Deaths have occurred directly following such maneuvers The patient must be warned against straining at stool thus producing a Valsalva experiment following which the hemodynamic pressures are markedly dis turbed In one series 20 per cent of the deaths from pulmonary embolism were reported as occurring at stool The physician must provide adequate laxatives to prevent this situation

As discussed elsewhere, the acute reaction of pulmonary embolism has been thought to be due in part to spasm of the artery This led to the use of antispasmatic substances includ ing papaverine aminophylline, atropine and opium derivatives, separately or in combina tion, as for example, spasmalgin® Favorable results have been reported following their use, but large well controlled series are not available Nevertheless, it seems advisable to use these or other relaxing agents to allay the extreme tension so commonly present in these patients

Twenty years ago serious attempts were made to develop operative procedures for removal of pulmonary emboli but they were very hazardous and with the advent of anti coagulant therapy have been abandoned The use of oxygen appears to be indicated in the presence of dyspnea or cyanosis to lessen the burden of the functioning area for gas exchange and hence the strain of the heart In recent years efforts have been made to reduce the incidence of thromboembolism prior to its origi

nal development The most popular methods have included the following

1 Early ambulation within twenty four hours of the operation or delivery This is still a matter of controversy but we incline toward the evidence in favor of it Active proponents of this method have pointed out that merely sitting in a chair as commonly practiced is not ambulation and indeed greater stasis may occur with the legs in dependency for long periods than if they are actively moved in bed or by walking In all patients we prefer the osc llat

2 De t

atment of phlebitis we elevate the foot of the bed to speed up the flow of blood through the venous channels of the legs and pelvis and to prevent stasis For man years it has been our practice to do this as a prophylactic measure following surgery when ever the surgeon feels the operative procedure justifies it and also provided the arterial supply to the limbs is adequate [5] None of these surgical patients has had a postoperative pulmonary embolus Torpin [7] has reported similar results namely no pulmonary embol in 1 500 gynecologic operations using this simple prophylactic measure The use of an oscillating bed in chronically ill or postopera tive patients has much to recommend it The repeated filling and emptying of the ve ns should aid in prevention of phlebitis

4 Elastic stockings in the prevention of pulmonary embolism Wilkins and Stanton [8] have recently reported that in a series of over 5 000 routine hospital admissions pulmonary emboli were significantly reduced by the con tinuous wearing of light elastic hose

5 Prophylactic ligation of the veins post operatively This is much less popular than it was ten years ago Some workers have even reported more emboli after ligation than in a control series We do not favor this procedure

6 Anticoagulant therapy on a purely pro phylactic basis We would not recommend this in all patients or after all operations but cer tain situations probably justify its use accord ing to a large series reported by Barker Brambel and others and our own experience These include (1) major pelvic surgery (2) herniorrhaphy (3) major abdominal surgery especially in the presence of a history of former



F 6 Pulmonary embolus and atelectas s in a p t ent w th postoperative phleb t s

thromboembolic conditions (4) surgery on older persons (5) surgery in the presence of auricular fibrillation coronary artery disea or passive congestion (6) the presence marked varicose veins or venous insufficienc (7) after delivery when the mother has ha previous thrombophlebitis or pulmonary embo lism and (8) in all patients who have previ ously demonstrated a tendency toward throm bosis or embolism

LONG TERM ANTICOAGULANT THERAPY

The treatment of pulmonary embolism should not be limited to a consideration of the acute episode first encountered This may be a single experience secondary to thrombosis which becomes organized and causes no further trouble and treatment of three to four weeks duration may be sufficient On the other hand the patient may continue to have repeated emboli from chronic recurrent thrombo- phlebitis or auricular fibrillation We have patients who have had as many as twenty emboli from such sources It then becomes necessary to employ long term anticoagulant therapy The results of such therapy are encouraging and have been reported by us [11 12] Our experience has greatly increased

FIG 2 Multiple pulmonary emboli and mitral stenosis

FIG 3 Pulmonary embolus mitral stenosis

since then We have maintained more than 100 patients for from one to eight years on anticoagulants

The following case reports present examples of interest

CASE I M A A (N Y H No 625-583), a fifty year old man, had cholecystectomy performed because of cholelithiasis On the eighth postoperative day he experienced sharp right chest pain and raised blood streaked sputum Deep phlebitis was found in his right calf Anticoagulants were administered promptly, the leg was wrapped in warm, moist packs and elevated An uneventful recovery ensued

Figure 1 is a portable chest film The right diaphragm is elevated and tented A pleural effusion is present There is partial atelectasis of the right lower lobe

CASE II Miss J R (N Y H No 530-436), a fifty seven year old social service administrator was first seen in November, 1948 During the previous ten years she had had eight illnesses that had been characterized as "lobar pneumonia" On admission she complained of cough, chest pain and blood tinged sputum Examination showed typical signs of mitral stenosis X-ray of the chest showed a shadow in the right lower lung field Dicumarol therapy was instituted and maintained for two months The patient lapsed from treatment She again had a sudden episode of chest pain, cough and blood streaked sputum (Fig 2)

CASE III Mrs E H (N Y H No 570-625) a fifty one year old woman, was first seen in June, 1950, with a pulmonary infarct At age fourteen she had had rheumatic fever and at eighteen she had been told she had a heart murmur Until her present illness she had been entirely well She was a business executive and led a busy professional and social life The day prior to admission she had developed severe pain in the right lower chest radiating to the back Examination disclosed signs of mitral stenosis and aortic stenosis There was a regular sinus rhythm interspersed with many premature contractions The chest showed dull [illegible] at the right

ment, bilateral pleural effusion and an increased density in the posterior basal segment of the right lower lobe which is consistent with the clinical findings of pulmonary infarction

The patient ran a febrile course for a week She was given anticoagulants starting with heparin and shifting to dicumarol She was digitalized, and discharged on her fourteenth hospital day Dicumarol was discontinued

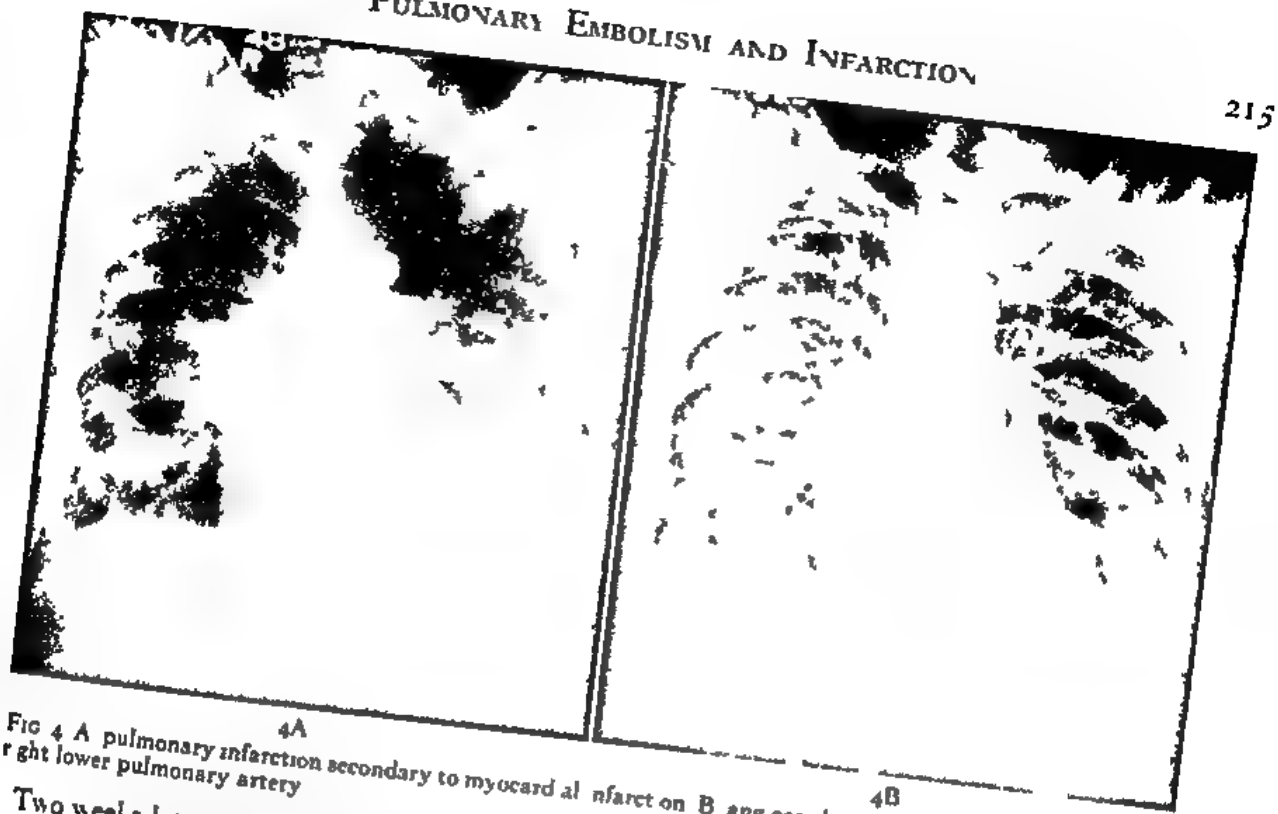

4A 4B

FIG 4 A pulmonary infarction secondary to myocard al nfarct on B ang ocard ogram showing embolus blocking r ght lower pulmonary artery

Two weeks later a second pulmonary infarct occurred She was readmitted to the hospital and again given dicumarol The decision was made to keep her on anticoagulants perma nently There have not been any further emboli during a period of four years She re ports every fourteen days for prothrombin determinations She has had several minor emorrhagic manifestations large bruises after ight trauma but no major ones Her pro rombin time varies from twenty to a high of forty seconds Her average daily dose is 75 mg of dicumarol While under treatment she has made two business trips to California one to Paris and Rome and many shorter trips Her blood tests have been arranged at various points with physicians interested and trained in this work Her course was complicated two years ago by the development of hyperthyroid ism This was successfully controlled with radioactive iodine

The patient represented a case of rheumatic heart disease not fibrillating who delivered emboli from the right auricle to the lungs

CASE IV L S (N Y H No 494 688) a forty four year old white man had had three previous episodes of myocardial infarction He had also had multiple pulmonary infarctions The x ray of the chest (Fig 4A) shows increased vascular markings in both lung fields and a b lateral pleural effusion The angiocardiogram (Fig 4B) made four and a half seconds after the intravenous injection of the contrast medium shows the pulmonary conus pulmo- nary artery and its major branches well out lined The branches to the right lower lobe are irregular and cut off and indicate the point of lodgement of a pulmonary embolus

The patient died several months later Autopsy showed a large embolus in the right lower pulmonary artery branch multiple old pulmonary infarcts and multiple myocardial infarction

SUMMARY

The importance and frequency of pulmonary embolism has been discussed The diagnosis and treatment have been presented Important strides have been made in the treatment of this condition during the past twelve years since the advent of anticoagulant drugs While death and recurrent emboli may occur during such therapy the incidence of both has been strik ingly reduced by the use of heparin and coumarin derivatives

Greater awareness of the possibility of thrombosis and pulmonary embolism will re- sult in earlier diagnosis and treatment and

further reduction in mortality from these conditions

REFERENCES

1 FARMER, D A and SMITHWICK, R H Thromboembolic disease discussion of problem in surgical patients with particular reference to fatal embolus *Angiology*, 1 291, 1950

2 SCHERF, D and SCHONBRUNNER, E Über Herzbefunde bei Lungenembolien *Ztschr f klin Med*, 128 455, 1935

3 IDEM Über den pulmocoronaren Reflex bei Lungenembolien *Klin Wchnschr*, 16 340, 1937

4 DETAKATS, G, BECK, W C and FENN, G K Pulmonary embolism An experimental and clinical study *Surgery*, 6 339, 1939

5 KJELLBERG, S R and OLSSON, S E Roentgenological studies of experimental pulmonary embolism without complicating infarction in dog *Acta radiol*, 33 507, 1950

6 BARKER, N W Anticoagulant therapy in peripheral vascular disease *Circulation*, 4 613 1951

7 ERB W H and SCHUMANN, J An appraisal of bilateral superficial femoral vein ligation in preventing pulmonary embolism Application of the procedure in 100 controlled cases of fracture of the femoral neck *Surgery*, 29 819, 1951

8 BARNES, A R Pulmonary embolism *J A M A*, 109 1347, 1947

9 BRAMBEL, C E, HUNTER, R E and FITZPATRICK, V DEP Prophylactic use of anticoagulants in puerperal period (dicumarol heparin and Link compound 63) *Bull School Med Univ Maryland*, 35 91, 1950

10 WRIGHT, I S, MARPLE, C D and BECK, D F Anticoagulant therapy of coronary thrombosis with myocardial infarction *J A M A*, 138 1074, 1948

11 WRIGHT, I S Vascular Diseases in Clinical Practice 2nd ed, p 439 Chicago 1952 Year Book Publishing Co

12 [illegible]

13 [illegible]

14 [illegible] York Med, 6 16, 1950

15 IDEM Pulmonary thromboembolism diagnosis and treatment *New York State J Med*, 52 1904, 1950

16 WILKINS R W and STANTON, J R Elastic stockings in the prevention of pulmonary embolism *New England J Med*, 248 1087, 1953

24

Thrombosis of Pulmonary Arteries

D R Keating M D *Cleveland Ohio*

From the Department of Radiology School of Medicine Western Reserve University, and the Radiological Division of the University Hospitals Cleveland Ohio

Massive organized thrombosis of the main pulmonary artery and its branches has for years been a recognized pathologic entity [1,2] but it is only recently that a clinical syndrome of the disease has been evolved making the antemortem diagnosis of pulmonary thrombosis possible

It is sometimes astonishing how organized thrombi can occlude large branches of the pulmonary artery for periods of weeks, months or years and yet produce surprisingly little disability in proportion to the critical function of the vessels involved Apparently this is a result of slow progression in size of the thrombi the occurrence of recanalization and limitation in the number of large pulmonary arterial branches involved

INCIDENCE

The syndrome of chronic massive pulmonary artery thrombosis is not a commonly encountered one, but it occurs with sufficient frequency for it to merit consideration in the differential diagnosis of mediastinal mass lesions We have previously reported seven cases of chronic massive thrombosis involving either the main pulmonary artery, several of its major branches or both [4] Other series in the literature bring the total of reported cases to well over 100

PATHOGENESIS

Onset of massive pulmonary artery thrombosis is most commonly in pulmonary embolism arising from systemic veins or right ventricle Thus a history of pulmonary embolism is a leading clue to the correct clinical diagnosis of the entity *Thrombosis of pulmonary arteries* occurs and has been reported as a complication of certain local pathologic processes such as carcinoma of the lung pulmonary tuberculosis, pneumoconiosis and congenital and acquired heart disease [5,6,7]

Cor pulmonale may antedate massive thrombosis of the pulmonary artery, or it may result from the arterial occlusion itself In most of our previously reported cases it has not been possible to ascribe the exact pathogenesis of the syndrome

SYMPTOMS

Symptoms of chronic massive thrombosis of pulmonary arteries may have their onset in pulmonary embolism or they may in more subtle fashion be associated with pre-existent disease of the heart, lungs or pulmonary vessels Most often the symptoms are those of congestive failure, typically of the right heart Duration of symptoms may be of weeks, months or years and thrombi may exist and propagate for corresponding lengths of time Dyspnea was a universal symptom in our previous cases Clubbing and cyanosis were uncommon Polycythemia was not the rule Pulmonary embolism is common, occurring either as the initiating factor or secondarily as the result of detachment of thrombi from the pulmonary artery branches occluded Death was in all cases sudden and unexpected

DIAGNOSIS

The clinical diagnosis of pulmonary artery

largement involving one or more of the vessels in the hilar regions, or enlargement of the pulmonary artery itself Thus thrombosis may involve the main artery, its primary branches and the larger branches of the latter, singly or collectively, depending upon location and extent of thrombosis /The thrombosed artery has specific fluoroscopic and radiographic characteristics It is possessed of little motion, producing sharp, clear images on the film

Fig 1 Case 1 Chest roentgenogram made three weeks before death heart not enlarged Thrombosed right branch of pulmonary artery very sharply circumscribed due to immobility S milar but less obvious changes in left hilar region Lung fields normal

The thrombosed vessel has an elliptic configuration tapering abruptly at the distal point of thrombotic closure Distal to the point of thrombosis the lung segment involved exhibits reduced radiability because of diminished blood flow in the pulmonary segments so affected [5] The mass is localized to the artery or to its branches and it is demonstrated to be continuous with those branches

Differential diagnosis of pulmonary artery thrombosis includes the differential diagnosis of mediastinal mass lesions of variable origin as well as other causes of pulmonary arterial dilatation Massive thrombosis of a secondary or tertiary branch of the artery may result in a unilateral mass lesion characterized also by segmental increase in radiability of the lung simulating check valve obstruction of the bronchus as the result of bronchogenic carcinoma

The electrocardiogram may be expected to reveal right ventricular hypertrophy A change by serial records from a normal record or from left axis deviation to right ventricular hypertrophy may occur coincident with the development of cor pulmonale (Fig 3)

Angiocardiograms are of aid in the diagnosis although as in the case of mediastinal neoplasms opacification of the mass may fail to occur This will not necessarily be the case especially if recanalization of the thrombus has occurred Normal opacification of the peripheral pulmonary arteries is not to be expected

Since our previous report of seven cases with autopsy verification[4] we have observed one additional case confirmed at autopsy One other case in a living patient presented herein is not confirmed anatomically

CASE REPORTS

CASE I A seventy three year old man had paroxysms of nocturnal dyspnea for two months prior to hospital admission On physical examination there was edema of the legs, enlargement of the heart without murmurs enlargement of the liver and shortness of breath The blood pressure was 172/105 The electrocardiogram showed right ventricular hypertrophy Chest roentgenograms revealed findings typical of massive thrombosis of pulmonary arteries bilaterally (Fig 1) The patient improved following treatment of cardiac failure However relapse occurred and a few days prior to death there was clinical and radiographic evidence of pulmonary embolism Death was sudden and unexpected Autopsy revealed right ventricular hypertrophy There were large thrombi firmly attached to the walls of each main pulmonary artery The main pulmonary artery, its right and left branches and branches to the left lower lobe right middle lobe and right lower lobe were all occluded Microscopically there was pulmonary arteriosclerosis and focal pulmonary arteritis Serial chest roentgenograms indicated that thrombi had existed for at least five weeks before death occurred

CASE II A sixty six year old man had a transurethral resection of the prostate gland A preoperative chest film (Fig 2) revealed no abnormality During the postoperative period there was clinical and radiographic evidence of pulmonary embolism At that time the electrocardiogram showed left axis deviation (Fig 3A) Eight months later the patient returned with dyspnea and ankle edema. Clubbing of the fingers had occurred He responded to therapy for cardiac failure A chest film (Fig 4) made a few days before death eight months after the initiating episode of pulmonary embolism revealed changes indicative of pulmonary thrombosis and at

FIG 2 Case II Control roentgenogram of chest made before operation, normal chest

this time the electrocardiogram showed right axis deviation (Fig 3B) Death occurred suddenly about eight months after pulmonary embolism Autopsy revealed cardiac hypertrophy involving the right ventricle especially The right pulmonary artery was completely occluded by a laminated and firmly adherent thrombus which distended the artery to a diameter of 5 cm and extended from the bifurcation of the artery to the middle portion of the right lower lobe Branches of the left pulmonary artery to the left lower lobe were occluded at their origin Microscopically there was slight arteriosclerosis of pulmonary arteries

CASE III A sixty year old woman had been dyspneic with obesity but was otherwise well until six years prior to admission, when she had her first attack of paroxysmal auricular tachycardia Since then there had been progressive exertional dyspnea and orthopnea, and she had had mild ankle edema for several years, failure being controlled with digitalis and diuretics On physical examination the pulse was 98, the blood pressure 130 85 She was chronically ill, with cyanosis of nailbeds and lips, and with clubbing of fingers and toes There were palpable nodules in both lobes of the thyroid The heart was enlarged, with a soft diastolic murmur and a systolic murmur at the apex Venous pressure was 130 mm of saline There was mild pretibial and ankle edema Circulation time, arm to tongue, was

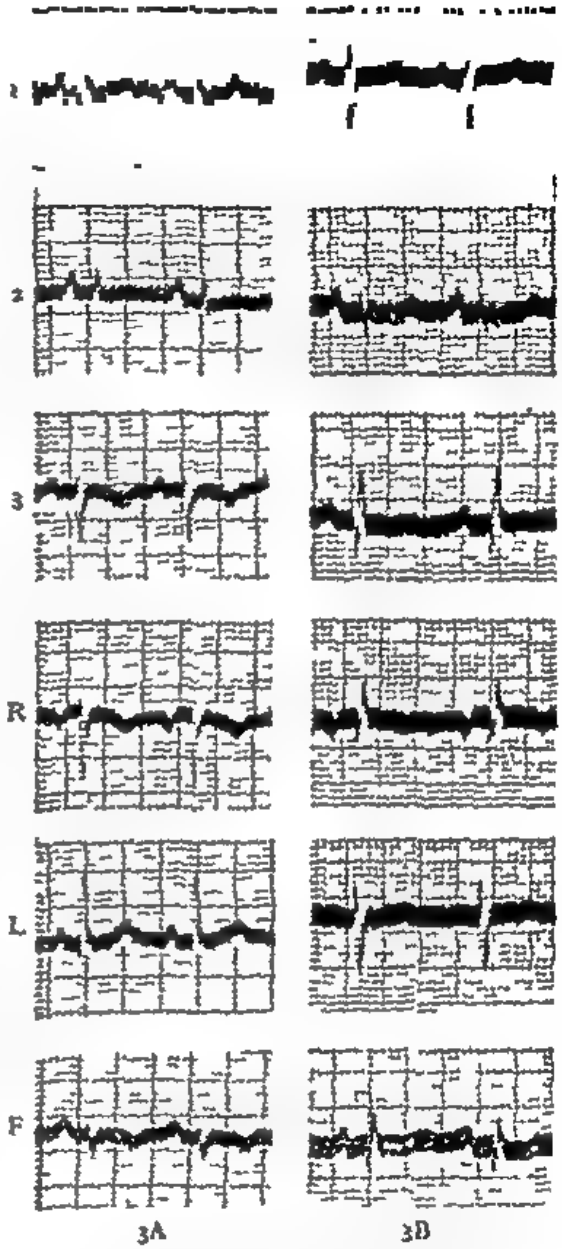

FIG 3 Case II A, electrocardiogram reveals left axis deviation and pulmonale P waves B electrocardiogram now shows right axis deviation and inverted T waves in 1, 2 3 and V_1 to V_4 R waves are tall and peaked

12 seconds with ether and magnesium sulfate The electrocardiogram revealed broad-notched mitral P waves, right ventricular hypertrophy and right bundle branch block The hemoglobin was 18 gm , the red cell count 7 25 million

before death she experienced onset of severe left chest pain with cough and hemoptysis She responded poorly to supportive treatment

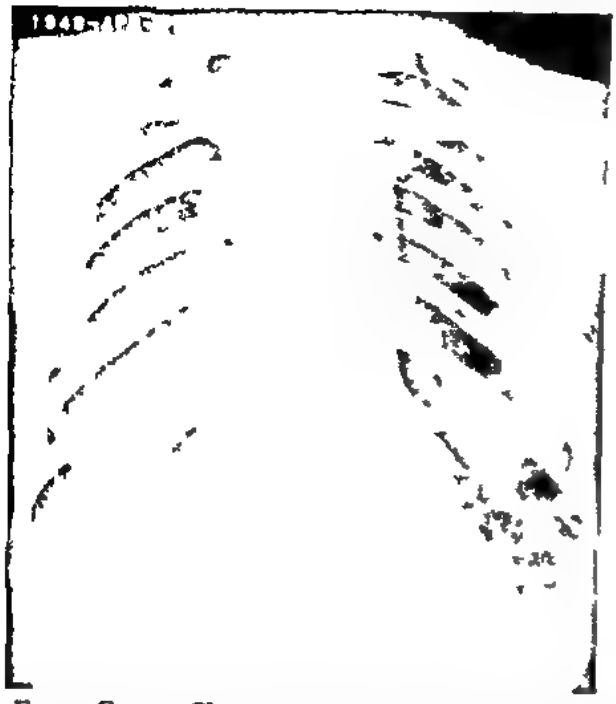

FIG 4 Case II Chest roentgenogram made one week before death nine months after postoperative pulmonary embolism Right hilus now abnormal with mass shadow representing thrombus filled right branch of pulmonary artery Lung fields abnormally clear especially the right Minor residua of old pulmonary embolism at left lung base

and died unexpectedly in her sleep Autopsy revealed mitral stenosis, an atrial septal defect, and bilateral massive thrombi involving primary and secondary branches of the pulmonary artery There was evidence of pulmonary arteriosclerosis with hemorrhage into plaques, but there was not much evidence of organization According to morphologic estimates the thrombi had not been present for longer than one week However, the diagnosis had been suspected radiographically before death and

CASE IV This thirty five year old man was an asthmatic, with onset early in life Six years previously he had his first episode of decompensation, with edema of legs, thighs and trunk He recovered but a similar episode recurred three years prior to admission Since then, despite digitoxin and other supportive measures, there had been chronic pedal edema Three years prior to admission there was an attack of semiconsciousness and aphasia, with right hemiparesis which persisted Diagnosis at that time was cerebral thrombosis

are the result of pulmonary embolism

On physical examination he was not acutely or chronically ill in appearance, but there was moderate respiratory distress The blood pressure was 100/80 There was increased anteroposterior diameter of the chest with reduced excursions and diminished breath sounds bilaterally The heart was not enlarged and there were no murmurs The liver was palpable 3 fingerbreadths below the costal margin, the nailbeds were dusky and there was pretibial and ankle edema The electrocardiogram revealed right ventricular hypertrophy

Cardiac catheterization revealed an enlarged right atrium There was no evidence of an intracardiac shunt Pressure in the pulmonary "capillary bed" was 18 mm Hg in the right branch of the pulmonary artery 96/47, in the main pulmonary artery the same, and in the right ventricle 105/5

Hemoglobin was 16 gm the red blood cell count 5 1 million and the hematocrit 52 The Wassermann test was negative and the venous pressure 85 mm of saline, the circulation time arm to-tongue was 28 seconds, arm to-lung 9 seconds

A chest film revealed a mass in the right hilar region possessing all of the characteristics of

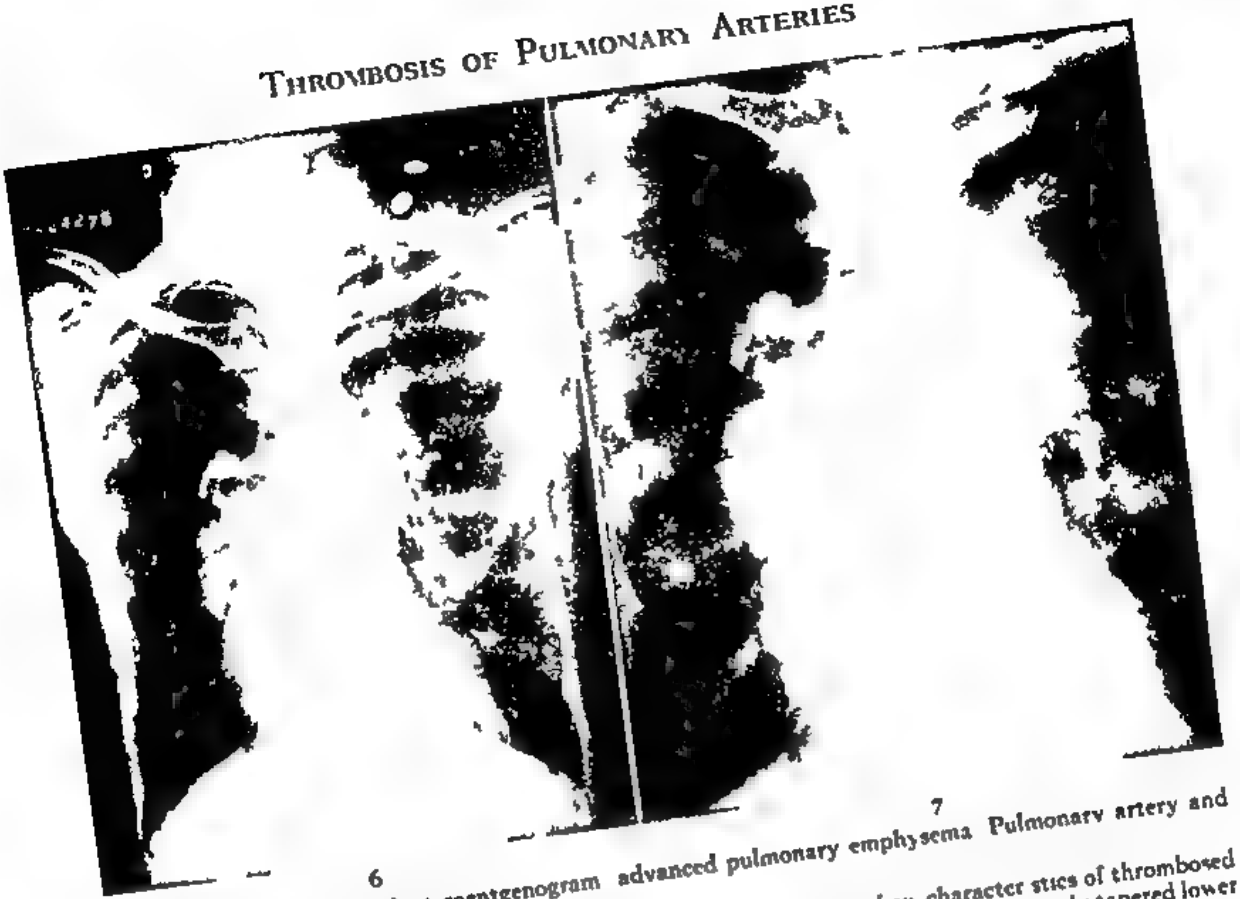

6 7

FIG 6 Case IV Routine chest roentgenogram advanced pulmonary emphysema Pulmonary artery and its branches enlarged

FIG 7 Same case Magnified view of chest roentgenogram especially to show characteristics of thrombosed artery in right hilar region Note sharp smooth elliptic lateral border of mass and its abruptly tapered lower extremity Left hilar mass composed of main pulmonary artery and its left branch Abnormally clear lung fields as the combined result of pulmonary emphysema and reduced blood flow

massive thrombosis of the right branch of the pulmonary artery (Figs 6 and 7) Comparison with a chest film made two years before had shown a normal appearing right pulmonary artery at that time Fluoroscopically the mass moved only slightly The heart was enlarged a little and the lung fields were abnormally clear in part as the result of pulmonary emphysema but probably also in part because of reduced blood flow

Angiocardiograms did not show appreciable opacification of the arterial circulation of either lung The main pulmonary artery and its primary branches opacified faintly and there was a suggestion of canalization of the right branch Previous passage of a cardiac catheter into the right branch of the pulmonary artery seemed to support the impression of recanalization The patient was discharged unimproved

SUMMARY AND CONCLUSIONS

Large thrombi may exist in the pulmonary artery its branches or in both for long periods of time Often they become organized and recanalized They arise either locally or are the result of emboli which originate in systemic veins Symptoms are usually those of congestive heart failure typically of the right heart Cyanosis clubbing and polycythemia may occur but they are not the rule Dyspnea is a frequent symptom Electrocardiograms uniformly reveal right ventricular hypertrophy Pulmonary embolism may initiate the syndrome and as an episode in the course of the disease it is a common occurrence There are characteristic roentgenographic findings which are to be differentiated especially from mediastinal mass lesions of variable etiology, notably carcinoma with check valve obstruction of the bronchus Death is usually sudden and unexpected

Acknowledgment Histories and illustrations of Cases I and II are reprinted from the *American Journal of Roentgenology Radium Therapy and Nuclear Physics* Volume 69 February,

1953,[4] with permission of the Publisher and the Editor

REFERENCES

1 BRENNER, O Sclerosis of pulmonary artery with thrombosis *Lancet* 1 911–914, 1931
2 BRENNER O Pathology of vessels of pulmonary circulation *Arch Int Med*, 56 211, 457, 724 976 1189 1935
3 HANELIN J and EYLER W R Pulmonary artery thrombosis roentgen manifestations *Radiology*, 56 689–703 1951
4 KEATING, D R BURKEY J N, HELLERSTEIN H K and FEIL, H Chronic massive thrombosis of pulmonary arteries *Am J Roentgenol.*, 69 208 220 1953
5 KAMPMEIER R H Thrombosis of main branches of pulmonary artery, with case report and review of literature *J Thoracic Surg*, 3 513 524 1934
6 POU, J F and CHARR R Thrombosis of pulmonary artery *Am Rev Tuberc* 37 394 409 1938
7 SAVACOOL, J W and CHARR R Thrombosis of pulmonary artery *Am Rev Tuberc* 44 42 57 1941
8 WESTERMARK, N Roentgen Studies of the Lungs and Heart Minneapolis 1948 University of Minnesota Press

VIII. UPPER RESPIRATORY TRACT AND PULMONARY DISEASE

25

Relation of the Nose and Throat to Pulmonary Diseases

ARTHUR J CRACOVANER M D *New York, New York*

IN the diagnosis and treatment of pulmonary diseases the chest physician encounters a number of symptoms that have their origin in pathologic conditions of the nose and throat The specialists in thoracic disorders are confronted with symptoms such as cough hemoptysis excessive expectoration and others that may or may not originate in the chest There are times when patients are treated for pulmonary abnormalities when in reality the symptoms are due to diseases in the nose and throat For example a person may be treated for tuberculosis bronchiectasis or bronchitis because his presenting symptom is cough or hemoptysis However if the symptom is thoroughly investigated the cause would be found in the nose or throat The opposite may also be true The otolaryngologist may treat the symptoms as difficulties in the nose and throat when they really originate in the lung

We wish to bring out in this discussion that an examination of the nose and throat by a competent otolaryngologist is important in investigating cough hemoptysis and other symptoms

Cough The most frequently encountered symptom is cough Infections anywhere in the upper respiratory tract may extend downward to produce inflammation and irritation of the trachea and bronchi accompanied by cough It is true too that the cough may be a reflex one due to infection in the nose and throat without actually causing inflammation of the bronchi We must remember that the mucous membrane of the upper respiratory tract is continuous with the bronchi and an infection in one area travels readily to another

There are certain areas in the nose that are very sensitive and may be irritated by mucus congestion or fumes by pressure of enlarged turbinates and by contacts with a deviated septum This irritation may cause a reflex type of cough The treatment is to remove the cause of the nasal irritation The presence of mucus and the congestion of the mucous membrane may be due to allergy or to infection and must be treated accordingly Enlarged turbinates may be reduced in size by cauterization or by partial resection Removal of pressure contacts of a deviated septum is accomplished by performing a submucous resection of the nasal septum

Catarrh or postnasal drip as it is more commonly called may also produce a cough The discharge may consist of mucus pus or mucopurulent exudate A mucopurulent exudate which is most probably due to sinusitis may drip into the trachea and thus cause tracheitis or bronchitis and cough This condition can be improved only by treating the sinuses This may be done by nasal shrinkage by irrigation or by antibiotics Should these methods fail more radical means involving operative procedures may be required in order to permit drainage of the purulent material or to remove infected mucous membrane lining the sinus

A non purulent mucous secretion resulting from a deviated septum may afford the same symptoms Coughing may be the result of any type of nasal obstruction Allergic rhinitis or vasomotor rhinitis of long duration as well as chronic infection may terminate in hypertrophic turbinates Shrinkage and relief of the obstruction can be attained through scarring by cauterizing the turbinate In the case of allergic rhinitis appropriate treatment can be given only after the cause of the hypersensi

tivity has been ascertained Vasomotor rhinitis when not due to hypersensitivity may be traced to other factors such as menopause, fibroid uterus ovarian dysfunction, emotional upsets diabetes etc Although postnasal drip is a common complaint, when it produces a cough the source of the trouble may be difficult to trace

Infection or enlargement of the tonsils and adenoids often produces cough, especially in children and immediate relief is obtained by their removal Regrowth of nasopharyngeal lymphoid tissue causing cough may be removed either by surgery or radiation therapy This regrowth of tissue may be on an allergic basis, usually bacterial sensitivity due to infection in the excessive lymphoid tissue However, other sensitivities must be investigated also Dryness due to mouth breathing as a result of nasopharyngeal obstruction may also cause coughing in children

A cough may be caused by inflammation and enlargement of lateral lines of lymphoid tissue situated behind the posterior pillars of the pharynx This lymphoid tissue may be removed or treated by cauterization

The sensation of irritation or of a lump in the throat, most marked when a patient is lying down may produce a cough and may be due to enlarged lingual tonsils Again, removal or cauterization relieves the condition If the lingual lymphoid hyperplasia is caused by chronic sinusitis and its postnasal discharge, the sinuses must also be treated

Inflammation of the mucous membrane of the upper respiratory tract is frequently produced by excessive smoking Irritating fumes encountered in certain occupations may create a cough Congestion of the mucous membrane of the larynx and pharynx may be due to alcoholism An elongated uvula resting on the base of the tongue can cause an annoying cough Aspiration of food or fluid due to motor or sensory paralysis of the pharynx and larynx can produce coughing Likewise esophageal stenosis or pharyngeal diverticulum may cause overflow of material into the larynx Any type of tumor along the respiratory tract, particularly in the hypopharynx or larynx may result in a cough either by irritation or aspiration

A prominent causative factor in cough is allergy There is swelling and congestion of the mucous membrane throughout the nose and throat giving a sensation of irritation and stuffiness Often after an acute upper respiratory infection the cough persists This could be due to an allergic type reaction to infection and should be treated by intranasal shrinkage [illegible] be cured by proper treatment once the cause is ascertained and traced to the nose and throat

Hemoptysis Whenever hemoptysis is present and an x ray of the chest proves to be negative, the upper respiratory tract should be thoroughly investigated Expectoration of blood may result from rupture of varices in the postnasal space pharynx or at the base of the tongue When irritated by acute or subacute infections the varices may bleed on coughing Benign or malignant tumors of the nasopharynx pharynx base of tongue or larynx may be a source of bleeding Telangiectasis may be another [illegible] gums are [illegible] case in wh[illegible] found in either the upper respiratory tract or the lung bronchoscopy should be performed to determine the origin

Expectoration It is difficult to determine whether expectoration of purulent or non purulent material comes from the lungs or upper respiratory tract, and both must be investigated Examination of the upper respiratory tract, especially the nose and sinuses is imperative to discover the origin of a postnasal drip which may strike the larynx and be coughed up This discharge may accumulate in the trachea during the night and produce expectoration and cough in the morning

Fetid Odor There are many causes of this complaint which may or may not accompany cough and expectoration A purulent sinusitis that is otherwise silent may produce a fetid [illegible] extend [illegible] lent [illegible] gan[illegible] isms Infection may involve the mucous membrane of an antrum following a tooth extraction causing an extremely foul odor A very frequent cause of foul breath is infection in the lymphoid tissue at the base of the tongue Ozena or atrophic rhinitis also produces a fetid odor Poor dental hygiene and mycotic infection in the lymphoid tissue of the pharynx, faucial tonsils and lingual tonsils may cause

fetid breath, and cauterization or removal is required

Dyspnea and Wheeze A careful history is important in differentiating between nasal obstruction and dyspnea A patient will say that he cannot breathe or cannot "catch his breath when actually there is some obstruction to the air passage in the nasal cavity

Laryngeal obstruction by a tumor, paralysis of a vocal cord, edema or cicatricial stenosis following trauma to the larynx may result in a wheeze that is heard in the chest Congenital stridor due to infantile type larynx or congenital web or foreign body must be considered in children In some cases of wheezing laryngeal examination is imperative

Sinobronchitis Some diseases of the lungs are directly related to pathologic disease in the nose and throat, for example the syndrome of sinobronchitis Persistent or recurrent bronchitis often is traced to infection in the upper respiratory tract, particularly the sinuses Sinusitis may either act as a focus for the disease in the bronchi, or the infection may involve the mucous membrane of the bronchi by direct extension Pus dropping from the nasopharynx into the trachea may also cause inflammation of the bronchi Bronchitis may follow acute nasopharyngitis without involvement of the sinuses These upper respiratory infections may be prevented by the use of autogenous or stock vaccine in an effort to increase resistance to infections and thus reduce the possibility of recurrent attacks of bronchitis Tonsillar infections may extend to the bronchi, and only by tonsillectomy will the chronic or recurrent bronchitis be cured

Bronchiectasis There are different trends of thought concerning the relationship of bronchiectasis to sinusitis Some believe that the basic causative factor of both conditions is allergy, especially sensitivity to bacteria, and that both conditions occur simultaneously Others contend that chronic sinusitis produces the conditions which lead to bronchiectasis However, there are many instances of bronchiectasis in which the sinuses are very clear and certainly sinusitis may be present without bronchiectasis It has been found that proper treatment of the sinuses will frequently alleviate some of the distressing symptoms of bronchiectasis It must be remembered that aspiration of purulent discharge may produce bronchial obstruction which may, after a time, lead to bronchiectasis

Asthma Infection in tonsils and adenoids, especially in children, may be the causative factor of still another symptom—asthma It is sometimes considered a bacterial sensitivity At times there is a regrowth of lymphoid tissue following tonsillectomy and adenoidectomy which when infected, produces the asthma Surgery or radiation therapy to shrink the affected tissue attains relief of the condition

Sinus infection in adults may account for the complaint of asthma Frequently there is a suppurative process in one or more of the sinuses or polyp formation in the nose Various conservative and radical procedures may be indicated depending on the extent of the pathologic condition Allergic individuals may have swelling of the mucous membrane of the sinuses but no infection therein, and therefore operative removal will not aid the condition and might tend to create chronic nasal ills Only when pus and abscess formation is demonstrated in the mucous membrane is surgical intervention advised This may range from simple nasal polypectomy or straightening of deviated septa that prevent proper drainage of the sinuses to the more radical type procedures as indicated However, since the latter may aggravate asthma, it is most important to determine the state of infection at time of examination and by x ray, and chose the most conservative yet effective treatment

SUMMARY

Since certain conditions of the lungs and bronchi may originate in pathologic disease in the upper respiratory tract the otolaryngologist can be of great assistance to the chest specialist or internist in investigating these conditions and in determining the origin of such symptoms as cough, hemoptysis, expectoration asthma etc Thorough work-up and competent treatment of abnormalities of the nose and throat may explain many symptoms attributed to the lungs and may cure some pulmonary diseases

26

Cough, Its Pathology and Management

A Worth Hobby, M D, *Atlanta, Georgia*

Ignorance of the true pathology of the cough mechanism and the confusion in the selection of proper management of this symptom may be due to its constant presence in all degrees of severity New drugs are accepted slowly because the physician is more familiar with an older product and because the importance of the symptom is minimized Constant effort is necessary to keep up with the new literature on the subject, as well as a burning desire to learn the cause of each individual cough The simplest efficient method of management is desirable but not a substitute for a knowledge of the cause and effect This is even more important when it is realized that 13 per cent of the population of this country will be over sixty-five years of age at the end of this century Of this 13 per cent, it is estimated that 6 per cent will be "*chronic coughers*" as a result of many chronic lung diseases An example is the increase of hypertrophic emphysema, or consider the coughing in bronchiectasis which "is the second commonest lung disease The National Health Survey of 1935–1936 showed 1,700 000 persons to be affected by chronic bronchitis To these cases many of the 1,150 000 persons with chronic sinusitis can be added since chronic bronchitis and sinusitis frequently complicate each other Furthermore, *most cases of chronic asthma*, although still indexed among the 3 500,000 victims of hay fever and asthma, represent

2 to 3 million persons suffer from chronic bronchopulmonary disease"[1]

DEFINITION

Cough is defined as a sudden violent expulsion of air after deep inspiration and closure of the glottis The helpful cough has as its purpose the removal of abnormal mucus, inflammatory products, foreign bodies, product resulting from circulatory congestion and al irritating sensations in the respiratory tree To be successful a cough must produce effectiv drainage of the lung without undue stress or the tissues of the body

During cough, particles are propelled through the air at the rate of 150 to 160 feet per second In normal toned conversation these same particles are sprayed for a distance of 8 feet A cough sprays about 12 to 15 feet and a sneeze sprays as much as 20 feet

ETIOLOGY

All classifications of cough are unsatisfactory because they are as numerous as there are descriptive adjectives and lead only to confused thinking

Therefore, for simplicity, the author has listed the following causes of harmful cough (1) stimulation of the cough reflex by extrapulmonary irritation due to drainage from the paranasal sinuses, an elongated uvula and pressure on the trachea or bronchi by mediastinal inflammation, tumors or dilated blood vessels, (2) non inflammatory lesions of the bronchial tree such as benign or malignant tumors, (3) inflammatory processes of the bronchi or the lung parenchyma without the formation of exudate but with constant irri [illegible] the dry cough

[illegible]

be removed by cough, as in the paroxysmal [illegible]

[illegible]

exudates distal to the obstruction (7) atelectasis because the definition of cough cannot be fulfilled, (8) emphysema as result of weakening and destruction of the elastic structures

reduction of the intrapleural subatmospheric pressure, abnormally low position of the diaphragm, (9) fatigue and exhaustion of the expiratory muscles as in fibrotic tuberculosis and pulmonary fibrosis (10) psychogenic cough such as that produced by the exhibitionist (11) allergies

PATHOLOGY

Full credit should be given to Banyai[2-6] the pioneer in bringing to our attention the pathology of the cough mechanism The basic pathology of the cough mechanism changes only with addition of new knowledge of the nerve pathways

Further pathologic knowledge is necessary to appreciate the full significance of the previously outlined causes of cough The cough

also produced by stimulation of the sensory endings of the glossopharyngeal and vagus nerves

lated by wax, eczema, etc, causing a cough the pharyngeal branch, the superior laryngeal branch sensory to the base of the tongue and larynx, frequently a cause of coughing Among this group is also found the inferior laryngeal branch (motor), which may produce an inefficient cough, and cardiac branches which are indirect causes through circulatory failure The last three in this group are listed as the pulmonary branches which are concerned in the cough of gross pulmonary or pleural

blocked tuberculous cavities and atelectasis Tussal insufficiency plus severe cough increases the rate of metabolism and prevents rest Other results are pulmonary hemorrhage, vomiting spontaneous pneumothorax head ache, loss of weight exhaustion loss of appetite elevated temperature insomnia marked dyspnea, cyanosis, thoracic pain, fractured ribs, mediastinal emphysema subcutaneous emphysema, urinary incontinence and, indirectly, myocardial failure

Advanced mitral stenosis may cause the pulmonary vascular pressure to rise producing pulmonary congestion which in turn produces

be incomplete without a consideration of 'tussive syncope' Circulatory disturbances due to coughing rather than epilepsy of the larynx is believed to be the cause of the phenomenon Pressures in the right ventricle during coughing have been proved to be abnormally high Convulsions may be present There is a congestion of the cerebral veins decreased cardiac output and anoxemia, all of which may cause syncope in some cases

MANAGEMENT

Even though city dwellers and smokers all have morning coughs, they should not be allowed to go unobserved or untreated when persistent An adequate history embraces all aspects of the condition and must be accompanied by complete physical examination with all laboratory studies necessary for diagnostic purposes

Surgical Intervention When tumor, foreign body elongated uvula, dilated blood vessels and atelectasis are found to be the cause, appropriate surgery is most often indicated. Surgery is needed often in infections such as

surgery in the foregoing conditions The presence of infection, the type of infection, the location extent and character of the lesion

surgery is a must It is also useful in chest abnormalities faulty drainage of the respiratory tree, faulty respiratory movements, bad habits and chronic lung infections

Postoperative Atelectasis and Pneumonia Methods of preventing postoperative atelectasis and pneumonia are important to the surgeon Greene[10] states that postoperative 'Atelectasis and pneumonia are preventable by a strict regimen of detecting the abnormal tracheo-bronchial tree in the predisposed

patient and removing potentially obstructing [illegible]

after an abdominal operation can—except for rare occasions—be regarded as an evidence of imperfect anesthetic care" Prophylaxis de [illegible]

intravenous nikethamide, back slapping, side-to-side rolling of patient, topical anesthesia of the larynx, sudden inhalation of ether, endotracheal catheter suction, prolonged post-operative wound analgesia, intravenous procaine, early ambulation and intravenous administration of sodium iodide All depends on the ability and cooperation of the patient to cough vigorously

The so-called "wet" cough is always to be regarded with suspicion by the surgeon The most common cause for this type of cough is the inhaled smoke of twenty cigarettes per day, and the next most common cause is infection Asthma, marked obesity, emphysema or thoracic kyphoscoliosis are also associated with a wet cough However, this wet cough may fail to develop because of severe painful surgical disease, debility, stupor, excessive premedication, extreme obesity, abdominal distention or emphysema

The increasing number of emphysematous patients demands an intimate knowledge of the anatomic and physiologic mechanism of the terminal respiratory system All emphysematous patients cannot be correctly placed in one type of emphysema The cough of each is manifestly different to those experienced in that work Rhythmic relaxation and contraction of smooth muscles in the walls of the bronchioles is a normal process Spasm of these muscles causes occlusion of the smaller bronchioles This may result from irritants or allergies as foreign bodies and gases The bronchioles direct their peristaltic motion from the smaller to the larger structures With this in mind, it is easy to see that emphysema (genuine) is due to (1) increased intrapulmonary pressure due to strenuous coughing, (2) infections and other pathologic changes which result in extensive degenerative alterations in elastic elements of the lung, (3) partial bronchial occlusion of the check valve type

Cough is one of the predominant features of the common cold and [illegible] mentioned here because of the economic bearing on industry Statistics[11] state that this condition accounts for the loss of 100 million work days, or in excess of one billion dollars each year in the United States There is an average of two and a half colds for every man, woman and child in the United States each year These figures were compiled before the common use of "air conditioning," which has probably increased common colds by 15 per cent The author has noted that although "air conditioning" may cleanse and cool the air, the "coughers" are much worse because of the increased postnasal drainage This [illegible] caused by rapid change in atmospheric conditions while at work or at home and the "outside natural air" The mucous membranes of the upper respiratory tract cannot become acclimated with the same rapidity Add to this the insult of tobacco smoke (regardless of whether inhaled or not) and varying pathologic changes of the mucous membrane are sure to follow The length of exposure, virulence of the bacteria, amount of bacterial exposure, acuteness of the atmospheric changes and lack of resistance of the host must contribute to the type of disease to follow

Ordinary hilar adenopathy in childhood tuberculosis produced no cough but large caseous nodes may cause pressure on bronchi or rupture into bronchi producing cough In cases of persistent coughs, colds and frequent respiratory episodes in those who fail to gain weight, fibrocystic disease of the pancreas should be suspected

The etiology of cough is more often found in the upper respiratory tract in children than in adults Large adenoids excessive lymph tissue in the pharynx and excessive carbohydrate diet[12] all cause excessive secretion and produce cough in addition to the usual infectious processes

The treatment of cough in children and adults differs in the child's ability to receive adult methods Ice collars, painting [illegible] of the throat, packs on chest and unpalatable mixtures are to be avoided

DRUG THERAPY

There is much disagreement in the choice of cough remedies "It seems to be a field

in which poly-pharmacy and shotgun mixtures have enjoyed immunity from attack, for it makes little difference what the ingredients are or how many are included if the mixture only expressed the art of mixing palatable materials

It is well to confine the term cough remedy in a specific sense to a drug which acts to raise the threshold of the cough center in the central nervous system, or acts peripherally in the respiratory tract to reduce the impulses which pass to the center, or a mixture that combines both actions "[13]

[illegible]

than 125 articles published since 1949 have been reviewed and the need for clarification and a unanimity of thinking is more and more evident New drugs which have been proved more efficient than the old should be accepted and used Definitions should be changed to express new knowledge As an example, the term "expectorants" is obsolete as applied to cough remedies and obscures clear thinking An outstanding textbook lists and defined expectorants as drugs which assist in the removal of exudate from the respiratory tree, classifying them as sedative, stimulant and anodyne—the latter referring to opiates which depress the cough mechanism by central action The term expectorant should be confined to peripherally acting cough remedies, usually irritants which act on the mucous membrane directly or reflexly to increase secretion The increase is apt to make the secretion more alkaline and the raise in pH renders the mucus thinner and less viscid It protects a dry mucous membrane Intimate knowledge of the action of each drug or combination of drugs will insure the best results but the drugs must be selected on the basis of pulmonary finding and the general condition present Even the most efficient management of cough does not relieve the physician of the responsibility of treating the underlying disease on an etiologic basis

Morphine Morphine and its alkaloids depress the irritative reflex and decrease the amount of bronchial secretions If used they should be confined to the dry hacking cough and never used in a wet cough Although morphine is one of the oldest and most commonly used drugs, it should be very rarely used Morphine should never be used in a case of hemoptysis It reduces bleeding by sedation and slowing the circulation, but suppresses the elimination of blood and clots If tuberculosis is present, spread of the disease is encouraged It should be known that this drug and even codeine (1) depresses the respiratory center, (2) diminishes the tone of striated muscles involved in respiration (the muscles of the diaphragm are responsible for 37 to 47 per cent of the ventilatory function of the lungs and in a large measure for the normal cough mechanism),[5] (3) inhibits glandular action of the bronchial mucous membrane, (4) causes spasm of the smooth muscles of the bronchi and bronchioles, and (5) causes paralysis of bronchial peristalsis

The only excuses for the use of morphine are (1) inoperable lung and mediastinal tumors associated with uncontrollable pain, (2) aortic aneurysm causing pressure that cannot be controlled otherwise and (3) certain cases of cardiac decompensation with cough (4) Lansdown[12] believes that old debilitated patients in a terminal illness such as bronchiectasis should have morphine or codeine, even if it shortens their life, if it affords them comfort

Dihydrocodeinone A codeine derivative called hycodan bitartrate® and para hycodan® are far superior in every way to codeine Depression, constipation, nausea and the habit-forming ability are far less It is an effective and satisfactory antitussive agent which relieves cough without interference with expectoration

Caramiphen ethanedisulfonate (bis [1-(arbo-B-diethylaminoetroxy)-1-benylcyclopenane]), an anticholinergic compound [14 15] was found to have excellent antitussive effect in the dry or moist unproductive cough and is manufactured under the name toryn® (Smith, Kline & French Laboratories) Romilar hydrobromide® (Hoffmann La Roche Inc) is found to be less depressing and less habit-forming than codeine and its derivatives and is essentially free of atropine-like effects [16]

Dextromethorphan hydrobromide (dextro-3-methoxy-N methylmorphinan), 4 mg, was compared[17 18] with codeine sulfate, 17 mg, and a placebo medication The antitussive effectiveness of the first was equal to that of codeine, but the side effects (nausea, constipation, etc) were the same as that of the placebo medication

Methadone[20] is similar to morphine but more powerful It does not increase the rate of production of respiratory tract fluid Other names for this product are dolophine,[®] madone, physeptone and amidone It is habit-forming

Bronchocatharsis[5] is accomplished by so-called expectorants not only by facilitating expectoration but also by accelerating resorption of inflammatory exudate The latter process is carried out by digestion or dilution and liquefaction through the admixture of the secretions of the glands of the bronchial mucosa and the alveoli[21] Dehydration will prevent any expectorant from producing the proper results

Potassium Iodide Heading this list should be potassium iodide with the emphasis placed on the size of the dose The authors of two monographs on cough have stated that there is no evidence that this drug will increase the respiratory tract secretions This statement is in error as proved by direct visual observations of the respiratory tree through the bronchoscope before, during and after the oral administration of potassium iodide Hopkins[22] observed a dry bronchi become "wet" enough to aspirate the secretions fifteen to twenty minutes after the oral administration Herxheimer and McAllen[23] used potassium iodide intermittently in doses of 15 to 25 gr and produced a real increase in respiratory secretions Many other authors also confirm the value of this drug, but the literature fails to show that these benefits are obtained only when large doses are used The author finds that the dosage should start with 10 drops of a saturated solution, three times a day in water after meals, increasing one drop each day up to 30 drops, three times a day Beneficial results usually begin when the patient has reached 20 drops after each meal Iodine reactions are common and must be controlled promptly by omitting or reducing the dose The pH is lowered in the bronchi where the secretions present are diluted and made thinner and less viscid

Potassium iodide is not contraindicated in pulmonary tuberculosis as has been stated by some authors The thinning out of the secretions produces more sputum and floats out bacteria already present, but it does not cause reactivation or spread of the disease.

Ammonium Chloride The next most widely used expectorant is ammonium chloride Ammonium carbonate is better but must be dissolved in alcohol before adding to a vehicle This detail appears to be little known and for this reason it is rarely used This drug increases the respiratory tract fluid by reflex action on the stomach When the gastric branches of the vagus are cut, no action results Here again large doses must be used

Cass[24] compared terpin hydrate, ammonium chloride and aromatic syrup with glyceryl guaiacolate The latter contains 100 mg [illegible] losis patients was markedly superior to the others, causing marked increase in the respiratory tract secretions without increasing the volume of sputum

Combinations of drugs in suitable vehicles are numerous and space does not permit a detailed description However, the trade names and manufacturers of a few are given with a very brief comment (1) autosen[®] (E R Squibb & Sons) containing prophenyridamine maleate, codeine phosphate and alcohol for non-expectorant cough sedation, (2) extosen[®] (E R Squibb & Sons) containing prophenyridamine maleate, ammonium chloride and ephedrine sulfate, for asthmatic cough with thick mucus, (3) cosanyl[®] (Parke, Davis & Company) containing eight ingredients, the principle one being dihydrocodeinone bitartrate, used in dry, painful coughs, (4) benylin[®] (Parke Davis & Company) containing six ingredients, the principal of which is benadryl hydrochloride and ammonium chloride, for allergic cough where the sputum is very thick and in emphysematous patients,[16] (5) methajade[®] (Sharp & Dohme) containing five ingredients, the principal of which is methadone hydrochloride and an antispasmodic, used primarily in exhausting paroxysmal coughs, (6) coricidin syrup[®] (Schering Corporation) contains dihydrocodeinone bitartrate, chlortrimeton maleate, sodium salicylate, sodium citrate, caffeine and glyceryl guaiacolate, and is combined in a palatable syrup acceptable to all ages, (7) theophylline ethylenediamine plus diphenhydramine hydrochloride (hydrilin compound[®]) (G D Searle & Company) combines aminophylline with benadryl and is a most effective antihistaminic antitussive

Nauseant expectorants such as ipecac,

secretions and lessen the viscosity of the bronchial mucus However, except for ipecac in pediatrics, the entire group can be forgotten Ipecac will relax the smooth muscles in the bronchi but will not lower the pH

Demulcent expectorants such as syrup of acacia, licorice, glycerin, cane sugar, "cough drops," hot drinks are described at length in the English literature but are rarely prescribed in the United States These are primarily used by those who do not believe that the saline expectorants will increase the bronchial tree fluid Mildly irritating expectorants as creosotes (calcium creosote and creosote carbonate), guaiacol (potassium sulfonate in syrup), terpin hydrate, balsams of Tolu and Peru, tar and terpin are supposed to diminish bronchial secretions The first, creosote, is the only one worthy of mention This drug, given after meals in the form of calcreose® compound, is very efficient in bronchiectasis, bronchial asthma and emphysema It may well be said that if the other drugs "cure" the patient, he did not need a cough remedy in the first place except for psychologic reasons. Never forget that some coughs should not be stopped and that some will stop in a reasonable period without treatment Occasionally a simple upper [illegible]

a chain reaction long after the primary condition is gone This kind of cough is quickly cured by this type of expectorant

Antispasmodic drugs such as atropine, belladonna, stramonium, lobelia, hyoscyamus, epinephrine, ephedrine, nicotine and papaverine find a limited use The causative organisms of a common cold multiply best in a wet media The addition of atropine or belladonna to other supportive medication will greatly shorten the course of a common cold and add much to the relief of the patient

Coughing and dyspnea of emphysema may be greatly benefited by the use of small doses of ephedrine sulfate when combined with effective doses of aminophylline Orthoxine® (methoxyphenamine hydrochloride) (Upjohn Company) has less side effect and is about as effective as ephedrine The effectiveness of aminophylline is enhanced by the addition of antinausea agents as in dainite® (Irwin, Neisler & Company) and cardalin® (Irwin, Neisler & Company)

Strychnine, coramine® and cordiazol are said to promote expectoration but are rarely used

Gases Carbon dioxide aids in increasing the respiratory motion and, in turn, the removal of inflammatory products from the bronchi It is to be noted that shallow breathing found in debilitated patients, as an effect of general anesthesia, in depression of the respiratory center by narcotics or in anoxemia is harmful

Banyai[5] states that carbon dioxide benefits by (1) preventing exhaustive spells of coughing which gives more rest, (2) converting an unsuccessful cough into a successful cough, (3) increasing the amount of sputum which is made thinner, more serous and watery, and (4) reducing the need for other drugs and narcotics Its effectiveness is due to (1) stimulation of all muscles involved in breathing, [illegible] the ove-

Short inhalations of 5 to 10 per cent carbon dioxide with oxygen are most useful in increasing the rate of respiration and the volume of air in the lungs, in augmenting the auricular output of the heart, in raising the diastolic and systolic blood pressures, and in increasing the pulse rate and pulse pressure Contraindications for the use of carbon dioxide are (1) recent pulmonary hemorrhage, (2) marked emphysema, (3) widespread pulmonary fibrosis without atelectasis, bronchiectasis or mucopurulent retention in the air passages, (4) acute plastic pleurisy, (5) pleurisy with effusion, (6) hypertension and (7) coughs with source extrapulmonary in origin

Much has been said in this paper about the association of the bronchial secretions or fluid with cough The relatively new work of Arnold, Carbasi,[25] Segal and others[18 19] must be included in this discussion These authors refer frequently to the work of Barach, Beck and others in offering a new approach to removal of obstructive secretions from the bronchial tree with the use of oxygen under positive and negative pressure The procedure is not complicated but requires study and selectivity of patients When combined with bronchodilator

aerosols in asthma and chronic pulmonary emphysema, the results are gratifying The explosive passage of air out of the lungs brings with it sputum and secretions otherwise unexpelled Further use of the Eliot exsufflator with bronchodilator aerosols in chronic lung diseases is recommended in selected cases

Aerosol Antibiotics in aerosol therapy are used less and less having proved to be disappointing in results Antibiotics are efficient when given intramuscularly if the exudate, mucus and secretions in the bronchial tree are liquefied The object of the aerosol should be to liquefy the bronchial content and to shrink the mucous membrane of the entire respiratory system This promotes drainage and cleansing and better results from all medication The objections to antibiotics by aerosol are (1) They are not effective if the mucus and exudate are thick and purulent and antibiotics are not given intramuscularly or orally at the same time (2) They produce objectionable local reaction (increasing numbers of patients return after the second or third antibiotic aerosol treatment with an increased cough red and swollen mucous membrane and general discomfort) (3) The procedure cannot be carried out often enough to give its best results unless the patient is hospitalized Equally good results can be obtained from the use of oral or intramuscular antibiotics and a liquefying aerosol given once a day

Such a liquefying aerosol is exyethylated tertiary octylphenolformaldehyde polymer 0 125 per cent in combination with sodium bicarbonate 2 per cent and glycerin 5 per cent (alevaire® Winthrop Stearns Inc) It is combined with epinephrine 1 1000 by the author This combination has been found most effective in liquefying the mucus by lowering surface tension creating an alkaline media and shrinking the thickened mucous membrane Allergic manifestations seem to respond about as well as infections Antibiotic therapy given intramuscularly should always be used in the presence of infection

Varying combinations of the sympathomimetic drugs are acclaimed by various authors Racemic epinephrine hydrochloride (vaponefrin® Vaponefrin Company) or isopropylartenol hydrochloride (isuprel® Winthrop Stearns Company) appear to be efficient relaxors of bronchospasm One author[16] finds 0 5 cc of 2 25 per cent isuprel 0 5 cc of 1 per cent phenylephrine hydrochloride (neosynephrine Winthrop Stearns Inc) a bronchovasoconstrictor, and 0 5 cc of an aqueous solution containing 0 125 per cent of alevaire to be of excellent value in relieving cough in emphysema

For the sake of completeness the use of pancreatic desoxyribonuclease is mentioned in control of cough in the presence of bronchial infection bronchiectasis or tenacious purulent secretions [16] This enzyme called pancreatic dornase is used as an aerosol in addition to other measures such as pneumoperitoneum an

bir

may be effective in a small number of cases but are rarely used Immobilization of the cilia (the rate of movement of a foreign particle by the cilia is about 1 inch per minute) by the oil is a strong contraindication However it is recognized that a few patients with such conditions as bronchiectasis do occasionally obtain temporary relief Adequate supervised postural drainage is a necessity after the instillation

Antihistaminic drugs number more than 100 and are characterized by an indefinite knowledge of which one to use on any patient One allergist gives his patients the entire list with instructions to use one after the other until he finds one that gives the desired effect The relief is only temporary in any case Boyd[7]

found they are not beneficial in the common cold They should be reserved for use only in allergic manifestations Prigal[18] described the characteristics of an allergic cough as loud, barking and paroxysmal in nature It is relatively non productive and lasts an indefinite length of time The allergic cough rarely requires as much treatment as the other symptoms produced For this reason ACTH and cortisone and their derivatives are rarely mentioned as cough remedies although they are used frequently in the treatment of the over all condition

Radiation Therapy The indications for the use of x ray therapy and the method of its administration has not changed for many years It is usually reserved for those cases which fail to respond to other forms of treat

ment Radiation for chronic infections in the sinuses and throat aids in stopping the postnasal drainage that produces a large number of chronic coughs Mild radiation over the lungs destroys a certain amount of lymphoid tissue It is theorized that this breaking down of the lymphoid tissue liberates a protein like substance Relief from symptoms is slow in this type of treatment and the delay should be explained to the patient

Teaching the Patient Time and thought should go into the personal instructions to each patient This is just as important as medication Personal care is important in the management of chronic coughs Patients should be instructed to keep outside windows in sleeping quarters closed in damp or cool weather They should avoid changes in temperature as much as possible They should wear warm sleeping apparel at night and warm clothing during the day They should avoid drafts both at night and in the daytime and should avoid dust or other irritating inhalants at all times Exercise may well be restricted and smoking should be discontinued If possible they should avoid others who have respiratory infections Regular habits at all times and a maximum amount of mental and physical rest is helpful Every effort should be made to go into the [illegible]

in emphysema and its attendant cough but the patient must have specific instructions about the proper manner of applying them Postural drainage is never a successful procedure unless the patient is repeatedly instructed in the proper methods and time He should be taught that the sputum is better in a cup than in the lung that the more noise the less effective cough, and that constant hacking and hawking only irritate and make his condition worse

SUMMARY

1 Importance of cough as a symptom as viewed both from the health and economic standpoint is stressed Pathology of the cough mechanism is simplified by describing the causes and effects of harmful and helpful coughs Pathways of the cough reflexes are described Tussal insufficiency and tussive syncope are discussed

2 Surgical intervention, physiotherapy and postoperative prevention of atelectasis are discussed with reference to cough The role of cough in emphysema is described Common colds, "air conditioning" and the lack of acclimatization of the respiratory mucous membrane as a cause of cough are discussed

3 Drug therapy including morphine and its derivatives is described Bronchocatharsis and the use of such drugs as potassium iodide, ammonium chloride and others are described in detail A few of the common combinations of cough remedies are listed The use of antispasmodic drugs and gases including the use of carbon dioxide, is enumerated Positive-negative oxygen therapy in chronic pulmonary disease is reviewed and emphasized Inhalations and aerosols are evaluated, and newer [illegible]

REFERENCES

1 FINKE W Public health aspects and prevention of bronchopulmonary disease J A M A 151 105 108 1953

2 BANYAI A L Fifteen years experience with carbon dioxide in management of cough Dis of Chest 13 1 1947

3 BANYAI A L and CADDEN A V Carbon dioxide [illegible]

[illegible] 14 501 504 1952

6 BANYAI A L So-called hypertrophic emphysema [illegible]

84 845 856 1950

9 LEVINE S and GROW J B Unilateral loss of cough reflex following complete autonomic denervation of lung for bronchial asthma case J Thoracic Surg 21 121 124 1950

10 GREENE B A and BERKOWITZ S The prevention of atelectasis or pneumonia following abdominal operations Anesthesiology 14 166-170 1953

11 CERRATO C M and GRASSE L A Clinical evaluation of acetylpyrediniium chloride cough mixture *Delaware State M J* 25 165–178 1953

12 VAN LOON, E L Some aspects of chronic cough *J Am M Women s A* 8 181–186 1953

[illegible] treatment of cough *Am J* [illegible]

[illegible] hen ethane disulfonate as a [illegible] *tryngoscope* 63 1008–1013 1953

15 ABELMAN W H GAENSLER E A and BADGER T L Clinical evaluation of toryn *Dis of Chest* 25 532 1954

16 SEGAL, M S SALOMON A and HERSCHFUS J A Treatment of chronic pulmonary emphysema *Am Rev Tuberc* 69 915 1954

17 CASS L J and FREDERIK W S Evaluation of a new antitussive agent *New England M J* 249 132–136, 1953

18 RALPH N Evaluation of a new cough suppressant *Am J M Sc* 227 297 1954

19 CASS L J FREDERIK W S and ANDOSCA J B Quantitative comparison of dextromethorphan hydrobromide and codeine *Am J M Sc.*, 227 291, 1954.

20 BOYD E M and BUELL, M Methadone and respiratory tract fluid *Canad M A J* 63 588 590 1950

21 GORDONOFF T Physiology and pharmacology of expectoration *Ergebn d Physiol* 40 53 1938

22 HOPKINS W A Personal communication July 1954

23 HERXHEIMER H and MCALLEN M K Treatment of cough *Lancet* 1 1189–1190 1953

24 CASS L J and FREDERIK W S Comparative clinical effectiveness of cough medication *Am Pract & Digest Treat* 2 844 851 1951

25 ARNOLD W O and CARABASI R J Expiratory positive pressure oxygen therapy in chronic pulmonary disease *J A M A* 155 1329, 1954

26 SEGAL, M S SALOMON A and HERSCHFUS, J A. Alternating positive negative pressure in mechanical respiration *Dis of Chest* 25 640 1954

27 BOYD E M Cough medication and antihistaminic drugs *Canad M A J* 67 289–292 1952

28 PRIGAL, S J Allergic cough *Dis of Chest* 8 115 1942

X. BRONCHITIS, BRONCHOLITHIASIS AND BRONCHIAL FISTULA

27

Bronchitis

COLEMAN B RABIN, M D, *New York, New York*

Associate Physician and Associate Radiologist, Mount

BRONCHITIS is defined simply as inflammation of the bronchi In its superficial form, it involves simply the mucous membrane and the submucous glands, and this may be the only manifestation of the acute type of the disease In other instances the inflammatory process extends through the entire wall of the bronchus, into the surrounding lymphatics and from them into the perivascular tissues and the larger interlobular septa This occurs in the more severe forms of acute bronchitis which are associated with a more or less well developed phlegmonous interstitial inflammation of the lung Infiltration of the deeper structures also occurs in chronic bronchitis when it is associated with chronic interstitial pneumonitis

Bronchitis, as such, rarely occurs as an isolated disease without some underlying pathologic state or without disease in other parts of the respiratory tract These factors must be taken into account, both in the diagnosis and treatment of the condition Thus the presence of a bronchial stricture, a stone or a neoplasm will lead to chronic infection, not only of the bronchus but also of the lung distal to the point of obstruction The bronchitis simply may be part of a more diffuse respiratory infection, such as pneumonia tuberculosis or a fungus infection or it may be secondary to an infection in the upper respiratory passages The presence of an allergic state may predispose to recurrence or persistence of the bronchitis, and this must be recognized if the treatment is to be efficacious

In this exposition no attempt will be made to classify all of the causes of bronchitis, and the diagnosis and treatment of each one in particular, nor will the instances in which the bronchitis is of secondary importance be discussed However, stress will be laid on certain basic concepts that are important from the standpoint of diagnosis and treatment

BASIC CONSIDERATIONS

The ordinary form of acute bronchitis is undoubtedly caused by the virus associated with the common cold As such, it should run a short and uncomplicated course if additional factors, such as secondary infection or an underlying allergic state, are absent. This is the case in rhinitis with which the common cold begins, and which is short lived if no other factors come into operation

It is well known that viral infections of the respiratory tract are associated with a tendency to secondary infection with pyogenic organisms In the serious epidemics of influenza, a characteristic example of a virus infection in the human, comparatively few patients died from the effects of the influenza virus itself and these died within the first few days, presumably from the viral infection alone Those who died later succumbed to a diffuse suppurative disease of the lungs caused by secondarily invading streptococci and staphylococci This was well shown in the classical report of MacCallum on the pneumonias occurring in the Army camps during the First World War Similar examples of the implantation of serious infections by pyogenic bacteria on the soil modified by a virus infection are to be seen in the highly fatal distemper of dogs and the epidemic pneumonias of swine

The tendency to secondary purulent infections in the nasal mucous membrane, the paranasal sinuses, the hypopharynx, trachea

and bronchi also is to be ascribed to a lessening of the resistance to *ordinary bacteria in those* who are suffering from a virus infection/This concept has an important bearing on the prevention and treatment of acute bronchitis

In addition to the exudate and increased secretion within the bronchi there is frequently an associated spasm of the bronchial musculature Persistence of the infection in the bronchi as well as the occurrence of pulmonary complications may be ascribed in part to the obstruction of the bronchi by the secretions and the associated spasm Where there is an underlying allergic state the tissues tend to react both by an outpouring of thick tenacious secretion and by bronchial spasm Treatment must then be directed not only against the infection but also toward the thinning of the secretions and the relief of the spasm This will not only relieve respiratory distress but will also serve to shorten the duration of the disease and to prevent complications

When one considers the pathologic appearance of the bronchi in acute bronchitis the marked swelling of the mucous membrane and the amount of secretion that is present within the bronchial tubes the absence of severe dyspnea or of roentgen evidences of atelectasis *seems surprising But there are several mechanisms* that prevent these obstructive manifestations These are cough ciliary action and collateral respiration Cough that is productive must not be abolished by overdoses of medication In fact it is frequently necessary to induce cough in order to bring up the obstructing secretions particularly in the bronchitis that so often occurs after thoracic or abdominal operations Loss of ciliary action occurs from severe desquamation of the superficial epithelium from degeneration of these cells as a result of the infection and from interference with the motion of the cilia by thick secretions Naturally the treatment should be directed *toward control of infection and thinning of* the secretions

In the normal lung there are bronchiolar and alveolar communications which permit the passage of air from any portion of the lung to the neighboring alveoli Closure of a bronchial branch of a lobe of the lung therefore will not result in atelectasis of the alveoli supplied by that bronchus if the lung tissue is normal for the alveoli become distended by air from the neighboring pulmonary tissue This *collateral respiration* accounts for the absence *of any abnormality* on the roentgen film when there is obstruction of the bronchi by exudate in uncomplicated bronchitis When foci of atelectasis are noted on the film in bronchitis there is some complicating factor which prevents the collateral respiration This occurs when there is marked limitation of breathing because of pain in the chest immobility of the diaphragm in postoperative states or when there is edema of the alveolar septa as in cardiac failure or pneumonia

Collateral respiration occurs when even a single bronchus to a lobe remains patent It is important because it enables the cough to be effective The expulsion of secretion from the bronchi by cough depends upon the production of an increased pressure in the bronchus distal to the obstruction After the glottis is suddenly opened the marked difference in the pressure distal to the obstructing secretion and the atmospheric pressure on its proximal side results in the expulsion of the *secretion In* order for the straining action on the part of the patient during the initial phase of the cough to produce the high pressure in the bronchus beyond the obstruction it is necessary to have a sufficient quantity of air in the bronchus and lung beyond the obtruding mucus If this portion of the lung were completely *free of air* there would be no propulsive force applied to the mucus This is the case in which there is atelectasis beyond the obstruction *One can* readily understand therefore why in the presence of atelectasis cough is *ineffective* in bringing up the sputum On the other hand the air supplied by *collateral respiration* enters the obstructed portion of lung and acts as a medium through which the force of the cough is transmitted to eject the sputum

In postoperative states and in cases in which the lung is *either edematous or inflamed* there is little collateral respiration and atelectasis results Thus is also true when the main bronchus to a lobe is completely *obstructed* by mucus or exudate since there is no collateral *respiration between the lobes* which are separated by the pleural fissures *In such instances* it is necessary to permit air to enter the lung beyond the *obstruction in some way* or to extract the secretion by active *suction*

The use of bronchodilator *drugs* will permit some air to get by the *obstructing* mucus if the bronchi are sufficiently *dilated* Air may also

be forced beyond the obstruction by positive pressure Furthermore, the removal of some of the mucus by suction may open the bronchus sufficiently to permit air to pass by into the lung supplied by the partially obstructed bronchus The aeration of this portion of the lung now permits the cough to become effective in

normal conditions The sterility of this area is undoubtedly maintained largely by the action of the cilia which can rid the bronchial mucous membrane of small particles with amazing rapidity In bronchitis, however, ciliary action is interfered with and there is a tendency for a variety of organisms which descend from the mouth and throat into the bronchi, to stay there for a considerable period of time There fore, a mixture of bacterial flora is to be found in the secretion from inflamed bronchi

It is difficult, if not impossible, to determine which of these organisms, either acting alone or in symbiosis, is responsible for the secondary infection of the bronchi The results of cultures made to determine the predominating organism do not tell us which of them is actively engaged in producing the infection Furthermore, the possibility remains that the important bacteria are not even grown A knowledge of these facts is important in the choice of antibacterial drugs for it follows that in most instances the choice of the drug cannot be based on the results of cultures of the sputum

The physical character of the secretion or exudate often affects the clinical picture and the treatment to be employed Extremely thick secretion is present in the condition now known as *mucoviscidosis*, in which there is a particularly viscid quality to several of the secretions of the body, in addition to that of the bronchi The inability of the cilia to dispose of the thick secretion causes it to stagnate, and predisposes to secondary infection of varying degrees of severity Repeated infections extending to the lung, lead to changes which interfere with collateral respiration so that numerous small atelectatic foci result The extension of the chronic infection through the walls of the bronchi causes fibrosis of the peribronchial and interstitial tissues and of the atelectatic foci, and causes permanent crippling of the lung Similar changes may occur as a result of inability to expel the extremely thick secretion in patients with *bronchial asthma* In *postoperative states* stagnated secretion in the bronchi may become inspissated so that it cannot be expectorated, and this inevitably

exudate is made up largely of whorls of fibrin which may obstruct the main bronchus

ophil content of the blood, and numerous eosinophils are to be found between the interlacing threads of fibrin within the bronchial casts When a mild infection takes root in the lung beyond the bronchial cast, whether the latter be fibrinous or mucoid, a chronic granulomatous looking mass may appear in the lung This may so resemble a neoplasm that it has occasioned pulmonary resection in a number of instances

In children the caliber of the bronchi is so small that they are easily obstructed by the exudate and the swelling of the bronchial mucous membrane In the severe infection of the upper respiratory tract of infants known as acute tracheobronchitis, this obstruction is so severe that it may cause respiratory embarrassment sufficient to endanger life Here, the small size of the bronchi is the basic factor in the interference with pulmonary function

It is to be remembered that the bronchi widen during inspiration and narrow during expiration and that the narrowing during expiration becomes more pronounced when there is bronchial spasm Therefore, in the acute tracheobronchitis in infants and in the bronchial spasm in asthmatic patients there is difficulty in expiration The retention of air in the alveoli produces an acute emphysema and promotes a tendency to rupture of alveoli which are overdistended with air This may produce an *interstitial emphysema* of the lung which adds to the dyspnea, together with *mediastinal emphysema*, which may be associated with a pneumothorax

The inhalation of highly irritating gases causes an acute bronchitis accompanied by extreme bronchial spasm and may lead to permanent narrowing and perhaps destruction of small bronchi It may produce, in adults, the same complications as does acute tracheobronchitis in children

Chronic bronchitis tends to produce chronic emphysema of the lungs In part, this is the result of associated bronchial spasm in which an underlying allergic state often is a factor There is reason to believe that a vicious cycle operates here, in which the pressure of the air in the overdistended alveoli tends to produce further narrowing of the smallest bronchi, thus increasing and perpetuating the emphysema Certainly, patients with chronic bronchitis have a susceptibility to exacerbation of the bronchitis with bronchial spasm whenever they develop acute upper respiratory infections

DIAGNOSIS

Bronchitis is inevitably associated with increased bronchial secretion and generally with some degree of bronchial spasm One would therefore expect the production of sputum in significant quantities and the presence of bronchial rales It is a good rule never to make a diagnosis of bronchitis in a patient who has a dry cough and in whom no rales can be heard In such cases the impulse to cough practically always arises from the nerve endings in the pharynx and the diagnosis of bronchitis is often made erroneously, simply because the cough is a persistent one

Paroxysmal cough occurs in bronchitis only when there is bronchial spasm and then the wheezing rales and palpable rhonchi are evident In the patients whose cough is pharyngeal in origin, there is frequently a complaint of a tickling sensation in the jugular notch The cause of the cough then frequently lies in edematous lingual tonsils which obliterate the vallecular space After prolonged cough the patients may expectorate a small amount of mucus from the throat, and because of this the erroneous diagnosis of chronic bronchitis is frequently made despite the absence of bronchial rales

The response of the rales to coughing is a good indication of the cause of the wheezing Generally, sibilant and sonorous rales are classified as dry rales However, they are produced by mucus as frequently as they are caused by spasm or by a solid obstruction in a bronchus If the rales disappear promptly on coughing and the expectoration of secretion, it is safe to say that they are caused by the secretion If they persist, there is at least an element of bronchial spasm in their causation The presence of bronchial spasm may not be determined on auscultation when the patient is breathing quietly The wheezing rales become more noticeable if the patient is asked to breath forcibly Sometimes it is necessary to have the patient cough violently before bronchial spasm is produced

Care must be exercised to avoid confusion of the rales of bronchitis with those produced by an obstructing bronchial neoplasm a stricture or a foreign body In the latter instances the wheezing rales may be more pronounced during expiration, as in the case of bronchitis and the time honored emphasis on the inspiratory com

rarily on coughing because it is produced by a

minutes to determine whether the same rhonchus is again audible

It is characteristic of the neoplasm or foreign body in the bronchus that the rale has a single pitch at all times, and that it is most intense in the same place at several examinations On the other hand, in bronchitis which is a diffuse disease the rales are produced in various places in bronchi of varying caliber Therefore the rales are characterized by many pitches and vary in their intensity and location

In the treatment of bronchitis it is essential to determine some measure of the underlying cause Patients with chronic sinusitis are prone to recurring attacks of bronchitis Therefore the presence or absence of infection of the paranasal sinuses should always be determined In addition a search should be made for evidences of an underlying allergic state This can usually be determined by inquiry as to the

vasomotor rhinitis or of nasal polypi and the blood and sputum should be examined for eosinophilia It is also advisable to search for manifestations of allergy in patients with acute bronchitis, particularly if there is a history of frequent recurrences of this condition

The discovery of definite signs of bronchitis is sufficient indication for an x ray examination of the chest This will disclose immediately the presence of an associated pneumonia or of

pulmonary diseases which may be masked by the manifestations of bronchitis, such as

should be made for unusual organisms, particularly higher bacteria

Chronic bronchitis is sometimes confused with *bronchiectasis* It is rarely necessary to perform bronchography to differentiate these two conditions In bronchiectasis the patient expectorates more or less fluid, purulent sputum while in bronchitis the sputum has a tendency to be brought up in gobs, presenting a characteristic nummular appearance Whereas the patient with bronchiectasis coughs up the sputum on a few occasions during the day, the cough and expectoration is more or less constant in bronchitis Furthermore the patient who has suppurative bronchiectasis which is the form associated with cough, sputum and rales, will present changes on the x ray film referable to the disease while the x ray film in uncomplicated bronchitis shows no pulmonary infiltrations

ectasis, in fact, widening of the bronchi of a limited degree does occur in chronic bronchitis This produces a characteristic beaded or varicose appearance which is due to slight distention of the bronchial lumen between the cartilages While in a strictly pathologic sense this may be termed bronchiectasis it really represents only a mild stretching of the bronchial wall which is simply a part of chronic bronchitis In bronchiectasis there are other changes namely, destruction of bronchial branches and terminal saccul itions These prevent the bronchi from performing their natural function of carrying air to and from all parts of the lung and cause them to act as cesspools for the retention of pus In the absence of these changes one should not make the diagnosis of bronchiectasis

TREATMENT

The *most effective treatment for acute* bronchitis is the use of sulfa or antibiotic drugs The latter are generally more effective In the early stages in which the bronchitis is part of a virus infection, moderate doses are sufficient to prevent secondary infection with pyogenic organisms In the later stages when the sputum is purulent as a result of the secondary bacterial invaders, *larger doses are required* It is important to use drugs of a broad antibacterial range because one can never be certain as to the nature of the organism involved or its sensitivity to the drugs Tests of resistance or sensitivity of the bacteria may be misleading

In those cases in which the patient is known to be allergic, antihistaminic drugs may be most helpful However, if there is evidence of marked bronchial spasm, bronchodilator drugs are also necessary Cough depressants should be used in moderation and never to the point of complete suppression of the cough If the cough is constantly productive and there are no paroxysms of dry cough, they had best be omitted If the sputum is thick and tenacious and difficult to bring up, expectorants should be used The most effective is probably potassium iodide

Under this regimen most cases of acute bronchitis should clear within a week If there still remain symptoms or signs of the condition at the end of this time an x ray examination of the chest should be made, if this proves negative, the paranasal sinuses should be in-

condition found at the x ray examination of the chest should be investigated further and proper treatment instituted

If a rhonchus persists on one side of the chest bronchoscopy should be done to determine whether there is an obstructive lesion in a main bronchus not visible on the roentgen film Bronchoscopy should also be done if there is stridor without any audible or palpable rhonchi in order not to overlook a tracheal neoplasm

In the cases of acute tracheobronchitis of children, associated with severe dyspnea, it may be necessary to perform a tracheotomy because of associated laryngeal edema and inability of the patient to expectorate obstructing mucus Aspiration of the bronchi through *the tracheotomy* may prove to be a life saving measure The same procedure is required on rare occasions in bronchial obstruction by mucus in postoperative states in which the patient is unable to cough because of pain

associated with the operative procedure and because of the use of large doses of narcotic drugs required for the pain Most often, however, turning the patient from one side to the other, and supporting the patient's chest or abdomen, depending upon the location of the pain, and urging the patient to cough voluntarily, may be all that is necessary to have him bring up the sputum When the breath sounds are diminished on one side, it is best to have the patient lie on the opposite side, keeping the obstructed side up The tendency to more complete inflation of the lung on this side during inspiration may provide enough air beyond the obstruction to transmit the propulsive force of coughing to the obtruding mucus and result in its expulsion If the rhonchi persist or the patient becomes dyspneic, the mucus may be aspirated through a catheter inserted into the trachea and bronchi transglottically This maneuver always results in a paroxysm of coughing which may be even more productive than the suction through the catheter

Patients with chronic bronchitis should have the benefit of treatment with antibacterial drugs at the first evidence of any upper respiratory infection in order to prevent a severe exacerbation of the chronic bronchial infection In patients who already have some degree of pulmonary insufficiency such acute bronchial infections can produce a most severe anoxemia which may prove fatal It is obvious then that prompt and intensive treatment should be employed in all of these cases when they are complicated by an acute respiratory infection of any type

When an acute infection is established in a patient who has chronic bronchitis it is important to institute therapy on a broad basis Large doses of broad spectrum antibiotics, together with one of the sulfa drugs should be administered In addition, bronchodilator drugs should be employed When there is evidence of severe bronchial spasm or marked anoxemia due to obstruction by secretions, the use of positive pressure breathing by a suitable apparatus may be most helpful By this means air may be forced beyond the obstructing mucus to aid in the expulsion of the secretion In addition, nebulized antibiotics and bronchodilator drugs are forced into the bronchi Oxygen should be used with caution High concentrations should be avoided and the precaution should be taken to use the oxygen only intermittently, because the stimulus to respiration depends largely upon a certain degree of anoxemia If the breathing becomes shallow coramine by intravenous drip may be most effective Large doses of aminophyllin are also generally required to keep the bronchi dilated and this drug is best given through the intravenous drip at the same time

Much can be done for patients with chronic bronchitis and emphysema even between acute exacerbations. In those who expectorate purulent sputum, antibiotics given by mouth, injection and nebulization are most effective Patients with an allergic background may benefit from the antihistaminic drugs Bronchodilator drugs such as ephedrin and isuprel may be given by mouth or sublingually and aminophyllin may be administered by rectum When the sputum is not purulent and there is a tendency to considerable bronchial spasm the steroid drugs have been found to be quite helpful However, the precaution should be taken to administer simultaneously small maintenance doses of antibacterial drugs because of the diminished resistance to infection produced by steroids

28

Broncholithiasis

COLEMAN B RABIN, M D, *New York New York*

Associate Physician and Associate Radiologist Mount Sinai Hospital Assistant Clinical Professor Columbia University Consultant Physician Beth El Hospital and Veterans Administration Brooklyn Regional Office and East Orange Hospital

UNTIL recently broncholithiasis was considered a medical curiosity because of its supposed rarity The diagnosis was generally made only when the patient expectorated one or more stones or when the condition was found at autopsy There was little done in the way of treatment except in an occasional rare case in which the stone was extracted through the bronchoscope In general, it was thought that bronchial calculi were the result of either a general metabolic disturbance or were secondary to bronchial or pulmonary diseases which were the major problem

We know today that broncholiths are due to local disease rather than to a disturbance of the general metabolism and that in the main the pulmonary and bronchial diseases associated with the stones are secondary to them It has now been quite definitely established that the calculi have their origin in calcified lymph nodes adjacent to the bronchi and that they find their way into the bronchial lumen by eroding the bronchial wall which then becomes either strictured or obstructed by the stone It is therefore, this local obstructive lesion in the bronchus which is responsible for the pulmonary disease distal to it

The frequency with which broncholithiasis occurs is evidenced by several reports on this subject based upon fairly large groups of cases In fact, our own experience at the Mount Sinai Hospital relates to no less than eighty cases of this condition The complications of

through the bronchoscope and, in others by resection of the secondarily affected area of the lung together with the bronchus bearing the stone

The frequency of broncholithiasis its seriousness and the fact that it is amenable to treatment make its recognition important Furthermore, it is necessary that the situation of the lesion be localized accurately before bronchoscopy and that the diagnosis be made before operation if these procedures are to be carried

carcinoma It is important to make the differentiation from this disease if a proper choice of treatment is to be made

The diagnosis of broncholithiasis can generally be made with a considerable degree of

the choice of therapy

PATHOGENESIS

It has been stated that broncholithiasis begins in a calcified lymph node that lies adjacent to a bronchus In this part of the country the calcified lymph nodes are generally due to the first infection type of tuberculosis In the Mississippi Valley they are perhaps more frequently caused by histoplasmosis and this may be the underlying disease in that section of the country The lymph nodes most frequently causing the condition are those located in the angle between the middle and the right lower lobe bronchi The nodes here are wedged within an acute angle made by these bronchi and the perforation of the bronchial wall is apt to occur through the posterior surface of the middle lobe bronchus where it is not protected by cartilage The thick cartilaginous anterior wall of the lower lobe bronchus is more resistant and is rarely involved A similar relationship is

associated with the operative procedure and because of the use of large doses of narcotic drugs required for the pain Most often, however, turning the patient from one side to the other, and supporting the patient's chest or abdomen, depending upon the location of the pain, and urging the patient to cough voluntarily, may be all that is necessary to have him bring up the sputum When the breath sounds are diminished on one side, it is best to have the patient lie on the opposite side, keeping the obstructed side up The tendency to more complete inflation of the lung on this side during inspiration may provide enough air beyond the obstruction to transmit the propulsive force of coughing to the obtruding mucus and result in its expulsion If the rhonchi persist or the patient becomes dyspneic, the mucus may be aspirated through a catheter inserted into the trachea and bronchi transglottically This maneuver always results in a paroxysm of coughing which may be even more productive than the suction through the catheter

Patients with chronic bronchitis should have the benefit of treatment with antibacterial drugs at the first evidence of any upper respiratory infection in order to prevent a severe exacerbation of the chronic bronchial infection In patients who already have some degree of pulmonary insufficiency, such acute bronchial infections can produce a most severe anoxemia which may prove fatal It is obvious then that prompt and intensive treatment should be employed in all of these cases when they are complicated by an acute respiratory infection of any type

When an acute infection is established in a patient who has chronic bronchitis, it is important to institute therapy on a broad basis Large doses of broad spectrum antibiotics, together with one of the sulfa drugs should be administered In addition, bronchodilator drugs should be employed When there is evidence of severe bronchial spasm or marked anoxemia due to obstruction by secretions, the use of positive pressure breathing by a suitable apparatus may be most helpful By this means, air may be forced beyond the obstructing mucus to aid in the expulsion of the secretion In addition, nebulized antibiotics and bronchodilator drugs are forced into the bronchi Oxygen should be used with caution High concentrations should be avoided and the precaution should be taken to use the oxygen only intermittently, because the stimulus to respiration depends largely upon a certain degree of anoxemia If the breathing becomes shallow coramine by intravenous drip may be most effective Large doses of aminophyllin are also generally required to keep the bronchi dilated and this drug is best given through the intravenous drip at the same time

Much can be done for patients with chronic bronchitis and emphysema even between acute exacerbations In those who expectorate purulent sputum, antibiotics given by mouth, injection and nebulization are most effective Patients with an allergic background may benefit from the antihistaminic drugs Bronchodilator drugs, such as ephedrin and isuprel may be given by mouth or sublingually and aminophyllin may be administered by rectum When the sputum is not purulent and there is a tendency to considerable bronchial spasm, the steroid drugs have been found to be quite helpful However, the precaution should be taken to administer simultaneously small maintenance doses of antibacterial drugs because of the diminished resistance to infection produced by steroids

Bronchol ithiasis

COLEMAN B RABIN M D New York, New York

Associate Physician and Associate Radiologist Mount Sinai Hospital Assistant Clinical Professor Columbia University Consultant Physician Beth El Hospital and Veterans Administration Brooklyn Regional Office and East Orange Hospital

UNTIL recently bronchol ithiasis was considered a medical curiosity because of its supposed rarity The diagnosis was generally made only when the patient expectorated one or more stones or when the condition was found at autopsy There was little done in the way of treatment except in an occasional rare case in which the stone was extracted through the bronchoscope In general it was thought that bronchial calculi were the result of either a general metabolic disturbance or were secondary to bronchial or pulmonary diseases which were the major problem

We know today that bronchol iths are due to local disease rather than to a disturbance of the general metabolism and that in the main the pulmonary and bronchial diseases associated with the stones are secondary to them It has now been quite definitely established that the calculi have their origin in calcified lymph nodes adjacent to the bronchi and that they find their way into the bronchial lumen by eroding the bronchial wall which then becomes either structured or obstructed by the stone It is therefore this local obstructive lesion in the bronchus which is responsible for the pulmonary disease distal to it

The frequency with which bronchol ithiasis occurs is evidenced by several reports on this subject based upon fairly large groups of cases In fact our own experience at the Mount Sinai Hospital relates to no less than eighty cases of this condition The complications of the disease namely hemorrhage and infection distal to the stone are attended with a considerable degree of mortality Cure may be effected in some cases by removal of the stone through the bronchoscope and in others by resection of the secondarily affected area of the lung together with the bronchus bearing the stone

The frequency of bronchol ithiasis its seriousness and the fact that it is amenable to treatment make its recognition important Further more it is necessary that the situation of the lesion be localized accurately before bronchoscopy and that the diagnosis be made before operation if these procedures are to be carried out to the best advantage of the patient In many cases the clinical and radiologic picture is quite similar to that of bronchiogenic carcinoma It is important to make the differentiation from this disease if a proper choice of treatment is to be made

The diagnosis of bronchol ithiasis can generally be made with a considerable degree of accuracy if the pathogenesis as well as the clinical and roentgen features of the disease are thoroughly understood These will be discussed in the order named before discussing the methods of diagnosis indications for treatment and the choice of therapy

PATHOGENESIS

It has been stated that bronchol ithiasis begins in a calcified lymph node that lies adjacent to a bronchus In this part of the country the calcified lymph nodes are generally due to the first infection type of tuberculosis In the Mississippi Valley they are perhaps more frequently caused by histoplasmosis and this may be the underlying disease in that section of the country The lymph nodes most frequently causing the condition are those located in the angle between the middle and the right lower lobe bronchi The nodes here are wedged within an acute angle made by these bronchi and the perforation of the bronchial wall is apt to occur through the posterior surface of the middle lobe bronchus where it is not protected by cartilage The thick cartilaginous anterior wall of the lower lobe bronchus is more resistant and is rarely involved A similar relationship is

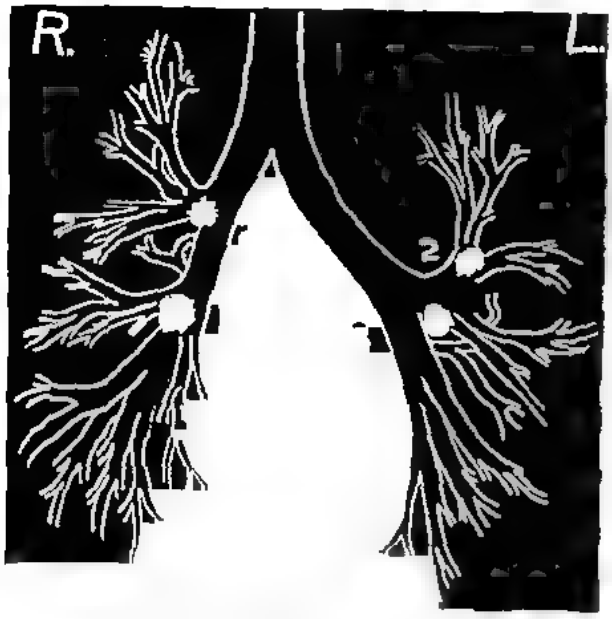

FIG 1 MOST COMMON LOCATION FOR STONES
1 Middle lobe 2 Anterior segment of upper lobe
3 Apical posterior segment of left upper lobe

present at the point of origin of the anterior and lingular division of the upper lobes and these therefore, are also common sites for perforation of the calcified nodes Thus fully three-fourths of all the cases of broncholithiasis occur in the above locations Most of the remainder are to be found at the origin of the other segmental bronchi at which point lymph nodes are also found

The calcified node need not perforate entirely through the wall of the bronchus to lie free within the bronchial lumen (*endobronchial lithiasis*), in order to produce symptoms and bronchial obstruction It may remain within the wall of the bronchus and bulge into its lumen while the mucous membrane over it lies intact and yet produces complications Bleeding may occur from distended blood vessels in the overlying mucous membrane and the bronchial narrowing produced by the bulging mucosa may result in atelectasis, bronchitis and infection of the lung distal to this region Such stones which lie within the wall of the bronchus are examples of *intramural* broncholithiasis

When the stone perforates completely through the bronchial wall and lies within its lumen, a constant ulceration of the bronchial mucous membrane results The ulceration in the endobronchial form of lithiasis predisposes to more serious hemorrhage and greater likelihood of infection than the intramural form in which the mucous membrane may be intact. The irritation of the stone and the local infection of the bronchus about it produces an overgrowth of granulation and scar tissue which easily obscures the stone at bronchoscopy

[illegible]

sis, the formation of suppurative areas and cavities of varying size, and infection of the pleura, all of which tend to obscure the basic disease

CLINICAL FEATURES

The disease may occur at almost any age but is most frequent in the fourth and fifth decades It is unusual in children because it takes several years for the lymph nodes which are responsible for the disease, to undergo calcification In our experience the most common age at the onset of symptoms has been forty years

Cough is the most frequent symptom and is practically universal Hemoptysis occurs in three-fourths of the cases, and its character is somewhat different from that of the blood spitting that occurs in bronchiogenic carcinoma Whereas in the latter disease the patient characteristically expectorates blood mixed with sputum, in broncholithiasis the patient generally complains of episodes of expectoration of pure red blood Such bleeding also occurs in bronchial adenoma and in tuberculosis, but its rarity in carcinoma is helpful in the differential diagnosis from that disease Massive hemoptysis is not uncommon and occurred in about 30 per cent of the cases which we have observed It may be so severe as to result in death

Fever caused by infection of the lung distal to the stone is a common manifestation and occurred in over one half of our cases It is almost always associated with chest pain resulting from a pleuritis over the infected portion of lung Often the fever is recurrent as a result of re-activation of the pulmonary infection Frequently the occurrence of fever is concomitant with a cessation of the cough and sputum as the bronchus is completely obstructed by the stone In this respect the [illegible] differs

pleural pain and fever without expectoration it may be thought that the patient has suffered simply from recurrent attacks of pleurisy

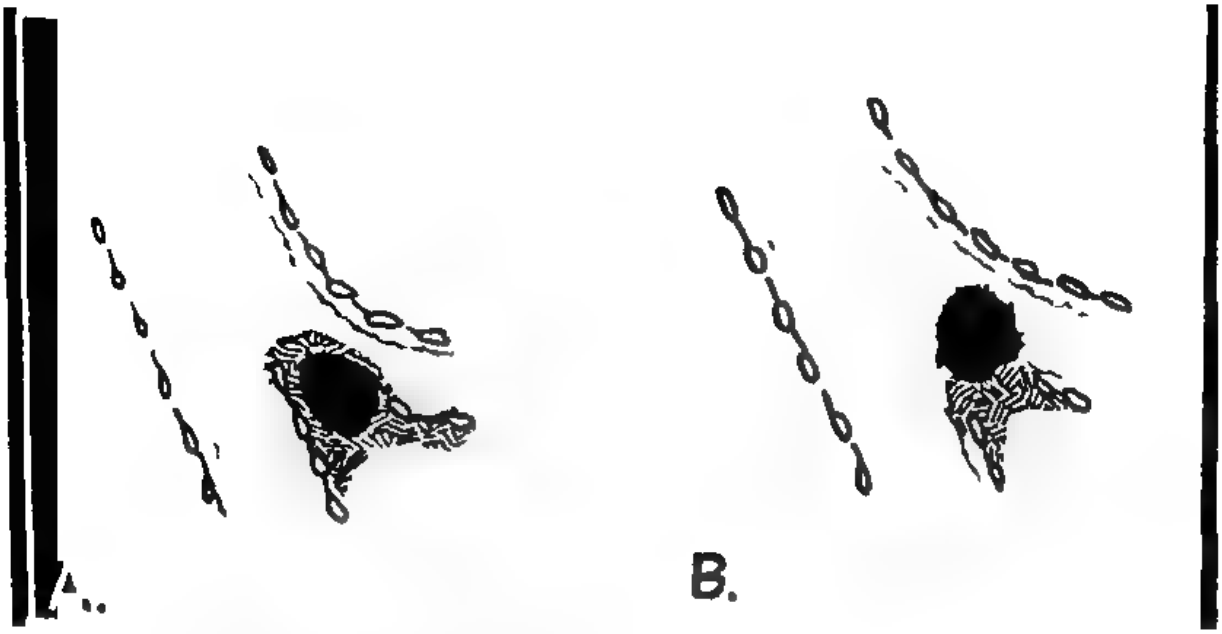

FIG. 2. A. *INTRAMURAL STONE.* The calcified node lies partly within the wall of the bronchus and narrows its lumen. It is covered by intact bronchial mucous membrane.

B. *ENDOBRONCHIAL STONE.* The stone has ulcerated through the bronchial mucous membrane and lies within the lumen of the bronchus.

In rare instances the presenting symptom is related to a pleurisy with effusion. The latter may be purulent and the case confounded with that of a postpneumonic empyema or with that of a simple perforated lung abscess. The latter error may be made particularly when the sputum is foul.

ROENTGEN FEATURES

The obvious roentgen manifestation in most of the cases is the presence of an area of atelectasis and infiltration in a part of the lung. In 50 per cent of the cases the involved area is in the middle lobe which appears collapsed and infiltrated. This often leads to the diagnosis of the so-called "middle lobe syndrome." In one-fourth of the cases the anterior or lingular segment of the upper lobe has been involved. In some the posterior or apical segment of the upper lobe, or the superior segment of the lower lobe has been the site of the disease. We have also seen rare instances of atelectasis and infection of an entire lobe. The involved portion of the lung may exhibit cavitation and there may be a pleural effusion of lesser or greater extent.

The calcific deposit in the bronchus or bronchial wall can always be visualized radiologically but it may not be evident on ordinary films. Practically always, however, the broncholith can be seen on films made with sufficient exposure to penetrate the overlying consolidated and infiltrated lung whose shadow may otherwise obscure the calcific deposit.

Of course, the presence of calcific deposits near the root of the lung is a most frequent finding on roentgen films, and little clinical significance should ordinarily be attached to this finding alone. If, however, the calcification can be demonstrated to be situated directly at [illegible] deposits are noted near the root of a pulmonary segment which is shrunken, infiltrated or the seat of cavitation, one must make a special effort to determine the exact relationship of the calcification to the bronchus leading to the diseased area. For this purpose oblique as well as lateral views are required. If on all of these projections the calcific deposit is seen to maintain its relationship to the root of the diseased portion of the lung, the possibility of bronchol ithiasis must be strongly suspected. In some cases sectional radiography may be required to demonstrate the relationship of the calcific deposit to the bronchus supplying the involved

part of the lung Bronchography may be useful in showing an obstruction to the flow of the radio-opaque material directly at the site of the calcific deposit

BRONCHOSCOPIC FEATURES

In most cases of broncholithiasis the site of the lesion can be visualized through the bronchoscope However more frequently than not the stone itself cannot be seen This is the reason why bronchoscopic observation alone is generally insufficient for diagnostic purposes in most patients with broncholithiasis What is usually seen is only the narrowing of the bronchus immediately proximal to the stone Where the stone is within the lumen it is generally obscured by granulation tissue which blocks the concretion from view

The site where the stone is most easily accessible is just within the orifice of the middle lobe bronchus This fortunately is by far the most common single location for broncho lithiasis There may be visualized only a bulge of the mucous membrane at the lower lip of the middle lobe orifice often extending to the anterior wall of the lower lobe This may indi cate an intramural type of stone which has not yet eroded through the bronchial mucous mem brane but which causes a narrowing at the mouth of the middle lobe bronchus A similar appearance may be found at the orifice of the anterior or of the lingular division of the upper lobe in which instance the bulge may extend to the adjacent part of the upper lobe bronchus

If granulation tissue is visible it may be cut away thus exposing the stone or it may be possible to dilate the bronchus and to feel the grating of the stone against the instrument If no stone is found a biopsy is made at the site of the stricture This may uncover the concre tion In any event the biopsy will prove the inflammatory nature of the disease Occasion ally after a biopsy has been made the patient may expectorate the stone within a few days even though it has not been seen through the bronchoscope At times the manipula tion may result in loosening of the stone which can then be recovered at a subsequent bronchoscopy

DIAGNOSIS OF BRONCHOLITHIASIS

The diagnosis of broncholithiasis is quite definite when the patient volunteers a history of expectorating one or more stones However such a history may not be forthcoming unless the patient is asked directly whether he has ever expectorated a stone and even then he may not recognize the fact that he has done so unless he is carefully questioned and the ap- pearance of a broncholith is described to him Moreover patients have been known deliber ately to withhold the information that they have brought up a stone until they have been questioned very closely

The suspicion of broncholithiasis is aroused by the discovery of a calcific deposit in relation to a lesion in the middle lobe or to one of the pulmonary segments This should be sought for in all patients with such a lesion and in whom the diagnosis is not perfectly clear

Once the suspicion has been aroused x ray films should be made in various views to deter mine the exact relationship of the stone to the involved lung If the calcific deposit cannot be seen on the proper views the Potter Bucky diaphragm should be employed and if good visualization is not obtained by this method sectional radiography is required The demon stration radiologically that the calcific deposit lies at the apex formed by the root of the d s eased portion of the lung constitutes presump tive evidence that the patient has broncho- lithiasis This presumption usually turns out to be correct in disease of the middle lobe and the anterior or lingular segments of the upper lobe However it may prove to be wrong on further investigation

Confirmation of the diagnosis of broncho- lithiasis is usually obtained at bronchosco either by the discovery of the stone itself or of an inflammatory stricture at the exact site where the concretion was seen on the roent genograms Neoplastic disease must always be excluded by biopsy at the site of the bronchia narrowing Where the lesion lies beyond th reach of the bronchoscope confirmation of th diagnosis may be obtained by selective bro chography of that portion of the lung which diseased Demonstration of an obstruct on the iodized oil at the exact site of the concretion on the film may be considered as confirmation of the diagnosis of broncholithiasis

It is most important to make the diagnos s of broncholithiasis definite by these methods before resorting to exploratory operation Un fortunately, the findings at thoracic explorat on are often so difficult to evaluate that the d ag

nosis of broncholithiasis and the exclusion of a neoplasm may be impossible at the operating table Generally, the structures of the lung root are matted together and the appearance is so suggestive of neoplastic disease that a definite diagnosis cannot be made before either the entire lung or a considerable portion of it has been removed for examination

TREATMENT

Bronchoscopy serves as a therapeutic as well as a diagnostic procedure In about 25 per cent of the cases the stone may be removed through the bronchoscope In most of these cases the patient's symptoms are relieved and further complications are prevented even though residual fibrosis and atelectasis may remain

In the remainder of the cases, some judgment should be exercised in the determination of further treatment, keeping in mind that resection of the lesion is often a difficult procedure fraught with considerable danger from hemorrhage and often necessitates the removal of a large amount of healthy lung In patients who have had no symptoms and in those who have had only an occasional hemoptysis, it is best to withhold operative treatment and simply keep the patient under observation In such cases the stone is often intramural, the bronchial mucous membrane is not extensively ulcerated and there is comparatively little danger of serious pulmonary infection On the other hand, where there is a history of large hemorrhage, frequent harrassing cough, or recurrent pulmonary infection or suppuration, the outlook is grave unless the lesion is resected

In such instances it is generally necessary to perform a more extensive resection of the lung than would appear to be necessary at first glance Thus the lower lobe may have to be removed together with the middle lobe, even though only the latter appears diseased This is frequently required because of the extensive inflammatory disease at the lung root accompanying the perforated calcified node and which makes separation of the structures a difficult technical procedure The necessity for extensive resection in this disease is exemplified particularly in those cases in which only a segment of the lung is involved It is generally technically impossible to remove the segment together with the bronchial stricture and stone while preserving the rest of the lobe Lobectomy is therefore required in most instances even though the disease is confined to a single segment

At times the difficulty encountered is so great and bleeding so difficult to control, that even pneumonectomy may be required for the eradication of what appears to be a lesion of minor extent Because of these difficulties it is obvious that operative treat-

avoided c

not k

tysis,

occur

chronic suppuration

29

Bronchial Fistulas

J Winthrop Peabody, Jr, M D, Sol Katz, M D, and Edgar W Davis, M D, Washington D C

Fistulous connections with the tracheobronchial tree may arise from many extrapulmonary sources each unusual enough to be of interest yet as a group not so rare as to be devoid of practical importance In their approximate order of decreasing frequency the following types of bronchial fistula have been described [1] (1) bronchopleural fistula, (2) bronchoesophageal fistula, (3) bronchosubphrenic fistula, (4) bronchobiliary fistula, (5) bronchoperinephric fistula and (6) bronchocolic fistula

Bronchopleural Fistula Not too long ago tuberculosis was by far the most common cause of bronchopleural fistulas Especially was this true of patients treated by artificial pneumothorax about 5 per cent of whom developed this complication [2] However, following virtual abandonment of this form of therapy along with the advent of effective antituberculous chemotherapy, the incidence of tuberculous bronchopleural fistula has been tremendously reduced probably well below that reported in 1939 by Auerbach and Lipstein[2] who found 7 8 per cent fistulas among 1,000 autopsied patients dying of pulmonary tuberculosis Nevertheless even though the majority of tuberculous bronchopleural fistulas seen nowadays are complications of resective surgery, one still sees an ample number among those with far advanced pulmonary tuberculosis untreated either by excisional or collapse measures

Insofar as inflammatory causes of bronchopleural fistula are concerned, non tuberculous infections now outrank the tuberculous Various pulmonary diseases particularly anaerobic infections such as putrid lung abscess, bronchiectasis and suppurative gangrenous pneumonia or pneumonias due to certain aerobes like staphylococcus streptococcus, H influenza or Friedlander's bacillus are apt to be complicated by a bronchopleural fistula Chronic granulomatous processes like the mycoses have also been incriminated

Other causes include carcinoma and trauma Spontaneous pneumothorax, itself a fistula between the bronchi and pleural cavity is not regarded as a bronchopleural fistula in the usual sense of the term Of course a persistent air leak may convert a spontaneous pneumothorax into a true bronchopleural fistula This last distinction serves to emphasize that the significance of a fistula lies not in the communication itself but in its complications which include (1) tension pneumothorax, (2) empyema and (3) bronchial aspiration of pus Initially at least, treatment must be directed at these complications rather than at the fistula *per se*

In much the same way the type of complication will influence the symptomatology When a tension pneumothorax develops the chief and perhaps only symptom is dyspnea Physical findings are often significant in the severe case consisting of tympany, absent breath sounds and fullness of the affected side with bulging of the intercostal spaces Dyspnea may be severe enough to render x ray impossible and prompt treatment imperative

Where pressure relationships are not so markedly altered, the first sign of a bronchopleural fistula is apt to be the expectoration of pleural fluid or pus The patient soon becomes aware of the influence that position exerts on the productivity of his cough When the pleural fluid level is above the fistulous orifice the patient expectorates fluid, when it is below the orifice he does not When lying with the involved side up he may raise fluid, whereas in the erect position or when lying with the involved side down, expectoration of fluid or pus may be alleviated Obviously the size of the fistulous connection will play a big part in determining the amount and adequacy of transbronchial drainage

While diagnosis of a bronchopleural fistula may be suggested by the symptomatology, in some instances the fistula may remain silent even in the face of an established empyema

This was particularly true of tuberculous bronchopleural fistulas evolving under an artificial pneumothorax and it is claimed that about one third of those were demonstrable only by gas analysis of the pleural air [2] Ordinarily the simplest means of proving the presence of a fistula is the introduction of 5 to 10 cc of methylene blue into the pleural space but even in the face of an open fistula the dye may not appear in the sputum This is a point worth emphasizing because of thirty four cases of fistula proved at autopsy who had had methylene blue injected during life there were only twenty two instances (65 per cent) in which the dye appeared in the sputum in the series of 1 000 autopsied cases of pulmonary tuberculosis referred to previously [3] This may be due to a number of factors chief among which are the minute size of some fistulas and the tendency for a multiloculated pleural space to exclude the injected dye from the fistulous tract Even so this is easily the most widely used method of

may have to wait a few minutes for air to rebuild within the pleural space and tension can sometimes be shown to build up more quickly by coughing In some instances the fistula may be elusive enough to necessitate recourse to gas analysis of the pleural air a procedure once used quite extensively in the evaluation of artificial pneumothorax After the introduction of atmospheric air for example carbon dioxide will diffuse into the space and oxygen will diffuse out until an equilibrium is established After twenty four hours any elevation of the oxygen content above 5 volumes per cent with a carbon dioxide content below 6 volumes per cent indicates a replenishment of pleural air by alveolar air in other words a bronchopleural fistula Although this is a satisfactory means of detecting the more subtle type of fistula it is seldom necessary nowadays its field of usefulness being restricted solely to artificial pneumothorax

The treatment of any bronchopleural fistula will vary of course with the etiology size location and duration of the communication Closed tube drainage is generally indicated followed later by resection or thoracoplasty should spontaneous closure of the fistula not ensue For chronic fistulas with long standing empyema referring particularly to those due to tuberculosis an extrapleural pneumonectomy or in some instances a more limited resection combined with decortication may be indicated For the average bronchopleural fistula seen today however, if specific infection can be demonstrated and adequate drainage plus appropriate drug therapy will ordinarily achieve a satisfactory result without recourse to more vigorous surgical measures On the other hand when there is underlying tuberculosis an outlook as optimistic as that is hardly justified

Bronchoesophageal Fistula The best known or at least the most discussed of all bronchial fistulas are the tracheoesophageal fistulas of congenital origin Because they entail a unique and decidedly different problem congenital fistulas are not germaine to this discussion yet it is worth mentioning in passing that an occasional case of this sort without associated esophageal atresia may survive infancy untreated and actually develop symptoms only

unexplained fistula

Over half of all acquired bronchoesophageal fistulas are due to cancer and are therefore clearly unsalvagable A small but significant

all been reported as etiologic factors Of the infectious causes tuberculosis is the one most frequently cited but any granulomatous infection may be responsible The pathogenesis of tuberculous fistulas is best explained on the basis of erosion from caseating or calcified tracheobronchial or mediastinal lymph nodes

often in the past but must certainly be an exceedingly rare cause at present A most unusual way in which syphilis can lead to fistula formation is by pressure necrosis secondary to a luetic aneurysm In other isolated instances actinomycosis and blastomycosis have produced bronchoesophageal fistulas

Traction diverticula of the esophagus have been cited as a causative factor in a substantial number of cases Inasmuch as most esophageal diverticula result from periesophageal inflammation secondary to chronic mediastinal lymphadenitis it would seem that subsequent development of a bronchoesophageal fistula might more properly be blamed on the lymphadenitis rather than on the diverticulum Such a conclusion seems particularly justified when the contiguous lymph nodes are calcareous and incontestible when there is a history of having expectorated broncholiths Thus although broncholithiasis is seldom thought of as a cause of tracheoesophageal fistula our own experience suggests the contrary[5] One might argue in fact that only broncholithic erosion would account for the much higher incidence of acquired non malignant fistulas on the right side a distribution opposed to what would be expected from the closer proximity between the left stem bronchus and the esophagus but consistent with the location of a calcified complex more commonly on the right

The location diameter and direction of any particular fistula will determine the clinical picture In the typical case the chief complaint is a choking sensation after the ingestion of liquid and in some instances after swallowing solids as well Eventually as a result of continual tracheobronchial contamination recurrent pneumonia and bronchiectasis ensue and cough may then occur independent of fluid intake Rarely do these patients maintain a satisfactory nutritional state and death is generally inevitable if left untreated Hemoptyses often massive are prone to occur and may provide the immediate cause of death[6]

History alone should suggest the diagnosis yet Coleman and Bunch[7] have reported four patients under observation for periods ranging from ten months to eight years before the correct diagnosis was established

Radiographic delineation of the fistula can usually be obtained by introducing iodized oil into the esophagus In addition to outlining the tract a bronchogram may result Barium is best avoided if a fistula is suspected At esophagoscopy or bronchoscopy the fistulous opening can sometimes be visualized If not the instillation of methylene blue into the esophagus during bronchoscopy may identify the involved bronchus by dye issuing from the opening Repeated roentgenographic study may be necessary, and even when these are negative a fistula is not necessarily ruled out

All too often the surgical implications of such a fistula are not appreciated It is true that on occasion cauterization of the esophageal end of the fistula has resulted in apparent cure but there is little doubt that the best definitive approach to these lesions is thoracotomy with division and suture of the fistulous tract Chronically diseased portions of the involved lung can simultaneously be resected The results with this technic have been highly satisfactory

Bronchosubphrenic Fistula Until one has seen a subdiaphragmatic hepatic or perinephric abscess traverse the diaphragm and drain transbronchially the possibility of purulent expectoration originating from extra rather

statistics of Ochsner and De Bakey[8] who in a review of 1 380 cases of subphrenic abscess found 10 5 per cent to be associated with a bronchial fistula So emphatic are some authors[9] that they consider thoracic complications to be the rule whenever surgical intervention is too long delayed Thanks to modern chemotherapy and improved surgical technics the incidence

Prior to the development of such a fistula the patient presents the local and systemic manifestations of an undrained abscess Coincident with perforation into a bronchus he suddenly begins to cough up large quantities of pus As emphasized by Head and Hudson[9] this is always a difficult and trying experience and is occasionally more than a debilitated patient can stand even to the extent of drowning in pus Pulmonary contamination may invoke a severe and sometimes fatal bronchopneumonia If the patient survives these immediate hazards however fever cough and expectoration may all gradually subside and rarely spontaneous recovery may ensue

More commonly the patient follows a septic course with persistent cough and expectoration which may cease from time to time due to plugging of the fistula Characteristically the degree of fever parallels the adequacy of bronchial drainage Suggestive as this description may be the most revealing clue would be a

preexisting history of an inciting course, whether it be a perforated viscus appendicitis carcinoma, peritonitis or any other type of intra abdominal infection operation or injury

The typical roentgenographic finding is an elevated hemidiaphragm with or without an air fluid level beneath Above the diaphragm the picture is more variable There may be nothing more than pleural thickening at the base More often than not there is no evidence of a true empyema, the perforation being directly into the lung through a site of pleural symphysis set up earlier by the presence of pus beneath the diaphragm [10] As might be expected the pulmonary findings are mainly confined to the lower lobes and are quite inconstant The occurrence of copious sputum in the presence of fever but disproportionately little radiographic evidence of pleuropulmonary involvement raises the possibility of an underlying bronchosubdiaphragmatic fistula [10] A negative bronchogram renders this possibility all the more likely If after inducing a pneumoperitoneum the undersurface of the suspicious hemidiaphragm cannot be delineated by air further support is gained for the presence of pus beneath the diaphragm

The treatment is essentially the same as for the uncomplicated subphrenic abscess namely incision and drainage of the involved subdiaphragmatic compartment Inasmuch as the diaphragmatic pleura is commonly fused in these cases low transpleural transdiaphragmatic drainage may be a perfectly acceptable procedure For complete rehabilitation it is occasionally necessary to carry out pulmonary resection in order to eradicate persistent symptoms arising from irreversibly damaged lung

Bronchobiliary Fistula The expectoration of bile is an astonishing development so improbable an occurrence that of all bronchial fistulas those between the biliary tract and bronchial tree hold perhaps the greatest fascination The dramatic nature of such a lesion accounts no doubt for the sixty four cases found in the literature [11] a relatively large number when compared with their extreme rarity in

F most
es
ut
and echinococcu
many other causes have been described a ong
them various types of hepatic suppuration
common duct obstruction whether by stricture
stone secondary infection or neoplasm thora
coabdominal wounds, operative trauma, etc
First, there is a communication with the peri
hepatic and subdiaphragmatic spaces, later
due to infection and biliary hypertension there
is erosion through the diaphragm If the over
lying pleura is free a pleurobiliary fistula [11] is
results but if the pleura is already sealed in
fected bile will likely rupture into the lung and
thence into a bronchus Immediately it becomes
imperative to institute appropriate antibiotic
therapy and drain the subphrenic space before
necrotizing lung involvement takes place Once
the acute inflammatory element is controlled
surgical measures aimed at the primary hepato-
biliary disease can then be undertaken

Bronchoperinephric Fistula Judging from the sixteen reported cases of bronchoperinephric fistula in the literature this must be a distinctly unusual occurrence Nesbit and Keeney found six such cases among sixty perinephric abscesses encountered over an eleven year period Being so often insidious in onset and difficult to diagnose recognition of a perinephric infection is apt to be delayed Unlike the intraperitoneal subphrenic infections discussed previously these are extraperitoneal subphrenic abscesses and are seldom considered as a cause of pulmonary complications despite a reported incidence of 16 5 per cent [12] Actually the signs and symptoms of pleuropulmonary involvement may overshadow renal signs thus providing time for rupture into a bronchus This is manifested by the sudden onset of a severe cough productive of foul sputum estimated in one instance as amounting to 2 quarts daily [13] Except in the face of a frank empyema or lung abscess the treatment of the respiratory complications entails primarily the drainage of the primary infection

Bronchocolic Fistula These lesions represent bronchosubphrenic abscesses having in addition a communication with the bowel We are acquainted with but three cases and these are worth mentioning only as medical oddities

Felkl and Michalek [14] have cited the case of a six year old boy who after a bout of left lower lobe pneumonia developed bronchiectasis empyema and ultimately a subphrenic abscess The latter is stated to have perforated into the splenic flexure of the colon resulting in a bronchocolic fistula Despite this he subsequently showed progressive improvement Comment should be made about the evolution of this

fistula from an initial infection in the lung for this is quite opposite to the usual chain of events which almost invariably start below the diaphragm and proceed superiorly

Ackermann[20] has reported the case of a sixteen year old girl with a subdiaphragmatic abscess secondary to a perforated appendix There followed a rupture into both bronchus and colon the tract being demonstrated roentgenographically at barium enema and likewise by the expectoration of barium in the course of the procedure Treatment was limited to conservative measures and the outcome was not stated

Urrutia[21] has described another equally remarkable case A twenty two year old seaman had an appendectomy complicated by a pelvic abscess which required drainage Soon there after he developed pneumonia at the left base When given a soapsuds enema, he complained of tasting soap Subsequently a fistulous tract was demonstrated connecting the terminal ileum splenic flexure and left basal bronchus The patient recovered following partial excision and ligation of the tract For some inexplicable reason this was regarded as a congenital lesion and was so reported

As a final example of the bizarre lesions that occasionally arise the occurrence of a bronchogluteal fistula[22] warrants comment This resulted from a paravertebral abscess in the lumbar region which dissected its way downward to form a gluteal abscess and upward into the left stem bronchus Incision of the gluteal cold abscess produced a bony sequestrum identifiable as the transverse process of the third lumbar vertebra The tortuous connection between the bronchus and site of gluteal drainage was outlined by the injection of iodized oil

REFERENCES

1 BANYAI A L and PEABODY J W Bronchial Fistulas Nontuberculosis Diseases of the Chest Springfield Ill 1954 Charles C Thomas
2 WOODRUFF W The recognition and management of bronchopleural fistula Am J Surg 54 236 1941
3 AUERBACH O and LIPSTEIN S Bronchopleural fistulas complicating pulmonary tuberculosis J Thoracic Surg 8 384 1939
4 MULLARD K S Congenital tracheoesophageal fistula without atresia of the esophagus J Thoracic Surg 28 39 1954
5 DAVIS E W KATZ S and PEABODY J W Jr Broncholithiasis—a neglected cause of bronchoesophageal fistula J A M A in press
6 MAIER H C Esophagobronchial fistula associated with severe hemorrhages treated by surgical excision and lobectomy Am Rev Tuberc 63 220 1951
7 COLEMAN F P and BUNCH G H Jr Acquired nonmalignant esophagotracheobronchial fistula J Thoracic Surg 19 542 1950
8 OCHSNER A and DE BAKEY M Subphrenic abscess Surg Gynec & Obst 66 426 1938
9 HEAD J and HUDSON T R Subphrenic abscess with bronchial fistula Surg Gynec & Obst 75 54 1942
10 ALBERTSON H A Bronchosubdiaphragmatic fistula with a report of two cases J Thoracic Surg 25 505 1953
11 GUY C C and OLECK H T Traumatic biliary bronchial fistula with report of two cases due to war wounds Arch Surg 55 316 1947
12 MORTON J J and PHILLIPS L W Bronchobiliary fistula review of recorded cases other than those due to echinococcus and amebic abscess A b Surg 16 697 1928
13 FRENCH R W Bilio-bronchial fistula Arch Surg 30 635 1935
14 ADAMS H D Pleurobiliary and bronchobiliary fistulas J Thoracic Surg 30 255 1955
15 TRUNOWITZ S Bronchobiliary fistula in Hodgkin disease Arch Int Med 88 400 1951
16 NEILSEN A M DICK G F and MADDOCK W G Chronic perinephric abscess with perinephric bronchial fistula and psoas abscess J Urol 63 433 1950
17 NESBIT R M and KEENT C H Perinephric abscess with bronchial fistula J Urol 37 1937
18 NESBIT R M and DICK V S Pulmonary complications of acute renal and perirenal suppuration Am J Roentgenol 44 161 1940
19 FELKL H and MICHALEK F Bronchocutaneal fistel bei einem fünfzehn viertel Jahre alten Knaben Wien klin Wchnschr 49 875 1936
20 ACKERMANN A J Bronchocolic fistula report of a case Am J Roentgenol 47 294 1942
21 URRUTIA J M Quoted in Lancet 2 116 1942
22 MACHADO G and DIAZ M Quoted by Banyai and Peabody

XI. ALLERGY

30

Allergic Manifestations in the Respiratory Tract

JOSEPH HARKAVY, M.D., *New York, New York*

Head of Allergy Service, Medical Division, Montefiore Hospital; Consulting Allergist, Mt. Sinai Hospital, New York, N. Y.

TREATMENT of allergic manifestations of the respiratory tract obviously depends upon the area affected and the basic cause. The possible sites of the respiratory system which may be involved in the allergic response are the nose and accessory sinuses, the trachea, bronchial tubes, pulmonary parenchyma and associated blood vessels. These various tissues are referred to as "shock tissues." The constitutionally allergic (atopic) individual who is characteristically subject to polyvalent sensitivity may possess one or several shock tissues which are the seats of the allergic reactions. The latter are the result of interaction between the antigen, which may be introduced into the body through inhalation, ingestion or injection, and antibody evoked by previous exposure to the specific antigen or allergen. The antigen may consist of inhalants such as pollens, various dusts, foods, drugs or bacteria. The antibodies are modified globulins manufactured by the reticuloendothelial system under antigenic stimulation. The antibodies are discharged into the blood stream and become attached to various cellular components of the shock tissue, i.e., blood vessels, smooth muscle, connective tissue, epithelial structures, etc. Union between the antigen and specific antibody results in the release of a toxic element such as histamine and probably other substances. The histamine thus liberated in the cells of a capillary vessel leads to injury to the wall, increased vascular permeability and edema characteristic of the immediate form of the hypersensitive reaction. This contrasts with the delayed inflammatory type of response (tuberculin reaction) noted after the intradermal injection of a bacterial product such as tuberculin into the skin. The immediate type of hypersensitiveness is best illustrated clinically by the urticarial wheal induced by the intracutaneous injection of a [illegible] hour and subsequently give way to non specific round cell infiltration.

The acute allergic manifestations in the respiratory tract, whether in the nose, sinuses, trachea or bronchial tubes, are also attributable to edema and eosinophilic infiltration in the aforesaid shock organs. This accounts for the sneezing and running as well as stuffiness of the nose present in allergic rhinitis such as hay fever, and the cough and wheezing respiration in bronchial asthma.

ALLERGIC RHINITIS AND SEASONAL HAY FEVER (POLLINOSIS)

Individuals who develop nasal symptoms characterized by sneezing and blocking of the nose, accompanied in certain instances by tearing, edema and itching of the eyes and nasopharynx at about the same time each year should be suspected of having hay fever. This also holds true for the seasonal development of bronchial asthma which may be due to the same pollen responsible for hay fever.

Etiology. Although pollens are the most common causes of seasonal allergic rhinitis or asthma, other exciting agents such as molds, insects and foods may likewise be involved in the development of seasonal respiratory manifestations. [illegible] disseminated by insects are rarely responsible

fistula from an initial infection in the lung for this is quite opposite to the usual chain of events which almost invariably start below the diaphragm and proceed superiorly

Ackermann[20] has reported the case of a sixteen year old girl with a subdiaphragmatic abscess secondary to a perforated appendix There followed a rupture into both bronchus and colon the tract being demonstrated roentgenographically at barium enema and likewise by the expectoration of barium in the course of the procedure Treatment was limited to conservative measures and the outcome was not stated

Urrutia[21] has described another equally remarkable case A twenty two year old seaman had an appendectomy complicated by a pelvic abscess which required drainage Soon there after he developed pneumonia at the left base When given a soapsuds enema he complained of tasting soap Subsequently a fistulous tract was demonstrated connecting the terminal ileum splenic flexure and left basal bronchus The patient recovered following partial excision and ligation of the tract For some inexplicable reason this was regarded as a congenital lesion and was so reported

As a final example of the bizarre lesions that occasionally arise the occurrence of a bronchogluteal fistula[22] warrants comment This resulted from a paravertebral abscess in the lumbar region which dissected its way downward to form a gluteal abscess and upward into the left stem bronchus Incision of the gluteal cold abscess produced a bony sequestrum identifiable as the transverse process of the third lumbar vertebra The tortuous connection between the bronchus and site of gluteal drainage was outlined by the injection of iodized oil

REFERENCES

1 BANYAI A L and PEABODY J W Bronchial Fistulas Nontuberculous Diseases of the Chest Springfield Ill 1954 Charles C Thomas
2 WOODRUFF W The recognition and management of bronchopleural fistula Am J Surg 54 236 1941
3 AUERBACH O and LIPSTEIN S Bronchopleural fistulas complicating pulmonary tuberculosis J Thoracic Surg 8 384 1939
4 MULLARD K S Congenital tracheoesophageal fistula without atresia of the esophagus J Thoracic Surg 28 39 1954
5 DAVIS L W KATZ S and PEABODY J W Jr Broncholithiasis—a neglected cause of bronchoesophageal fistula J A M A in press
6 MAIER H C Esophagobronchial fistula associated with severe hemorrhages treated by surgical excision and lobectomy Am Rev Tuberc 63 220 1951
7 COLEMAN T P and BUNCH G H Jr Acquired nonmalignant esophagotracheobronchial fistula J Thorac Surg 19 542 1950
8 OCHSNER A and DE BAKEY M Subphrenic abscess Surg Gynec & Obst 66 426 1938
9 HEAD J and HUDSON T R Subphrenic abscess with bronchial fistula Surg Gynec & Obst 75 54 1942
10 ALBERTSON H A Broncho-subdiaphragmatic fistula with a report of two cases J Thoracic Surg 25 505 1953
11 GUY C C and OLECK H T Traumatic bilary bronchial fistula with report of two cases due to war wounds Arch Surg 55 316 1947
12 MORTON J J and PHILLIPS E W Broncho-biliary fistula review of recorded cases other than those due to echinococcus and amebic abscess Arch Surg 16 697 1928
13 FRENCH R W Biliobronchial fistula Arch Surg 30 635 1935
14 ADAMS H D Pleurobiliary and bronchobiliary fistulas J Thoracic Surg 30 255 1955
15 TRUDOVITZ S Bronchobiliary fistula in Hodgkin's disease Arch Int Med 88 400 1951
16 NEILSEN A M DICK G F and MADDOCK W G Chronic perinephric abscess with perinephro bronchial fistula and psoas abscess J Urol 63 433 1950
17 NESBIT R M and KEENE C H Perinephric abscess with bronchial fistula J Urol 37 6[illegible] 1937
18 NESBIT R M and DICK V S Pulmonary complications of acute renal and perirenal suppuration Am J Roentgenol 44 161 1940
19 FELLL H and MICHALEK E Bronchocolonfistel bei einem funfdreivierteljahrigen Knaben Wien klin Wchnschr 49 875 1936
20 ACKERMANN A J Bronchocolic fistula report of a case Am J Roentgenol 47 294 1942
21 URRUTIA J M Quoted in Lancet 2 116 1942
22 MACHADO G and DIAZ M Quoted by Banyai and Peabody

XI. ALLERGY

30

Allergic Manifestations in the Respiratory Tract

Joseph Harkavy, M.D., New York, New York

Head of Allergy Service, Medical Division, Mount Sinai Hospital; Consulting Gerior, Mt. Sinai Hospital, New York, N. Y.

Treatment of allergic manifestations of the respiratory tract obviously depends upon the area affected and the basic cause. The possible sites of the respiratory system which may be involved in the allergic response are the nose and accessory sinuses, the trachea, bronchial tubes, pulmonary parenchyma and associated blood vessels. These various tissues are referred to as "shock tissues." The constitutionally allergic (atopic) individual who is characteristically subject to polyvalent sensitivity may possess one or several shock tissues which are the seats of the allergic reactions. The latter are the result of interaction between the antigen, which may be introduced into the body through inhalation, ingestion or injection, and antibodies evoked by previous exposure to the specific antigen or allergen. The antigen may consist of inhalants such as pollens, various dusts, foods, drugs or bacteria. The antibodies are modified globulins manufactured by the reticuloendothelial system under antigenic stimulation. The antibodies are discharged into the blood stream and become attached to various cellular components of the shock tissue, i.e., blood vessels, smooth muscle, connective tissue, epithelial structures, etc. Union between the antigen and specific antibody results in the release of a toxic element such as histamine and probably other substances. The histamine thus liberated in the cells of a capillary vessel leads to injury to the wall, increased vascular permeability and edema characteristic of the immediate form of the hypersensitive reaction. This contrasts with the delayed inflammatory type of response (tuberculin reaction) noted after the intradermal injection of a bacterial product such as tuberculin into the skin. The immediate type of hypersensitiveness is best illustrated clinically by the urticarial wheal induced by the intracutaneous injection of a specific allergen (antigen) such as pollen, food, etc. Histologically the urticarial wheal is characterized by edema and mobilization of eosinophils which reach their maximum within the hour and subsequently give way to non-specific round cell infiltration.

The acute allergic manifestations in the respiratory tract, whether in the nose, sinuses, trachea or bronchial tubes, are also attributable to edema and eosinophilic infiltration in the aforesaid shock organs. This accounts for the sneezing and running as well as stuffiness of the nose present in allergic rhinitis such as hay fever, and the cough and wheezing respiration in bronchial asthma.

ALLERGIC RHINITIS AND SEASONAL HAY FEVER (POLLINOSIS)

Individuals who develop nasal symptoms characterized by sneezing and blocking of the nose, accompanied in certain instances by tearing, edema and itching of the eyes and nasopharynx at about the same time each year should be suspected of having hay fever. This also holds true for the seasonal development of bronchial asthma which may be due to the same pollen responsible for hay fever.

Etiology. Although pollens are the most common causes of seasonal allergic rhinitis or asthma, other exciting agents such as molds, insects and foods may likewise be involved in the development of seasonal respiratory manifestations.

Pollens. The pollens which are most important in the causation of hay fever or asthma are those which are air borne. Pollens which are disseminated by insects are rarely responsible

for respiratory symptoms because they do not come in close enough contact with the individual Although the pollens of such flowers as asters and dahlias may cause hay fever or asthma in susceptible individuals who handle them (florists, gardeners), their pollen is too heavy and sticky to travel very far As a result, their importance in the causation of hay fever in the majority of persons is minimal

The periods of the year during which pollen is chiefly responsible for hay fever or asthma symptoms in parts of the United States east of Mississippi river are early and late spring, and fall The spring season begins early in March and continues until June During these months the tree pollens are chiefly implicated in the development of nasal or pulmonary manifestations In order of their appearance they are elm, maple, poplar, oak, beech, birch, sycamore and hickory Oak is the most important of these because it is the most widespread Alder, hazel maple and pecan are less significant except in Georgia and northern Florida In Texas and Bermuda cedar may play an important role In the District of Columbia the paper mulberry tree is a potent cause of spring hay fever in Texas the mesquite tree, in California the olive tree Evergreens such as pine, spruce balsam and hemlock affect but a small group of sensitive individuals In different communities the presence of certain special trees may prove the source of sensitization These, however, are of local importance and are not responsible for widespread discomfort

The so called early season begins in mid May with the pollination of plantain and sorrel which is at its height during the last week in May and the first week in June Although the pollination of plantain may gradually diminish thereafter, it may prevail in varying degrees as late as August The grasses begin to pollinate about the middle of May and may continue through the end of July Clinical symptoms due to grass pollens begin to appear most promiently at or about May 30th Whereas different varieties of grasses such as sweet vernal, June grass, red top, low spear orchard and timothy prevail they are all related and the patient who reacts to one will usually react to all The most abundant pollen is produced by orchard grass and timothy The peak of the former is reached about June 10th that of the latter in July The most important pollen producing grasses in the south are Bermuda and Johnson grass

Patients whose symptoms begin in mid May are usually plantain sensitive, those whose symptoms do not begin until June are probably sensitive to grass

The fall or late season begins early in August and continues till the early frost or later It is due to ragweed, both high and low The former begins to pollinate about the middle of August and reaches its peak about the end of August With the decline of pollination of high ragweed the low variety gains in ascendency, reaching its height during the first two days of September and continuing until the frost. West of the Mississippi other weeds vie with ragweed in the causation of hay fever The most important of these are the various amaranths pigweed or tumbleweed, artemisias (sages), chenopods (lambs quarter), ivies marsh elder cocklebur, Russian thistle and hemp, wild rice, great reed, Indian and marram grasses The sedges and sugar beet which may also be responsible for hay fever or asthma symptoms are of limited and local significance

Although most ragweed hay fever patients feel relieved with the termination of ragweed pollination there is a substantial group of patients whose symptoms become worse from about the middle of September until the end of October when ragweed is practically gone Many of these patients are ragweed sensitive individuals whose symptoms have been controlled by immunization (throughout August and part of September) during the height of the ragweed season Some, however, despite marked symptoms of hay fever do not show sensitivity either to ragweed or molds which prevail at this time The cause for the persistence or exacerbation of the nasal manifestations at this period of the year has not been satisfactorily determined The possible explanations suggested are the persistence of various molds in the air especially Alternaria in certain localities, the dust created by the decaying leaves which are overgrown with molds, the sudden changes of temperature which affect mucous membranes already irritated by pollen, the exacerbation of latent sinus infection, the onset of colds especially in children who return to school after their vacations contact with camphor in stored winter clothes, etc Each of those factors has to be evaluated individually and the patient treated accordingly

lungs. Next in importance in the development of seasonal rhinitis or asthma in some localities especially in the East, and perennial rhinitis as well as asthma in other communities, are molds. Molds are found in the air, on grass, trees and in dust. Despite their wide distribution molds become exciting agents when exposure to them is intense as in damp cellars or houses, during damp warm days of summer and fall.

Molds may act as infecting agents and as allergens. In the first instance they behave like bacteria of low virulence and induce infections in the lungs and other tissues, skin, etc. In the second place they act as allergenic substances like pollen or other inhalants and produce hay fever like symptoms, i.e., allergic rhinitis or vasomotor rhinitis and asthma. Their augmentation in the air during the hot, damp summer days may be responsible for nasal or pulmonary symptoms such as asthma in patients who do not show any pollen hypersensitivity and in others who may have both pollen and mold allergy. The most important molds are Alternaria, Hormodendrum, Aspergillus, Mucor, Penicillium, Rhizopus, rusts, smuts, torulae, Chaetomium, Cephalosporium, Fusarium and Monilia.

The mold season varies in length from year to year in contrast to the pollen season. In some localities Hormodendrum may have several peaks as in June, October, November, in others Alternaria may be in ascendency. Both these molds give off more spores in the air than any other with the exception of rusts and smuts which are important allergenic exciting in the Middle West in the farming country. Mold allergy should be suspected in a pollen case if the nasal or bronchial symptoms are aggravating during hot muggy weather even when there is pollen in the air during periods free from any important pollen as at the end of July or early August and when poor results are obtained if the patient is treated with pollen only.

Insects. In certain regions in the United States, as for example around Lake Erie, seasonal appearance of hay fever like symptoms or asthma during June or July may be due to wings of insects such as the caddis fly in susceptible individuals. Sensitization to May fly have also been described.

Foods. Although foods may be responsible for hay fever like symptoms these are not seasonal in character as a rule. However, seasonal fruits or vegetables such as asparagus, berries, melons or peaches may aggravate hay fever symptoms due to pollens. Omission of these during the pollen season results in greater amelioration of nasal symptoms due to pollen immunization than would otherwise occur.

DIAGNOSIS

The diagnosis of hay fever or seasonal asthma is based upon the history correlated with the skin and eye as well as upon nasal tests. In eliciting the history one of the most important points is to determine the approximate date of onset of symptoms, the period of greatest intensity, the character, progress and duration of the manifestations and periods of freedom. Questions as to the nature of the environment under which the symptoms arise are also important. Thus it is essential to know whether the symptoms are worse outdoors or indoors, at night or day, whether they appear when the patient is exposed to dusty atmospheres, old bedding or feather pillows, or when working in the garden or on a farm. If the latter is the case, it is conceivable that the so-called hay fever symptoms occurring in the summer may really be due to exposure to animal dander or other inhalants such as feathers, or environmental dusts rather than pollens. To verify these points tests with various allergenic substances, pollens, fungi, dusts and other inhalants or foods should therefore be carried out. This is done by the intradermal or scratch technic, supplemented when necessary by the eye or nasal tests. The intradermal skin tests are much more sensitive than the scratch tests and may be accompanied by constitutional reactions unless care is taken with the dilution of the extract employed. The scratch test is carried out by superficial scarifications or abrasions of the skin of the arm, the forearm or back, about ⅛ inch in length and applying the dry pollen or dust, etc., to the scarified skin adding thereto a drop of N/10 sodium hydroxide or saline. This is read within fifteen to twenty minutes after removing the allergens. A positive skin reaction consists of an urticarial wheal varying in size surrounded by an area of erythema anywhere from 1 to 2 cm. in diameter or less or erythema alone of about 2 or more cm. Intradermal tests are made by introducing about 0.01 ml. of a sterile allergenic substance intracutaneously with a 26-gauge needle ⅜ inch in

for respiratory symptoms because they do not come in close enough contact with the individual Although the pollens of such flowers as asters and dahlias may cause hay fever or asthma in susceptible individuals who handle them (florists gardeners) their pollen is too heavy and sticky to travel very far As a result their importance in the causation of hay fever in the *majority of persons is minimal*

The periods of the year during which pollen is chiefly responsible for hay fever or asthma symptoms in parts of the United States east of Mississippi river are early and late spring and fall The spring season begins early in March and continues until June During these months the tree pollens are chiefly implicated in the development of nasal or pulmonary manifestations *In order of their appearance they are* elm maple poplar, oak beech birch sycamore and hickory Oak is the most important of these because it is the most widespread Alder hazel maple and pecan are less significant except in Georgia and northern Florida In Texas and Bermuda cedar may play an important role In the District of Columbia the paper mulberry tree is a potent cause of spring hay fever *in Texas the mesquite tree in the Sacramento Valley* the black walnut in California the olive tree Evergreens such as pine spruce balsam and hemlock affect but a small group of sensitive individuals In different communities the presence of certain special trees may prove the source of sensitization These however are of local importance and are not responsible for widespread discomfort

The so-called early season begins in mid May with the pollination of plantain and sorrel which is at its height during the last week in May and the first week in June Although the pollination of plantain may gradually diminish thereafter it may prevail in varying degrees as late as August The grasses begin to pollinate about the middle of May and may continue

varieties of grasses such as sweet vernal June grass red top low spear orchard and timothy prevail they are all related and the patient *who reacts to one will usually react to all* The most abundant pollen is produced by orchard grass and timothy The peak of the former is reached about June 10th that of the latter in July The most important pollen producing grasses in the south are Bermuda and Johnson grass

Patients whose symptoms begin in mid May are usually plantain sensitive those whose symptoms do not begin until June are probably sensitive to grass

The fall or late season begins early in August and continues till the early frost or later It is *due to ragweed both high and low* The former begins to pollinate about the middle of August and reaches its peak about the end of August. With the decline of pollination of high ragweed

Mississippi other weeds vie with ragweed in the causation of hay fever The most impor*tant of these are the various amaranths pig* weed or tumbleweed artemisias (sages) chenopods (lambs quarter) iva marsh elder cocklebur, Russian thistle and hemp wild rice great reed Indian and marram grasses. The sedges and sugar beet which may also be responsible for hay fever or asthma symptoms are of limited and local significance

Although most ragweed hay fever patients feel relieved with the termination of ragweed pollination there is a substantial group of patients whose symptoms become worse from about the middle of September until the end of October when ragweed *is* practically gone Many of these patients are *ragweed sensitive* individuals whose symptoms have been controlled by immunization (throughout August and part of September) during the height of the *ragweed season* Some, however despite marked symptoms of hay fever do not show sensitivity either to ragweed or molds which prevail at this time The cause for the persistence or exacerbation of the nasal manifestations *at this period of the year* has not been satisfactorily determined The possible explanations suggested are the persistence of

the sudden changes
affect mucous membranes already irritated by pollen the exacerbation of latent sinus infection the onset of colds especially in children *who return* to school after their vacations contact with *camphor* in stored winter clothes, etc Each of those factors has to be evaluated individually and the patient treated accordingly

Having selected the pollen to which the patient is sensitive on the basis of history, skin or eye tests, treatment frequently referred to as hyposensitization is instituted. This may be carried out preseasonally, co-seasonally and perennially.

Treatment

Preseasonal Treatment. Preseasonal treatment is started each year about three months before the season during which the patient manifests his symptoms. The maximum dose of pollen should be reached just prior to the onset of the season. The earlier treatment is begun in the disease and the more conscientiously it is kept up, the better the chance for immunity to develop in the course of time. This applies to children as well as adults. To expect that the patient will outgrow his hay fever without treatment is an illusion. Rare exceptions to this rule occur but the majority of the untreated patients become subject to frequent colds, sinus infection and asthma.

In view of the fact that hay fever patients frequently show sensitization to several pollens, mixed pollen preparations are often employed in treatment. Thus patients allergic to two or three trees may be treated with an extract containing all the three or even more of the suspected tree pollens, such as elm, poplar, ash, sycamore, beech, maple, hickory, etc. Those sensitive to several grasses related botanically as well as antigenically may be treated with timothy alone or if one prefers with a mixture of several individual grasses contained in the same vial. Another method is to determine the pollens to which a patient is sensitive and expose as well as the degree of sensitiveness to each and then combine them in one individual mixture so that the patient will require only one injection at each visit. Thus for example a patient who has hay fever from mid May till the end of July and who reacts equally to both timothy and plantain may be treated with a mixture of equal parts of the two. For patients manifesting early and late hay fever one may prepare a mixture of one part timothy and two or three parts of ragweed or one half timothy and plantain and one-half ragweed. For the late hay fever cases a mixture of one half or two-thirds ragweed combined with other fall weeds such as amaranth, artemisia, chenepod, cocklebur, corn and Iva. Since the latter are of less importance in the eastern parts of this country than ragweed pollen, their proportion to ragweed should be less. Ragweed extract is usually made up of equal parts of high and low ragweed pollen. Of the flowers, aster, dahlia, chrysanthemum and golden rod are of varying importance. Before making up a final mixture it is suggested that two or three doses of the individual pollens should be given separately in order to gauge the proper proportions for the mixture by means of the local reactions.

Based upon the strength of the pollen extract necessary to elicit a marked reaction Van der Veer,* who used pollen extracts standardized according to the protein unit technic, classified hay fever patients for the purposes of treatment, into four groups, (*A*), (*B*), (*C*) and (*D*). Those who gave a marked reaction consisting of redness, itching with pseudopods when tested with ten units were put into class (*A*), i.e., very sensitive. Those who showed slight or moderate reactions to 10 units but marked to 100 were placed in class (*B*) or average, whereas those who required 1,000 units to elicit a marked reaction were placed in class (*C*) or less sensitive. Others yielding moderate reactions to 5,000 or 10,000 units were classed as (*D*). The average maximum dose of pollen required to protect the patient in these various categories was found to be as follows:

Patients in class (*A*) needed about 1,000 units, class (*B*) about 5,000 units, class (*C*) about 10,000 and class (*D*) about 20,000. This is necessarily a rough classification since one must realize that the size of a reaction is not a true index of the clinical sensitivity of the patient (Cooke[11]). Nevertheless it is of value in indicating a safe initial dose and how slowly or rapidly one should proceed with the injections in any one patient. If there is little or no reaction following injection of a certain dose, the latter may be increased more rapidly. If marked reactions follow, the amount should be reduced to an acceptable level and the same dose repeated several times if necessary until it is safe to increase it.

[illegible]

constitutional reactions before the start of the

[illegible]

four to five days to 10, 15, 20 units, etc., till a

length The testing material is first used in high dilutions so as to avoid any untoward reactions If the reaction is negative progressively higher concentrations of the suspected allergenic extract may be tested A positive reaction just as with the scratch technic consists of an urticarial wheal with pseudopods circumscribed by redness and itching Redness and itching alone without pseudopods may also be regarded as a positive response provided a control injection of the same amount consisting of plain diluent either Coca s buffered saline or normal saline is negative

Ophthalmic Tests Occasionally clinically sensitive pollen cases may give negative skin reactions In such individuals the eye test may

may also be carried out by placing a minute amount of dry pollen into the lower conjunctiva at the end of a toothpick A control test with an indifferent pollen may be applied in the conjunctival sac of the opposite eye The conjunctivae of both eyes are examined after twenty minutes A positive reaction consists of congestion and/or edema of the caruncle and the conjunctiva These signs may be associated with itching of the eye lacrymation and rhinitis If the reaction is severe, a drop of 1 1000 epinephrine may be placed into the lower eyelid with an eyedropper

Nasal Tests Intranasal insufflation tests with pollens molds and dusts or other allergens are used by some for the purposes of diagnosis

mucosa

Inasmuch as hay fever patients react to more than one pollen it is important to consider the clinical significance of a reaction in the light of the patients history and treat him accordingly rather than on the basis of the skin tests Thus if a patient reacts to grasses and ragweed but has symptoms during the grass season treatment should be limited to grasses and vice versa This rule applies not only in the case of pollen but also in respect to various molds foods and other substances which are found to be positive on testing the allergic individual Occasionally there are patients with a history of seasonal hay fever who give negative skin or eye tests Despite this treatment of such patients with the appropriate pollens as indicated by the history has been found to give satisfactory results

Extracts The type of pollen or other allergenic extracts used in diagnosis and treatment may be commercial or prepared in a well equipped laboratory Different methods are used in the preparations of such material These consist of the weight by volume method pollen or Noon units total nitrogen content protein nitrogen units (P N U) and protein content In view of these diversities there is no exact mathematic relationship between these various units of standardization The weight by volume and pollen unit method are most commonly employed The protein nitrogen content is advocated by Cooke Various commercial firms use different methods of labelling their preparations and physicians should follow the indicated directions

If one uses an extract employing the weight by volume standardization a 1 100 solution signifies that each milliliter contains 0 01 gm of dry pollen A 1 100 000 solution means that each milliliter contains 0 001 mg of dry pollen

A comparison of various standards of extracts discloses the following

Noon unit based on original pollen weight

1 Noon unit = 1 100 000 gm or 0 001 mg pollen (Also called a pollen unit)

Cooke unit * based on protein nitrogen content of extract

1 Cooke unit = 0 00001 mg protein nitrogen per milliliter

Total nitrogen unit based on the total nitrogen content of the extract

1 total nitrogen unit = 0 00001 mg total nitrogen per milliliter (Also called a pollen unit)

Dilution standard based on weight by volume extraction and dilution

A 1 100 extract contains 0 01 gm of extracted pollen per milliliter

Equivalents of 1 50 dilution extract

1 cc of a 1 50 dilution extract (pollen weight by volume) is equivalent to

(1) 20 000 pollen units

(2) 20 000 Noon units

(3) 10 000 P N (protein nitrogen units Cooke)

(4) 0 26 mg total N

(5) 26 000 total nitrogen units

*COOKE R Allergy in Theory and Practice page 529 Philadelphia 1917 W B Saunders Co

Having selected the pollen to which the patient is sensitive on the basis of history, skin or eye tests, treatment frequently referred to as hyposensitization is instituted This may be carried out preseasonally, co-seasonally and perennially.

Treatment

Preseasonal Treatment Preseasonal treatment is started each year about three months before the season during which the patient manifests his symptoms The maximum dose of pollen should be reached just prior to the onset of the season The earlier treatment is begun in the disease and the more conscientiously it is kept up, the better the chance for immunity to develop in the course of time This applies to children as well as adults To expect that the patient will outgrow his hay fever without treatment is an illusion Rare exceptions to this rule occur but the majority of the untreated patients become subject to frequent colds sinus infection and asthma

In view of the fact that hay fever patients frequently show sensitization to several pollens mixed pollen preparations are often employed in treatment. Thus patients allergic to two or three trees may be treated with an extract containing all the three or even more of the suspected tree pollens, such as elm poplar ash sycamore, beech, maple, hickory etc Those sensitive to several grasses related botanically as well as antigenically may be treated with timothy alone or if one prefers with a mixture of several individual grasses contained in the same vial Another method is to determine the pollens to which a patient is sensitive and exposed as well as the degree of sensitiveness to each and then combine them in one individual mixture so that the patient will require only one injection at each visit Thus for example a patient who has hay fever from mid May till the end of July and who reacts equally to both timothy and plantain may be treated with a mixture of equal parts of the two For patients manifesting early and late hay fever one may prepare a mixture of one part timothy and two or three parts of ragweed or one-half timothy and one-half ragweed For the late hay fever cases a mixture of one half or two-thirds ragweed combined with other fall weeds, such as amaranth artemisia chenopod cocklebur, corn and Iva Since the latter are of less importance in the eastern parts of this country than ragweed pollen, their proportion to ragweed should be less Ragweed extract is usually made up of equal parts of high and low ragweed pollen Of the flowers, aster, dahlia, chrysanthemum and golden rod are of varying importance Before making up a final mixture it is suggested that two or three doses of the individual pollens should be given separately in order to gauge the proper proportions for the mixture by means of the local reactions

Based upon the strength of the pollen extract necessary to elicit a marked reaction Van der Veer,* who used pollen extracts standardized according to the protein unit technic, classified hay fever patients for the purposes of treatment, into four groups, (*A*), (*B*), (*C*) and (*D*) Those who gave a marked reaction consisting of redness, itching with pseudopods when tested with ten units were put into class (*A*), i e very sensitive Those who showed slight or moderate reactions to 10 units but marked to 100, were placed in class (*B*) or average, whereas those who required 1,000 units to elicit a marked reaction were placed in class (*C*), or less sensitive Others yielding moderate reactions to 5 000 or 10 000 units were classed as (*D*) The average maximum dose of pollen required to protect the patient in these various categories was found to be as follows

Patients in class (*A*) needed about 1,000 units class (*B*) about 5 000 units, class (*C*) about 10 000 and class (*D*) about 20,000 This is necessarily a rough classification since one must realize that the size of a reaction is not a true index of the clinical sensitivity of the patient (Cooke) Nevertheless it is of value in indicating a safe initial dose and how slowly or rapidly one should proceed with the injections in any one patient If there is little or no reaction following injection of a certain dose, the latter may be increased more rapidly If marked reactions follow the amount should be reduced to an acceptable level and the same dose repeated several times if necessary until it is safe to increase it

The goal in treatment is to give the patient the largest amount of pollen extract to which he is allergic without any marked local or constitutional reactions before the start of the season Patients in class (*A*), for example, who give marked reaction to a very dilute amount of pollen extract may have to be started with 2 or 5 units This may be gradually increased every four to five days to 10 15 20 units, etc , till a

length The testing material is first used in high dilutions so as to avoid any untoward reactions If the reaction is negative, progressively higher concentrations of the suspected allergenic extract may be tested A positive reaction just as with the scratch technic, consists of an urticarial wheal with pseudopods circumscribed by redness and itching Redness and itching alone without pseudopods may also be regarded as a positive response, provided a control injection of the same amount consisting of plain diluent, either Coca's buffered saline or normal saline, is negative

Ophthalmic Tests Occasionally clinically sensitive pollen cases may give negative skin reactions In such individuals the eye test may be used This consists of introducing one or two drops of varying dilutions of pollen extract into the lower conjunctival sac and reading the reaction within fifteen to twenty minutes This test may also be carried out by placing a minute amount of dry pollen into the lower conjunctiva at the end of a toothpick A control test with an indifferent pollen may be applied in the conjunctival sac of the opposite eye The conjunctivae of both eyes are examined after twenty minutes A positive reaction consists of congestion and/or edema of the caruncle and the conjunctiva These signs may be associated with itching of the eye lacrymation and rhinitis If the reaction is severe, a drop of 1 1000 epinephrine may be placed into the lower eyelid with an eyedropper

Nasal Tests Intranasal insufflation tests with pollens molds and dusts or other allergens are used by some for the purposes of diagnosis [illegible]

mucosa

Inasmuch as hay fever patients react to more than one pollen it is important to consider the clinical significance of a reaction in the light of the patients history and treat him accordingly rather than on the basis of the skin tests Thus if a patient reacts to grasses and ragweed but has symptoms during the grass season treatment should be limited to grasses and vice versa This rule applies not only in the case of pollen but also in respect to various molds, foods and other substances which are found to be positive on testing the allergic individual Occasionally there are patients with a history of seasonal hay fever who give negative skin or eye tests Despite this treatment of such patients with the appropriate pollens as indicated by the history has been found to give satisfactory results

Extracts The type of pollen or other allergenic extracts used in diagnosis and treatment may be commercial or prepared in a well equipped laboratory Different methods are used in the preparations of such material These consist of the weight by volume method pollen or Noon units total nitrogen content protein nitrogen units (P N U) and protein content In view of these diversities there is no exact mathematic relationship between these various units of standardization The weight by volume and pollen unit method are most commonly employed The protein nitrogen content is advocated by Cooke Various commercial firms use different methods of labelling their preparations and physicians should follow the indicated directions

If one uses an extract employing the weight by volume standardization a 1 100 solution signifies that each milliliter contains 0 01 gm of dry pollen A 1 100 000 solution means that each milliliter contains 0 001 mg of dry pollen

A comparison of various standards of extracts discloses the following

Noon unit based on original pollen weight.

1 Noon unit = 1 100 000 gm or 0 001 mg pollen (Also called a pollen unit)

Cooke unit * based on protein nitrogen content of extract

1 Cooke unit = 0 00001 mg protein nitrogen per milliliter

Total nitrogen unit based on the total nitrogen content of the extract

1 total nitrogen unit = 0 00001 mg total nitrogen per milliliter (Also called a pollen unit)

Dilution standard based on weight by volume extraction and dilution

A 1 100 extract contains 0 01 gm of extracted pollen per milliliter

Equivalents of 1 50 dilution extract

1 cc of a 1 50 dilution extract (pollen weight by volume) is equivalent to

(1) 20 000 pollen units

(2) 20 000 Noon units

(3) 10 000 P N (protein nitrogen units Cooke)

(4) 0 26 mg total N

(5) 26 000 total nitrogen units

* COOKE R Allergy in Theory and Practice, page 529 Philadelphia 1947 W B Saunders Co

Having selected the pollen to which the patient is sensitive on the basis of history skin or eye tests treatment frequently referred to as hyposensitization is instituted This may be carried out preseasonally, co seasonally and perennially

Treatment

Preseasonal Treatment Preseasonal treatment is started each year about three months before the season during which the patient manifests his symptoms The maximum dose of pollen should be reached just prior to the onset of the season The earlier treatment is begun in the disease and the more conscientiously it is kept up the better the chance for immunity to develop in the course of time This applies to children as well as adults To expect that the patient will outgrow his hay fever without treatment is an illusion Rare exceptions to this rule occur but the majority of the untreated patients become subject to frequent colds sinus infection and asthma

In view of the fact that hay fever patients frequently show sensitization to several pollens mixed pollen preparations are often employed in treatment Thus patients allergic to two or three trees may be treated with an extract containing all the three or even more of the suspected tree pollens such as elm poplar ash sycamore beech maple hickory etc Those sensitive to several grasses related botanically as well as antigenically may be treated with timothy alone or if one prefers with a mixture of several individual grasses contained in the same vial Another method is to determine the pollens to which a patient is sensitive and exposed as well as the degree of sensitiveness to each and then combine them in one individual mixture so that the patient will require only one injection at each visit Thus for example a patient who has hay fever from mid May till the end of July and who reacts equally to both timothy and plantain may be treated with a mixture of equal parts of the two For patients manifesting early and late hay fever one may prepare a mixture of one part timothy and two or three parts of ragweed or one-half timothy and plantain and one-half ragweed For the late hay fever cases a mixture of one half or two-thirds ragweed combined with other fall weeds such as amaranth artemisia chenepod cocklebur corn and Iva Since the latter are of less importance in the eastern parts of the country than ragweed pollen, their proportion to ragweed should be less Ragweed extract is usually made up of equal parts of high and low ragweed pollen Of the flowers aster, dahlia, chrysanthemum and golden rod are of varying importance Before making up a final mixture it is suggested that two or three doses of the individual pollens should be given separately in order to gauge the proper proportions for the mixture by means of the local reactions

Based upon the strength of the pollen extract necessary to elicit a marked reaction Van der Veer * who used pollen extracts standardized according to the protein unit technic, classified hay fever patients for the purposes of treatment, into four groups (*A*), (*B*), (*C*) and (*D*) Those who gave a marked reaction consisting of redness, itching with pseudopods when tested with ten units were put into class (*A*) i e very sensitive Those who showed slight or moderate reactions to 10 units but marked to 100 were placed in class (*B*) or average, whereas those who required 1 000 units to elicit a marked reaction were placed in class (*C*) or less sensitive Others yielding moderate reactions to 5 000 or 10 000 units were classed as (*D*) The average maximum dose of pollen required to protect the patient in these various categories was found to be as follows

Patients in class (*A*) needed about 1,000 units class (*B*) about 5 000 units class (*C*) about 10 000 and class (*D*) about 20 000 This is necessarily a rough classification since one must realize that the size of a reaction is not a true index of the clinical sensitivity of the patient (Cooke) Nevertheless it is of value in indicating a safe initial dose and how slowly or rapidly one should proceed with the injections in any one patient If there is little or no reaction following injection of a certain dose the latter may be increased more rapidly If marked reactions follow the amount should be reduced to an acceptable level and the same dose repeated several times if necessary until it is safe to increase it

The goal in treatment is to give the patient the largest amount of pollen extract to which he is allergic without any marked local or constitutional reactions before the start of the season Patients in class (*A*) for example, who give marked reaction to a very dilute amount of pollen extract may have to be started with 2 or 5 units This may be gradually increased every four to five days to 10 15 20 units etc , till a

length The testing material is first used in high dilutions so as to avoid any untoward reactions If the reaction is negative, progressively higher concentrations of the suspected allergenic extract may be tested A positive reaction just as with the scratch technic consists of an urticarial wheal with pseudopods circumscribed by redness and itching Redness and itching alone without pseudopods may also be regarded as a positive response provided a control injection of the same amount consisting of plain diluent either Coca s buffered saline or normal saline is negative

Ophthalmic Tests Occasionally clinically sensitive pollen cases may give negative skin reactions In such individuals the eye test may be used This consists of introducing one or two drops of varying dilutions of pollen extract into the lower conjunctival sac and reading the reaction within fifteen to twenty minutes This test may also be carried out by placing a minute amount of dry pollen into the lower conjunctiva at the end of a toothpick A control test with an indifferent pollen may be applied in the conjunctival sac of the opposite eye The conjunctivae of both eyes are examined after twenty minutes A positive reaction consists of congestion and/or edema of the caruncle and the conjunctiva These signs may be associated with itching of the eye lacrymation and rhinitis If the reaction is severe, a drop of 1 1000 epinephrine may be placed into the lower eyelid with an eyedropper

Nasal Tests Intranasal insufflation tests with pollens molds and dusts or other allergens are used by some for the purposes of diagnosis [illegible]

mucosa

Inasmuch as hay fever patients react to more than one pollen it is important to consider the clinical significance of a reaction in the light of the patients history and treat him accordingly rather than on the basis of the skin tests Thus if a patient reacts to grasses and ragweed but has symptoms during the grass season [illegible]

foods and other substances which are found to be positive on testing the allergic individual Occasionally there are patients with a history of seasonal hay fever who give negative skin or eye tests Despite this treatment of such patients with the appropriate pollens indicated by the history has been found to give satisfactory results

Extracts The type of pollen or other allergenic extracts used in diagnosis and treatment may be commercial or prepared in a well equipped laboratory Different methods are used in the preparations of such material These consist of the weight by volume method pollen or Noon units, total nitrogen content protein nitrogen units (P N U) and protein content In view of these diversities there is no exact mathematic relationship between these various units of standardization The weight by volume and pollen unit method are most commonly employed The protein nitrogen content is advocated by Cooke Various commercial firms use different methods of labelling their preparations and physicians should follow the indicated directions

If one uses an extract employing the weight by volume standardization a 1 100 solution signifies that each milliliter contains 0 01 gm of dry pollen A 1 100 000 solution means that each milliliter contains 0 001 mg of dry pollen

A comparison of various standards of extracts discloses the following

Noon unit based on original pollen weight.

1 Noon unit = 1 100 000 gm or 0 001 mg. pollen (Also called a pollen unit)

Cooke unit * based on protein nitrogen content of extract

1 Cooke unit = 0 00001 mg protein nitrogen per milliliter

Total nitrogen unit based on the total nitrogen content of the extract

1 total nitrogen unit = 0 00001 mg total nitrogen per milliliter (Also called a pollen unit)

Dilution standard based on weight by volume extraction and dilution

A 1 100 extract contains 0 01 gm of extracted pollen per milliliter

Equivalents of 1 50 dilution extract

1 cc of a 1 50 dilution extract (pollen weight by volume) is equivalent to

(1) 20 000 pollen units

(2) 20 000 Noon units

(3) 10 000 P N (protein nitrogen units Cooke)

(4) 0 26 mg total N

(5) 26 000 total nitrogen units

*COOKE R Allergy in Theory and Practice page 529 Philadelphia 1947 W B Saunders Co

Having selected the pollen to which the patient is sensitive on the basis of history skin or eye tests treatment frequently referred to as hyposensitization is instituted This may be carried out preseasonally, co seasonally and perennially

Treatment

Preseasonal Treatment Preseasonal treatment is started each year about three months before the season during which the patient manifests his symptoms The maximum dose of pollen should be reached just prior to the onset of the season The earlier treatment is begun in the disease and the more conscientiously it is kept up the better the chance for immunity to develop in the course of time This applies to children as well as adults To expect that the patient will outgrow his hay fever without treatment is an illusion Rare exceptions to this rule occur but the majority of the untreated patients become subject to frequent colds sinus infection and asthma

In view of the fact that hay fever patients frequently show sensitization to several pollens mixed pollen preparations are often employed in treatment Thus patients allergic to two or three trees may be treated with an extract containing all the three or even more of the suspected tree pollens, such as elm poplar ash sycamore beech maple hickory etc Those sensitive to several grasses related botanically as well as antigenically may be treated with timothy alone or if one prefers with a mixture of several individual grasses contained in the same vial Another method is to determine the pollens to which a patient is sensitive and exposed as well as the degree of sensitiveness to each and then combine them in one individual mixture so that the patient will require only one injection at each visit Thus for example a patient who has hay fever from mid May till the end of July and who reacts equally to both timothy and plantain may be treated with a mixture of equal parts of the two For patients manifesting early and late hay fever one may prepare a mixture of one part timothy and two or three parts of ragweed or one half timothy and plantain and one-half ragweed For the late hay fever cases a mixture of one half or two-thirds ragweed combined with other fall weeds such as amaranth artemisia chenepod ckelbur corn and Iva Since the latter are of s importance in the eastern parts of this country than ragweed pollen, their proportion to ragweed should be less Ragweed extract is usually made up of equal parts of high and low ragweed pollen Of the flowers, aster, dahlia chrysanthemum and golden rod are of varying importance Before making up a final mixture it is suggested that two or three doses of the individual pollens should be given separately in order to gauge the proper proportions for the mixture by means of the local reactions

Based upon the strength of the pollen extract necessary to elicit a marked reaction Van der Veer * who used pollen extracts standardized according to the protein unit technic, classified hay fever patients for the purposes of treatment into four groups (*A*), (*B*), (*C*) and (*D*) Those who gave a marked reaction consisting of redness itching with pseudopods when tested with ten units were put into class (*A*) i e very sensitive Those who showed slight or moderate reactions to 10 units but marked to 100 were placed in class (*B*) or average whereas those who required 1,000 units to elicit a marked reaction were placed in class (*C*) or less sensitive Others yielding moderate reactions to 5 000 or 10 000 units were classed as (*D*) The average maximum dose of pollen required to protect the patient in these various categories was found to be as follows

Patients in class (*A*) needed about 1 000 units class (*B*) about 5 000 units class (*C*) about 10 000 and class (*D*) about 20 000 This is necessarily a rough classification since one must realize that the size of a reaction is not a true index of the clinical sensitivity of the patient (Cooke[11]) Nevertheless it is of value in indicating a safe initial dose and how slowly or rapidly one should proceed with the injections in any one patient If there is little or no reaction following injection of a certain dose the latter may be increased more rapidly If marked reactions follow, the amount should be reduced to an acceptable level and the same dose repeated several times if necessary until it is safe to increase it

The goal in treatment is to give the patient the largest amount of pollen extract to which he is allergic without any marked local or constitutional reactions before the start of the season Patients in class (*A*) for example who give marked reaction to a very dilute amount of pollen extract may have to be started with 2 or 5 units This may be gradually increased every four to five days to 10 15 20 units etc, till a

length The testing material is first used in high dilutions so as to avoid any untoward reactions If the reaction is negative progressively higher concentrations of the suspected allergenic extract may be tested A positive reaction just as with the scratch technic consists of an urticarial wheal with pseudopods circumscribed by redness and itching Redness and itching alone without pseudopods may also be regarded as a positive response provided a control injection of the same amount consisting of plain diluent either Coca s buffered saline or normal saline is negative

Ophthalmic Tests Occasionally clinically sensitive pollen cases may give negative skin reactions In such individuals the eye test may be used This consists of introducing one or two drops of varying dilutions of pollen extract into the lower conjunctival sac and reading the reaction within fifteen to twenty minutes This test may also be carried out by placing a minute amount of dry pollen into the lower conjunctiva at the end of a toothpick A control test with an indifferent pollen may be applied in the conjunctival sac of the opposite eye The conjunctivae of both eyes are examined after twenty minutes A positive reaction consists of congestion and/or edema of the caruncle and the conjunctiva These signs may be associated with itching of the eye lacrymation and rhinitis If the reaction is severe, a drop of 1 1000 epinephrine may be placed into the lower eyelid with an eyedropper

Nasal Tests Intranasal insufflation tests with pollens molds and dusts or other allergens are used by some for the purposes of diagnosis This form of testing is not as a rule satisfactory, because it is difficult to distinguish between irritative and specific reactions of the nasal mucosa

Inasmuch as hay fever patients react to more than one pollen it is important to consider the clinical significance of a reaction in the light of the patients history and treat him accordingly rather than on the basis of the skin tests Thus if a patient reacts to grasses and ragweed but has symptoms during the grass season treatment should be limited to grasses and vice versa This rule applies not only in the case of pollen but also in respect to various molds foods and other substances which are found to be positive on testing the allergic individual Occasionally there are patients with a history of seasonal hay fever who give negative skin or eye tests Despite this treatment of such patients with the appropriate pollens as indicated by the history has been found to give satisfactory results

Extracts The type of pollen or other allergenic extracts used in diagnosis and treatment may be commercial or prepared in a well equipped laboratory Different methods are used in the preparations of such material These consist of the weight by volume method pollen or Noon units total nitrogen content protein nitrogen units (P N U) and protein content In view of these diversities there is no exact mathematic relationship between these various units of standardization The weight by volume and pollen unit method are most commonly employed The protein nitrogen content is advocated by Cooke Various commercial firms use different methods of labelling their preparations and physicians should follow the indicated directions

If one uses an extract employing the weight by volume standardization a 1 100 solution signifies that each milliliter contains 0 01 gm of dry pollen A 1 100 000 solution means that each milliliter contains 0 001 mg of dry pollen

A comparison of various standards of extracts discloses the following

Noon unit based on original pollen weight, 1 Noon unit = 1 100 000 gm or 0 001 mg pollen (Also called a pollen unit)

Cooke unit * based on protein nitrogen content of extract

1 Cooke unit = 0 00001 mg protein nitrogen per milliliter

Total nitrogen unit based on the total nitrogen content of the extract

1 total nitrogen unit = 0 00001 mg total nitrogen per milliliter (Also called a pollen unit)

Dilution standard based on weight by volume extraction and dilution

A 1 100 extract contains 0 01 gm of extracted pollen per milliliter

Equivalents of 1 50 dilution extract

1 cc of a 1 50 dilution extract (pollen weight by volume) is equivalent to

(1) 20 000 pollen units

(2) 20 000 Noon units

(3) 10 000 P N (protein nitrogen units Cooke)

(4) 0 26 mg total N

(5) 26 000 total nitrogen units

* COOKE R Allergy in Theory and Practice page 529 Philadelphia 1947 W B Saunders Co.

Having selected the pollen to which the patient is sensitive on the basis of history skin or eye tests treatment frequently referred to as hyposensitization is instituted This may be carried out preseasonally, co seasonally and perennially

Treatment

Preseasonal Treatment Preseasonal treatment is started each year about three months before the season during which the patient manifests his symptoms The maximum dose of pollen should be reached just prior to the onset of the season The earlier treatment is begun in the disease and the more conscientiously it is kept up the better the chance for immunity to develop in the course of time This applies o children as well as adults To expect that the patient will outgrow his hay fever without treatment is an illusion Rare exceptions to this rule occur but the majority of the untreated patients become subject to frequent colds sinus infection and asthma

In view of the fact that hay fever patients frequently show sensitization to several pollens mixed pollen preparations are often employed in treatment Thus patients allergic to two or three trees may be treated with an extract containing all the three or even more of the suspected tree pollens such as elm poplar ash sycamore beach maple hickory etc Those sensitive to several grasses related botanically as well as antigenically may be treated with timothy alone or if one prefers with a mixture of several individual grasses contained in the same vial Another method is to determine the pollens to which a patient is sensitive and expose as well as the degree of sensitiveness to each and then combine them in one individual mixture so that the patient will require only one injection at each visit Thus for example a patient who has hay fever from mid May till the end of July and who reacts equally to both timothy and plantain may be treated with a mixture of equal parts of the two For patients manifesting early and late hay fever one may prepare a mixture of one part timothy and two or three parts of ragweed or one half timothy and plantain and one-half ragweed For the late hay fever cases a mixture of one half or two thirds ragweed combined with other fall weeds such as amaranth artemisia chenepod cocklebur corn and Iva Since the latter are of less importance in the eastern parts of this country than ragweed pollen, their proportion to ragweed should be less Ragweed extract is usually made up of equal parts of high and low ragweed pollen Of the flowers aster dahlia, chrysanthemum and golden rod are of varying importance Before making up a final mixture it is suggested that two or three doses of the individual pollens should be given separately in order to gauge the proper proportions for the mixture by means of the local reactions

Based upon the strength of the pollen extract necessary to elicit a marked reaction Van der Veer * who used pollen extracts standardized according to the protein unit technic, classified hay fever patients for the purposes of treatment into four groups (*A*) (*B*) (*C*) and (*D*) Those who gave a marked reaction consisting of redness itching with pseudopods when tested with ten units were put into class (*A*) i e very sensitive Those who showed slight or moderate reactions to 10 units but marked to 100 were placed in class (*B*) or average, whereas those who required 1 000 units to elicit a marked reaction were placed in class (*C*) or less sensitive Others yielding moderate reactions to 5 000 or 10 000 units were classed as (*D*) The average maximum dose of pollen required to protect the patient in these various categories was found to be as follows

Patients in class (*A*) needed about 1 000 units class (*B*) about 5 000 units class (*C*) about 10 000 and class (*D*) about 20 000 This is necessarily a rough classification since one must realize that the size of a reaction is not a true index of the clinical sensitivity of the patient (Cooke[12]) Nevertheless it is of value in indicating a safe initial dose and how slowly or rapidly one should proceed with the injections in any one patient If there is little or no reaction following injection of a certain dose the latter may be increased more rapidly If marked reactions follow the amount should be reduced to an acceptable level and the same dose repeated several times if necessary until it is safe to increase it

The goal in treatment is to give the patient the largest amount of pollen extract to which he is allergic without any marked local or constitutional reactions before the start of the season Patients in class (*A*), for example who give marked reaction to a very dilute amount of pollen extract may have to be started with 2 or 5 units This may be gradually increased every four to five days to 10 15 20 units etc till a

level is reached which is the maximum safe dose that the patient can take before the onset of the season Patients in class (*B*) may be given 20 units as the initial dose in class (*C*) 50 and in class (*D*) 100 units It has been found that individuals in class (*A*) may require less pollen extract to protect them for the season than those in class (*C*) or (*D*) The writer has seen some cases in class (*A*) who were protected with as little as 75 to 100 units in contrast to those in class (*C*) or (*D*) who needed as much as 10 to 15 000 units for satisfactory results As a rule 15 to 20 injections may be necessary to reach a maximum required dose in the average case others may need as many as 30 or more If one uses extracts standardized according to the weight by volume method one may begin treating very sensitive patients with 0 1 ml of 1 10 000 dilution then 0 2 0 3 0 4 and 0 5 and finally go on to 1 5000 1 500 and 1 50 strengths Irrespective of the type of extract used when the season is on the final dose reached preseasonally should be reduced to a half or less and repeated once every one or two weeks throughout the pollinating season provided no adverse reactions develop If the latter occur the dose should be decreased to a tolerated minimum or if necessary stopped altogether during the season

Co seasonal Treatment Individuals who present themselves for treatment shortly before the season or during the season may obtain relief by the administration of small amounts of pollen extract every day for three to five days followed by gradually larger doses at two or three day intervals If no effect is obtained symptomatic therapy in the form of antihistaminics or cortisone should be employed

Perennial Treatment Patients who have been successfully treated may be given the maximum amount of pollen extract which controlled their symptoms every three to four weeks throughout the year to maintain immunity The advantage of this form of therapy is that the results may be better although not always the number of injections may be lessened and permanent protection is more apt to be reached The disadvantage of this treatment lies in the fact that many patients may become saturated and develop constitutional symptoms with doses which they previously tolerated If this occurs all treatment should be stopped and the normal preseasonal treatment substituted

Constitutional reactions which may develop in the course of treatment not only may be disagreeable but also may be dangerous and occasionally even fatal They also may upset the patient s tolerance so that adequate protection may be impossible The major constitutional symptoms consist of itching of the palms of the hands or of the body generalized urticaria sneezing and cough or severe asthma and occasionally abdominal or uterine cramps The sooner these signs appear the more violent is the reaction apt to be Reasons for such untoward manifestations are (1) the administration of a larger dose than the patient can tolerate and (2) the inadvertent injection of the extract directly into the vein With the onset of constitutional symptoms a tourniquet should be applied above the injection site and epinephrine injected above the tourniquet or in the [illegible] of be be ave subsided

In addition to pollen immunization avoidance of pollens is best achieved by the installation of pollen filters in the windows of the patient s home or air conditioning apparatus The latter is obviously more desirable because it both filters the pollen and dust and cools the room at the same time If neither is possible the patient may sleep in a room with the windows closed and keep the door open for ventilation from an adjoining room Elevation of the head on several pillows made preferably of foam rubber will facilitate drainage of the nose

Results In view of the many variables that enter into the evaluation of the results in the treatment of hay fever (degree of individual susceptibility amount of exposure locale weather conditions etc) it is difficult to give precise figures as to the effectiveness of immunization In general it may be stated that with proper treatment satisfactory results may be obtained in 90 per cent of cases of tree and grass hay fever and in about 80 per cent of patients with ragweed hay fever Satisfactory results indicate that the patient was either completely relieved or had occasional attacks. About 15 per cent will have slight or moderate relief and 5 per cent will not be benefited at all

Besides the favorable effects of immunization successfully treated patients are less apt

to develop winter colds and sinus infections, and rarely develop asthma Thirty to 50 per cent of untreated patients ultimately develop pollen asthma which may become perennial and difficult to cure It is therefore important that hay fever be properly treated to prevent such a complication

Symptomatic Therapy The antihistaminics are the most satisfactory drugs for control of the symptoms of hay fever when immunization has not been carried out or in cases in which symptoms persist despite treatment The more common antihistaminics used are pyribenzamine,® chlor-trimeton,® benadryl® and chephorin ® The major disagreeable side effects from these drugs are drowsiness, occasionally nausea, pyrosis and in certain cases depression Some patients respond better to one antihistaminic as compared with another After trying different preparations the patient frequently finds one which suits him the best In the treatment of eye symptoms such as itching and tearing one may use two to three drops of epinephrine 1 2000 or hydrocortone ophthalmic suspension 2 5 to 5 per cent two or three times a day

Cortisone, hydrocortone or metricortin may be used in cases in which immunization has not been carried out or has failed to attain results, and in which antihistaminic drugs or other agents fail to control the symptoms of seasonal rhinitis In a study by Schiller and Lowell,[1] 100 mg of oral cortisone per day administered for four days (25 mg every four hours) provided complete to satisfactory relief in forty two of fifty-one patients with hay fever which could not be controlled by specific pollen therapy, antihistaminics or other types of medication Nine patients failed to obtain relief Ten per cent of this group of fifty-one patients had seasonal asthma as a complication Results in patients who reacted favorably were achieved within two to three days after the start of this medication Six to nine days after cortisone was discontinued the symptoms began to reappear, in some patients this was even sooner The therapeutic effects with the use of hydrocortone (free alcohol) in the symptomatic treatment of hay fever and asthma have also been reported by Schwartz[2] The daily initial dose was 80 mg in four divided doses This was rapidly reduced to a maintenance dose of 40 to 60 mg Of ten patients with severe hay fever, excellent results were obtained in seven, marked relief in two and moderate relief in one Metacortin has likewise been used successfully by the writer on a short term basis in the supplementary treatment of severe cases of hay fever which did not respond to the usual desensitization procedures

Prognosis Some patients outgrow their hay fever after varying periods of time while many retain it practically all their lives At present immunization is more helpful than any other form of therapy in effecting a cure and preventing such complications as chronic sinusitis or asthma Since it is impossible to gauge when a patient is cured, it is advisable for the individual who has been symptom-free for several years post treatment to take one injection a month through the season rather than take a chance and discontinue treatment Although some patients who fail to do so may remain permanently free of symptoms, others may have a gradual return of hay fever and again have to resume treatment

PERENNIAL ALLERGIC RHINITIS OR VASOMOTOR RHINITIS

Patients with seasonal pollen rhinitis usually become symptom-free at the end of the pollinating season whether they are treated or not There is, however, a substantial number of atopic, i e, constitutionally allergic, individuals who may develop symptoms of rhinitis not only from pollen but also as a result of sensitization to various dusts, animal danders, fungi, foods, drugs and/or bacterial infection Thus instead of manifesting nasal symptoms for one, two or three months a year, depending upon a particular pollen season, they may suffer all year long with coryza, sneezing, stuffiness and itching of the nose, loss of the sense of smell and taste, and/or cough because of continuous exposure to the aforementioned allergens If such symptoms continue year after year, these patients are said to have perennial allergic rhinitis or chronic vasomotor rhinitis In certain instances besides allergy to extrinsic excitants prolongation and accentuation of the vasomotor symptoms may be traced to psychosomatic factors The role of these has to be evaluated in each individual case

The patient subject to chronic allergic rhinitis from exposure to various extrinsic factors may develop superimposed respiratory infections due to viruses and other bacterial agents, these may terminate favorably without

any residue, just as in the so-called normal person There are other persons however whose chronically hypersensitive edematous mucous membranes present an ideal environment for the propagation of the invading microorganisms which act as additional sensitizing agents of the nasal tissues Persistence of such sensitization leads to chronic proliferative changes of the mucous membrane of the nose which may extend to the sinuses as well giving rise to chronic rhinitis and hyperplastic sinusitis with polypoid formation

The bacterial flora in the nose and paranasal sinuses in these cases is never static The common organisms recovered consist of Staphylococcus aureus hemolytic streptococcus viridans Micrococcus catarrhalis influenza bacilli and pneumococci

Allergic individuals with infective vasomotor rhinitis and chronic hyperplastic sinusitis may develop symptoms from exposure to a relatively small number of bacterial organisms A smear of nasal secretions in these cases may show a preponderance of eosinophils indicative of the allergic nature of the process Since similar findings are present in non infective vasomotor rhinitis essentially due to sensitization to inhalants foods or drugs the presence of eosinophilia cannot always be used as a basis for differentiation between the infective and non infective forms of vasomotor rhinitis and sinusitis Hyperplastic sinusitis may frequently be complicated by an acute intercurrent suppurative process wherein the number of bacteria may be greatly augmented and the eosinophils temporarily disappear

Treatment Just as in other forms of hypersensitivity treatment of vasomotor rhinitis is based on determining the cause and eliminating it if possible This is feasible in cases in which the exciting agents are removable such as foods or inhalants Thus offending foods the allergenicity of which is determined either by skin tests checked by clinical trial or elimination diets should be excluded from the diet Inhalant allergens such as contained in feather pillows can be avoided by replacing them with foam rubber Cats and dogs should be removed from the environment If contact cannot be avoided immunization by intracutaneous injection with specific allergens must be carried out as for example against pollens house dust molds orris root and various epithelia (chicken feathers animal hair etc) House dust is an important exciting agent of perennial rhinitis It may take on seasonal characteristics if the patient moves in the summer to a country house which has accumulated dust through the winter months It may also be a factor in the winter when persons who lived out doors during the summer return home or attend schools where the windows are shut and radiators are open

Dust sensitive individuals may require injections with this allergen for prolonged periods depending upon the case The dust used may be either autogenous collected at home by means of a vacuum cleaner and extracted according to standard technics or stock dust required commercially The most popular commercial dust is called Endo-house dust This is quite concentrated and the manufacturer recommends that it be diluted to 1 400 000 or 1 40 000 before using Autogenous or stock dust extract is employed either in a concentrated form or 1 10 dilution depending on the size of the preliminary skin reaction to these preparations The safest method is to begin with 0 1 ml of 1 10 dilution This is increased gradually by 0 1 ml each week for about ten injections Then one may change to the concentrated extract beginning with 0 1 ml and increasing the dose progressively to 0 5 ml The last dose may be repeated at bi weekly intervals as long as it is indicated

Other inhalant extracts such as orris root chicken dog cat or horse epithelia may be employed for hyposensitization when the patient cannot avoid them These are administered at five day intervals beginning with the smallest dose which will give a positive skin reaction and carefully increased to a maximum tolerated amount which will give no untoward reactions Children whose nasal mucous membranes are boggy due to irritation from dust when crowded into hot stuffy school rooms are especially susceptible to upper respiratory infections transmitted by their fellows

When bacterial infection is superimposed upon chronic vasomotor rhinitis due to extrinsic factors both conditions have to be treated before any relief can be obtained The infective element has to be determined by a thorough rhinologic examination supplemented by x rays of the sinuses and culture of aspirated secretions from the infected sinuses After determining the nature of the infective organisms and testing their sensitivity to various anti

biotics, treatment with the most suitable anti-
biotic should be instituted It should be pointed
out in this connection that of all the antibiotics,
penicillin is the most actively allergenic and
great care should be exercised in its use in
allergic individuals. Unless absolutely impera-
tive, it is safer to use broad spectrum anti-
biotics although these also may show side
effects While antibiotics are of great value in
influencing the acute infections, they are less
effective in the treatment of established foci
of infection in chronically diseased sinuses.
To eliminate these radical surgery may have
to be performed However, before this is under-
taken, allergy to extrinsic factors should be
thoroughly investigated and properly treated
in order to see whether the sinus disease will
subside by controlling the underlying predis-
posing sensitizing agents

Besides surgery and suitable antibiotics, im-
munization by the use of either stock or au-
togenous vaccines, or polyvalent bacterial fil-
trates prepared from cultures of the sinuses and
nasopharynx should be employed Stevens[2] has
reported favorable results in the treatment of
children with recurrent bacterial rhinitis by the
use of such bacterial filtrates

Symptomatic treatment of the nasal symp-
toms is usually necessary to relieve the patients
of the coryza and blocking of the nose due to
edema of the mucous membrane To control
the running of the nose due to inhalant
allergy antihistaminics such as pyribenzamine,
benadryl, thephorin and chlor-trimeton are of
value To relieve the stuffiness, oral medication
in the form of quadrinal[3] (ephedrine hydro-
chloride 3/8 gr., phenobarbital 1/8 gr., phyllicin
1/2 gr and potassium iodide 5 gr) is to be pre-
ferred to intranasal instillation of drugs such
as ephedrine or neosynephrine frequently
employed to decongest the edematous mem-
branes Although such nasal medication is
helpful on a short term basis, its prolonged
use not only lessens its efficacy but also leads
to atony of the capillary walls and increases
the bogginess of the mucous membranes. These
drugs may also sensitize the nasal mucous
membranes of the patient and in this way
prolong the congestion of the nose Unpleasant
systemic effects in the form of nervousness and
tachycardia as well as insomnia have been noted
following the use of ephedrine preparations.

Oral cortisone and hydrocortone have also
been employed to relieve nasal blocking in
cases of vasomotor rhinitis While these hor-
mones are helpful in reducing polyps and the
inflammatory edema of the nasal mucous
membranes, the effects are temporary Dis-
continuance of their use results in gradual
return of the polyps and general nasal dis-
comfort as long as the allergenic excitant is
operative Nasal sprays containing hydrocor-
tone and cortisone with and without antibiotics
are now available These may be helpful in
reducing the congestion and polypoid swelling
as long as they are employed They do not,
however, cause permanent reversibility of the
reactive tissue

BRONCHIAL ASTHMA

Etiology Bronchial asthma and allergic
cough, just like vasomotor rhinitis, may be the
result of sensitization to (1) extrinsic factors
such as inhalants, foods and drugs (about
50 per cent), (2) intrinsic factors, i e, infection
arising in the upper and lower respiratory
tract in the form of bronchitis or pneumonia,
(3) a combination of intrinsic and extrinsic fac-
tors and (4) undetermined etiology In the
last category cases may be included in which
psychosomatic factors may occasionally play
a dominant role in some and a complicating
role in others

Prolonged bronchial asthma in adults be-
ginning after forty years of age is frequently
but not exclusively due to chronic foci of infec-
tion in the upper respiratory tract and/or in
the sinuses, and less often in the teeth or tonsils
In about 15 per cent of the cases antecedent
infections in the pulmonary tract, such as
bronchitis or pneumonia, may serve as sources
of bacterial sensitization Despite the fact that
many such individuals may not give any posi-
tive whealing skin reactions to account for their
symptoms, allergy to external factors, in-
halants, foods, etc, or physical agents such as
cold or heat and humidity may be present and
should be looked for constantly

The relationship between chronic sinusitis
and bronchial asthma has been subject to con-
siderable controversy This question is impor-
tant not only from the point of view of etiology
but also that of therapy The studies of Cooke
and Grove,[4] Chobot,[5] Gottlieb,[6] Kern and
Schenck,[7] Guerrant, McCausland and Swine-
ford,[8] Hansen-Pruss[9] and others indicate that
chronic sinusitis, both hyperplastic and sup-
purative, may antecede and be associated with

bronchial asthma in children as well as adults in proportions varying from 20 to 41 per cent In fact, involvement of the upper respiratory tract antedates asthma in a large proportion of patients It may be looked upon as a first line of defense in the spread of the allergic process to the lower respiratory tract With prolonged allergenic insults of various kinds (extrinsic and intrinsic) this defense sooner or later breaks down and there is a shift in the allergic response from the nasopharyngeal to the lower bronchopulmonary area The question at this point arises whether (1) the bacteria in chronic sinusitis serve as a source of sensitization and cause the development of the subsequent asthma, as claimed by the aforementioned investigators, or (2) as contended by Hansel,[10] Piness and Miller[11] as well as others, the organisms found in the sinus mucous membrane are secondary invaders which have nothing to do with the pulmonary reaction Finally there is the viewpoint of Tuft[12] who believes that chronic hyperplastic sinusitis bears no direct etiologic relationship to the asthma but is a part of the asthma syndrome

While allergy to extrinsic agents as a cause of both acute and chronic bronchial asthma is generally accepted and may be supported by skin tests, elimination of offending agents and other measures, the specific sensitizing role of bacteria in the causation of chronic asthma is more difficult to prove Routine skin tests with the common bacteria are unreliable, and corresponding circulating antibodies have thus far not been demonstrated with any degree of regularity The evidence therefore that infection may be the source of specific bacterial sensitization is in part circumstantial, i e, clinical, and in part based on the following blood and tissue findings (1) the presence of increased blood eosinophilia in patients with infective asthma, (2) the finding of eosinophils in the nasal discharge and mucopurulent sputum of the asthmatic patient, (3) the presence of eosinophil cells in the walls of small- and medium sized bronchi in chronic infective asthmatics associated with purulent bronchitis and the presence of various bacteria at autopsy, and (4) the ability to precipitate asthmatic seizures in some patients by the injection of stock and especially of autogenous vaccines (Cooke) [13] This type of response may appear promptly and may be anaphylactic in nature as noted by us in several instances, or it may develop twelve to forty eight hours after the introduction of a vaccine or various bacterial fractions Stevens[14] has also observed such reactions in selected patients when injected under ideal conditions The latter implies the parenteral introduction of the bacterial products at a time when the respiratory tissues are in a relatively quiescent state Otherwise any kind of injection, changes in temperature, emotional stress, chemical or mechanical irritation may initiate a train of symptoms in the respiratory tract similar to those induced by specific sensitization In addition to the evidence that specific bacterial sensitizations may be responsible for asthmatic attacks, the precipitation of asthmatic seizures in the allergic individual by respiratory infections with microorganisms unrelated to the primary sensitizing bacteria may also occur This type of reaction is immunologically nonspecific and may be explained on the basis of the Shwartzman phenomenon

Clinical Picture The symptoms and signs of the ordinary acute attack of asthma are too well known to warrant description Since the wheezing in the average asthmatic is the result of edema and spasm of the bronchi the lungs show no abnormal changes on x ray examination The heart is perfectly normal although the pulse may be rapid due to transient anoxemia The sputum usually contains eosinophils The blood eosinophils average about 10 per cent With the termination of the acute paroxysms, the affected tissues are as a rule restored to normal However, where the exciting agent or agents are not determined or if detected are not eliminated by proper treatment early enough in the course of the illness when the best results can be achieved, prolonged disease due to persistence of the allergenic stimulation will ensue Depending upon the degree of individual susceptibility, the character of the exciting agent and the nature of the shock tissue involved in the allergic response, the following clinical syndromes may supervene group of bronchial asthma with bronchopulmonary reactions, with or without secondary cardiovascular complications, and group II bronchial asthma associated with vascular allergy

I *Bronchial Asthma Associated with Bronchopulmonary Reactions and Secondary Cardiovascular Complications* The clinical course in the untreated patient with chronic asthma due

to intrinsic factors alone or in combination with extrinsic exciting agents may develop along the following lines In view of his allergic predisposition the asthmatic individual has an enhanced susceptibility to respiratory infections Each acute attack of the latter is usually accompanied by an asthmatic seizure which may be associated with bronchitis, so called asthmatic bronchitis In some instances this may be complicated by bronchopneumonia While the pneumonia is at its height, the asthma may temporarily disappear only to return with increased intensity during convalescence This may be attributed to bacterial sensitization arising from residual foci of infection in the sinuses or lower respiratory tract, or possibly to autoantigens accompanying tissue destruction Under such circumstances delayed healing of the lung may be followed with fibrosis at the sites of previous inflammation and by the development of compensatory emphysema

In some cases the process may be arrested at this juncture In others the continuous existence of some underlying inhalant or food allergy may serve not only to prolong the patient s symptoms but also act as an additional factor in further enhancing the susceptibility to respiratory infections Repeated insults to the pulmonary tissues in the form of recurrent attacks of bronchopneumonia may result in bronchial obstruction due to inflammatory edema and this in turn may lead to atelectasis of the contiguous lung In certain instances bronchostenosis and/or bronchiectasis may follow Healing of inflamed areas may be succeeded by further scarring and by extension of the fibrosis and emphysema with gradual development of pulmonary insufficiency

The progressive shrinking of the vascular bed as a result of pulmonary fibrosis and emphysema leads to hypertension of the lesser circulation which is frequently accompanied by sclerosis of the pulmonary vessels This in turn may create right ventricular strain, cor pulmonale cardiac insufficiency and ultimately death from right sided cardiac failure

II *Bronchial Asthma Associated with Vascular Allergy* Although the most common forms of chronic asthma encountered in practice are those in group I there is a much smaller category of patients (group II) who present themselves with symptoms of asthma primarily based on allergic reactions in the connective tissue vascular system, i e , the mesenchymal tissues in the body, this is in contrast to that seen in group I where ectodermal structures are the primary seat of attacks

The etiology of asthma based on vascular allergy just as in the ordinary types of bronchial asthma may be due to extrinsic as well as intrinsic factors The former may be inhalants such as pollens dusts and foods, and the latter bacterial infection In twenty one cases studied by the writer[15] bacterial sensitization arising from chronic sinus and res

polysaccharide fractions followed after twenty-four hours by delayed reactions to the nucleoprotein residues contained therein These were accompanied by focal and systemic reactions in the form of asthma and purpura The purpura indicated the implication of blood vessels in the hyperergic response In three cases in which asthma was originally due to inhalant

employed in the treatment of the asthma from which these patients suffered Similar cases have been reported in the literature following sensitization to these drugs as well as iodides, polythiouracil, dilantin® and foreign serum Experimentally, vascular allergy has been induced in rabbits and rats following sensitization by bacteria horse serum serum globulin and other substances

Evidence that the asthma and cough which the patients in this group presented were manifestations of allergic reactions in the pulmonary vessels and associated structures was found in the x ray studies of the lung as well as the pathologic changes noted at autopsy

Roentgen examination disclosed that the pulmonary lesions were migratory in character

against the chest wall peripherally In addition to the hilar lesions, consolidated areas may appear in the periphery extending toward the

bases suggestive of lobar pneumonia Infiltrations extending symmetrically downward in both lungs paralleling the bronchi in the form of narrow plate-like homogeneous masses have also been noted The paucity of physical signs in the lungs which was characteristic in the majority of these cases is to be attributed to the predominantly interstitial nature of the involvement

tion of the basement membrane characteristic of bronchial asthma The pulmonary parenchyma showed periarterial and pericapillary inflammatory reactions with eosinophilic infiltration of the interalveolar septa and granulomatous lesions associated with organized eosinophilic and interstitial pneumonia The changes in the pulmonary vessels varied from simple thickening of small arteries involving the intima to acute arteritis as well as necrotizing arteritis with perivascular eosinophilic infiltrations, endarteritis and thrombosis of small arteries and veins with areas of hemorrhagic infarction of the lung

The most significant feature which distinguishes this type of asthma from group 1, besides the characteristic pulmonary lesions, is the presence of protracted fever (temperatures may range from 99° to 104°F) and marked blood eosinophilia The latter may vary from 20 to 70 per cent and the total white blood count may reach 40 000 to 50,000 cells and even higher Depending upon the number of shock tissues involved in the hyperergic vascular response, the patients may be grouped as follows

1 Mild cases consisting of individuals who have an attack of asthma or cough associated with pulmonary infiltrations, fever and increased blood eosinophilia usually following an upper respiratory infection or the ingestion of drugs The signs and symptoms may persist for several weeks and gradually subside without any residue Such patients may be symptom-free for a number of months or a year and then suddenly have a recurrence This type of case is comparable to those described by Loeffler[13] except that his cases were even milder and had no asthma They were originally regarded by Loeffler as due to tuberculous infection but later on as manifestations of ascaris sensitization as well as other allergens

2 Patients with asthma previously described by us, who besides having migrating pulmonary eosinophilic infiltrations show electrocardiographic changes in the auricular and ventricular complexes suggestive of involvement of the coronary vessels and myocardium

3 Patients who manifest asthma pulmonary eosinophilia, abnormal electrocardiographic changes and pleural effusions containing sterile fluid with 90 to 100 per cent eosinophil cells indicative of the participation of the capillaries of the pleural serous membranes in the allergic response All of these manifestations may be reversible in the early phases of the disease With termination of the asthmatic attacks the pulmonary lesions and the electrocardiographic changes as well as pleural effusion may resolve only to start all over again with the next asthmatic attack without, however, affecting any other new shock organs These patients may recover and remain well for many years

4 Patients in whom there is progressive extension of the hyperergic vascular process This gives rise to varying clinical pictures (a) Cases of asthma, pulmonary eosinophilia, cardiac involvement with electrocardiographic changes eosinophilic serous effusions in the pleura pericardium and peritoneum with enlargement of the liver and spleen resembling Pick's syndrome This suggests that the latter may be a manifestation of vascular allergy In some of these cases constrictive pericarditis may develop and the entire disease process may stop short at this point Ultimately such patients may die of cardiac failure (b) Cases in which the hyperergic vascular disease not only may affect the cardiopulmonary and serous tissues but also may spread to the liver, spleen, kidneys, joints, nerves and cutaneous shock organs giving rise to the clinical syndrome of periarteritis nodosa

The basic anatomic changes in patients in this group who come to autopsy consist of widespread vascular lesions characterized by various degrees of necrotizing arteritis, fibrosing arteritis in long standing cases, inflammatory changes in the veins, and granulomatous lesions within the vessel walls and in the connective tissue throughout the body

The lesions in the heart responsible for the abnormal electrocardiographic changes vary in different cases In some they consist of diffuse eosinophilic infiltration of the myocardium

so-called eosinophilic myocarditis In others fibrosis of the myocardium with minimum involvement of the coronary vessels is the most conspicuous feature In still others varying degrees of arteritis in the coronary vessels, including periarteritis nodosa, prevail Granulomatous nodules simulating the Aschoff body have also been found occasionally in the connective tissue septa of the myocardium

About 18 per cent of cases of periarteritis nodosa present manifestations of asthma In these patients the latter may be regarded as a symptomatic expression of an underlying connective tissue vascular reaction in the lungs The periarteritis nodosa-like lesions in cases with asthma which are associated with granulomatous alteration within the vessel walls and in connective tissue are looked upon by Churg and Strauss[19] as an entity apart from classical periarteritis nodosa These workers, in agreement with Zeek, Smith and Weeter,[20] believe that necrotizing arteritis and/or periarteritis

periarteritis nodosa is not dependent upon an allergic mechanism These authors designate the former group allergic angiitis This concept needs further classification It may be noted that it is difficult to exclude an allergic pathogenesis in any given case purely on the basis of a negative history of allergy or asthma, nor does the absence of extravascular granulomatous changes exclude the existence of hypersensitivity

Cases of asthma or cough with prolonged pulmonary eosinophilia due to vascular allergy must be distinguished from so-called cases of tropical eosinophilia and from cases of pulmonary eosinophilia with asthma due to parasitic infections such as coccidioidomycosis, amebiasis microfilaria and Bilharzia This may be done on the basis of the fact that patients with tropical eosinophilia, the cause of which in 60 per cent of cases has been attributed to infestations with mites but not proved, can be definitely cured by the administration of arsenicals, whereas the types due to parasitic infestations respond to specific chemotherapy The previously described patients with asthma based on vascular allergy resulting from polyvalent sensitization are not benefited by any of these specific drugs, in fact they may become sensitized to them

The fate of the ordinary asthmatic who is inadequately treated is protracted illness He may die in status asthmaticus or succumb to various complications of a general nature intercurrent infections especially in the lungs, such as pneumonia, cardiac failure due to cor pulmonale, coronary artery disease or vascular accidents due to arteriosclerosis and/or hypertension The clinical course in cases of asthma associated with hyperergic vascular disease depends on the extent and character of the shock organs involved In those instances in which the vascular disease becomes generalized, the period of survival is usually about one to three years depending upon the degree of cardiac or renal involvement During the time when the cardiac or renal symptoms dominate the clinical scene, the asthma may disappear Should the patient present himself at this stage for the first time, he may be classified as having a cardiac or nephritic condition and the asthma may be considered an unrelated episode As a matter of fact, it may be of the utmost importance in identifying

cases due to hypersensitivity may appear in childhood and once established may recur for many years, it is obviously important to initiate prophylactic measures to prevent their exacerbation and development into a chronic state Children subject to eczema, frequent colds and bronchitis should be studied for the presence of an underlying allergy Wherever possible they should be immunized against

the seat of recurrent acute infection and are associated with asthmatic attacks should be removed If they are merely enlarged, they should be left alone unless they interfere with respiration A *laissez faire* policy in the hope that "the youngster will outgrow his allergies" is to be condemned

The well established procedure of testing with common allergens such as pollens, dust, inhalants and foods should be used in every case of asthma It will be found that foods and inhalants as well as bacterial infections are most frequent causes of asthma in children

In the older individuals past forty foods are less of a factor, whereas inhalants and infection play a more important role Positive skin reactions when present are important guides in treatment provided they are properly evaluated by clinical trial

The procedure in the diagnosis and treatment of asthma is just the same as in the case of vasomotor or seasonal rhinitis Once the diagnosis is established and the exciting factors eliminated as far as possible, desensitization to inhalants, etc , should follow If the asthma is seasonal due to pollen, desensitization to the incriminating pollen should be carried out as indicated previously The results in the treatment of uncomplicated pollen asthma are usually good If, however, asthma is due to polyvalent sensitization such as pollens foods, inhalants dust and/or molds, or infection, it is necessary to consider each one of these factors in the therapeutic management Thus clinically proven sensitizing foods should be eliminated from the diet Desensitization to pollen dust and/or molds should be carried out at the same time if necessary Some hay fever patients as well as pollen asthmatics who are also food sensitive may be able to eat the foods to which they are allergic after the pollen season but not during the pollen season In such cases it is important that the offending foods be excluded during the particular pollen season otherwise poor results will be obtained from desensitization alone Other inhalants, such as feathers dust dog or cat epithelia, should be removed from the patient s environment The rooms which the patient occupies should be as free from dust as possible Wool rugs may have to be replaced by linoleum and washable rugs heavy wool draperies changed to cotton or fiber glass materials which are readily cleaned Old overstuffed chairs or sofas containing feathers, molds or horse hair should also be removed Foci of infection in the teeth and sinuses should be properly investigated and controlled

Chronic Sinus Disease The problem of dealing with patients who have chronically affected sinuses antecedding long standing asthma is both difficult and controversial Those who contend that sinus disease and asthma are manifestations of the same process in two different segments of the respiratory tract dependent upon the same causative factors advise leaving the sinuses alone and treating the underlying disease conservatively While it is true that both conditions may be attributable to the same allergenic excitants it should be borne in mind that involvement of the sinuses may precede asthma for many years and in many individuals the latter may never materialize When asthma does finally appear it may do so irrespective of any fresh infection in the lung but as a result of sensitization by bacterial products derived from organisms long established in the sinal mucosa or other foci in the respiratory tract It would seem logical therefore, in order to remove a major source of sensitization to resort to radical sinus surgery only in such cases in which infection is definitely proved to be a cause using criteria suggested by Goldman [21] and in cases in which the sinus disease is so far advanced as to warrant surgical interference under any circumstances

The results due to surgery vary with different operators and probably depend upon the individual patient Grove[22] reports 76 per cent improvement in a group of 110 patients completely operated upon and 36 per cent in fifty three patients incompletely operated upon The experiences of Weille,[23] Hansel[16] and Gay[24] are less impressive Failure following operation may be due to the fact that once the bronchi have become the reacting shock organ all kinds of non specific stimuli such as cold dampness rain wind and psychosomatic factors may at one time or another precipitate attacks of asthma It is therefore important to treat the individual with every therapeutic measure available Immunization with stock or autogenous vaccines or polyvalent bacterial filtrates may be suitable in some instances and change of climate may be suitable in others Psychotherapy may be employed if desired after first, however, ruling out allergic factors and organic disease which may also give rise to asthma like symptoms The latter may be tumors and foreign bodies in the larynx, trachea bronchi and lungs obstruction by mediastinal growths such as sarcoma, Hodgkin's disease tuberculous glands, pulmonary tuberculosis cardiac and renal asthma and chronic emphysema

Symptomatic Treatment The symptomatic treatment of asthma is to be looked upon as an aid in controlling the acute episodes and not as the ultimate objective To control mild attacks of asthma ephedrine ¾ gr alone or combined with codeine ½ gr and aminophylline gr 3 in capsule form may be used when required Proprie-

tary preparations such as tedral® or quidrinal® may also be employed Inhalation of epinephrine 1-100 vaponephrin® or isuprel® hydrochloride 1 200 through a nebulizer is likewise

cutaneous injections of epinephrine 1-1000 in doses of 0 5 cc or less depending upon the age of the patient This medication should be avoided if the patient has coronary artery disease or severe hypertension It may, however,

in doses of 0 5 to 1 cc subcutaneously In patients who become epinephrine fast aminophylline may be given intravenously in doses of 3¾ or 7½ gr (0 24 to 0 48 gm) dissolved in 10 to 20 cc of sterile solution This should be administered very slowly at the rate of 1 ml per minute to avoid symptoms such as hyperpnea, nausea, vomiting and collapse so-called speed shock This may be repeated if necessary within four to six hours

Aminophylline may also be used as a suppository or small retention enema Suppositories usually are prepared with 5 to 7½ gr of aminophylline (0 324 to 0 5 gm) with or without phenobarbital In children suppositories containing 1½ to 4 gr of aminophylline may be successfully employed In place of suppositories 7½ gr of aminophylline (0 5 gm) dissolved in 20 cc of water can be given by rectal installation with a small catheter

Iodides in the form of potassium or sodium, orally, is one of the oldest remedies in asthma It may be administered in 5 to 25 drops daily It is most important however to determine in each case whether the patient is allergic to iodides, otherwise severe reactions both local and systemic may ensue, especially if given intravenously

For ordinary sedation of the ambulatory asthmatic chloral hydrate may be used orally

range of safety Nevertheless some patients may be sensitive to this drug and addiction can be easily produced It should therefore be given with a great deal of circumspection Morphine should be strictly avoided because of its untoward effect on the respiratory centers Atropine must never be used on account of its drying effect upon bronchial secretions

In patients with cyanosis oxygen through nasal catheter or mask is of significant aid in therapy

Intercurrent infections should be treated by suitable antibiotics, preferably parenterally rather than by aerosol in order to avoid possible

always be positive even if the patient is sensitive to penicillin It is therefore safest to administer this drug orally to avoid any untoward reactions Broad spectrum antibiotics such as erythrocin, achromycin, etc , given by mouth are to be preferred Antihistaminics are of no value in the treatment of chronic asthma and should be avoided

ACTH Cortisone, Metacortin (Prednisone®) and Metacortelone (Prednisolone®) Treatment with ACTH cortisone hydrocortisone and metacortin or metacortelone are indicated in the treatment of chronic intractable bronchial asthma and status asthmaticus when other therapeutic measures have failed These hormones should not be used in cases complicated by tuberculosis chronic nephritis, peptic ulcer,

intramuscularly depending upon the condition of the patient As the symptoms subside the dosage may be gradually reduced to 50 mg , then to 25 mg per day and finally withdrawn altogether if the patient becomes symptom-free In children the dosage to be used is 25 to 75 per cent of the adult dosage

Asthma may be controlled as long as these hormones are administered Following their discontinuance some patients may be relieved for a varying number of months others only for several weeks or less These drugs may be repeated if necessary either orally or by injec-

tion Maintenance doses anywhere from 25 to 75 mg of cortisone per day have been successfully employed in some cases of protracted asthma for as long as two and three years The daily maintenance dose, determined empirically *in each individual*, should be as low as possible It must be borne in mind that even a small amount of cortisone continued over prolonged periods is not without danger and may lead to the development of Cushing's syndrome including osteoporosis To detect such complications it is advisable to x ray the spine from time to time and to determine the urinary calcium excretion periodically In patients in whom symptomatic osteoporosis develops Irwin et al[25] have found that administration of testosterone may give some relief to the back pain and reduce urinary calcium excretion

Hydrocortisone (free alcohol) may be employed in place of cortisone In some patients it may prove to be superior to cortisone The initial dose is usually 80 mg in four divided doses This is reduced as rapidly as possible to a maintenance dose of 40 to 60 mg and even as low as 10 mg per day

Metacortin or prednisone and metacortelone (prednisolone) are the most recent synthetic steroids They are approximately four times as potent as cortisone and hydrocortisone in suppressing inflammatory manifestations Since the administration of these hormones in moderate doses is not followed by sodium retention or edema they offer important advantages over the other steroids Favorable results in intractable asthma may be obtained with as little as 20 mg of metacortin per day in divided doses of 5 mg each The schedule followed by us is 4 or 5 tablets of metacortin (5 mg each) for the first three days after meals 4 to 3 tablets for the next three days then 3 to 2 tablets for three days followed by 1 to 1½ tablet per day for varying periods of time depending upon the condition of the individual If the patient becomes well the metacortin can be discontinued altogether If there is a flare up medication may be resumed or increased for a few days as the situation demands This steroid preparation is especially suitable in the treatment of intractable asthma with complications Two such cases complicated by diabetes and hypertension have been controlled by the writer with as little as 5 mg of metacortin per day according to the schedule outlined above The diabetes was controlled at the same time with

case of intractable asthma with pulmonary fibrosis and recurrent bouts of bronchopneumonia was adequately treated with 10 to 15 mg of metacortin daily The supplementary administration of erythrocin for three days every month prevented recurrences of bronchopneumonia This patient was allergic to penicillin achromycin as well as iodides He required 75 to 100 mg of cortisone per day to be comfortable before he changed to metacortin Previous injections of ACTH alone were followed by fever and bouts of bronchopneumonia

ACTH may be administered either intramuscularly or intravenously The latter should be used in emergencies or when the patient does not respond to the intramuscular route of injection Its main advantage lies in economy of material Its disadvantage is that the patient must be hospitalized and might develop allergic reactions to the hormone as such

For intravenous administration the ACTH powder is dissolved in 1 000 cc of 5 per cent glucose in distilled water and given by a slow continuous intravenous drip for periods varying from eight to twelve hours The initial dose usually employed is 20 mg daily for three days This is gradually diminished to 15 10 and 5 mg during a period of six to ten days Patients receiving these hormones must be placed on a low sodium diet and given supplemental potassium 1 to 2 gm daily in divided doses either in the form of potassium iodide or chloride In addition large doses of vitamin C should be given to replace that which is lost in the urine during intravenous administration of ACTH The intramuscular dose of ACTH consists of 10 to 12 5 units every six hours to a total dosage of 40 to 50 mg for twenty four hours for a few days until the symptoms are under control If necessary 15 or 20 units per dose may be employed Thereafter the total amount may be reduced every day or every other day by 5 units to a maintenance dose of 10 to 30 mg in twenty four hours Recently this method of treatment has been supplanted by the use of a highly purified corticotropin in gelatin HP acthar gel® This is available in 5 cc vials containing 20 40 and 80 units per cc It has been used by Gay[26] in the treatment of intractable asthma in patients from the ages of three to eighty As a rule the initial dose on the

first day ■ 60 to 100 units depending upon the severity of the symptoms, 60 to 80 units the second and third days, and 20 to 60 units on the fourth and subsequent two or three days depending upon the individual response Treatment is usually carried on for five to seven days In the majority of cases this is followed by a drop in eosinophils after the first or second dose Thereafter the counts fluctuate and may occasionally be higher than at the beginning Once the patient ■ controlled, HP acthar gel may be maintained on a weekly or biweekly basis in doses of 40 to 80 units or by the substitution of oral cortisone or hydrocortone In twenty-six patients with intractable asthma sixty to eighty years of age who were treated with HP acthar gel, remarkable relief and well being were attained in spite of the presence of numerous complications such as hypertension, diabetes, coronary occlusion, chronic sinusitis and marked emphysema In no instance was the complication aggravated It was believed that the relief of dyspnea prolonged rather than shortened the life of the patient

In the treatment of asthma and cough associated with pulmonary eosinophilia ACTH, HP acthar gel and cortisone are most effective If not tolerated these hormones may be substituted, according to Mark,[21] by transfusions of 500 cc of whole blood for three successive days This may be repeated every six to eight months to prevent recurrences ACTH and cortisone are also most valuable in the therapy of the more generalized forms of vascular allergy during the reversible stages Here they should be used as promptly as possible in the aforementioned amounts Once vascular allergy has become generalized, particularly in cases which go on to periarteritis nodosa, where the lesions especially in the heart and kidneys have become irreversible, no amount of cortisone or ACTH will be of any avail even if given early in the disease In the administration of these hormones the usual precautions in respect to the electrolyte balance should be observed When edema develops, the hormones should be reduced or discontinued for a while Mercurial diuretics should be employed to eliminate the accumulated fluid

STATUS ASTHMATICUS

At any stage in this clinical course the patient may suddenly go into status asthmaticus consequent upon some prolonged allergenic stimulation or perhaps a severe emotional strain The bronchi become occluded by tenacious fibrinopurulent material which the patient is unable to expel Because of the stress associated with continuous dyspnea and cough he becomes exhausted Anoxemia supervenes and the patient may become asphyxiated unless prompt measures are instituted, such as aspiration of mouth

In cases of status asthmaticus in which ACTH or cortisone is contraindicated, sedation with chloral hydrate and intravenous administration of aminophylline 0 5 gm dissolved in 1,000 cc of 5 per cent glucose to which 1,000 mg of ascorbic acid can be added, may be given at the rate of 30 drops per minute This may be repeated a number of days for a week or more if necessary When the patient is improved, the amount of aminophylline can be reduced In patients who have not responded to aminophylline some workers have given ethyl alcohol intravenously This is available commercially in 5 per cent strength in glucose-saline It can be prepared from 95 per cent ethyl alcohol which should be Seitz filtered so as to eliminate mold spores The amount employed depends upon the patient's history Those who are habitual drinkers as well as portly individuals may require 75 to 125 ml The majority of patients can be successfully treated with 1 L of the 5 per cent alcohol solution by drip at the rate of 80 to 120 drops per minute Under this regimen the patient usually develops a pink flush or mild excitement followed by relief of the wheezing respiration When he falls asleep, the flow may be reduced to 60 or 80 drops per minute This may be repeated if effective

Dehydration often present in patients with status asthmaticus should be treated by parenteral replenishment of fluids Those who manifest dehydration with salt depletion may require large doses of isotonic saline (0 9 per cent solution) In place of the latter Ringer's, Hartmann's or Fisher's solutions may be substituted Hypopotassemia occasionally seen in older diabetic or nephritic individuals in status asthmaticus should be treated with potassium chloride 2 gm or potassium citrate 3 gm every three hours for six doses When possible, foods with high potassium content such as chicken

broth, oatmeal or orange juice may be used instead

Acidosis masked by severe asthma may supervene in patients who because of their respiratory difficulty have been unable to eat or who have been vomiting This condition can be readily differentiated from acidosis of diabetic or renal origin by chemical analysis of the blood sugar and non-protein nitrogen When present, it should be treated by intravenous injections of sodium racemic lactate (10 ml of the concentrated sodium-r-lactate per kg of body weight), the standard solution being diluted with 5 times its volume of distilled water prior to administration If this is not available, the electrolyte balance may be restored by the intravenous injection of plasma or physiologic saline Amino acids combined with glucose and plasma for nitrogen balance may also be used intravenously in instances of coexisting hypoproteinemia

Alkalosis due to hyperventilation because of increased respiration accompanied by tetany and convulsions, although rare, may also be seen in patients in status asthmaticus To combat this condition intravenous dextrose combined with inhalation of oxygen with CO_2 up to 10 per cent, preferably by mask, may be employed Ammonium chloride may also be given either orally in 10 gm doses per day or 0 9 per cent solution intravenously until symptoms are controlled

In patients whose asthmatic state is complicated by signs of cardiac failure due either to cor pulmonale, hypertension, arteriosclerosis or otl [illegible] tion, [illegible] s the ti [illegible] t be differentiated from cardiac asthma as such, in which morphine, contraindicated in bronchial asthma associated with congestive heart failure, may be used in conjunction with aminophylline mercurial diuretics and oxygen

REFERENCES

1 SCHILLER, I W and LOWELL, F C Prolonged treatment of bronchial asthma with cortisone *J Allergy* 24 297, 1953
2 SCHWARTZ E Oral hydrocortisone therapy in bronchial asthma and hay fever, *J Allergy*, 25 112 1954
3 STEVENS, F and JORDAN L The treatment of infectional asthma in children with filtrates of upper respiratory pathogenic bacteria *J Pediat*, 4 307, 1939
4 COOKE, R and GROVE, R C. Relation of asthma to sinusitis *J A M A*, 56 779 1935
5 CHOBOT, R Asthma in children *Am J Dis Child.*, 45 25, 1933
6 GOTTLIEB, M J Relation of intranasal disease in production of bronchial asthma *J A M A* 85 105, 1925
7 KERN, R A and SCHENCK, H P Chronic paranasal sinus infection, relation to diseases of the lower respiratory tract *Arch Otolaryng* 18 425, 1933
8 GUERRANT, J L, McCAUSLAND A and SWINEFORD O Asthma with sinus disease *J Allergy* 21 187, 1950
9 HANSEN PRUSS, O C. Bacterial allergy and the importance of otolaryngological procedures *Laryngoscope* 59 540 1949
10 HANSEL, F K Nose and sinuses in allergy *J Allergy*, 1 43 1929
11 PINESS, G and MILLER, H Specific protein reactions in eye, ear, nose and throat *Ann Otol., Rhin & Laryng* 38 691, 1929
12 TUFT L Bronchial asthma *J Allergy* 17 27 1946
13 COOKE R Allergy in Theory and Practice Philadelphia, 1947 W B Saunders Co
14 STEVENS F A Personal communication
15 HARKAVY, J Vascular allergy *Arch Int Med.*, 67 709 1941
16 HARKAVY, J Vascular allergy III *J Allergy* 14 507, 1943
17 HARKAVY J Cardiovascular allergy due to penicillin sulfadiazine and bacterial sensitization *J Allergy*, 23 104 1952
18 LOEFFLER, W (a) Zur differential Diagnoses der [illegible] Succedan [illegible] 66 1069 1936
19 CHURG J and STRAUSS, L Allergic granulomatosis, allergic angiitis and periarteritis nodosa *Am J Path* 27 277 1951
20 ZEEK P M SMITH C C and WEETER J C. Studies on periarteritis nodosa III The differentiation between vascular lesions in periarteritis nodosa and hypersensitivity *Am J Path* 24 889 1948
21 GOLDMAN J L *Bacteriologic and rhinologic* diagnosis and treatment improved criteria *Laryngoscope*, 63 406, 1952
22 GROVE R D Hyperplastic sinusitis in asthma In Allergy in Theory and Practice Philadelphia, 1947 W B Saunders Co
23 WEILLE, F L Studies in asthma *J A M A* 100 241, 1933
24 GAY, L N The Diagnosis and Treatment of Bronchial Asthma Baltimore 1946 William & Wilkins Co
25 IRWIN, J W, HENNEMAN, P H, WANG D M K and BURRAGE W S Maintenance cortisone in intractable asthma *J Allergy* 25 201–209 1954
26 GAY L N and MURGATROYD G W JR Treatment of the ambulatory asthmatic patient with corticotropin purified in gelatin *J Michigan M Soc*, 53 33 47, 1954
27 MARK, L Treatment of Loeffler s syndrome *Dis of Chest* 25 128 1954

XII. PULMONARY MANIFESTATIONS OF SYSTEMIC DISEASES

31

Blood Dyscrasias and Metabolic Disorders

RICHARD R. FERAYORNI, M.D., *New York, New York*

From the Medical Service of Columbus Hospital, New York, New York

THE lungs are frequently involved in a number of diseases which are primarily systemic. Clinically speaking, in dealing with these diseases the attention of the physician may be drawn to the lungs because of the presence of a minimal or a distressing symptom or abnormal x-ray finding. Thus it is important that the clinician be cognizant of diseases in which the lungs are involved as a part of a generalized process. At times the pulmonary component may be the sole presenting manifestation of the illness. Other times the pulmonary component may be obscure or absent. Some of these systemic diseases are infrequent and others are rare. The diagnosis of these conditions may prove difficult and may require not only an awareness on the part of the physician of the condition, but also the utilization of many laboratory tests and specialized procedures.

BLOOD DYSCRASIAS

Pulmonary changes of clinical importance may occur in certain diseases of the blood. The conditions are: the leukemias, polycythemia vera, plasmacytoma, multiple myeloma, pulmonary hemosiderosis and sickle cell anemia.

Acute Lymphatic Leukemia. In this disease pulmonary infarction and venous thrombosis are common findings. Many of these patients present themselves early in the course of the disease with ulcerative lesions of the mouth [illegible]

with characteristic shadows.

Chronic Lymphatic Leukemia. The mediastinal lymph nodes are often enlarged during the course of chronic lymphatic leukemia. When they become of sufficient size to cause pressure on the neighboring structures, compression of the trachea or one of the large bronchi may occur. This may cause atelectasis or emphysema of the corresponding portion of the lung. Pleural effusion or a superior vena caval syndrome may be brought on by obstruction of the large thoracic veins or lymphatic channels.

Parenchymal infiltration of the lung is not uncommon. Falconer and Leonard in 1938 noted hilar node enlargement with invasion of the lung in approximately 42 per cent of their patients with lymphatic leukemia. Miliary nodulation with widespread infiltration was found in approximately 17 per cent and pleural effusion in 64 per cent of their cases.

The patients may complain of cough, pain and dyspnea. Pulmonary hemorrhage may occur but is more frequent in the acute forms which have greater degrees of thrombocytopenia. Bronchopneumonia and tuberculosis may supervene and increase the respiratory symptoms.

The diagnosis is made by the finding of increased numbers of immature lymphocytes in the peripheral blood or preferably in the bone marrow. X ray films of the chest may reveal enlarged hilar nodes with segmental or lobar infiltration, or widespread miliary nodules.

Myelogenous Leukemia. Most of the changes that occur in the lung in this disease are similar to those which take place in lymphatic leukemia. Pulmonary infiltration, mediastinal node enlargement, pleural effusion, atelectasis, bronchopneumonia and consolidation have occurred in some cases but not as frequently as in lymphatic leukemia.

This disease is diagnosed by the presence of large numbers of immature myeloid cells in the bone marrow or in the peripheral blood.

The prognosis in all leukemias is poor

and all patients die eventually However, many types of treatments have been used with some success The most important of these have been Fowler's solution radiation, cortisone and ACTH, urethane, TEM (triethylene melamine), folic acid antagonists and 6-mercaptopurine

Polycythemia Vera This is a primary neoplastic process involving the erythroblastic portion of the bone marrow Often there is associated leukemia Pulmonary hemorrhage may be a major presenting symptom The pulmonary lesions may be found on x ray in transitory or permanent form These x ray changes are most likely due to perivascular hemorrhage after thrombosis of a branch of a pulmonary vein with stasis infarction and with consequent diapedesis of blood or rupture of the vein If replaced by fibrous tissue a spherical shadow will appear on x ray

Numerous methods of therapy have been employed in this disease namely radioactive phosphorus nitrogen mustard x ray, phlebotomy and triethylene melamine The most effective agent at the present time is radioactive phosphorus

Plasmacytoma This is a neoplasm of the plasma cell variety involving the bone marrow Occasionally an extramedullary site is encountered of which the upper respiratory passages and pleura may be involved A few cases have involved the lung and mediastinum The x ray findings are similar to those of any other tumor of the lung It is characterized by anemia and an increase in the white blood cell count The plasma cells are predominant

Multiple Myeloma Recurrent pneumonia has been observed frequently in patients with multiple myeloma In 1954 Zimmerman and Hall found ten patients in a group of sixty four cases of multiple myeloma who had a total of forty four recurrent episodes of pneumonia The authors observations of the immunologic response of these patients revealed that there was a profound reduction of immunologically active serum globulins Their reactions were similar to those of patients with agammaglobulinemia In 1954 Lawson et al studied nine patients with multiple myeloma and found a definite reduction in circulating antibodies with an increased susceptibility to pneumonia In cases of spontaneous fractures of the rib commonly observed in this disease, restriction of thoracic movements leads to the development of atelectasis pneumonitis and emphysema

Pulmonary Hemosiderosis Pulmonary hemosiderosis may occur as a complication of mitral stenosis or it may occur as an idiopathic disease The latter occurs mostly in children under the age of sixteen It was first reported by Ceelen (1930) Wyllie (1948) later collected seventeen cases from the literature and added seven of his own

The symptoms consist of recurrent attacks of pallor, fatigue, cyanosis and dyspnea Cough associated with vomiting and hemoptysis is frequent The attacks may last from two to several days and may include severe abdominal pain and jaundice in the more acute cases The clinical picture may be that of hemolytic anemia with congestive heart failure due to pulmonary circulatory disturbance X rays of the chest show a diffuse fine mottling throughout both lung fields but most dense at the hilar regions

At autopsy the lungs appear full and firm dark reddish brown in color, with punctate hemorrhages on the pleura There is enlargement of the bronchopulmonary and tracheobronchial lymph nodes The right heart is usually hypertrophied

Microscopically, the alveoli are filled with hemosiderin laden phagocytes Hemosiderin granules are found in the alveolar cells the interstitial tissues and the lymph nodes The cause and the treatment of this condition are unknown and the prognosis is generally poor

In hemosiderosis due to mitral stenosis the source of the irritant iron is a focal accumulation whereas in idiopathic hemosiderosis the hemorrhage is widespread throughout the lungs

X rays of the lungs in mitral stenosis with hemosiderosis show the characteristic cardiac silhouette In addition the fine nodular opacities are most numerous in the mid zones and most dense at the hilar areas The periphery and the apexes of the lungs may be clear Treatment is directed toward the correction of the cardiac lesion/

Sickle Cell Anemia This disease occurs almost exclusively in Negroes Often infections of the respiratory tract develop frequently precipitating crises and causing death Rubin emphasizes that the changes in the lungs are characterized by capillary stasis a tendency toward thrombus formation and infarction

These patients rarely present normal findings on x ray of the chest Patchy infiltrations striations and nodular densities may be seen on the chest roentgenogram Rubin also stresses the frequent occurrence of pulmonary tuberculosis in this disease

METABOLIC DISORDERS

The lungs may be affected in diseases of metabolism either by direct invasion or indirectly by the creation of conditions which favor infection As a result in certain instances symptoms referable to the bronchopulmonary tree may be prominent and overshadow the primary disease In other cases the pulmonary manifestations are those of secondary infection

Fibrocystic Disease of the Pancreas This condition is seen in infants and young children The pancreas is found to be reduced in size due to a contracting interstitial fibrosis The disease is progressive and is due to constitutional factors as shown by the fact that when aberrant pancreatic tissue is found the same changes are noted in it The pancreatic secretions are diminished causing poor digestion and malnutrition Vitamin A deficiency associated with the disease causes marked changes in the respiratory mucosa These changes invariably lead to bronchitis bronchopneumonia bronchiectasis and pulmonary fibrosis Peripheral emphysema may occur due to bronchial obstruction with mucous plugs

The diagnosis is suggested on x ray of the chest by the finding of bilateral usually symmetric irregular mottled infiltrations in the form of light densities localized predominantly in the hilar areas These extend fan like from the hilar area toward the mid lung field and as a rule the periphery is clear Small areas of atelectasis may be seen and emphysema is often found in the periphery of the lung In the later stages fibrosis and exaggerated bronchovascular markings in the bases suggest bronchiectasis

Treatment is directed toward the pancreatic insufficiency and pulmonary infection The prognosis is poor

Diabetes Mellitus Occasionally an old healed tuberculosis may become active during the course of diabetes mellitus because of the lowered resistance resulting from the primary disease However with the present newer chemotherapeutic agents the tuberculosis as well as the other bacterial infections affecting the pulmonary tissues can be adequately controlled

Diabetes Insipidus The pulmonary manifestations of diabetes insipidus are usually secondary to the underlying cause The series of cases of diabetes insipidus associated with pulmonary disease collected by Spillane in 1952 were found to be due to the following causes (1) sarcoidosis (2) tuberculosis (3) xanthomatosis (4) syphilis (5) tuberous sclerosis and (6) bronchogenic carcinoma

Addison's Disease There are two major causes of this condition tuberculosis of the adrenal gland and an idiopathic process with bilateral adrenal cortical atrophy In the former type x ray examination of the lung may reveal old tuberculous lesions Occasionally these lesions may become activated as a result of steroid therapy It is therefore important to follow the pulmonary lesion closely by repeated x ray examinations

Metastatic Calcification of the Lungs Metastatic calcification of the lungs is caused by renal rickets (renal dwarfism) The pathologic process is characterized by renal insufficiency with associated azotemia hyperphosphatemia and hypocalcemia Growth in these cases is stunted The pulmonary manifestations consist of deposits of calcium either in a miliary or a nodular form with concomitant calcification of the pulmonary vessels Pulmonary hemorrhage is a common complication and this is due to the low blood calcium content and the existing hypertension The treatment has formerly been palliative and the prognosis poor but the newer chelating agents offer promising results

The Xanthomatoses The xanthomatoses which are rare may involve the lungs Gaucher's disease rarely affects the lungs Niemann Pick's disease may involve the lungs in the general process of congestion and edema In this disease the alveoli may contain many characteristic large pale cells

There are three other varieties of xanthomatous diseases which are closely related and

is an acute leukemic reticulosis which attacks infants almost exclusively This disease runs a febrile course for a few weeks and the liver spleen and lymph glands are enlarged It is

diagnosed by the detection of the large, pale, non lipoid-containing mononuclear cells It invariably terminates fatally (2) Hand Schuller Christian disease, with its triad of exophthalmos, diabetes insipidus and erosions of the skull, tends to develop in early childhood Here the mononuclear cells invading the tissues contain cholesterol (3) Eosinophilic granuloma occurs at any age and is usually diagnosed by finding cysts in the long bones The cysts are filled with eosinophils

The characteristic picture in the late stage of these diseases is the formation of multiple cysts producing the "honeycomb lung" The degeneration of the granuloma containing the pale staining lipoid cells leads to the formation of the cysts Rupture of a cyst may produce pneumothorax Bronchitis and bronchopneumonia occur frequently At times the xanthoma ceases to progress but the "honeycomb lungs" may persist for many years

Tuberous Sclerosis Tuberous sclerosis is a familial disease of children who manifest mental deficiency epilepsy and adenoma sebaceum of the face Death can be anticipated in several years usually before the patient reaches middle life Myomas of the heart and kidneys and subungual fibromas and tumors of the retina have also been found in these cases Occasional patients have been reported to have pulmonary lesions A small group of females with a family history of tuberous sclerosis has been found On x-ray of these patients' lungs a typical "honeycomb" appearance was found They also were found to have infiltrations which pathologically proved to be leiomyomatous, however, these patients did not have mental deficiency or epilepsy

Primary Amyloidosis This disease is much less frequently encountered than secondary amyloidosis The characteristic features of primary amyloidosis are the absence of chronic disease and the appearance of amyloid in organs not usually involved in secondary amyloidosis notably the heart, lungs and skin The absence of amyloid in the organs such as the liver spleen, kidneys and suprarenal glands and the failure of primary amyloid tissue to turn blue with iodine strongly suggest that this disease may be of different origin Sappington et al in 1942 collected fifty four cases of primary amyloidosis proved by necropsy Pulmonary involvement was present in twenty-four of these cases X rays of the lungs revealed an enlargement of the hilar nodes and an accentuation of the linear markings with or without a ground glass appearance of the lung fields In some instances there were widely distributed nodular densities throughout the parenchyma of the lungs The diagnosis is made by the elimination of other diseases which have similar findings, biopsy of lung tissue and the Congo red test The latter test is negative in one-half of the cases This disease has a poor prognosis

CONCLUSION

Systemic diseases may be associated with pulmonary manifestations When the lung manifestations of these conditions are known a physician on occasion will be given a clue as to the presence of the constitutional disorder Thus the disease process can be detected earlier

been discussed

REFERENCES

of 100 cases

RUBIN E H Pulmonary manifestations of systemic diseases *Am J Surg* 90 50 1955

SAPPINGTON S W DAVIS J H and HORNEFF J A Primary amyloidosis of the lungs *J Lab Clin Med* 27 882 1942

SPILLANE J D Four cases of diabetes insipidus and pulmonary disease *Thorax* 7 134 1952

VON MEYENBURG H Eosinophil pulmonary in- *Schweiz med*

and BARRON *J Med* 17

26 1948

of virus

49

on

the immunologic response *Ann*

1152 1954

32

Collagen Diseases

L H Garland M D and M A Sisson, M D, *San Francisco California*

From the Department of Radiology Stanford University Medical School Service San Francisco Hospital San Francisco California

The respiratory and cardiovascular systems are commonly involved in the so-called collagen diseases This chapter will outline the more conspicuous pleuropulmonary changes and the associated pericardiovascular changes which are encountered in this group of disorders

The collagen diseases are a group of disorders characterized anatomically by generalized alterations of the connective tissue especially of its extracellular components The currently accepted members of this group are periarteritis nodosa, disseminated lupus erythematosus dermatomyositis scleroderma rheumatic fever and rheumatoid arthritis

The term polyarteritis is synonymous with periarteritis nodosa Because of the predominance of vascular changes this disorder (and to a lesser extent, generalized lupus erythematosus) may also be referred to as visceral angiitis Disseminated lupus erythematosus is also known as acute lupus erythematosus or generalized lupus erythematosus

Becker[3] and others believe that the systemic manifestations of Schönlein Henoch purpura erythema nodosum and certain cases of glomerulonephritis include similar involvement of connective tissue and may belong to this group of diseases Ehrich and associates[8] on the basis of animal experiments, would also include serum sickness Kampmeier[10] has suggested that the necrotic changes found in afferent renal arteries in both malignant hypertension and periarteritis nodosa have more than coincidental relationship Stewart[22] believes that thromboangiitis obliterans and ulcerative colitis are also collagen diseases

ETIOLOGY AND PATHOLOGY

The etiology of the collagen diseases is not known Several workers have produced fibrinoid changes of connective tissue experimentally by mechanical and by chemical means[5] These observations tend to invalidate the supposition that hypersensitivity is the sole cause of collagenous degeneration Indeed it has been observed that undue significance should not be attached to the occurrence of fibrinoid changes in localized connective tissue collagen Pathologically, this [illegible] merely a form of degeneration unspecified in etiology, and occurring in a wide variety of dissimilar diseases This fact, of course greatly minimizes the clinical usefulness of the term collagen [illegible]

microscopic findings do not consist merely of changes in the collagen fibers alone but of changes in the connective tissue elements as a whole

Histologically, connective tissue consists of cellular elements and extracellular substances The cellular elements consist of fibrocytes and fibroblasts, macrophages lymphoid cells, mast cells and various other leukocytes The extracellular substances are composed of an amorphous ground substance and three known types of fibers namely collagenous reticular and elastic The basic lesion in the collagen diseases consists of a swelling of the interfibrillary ground substance as well as swelling of the fibers themselves The location of these basic lesions and the type of response of the adjacent tissues are somewhat different in the different collagen diseases, and constitute the anatomic basis by which they may be at least partly distinguished

Abnormal collagen may be detected by suitable x ray diffraction studies and electron microscopy Kellgren believes that this will prove a useful method for diagnosing connective disorders

Not all clinical subdivisions of the collagen diseases are clearly demarcated In some patients, at necropsy, lesions peculiar to or predominant in some of the different entities may be found in one and the same patient For example, a fatal case may show (1) chronic skin lesions, as in scleroderma, (2) erythematosus, (4) non bacterial verrucous endocarditis,* (5) infiltration and dilatation of arterioles as in periarteritis nodosa, (6) pericardial changes, as in rheumatic infection, and (7) articular and tenosynovial changes, as in rheumatoid arthritis

A case embodying all these diverse manifestations was recorded by Kampmeier [16]

Miale[21] mentions that Krupp first emphasized a characteristic urinary finding in "visceral angiitis", he found the pattern in fourteen of twenty one cases of periarteritis nodosa and disseminated lupus erythematosus It consists of the simultaneous presence of elements usually characteristic of the early stages of nephritis (erythrocytes and erythrocytic casts), and elements usually seen in the chronic stage (broad casts, waxy casts, fatty casts and "oval fat bodies") This finding has been referred to as a "telescopic urinary sediment"

CLINICAL TYPES AND SOURCE OF MATERIAL

The types of collagen disease to be discussed in the following pages include periarteritis *nodosa, generalized lupus erythematosis,* dermatomyositis and scleroderma Space will permit only brief mention of the two more common entities, rheumatic fever and rheumatoid arthritis

The cases studied were obtained by a review of the files in the roentgen departments and the record rooms at San Francisco Hospital and Stanford University Hospital The period covered is approximately fifteen years, a majority of the cases having been indexed in the last ten years

PERIARTERITIS NODOSA (POLYARTERITIS)

Periarteritis nodosa is frequently and more correctly called polyarteritis as there is actually a widespread poly- *rather than periarteritis,* affecting chiefly the medium sized and smaller arteries of the body Pathologically there is a degeneration of the collagenous tissue in the walls of the vessels, sometimes with necrosis of the media, rupture of the elastic lamina and infiltration of inflammatory cells and eosinophils into all of the vascular layers When this infiltration of the arterial coats is localized, or is followed by local fibrosis, or the development of small aneurysmal dilatations, nodular changes develop (giving rise to the term nodosa)

Clinically the signs and symptoms are determined more by the distribution of the involved arteries than by the disease process itself Almost any clinical condition may be mimicked However, a polysystemic involvement with chronic fever, leukocytosis, eosinophilia and secondary anemia suggests the condition, and is an indication for skin and muscle biopsy Recurrent hemoptysis has been reported by to be involved, and also on the acuteness and degree of that involvement Cardiac enlargement and/or pericardial effusion occurs The respiratory system may show massive symmetric or non symmetric edema in severe acute cases In others, small hazy shadows or non-confluent patches of edema (pulmonary hives) may be scattered throughout the lung fields, usually peripherally and at the bases [1] Some authors[9,18] report cases in which the nodulation is most marked centrally In addition to the nodular densities, the pulmonary linear markings may be accentuated, particularly the hilar and basal ones Doub et al[4] *report hilar enlargement* as a conspicuous finding in a series of ten microscopically proven cases Pleural effusion, secondary to pneumonitis or pulmonary infarction, is reportedly not uncommon

Roentgen examination of the abdomen is frequently requested since abdominal pain is one of the most common early symptoms A triad of myositis, abdominal pain and weight loss has been referred to by some The abdominal films usually show either no abnormality, or some gas collections suggesting paralytic obstruction (so-called adynamic ileus) Very rarely, there may be a perforated ulcer, intestinal infarction or pancreatic necrosis One of our cases had both intraperitoneal and retro-

* Non bacterial verrucous endocarditis, as in Libman Sacks syndrome, is now known to be part of the changes occurring in disseminated lupus erythematosus

peritoneal bleeding due to ruptured aneurysm of a small mesenteric vessel, secondary to "healed" arteritis A hypertension of 200/140 was present, this patient also had multiple duodenal ulcers

TABLE 1

CHEST ROENTGEN FINDINGS IN THIRTY-ONE CASES OF PERIARTERITIS

No evidence of disease	9
Evidence of disease	22
Cardiac enlargement	6
Pericardial effusion	6
Pleural effusion	7
Pulmonary changes	16
Parenchymal nodules, patches etc	6
Pulmonary congestion passive	6
Accentuated markings ? arteritis	4
Pulmonary edema massive	4

Note Some of the cases with ' cardiac enlargement may also have had some pericardial effusion

Renal lesions are the most common of all the systemic lesions, being present in 80 per cent of the cases ¹⁸ Occasionally hypertension or hematuria may be so prominent that intravenous urograms are requested These usually show either normal or decreased function

The records of thirty-two cases of periarteritis nodosa were reviewed In thirty one of these, chest films were available and disclosed the findings shown in Table 1 It is to be noted that some cases had more than one finding (e g , pericardial, pleural and pulmonary lesions)

At autopsy one of our patients had both polyarteritis and rheumatic heart disease (mitral and aortic stenosis with insufficiency) His roentgenograms showed an enlarged heart, pulmonary congestion and pleural effusion

None of the foregoing roentgen findings are diagnostic *per se* of periarteritis nodosa, but the presence of pulmonary, pleural or cardiopericardial changes in a patient with involvement of other systems, should cause one to bear the possibility of a collagen disease in mind

In the entire thirty two cases adequate roentgenologic records of systems other than the cardiorespiratory were limited In two cases hepatomegaly and in two cases splenomegaly were noted by our department One case showed roentgen evidence of mild paralytic ileus Three cases showed peptic ulcer (one gastric and two duodenal) No cases of gross renal enlargement were recorded, but one did show poor function by excretory urography No bone changes were noted, three patients showed roentgen evidence of articular disease (two synovial thickening, one rheumatoid arthritis) Biopsy or necropsy material compatible with the diagnosis of periarteritis nodosa was available in twenty of the thirty-two cases In seven cases biopsy reports were negative but the clinical evidence was outstanding, two of these patients died apparently of the disease *

The following are some illustrative cases

Case E M (Fig 1), a white female, aged twenty six, had migratory joint pains, low-grade fever, myalgia and patchy gangrene of some of the fingers and toes She was known to have had periarteritis nodosa for two years On April 29, 1950, a roentgenographic examination of the chest was negative Re-examination in two and one-half weeks showed small bilateral pleural effusions and a pericardial effusion One month later, after cortisone therapy, clinical and roentgenographic improvement was present This case showed acute development of pleural and pericardial lesions during the course of a chronic multiple system disease Biopsy of skin and muscle positive for periarteritis nodosa

Case R S (Fig 2) a sixty-three year old man, had fainting spells of unknown origin for a few weeks, and pain and stiffness of the shoulders and knees since a fall one month prior to entry Initial chest roentgenograms showed only slight left ventricular enlargement Two days later, films showed bilateral pleural effusion and pulmonary congestion Clinically he had become acutely ill, with high fever (up to 103 1°F), but without evidence of cardiac failure Roentgen examination four weeks later showed clearing of the congestion and effusions, despite the fact that the patient was failing generally The urine then showed abnormal findings, the so-called telescopic sediment, and the possibility of "visceral angiitis" became entertained He recovered

* Most of the histopathologic studies referred to in connection with the cases reported in this paper were made by members of the Stanford University Medical School Department of Pathology staff in a few instances material was reported by the University of California staff at the San Francisco Hospital, to whom we are indebted

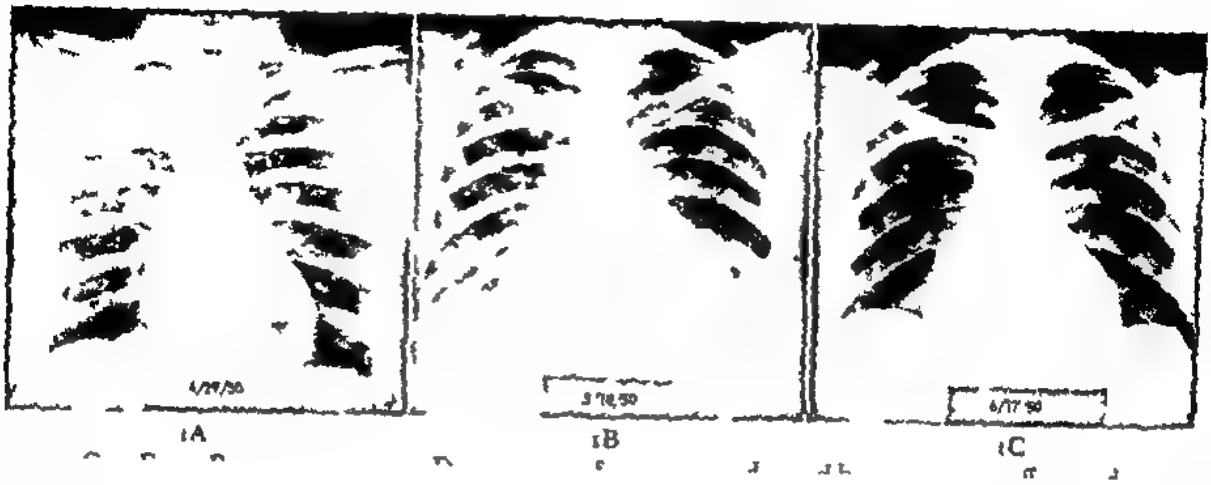

J Roentgenol)

F G 2 Case R S Per arter t s nodosa Rap d development af per cardial and b lateral pleural effus ons Negro lungs clear patient now

partially and was discharged Biopsy of skin and muscle was reported negative

Case L E L (Fig 3) a white female aged thirty four had asthma for one year and numbness of the left leg and pain in the left foot for six months She was found to have splenomegaly eosinophilia and a renal lesion with casts and cells Chest films showed pul monary nodulation fibrosis and emphysema Biopsy of skin and muscle was negative Marked clinical and roentgenologic improve-

aged forty five entered on August 12 1948 with chills fever (101°F) mild cough chest pain and dyspnea He had had a dermatitis of his leg for two years with local ulceration Pain in the right upper abdominal quadrant a markedly enlarged liver and massive hema turia were present He had a hypertension of 180/80 his blood urea was 27 mg per cent s normal Roent

as pulmonary edema moderate splenomegaly was noted on abdominal film Nine days after entry the patient was clinically and roent genologically improved Biopsy was not per formed A year later his chest film continued to be negative

Case G H B a white male aged forty was clinically diagnosed as having rheumato d arthritis Roentgenograms showed cardiomeg

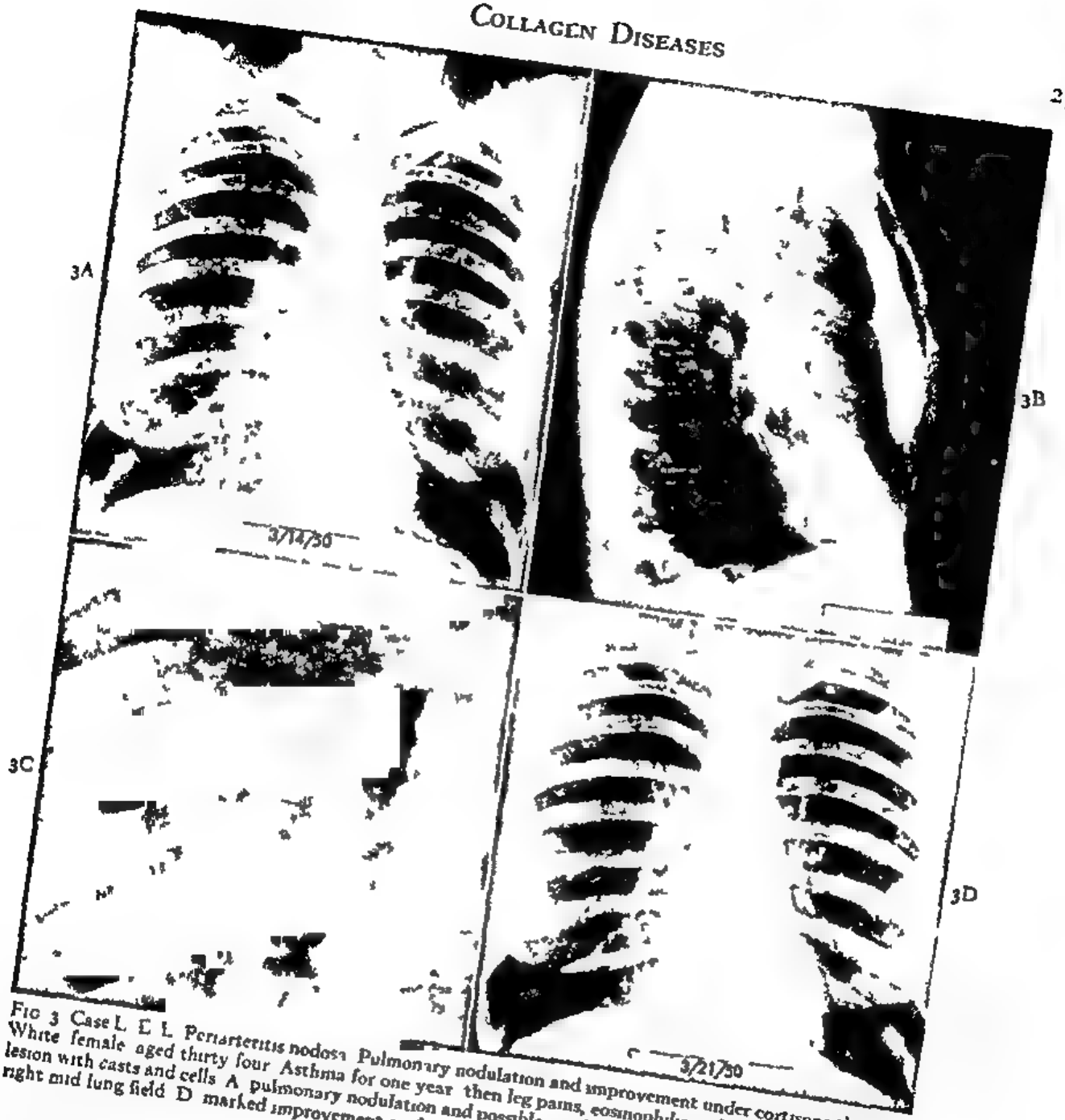

FIG 3 Case L. E L Periarteritis nodosa Pulmonary nodulation and improvement under cortisone therapy White female aged thirty four Asthma for one year then leg pains, eosinophilia splenomegaly and renal lesion with casts and cells A pulmonary nodulation and possible emphysema B lateral view C, close up of right mid lung field D marked improvement on fourth day of cortisone therapy

aly, predominantly left ventricular, and bilateral pleural effusion The patient died shortly after examination apparently from cardiac failure Autopsy showed (1) diffuse collagen disease with polyserositis (peritoneal pleural and pericardial fluid), rheumatic heart disease (aortic valve stenosis), wire-looping of renal glomeruli (as in lupus erythematosus) rheumatoid arthritis periarteritis nodosa (of pulmonary, thyroid and testicular arteries), (2) pulmonary emphysema (and fibrosis), (3) generalized arteriosclerosis (coronary, aortic and renal)

This case illustrated a combination of four types of "collagen" disease—periarteritis nodosa, lupus erythematosus, rheumatoid arthritis and rheumatic carditis

Case I S (Fig 5), a female singer, age thirty one, was hospitalized for mental disturbance She stated that she had had severe asthma for

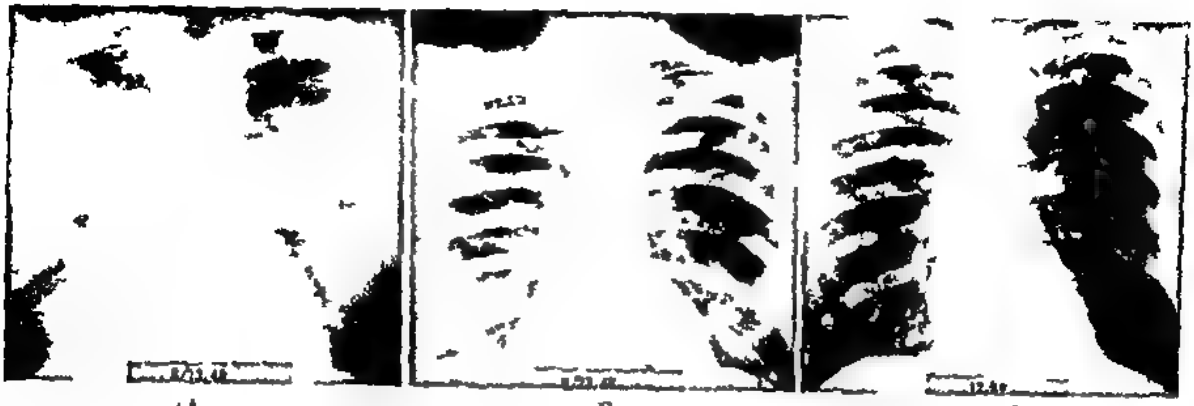

4A 4B 4C

sixteen months with muscle and joint aches abdominal pain and nervousness She was found to have splinter hemorrhages of the finger nail beds conjunctival petechiae a grade II pulmonic systolic murmur rales at the lung bases splenic and hepatic enlargement and a temperature spiking to 103°F The white blood count was 21 000 with 30 per cent eosinophils the urine contained albumin granular and hyaline casts and a few red and white blood cells Chest x rays showed a pulmonary edema pattern with a small area of left upper lobe consolidation six days later there was extensive bat wing edema with small nodules in the right costophrenic area there was also a small pleural and a pericardial effusion Biopsy of calf muscle was reported perivascular inflammation and of skin as chronic dermatitis Cortisone resulted in excellent subjective response Fever stopped strength improved but the splenomegaly and hepatomegaly persisted She was discharged as improved

DISSEMINATED LUPUS ERYTHEMATOSUS

Disseminated lupus erythematosus or systemic lupus erythematosus is a disease most commonly seen in women and in the ages of twenty to forty It is characterized by a cutaneous eruption most often in the form of discoid lesions—with a butterfly distribution over the nose and cheeks—along with varying degrees of visceral manifestation notably in kidneys heart spleen and lungs The skin lesion is frequently photosensitive being made worse by sunlight or ultraviolet light or such light sensitizing drugs as the sulfonamides Patients may show fatigue arthralgia and fever The laboratory findings include leukopenia an elevated sedimentation rate a telescopic urinary sediment and the presence of so called lupus erythematosus cells [10] These lupus erythematosus cells found only in this disease are seen in various preparations of blood and bone marrow and are reportedly large leukocytes containing phagocytosed material resulting from lysis of the nuclei of other leukocytes

Pathologically there is predominant involvement of the smaller arteries and arterioles Polyserositis is common with pericardial lesions the most frequent In the heart itself lesions predominate in the valvular structures and the mural endocardium The kidneys when involved tend to be enlarged The glomerular vessels show the so-called wire-loop appearance due to eosinophilic thickening of the vascular loops within the glomeruli Occasionally the renal changes resemble those of glomerulonephritis or periarteritis nodosa The spleen shows microscopic involvement in at least half of the cases (periarterial fibrosis) The lymph nodes are said also to be frequently involved showing free hematoxylin staining bodies *

Roentgenologically findings may be noted in the urinary and respiratory tracts In the urinary tract when a case of hypertension

* Klemperer P et al Cytochemical changes of acute lupus erythematosus Arch Path 49 503 516 1950.

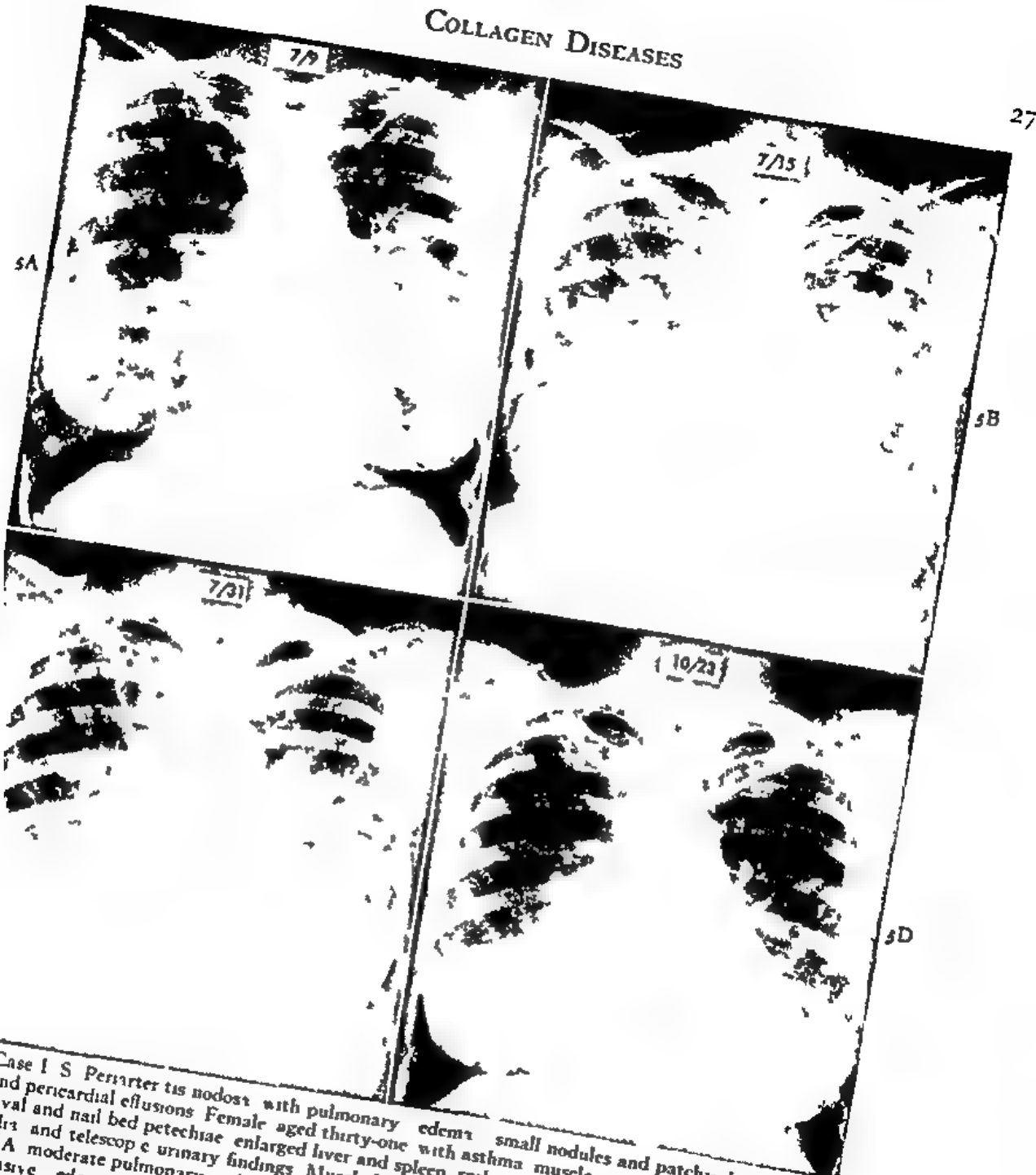

FIG 5 Case I S Periarteritis nodosa with pulmonary edema small nodules and patchy densities and pleural and pericardial effusions Female aged thirty-one with asthma muscle joint and abdominal pains, conjunctival and nail bed petechiae enlarged liver and spleen spiking fever leukocytosis with 30 per cent eosinophilia and telescopic urinary findings Muscle biopsy consistent with diagnosis Partial response to cortisone A moderate pulmonary edema with small area of consolidation in left upper lobe B six days later extensive edema small nodules in right costophrenic area and small right pleural and pericardial effusion C, sixteen days later after being on cortisone for about one week Lungs improved but pericardial effusion slightly increased D three months later residual prominence of pulmonary markings and increased pericardial effusion

shows unusually large kidneys the possibility of disseminated lupus erythematosus rather than a chronic glomerular nephritis must be considered Patients with the latter condition tend to have small or contracted kidneys

Pulmonary involvement is remarkable for its frequency and its atypical course Rakov and Taylor[24] and Foldes[11] describe a chronic interstitial pneumonitis which leads to atelectasis (due to interstitial edema and inflammation

resulting in obliteration of some alveoli)—termed atelectasizing pneumonitis These lesions are regarded as different from the ordinary pyogenic and fibrinous types of bronchopneumonia which so frequently complicate the terminal stages of lupus erythematosus

TABLE II
CHEST ROENTGEN FINDINGS IN THIRTY FIVE CASES OF DISSEMINATED LUPUS ERYTHEMATOSUS

No evidence of disease		12
Evidence of disease		23
Cardiac enlargement	5	
Pericardial effusion	5	
Pleural effusion	15	
Pulmonary changes (Accentuated markings nodules densities or edema)	11	

Thorell[10] reviewed the roentgenograms of fifteen cases of disseminated lupus erythematosus and found eight with pleural or pulmonary parenchymal changes, or both The pleural effusions were generally small, the pleural thickening more or less irregular These pleural changes varied in extent in relatively short periods of time The parenchymal changes consisted of small areas or patches of increased density, mostly subpleural, especially in early and moderately advanced cases (He used different oblique projections to bring out the subpleural location of the lesions) He believed that a combination of pleural and subpleural change ought to lead to the correct diagnosis even if the changes in themselves were not characteristic

In our experience pleural and pericardial effusions were the most common findings in this group The pulmonary parenchymal changes varied from localized accentuated markings, nodules and patches to extensive edema

We have reviewed the records of thirty eight cases, in thirty-five of which chest films were available (Table II)

In these cases the pulmonary changes consisted of accentuated basal bronchovascular markings in two instances, of nodular or patchy pulmonary densities (edema?) in seven instances, and of diffuse pulmonary density (edema) in two instances

As far as other anatomic sites are concerned, our roentgenologic findings are limited In one case hepatomegaly was reported, in two cases ascites was noted No gastrointestinal lesions were detected In one case slight osteoporosis of the hands was noted While many of our patients had clinical evidence of joint disorder, none were so reported roentgenologically (largely because examination was not regarded as necessary by the ward physician)

Biopsy or necropsy material compatible with the diagnosis of disseminated lupus erythematosus was available in twenty four of the thirty five cases In two cases biopsy reports were negative It is currently believed that search of the blood or bone marrow should replace biopsy, being an easier and more

e,
had a facial rash of butterfly shape, fever, joint pains for six months and generalized edema (nephrotic syndrome?) for four weeks Chest films showed a small amount of fluid in the costophrenic sulci This minimal bilateral effusion, without other roentgen evidence of chest disease, is one of the more suggestive findings of disseminated lupus erythematosus in patients with concomitant clinical findings Biopsy was not performed

Case T S (Fig 7), a thirteen year old boy, entered with high fever and weakness, splenomegaly and lymphadenopathy of two months' duration and a butterfly facial rash of one month's duration The initial chest film showed slightly accentuated pulmonary markings Three days later bedside films showed a bilateral pneumonitis, and six days later the patient died Autopsy showed a disseminated lupus erythematosus and also a bilateral atypical lobar pneumonia with features suggesting the anaphylactic pneumonia of Rich

n,
Chest roentgenograms showed a "water-bottle" shaped heart suggesting pericardial effusion (this was confirmed by roentgenoscopy), she also had minimal bilateral pleural effusions Examination eighteen days later showed a marked decrease in heart size, the pleural effusions were unchanged The clinical diagnosis was disseminated lupus erythematosus No biopsy was performed

Case R P W, a thirty six year old white man, gave a history of chorea at the age of twelve, and had developed a butterfly rash two and one-half years ago, then hematuria and fever, weakness and fatigue Ten months ago he

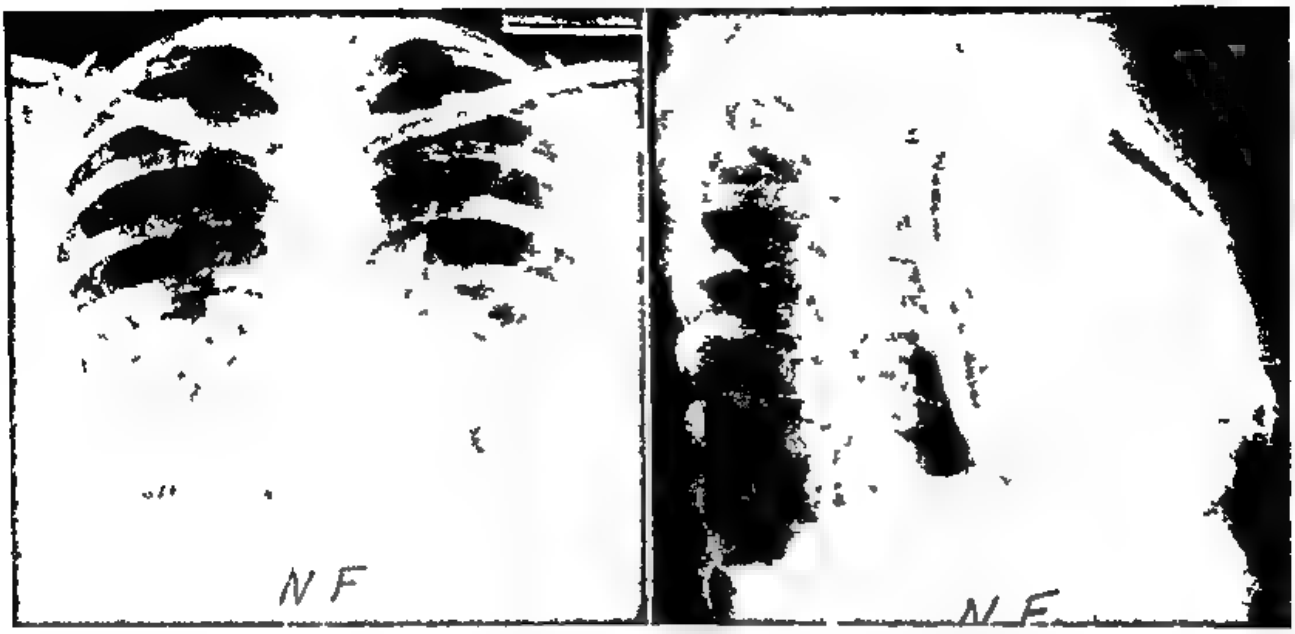

6A 6B

FIG 6 Case N F Disseminated lupus erythematosus with small bilateral pleural effusions White, female, aged nineteen, with facial rash, fever and joint pains for six months "Nephrotic syndrome" for four weeks A, bilateral pleural effusions B, right oblique view, fluid seen posteriorly Similar findings were present in left oblique view (Courtesy of *Am J Roentgenol*)

7A 7B

(Courtesy of *Am J Roentgenol*)

was hospitalized and a diagnosis of disseminated lupus erythematosus and aortic insufficiency was made The blood pressure was 170/96 Recently marked orthopnea and minimal edema developed The blood pressure varied from 160/90 to 200/110 Roentgenograms ten days before death showed cardiac

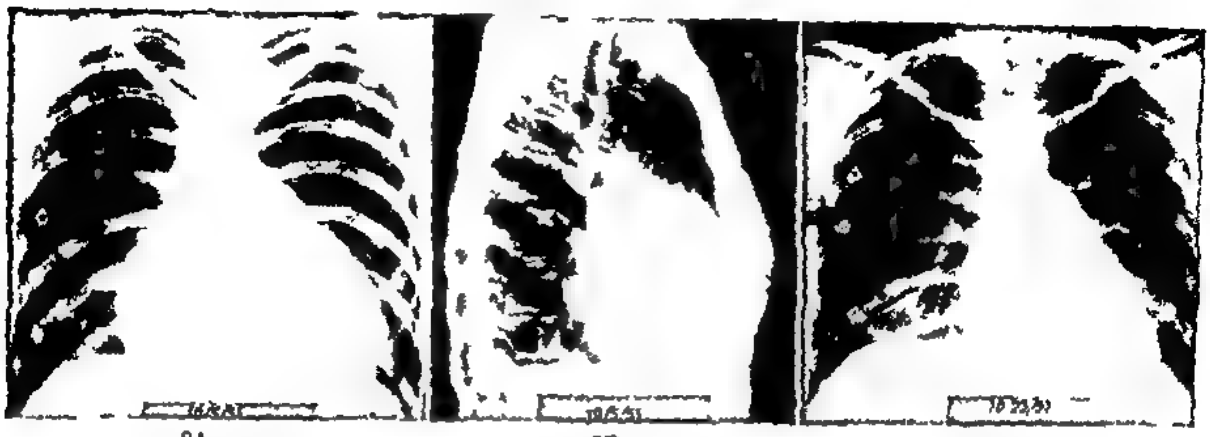

8A 8B 8C

FIG 8 Case F R Disseminated lupus erythematosus showing marked pericardial effusion and minimal pleural effusion White female aged fifteen Painful swollen joints and fever A "water bottle" heart due to pericardial effusion small bilateral pleural effusions B lateral view C, marked decrease of pericardial effusion minimal pleural effusions persist (Courtesy of *Am J Roentgenol*)

lupus erythematosus) and spleen lesions consistent with disseminated lupus erythematosus There was microscopic evidence of active rheumatic lesions This case again showed a combination of "collagen" diseases

DERMATOMYOSITIS

Dermatomyositis is the rarest of the collagen disease group and is characterized by a nonsuppurative inflammation of the skin, subcutaneous tissues and skeletal muscle There also may be inflammatory changes in the vessels, myocardium and muscles of deglutition Little is known about the roentgenologic features We have had only one autopsy proved case, this showing a cloudy swelling of the myocardium and a congestive failure Chest roentgenograms taken a year before death showed the heart to be slightly larger than normal, but several weeks before death the heart vessel shadow was normal in size The lungs were clear

SCLERODERMA

Scleroderma is a polysystemic disease, with fairly well known roentgen findings (Table III) Large series of cases have been reported in the literature, one of the most comprehensive, from the roentgenologic viewpoint, being that by Pugh[22] Based on this material plus our own experience we believe that Table III summarizes the more important roentgenologic changes in this disease

We have reviewed ten microscopically proved cases of scleroderma in our hospital, five of

TABLE III
SUMMARY OF THE ROENTGENOLOGIC FINDINGS IN SCLERODERMA

A Gastrointestinal tract
  1 Esophagus
    a Loss of peristalsis due to rigidity
    b Variable degrees of dilatation
    c Occasional narrowing of distal esophagus
    d Occasional shortening of esophagus
  2 Stomach
    a Peristalsis may be decreased
    b Hiatus hernia may develop
  3 Small intestine
    a Peristalsis decreased or absent
    b Widening especially of duodenum and jejunum this may be segmental
  4 Colon
    a Peristalsis decreased
    b Segmental narrowing
B Lungs
  1 Diffuse or localized fibrosis
  2 Diffuse or localized nodulation
  3 Subpleural "cystic disease" (basal)
  4 Calcification (calcinosis)
C Heart
  1 Decreased amplitude or excursion
  2 Heart may be small normal or large
D Phalanges
  1 Absorption of distal phalanges in advanced cases
  2 Occasional increased density of phalanges
  3 Occasional synostosis, distal and middle phalanges
E Soft tissues
  1 Calcinosis—fairly frequent and often accompanies phalangeal absorption
    a Varies from "sand" to plaques
    b Usually in pressure areas fingertips, elbows ischial tuberosities
    c Usually seen only where there is cutaneous sclerosis
F Teeth
  1 Uniform widening of the periodontal spaces (reported in 7 per cent of cases)

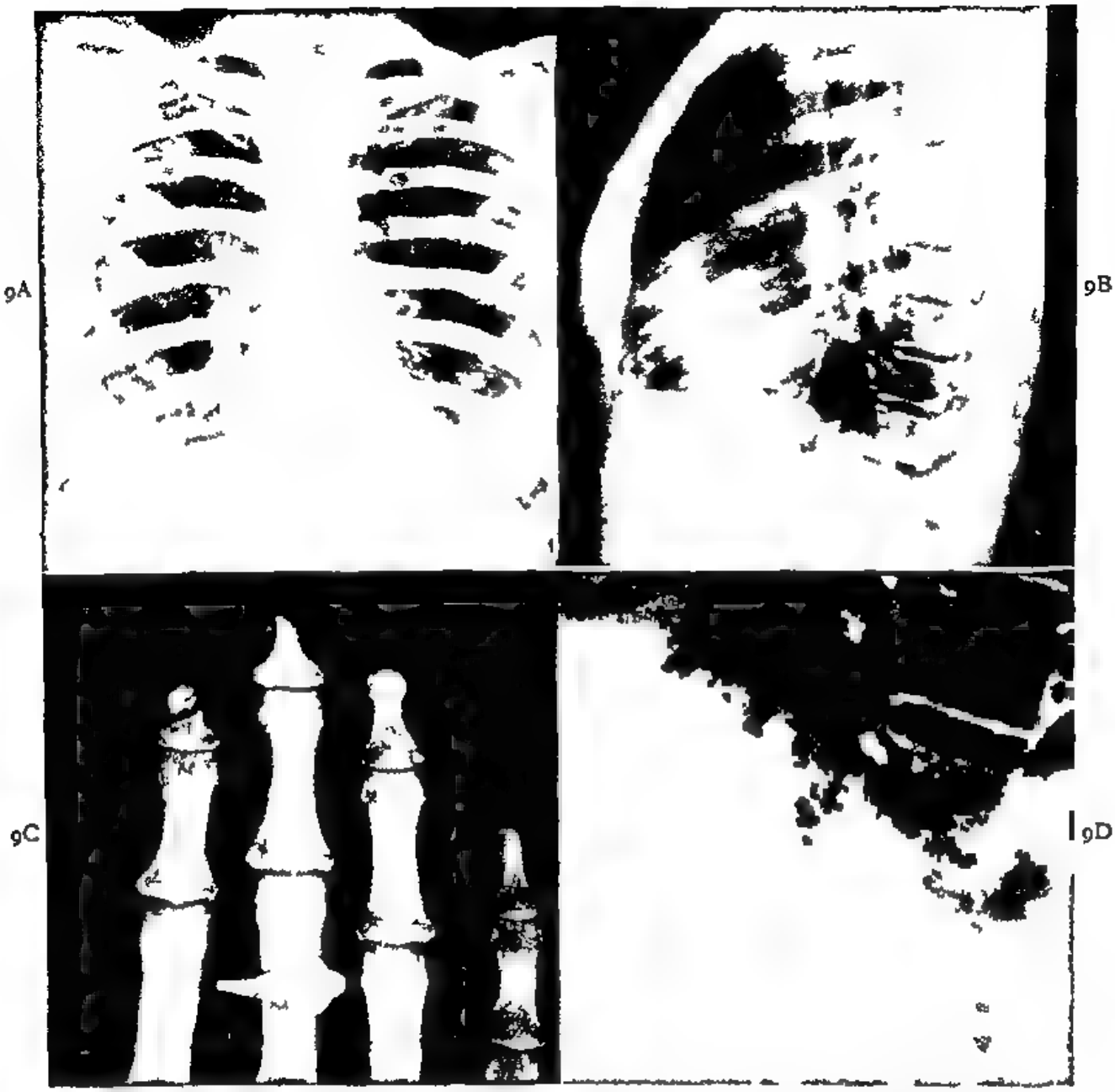

F c 9 Case D R Scle oderma w th cyst c d sease of the lung bases N gro female aged th rty Scleroderma for twelve years A mottled rad olucenc es (? cysts) n lung bases ■ lateral v ew C, tuft absorpt on and calc nos s D deta l v ew of cyst c appearance the les ons a e small result ng n a spongy appearance on the films (*Courtesy of Am J Roentgenol*)

which sho ved some degree of small intestinal abnormal ty One of the ten cases showed pul monary disease

Case R L P a seventy five year old Chinese man had weight loss (from 150 to

peared drawn tense and shiny He died of a ruptured diverticulum (diverticulitis) of the mid ascending colon eight days after starting on corticotropin Chest roentgenograms five months before death showed minimal prom inence of the lo ver lobe pulmonary markings and sl ght cardiac enlargement Examination

course of these markings The changes were more evident in the right upper lobe where one patchy density (1 5 by 3 cm) was also present The left costophrenic sulcus was blunted by fluid

Among several clinically diagnosed cases of scleroderma, we have seen one with subpleural cystic changes Case D R (Fig 9), a thirty year old Negro woman, had definite scleroderma for twelve years Chest roentgenograms showed a peculiar "spongy" appearance in the bases, presumably due to cystic changes, as described by Getzowa[13] in two cases These were cases interpreted as examples of "cystic and compact pulmonary sclerosis" The "cysts" varied from pinhead size up to 1 5 cm in diameter Only one showed concomitant extensive fibrosis The cyst like changes were believed to be due to a disappearance of alveolar tissue in the lung secondary to lysis of the alveolar walls and progressive sclerosis This sclerosis is reportedly on a basis of a "hyaline process involving the alveolar walls, accompanied by the disappearance of capillaries, superimposed on a generalized diffuse simple fibrosis of the alveolar walls"

Shuford et al [22] found that six of thirty seven patients clinically diagnosed as scleroderma had abnormal chest x-rays One had pulmonary edema (as a terminal phenomenon) Five had widespread linear reticulated infiltration, more marked in the lower halves of the lung fields They believe that differentiation from other diseases causing diffuse interstitial pulmonary fibrosis is difficult, if not impossible The pneumoconioses classically have a nodular rather than linear type of fibrosis, with emphysema (which is absent in scleroderma) Hilar adenopathy is frequent in sarcoid but rare in scleroderma

RHEUMATIC FEVER AND RHEUMATOID ARTHRITIS

We have reviewed some of the recent literature on rheumatic fever and rheumatoid arthritis, but have not analyzed in detail our cases of these diseases Acute rheumatic fever is regarded as a collagenous degeneration which localizes selectively in the heart The changes may be found in many other organs, as shown by the arthritic, dermal, serosal, intestinal and pulmonary manifestations of the disease In acute fulminating form, pulmonary complications are reportedly found in as high as 50 per cent of cases [14] "Rheumatic pneumonitis" has no specific diagnostic features in our experience Pericarditis is not uncommon The involved joints tend to show only articular and periarticular swelling

While the foregoing has been our own experience in connection with so called "rheumatic pneumonitis," many writers do believe that such an entity is common and diagnosable For example, Bland and Jones[3] mention that "areas of consolidation in the lungs, peculiar in their clinical behavior, occur in rheumatic pneumonia" Chancey[4] describes three types of rheumatic pneumonitis a primary acute type which may be the presenting sign of rheumatic fever, a secondary acute type which occurs in the established case of rheumatic fever and a "subclinical pneumonitis" which is often discovered accidentally in patients with subacute, monocyclic rheumatic fever

Part of the confusion may arise from the fact that pathologically there appears to be a distinct entity Neubuerger et al [23] reviewed the pathologic findings on sixty three cases of active and quiescent rheumatic fever, and noted eight in which there was pulmonary inflammation with distinctive microscopic features These included peculiar granulomas in the alveolar ducts and alveoli focal alveolitis with necrosis, mononuclear cell exudation and septal cell proliferation The rheumatic pulmonary granuloma has been referred to as the Masson body, allegedly similar to the Aschoff body which is found in the heart, Seldin et al [24] believe that there is little difficulty in microscopically distinguishing rheumatic pneumonia from bacterial or viral forms

Rheumatoid arthritis is frequently complicated by myositis, neuritis and arteritis as demonstrated in 70 per cent of muscle biopsies by Traut[11] and Campoine Traut also states that these biopsies show aggregates of lymphocytes, epithelioid cells and plasma cells somewhat similar to those in dermatomyositis, lupus erythematosus and scleroderma Pericarditis is the only unusually frequent cardiac complication, being especially common in juvenile rheumatoid arthritis (Still's disease) In addition, a pneumonitis and pleuritis may occur along with the inflammatory reaction in the joints but is rare The roentgen findings in the bones and joints of patients with rheumatoid arthritis are well known

While we have seen no convincing evidence of specific pneumonitis in connection with rheumatoid arthritis Ellman and Ball[10] report three cases in which they believe there was such relationship The roentgen findings in one case consisted of "fine reticulation" with chronic bronchopneumonia In one there was

bilateral patchy consolidation in the bases, with "reticular shadows" in the middle thirds of the lungs In the third case there was widespread "heavy reticulation and miliary mottling" The first and second cases were autopsied and showed interstitial pneumonitis and terminal bronchopneumonia, the pneumonitis had well marked fibrinoid necrosis between the lung alveoli, similar to that described in other collagen diseases

COMMENTS

Collagen diseases constitute an interesting group of disorders—from the clinical side because of their diagnostic and therapeutic challenge, from the pathologic viewpoint because of recent interest in the intercellular substances, and from the roentgenologic viewpoint because of their widespread but unfortunately non specific nature * The latter is particularly true of the pulmonary manifestations of the collagen diseases We believe, however, that diagnostic possibilities, slim as they are, depend on an awareness of these conditions, plus a knowledge that the patient has a polysystemic disease It is desirable that radiologists, as clinicians, be able occasionally to suggest the consideration of one of these diseases, on logical grounds, and be cognizant of the further studies, clinical, laboratory or pathologic, required to confirm the diagnosis

From a review of our roentgenologic findings we believe that pulmonary changes occur more frequently in periarteritis nodosa and disseminated lupus erythematosus than one would gather from the literature Further from a survey of the histories of over eighty patients with established or clinically diagnosed collagen disease, we have the distinct impression that peptic ulcers occur with relatively greater frequency in these conditions than in the rest of the hospital population in general

In studying a patient for possible collagen disease it is desirable that particular attention be paid to the following structures (1) the skin and muscles, (2) the heart and pericardium, (3) the lungs and pleura, (4) the abdomen and intestinal tract, (5) the kidneys and (6) the bones and joints

The skin and muscles may show microscopic evidence of involvement in any of the four types of collagen disease discussed in this paper * Histopathologic changes are reportedly fairly decisive in all except dermatomyositis, about which not enough is yet known, they are said to be most clear-cut in periarteritis, but there is divergence of opinion as to their clarity in scleroderma

The cardiac and pleuropulmonary changes are many and non specific Pericardial effusion, cardiac enlargement, pleural effusion, pulmonary nodular changes and variable degrees of pulmonary edema or fibrosis may occur These changes may be reversible

Abdominal distention, with paralytic obstruction, may occur in the first two conditions Renal enlargement may also be seen in these two (periarteritis nodosa and disseminated lupus erythematosus)

The intestinal tract changes are most conspicuous in scleroderma, notably in the esophagus and small intestine (variable degrees of rigidity, dilatation and narrowing occur in about 50 per cent of cases)

The articular and osseous changes occur in periarteritis nodosa, lupus and especially scleroderma Roentgenologically, they are characteristic only in the latter condition Calcinosis is also confined largely to this disorder

TREATMENT

Cortisone and corticotropin are of great value in alleviating the manifestations of the collagen diseases This treatment is by no means specific since it is not directed toward the cause An artificial remission may be lifesaving Nevertheless, despite the most skillful management of the disease with steroids, many terminate fatally

SUMMARY

We have reviewed currently accepted criteria concerning the pathology, classification and diagnosis of the so-called collagen diseases

We have reviewed our personal experience with the roentgenologic aspects of these diseases, and have summarized our findings in thirty-one cases of polyarteritis, thirty-five cases of generalized lupus erythematosus, one case of dermatomyositis, and twenty-five cases of scleroderma

* At the same time it is believed that the term "collagen disease" is one of high abstraction to be modified or abandoned as soon as the etiology and fundamental nature of these conditions becomes established

* Periarteritis nodosa, disseminated lupus erythematosus, dermatomyositis and scleroderma

In this entire group pathologic material was available for study in sixty-four cases and was interpreted as "positive" for the particular disease in question in fifty-four instances

It is believed that awareness of the roent-

in everyday practice

REFERENCES

1 BARDEN, R P and COOPER, D A Roentgen appearance of chest in diseases affecting peripheral vascular system of lungs, conditions associated with increased vascular permeability *Radiology*, 51 44–57, 1948

2 BECKER, R M Hypersensitivity and diffuse vascular (collagen) diseases *Bull New England M Center* 2 127–133, 1949

3 BLAND E F and JONES, T D Natural history of rheumatic fever *Ann Int Med*, 37 1006–1026, 1952

4 CHANCEY, R L Rheumatic fever *U S Armed Forces M J*, 4 1129 1953

5 Editorial Collagen diseases *J A M A*, 150 220–221, 1952

6 DOLB, H P et al Polyarteritis nodosa *Am J Roentgenol*, 71 785–792, 1954

7 EDWARDS J E et al Periarteritis *Proc Staff Meet, Mayo Clin*, 29 193 199, 1954

8 EHRICH, W E, FORMAN, C and SEIFTER, J Experimental differentiation of pathogenesis of serum sickness glomerular nephritis, rheumatic fever and periarteritis nodosa *Am J M Sc*, 215 713 714 1948

9 ELKELES A and GLYNN L E Serial roentgenograms of chest in periarteritis nodosa as aid to

10 E

J, 2 816 1948

11 FOLDES J Acute systemic lupus erythematosus. *Am J Clin Path*, 16 160 173 1946

12 GARLAND, L H and SISSON, M A Roentgen findings in the collagen diseases. *Am J Roentgenol*, 71 581–598 1954

13 GETZOWA, S Cystic and compact pulmonary sclerosis in progressive scleroderma *Arch Path*, 40 99–106, 1945

14 GRIFFITH, G C, PHILLIPS, A W and ASHER, C. Pneumonitis occurring in rheumatic fever *Am J M Sc*, 212 22–30, 1946

15 HARGRAVES, M M, RICHMOND, H and MORTON, R Presentation of 2 bone marrow elements "tart" cell and "L. E" cell *Proc Staff Meet, Mayo Clin*, 23 25–28, 1948

16 KAMPMEIER, R H Vascular diseases due to hypersensitivity so-called diffuse collagen disease *Am Pract*, 1 113 121, 1950

17 KELLGREN, J H Concepts of rheumatic disease *Brit J Med*, II 1093–1098 1952

18 LIBMAN, E and SACKS, B A hitherto undescribed form of valvular and mural endocarditis. *Arch Int Med*, 33 701–737, 1924

19 LOGUE, R B and MULLINS, F Polyarteritis nodosa, report of 11 cases with review of recent literature *Ann Int Med*, 24 11–26, 1946

20 MASSON, P et al Rheumatic fever *Ann d'anat path*, 14 359 1939

21 MIALE, J B Characteristic urinary findings in visceral angiitis (periarteritis nodosa, lupus erythematosus) *Am J Clin Path*, 17 820–822, 1947

22 NEUBERGER, K T et al Rheumatic pneumonia *Arch Path*, 27 1–15 1944

23 PUGH, D B Roentgenologic manifestations of scleroderma *Am J M Sc*, 216 571–580, 1948

24 RAKOV, H and TAYLOR, J S Acute disseminated lupus erythematosus, without cutaneous manifestations and with heretofore undescribed pulmonary lesions *Arch Int Med*, 70 88–100 1942

25 REEDER, W H and GOODRICH, R E Pulmonary infiltration with eosinophilia (PIE syndrome) *Ann Int Med*, 36 1217–1240 1952

26 RICH, A R and GREGORY, J E On anaphylactic nature of rheumatic pneumonitis *Bull Johns Hopkins Hosp*, 73 465–478, 1943

27 SELDIN, D W et al Rheumatic pneumonia *Ann Int Med*, 26 496–520, 1947

28 SHELFORD, W H et al Pulmonary manifestations of scleroderma *Arch Int Med*, 92 85–97, 1953

29 STEWART, L L Quoted by Hollenhurst, R W and Henderson J W Ocular manifestations of diffuse collagen diseases *Am J M Sc*, 221 211–222, 1951

30 THORELL, I Pulmonary changes in cases of disseminated lupus erythematosus *Acta radiol*, 37 8–16, 1952

31 TRAUT, E F Rheumatic Diseases, Diagnosis and Treatment St Louis, 1952 C V. Mosby Co

33

Sarcoidosis

LOUIS E SILTZBACH, M D, *New York, New York*

ALTHOUGH sarcoidosis is a systemic disease capable of affecting almost any organ its intrathoracic manifestations have come to be [illegible] clue is the disclosure of symmetrically enlarged bilateral hilar lymph nodes by a film made in a mass chest survey These surveys have shown that sarcoidosis in its clinically silent stage is by no means rare Regarding prognosis, the type and degree of pulmonary involvement and the course which the lung lesions take largely determine whether the patient will recover or be left with a significant degree of pulmonary insufficiency and cor pulmonale The number of patients who in time suffer from respiratory difficulties is substantial and such patients account for a high proportion of the fatalities which occur in sarcoidosis

The toll of disability and death from chronic pulmonary sarcoidosis is reflected in our experience with 134 patients over a nine year period Seven deaths have occurred six from sarcoidosis For all six, pulmonary insufficiency was an immediate cause of death Eighteen of the living patients are handicapped by dyspnea, and in six of these the symptom is severe enough to be almost wholly incapacitating There is but one other organ in which sarcoidosis does comparable damage, namely, the eyes Twenty six of our patients suffered some loss of vision, and in six patients the result was blindness in one or both eyes

DEFINITION

The most widely accepted definition of sarcoidosis is one which was adopted by the Conference on Sarcoid of the National Research Council in 1948,[1] as follows

"Sarcoidosis is a disease of unknown etiology Pathologically it is characterized by the presence in any organ or tissue of epithelioid cell tubercles with inconspicuous or no necrosis and by the frequent presence of refractile or apparently calcified bodies in the giant cells of the tubercles The characteristic lesions may be replaced by fibrosis, hyalinization or both Clinically the lesions may be widely disseminated The tissues most frequently involved are lymph nodes, lungs, eyes, and bones, particularly of the extremities The clinical course usually is chronic with minimal or no constitutional symptoms, however, there may be acute phases, characterized by a general reaction with malaise and fever There may be signs and symptoms referable to the tissues and organs involved The intracutaneous tuberculin test is frequently negative, the plasma globulins are often increased The outcome may be clinical recovery with radiographic evidence of residue or impairment of function of organs involved, or a continued chronic course of the disease"

DIAGNOSIS

[illegible] structure, the so-called "hard" tubercle, also occurs in certain granulomatous conditions of known cause tuberculosis, leprosy, histoplasmosis, beryllosis and brucellosis, among others Those conditions must therefore first be excluded The next step is to determine whether the clinical and laboratory findings are compatible with sarcoidosis

Usually there is a fairly typical clinical picture The patient is likely to be between the ages of twenty and forty Often the patient first comes under observation because a chest roentgenogram has unexpectedly disclosed bilateral hilar node enlargement, usually with-

out but sometimes with disseminated pulmonary lesions As a rule in early cases there are no symptoms and no abnormal physical findings However, on investigation some patients are found to have palpable superficial lymph nodes and a recent history of erythema nodosum along with joint pains parotid or lacrimal gland swelling uveitis or hepatosplenomegaly If there is also a relative cutaneous insensitivity to tuberculin and an elevation of the serum globulin and calcium levels the finding of the epithelioid cell tubercles in the tissue biopsy may be expected and that closes the diagnostic circle

When neither superficial lymph nodes nor cutaneous lesions are available for biopsy other means are used to obtain tissue to verify the diagnosis Needle aspiration of the liver has yielded the granuloma with a fair degree of frequency Less successful have been blind' biopsies of nasal and bronchial mucosa bone marrow and muscle

All those diagnostic procedures are gradually being superseded by the scalenus fat pad biopsy [3] Frequently even when the supraclavicular areas do not contain palpable lymph nodes epithelioid cell granulomas are found within the fat pad which contains lymphoid tissue in communication with the upper mediastinal nodes The fat pad lies behind the clavicle between the scalenus anticus and sternocleidomastoid muscles It is easily removed under local anesthesia through a small incision in the supraclavicular fossa Carstensen[3] has reported on 200 scalenus fat pad biopsies in sarcoidosis suspects and found 60 per cent of them positive This procedure is proving itself especially useful in early cases when the disease process is still limited to the thorax

The Nickerson Kveim Cutaneous Reaction There remains a fair sized group of patients who have sarcoidosis but who nonetheless present either atypical clinical features or tissue biopsies which are wanting in the characteristic histologic changes It is especially for such patients that the Nickerson Kveim intracutaneous reaction has been found helpful A report concerning 200 patients who underwent the test has been published elsewhere [4]

The test consists of intradermal injection of a heat sterilized suspension of human sarcoid tissue and histologic examination of the site of the injection after four to six weeks In a positive reaction a sarcoid like granuloma is produced at the injection site A large percentage of sarcoidosis patients with biopsy verification and a group clinically diagnosed as having sarcoidosis reacted positively to the test—86 per cent of the former and 85 per cent of the latter Two patients of a 'control group numbering fifty four patients with diseases other than sarcoidosis also responded positively to the test—an incidence of 4 per cent of false positive reactions Biopsy of the injected site was considered an obligatory part of the test Suspensions of normal lymph nodes and normal spleen failed to evoke positive responses Foreign body reactions and nonspecific inflammatory changes sometimes interfered with the microscopic reading Some experience is required for proper reading of the test As the disease process regressed the test result tended to become negative, but positive responses were encountered in a few patients whose illness had begun a decade earlier The Nickerson Kveim intracutaneous reaction was considered a useful confirmatory tool in the

tested patients had gone through months or even years of investigation without having a

scalenus fat
results with

the Nickerson Kveim reaction it becomes less and less necessary to perform an open lung biopsy or a mediastinal node biopsy to establish the diagnosis of intrathoracic sarcoidosis

Patient Material The analysis presented herein is based on observation of 123 patients with sarcoidosis who showed evidence of mediastinal node or pulmonary involvement at

For sixty six patients tissue biopsy or autopsy verification was obtained for fifty the diagnosis was a clinical one and was also confirmed microscopically by positive Nickerson Kveim tests The remaining seven patients had neither tissue biopsy verification nor positive Nickerson Kveim tests but the constellation of intra and extrathoracic organ involve-

ment, course and outcome of the illness made sarcoidosis the diagnosis of choice

Female patients outnumbered male patients seventy eight to forty-five There were seventy-three white patients and fifty Negro patients The age of the patients ranged from twelve to fifty-five years The average age was thirty-three years, 103 patients or 83 per cent were under forty years of age Seventy patients had extrathoracic lesions of sarcoidosis at some stage of their illness, usually with multiple organ involvement

The patients have been under observation one month to eighteen years The average observation period was 32 7 months Forty-nine patients were observed one year or less, fifty-one patients from one to five years and twenty three patients more than five years In some instances early observations were carried out at other clinics or by referring physicians Our long term observations are still relatively scanty

All patients were given a Nickerson-Kveim intracutaneous test One hundred thirteen patients or 93 per cent had a microscopically positive response Ten patients reacted negatively Five of the ten were patients whose pulmonary lesions had already undergone fibrosis

As expected, most patients showed tuberculin insensitivity Only eleven reacted to a dilution of 1 10,000 O T or the first strength P P D Five reacted to a dilution of 1 1,000 O T Thirty two patients responded only to a dilution of 1 100 O T and seventy-five did not respond at all In short, 107 patients or 87 per cent reacted weakly or not at all

CLASSIFICATION OF INTRATHORACIC LESIONS BY STAGES

For a clear understanding of the symptomatology and course of mediastinal node and pulmonary sarcoidosis it is helpful to classify the presenting roentgenographic lesions according to a chronologic scheme wherever possible A classification of intrathoracic sarcoidosis which has been found useful in the present series is shown in Table 1 Extrathoracic lesions require their own schemes of classification, which vary with the organ affected

Three stages of intrathoracic sarcoidosis are recognized the first stage, which may be described as early or florid, the second or transitional stage, and the third, late or fibrotic stage It is not always possible to fit a given case into the scheme with ease and precision This was especially true of our patients with mixed lesions which were placed in the transitional stage Yet each stage seems to have its characteristic set of roentgen patterns, its

assessment Seven patients were already in the transitional stage, and seven others had reached the late or fibrotic state when first observed Some of the early stage patients went into the second and third stage while under observation, hence the number in the later stages rose from fourteen to thirty-eight Nevertheless, in this as in most published series of patients with intrathoracic sarcoidosis, the patients with early or florid lesions continued to outnumber the rest This is understandable since most patients with early lesions recover without ever entering the two later stages From mass roentgenographic chest surveys and follow-up observations it may be postulated that a sizable number of persons in the general population pass through the early stage of sarcoidosis and then recover with the entire episode undetected

I The Early or Florid Stage

The early or florid stage may be subdivided according to three distinct patterns which appear in the chest films, as follows (1) bilateral symmetric hilar node enlargement, with or without enlargement of the tracheobronchial and paratracheal nodes, (2) widely disseminated or localized fine miliary and occasionally gross miliary nodulation in both lung fields with hilar node regression or persistence, and (3) diffuse fluffy bronchopneumonic patches usually accompanied by some nodal enlargement

1 *Bilateral Hilar Node Enlargement (Sixty-two Patients)* If there is a stage of sarcoidosis which precedes the hilar node enlargement, there is as yet no way to detect it Usually the first nodes to show any abnormality are those of the bronchopulmonary chain Often the paratracheal chain on the right side is enlarged as well, less commonly, the tracheo-

hand and, on the other hand, malignant lymphoma and metastatic carcinoma

Symptoms seldom stem from the enlargement of the hilar nodes Twenty-nine patients, or almost one half the sixty-two patients with nodal enlargement, first learned of an abnormal shadow in the mediastinum through a film made in a mass survey or during a periodic health examination Eight other patients had a chest film made during an attack of erythema nodosum at which time the enlarged nodes were first discovered

The remaining twenty five of these early stage patients with nodal enlargements had symptoms related to other *manifestations* Here diagnostic impressions ranged from rheumatic fever to mumps infectious *mononucleosis* malignant lymphoma, hypersplen *ism, tuberculous meningitis* and hyperpara thyroidism or chronic glomerulonephritis (the last two proved to be renal impairment caused by hypercalcemia of sarcoidosis) There was even an instance when trichinosis was suspected because voluntary muscles were affected by sarcoidosis In each instance it was the presence of bilateral hilar node enlargement that raised the suspicion of sarcoidosis which later was confirmed by appropriate investigations

Extrathoracic involvement, either silent or symptomatic, may be present at the time when the enlargement of the hilar nodes is detected Such generalization, involving peripheral nodes eyes parotid glands and liver, apparently occurs at times very soon after if not simultaneously with the hilar node enlargement This became apparent in a few patients in our series These actually had had a normal film just prior to appearance of the hilar node *enlargement*, and so it was possible to date accurately the onset of both nodal enlargement and symptoms

Although the pulmonary fields in this early nodal enlargement stage simply show a few perihilar streaks, there is indication that minute disseminated pulmonary lesions actu *ally exist without being visible roentgenographically* This supposition is supported by the findings of Löfgren[4] who had bronchoscopies performed on patients with *bilateral* hilar node enlargement ascribed to sarcoidosis Among the bronchoscopic *biopsies* there were eight which had pieces of lung *parenchyma* attached to them, and four of *these showed* classical sarcoidosis lesions within the lung

TABLE I

COURSE OF SARCOIDOSIS (123 PATIENTS WITH INTRATHORACIC LESIONS)

Stage of Disease According to Chest Roentgen Pattern	No of Patients in Specified Stage on First Film	Course of Lesions*				
		No of Patients with Total or Nearly Total Regression	No of Patients without Significant Change	No of Patients with Progression to Fibrosis		Deaths from Sarcoidosis
				Transitional	Late	
I Early or florid						
1 Bilateral hilar node enlargement	62	25	31	5	1	1
2 Miliary nodulation	33	7	13	7	6	2
3 Patchy infiltrations	14	4	4	1	5	1
II Transitional						
Reticular pattern plus nodules and infiltrations in pulmonary fields	7	0	6	6	1	
III Late or fibrotic						
With bullae and non specific infection	7	0	7	0	7	2

* Twenty six patients with intrathoracic lesions received cortisone or corticotrophin therapy

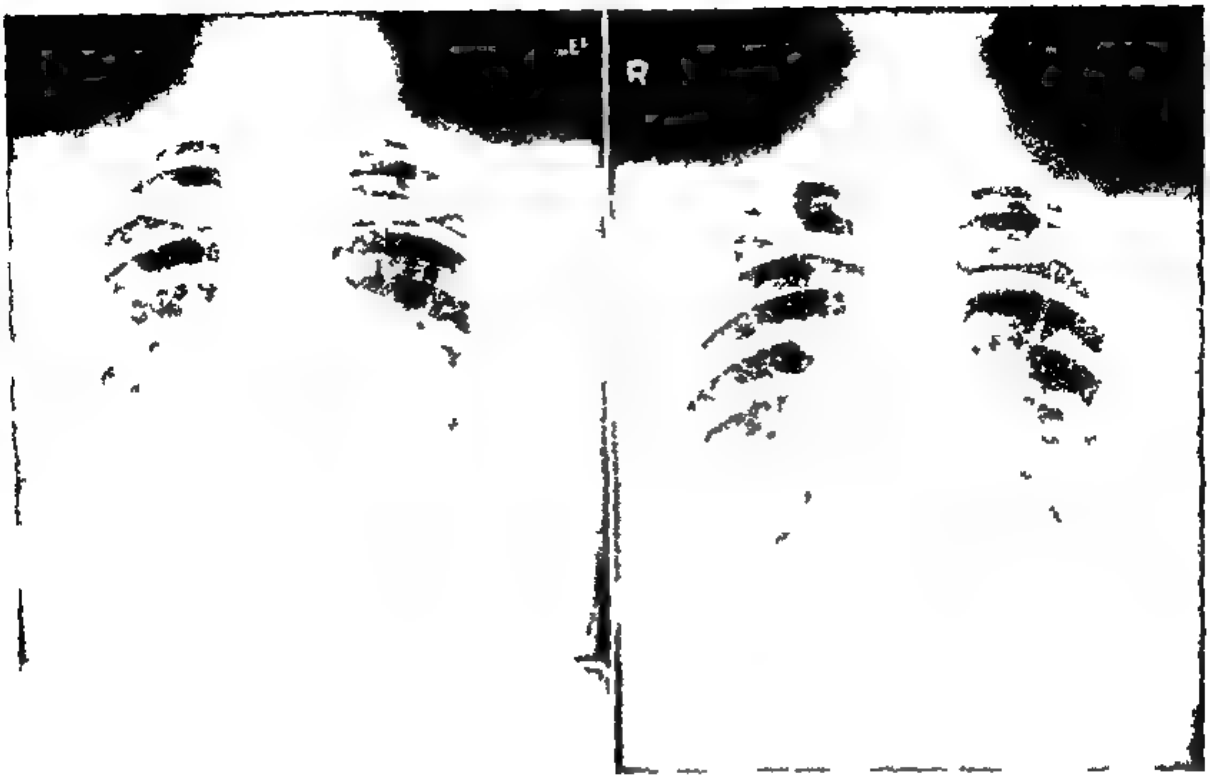

1A 1B

Furthermore impairment of pulmonary function occasionally is reported in patients with

outcome of this stage of the illness is favorable Of sixty two patients who were followed up on the average twenty seven months (twenty eight patients for less than one year) there were twenty five who experienced complete regression or nearly complete regression within the period of observation Only one patient of this group experienced disabling pulmonary symptoms which led to death after fourteen years Thirty one of the group had persistently enlarged nodes In many instances the nodes were smaller but still substantial Sometimes the nodes remained enlarged for as long as five years before regression occurred (Fig 1) With a longer period of observation many of the persistent nodes will disappear if one is to judge by the adequately observed group Loefgren[8] observed regression of nodes after two years in 72 6 per cent of seventy patients with hilar nodes He has designated the enlargement of hilar nodes as the primary stage of pulmonary sarcoidosis

Regression of the mediastinal nodes sometimes occurs at varying tempos in different chains Occasionally the last to disappear are the right paratracheal or the left tracheobronchial nodes Then the nodes are unilaterally enlarged and may be confused with enlargements caused by Hodgkin s disease and tuberculosis Only three times in this series did a patient show unilateral hilar node enlargement and in two of those instances the opposite bronchopulmonary nodes subsequently enlarged Eight patients with erythema nodosum had complete resolution of enlarged nodes within two years

In all ten patients with hilar node enlargement later experienced pulmonary lesions

2A 2B

However, in four of the ten the lesions were of a miliary character and eventually disappeared without a trace, in the other six, fibrosis occurred Five of the six patients eventually presented the reticular pattern of the transitional stage without symptoms and one, as stated, went on to dense fibrosis and death from pulmonary insufficiency (Table 1) A second patient in this group died but from an unrelated cause, gastric carcinoma The death not shown in the table, occurred eleven months after a biopsy-verified diagnosis of generalized peripheral lymph node sarcoidosis had been established *There were no symptoms of* sarcoidosis

In recapitulation, patients with bilateral hilar node enlargement seldom reach either the transitional or the late stage of chronic pulmonary sarcoidosis (in our series only six of sixty-two patients, or a little less than 10 per cent) Only one of these patients experienced dense pulmonary fibrosis with disabling symptoms, which led to death after fourteen years

2 *Miliary Nodulation (Thirty three Patients)* The roentgenographic pattern found here is characterized by widely disseminated fine miliary nodules Probably this always follows enlargement of the hilar nodes although in some instances the nodal phase is missing having gone by unrecognized (Fig 2A) The miliary lesions may be unilateral (Fig 2B) but this is uncommon The miliary dissemination usually occurs within the same year as the hilar node enlargement, although exceptionally *the nodulation first appears later* Sometimes the nodules are so fine as to give a ground-glass

3A 3B

patients have persistent nodal enlargement throughout the phase

Conditions which mimic this phase of early pulmonary sarco dos s are as mentioned miliary tuberculosis pneumonoconiosis beryl losis lymphangitic carcinoma idiopath c pul monary fibrosis and hemos derosis compl cating mitral stenosis among others

Miliary nodulation like enlarged nodes may cause no symptoms However low grade fever fatigue and slight dyspnea are occasion ally experienced We have not encountered in this series acutely ill patients in the early phase whose complaint is tachypnea requiring an oxygen tent for its control Such cases have been reported and they are found to have the alveolar capillary block syndrome with gas diffusion difficulties [7,9] Fourteen cases or almost one-half of the th rty three with miliary nodulation were discovered through chest surveys

Course and prognosis These thirty three pa tients with miliary nodulation on the first available chest film had a less favorable out come than patients with hilar node enlarge- ment only as Table 1 shows The thirty three patients were followed up on the average thirty eight months (twelve for less than one year)

Seven of the thirty three experienced com plete regression of the nodules (If four other patients are counted who had miliary nodula tion some time after discovery of hilar enlarge- ment then in our series there were eleven patients with miliary nodulation who had complete regression)

Thirteen other patients had residual miliary nodulation but without respiratory symptoms However most of these were followed up less than t vo years

Finally the other thirteen of our thirty three patients in time exhibited some irreversible pulmonary changes on the chest film In seven of these reticular fibrosis of the transitional

monary fibrosis with formation of bullae and five of them had considerable respiratory dis tress Two succumbed to pulmonary insuf

ficiency with cor pulmonale—one at the age of thirty seven seven years after discovery of the miliary nodulations and the other at the age of thirty after eighteen years illness

In summary, of thirty three patients whose first chest film showed miliary nodulation thirteen later evidenced significant pulmonary fibrosis of whom two died and five have respiratory difficulty There was no way of predicting the outcome for the individual patient at the outset but the later appearance of gross nodulation or coalescent patches was a bad omen

3 *Diffuse Bronchopneumonic Infiltrations* Fourteen of 109 patients of the early stage had an initial roentgen pattern of diffuse areas of soft mottling suggesting bronchopneumonic patches These parenchymal lesions were usually accompanied by bilateral hilar node enlargement (Fig 3A) The soft infiltrations are hard to differentiate from those of non specific bronchopneumonia exudative pulmonary tuberculosis eosinophilic pneumonia acute beryllosis and terminal bronchiolar carcinoma among others In sarcoidosis the patient has very few or no respiratory symptoms however and the contrast between extensive involvement of the lung fields and the relative comfort of the patient may be taken as a hallmark of early pulmonary sarcoidosis. Six of our fourteen patients with patchy lesions were discovered in the silent asymptomatic stage by survey chest films

The patchy infiltrations in the lungs appear to arise *de novo* and if there is a stage of hilar node enlargement or miliary nodulation which precedes it it must be extremely brief In a few instances films were available from just before the film showing the soft lesions and they were entirely normal Although the patchy lesions do not appear roentgenographically to develop by confluence of miliary nodules they may leave coarse nodules in their wake when they regress

Course and prognosis As can be seen in Table 1 the lung lesions regressed fully in four of the fourteen patients who started with this soft shadow manifestation of sarcoidosis Four of the fourteen patients had persistent soft shadows and two patients had dyspnea (one moderate and one severe) This last mentioned patient a fifty six year old woman succumbed to pulmonary insufficiency eleven months after discovery of her abnormal roentgen findings

Another of these patients showed remarkably rapid resorption of the infiltrations within nine months only a few localized strands of fibrosis remained The patient, a woman had no symptoms during the succeeding four years and she has successfully passed through two spontaneous deliveries (Fig 3A and B) In contrast the table shows that five of the four teen patients went on to dense pulmonary fibrosis Two suffered from severe dyspnea were totally disabled one had moderate dyspnea

In summary, of fourteen patients with an initial roentgen pattern of patchy bronchopneumonic areas five were left with densely scarred lungs and one with a small localized area of fibrosis Four were left with dyspnea One patient of the group died of pulmonary insufficiency and cor pulmonale her chest film at death still showing diffuse soft shadows and little evidence of fibrosis

II Transitional Stage

The transitional stage of intrathoracic sarcoidosis is characterized roentgenographically by fine or coarse reticulation This network usually extends throughout both lung fields but it may be limited to a few areas It is considered to be caused by infiltration of the interstitial tissue particularly about the roots of the lung with granuloma and fibrous tissue in varying proportions In the background nodules and confluent mottled areas are seen Occasionally the hilar nodes are still enlarged (Fig 4D) Emphysema may be present but it is not so advanced as it is in the late fibrotic stage Bullae are not a prominent feature It usually requires two or more years to reach the transitional stage

The roentgen picture of this stage of pulmonary sarcoidosis may easily be confused with the picture of diffuse pulmonary fibrosis caused by other conditions such as pneumonoconiosis beryllosis asthmatic bronchitis with infection congestive heart failure lymphangitic carcinoma and idiopathic pulmonary fibrosis the Hamman Rich type

Only seven patients were placed in the transitional category originally but it can be seen from the table that thirteen other patients passed from the early stage into this group and remained here for the rest of the period of observation on the average thirty months How

FIG 4A Film of a twenty four year old man who had abnormal chest film during Army induction

found to have negative reaction to tuberculin 1 :100 O T and was discharged There was no history of industrial dust exposure

FIG 4B Detail of Figure 4A showing very faint miliary densities studding the lung field and en larged right bronchopulmonary nodes

ever, of the seven original patients in this category, six showed no change and one progressed to dense fibrosis Four of the patients in this group had moderate dyspnea Three patients had no symptoms at all in spite of significant changes in the lung fields There were no deaths in this group

III Late or Fibrotic Stage

In the late fibrotic stage the granulomatous process in the lung undergoes involution and the lesions for the most part become hyalinized, the result is dense fibrosis and marked distortion of the normal roentgen pattern Generally the extensive interstitial fibrosis, which is most pronounced near the lung roots and in the peribronchial and peribronchiolar regions, requires five years longer to come about The

develop (Fig 4A to 4F) Patchy infiltrations may represent non specific superinfection

Symptoms in this stage are usually severe Dyspnea is outstanding Cough and copious expectoration of purulent sputum may indicate a grave outlook Hemoptysis occurs but infrequently Some patients have marked

emphysema from any of numerous causes

are mixed with finer ones and giant bullae may

thirty-four and thirty-eight, respectively) five years after discovery of lesions which were in

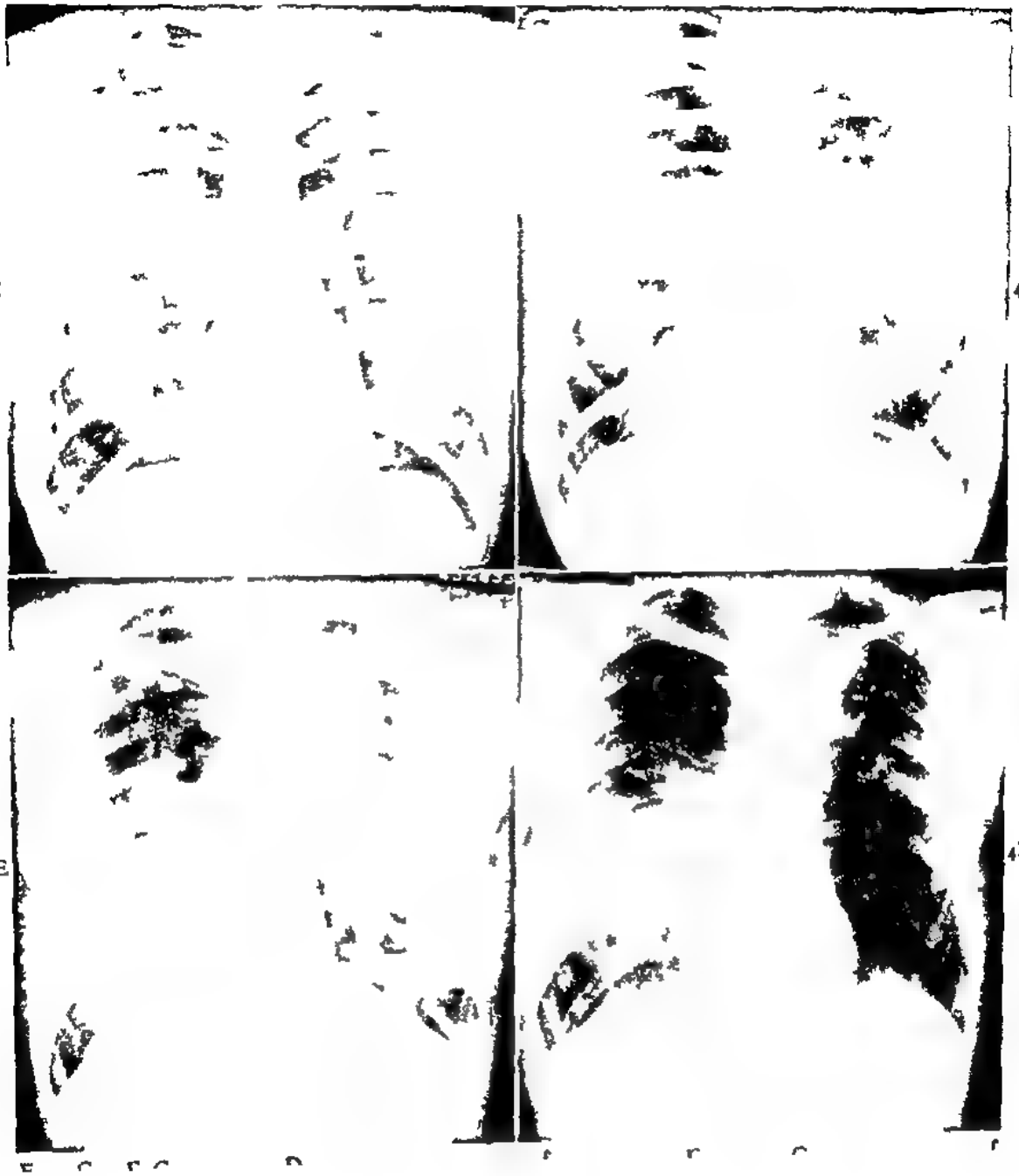
4C
4E
4F

each instance densely fibrotic It can be assumed that they had had sarcoidosis for many years before the disease process became recognizable

In conclusion it is apparent that the outcome of intrathoracic sarcoidosis may be predicted on the basis of the roentgenographic pattern which is present when the patient first comes under observation

[illegible]

were left with some residual fibrosis without [illegible]

The other two groups of the early or florid stage had parenchymal involvement on initial films and these patients did not do so well Of thirty three patients with miliary nodulation thirteen showed progressive fibrosis Two died and five were left with dyspnea Of fourteen patients with bronchopneumonic onset, six showed residual fibrosis and four of these patients were dyspneic Among the fourteen there was one death

Adding the deaths and disabilities of the patients of the transitional and late fibrotic stages, it is found that for the entire series of 123 patients seven died, six or 5 per cent of sarcoidosis, thirty-nine patients or 31 per cent showed evidence of irreversible pulmonary scarring and eighteen patients or 15 per cent were left with significant respiratory disability

Tuberculosis developed in three other patients after the pulmonary lesions of sarcoidosis had regressed All three were Negroes

From these data it is clear that pulmonary [illegible]

TREATMENT

Before the advent of cortisone and corticotrophin therapy no treatment was demonstrably effective in sarcoidosis It has been shown previously that cortisone therapy was capable of suppressing some clinical manifestations of sarcoidosis in thirteen patients Fresh lesions proved more responsive than older ones The drug's suppressive action often proved temporary but even this was beneficial in selected instances in which the unremitting course of the disease was producing loss of organ function Biopsies of various tissues removed during and shortly after cortisone therapy frequently showed regression of epithelioid cell tubercles and their replacement by scar tissue The changes were similar to those occurring with spontaneous healing but the tempo appeared to be accelerated by the drug

Since the previous study twenty other patients have been given the hormones * Thus thirty three patients in all have been treated in the last four and a half years and a brief summary of the experience follows

The sites of involvement for which hormonal therapy was *primarily* given were lungs, twelve patients, eyes seven patients, cutaneous or subcutaneous lesions, six patients, grossly enlarged cervical lymph nodes, three patients, central nervous system involvement, two patients, recurrent parotid swelling one patient, severe arthralgia accompanying erythema nodosum of early sarcoidosis, one patient, and, finally, protracted fever and marked weight loss one patient Of the thirty-three patients who were treated with cortisone, diagnosis was confirmed by tissue biopsy in twenty eight patients and by positive Nickerson Kveim intracutaneous test in five patients

Of the patients with pulmonary involvement, only those having moderate or severe dyspnea, twelve in number, were chosen for treatment Patients with bilateral hilar node involvement and those with miliary nodulation were not considered to require therapy since they presented no pulmonary symptoms and the prospect for spontaneous recovery was considered good, particularly for the nodal group Yet as will be shown the incidental effects of cortisone upon lesions of this type could be observed in a number of patients who were treated for lesions at other sites such as ocular and cutaneous sites The duration of treatment usually ranged from four weeks to four months Seven patients received more than one course In three instances the treatment courses lasted forty to sixty six weeks, and one other patient has been receiving maintenance cortisone therapy for the last two and a half years

* Cortisone used in this study was partly supplied by Merck & Co Inc

The roentgenographic response to cortisone therapy of intrathoracic lesions varied Accelerated clearing was the rule in patients with early stage pulmonary involvement These lesions are known to revert spontaneously Little or no roentgenographic clearing occurred in patients with transitional or late fibrotic stage pulmonary lesions For that group the benefits which accrued from therapy were mostly symptomatic, as was expected

The results of cortisone therapy according to the stage of disease at which the patient was treated follow

Nineteen patients had enlarged mediastinal nodes, three of these showed complete regression eight partial regression and eight no change The lack of shrinkage was noted often at the same time as the patient s peripheral lymphadenopathy disappeared dramatically There was no relapse after the drug was stopped As mentioned, in no instance was the basis for therapy the enlarged nodes

Six patients had miliary nodulation of the lung fields, four of these had prompt and complete clearing one partial clearing and one no effect after four months therapy Relapse was uncommon, only one patient had recurrence of the nodules within six weeks after the drug was stopped None of the patients was treated primarily for these lesions In one treatment was for a complicating bronchial involvement [12] in five for extrathoracic lesions

Two patients had bronchopneumonic patches of early sarcoidosis both complaining of dyspnea, and they experienced partial clearing of the lung infiltrations and lost their symptoms One of these two patients had roentgenographic and symptomatic relapse five months after withdrawal of the drug The other maintained gains but the period of observation is as yet too brief to determine whether the beneficial result will endure

Three patients had transitional stage lesions in the lung and none of these showed much resorption on the chest film Two of these patients had dyspnea and they had a good symptomatic response The other patient received a drug for a central nervous system lesion and had no pulmonary complaints The two patients who gained relief of symptoms from cortisone had prompt symptomatic relapse after the drug was discontinued

Finally, seven patients had lesions of the late fibrotic stage Of these, four showed no change on their chest films and three showed some lessening of infiltrations One of these patients had no relief of dyspnea cough and expectoration, and another died of a suppurative fungal infection while being treated with cortisone and antibiotics Four patients who improved suffered prompt relapse after the drug was withdrawn, but one patient has continued on maintenance therapy for more than two years without relapse The long term result of therapy in this group has been unsatisfactory but this therapy is the best that can be offered at present

Comment on Cortisone Therapy In this series only those patients who were headed inexorably toward pulmonary insufficiency were treated with cortisone It was realized that the drug could have no effect upon the scar tissue already present in the lung yet in some instances patients with late fibrotic disease experienced considerable relief of symptoms It is generally agreed that mediastinal node enlargement *per se* does not require treatment since in almost all instances spontaneous regression even if slow will eventually occur Furthermore there is also little question that the unusual patient with the picture of acute pulmonary insufficiency from diffuse miliary nodulation or bronchopneumonic [illegible] as the hormone therapy is whether or not to treat patients with early diffuse nodulation or infiltration before symptoms appear If the patient is treated with hormones pulmonary insufficiency may develop sooner because of the fibrosis promoting action of the drug We have seen fibrosis proceeding while the patient was receiving the hormones If the patient goes untreated he may continue to elaborate granulomatous lesions in the lung which eventually will make for a more severe pulmonary insufficiency

More data about the rate of development of fibrosis and the resulting impairment of lung function will have to be obtained in treated as well as untreated patients before a valid conclusion concerning this problem can be drawn The experience with this series of patients does demonstrate that in a good many instances early lung infiltrations caused by sarcoidosis even though asymptomatic later lead to a crippling of respiratory function

In addition to these indications for cortisone

treatment of intrathoracic sarcoidosis, the following criteria are those presently observed for assessing the need for hormonal therapy for extrathoracic lesions of sarcoidosis (1) in all cases with ocular manifestations no matter how minimal, (2) patients with febrile course and marked weight loss (3) patients with central nervous system or cardiac involvement, (4) patients with disfiguring cutaneous and superficial lymph node lesions and (5) patients with persistent hypercalcemia It appears that cortisone therapy can reduce the serum calcium level and this may help prevent nephrocalcinosis and renal insufficiency Moderate peripheral lymph node enlargement, parotid lesions and other minor sites of involvement generally do

etiologic agent is identified, a more direct approach to treatment may be possible

In none of the thirty three cortisone treated patients in this series did tuberculosis develop Carstensen[8] states there was no case of tuberculosis in his group of sixty six patients with sarcoidosis who had received cortisone and corticotrophin

SUMMARY

During the last nine years 123 patients with intrathoracic localization of sarcoidosis have been observed There were six deaths from sarcoidosis Thirty nine patients showed varying degrees of pulmonary fibrosis, and eighteen patients among the survivors were left with significant respiratory difficulty

Intrathoracic lesions could be assigned to one of three broad chronologic stages according to the roentgen pattern present on the initial chest film early, transitional and late In the early stage, for those patients whose film showed enlarged mediastinal nodes without pulmonary lesions the outlook was best It was not so favorable for patients whose films showed miliary nodulation of the lung fields and still less favorable when the film first showed a patchy bronchopneumonic pattern Patients in the transitional and late fibrotic stages often showed disabling symptoms, and five of the six deaths caused by sarcoidosis were in patients with pulmonary lesions in these stages

Scalenus fat pad biopsies and the Nickerson-Kveim intracutaneous reaction are valuable diagnostic aids when involved tissue is not easily accessible for biopsy verification

Cortisone and corticotrophin generally act favorably upon intrathoracic sarcoidosis although the benefits usually prove temporary In severe pulmonary insufficiency occasionally seen in the early stage and more often in the late fibrotic stage of pulmonary involvement, hormones may be the only means to tide a patient over the crucial period

In early stage lesions consisting of mediastinal lymphadenopathy, treatment is unnecessary because spontaneous regression is the rule It is still debatable whether patients with asymptomatic miliary nodulation or bronchopneumonic patches in the lung fields should receive hormonal therapy in an attempt to forestall widespread pulmonary fibrosis

In chronic pulmonary sarcoidosis the effects of the hormones are variable Sometimes symptomatic relief is dramatic and sustained More often the relief is partial and relapse occurs promptly after the hormones are withdrawn Pulmonary fibrosis may proceed even while the patient continues to receive the drugs Indications for the treatment of extrathoracic lesions of sarcoidosis are listed

REFERENCES

1 Quoted by RICKER, W and CLARK, M Sarcoidosis. *Am J Clin Path* 19 725 1949
2 DANIEL, A C A method of biopsy useful in diagnosing certain intrathoracic diseases *Dis of Chest* 16 360 1949

16 790 1954
5 LÖFGREN S and LUNDBACK H The bilateral hilar syndrome *Acta med Scandinav* 142 266 1952
6 COATES E O and COMROE J H, JR. Pulmonary function studies in sarcoidosis *J Clin Investigation* 30 849 1951
7 STONE D J et al Pulmonary function in sarcoidosis *Am J Med* 15 468 1953
8 LÖFGREN S Primary pulmonary sarcoidosis II *Acta med Scandinav* 145 465 1953
9 MCCLEMENT J H et al Cardiopulmonary function in pulmonary form of Boeck's sarcoid and its modification by cortisone therapy *Am Rev Tuberc*, 67 154, 1953
10 NETTER, L. Changes in the chest roentgenogram in Boeck's sarcoid of the lungs *Acta Radiol* Suppl 105 pp 1 202 1953
11 SILTZBACH L. E Effects of cortisone in sarcoidosis. *Am J Med* 13 139 1952
12 SILTZBACH L. E. and SOW M L. Sarcoidosis with bronchial involvement *J Mt Sinai Hosp* 19 473 1952

34

Pulmonary Manifestations in Infectious Diseases

MAXWELL L. GELFAND, M.D., *New York, New York*

Assistant Professor of Clinical Medicine New York University—Postgraduate Medical School
Associate Visiting Physician Bellevue Hospital
Associate Visiting Physician University Hospital

THE bronchopulmonary tree is normally inhabited by a variety of micro-organisms many of which may, under the proper stimulus, become active and produce pathologic changes depending on the resistance of the host Any acute infectious disease can alter the local medium or affect the immune response of the body in such a manner as to permit these organisms to propagate in sufficient numbers to damage the respiratory tract In the present chemotherapeutic era with its emphasis on antibiotics for the control of most infections the equilibrium may easily be upset and non pathogens transformed into pathogens In addition, the toxicity of an original disease may so disturb the defense mechanisms of the body that pneumonitis will eventually ensue Such complications are therefore not unusual and can be observed in almost all fatal cases of overwhelming infections, they do not come within the scope of this paper

There are however, a number of infectious diseases of varying etiology which present themselves in a specific manner not primarily in the bronchopulmonary tree but in the course of their clinical development affect this area Early recognition of these manifestations is thus important to permit a proper evaluation of the disease entity itself, to offer a correct prognosis and to institute suitable therapy

The purpose of this chapter is to emphasize the variety of pulmonary findings encountered in the various common acute infectious diseases of either viral rickettsial or bacterial origin Those caused by fungi, protozoa or parasites are covered in other sections of this volume

DISEASES OF VIRAL ORIGIN

Influenza Although considerable advances have been made in the study of the etiology of influenza, there is still a tremendous void in the understanding of this disease The term "influenza" has unfortunately become a by word in clinical medicine to describe almost any vague short term febrile condition un accompanied by localizing signs Since a number of infectious states closely resemble it, differentiation can be made only on the basis of complicated laboratory procedures In the absence of such data, the diagnosis of influenza depends predominantly on the existence of an epidemic Basically, it is considered a specific infectious disease caused by three viruses namely those of Influenza A B and C se rologically unrelated and immunologically distinct

Influenza occurs both in epidemics and pandemics In the former case it may be localized or widely spread and persons of any race age or sex are susceptible Pandemic out breaks are rare, the last extensive one in 1918–1919 involved the entire globe and cost the lives of nearly twenty million people The condition is most prevalent during the winter months but sporadic epidemics may develop at any time and in the past twenty years have occurred yearly Transmission is probably through infected droplets from the upper respiratory tract

The incubation period of Influenza A and B is usually one to two days and the onset is acute The symptoms are constitutional con sisting of chilliness, headache malaise lassi tude, anorexia, fever and muscular pains [illegible] include sneez [illegible] itation [illegible] ynx or

trachea Cough is a prominent feature but is usually non-productive and occasionally is associated with substernal pain

The pulmonary manifestations of influenza are minimal, consisting at times of a few moist *rales at the bases posteriorly Percussion reveals good resonance X-rays of the chest disclose either an absence of abnormal findings* or some congestion at the hila, with or without infiltration into the parenchyma of one or both lungs As a rule, there is a striking disparity between the physical and radiologic findings In a small percentage of cases, however, percussion will give evidence of dullness over one or more lobes, with signs of bronchial breathing, increased voice sounds and sibilant rales in these areas—typical signs of consolidation X-rays confirm the presence of lobar or bronchopneumonia in this type of involvement Some observers believe this to be the result of

characteristic interstitial or extensive bronchopneumonia produced by the influenza virus itself, which alone is responsible for the signs of patchy involvement of the lungs This opinion is based on the work of Goodpasture who, during the pandemic disease of 1918–1919 described a lesion found in many who succumbed to pneumonia at that time, i e, dilated alveolar ducts, with a hyaline membrane covering their walls and those of the *adjacent alveoli In another group in which the pneumonia did not develop until the acute* phase of the initial infection had passed, he attributed the cause to a secondary bacterial infection caused by staphylococci, beta hemolytic streptococci, H influenza and pneumococci Complications from these infections involving the pleura and empyema, with lung abscesses and bronchiectasis, were also common In the last two decades, however, epidemics of influenza that developed in previously *normal persons have been accompanied only rarely by pneumonia*

Measles Although measles, a highly contagious infectious disease, is observed chiefly

is characterized by a prodromal period of fever, catarrhal symptoms of the eyes and respiratory tract and enanthem in the mouth (Koplik's spots), followed by a typical rash The incubation period usually lasts fourteen days, and although the disease can occur at

present

Because of the involvement of the entire respiratory tract, physical signs indicative of this appear early In addition to sneezing

istic of this disease

however, percussion will reveal evidence of consolidation and auscultation a change in the breath sounds, significant of patchy areas of bronchopneumonia

Radiography of the lungs discloses four

frequently observes complications involving the lungs as a result of secondary bacterial invasion The organisms usually responsible for this type of bronchopneumonia or pneumonia are beta hemolytic streptococci, the pneumococci and the H influenza bacilli In such instances antibiotics which would be wholly ineffectual against the pneumonitis due to the virus *per se* will prove of considerable value in controlling the infection

Mumps Mumps is an acute, viral, self-limited, contagious disease with a high morbidity and a very low mortality The most

enlargement of the parotid

is not

rarely

affected although at times bronchitis has been associated with the condition The clinical

signs are minimal and the x-ray findings of the lungs entirely negative.

Chicken Pox This viral disorder is characterized by fever and a vesicular eruption, with erythema around the vesicles, and involves the skin over the entire body and the mucous membranes of the mouth and throat Although predominantly a disease of childhood, chicken pox is not entirely uncommon in adults in whom the morbidity is high and complications frequent Involvement of the mucous membrane of the larynx causes respiratory difficulty, with signs of obstruction due to the stenosis Rarely does the responsible virus attack the lungs themselves, but occasionally in such cases there are typical signs of dullness to percussion and modification of breath sounds with rales Most frequently the pulmonary signs elicited are due to a secondary infection from the pathogenic microorganisms residing in that area or from an extension of the existing laryngeal ulceration

Smallpox This is an acute, highly communicable disease caused by a virus and characterized by severe constitutional symptoms and a single crop of skin lesions, all developing at the same rate during the various stages of the condition, over a period of three to nineteen days Other organs are likewise involved, for example, the lungs It is not generally understood that the smallpox virus itself may give rise to a specific bronchopneumonia, with characteristic inclusion bodies in many of the affected cells In addition there may be a frank lobar pneumonia of a hemorrhagic type secondarily produced by such invading organisms as the staphylococci, pneumococci and streptococci The physical signs and roentgen findings in the pulmonary fields in the first type of involvement are similar to those usually observed in atypical pneumonia, but in the complicating lung condition they consist of dullness, bronchial breathing, alteration of breath sounds and moist and crepitant rales

Erythema Multiforme Exudativum This disease is an acute, febrile, debilitating one lasting two to four weeks and not as uncommon as ordinarily supposed It is known by many other eponyms, e g , mucosal respiratory disease, Stevens-Johnson syndrome, Behcet's disease, Klauder's syndrome, Hebra's disease and ectodermosis erosiva pluriorificialis All writers agree that the general term erythema multiforme exudativum is by far the most descriptive and therefore preferable designation Since no specific agent has as yet been isolated, there is considerable speculation as to the etiology, although a virus is believed to be the most likely suspect The condition has protean manifestations, but its outstanding feature is extreme toxicity, with marked dehydration and apathy In addition, there are the characteristic multiforme-like cutaneous and mucosal lesions involving the lips, buccal mucosa and genitalia, as well as eye lesions, fever, joint manifestations and lung involvement

The presence of the pulmonary complications in erythema multiforme exudativum was stressed in this country by the Commission on Acute Respiratory Diseases in 1946 The associated pneumonia is now considered to be an integral part of the disease and closely resembles the primary atypical variety in its clinical features An initial unproductive cough subsequently changes into one with moderate expectoration of a tenacious mucopurulent sputum The physical signs in the chest during the early phase of the illness may be entirely negative despite significant x ray findings, consisting of either (1) increased bronchovascular markings, (2) feathery pneumonic infiltrations in one or more lobes or (3) hilar densities radiating to the periphery As the disease progresses, physical signs appear, consisting of sonorous and sibilant rales over the involved areas with alteration of breath sounds and patchy signs of dullness to percussion It is important to realize that the pulmonary findings in this disease are features of the general infection and that treatment is therefore nonspecific Broad spectrum antibiotics and steroids have been employed with success at times

Infectious Mononucleosis Although there is no clue as to the exact etiology of this disease, a virus has generally been considered responsible Young people are most often affected The condition is characterized by fever, sore throat, enlarged lymph glands and a pathognomonic blood picture, with elevated sheep cell agglutinin titer in the serum Wechsler and his co-workers have classified the various types of the illness according to its clinical manifestations as follows (1) anginose, (2) insidious, (3) eruptive, (4) icteric, (5) pulmonary, (6) abdominal, (7) lymphoglandular and (8) meningitic They found that 2 5 per cent of their

patients showed pulmonary lesions similar to those in atypical pneumonia In most instances the physical signs in the lung fields are minimal but roentgen examination reveals hazing and mottling in various lobes with increase in the hilar markings Cough is frequently encountered and when present resembles whooping cough with bronchospasm

Most authors do not consider the broncho pulmonary involvement a prominent feature of infectious mononucleosis although routine x rays of the chest have disclosed broncho pneumonia in patients with this disease

Lymphocytic Choriomeningitis This is a relatively benign disease of viral etiology producing a marked diversity of signs and symptoms Although showing a predilection for the central nervous system with the classi

grippe without involvement of the brain Occasional cases reported as implicating the lungs have closely resembled the pneumonia of the atypical variety Rales may be heard with or without signs of consolidation but an x ray examination of the chest demonstrates areas of patchy pneumonitis In a few fatal cases the virus was isolated from the lungs at necropsy

Poliomyelitis Acute anterior poliomyelitis is an endemic and epidemic disease of viral etiology affecting both children and adults It is characterized clinically by a brief febrile illness with sore throat and gastrointestinal symptoms followed by central nervous system involvement with or without flaccid paralysis of the voluntary muscles

There are three recognized forms of polio *myelitis the abortive the non paralytic and* the paralytic The abortive type possesses no symptoms which are unique for poliomyelitis It may be the only phase of the disease in which no definite diagnosis is possible and the history alone would cause one to suspect its presence since the cerebrospinal fluid is entirely normal At times this early stage may be followed by the other forms Non paralytic poliomyelitis is a syndrome in which there is evidence of invasion of the central nervous system without localizing signs The abnormally high spinal fluid count is the only indication of meningeal irritation Spinal paralytic poliomyelitis is the classical form of the disease, in which flaccid paralysis of the legs arms back thorax face intercostal region and diaphragm occurs The encephalomyelitic and bulbar forms are additional examples of paralytic involvement

The tracheobronchial tree is never directly attacked by the virus of poliomyelitis but due to the implication of the muscles of respiration the disturbances of the central control of respiration the obstruction of the airway caused by the inability to swallow and by paralysis of the intrinsic muscles of the larynx and direct involvement of the brain stem a number of pulmonary abnormalities can occur Circumscribed areas of atelectasis often develop in one or both lungs and these are difficult to detect in ordinary physical examination On the x ray screen they are frequently mistaken for the consolidations of bronchopneumonia When they occur at the bases of the lungs as a result of obstruction of the small bronchi they are called plate shaped atelectasis Aspiration pneumonia bronchopneumonia and

Secondary infections from streptococci pneumococci and Friedlander bacilli leading to frank lobar pneumonia are not uncommon and when present are usually of a serious nature requiring aggressive antibiotic therapy Thus an awareness of the many pulmonary disturbances in poliomyelitis is mandatory for the reduction of the morbidity and mortality of this catastrophic disease

RICKETTSIAL DISEASES

Typhus Fever This is an acute infectious disease characterized by severe headache *sustained high fever generalized maculo*papular rash and termination by rapid lysis in two weeks The three types of typhus fever—epidemic louse borne Brill Zinsser and flea borne—though epidemiologically and histori

illness patients complain of severe headache with marked elevation of temperature and a violent unproductive cough At the end of the week there is marked photophobia a suffused conjunctiva impaired hearing and a macular or maculopapular rash on the back and chest spreading later to the abdomen and extremities

but sparing the palms and soles During the second week increased signs of toxicity with delirium and coma as well as skin necrosis otitis media and bacterial bronchopneumonia are frequent complications The latter pulmonary involvement is more often detected by roentgen examination than by physical signs Active immunization against this rickettsial disease and the early administration of chloromycetin and the tetracycline drugs modify and alter the clinical course of epidemic typhus so favorably that complications never develop

Scrub Typhus This is a self limited febrile illness caused by Rickettsia Tsutsugamushi and transmitted by chiggers It is characterized by a sudden rise in temperature associated with a primary eschar and followed by a red macular rash over the trunk extending on the fifth day to the arms and legs A non productive cough is frequently present during the first few days at which time numerous rhonchi and rales are audible over both lung fields In about 20 per cent of cases the x ray will show signs of a non specific pneumonitis consisting of increased bronchovascular markings and patchy areas of increased density Only rarely do frank signs of pneumonia appear but at present since the introduction of chloramphenicol and the tetracycline drugs for the treatment of the disease this complication has been completely eradicated

Q Fever This is an acute illness caused by Rickettsia burnetii and characterized by its sudden onset malaise headache anorexia and in many instances an interstitial pneumonitis Inasmuch as the condition is discussed in another section of this text it will not be treated in detail here Suffice it to say that the pulmonary picture in Q fever is similar to that in typical pneumonia As a rule a cough develops on the fifth or sixth day and examination of the chest reveals the presence of a few crepitant rales and slight diminution in resonance Roentgen examination confirms the pulmonary implication by demonstrating patchy areas of consolidation corresponding to the areas detected by percussion The involvement seems to be confined to a portion of one lobe and tends to present a homogeneous ground glass appearance In many instances the x rays continue to show pulmonary involvement even after the febrile episode is completely past and the patient has been discharged from the hospital The diagnosis should be suspected on the basis of such a pulmonary picture and in the absence of symptoms and signs of a respiratory disease but the only reliable criterion is the result of laboratory tests directly demonstrating the virus in the blood spinal fluid or urine or of agglutination and complement fixations tests which are positive in the convalescent period

BACTERIAL DISEASES

Pertussis Pertussis or whooping cough is an acute infectious disease of the respiratory tract caused by the Hemophilus pertussis a gram negative bacillus and is transmitted by droplets The tracheobronchial tree bears the brunt of the disease developing a catarrhal infection of the epithelium of the larynx trachea and bronchi and an essential lesion consisting of necrosis of the mid zonal and basal portions of the bronchial epithelium Peribronchiolitis extending from the hilum along the bronchial vascular rays to the middle or outer zones of the lung also occurs As the condition progresses typical interstitial pneumonia develops At times an accumulation of mucus pus and cellular debris within the alveolar spaces results from secondary infection The outstanding symptom a characteristically spasmodic cough is most frequently followed by a forced inspiration the whoop and sometimes by vomiting The physical signs in the chest vary from numerous rhonchi and wheezes to a patchy pneumonitis X ray examination may reveal clear lungs or slow signs of increased bronchovascular markings with hilar congestion increased radiolucency of both lung fields areas of increased density atelectasis or manifestations of a frank pneumonia Emphysema of the vesicular or interstitial type occurs in almost all cases and at times as a result of rupture of the air blebs on the surface of the lung the air may find its way from the mediastinum into the subcutaneous tissue Bronchial asthma bronchiectasis and pulmonary fibrosis may remain as sequelae of the disease

Scarlet Fever This is an infection of the upper respiratory tract produced by group A hemolytic streptococcus and resembles the acute tonsillitis and pharyngitis caused by this organism with the addition of an exanthem and an enanthem Involvement of the lower respiratory passages is very rare but when it does occur presents itself as a tracheitis

bronchitis or bronchopneumonia The usual mechanism is an extension of the infection from the larynx, but occasionally the lungs are implicated simultaneously with the onset of the disease Rales are heard early in the affected area, with some diminution in the percussion note X rays reveal the typical picture of patchy bronchopneumonia At times a pleural effusion develops in association with bronchopneumonia

Diphtheria Although there has been a marked decline in the incidence of this disease since the introduction of active immunization on a large scale, nevertheless there are still a number of cases reported each year in the United States The condition occurs most commonly during the fall and winter months, and children under the age of five who have not been immunized are particularly susceptible The causative agent is the bacillus Corynebacterium diphtheriae, and the primary lesion is usually located in the pharyngeal area, which includes the fauces, nasopharynx and larynx Only rarely does diphtheria manifest itself primarily in the trachea and bronchial tree When the bronchi are involved, there is atelectasis due to occlusion of their lumina and danger of emphysema as a result of check-valve blockage of the smaller bronchi Bronchopneumonia and purulent bronchitis are fairly common complications The diagnosis is not easy, however, since the symptoms are similar to the hoarseness, dyspnea and cough due to the development of edema and the formation of the membrane seen in the laryngeal form As the laryngeal obstruction increases the dyspnea becomes more marked, cyanosis appears and with it aphonia and stridor The detection and removal of the constriction is therefore more important than attention to the pulmonary involvement, for unless the airway is restored by tracheotomy or intubation, death will ensue X ray examination of the chest will be extremely helpful in demonstrating the presence of any underlying disturbance in the lung

Brucellosis Brucellosis is an infectious disease caused by organisms belonging to the genus Brucella and occurring in two clinical forms, namely, the acute stage, characterized by fever, sweating weakness, myalgia and arthralgia, and the chronic stage, in which the same manifestations persist over many months or even years

The natural transmitter of brucellosis is the domesticated animal, cattle, hogs, goats, etc, and man contracts the disease directly either through small abrasions in the skin or by the ingestion of unpasteurized milk and cheese The condition is more prevalent among farmers, livestock producers, meat-packing employees and veterinarians, and affects the rural population rather than the urban

A number of clinical symptoms have been well described by Spink and others Examination may disclose few or no localized abnormalities In most cases fever, hepatosplenomegaly and lymphadenopathy are almost constant findings, either alone or in combination The lungs are more commonly affected than is usually realized Cough is a frequent complaint The disease may affect the bronchi, pleura and parenchyma of the lung, either separately or together As a result bronchitis, pleurisy with or without effusion, patchy involvement of the lungs, giving the appearance of a lobular bronchopneumonia, granuloma of the lung resembling a neoplasm, and lung abscess are types of damage encountered in this protean ailment The lesion most commonly seen on x-ray consists of increased hilar shadows, with bronchovascular infiltrations, and at times the picture of an unresolved pneumonia baffles the examiner The nodular shadow of a granuloma is frequently mistaken for a neoplasm, but the nature of the disease will in such cases clarify the diagnosis When one suspects the disease, an examination may be made of the sputum or the aspirated gastric contents and the brucella organism isolated by either direct vision or culture

Typhoid Fever and Salmonellosis Typhoid fever is an acute, febrile illness caused by Salmonella typhi, a parasite limited to man alone The organism is usually excreted in the urine and feces by those afflicted but sometimes persists in the stools during convalescence Patients may occasionally become permanent carriers The onset of the disease is gradual, beginning with malaise and apathy, headache, sweating, remittent fever, leukopenia, a non productive cough and a maculopapular eruption The rash appears in about the second week and consists of crops of round, slightly elevated rosy spots lasting two to five days At this time the spleen also becomes palpable The diagnosis can be established during the first week by blood culture, during the second week H and O agglutinins are

demonstrable in the serum, with subsequent rise in the titer of these antibodies as the disease progresses In the third and fourth week the stool culture is also found to be positive

There are several organisms of the genus Salmonella capable of causing salmonellosis in man and their number is constantly increasing The clinical picture of the infection may vary from a simple gastroenteritis to a severe enteric infection or a septicemia without gastrointestinal symptoms The diagnosis can be made only upon identification of the causative agent in the blood, feces, urine or some local focus

The pulmonary manifestations are the same in typhoid fever and the salmonella infections, with the identical symptoms of pleuritic pain, cough and expectoration Typhoid bacilli have been isolated in the sputum of many patients with typhoid fever Bronchitis is an almost constant finding, and this is often associated with dyspnea, cyanosis and generalized sibilant rales Lobar pneumonia, though rare in typhoid, does occasionally develop, and in such cases the signs and symptoms in the lungs dominate the picture Such a syndrome was formerly referred to as "pneumotyphoid," and typical signs of dullness to percussion, bronchial breathing and moist rales were noted Pulmonary infarction, congestion and edema are also occasionally encountered

In salmonellosis focal involvement of the lungs is more frequently observed Bronchopneumonia has been noted in about 25 to 40 per cent of cases Lobar pneumonia, pleural effusion, empyema and pericardial effusion have also been reported At times the organisms have been isolated from the sputum, pleural

will depend on the degree and extent of involvement and are the same as those found when this area is attacked by organisms known to be common invaders

PASTEURELLA INFECTIONS

Plague Plague, a generic term reminiscent of the Middle Ages and including three commonly recognized types—bubonic, septicemic and pneumonic—is an acute infection caused by Pasteurella pestis and transmitted chiefly by rodent fleas The scourge may be carried from wild rodent to domestic rat or vice versa, from either of these to man, and from man to man

In pneumonic plague the physical signs are usually minimal and consist mainly of a few scattered fine rales, but the breathing is usually rapid and shallow and cyanosis is marked The sputum is thin and watery at first but later becomes bloody with a close resemblance to that of streptococcal pneumonia These pulmonary manifestions may occasionally occur in the other two forms of plague but as a rule are characteristic of the pneumonic type alone

Tularemia This is a specific infection caused by Pasteurella tularensis, which requires no particular portal of entry for its penetration The sources of human infection are (1) contact with infected rabbits, (2) bites of arthropods, such as deer fly, wood and dog ticks, (3) bites by cats coyotes, dogs and skunks, (4) contact with sheep, (5) skinning and dressing of muskrats and beavers and handling of pheasants, (6) laboratory infections and (7) ingestion of partially cooked rabbit meat or water contaminated by water rats There are several forms of tularemia, namely, cutaneous, cryptogenic, oral, abdominal and pleuropulmonary

The pleuropulmonary type may begin as an inhalation infection with pulmonary symptoms, or it may develop on a secondary hematogenous basis, with a primary focus elsewhere In either case cough, pleuritic pain and signs of a patchy bronchopneumonia are characteristic Some writers believe that primary tularemic pneumonia does not occur, but that the condition is a direct result of the bacteremia The lung findings vary from a patchy lobular bronchopneumonia, with enlarged mediastinal and peribronchial lymph nodes, to that of a frank lobar consolidation Sometimes the lesion becomes necrotized, resulting in gangrene, cavitation and pulmonary abscess

Pulmonary Anthrax Industrial exposure to wool or animal hair, hides or skin infected with the spores of the Bacillus anthracis may give rise to a pulmonary form of anthrax The condition presents no characteristic clinical symptoms The mucosa of the nose, larynx and pharynx becomes reddened and swollen, and cough with chest pain and dyspnea ensue Expectoration of a frothy and blood tinged sputum is not uncommon The lungs present the picture of a diffuse bronchitis or bronchopneumonia In the latter case pleural effusion—

in most instances bilateral—is a frequent concomitant The causative organism can often be isolated from the sputum or pleural exudate but rarely from the blood Roentgenograms of the chest show irregular areas of confluence and pleural effusion

Glanders Glanders is primarily an equine ailment occasionally transmitted to man and caused by a specific organism, Malleomyces mallei It occurs in two forms, acute and chronic systemic In the past the disease in man was usually contracted by direct or indirect contact with infected horses During the last thirty years, however due to the constant testing of horses and the eradication of infected animals the condition has been rare in this country Occasional accidental infections have been reported recently among laboratory workers

The pulmonary manifestations in glanders are fairly common and have been reported in about one fourth of the cases They vary from a simple bronchitis with cough to a bronchopneumonia with a focal necrotizing lesion approximating lung abscess or a true lobar pneumonia The physical findings and x ray data of the chest indicate the underlying disorder

Syphilis of the Lung Although Treponema pallidum the etiologic agent of syphilis can invade the respiratory tract it does so very rarely The larynx can be attacked with hoarseness and occasional cough as the only symptoms The lower portion of the trachea and main bronchi may also be implicated leading to cough expectoration and substernal soreness Acquired syphilis of the lung in adults is regarded by many with the greatest skepticism, yet such cases have been observed at necropsy on rare occasions

Syphilis usually attacks the lower parts of the lungs sparing the apices The process is more marked around the hilus and progresses along the bronchi to the periphery It tends to develop unilaterally and may completely destroy the function of one lung yet have no effect on the other It also involves the pleura extensively and causes a connective tissue reaction producing radiating or stellate scars but rarely, if ever, calcification Gumma both single and multiple are usually seen in the untreated cases

Clinically the symptoms of syphilis of the lung are not very distinctive There may be cough with or without expectoration and hemoptysis is uncommon Physical signs when present consist of diminished expansion impairment of percussion, and bronchovesicular breathing over the localized area of involvement Occasionally complete collapse of a lung occurs and then signs of dullness are present over the entire field and there is an absence of breath or voice sounds

Radiographically three types of lesions are seen in the pathologic evolution of this condition namely, (1) gummata with syphilitic peribronchial infiltration, (2) syphilitic peri bronchial fibrosis and (3) bronchostenosis with collapse of the lung resulting from luetic ulceration of the bronchus

The diagnosis of pulmonary syphilis is a difficult one and can be made only after all other pulmonary conditions have been excluded To facilitate its recognition the following points should be observed (1) a thorough examination of the sputum to rule out any other organism (2) a positive serology (3) other stigmata of lues and (4) clearing of the lesion following antiluetic therapy

SUMMARY

It has been shown that a number of infectious diseases of varying etiology—viral rickettsial or bacterial—give rise to definite manifestations in the bronchopulmonary tree For a proper evaluation of these pulmonary conditions, the setting up of a correct prognosis the institution of suitable therapy in each case and a clear understanding of the clinical picture are essential It is the purpose of the present chapter to clarify this picture

REFERENCES

1 CECIL, R L. and LOEB R F A Textbook of Medicine 9th ed Philadelphia 1955 W B Saunders Co

2 RIVERS T M Viral and Ricketts al Infections of Man Philadelphia 1948 J B Lippincott Co.

3 BANYAI A L. Nontuberculous Diseases of the Chest Springfeld Ill 1954 Charles C Thomas

4 DUBOS R J Bacterial and Mycotic Infections of Man 2nd ed Philadelphia 1952 J B Lippincott Co

5 FREY J Lung involvement in influenza *Bru M J*, 2 1374 1951

6 SCHER, J M and JARUSZEWSKI L Virus influenza A' infection with pulmonary manifestations *Arch Int Med* 90 201 1952

7 TYRELL, D A J The pulmonary complications of influenza as seen in Sheffeld in 1949 *Quart J Med.*, 21 291, 1952

8. SMITH, W., ANDREWES, C. H. and LAIDLAW, P. P. A virus obtained from influenza patients. *Lancet*, 2: 66, 1933.
9. KOHN, J. L. and KORIANSKY, H. Pneumonia in measles, further roentgenographic studies of the chests of children during measles. *Am. J. Dis. Child.*, 46: 40, 1933.
10. DENTON, J. Pathology of fatal measles. *Am. J. M. Sci.*, 169: 531, 1925.
11. HOMER, L. and DONOVAN, W. N. Aureomycin in mumps. *J. A. M. A.*, 150: 465, 1952.
12. CLAUDY, W. B. Pneumonia associated with varicella. *Arch. Int. Med.*, 80: 185, 1947.
13. Smallpox in Japan and Korea. *Bull. U. S. Army M. Dept.*, 6: 101, 1946.
14. COUNCILMAN, W. T., MAGRATH, G. B. and BRINKERHOFF, W. R. The pathological anatomy and [illegible]
15. [illegible]
16. [illegible]
17. [illegible] exudativum. *Arch. Int. Med.*, 70: 607, 1940.
18. CONTRATO, A. W. Infectious mononucleosis. A study of one hundred and ninety-six cases. *Arch. Int. Med.*, 73: 449, 1944.
19. WECHSLER, H. F., ROSENBLUM, A. H. and SILLS, C. T. Infectious mononucleosis. Report of an epidemic in an Army Post. *Ann. Int. Med.*, 25: 113, 236, 1946.
20. FARMER, T. and JANEWAY, C. A. Infections with the virus of lymphocytic choriomeningitis. *Medicine*, 21: 1, 1942.
21. HORSTMAN, D. H., McCOLLUM, R. W. and MASCOLA, A. D. Viremia in human poliomyelitis. *J. Exper. Med.*, 99: 355, 1954.
22. Management of Poliomyelitis Patients with Respiratory Difficulty. Publication of the National *Foundation for Infantile Paralysis* (120 Broadway, New York 5, N. Y.).
23. Rickettsial Diseases of Man. American Association for the Advancement of Science. Washington, D. C., 1948.
24. YEOMANS, A., WOODWARD, T. E. and BLAND, E. F. Clinical observations in typhus fever with special reference to the cardiovascular system. *J. A. M. A.*, 126: 287, 1944.
25. LILLIE, R. D., PERRIN, T. L. and ARMSTRONG, C. An institutional outbreak of pneumonitis. III. Histopathology in man and Rhesus monkeys in the pneumonitis due to the virus of "Q" fever. *Pub. Health Rep.*, 56: 140, 1941.
26. BULLOWA, J. G. M. and WISHIK, S. M. Complications of varicella, their occurrence among 2,534 patients. *Am. J. Dis. Child.*, 49: 923, 1935.
27. HAYDEN, R. L. and KAGER, L. R. Pulmonary manifestations of brucellosis. *Cleveland Clin. Quart.*, 13: 220, 1946.
28. LEVITT, R. O. Undulant fever. *M. Clin. North America*, 27: 259, 1943.
29. MINOR, G. R. and WHITE, M. L., JR. Some unusual thoracic complications of typhoid and Salmonella infections. *Ann. Int. Med.*, 24: 27, 1946.
30. MORGAN, H. R. The Salmonella. In Dubos' Bacterial and Mycotic Infections of Man, 2nd ed., chap. 17. Philadelphia, 1952. J. B. Lippincott Co.
31. McCRUMB, F. R., JR., MERCIER, S., ROBIC, J., BOUILLAT, M., SHADEL, J. E., WOODWARD, T. E. and GOODNER, K. Chloramphenicol and terramycin in the treatment of pneumonic plague. *Am. J. Med.*, 14: 284, 1953.
32. HUNT, J. S. Pleuropulmonary tularemia: observations on 12 cases treated with streptomycin. *Ann. Int. Med.*, 26: 263, 1947.
33. STEELE, J. H. and HELVIC, R. J. Anthrax. *U. S. Pub. Health Rep.*, 68: 616, 1953.
34. HOWE, C. and MILLER, W. R. Human glanders—report of 8 cases. *Ann. Int. Med.*, 26: 93, 1947.
35. McINTYRE, M. C. Pulmonary syphilis. *Arch. Path.*, 11: 258, 1931.
36. [illegible] Pulmonary syphilis [illegible]
37. [illegible] *Roentgenol.*, 8: 502, 1921.

XIII. CONGENITAL DISEASES

35

Agenesis of the Lung

EMIL A NACLERIO, M D, New York, New York

From the Thoracic Surgical Services of Harlem and Columbus Hospitals New York New York

ESSENTIALLY asymptomatic but clinically significant anatomic anomalies of the respiratory tract, formerly undetected during life, are now being demonstrated with increasing frequency due to widespread acceptance of routine mass radiography, and are being diagnosed by follow-up bronchoscopy, bronchography and exploratory thoracotomy

Minor forms of abnormal embryologic development, such as anomalous vascular patterns, are not too uncommonly found during intrathoracic operations However, cases of agenesis, aplasia and hypoplasia in which there is practically no functioning pulmonary tissue are considered relatively rare Up to 1955 less than 150 cases have been recorded in the literature The first case was reported by Morgagni in 1762, the diagnosis having been made at autopsy[1] In 1937 Hurwitz and Stevens[2] reviewed thirty four cases of agenesis of the lung Reports by De Weese and Howard,[3] in 1944, increased the incidence to forty-four In 1946 Smart[4] collected 104 reported cases Of these, he believed that only seventy-five had been correctly diagnosed, the remaining twenty nine cases were principally those of atelectasis and pulmonary fibrosis In 1955 Vallee[5] brought the incidence of agenesis of the lung up-to-date He presented a chart listing 120 cases 119 of which were taken from the literature He includes cases only of complete agenesis In 1950, however, both Morton et al[6] and Hochberg and the author,[7] in two different articles, reported two cases of proven lobar agenesis In these cases there was an agenesis of the right upper and middle lobes Curiously enough in each report the diagnosis was made in one case by exploratory thoracotomy and in the other at autopsy These cases are significant in that lobar agenesis of one lung, associated with an anatomic developmental abnormality of the bronchial tree, is so exceptionally rare a manifestation that it is not specifically mentioned in the literature

CLASSIFICATION

An outline of agenesis of the lung was first presented by Schneider[8] in 1912 Since that time his classification has been employed as a basis for nomenclature (1) *Agenesis of the lung*, in which there is a complete absence of the lung and bronchi, (2) *aplasia of the lung*, in which there is a rudimentary bronchus but no pulmonary alveolar tissue, (3) *hypoplasia of the lung*, in which pulmonary tissue is underdeveloped in whole or in part of a lung.

PATHOGENESIS

The etiology of this condition is still obscure Some of the various theories propounded in an attempt to offer an explanation for this developmental defect are herein mentioned The earlier theory of Meckel and Fleischman[9] explained this condition on a phylogenetic basis, comparing it with that in reptiles Gruenfeld and Gray[10] believe that the phylogenetic newness of the lung, in addition to the enormous growth that the lung undergoes in the embryo before its functional form is achieved, predisposes to the development of these abnormalities The most plausible theory is that proposed by Schwalbe[11] who postulates that agenesis of the lung is due to a developmental error of endogenous origin, it is the result of an inherently faulty germ plasm This explanation seems most rational, since other abnormalities of development are often associated in the same patient In this regard Wexels[12] states that nearly 50 per cent of patients with pulmonary agenesis have associated defects These anomalies are patent ductus arteriosus, patent foramen ovale, atresia ani, atresia of the esophagus, short bowel, atresia urogenitalis, exencephalia, horseshoe kidney, ventricular defect, hypoplasia of the face, harelip and cleft palate, bifid uvula, spina bifida, wedge-shaped

vertebrae hemivertebra deformed ribs accessory thumb closed foramen epiploica rudimentary atlas deformed external ear con

Warkany which were published in 1949, it was difficult to explain the development of these anomalies on other than a genetic basis These studies are briefly discussed on page 2

DIAGNOSIS

Symptoms may be entirely lacking or extremely variable The most frequent symptoms are dyspnea and tachycardia Stridor, wheezing and coughing are other frequent complaints When symptoms do occur they are not necessarily due to agenesis but may be the result of associated malformations and their complications According to Banyai and Peabody approximately 14 per cent of the reported cases were stillborn or died within the first week of life Some individuals have been known to go through life without restriction of physical activity or even being conscious of respiratory embarrassment. This abnormality is slightly more common in males than females

Physical examination reveals that the thorax is usually symmetric A respiratory lag of the affected side may be evident In some cases asymmetry of the chest exists with a definite decrease in size of the involved side The trachea is often found shifted toward the side of the absent lung The heart however is always displaced toward the affected side Breath sounds may be heard in the upper part of the defective side due to the herniation of the existing lung In lobar agenesis normal breath sounds are heard over the remaining ipse lateral lobe(s)

X ray examination of the chest demonstrates that the involved side casts a homogeneous dense shadow The intercostal spaces may be narrowed on the affected side with an elevation of the diaphragm The heart is shifted to the affected side away from the hypertrophied remaining lung The installation of iodized oil into the tracheobronchial tree and the use of angiocardiography are valuable procedures in diagnosis

A bronchoscopic examination proves important for the correct diagnosis and is indispensable for differential diagnosis since atelectasis constitutes the common condition with pneumonectomy state obstruction of the main bronchus (in children particular attention must be given to possible foreign body aspiration), diaphragmatic hernia eventration of the diaphragm pneumonia and pleural effusion

In view of the many clinical points of interest three cases of lobar agenesis which were treated by the author are presented According to the literature this anomaly is noted slightly more often on the left side than the right However, in the following three cases it was noted on the right

CASE REPORTS

CASE 1 A 5 pound 8 ounce newborn female infant was delivered spontaneously at term Immediately after birth the infant began to show signs of respiratory distress The accessory muscles of respiration were being used with slight retraction of the sternum and ribs on inspiration Breath sounds were depressed on the left side There were harsh crackling rales over the right side The apex impulse was not palpable The heart sounds were faint and of poor quality Roentgenographic examination demonstrated the heart and mediastinal contents drawn to the right of the midline together with non aeration of the upper half of the right lung field and apical portion of the left (Fig 1)

FIG 2 Anterior view of specimen showing an absence of right upper and middle lobes The space is occupied by the heart (Naeler o and Hoehberg [7])

Bronchoscopy revealed an absence of the right upper and middle lobe orifices Despite slight improvement following bronchoscopy respiratory distress continued and rales became audible bilaterally The infant became progressively worse and expired about forty eight hours after delivery

Postmortem Examination (Only the pertinent pathologic changes are included) The lungs had a combined weight of 34 gm The left lung showed the usual two lobes whereas the right lung consisted of one lobe which was considerably smaller than the left (Fig 2) The right lung showed the usual diaphragmatic surface and was of the usual diameter in its lower portion whereas the upper portion was small This lung was supplied by a single bronchus which resembled in its course the bronchus of a normal lower lobe (Fig 3) The left lung had the usual bronchi of its upper and lower lobes The anterior portion of all lobes was pale and well aerated However the greater part of the lung tissues was red and markedly consolidated Its aeration was poor

The esophagus consisted of two portions which were not connected with one another The upper portion formed a continuation of the pharynx as usual It measured little more than 1 cm in length and was somewhat wider than usual It had a blind end The lower portion originated from the bifurcation of the trachea as was described above The two portions were separated from one another by a distance of more than 1 cm From the bifurcation of the trachea a duct arose which formed a downward continuation of the trachea and represented the lower portion of the esophagus It opened into the stomach in the usual manner

The kidneys were fused with one another at their lower poles forming a horseshoe kidney which weighed 16 gm The fused portion was located at the level of the lower lumbar vertebrae The anterior vena cava ran along the anterior surface of the right kidney The fused kidney received several arteries from the aorta and the inner iliac arteries near the bifurcation The shape of the horseshoe kidney was asymmetric

Microscopic observations were as follows the alveoli of the lung were partially expanded and their lumina filled almost without exception with an exudate containing large numbers of polymorphonuclear leukocytes A similar exudate occupied part of the lumina of the bronchi

Death was attributed to bronchopneumonia and tracheal obstruction by mucus

FIG 4 Postero-anterior view of tomogram demonstrating extreme angulation of the right main bronchus with an absence of lipiodol in the upper lung field

As previously stated if difficulties arise in cases of agenesis they may be the result of associated anomalies In this case complications arose from esophageal atresia and tracheo esophageal fistula This resulted in aspiration of the esophageal contents into the broncho pulmonary system The reason for temporary improvement immediately following bronchoscopy is evident in that secretions were aspirated from the tracheobronchial tree The cause of death however was not pulmonary agenesis but the continual aspiration of material into the tracheobronchial tree

CASE II The patient a thirteen year old Negro boy was admitted to the hospital for a bronchoscopic examination because of a shadow in the chest The x ray findings were detected during a routine chest survey at school Upon admission the patient said that he coughed a little upon severe exertion Upon questioning the patient regarding the possibility of having aspirated a foreign body he stated that following the ingestion of some candy there was an associated coughing spell The family history was significant in that his mother died of a tumor of the chest Further questioning at a later date revealed a history of cough and expectoration of mucopurulent material and shortness of breath after exercise

The positive physical findings were increased dullness to percussion over the right chest anteriorly and posteriorly increased tactile and vocal fremitus over the right upper lobe posteriorly decreased breath sounds over the entire right chest and bronchial breathing over the entire left chest with hyper resonance upon percussion The point of maximum cardiac impulse was in the right fourth interspace A soft blowing systolic murmur over the aortic area was audible The remainder of the physical examination revealed no abnormality Admission x ray disclosed narrowing of the interspaces on the right and marked elevation of the right diaphragm with marked deviation of the trachea and mediastinum to the right

In view of the history the possibility of a non-opaque foreign body causing a bronchial block was considered Bronchoscopy revealed the left main bronchus and its immediate subdivisions to be normal The right main bronchus contained a moderate amount of mucopurulent secretion The orifices of the lower lobe were markedly stenosed and edematous The upper and middle lobe orifices were not visualized Both tomographic examination and lipiodol bronchograms disclosed extreme angulation of the right main bronchus posteriorly and substantiated the diagnosis of congenital absence of the bronchi to the upper and middle lobes on the right with unaerated non functioning parenchymal tissue (Fig 4)

It was decided that the patient was to have an exploratory thoracotomy with resection of the poorly functioning diseased remaining lung At operation the right upper and middle lobes were found to be absent. The superior segment of the lower lobe was emphysematous and overdeveloped The basilar segment was indurated and on palpation revealed numerous cystic areas Concurrently with the absence of the upper and middle lobes the arteries and veins of those lobes were also absent

Comment Exploratory thoracotomy proved the diagnosis of agenesis of the upper and middle lobes of the right lung and associated disease in the remaining lobe While the diagnosis of agenesis of lung was made by roentgenographic studies bronchoscopy and bronchography surgery was decided upon in view of the findings indicative of chronic disease in the remaining lobe.

A diagnostic feature usually found in such cases namely external symmetry of the chest with equal movements together with gross displacement of the trachea and mediastinum was evident in this case

Children with congenital absence of lung often come to the early attention of the pediatrician or the radiologist during an attack of

bronchopneumonia to which these patients fall easy prey Later in life, as in this case, individuals with this anomaly may complain of frequent colds, dyspnea on slight exertion, expectoration of blood streaked sputum, or even frank blood and attacks of stertorous, wheezing breathing

CASE III This seven year old Negro male was admitted to the hospital for a possible situs inversus The chief complaint consisted of pain in the epigastrium of two weeks' duration The pain was unrelated to ingestion of food or activity According to his mother, the patient's heart was on the right side This was discovered after admission to a hospital down South because of frequent attacks of severe upper respiratory infection The parents have also stated that an extensive work up proved the heart to be normal

Examination of the child revealed a well *nourished well developed, alert, cooperative* male who did not appear ill The thorax was normally formed and symmetric The trachea appeared to be deviated to the right of the midline On percussion there was slight dullness of the right upper half of the chest anteriorly Breath sounds were bronchial in nature over the same area There were no other evident abnormalities

Examination of the heart showed precordial pulsation in the right chest in the third and fourth intercostal spaces The point of maximum impulse was in the third right intercostal space 5 cm to the right of the mid sternal line There was regular sinus rhythm and sounds were of good quality, with a grade II systolic murmur best heard in the third intercostal space

X ray showed definite shift of the trachea and mediastinum to the right (Fig 5)

At bronchoscopy the only abnormality discernible was absence of the upper and middle lobe orifices Lipiodol studies substantiated the *bronchoscopic findings*

Esophagram demonstrated a shift of the trachea and mediastinum to the right The esophagus was in the midline (Fig 5)

The patient was discharged with the final diagnosis of congenital absence of the right upper and middle lobes

Comment At the time of discharge there was no evidence of any other congenital abnormalities The patient s chances for longevity are excellent

FIG 5 Postero-anterior view of x ray demonstrating shift of the trachea and mediastinum to the right. The left lung is emphysematous and extends beyond the midline to the right (Naclerio and Hochberg [7])

CONCLUSION

The author believes that congenital absence of one or more lobes of a lung occurs much more frequently than is generally suspected, and the possibility of pulmonary agenesis should be considered in the differential diagnosis of unusual lung conditions particularly in what appear to be persistent atelectasis

REFERENCES

absence of a lung diagnosed before death. *Radiology* 42 389 1944

4 SMART J Complete congenital agenesis of a lung *Quart J Med*, 15 125 139 1946

5 VALLEE, A R Agenesis of the lung *Am J Surg*, 89 90-100 1955

6 MORTON D R KLASSEN K P and BAXTER E H Lobar agenesis of the lung *J Thoracic Surg*, 20 665, 1950

7 NACLERIO E A and HOCHBERG L A Congenital absence of lung *New York State J Med*, 50 1267 1950

8 SCHNEIDER, B Quoted by Schwalbe P 11

9 MECHEL and FLEISCHMAN Quoted by Hurwitz, S and Stephens, H B 1

10 GRUENFELD G E and GRAY S H Malformations of the lung *Arch Path* 31 392 407 1941

(Aplasia) of the Lung Non tuberculous Diseases of the Chest, pp 805-868 Springfield Ill, 1954 Charles C Thomas

36

Atelectasis of the Newborn—A New Treatment

EMIL A NACLERIO M D New York New York

From the Thoracic Surgical Services of Harlem and Columbus Hospitals New York New York

THE lungs at birth are collapsed and relatively solid and will remain so until an adequate respiratory effort is made[1] The initial respirations expand a comparatively small area and full expansion is usually attained after several days of extrauterine life Under ordinary circumstances the limited degree of expansion during the first few days of life is adequate for gaseous exchange of carbon dioxide and oxygen through the capillaries in the alveolar walls and often offers no clinical clue to any respiratory involvement These areas of incomplete expansion are referred to as physiologic atelectasis The term atelectasis literally means failure to expand or imperfect expansion The condition assumes clinical importance only when there are associated symptoms

PATHOGENSIS

Wilson and Farber[2] have clearly shown that the cohesion of the moist surfaces of the air passages in collapsed and airless lungs offers a considerable obstacle to the entrance of air They emphasize that a relatively great force is required to overcome this cohesion and to separate the bronchial and alveolar walls during the initial expansion of an atelectatic lung For a variable period after birth especially vigorous inspirations must be maintained until the atelectasis is finally overcome

These authors[2] state that when the initial resistance of the atelectatic lungs to expansion exists in association with other factors the state of atelectasis will be maintained to a pathologic extent The other factors which prevent adequate lung expansion may be listed as follows (1) An imperfectly developed or an injured respiratory center which not responding to normal stimuli fails to bring about repeated and sufficiently vigorous respiratory efforts (2) an imperfectly developed thoracic mechanism in which the contraction of the intercostal muscles and the bony resistance of the thorax do not furnish an effective vis a tergo for the efficient action of the diaphragm (3) bronchial obstruction due to aspiration of the contents of the amniotic sac mucus or blood Wilson and Farber[2] have found that rarely is bronchial obstruction in itself a complete cause of extensive and persistent obstruction

INCIDENCE

The incidence of atelectasis in the newborn is very low Yet it is of such importance that its persistence may lead to death In a study of 13 515 live births Clerf[3] found atelectasis in 157 cases Of these ninety five infants were premature the remaining sixty two were full term babies Alberton states that two out of one hundred newborn babies will not breathe properly at birth He further adds that some will live or die depending upon the resuscitative measures instituted by the physician Numerous observers believe that the percentage of asphyxia neonatorum is increasing because of the demand for comfort and convenience on the part of the woman in labor[4]

CLINICAL PICTURE

Atelectasis is most frequently observed in the premature or delicate and feeble infant in whom the normal respiratory excursions are limited Whenever congenital atelectasis exists the possibility of pulmonary hyaline membranes must be considered especially in infants delivered by cesarean section and in premature babies Physiologic atelectasis however may be demonstrable in the premature infant as long as six weeks and usually presents a problem in differential diagnosis

lacking, while more severe cases usually manifest signs of respiratory distress The respirations are shallow and rapid, with occasional periods of apnea at first The respiratory movements are mostly abdominal with almost no apparent thoracic component Close observations of the respiratory pattern in the newborn often reveals important information and the type of respiration may be of prognostic significance

Certain respiratory patterns are highly suggestive of an impediment to respiratory activity, while others are specific for respiratory insufficiency The presence of cyanosis usually indicates the severity of the condition In addition, the depth and duration of the cyanosis

administered In some cases the only manifestations of atelectasis may be the presence of intermittent attacks of cyanosis

Physical examination may reveal signs of

involved area is massive The presence of rales on auscultation is rather inconstant X-rays of the chest provide the best means for demonstrating the extent of the atelectasis The x ray findings in conjunction with the clinical picture aid immeasurably in making the diagnosis Although the clinical picture is usually established soon after birth, it may be delayed for as long as several days

DIFFERENTIAL DIAGNOSIS

Atelectasis frequently presents serious problems in differential diagnosis, since not infrequently it is a constant accompaniment of asphyxia neonatorum The conditions to be considered are namely, cerebral hemorrhage, pharyngeal and laryngeal paralysis, associated with massive cerebral hemorrhage, congenital heart disease, an enlarged thymus, aspiration, diaphragmatic hernia, tracheo-esophageal fistula, esophageal atresia, respiratory obstruction, congenital atresia of the postnasal orifices, congenital anomalies of the lung, pneumothorax and pneumomediastinum In addition, Morgan and Brown[8] emphasize that every case of cyanosis should be evaluated from the standpoint of parturition as well as that of disease in the infant In the former group the commonest sources of cyanosis are those conditions causing compression of the cord, e g, prolapse, knot formation and twisting, placental abnormality, i e, premature separation and low implantation, prolonged or difficult labor, delay in the delivery of an after-coming head, severe toxemias and the use of analgesics in labor

PROGNOSIS

The prognosis depends upon the establishment of adequate expansion of the lung and upon the avoidance of intercurrent infection. In severe cases, if the infants survive, crippling sequelae such as permanent, irreparable damage to the central nervous system may result, causing mental inferiority, diminished ability to learn, mental dullness and retardation in later life[47]

Experiences during the past decade with thirty-eight newborn infants manifesting respiratory distress, fourteen of whom were bronchoscoped by the author because of obstructive breathing, proved this latter finding Two of these infants later developed mental retardation, one having an associated cerebral palsy

Small areas of atelectasis, even though relatively asymptomatic, should be eliminated whenever detected because of the probability of inflammation and the subsequent formation of chronic disease

MANAGEMENT

In order to initiate respiration the newborn infant must be able to overcome a resistance to expansion of the lungs, which is often as high as 30 cm of water[49] Because of the cohesive tension effect in collapsed lungs, it is easy to understand why in many instances the newborn baby's first breath is much the hardest

The subject of treatment of atelectasis and asphyxia neonatorum has been dealt with in numerous articles and standard textbooks and there is no need to repeat many details Hence, only pertinent data as they refer to the prevention and treatment of atelectasis will be briefly presented

The incidence of asphyxia and atelectasis may be minimized by closer attention to certain factors, namely, antenatal care, mater-

nal afflictions, obstetric complications and premature labor and delivery

After overcoming the initial asphyxia, the treatment consists (1) of frequent external stimulation of the skin to induce crying, this favors further expansion of the lungs by the deeper respiratory efforts, and (2) in the administration of a high oxygen content, approximately 40 to 50 per cent, since there is a diminished area of air bearing pulmonary tissue

Aspiration of gastric contents for babies born by cesarean section or by difficult vaginal delivery will reduce appreciably the chances of aspiration of foreign material into the lungs This can be done simply by inserting a tube into the stomach and should be performed whenever large amounts of fluid pour out of an infant Aspiration of gastric contents in these situations constitutes an important prophylactic procedure

Nasopharyngeal, tracheal and bronchoscopic aspiration should be used whenever there is any evidence of obstruction Bronchoscopy is a useful but often neglected procedure It is without harm when performed by the experienced The author has found in a number of cases, even with the removal of only small amounts of material from the trachea and bronchi, a most immediate effect In a few cases it has been life saving Holinger[10] points out that obstruction due to excessive secretions not relieved by simple tracheal aspirations generally indicates a pharyngeal paralysis or a congenital esophageal anomaly such as congenital esophageal stenosis or atresia with or without a tracheo esophageal fistula While it is not the scope of this section to discuss the details of infant bronchoscopy, it should be mentioned that in a few instances bronchoscopic aspiration has proven ineffective In these cases the administration of oxygen through the bronchoscope caused an immediate replacement of the cyanosis by a bright pink color However, upon removal of the bronchoscope the infant would again become cyanotic In two infants in marked respiratory distress and anoxia, an attempt at bronchoscopy resulted in apnea in spite of most gentle contact

Most methods of artificial manual resuscitation in the newborn attempt to add to the expansion of the thorax by compression of the chest and abdomen or flexion of the body Autopsy studies reveal many cases with intracranial hemorrhage, rib fractures, muscular injury, traumatic emphysema and visceral lacerations incident to manual maneuvers The importance of gentleness is obvious Technics which attempt to accomplish the same are the "rocking" or "see saw" method,[11] in the weight of the abdominal organs assists in amplifying the diaphragmatic excursions

The majority of the methods employed in the treatment of atelectasis operate through changing pressures applied to the upper air passages These pressures are presumed to open up the lungs Mouth to mouth artificial respiration probably represents the oldest method of insufflation Intermittent positive pressure, administered with a Kreiselman infant resuscitator, can deliver controlled pressures by face mask at rhythms determined by the operator but cycled to the infant If positive pressures are used initially to expand alveoli, they should approach 20 cm of water pressure The range of safety is narrow, 10-20 cm of water pressure is usually necessary for initial expansion of alveoli, while 25 cm of water pressure or over may cause alveolar rupture and impede circulation[12] Gross pulmonary damage has occurred at even lower pressures[13,14] For these reasons, present day resuscitators operate at low pressures Smith[9] has clearly established that the baby's own respiratory efforts are far greater than the level of safety for positive pressure machines Day[15] emphasizes that it is not only the pressure that is important but also the time of exposure and the amount of expandable lung tissue available The apparatus suggested by Day is characterized by application, in a face mask, of very short bursts of high pressure This pressure is effective in distending the tracheobronchial tree but is not sustained long enough for alveolar pressure to rise much[17] During the rapid inflow phase there is a large pressure drop through the air passages due to resistance, if mask pressure were held long enough for flow to be completed, alveolar pressure would equal mask pressure and alveolar damage would probably occur The shortness of the interval of high pressure prevents this result Whittenberger[17] states that theoretically this method should be effective in opening up a collapsed lung, clinical experience with apparatuses based on this principle is awaited with interest Cherniack and Boyd,[18] using a resuscitator operating on these principles, were successful in reviving the apneic or markedly

depressed newborn infant after other resuscitative measures had failed in six of seven cases They mention that a prolonged clinical trial of high pressures of short duration in the resuscitation of the apneic newborn infant is needed in order to establish the efficacy of the method

Alternating positive negative pressure methods differ from other methods of intermittent pressure only in that the negative phase goes lower than 760 mm of mercury Commonly included in this category are the 'suck and blow' machines The positive pressure air lock chamber, developed by Bloxom, has caused much controversy [19] Whittenberger states that no one has presented evidence that this device is significantly superior to any other incubator [17] The oxygen "air lock" developed by Bloxom and the high pressure device suggested by Day are two methods which have created particular interest in recent years

Intermittent negative pressure may be accomplished in an apparatus such as the Drinker Infant respirator The infant's body is enclosed in the chamber with the head outside The Drinker Infant resuscitator pro-

the infant's respiratory pattern It has been emphasized with good reason that the pressure of the collar might be injurious in cases of intracranial hemorrhage which so often underlies a serious grade of asphyxia [20]

Electrophrenic artificial respiration may be accomplished by intermittently stimulating the phrenic nerves Twelve infants treated for atelectasis resulted in four survivals, all weighed more than 3½ pounds [21] These authors were not able to demonstrate that atelectasis in premature infants was affected by electrophrenic respiration However, x rays taken a few hours after birth of full term infants who survived demonstrated more air on the treated side This method of treatment is still considered to be in the developmental stage

Open thoracotomy and positive pressure insufflation proved successful in the treatment of three cases of atelectasis in the newborn [22] When positive pressure was applied the lung protruded and when pressure of 14 cm of water was applied, the hilar portions of the lung expanded with an audible crackling noise Gentle massage of the collapsed lung facilitated its expansion and the appearance of the lung changed strikingly Recently Williams has successfully treated one case by this method [8] This procedure, while not a simple means for the treatment of atelectasis may be the one of choice in selected cases

NEW METHOD OF TREATMENT

The use of sternal traction proves most effective in the treatment of persistent ate-

excavatum in that the deformity is evidenced by a sharp posterior bowing of the body of the sternum, deepest just above the junction with the xyphoid

The rationale of this method of treatment is understood when it is realized that even in the healthy robust infant respiration is carried out almost entirely by the diaphragm, while the thoracic wall acts more or less as a fixed point from which the diaphragm can work [24] Because of the weakness of the cartilages and ribs in the newborn, a certain amount of paradoxical respiration is usually evident which diminishes the efficiency of respiration Wilson and Farber[4] have shown that in certain cases, especially in premature infants the thorax may be so poorly developed that it is not able to furnish an effective vis a tergo for the efficient action of the diaphragm In addition, these authors were not able to demonstrate any evidence of tracheal or bronchial obstruction in these infants Thus, in these specific cases the use of sternal traction is obviously the one of choice

traction

C R, a female infant, who weighed 5 pounds 6 ounces, and was delivered by cesarean section cried spontaneously at birth Because of respiratory distress and cyanosis, the infant was placed in an incubator after the initial asphyxia was treated Bronchoscopy was requested because of the absence of improvement and evidence by x ray of bilateral atelectasis (Fig 1) Approximately five hours after birth, when the author first examined the infant, it was apparent that the newborn infant was in extremis In addition, there was slight inspiratory retraction of the lower sternal region with a minimum of thoracic cage

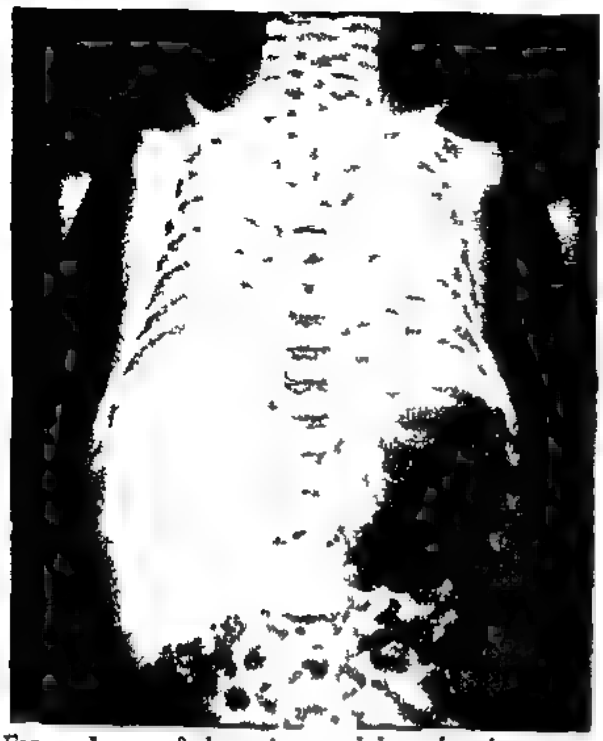

FIG 1 X ray of chest showing bilateral atelectasis in a newborn infant taken five hours after delivery by cesarean section Infant treated by sternal traction



A

B

expansion Bronchoscopy resulted in apnea as soon as the larynx was manipulated For this reason, it was not performed Further observation of the infant revealed a noticeable increase in the inspiratory retraction, creating a paradoxical respiration This type of abnormal respiration, especially in infants with extensive atelectasis in both lungs, will invariably prove fatal due to ensuing anoxia With the knowledge that the diaphragm can work efficiently only when it contracts from a fixed point and that it plays the most active role in ventilatory function, especially in the newborn, it was obvious that the sternum should be stabilized A No 2 silk suture was placed through the lower end of the sternum A fixed traction resulted when the silk was secured to a cord traversing the incubator (Fig 2 A and B) The infant's condition improved immediately. The cyanosis disappeared during the following three hours An x ray (Fig 3) taken twelve hours later clearly shows the improved aeration Traction was left in place for eighteen hours, at the end of this time the suture was removed The child was much better and the hospital course was uneventful This child has been in excellent health ever since

A review of the literature later revealed that the traction method of sternal stabilization for atelectasis in the newborn has been recently reported Love and Tillery[18] patterned the treatment after that found effective for a somewhat similar physiologic disturbance observed in the adult with "steering wheel" fractures of the sternum Traction was applied through the medium of small rubber bands attaching the handle of a towel clip which grasped the sternum to the top of the incubator.

FIG. 3. X-ray of chest taken twelve hours following treatment by sternal traction, showing a complete disappearance of the bilateral atelectasis.

Michelson[6] treated three cases successfully with sternal traction. In the first case the xyphoid was grasped with an Allis clamp through a skin incision and suspended with two rubber bands. In the other two cases a suture was forced through the xyphoid, a method very similar to the one first used by the author.

The author routinely uses only a number 2-0 silk and suspends it from a relatively fixed point. The suture should include a portion of the sternum or at least the sternal fascia. No local anesthesia is necessary. There have been no complications associated with the use of this technic.

The use of sternal traction is of value also in newborn infants without atelectasis who manifest signs of impending asphyxia and costosternal traction. Death in these cases is due to a respiratory insufficiency incident to the paradoxical respiration. The following case demonstrates the applicability of sternal traction in this situation.

Female twins were delivered by cesarean section because of fetal distress in one infant. The period of gestation was eight months. Routine gastric aspiration in one infant



FIG. 4. (*Top*) Lateral view showing costosternal retraction in moderate inspiration. (*Bottom*) Note absence of retraction on inspiration since sternum has been fixated. See Fig. 2.

weighing 4 pounds 4 ounces proved difficult in that the tube could not be passed into the stomach. An esophagoscopy was requested and approximately sixteen hours after birth the author saw the baby with the idea of performing the procedure. At that time there were signs of respiratory difficulty—duskiness of the skin, circumoral pallor, increased respiratory rate and retraction of the costosternal and lower thoracic regions, becoming more exaggerated with increased respiratory effort. Chest x-rays showed no evidence of any atelectasis or other lung abnormality (Fig. 4, top). A review of the lipiodol swallow revealed passage of the oil into the stomach despite difficulty of the infant to take fluids. In view of the findings sternal traction was instituted (Fig. 4, bottom). Respiratory difficulties abated promptly. Following this procedure a further attempt by the pediatrician to insert the polyethylene catheter into the stomach proved effective. This was used for feeding

purposes The following morning the traction was untied and the infant was taken to the x ray department to have lipiodol inserted into the stomach through the tube A return of the signs of respiratory distress resulted a few minutes after the removal of traction Upon returning the infant to the incubator, the sternal traction was again fixed This resulted in immediate amelioration of respiratory difficulties Sixteen hours later traction was removed and the baby's subsequent course was uneventful

SUMMARY AND CONCLUSIONS

1 Pertinent data relative to the clinical aspects of atelectasis of the newborn are presented

2 Representative cases personally treated by the author with the use of sternal traction have been briefly discussed

3 The use of sternal traction for the treatment of persistent atelectasis in infants who manifest signs of costosternal traction is advocated as a new method in the treatment of this condition Sternal traction will also prove of value in the treatment of newborn infants without atelectasis who manifest signs of impending asphyxia and costosternal retraction The latter group of infants, if left untreated, will die of anoxia because of the inefficient respiratory exchange of oxygen and carbon-dioxide despite the fact that the lungs are completely expanded

REFERENCES

1 FARBER S and WILSON J L. Atelectasis of newborn A study and critical review *Am J Dis Child* 46 572 589 1933
2 CLERF L. H PUTNEY F J and O KEEFE J J Pre-oral endoscopy *Arch Otol* 52 288 319 1950
3 ATHERTON H E Resuscitation of asphyxiated newborn infant *J Tennessee M A* 40 372 375 1947
4 BELL, L H The role of bronchoscopy in resuscitation of asphyxia of the newborn *Eye Ear Nose & Throat Monthly* 31 601 1952
5 MORGAN E A and BROWN A Cyanosis of the newborn *J A M A* 105 1085–1088 1935
6 TYSON R M Immediate care of newborn in relation to neonatal mortality *J A M A* 124 351 356 1944
7 DARKE, R A Late effects of severe asphyxia neonatorum preliminary note *J Pediat* 24 148 158 1944
8 WILSON J L. and FARBER, S Pathogenesis of atelectasis of newborn *Am J Dis Child* 46 590 1933
9 SMITH C A Physiology of Newborn Infant 2nd ed Springfield Ill 1951 Charles C Thomas
10 HOLINGER P H Role of the laryngologist in resuscitation of the newborn infant *J A M A* 159 1338 1955
11 EVE F C Resuscitation of the drowned today *J A M A* 124 964 1944
12 MILLEN R S and DAVIES J See-saw resuscitator for the treatment of asphyxia in the newborn *Am J Obst & Gynec* 52 508 1946.
13 BRUNS P D Resuscitation of the newborn *Pediatric Clin North America* 1 845 1954
14 MURPHY D P and BAUER J T Lungs after treatment of asphyxia neonatorum in Drinker respirator *Am J Dis Child* 45 1196 1933
15 FLAGG P J Treatment of asphyxia in newborn *J A M A* 91 788 1928
16 DAY R L GOODFELLOW A M APGAR, V and BECK G J Pressure-time relations in safe correction of atelectasis in an infant lungs *Pediatrics* 10 593 1953
17 WHITTENBERGER J L. Artificial respiration and its clinical applications *Seminar* 17 20 1955
18 CHERNIACK, M D and BOYD A Resuscitation of the newborn infant *Pediatrics* 14 49 1954
19 BLOXOM A Asphyxia neonatorum new method of resuscitation *J A M A* 146 1120 1951
20 STONE E L The Newborn Infant—A Manual of Obstetrical Pediatrics p 34 Philadelphia 1945 Lea & Febiger
21 DAY L. R and SANFORD H N Electrophrenic artificial respiration *Am J Dis Child* 89 553 1955
22 BERGLUND E and EDER W P Surgical approach to atelectasis of newborn infant preliminary report *Surgery* 29 127 1951
23 WILLIAMS M Personal communication
24 MILLER H C. and BEHRLE, F C. Changing patterns of respiration in newborn infants *Pediatrics* 12 141 149 1953
25 LOVE W G and TILLERY B New treatment for atelectasis of the newborn *Am J Dis Child* 86 423 1953
26 MICHELSON R P Treatment of atelectasis in the newborn by sternal traction *Laryngoscope* 63 379 1953

Pulmonary Arteriovenous Aneurysm

JAN W. MURE, M.D., Oslo, Norway

ARTERIOVENOUS aneurysm or fistula of the lung is a congenital shunt between arteries and veins in the lung. This abnormal vascular communication has been designated by a variety of names. Similar terms have been used to describe different pathologic lesions and conversely a single pathologic condition has been designated by different names. The lesion to be mentioned in this article appears on the basis of the pathologic picture to be a real arteriovenous aneurysm or fistula. Hemangiomas of the lung are neoplasms with a different clinical and pathologic aspect[1] and the term hemangioma or cavernous hemangioma ought to be reserved merely for these tumors. Lindgren[17] proposes the term aneurysm for congenital lesions and fistula for the rare traumatic shunts. This seems to be more and more generally accepted.

These lesions have attained much interest since 1939 when Smith and Horton[18] made the first clinical diagnosis of an arteriovenous aneurysm in the lung. In 1939 Yater et al.[19] and Quemerch[20] reviewed the literature and in 1953 the author[21] collected seventy-nine cases from the literature including a new case. At present the number has already surpassed 100.

The true incidence of the anomaly is difficult to evaluate since small aneurysms in the lung may so easily escape diagnosis both clinically and in routine autopsy studies. It seems to be relatively uncommon but cannot be extremely rare in view of the fact that more than 100 cases have been recorded during the last fifteen years.

Although the diagnosis is frequently made in the third and fourth decade, arteriovenous aneurysm of the lung has been diagnosed in children and even in the newborn[14] and is probably congenital in origin. The male-female ratio is about 3:2. In more than half of the cases cutaneous telangiectasis could be demonstrated and in many telangiectasis was present in near relatives of the patient. Goldman[12] supposes that arteriovenous aneurysm of the lung is a manifestation of hereditary hemorrhagic telangiectasis (Rendu-Osler-Weber's disease, Goldstein's heredofamilial angiomatosis).[22] In many patients this is not obvious but typical cases of Rendu-Osler-Weber's disease may have pulmonary arteriovenous aneurysm. In such cases the aneurysm may easily be overlooked when the cyanosis is masked by anemia.[23] Goldman[12] and Ackerman[24] and Glenn et al.[10] have observed the lesion in siblings and Tobin and Wilder[11] have reported the occurrence of arteriovenous aneurysm in a father and son.

Pathologic Anatomy. In the majority of the cases the shunt is from a pulmonary artery to a pulmonary vein. One or more branches from the artery enter the aneurysmal sac which is drained by a greatly enlarged and often tortuous vein (Figs. 1 and 2). The aneurysmal channel is often sinuous and may be partly filled with clots. The wall is often paper thin, built up by hyalinized fibrous tissue, elastic fibers and remnants of smooth muscle cells. The intima may be unevenly thickened, partly covered by mural thrombi and may show atheromatous lesions which may be calcified. Small compression atelectases and cell infiltration are commonly seen in the surrounding pulmonary tissue.[14] The size may vary from small pinpoint sized telangiectasis to huge tubular or saccular multilobulated aneurysms occupying the greater part of a lobe. Nearly half of the patients have two or more aneurysms large enough to be diagnosed clinically. Estimated from the records where the localization is described in detail they may be found in any part of the lungs but they seem to be most frequently seated in the middle and lower lobes of the lungs. Involvement of the thoracic wall by the aneurysm is rare[22,23] but may greatly complicate the surgical intervention. Brink[25] reports an otherwise typical case in which no aneurysm could be seen neither on the recent angiograms nor by angiographic examination. He supposes that this may be due to multiple

purposes The following morning the traction was untied and the infant was taken to the x ray department to have lipiodol inserted into the stomach through the tube A return of the signs of respiratory distress resulted a few minutes after the removal of traction Upon returning the infant to the incubator, the sternal traction was again fixed This resulted in immediate amelioration of respiratory difficulties Sixteen hours later traction was removed and the baby s subsequent course was uneventful

SUMMARY AND CONCLUSIONS

1 Pertinent data relative to the clinical aspects of atelectasis of the newborn are presented

2 Representative cases personally tr by the author with the use of sternal tr have been briefly discussed

3 The use of sternal traction for the tr ment of persistent atelectasis in infants w manifest signs of costosternal traction advocated as a new method in the treatment this condition Sternal traction will also prov of value in the treatment of newborn infants without atelectasis who manifest signs of impending asphyxia and costosternal retraction The latter group of infants if left un treated, will die of anoxia because of the inefficient respiratory exchange of oxygen and carbon dioxide despite the fact that the lungs are completely expanded

REFERENCES

1 FARBER S and WILSON J L Atelectasis of new born A study and critical review *Am J Dis Child* 46 572 589 1933

2 CLERF L H PUTNEY F J and O KEEFE J J Pre-oral endoscopy *Arch Otol* 52 288 319 1950

3 ATHERTON H E Resuscitation of asphyxiated newborn infant *J Tennessee M A* 40 372 375 1947

4 BELL, L H The role of bronchoscopy in resuscitation of asphyxia of the newborn *Eye Ear, Nose & Throat Monthly* 31 601 1952

5 MORGAN E A and BROWN A Cyanosis of the new born *J A M A* 105 1085–1088 1935

6 TYSON R M Immediate care of newborn in relation to neonatal mortality *J A M A* 124 351 356 1944

7 DARKE R A Late effects of severe asphyxia neonatorum preliminary note *J Pediat* 24 148 158 1944

8 WILSON J L and FARBER S Pathogenesis of atelectasis of newborn *Am J Dis Child* 46 590 1933

9 SMITH C A Physiology of Newborn Infant 2nd ed Springfield Ill 1951 Charles C Thomas

10 HOLINGER P H Role of the laryngologist in resuscitation of the newborn infant *J A M A* 159 1338 1955

11 EVE F C Resuscitation of the drowned today *J A M A* 124 964 1944

12 MILLEN R S and DAVIES J See-saw resuscitator for the treatment of asphyxia in the newborn *Am J Obst & Gynec* 52 508 1946

13 BRUNN P D Resuscitation of the newborn *Pediatric Clin North America* 1 845 1954

14 MURPHY D P and BAUER J T Lungs after treatment of asphyxia neonatorum in Drinker respirator *Am J Dis Child* 45 1196 1933

15 FLAGG P J Treatment of asphyxia in newborn *J A M A* 91 788 1928

16 DAY R L GOODFELLOW A M APGAR, V and BECK G J Pressure-time relations in safe correction of atelectasis in animal lungs *Pediatrics* 10 593 1953

17 WHITTENBERGER J L Artificial respiration and its clinical applications *Seminar* 17 20, 1955

18 CHERNIACK M D and BOYD A Resuscitation of the newborn infant *Pediatrics* 14 49 1954

19 BLOXOM A Asphyxia neonatorum new method of resuscitation *J A M A* 146 1120 1951

20 STONE E L The Newborn Infant—A Manual of Obstetrical Pediatrics, p 34 Philadelphia 1945 Lea & Febiger

21 DAY L R and SANFORD H N Electrophrenic artificial respiration *Am J Dis Child* 89 553 1955

22 BERGLUND E and EDER, W P Surgical approach to atelectasis of newborn infant preliminary report *Surgery* 29 127 1951

23 WILLIAMS M Personal communication

24 MILLER H C and HEIRLE F C Changing patterns of respiration in newborn infants *Pediatrics* 12 141 149 1953

25 LOVE W G and TILLERY B New treatment for atelectasis of the newborn *Am J Dis Child* 86 423 1953

26 MICHELSON R P Treatment of atelectasis in the newborn by sternal traction *Laryngoscope* 63 379 1953

Pulmonary Arteriovenous Aneurysm

JAN W MURI, M D, Oslo, Norway

ARTERIOVENOUS aneurysm or fistula of the lung is a congenital shunt between arteries and veins in the lung This abnormal vascular communication has been designated by a variety of names Similar terms have been used to describe different pathologic lesions and, conversely, a single pathologic condition has been designated by different names The lesion to be mentioned in this article appears on the basis of the pathologic picture, to be a real arteriovenous aneurysm or fistula [1] Hemangiomas of the lung are neoplasms with a different clinical and pathologic aspect,[2] and the term hemangioma or cavernous hemangioma ought to be reserved merely for these tumors Lindgren[3] proposes the term aneurysm for congenital lesions and fistula for the rare traumatic shunts. This seems to be more and more generally accepted

These lesions have attained much interest since 1939 when Smith and Horton[4] made the first clinical diagnosis of an arteriovenous aneurysm in the lung In 1949 Yater et al[5] and Quemerch[6] reviewed the literature, and in 1953 the author[7] collected seventy nine cases from the literature including a new case At present the number has already surpassed 100

The true incidence of the anomaly is difficult to evaluate since small aneurysms in the lung may so easily escape diagnosis, both clinically and in routine autopsy studies It seems to be relatively uncommon, but cannot be extremely rare in view of the fact that more than 100 cases have been recorded during the last fifteen years

Although the diagnosis is frequently made in the third and fourth decade, arteriovenous aneurysm of the lung has been diagnosed in children and even in the newborn,[8] and is probably congenital in origin The male female ratio is about 3 2 In more than half of the cases cutaneous telangiectasis could be demonstrated, and in many telangiectasis was present in near relatives of the patient Goldman[9] supposes that arteriovenous aneurysm of the lung is a manifestation of hereditary hemorrhagic telangiectasis (Rendu Osler-Weber's disease, Goldstein's heredofamilial angiomatosis) [10] In many patients this is not obvious, but typical cases of Rendu Osler-Weber's disease may have pulmonary arteriovenous aneurysm In such cases the aneurysm may easily be overlooked when the cyanosis is masked by anemia [11,12] Goldman,[12] Moyer and Ackerman[13] and Glenn et al [14] have observed the lesion in siblings, and Tobin and Wilder[15] have reported the occurrence of arteriovenous aneurysm in a father and son

Pathologic Anatomy In the majority of the cases the shunt is from a pulmonary artery to a pulmonary vein One or more branches from the artery enter the aneurysmal sac which is drained by a greatly enlarged and often tortuous vein (Figs 1 and 2) The aneurysmal channel is often sinuous and may be partly filled with clots The wall is often paper thin, built up by hyalinized fibrous tissue, elastic fibers and remnants of smooth muscle cells The intima may be unevenly thickened, partly covered by mural thrombi and may show atheromatous lesions which may be calcified Small compression atelectases and cell infiltration are commonly seen in the surrounding pulmonary tissue [16] The size may vary from small pinpoint sized telangiectasis to huge tubular or saccular multilobulated aneurysms occupying the greater part of a lobe Nearly half of the patients have two or more aneurysms large enough to be diagnosed clinically Estimated from the records where the localization is described in detail, they may be found in any part of the lungs, but they seem to be most frequently seated in the middle and lower lobes of the lungs Involvement of the thoracic wall by the aneurysm is rare,[17,18] but may greatly complicate the surgical intervention Brink[18] reports an otherwise typical case in which no aneurysm could be seen, neither on the roentgenograms nor by angiographic examination He supposes that this may be due to multiple

purposes The following morning the traction was untied and the infant was taken to the x ray department to have lipiodol inserted into the stomach through the tube A return of the signs of respiratory distress resulted a few minutes after the removal of traction Upon returning the infant to the incubator, the sternal traction was again fixed This resulted in immediate amelioration of respiratory difficulties Sixteen hours later traction was removed and the baby's subsequent course was uneventful

SUMMARY AND CONCLUSIONS

1 Pertinent data relative to the clinical aspects of atelectasis of the newborn are presented

2 Representative cases personally treated by the author with the use of sternal traction have been briefly discussed

3 The use of sternal traction for the treatment of persistent atelectasis in infants who manifest signs of costosternal traction is advocated as a new method in the treatment of this condition Sternal traction will also prove of value in the treatment of newborn infants without atelectasis who manifest signs of impending asphyxia and costosternal retraction The latter group of infants if left untreated, will die of anoxia because of the inefficient respiratory exchange of oxygen and carbon dioxide despite the fact that the lungs are completely expanded

REFERENCES

1 Farber S and Wilson J L Atelectasis of newborn A study and critical review *Am J Dis Child* 46 572 589 1933

2 Clerf L H Putney F J and O Keefe J J Pre-oral endoscopy *Arch Otol* 52 288 319 1950

3 Atherton H E Resuscitation of asphyxiated newborn infant *J Tennessee M A* 40 372 375 1947

4 Bell, L H The role of bronchoscopy in resuscitation of asphyxia of the newborn *Eye Ear Nose & Throat Monthly* 31 601 1952

5 Morgan E A and Brown A Cyanosis of the newborn *J A M A* 105 1085–1088 1935

6 Tyson R M Immediate care of newborn in relation to neonatal mortality *J A M A* 124 351 356 1944

7 Darke R A Late effects of severe asphyxia neonatorum preliminary note *J Pediat* 24 148 158 1944

8 Wilson J L and Farber S Pathogenesis of atelectasis of newborn *Am J Dis Child* 46 590, 1933

9 Smith C A Physiology of Newborn Infant 2nd ed Springfield Ill 1951 Charles C Thomas

10 Holinger P H Role of the laryngologist in resuscitation of the newborn infant *J A M A* 159 1338 1955

11 Eve F C Resuscitation of the drowned today *J A M A* 124 964 1944

12 Millen R S and Davies J See-saw resuscitator for the treatment of asphyxia in the newborn *Am J Obst & Gynec* 52 508 1946

13 Bruns P D Resuscitation of the newborn *Pediatric Clin North America* 1 845 1954

14 Murphy D P and Bauer J T Lungs after treatment of asphyxia neonatorum in Drinker respirator *Am J Dis Child* 45 1196 1933

15 Flagg P J Treatment of asphyxia in newborn *J A M A* 91 788 1928

16 Day R L Goodfellow A M Apgar, V and Beck G J Pressure time relations in safe correction of atelectasis in animal lungs *Ped atr cs* 10 593 1953

17 Whittenberger J L Artificial respiration and its clinical applications. *Seminar* 17 28 1955

18 Cherniack, M D and Boyd A Resuscitation of the newborn infant *Pediatrics* 14 49 1954

19 Bloxom A Asphyxia neonatorum new method of resuscitation *J A M A* 146 1120 1951

20 Stone E L The Newborn Infant—A Manual of Obstetrical Pediatrics, p 34 Philadelphia 1945 Lea & Febiger

21 Day L R and Sanford H N Electrophrenic artificial respiration *Am J Dis Child* 89 533 1955

22 Berglund E and Eder, W P Surgical approach to atelectasis of newborn infant preliminary report *Surgery* 29 127 1951

23 Williams M Personal communication

24 Miller H C and Behrle, F C Changing patterns of respiration in newborn infants *Ped atrics* 12 141 149 1953

25 Love, W G and Tillery H New treatment for atelectasis of the newborn *Am J Dis Child* 86 423 1953

26 Michelson R P Treatment of atelectasis in the newborn by sternal traction. *Laryngoscope* 63 379 1953

mon occurrence in cases with marked cyanosis, probably caused by local anoxemia or small air emboli in the central nervous system [55, 57]. Chest pain, usually sharp in nature, radiating and transient, is a major complaint in some patients. Hemoptysis is frequently the symp-

TABLE 1

Physical Findings	Present	Absent or Not Mentioned
Cyanosis and/or clubbing	91	26
Telangiectasis	62	53
Murmur	61	56

tom that brings the patients to seek medical advice, and may be the terminal event following rupture of the aneurysm into a bronchus. The physical findings in 117 reported cases is summarized in Table 1.

Cyanosis and clubbing of the fingers and toes are the most conspicuous objective signs. The cyanosis may reach extreme degrees depending on the arterial oxygen unsaturation and the hemoglobin value. When a mean of about 5 gm. of hemoglobin per 100 ml. of blood is present in reduced form in the capillaries cyanosis is visible. In a case reported by Friedlich et al.[15] only 68 per cent of the arterial blood was saturated with oxygen. With a hemoglobin content of 25.3 gm., this means about 8 gm. reduced hemoglobin in the arterial end of the capillary loop.

Telangiectasis in the skin or the visible mucous membranes is found in more than half of the cases and is a valuable clue to the diagnosis. Recurrent epistaxes are frequently reported by these patients.

A murmur, sometimes continuous but more frequently systolic and louder in deep inspiration, is heard in about half of the cases over the site of the aneurysm, and sometimes a thrill can be felt.[70, 95]

The heart sounds, which is important, are normal unless unrelated lesions are present. The blood pressure is not elevated. The liver and spleen are not essentially enlarged and edema is not present.

In some cases cyanosis and clubbing are not present. This may be due to the size of the shunt. Cyanosis will not be visible until about 20 per cent of the blood passes through the shunt, dependent to a certain degree on individual properties of the capillary network in the skin. While cyanosis may be present at birth, it frequently develops in the second and third decade when the aneurysm becomes large enough to shunt a sufficient amount of blood away from the alveolar capillaries. In some cases the cyanosis may be hidden by anemia caused by repeated bleeding from telangiectasis in the nose or in the intestinal tract.[74] In cases of Rendu-Osler-Weber's disease, therefore, roentgen examination of the chest should be performed to detect vascular anomalies in the lungs. When the "feeder artery" comes from the aorta or from a bronchial artery there exists no right-to-left shunt and no cyanosis.[18] In these cases the intravascular pressure must be high and the aneurysm theoretically more apt to rupture than in the ordinary cases with cyanosis.

OBSERVATIONS

Laboratory. In cyanotic cases there is an increase in the erythrocyte count and hemoglobin content of the blood (except in cases with posthemorrhagic anemia). The polycythemia is induced by the hypoxemia in the blood regulating center.[18] Values as high as 11.5 million red blood cells per cu. mm. have been recorded.[1] This will cause a considerable rise in the circulating blood volume, but as the plasma volume remains normal the hematocrit readings will tend to parallel the hemoglobin value. The white cell count is normal. Measurements of the circulation time may show an abnormally short arm-to-tongue time, indicating a right-to-left shunt but not the position of the shunt. The circulation time may however be normal even in the presence of a large arteriovenous aneurysm[7] probably because of the great viscosity of the blood. Determinations of the arterial oxygen saturation will give subnormal values, not normalized by oxygen breathing, in cases with a right-to-left shunt. The electrocardiogram is usually normal but may show right axis deviation and high P waves in cases with raised cardiac output.[7, 34]

Roentgenographic. The most important sign indicating the presence of an arteriovenous aneurysm in the lung is the finding of a shadow in the lung fields on the roentgenograms. The opacity is round or lobulated and connected with the pulmonary hilum by broad, band-shaped vascular shadows. These vessels even in the case of small aneurysms, are

FIG Oblique tomogram showing the vascular loop of an arteriovenous aneurysm in the L L L hidden behind the heart shadow in the anteroposterior projection

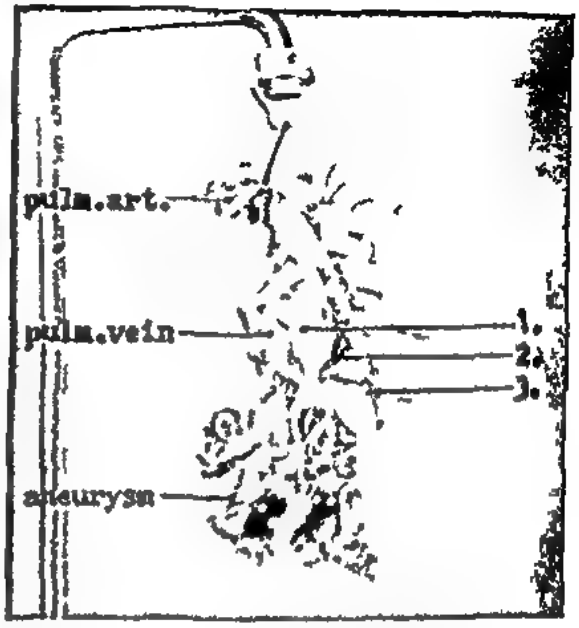

FIG 2 Same case as Figure 1 Vinyl cast of the vascular tree The branches not connected with the aneurysm are partly cut away Three arterial branches enter the aneurysmal sac which is dilated by a greatly enlarged vein (Same projection as Figure 1)

small arteriovenous aneurysms scattered in the lungs Grishman et al[44] emphasize the apparently frequent occurrence of aberrant and accessory pulmonary arteries and veins This anomaly was also noticed by Sloan and Cooley[88] In one case reported by Watson[92] the arterial branch to the aneurysm came from the descending part of the thoracic aorta In other cases without cyanosis the feeder artery may be a branch from the bronchial arteries[60]

Physiology When the aneurysm is built up by a pulmonary artery and a pulmonary vein a right to left shunt will be established leading to arterial oxygen unsaturation in the systemic circulation The hypoxemia will give rise to secondary polycythemia with augmentation of the cell volume while the plasma volume remains normal or nearly so As distinct from the systemic circulation the vascular resistance in the lungs is normally so low that the presence of a shunt will usually not significantly reduce the over all vascular resistance of the lungs Moreover in the presence of a pulmonary arteriovenous aneurysm the capillary resistance in the lungs is higher than normal[88] probably because of the hypoxemia or caused by multiple thrombi in the lung capillaries as described in the tetralogy of Fallot In accordance with this estimations of the cardiac output will usually be within normal limits and right heart failure is rarely seen If however the shunt is so large (in the case of Lequime et al 89 per cent of the blood passed through the shunt[56]) that the pulmonary vascular resistance is reduced the cardiac output [illegible] hypertrophy [illegible] to be 12 L per minute with 80 per cent passing through the shunt In the presence of systemic hypertension or valvular heart disease hypertrophy may exist independent of the pulmonary shunt

Symptoms and Signs Shortness of breath is the chief complaint of most patients The dyspnea however is often less pronounced than what should be allowed for the degree [illegible] of the

dizziness transient numbness and weakness [illegible] one side of the body and convulsions is a com

mainder some may have died since the report and, probably, some have been operated upon

TREATMENT

Sixty seven patients underwent surgical therapy with a primary mortality of 7 5 per cent (five cases) [7 8 21 88 94] One of the patients with bilateral lesions died twenty hours after the second lobectomy [88] One patient died two and a half years after successful lobectomy [81]

In five cases [28 35 45 69 93] ligature of the "feeder artery" was performed with improvement in one and a good result in three cases In one of these patients the arterial branch came from the aorta One patient had no symptoms before surgery Another case,[35] not typical in that there appeared to be an almost continuous channel between the pulmonary artery and the left atrium, was cured by ligature

Removal of the aneurysm was undertaken in sixty-one cases most frequently by lobectomy In six cases [16 37 38 40 50 70] the aneurysms were removed by segmental resection in four cases [17 38 38 60] by lobectomy and excision and in seven cases [1 41 45 51 63 87 99] pneumonectomy was performed

Most often the immediate result is excellent with disappearance of cyanosis in a few hours and a normal return of the blood values in a few weeks In some cases a certain degree of arterial unsaturation remains which may be caused by additional undiagnosed aneurysms In cases in which two or more aneurysms are to be removed in a two-stage operation the remaining aneurysm tends to enlarge in the interval between surgery with only temporary amelioration of the symptoms after the first operation [16] Late results are not available

The indication for surgical therapy is clear in cases with increasing cyanosis, hemoptysis or alarming nervous symptoms Patients with minimal symptoms run the risk of rupture and cerebral embolism and intervention in these cases will depend on localization the number of aneurysms and the age of the patient

REFERENCES

1 ADAMS W E THORNTON T F and EICHELBERG L Cavernous haemangioma of the lung (arterio-venous fistula) Report of a case with successful treatment by pneumonectomy *Arch Surg* 49 51 58 1944

2 ADAMS W L Bilateral resection for arterio-venous fistulae of lung *Proc Inst Med Chicago* 18 294 1951

3 ALEXANDER, W S Haemangioma of the lung Report of a case showing polycythemia *New Zealand M J* 44 180–182 1945

4 D ALLAINES F D DONZELOT E, DUBOST C, DURAND M MÉTIANU C and HEIM DE BALSAC, R Anévrysmes artérioveineux pulmonaires *Mem Acad de chir* 76 713–723 1950

5 ARMENTROUT H L and UNDERWOOD F J Familial hemorrhagic telangiectasia with associated pulmonary arteriovenous aneurysm *Am J Med*, 8 246–254 1950

6 BAER, S BEHREND A and GOLDBURGH H L Arteriovenous fistula of lung *Circulation*, 1 602–612 1950

7 BAKER C and TROUNCE J R T Arteriovenous aneurysm of the lung *Brit Heart J* 11 109–118 1949

8 BARNES, C G FATTI, L and PRYCE, D M Artero venous aneurysm of the lung *Thorax*, 3 148 160 1948

9 BEDOARD F D Arteriovenous fistula of the lung *Brit M J* 1 1038 1949

10 BEIERWALTES W H and BYRON F X Pulmonary arteriovenous aneurysm with secondary polycythemia *J A M A*, 134 1069–1072, 1947

11 BISGARD J D Pulmonary cavernous haemangioma with arteriovenous fistula surgical management case report *Ann Surg* 126 965–972, 1947

12 BLADES B Quoted by Yater et al [91]

13 BOERMA I and BRILMAN R P Cavernous angioma of the right lung *J Thoracic Surg*, 17 705 708 1948

14 BOWERS W F Rupture of visceral hemangioma as cause of death *Nebraska M J* 21 55 57, 1936

15 BRINK A J Telangiectasis of lung *Quart J Med* 19 239–284 1951

16 BRØBECK O A case of arteriovenous aneurysm of the lung cured by resection *Acta radiol*, 30 371 379 1948

17 BURCHELL, H B and CLAGETT O T The clinical syndrome associated with pulmonary arteriovenous fistula including a case report of a surgical cure *Am Heart J* 34 151 1947

18 BØE, J and BENESTAD A M Reticulocyte reaction following cerebral ischemia *Acta med Scandinav*, 149 345 349, 1954

19 CAPPON D Hereditary haemorrhagic teleangiectasia *Brit M J* 50 440 1945

20 CARSWELL, J JR. Arteriovenous fistula of the lung With report of a case *J Thoracic Surg*, 19 789–793 1950

21 CLELAND W P Cavernous haemangioma of the lung Report of a case *Thorax* 3 48 52, 1948

22 COBLENTZ B Les anévrysmes artério-veineux pulmonaires *France med* 14 13 16 1951

23 COPE C. C. The development of arterio-venous aneurysms in the lung *Brit J Tuberc*, 47 166–171 1953

24 CRANE, P LERNER, H H and LAWRENCE E. A Syndrome of arterio-venous fistula of the lung *Am J Roentgenol* 62 418–431 1949

25 CURTON Multiple aneurysms of pulmonary artery *Brit M J* 1 1223 1897

than others situated in the same region, they may have another course and are more sinuous By the Valsalva test (expiration against closed glottis) the shadow will diminish and conversely, by the Muller test (inspiration against closed glottis) the shadow will augment [67] By roentgenoscopic examination the shadow may show expansive pulsation Electrokymography may visualize that the systolic expansions of the mass precedes the normal pulmonary pulse wave [84] Tomograms may often show the vascular loop more distinctly than an ordinary plate and may also make visible aneurysms hidden behind the shadow of the heart and the liver The final proof of the vascular nature of the opacity may be given by angiography The dye will concentrate in the aneurysm and may appear in the left atrium and aorta with abnormal rapidity. Frequently other aneurysms not detected in the plain x-ray film may be visualized Serious reactions[79] and one death[87] have been reported by this procedure possibly because a too high concentration of the contrast medium (diodrast 70 per cent) reached the coronary vessels via the aneurysm without having been through the mixing effect of the lung capillaries After all, an angiocardiographic study should be performed in cases in which surgical intervention is being considered, in an effort to establish clearly the extent and number of aneurysms present Large films covering the whole of both lung fields should be used

Diagnosis The majority of these patients have been referred to the medical centers under a provisional diagnosis of congenital heart failure because of the cyanosis and clubbing Another group of patients are incidentally detected by routine x ray examination of the chest In a few hemoptysis and a shadow in the lung fields raise the suspicion of tuberculosis or tumor of the lung The cyanosis and polycythemia may also lead to an erroneous diagnosis of polycythemia vera

A complete heart examination will in most cases exclude the possibility of congenital heart failure, a condition which may be present in addition to an arteriovenous aneurysm of the lung [32 97 95] Other causes of polycythemia must be ruled out In polycythemia vera chest roentgenograms may show round pulmonary shadows These are, however, not vascular in nature and disappear after a short time The white cell count is high with a shift to the left The blood pressure is usually elevated and the patient looks more red than blue Pulmonary diseases preventing adequate oxygenation, such as fibrosis and emphysema, will rarely cause cyanosis so pronounced as a right to-left shunt in the heart or in the lungs Radiographic examination will be decisive in these cases and moreover, by the shadow of the aneurysm give a direct clue to the diagnosis Pulmonary metastases, tumors, cysts, tuberculomas and bronchiectatic sacs filled with secretions may give an appearance which resembles an arteriovenous aneurysm The important sign to recognize is the relation of the mass to the adjacent vessels which may be demonstrated by tomography and angiography

The diagnosis is based on the history of the patient and that of the family, physical examination (especially the presence of cyanosis clubbing, visible telangiectasis and a systolic murmur over the lungs), laboratory and x ray examination and ultimately the diagnosis may be confirmed by angiography

Course The disease may remain stationary for years if untreated, but frequently there is a definite tendency towards progression, probably caused by a slow enlargement of the shunt or the establishment of new shunts[7] In the case of Makler and Zion[60] the clinical picture was unchanged after four years, but the hemoglobin value had increased from 19 5 gm in 1946 to 22 3 gm in 1950 when the patient was operated upon with a good immediate result

Of fifty patients who were not operated upon twenty are known to be dead In seven cases the cause of death was rupture of the aneurysmal sac into a bronchus or into the pleural cavity [14 22 45 49 77 78 93] Five patients have died from abscess of the brain,[46 55 64 72 93] and Naffziger and Stern[65] have reported two additional cases of arteriovenous aneurysm of the lung complicated by brain abscess Linden[55] supposes that these cases are subject to abscesses of the brain caused by paradoxic emboli in the same manner as patients with congenital heart failure The patient reported by Alexander[1] died from coronary disease Theoretically these patients may be more vulnerable than normal to coronary stenosis because of the hypoxemia In one patient the death was caused by angiography [87] In two cases the cause of death is not mentioned [25 56] and four patients have died of causes probably not related to the aneurysm [21 76 81 65] Of the re-

mainder some may have died since the report and probably, some have been operated upon

TREATMENT

Sixty seven patients underwent surgical therapy with a primary mortality of 7 5 per cent (five cases) [7 8 21 89 94] One of the patients with bilateral lesions died twenty hours after the second lobectomy [88] One patient died two and a half years after successful lobectomy [81]

In five cases [28 35 44 69 93] ligature of the feeder artery was performed with improvement in one and a good result in three cases In one of these patients the arterial branch came from the aorta One patient had no symptoms before surgery Another case [88] not typical in that there appeared to be an almost continuous channel between the pulmonary artery and the left atrium, was cured by ligature

Removal of the aneurysm was undertaken in sixty-one cases most frequently by lobectomy In six cases [16 37 39 40 50 70] the aneurysms were removed by segmental resection, in four cases [12 28 31 90] by lobectomy and excision and in seven cases [1 41 48 51 63 67 99] pneumonectomy was performed

Most often the immediate result is excellent with disappearance of cyanosis in a few hours and a normal return of the blood values in a few weeks In some cases a certain degree of arterial unsaturation remains which may be caused by additional undiagnosed aneurysms In cases in which two or more aneurysms are to be removed in a two-stage operation the remaining aneurysm tends to enlarge in the interval between surgery with only temporary amelioration of the symptoms after the first operation [14] Late results are not available

The indication for surgical therapy is clear in cases with increasing cyanosis, hemoptysis or alarming nervous symptoms Patients with minimal symptoms run the risk of rupture and cerebral embolism and intervention in these cases will depend on localization the number of aneurysms and the age of the patient

REFERENCES

1 ADAMS W E THORNTON T F and LICHEL BERG L Cavernous hemangioma of the lung (arterio-venous fistula) Report of a case with successful treatment by pneumonectomy *Arch Surg* 49 51 58 1944

2 ADAMS W E Lateral resection for arterio-venous fistulae of lung *Proc Inst Med Chicago* 18 294 1951

3 ALEXANDER W S Haemangioma of the lung Report of a case showing polycythemia *New Zealand M J* 44 180–182 1945

4 D ALLAINES, F D DONZELOT E DUBOST C, DURAND M MÉTIANU, C. and HEIM DE BALSAC, R Anévrysmes artérioveineux pulmonaires *Mem Acad de chir* 76 713 723 1950

5 ARMENTROUT H L and UNDERWOOD F J Familial hemorrhagic telangiectasia with associated pulmonary arteriovenous aneurysm *Am J Med* 8 246–254 1950

6 BAER S BEHREND A and GOLDBURGH, H L. Arteriovenous fistula of lung *Circulation*, 1 602–612 1950

7 BAKER, C and TROUNCE J R T Arteriovenous aneurysm of the lung *Brit Heart J*, 11 109–118 1949

8 BARNES C G FATTI, L and PRYCE, D M Artero-venous aneurysm of the lung *Thorax*, 3 148 160 1948

9 BEDDARD F D Arteriovenous fistula of the lung *Brit M J* 1 1038 1949

10 BEIERWALTES W H and BYRON F X Pulmonary arteriovenous aneurysm with secondary polycythemia *J A M A* 134 1069–1072, 1947

11 BISGARD J D Pulmonary cavernous haemangioma with arteriovenous fistula surgical management case report *Ann Surg* 126 965–972 1947

12 BLADES B Quoted by Yater et al [91]

13 BOERMA I and BRILMAN R P Cavernous angioma of the right lung *J Thoracic Surg*, 17 705–708 1948

14 BOWERS W F Rupture of visceral hemangioma as cause of death *Nebraska M J* 21 55 57, 1936

15 BRINK A J Telangiectasis of lung *Quart J Med* 19 239–284 1951

16 BRØBECK O A case of arteriovenous aneurysm of the lung cured by resection *Acta radiol* 30 371 379 1948

17 BURCHELL H B and CLAGETT O T The clinical syndrome associated with pulmonary arteriovenous fistula including a case report of a surgical cure *Am Heart J* 34 151 1947

18 BØE, J and BENESTAD A M Reticulocyte reaction following cerebral ischemia *Acta med Scandinav* 149 345 349, 1954

19 CAPPON D Hereditary haemorrhagic teleangiectasia *Brit M J* 50 440 1945

20 CARSWELL J JR Arteriovenous fistula of the lung With report of a case *J Thoracic Surg*, 19 789–793 1950

21 CLELAND W P Cavernous haemangioma of the lung Report of a case *Thorax* 3 48 52 1948

22 COBLENTZ B Les anévrysmes artério-veineux pulmonaires *France méd* 14 13 16 1951

23 COPE C C The development of arterio-venous aneurysms in the lung *Brit J Tuberc* 47 166–171 1953

24 CRANE P LERNER, H H and LAWRENCE E A Syndrome of arterio-venous fistula of the lung *Am J Roentgenol* 62 418–431 1949

25 CURTON Multiple aneurysms of pulmonary artery *Brit M J* 1 1223 189-

26 DENOLIN, H, LEQUIME, J and JONNART, L L'anévrysme artériovenoveux pulmonaire *Acta cardiol*, 5 144 155, 1950
27 DIGNAM, B S Arteriovenous aneurysm of branch of pulmonary artery *Am Heart J*, 41 316–318, 1951
28 DONZELOT, E, DUBOST, C, DURAND M and MÉTIANU, E Hémangiome pulmonaire Diagnostic par angiocardiographie Intervention *Arch d mal du coeur*, 43 511–519 1950
29 DUBOST, C, DURAND, M, MÉTIANU, E and OECONOMOS, N Presentation d un cas d anevrysme arterio veineux pulmonaire opéré avec succes *Mém Acad de chir*, 77 694–698, 1951
30 DUISENBERG, C E and ARISIENDI, L Angiographic demonstration of pulmonary arterio venous fistula *Radiology*, 53 66–74 1949
31 DUVOIR, M, PICOT, G POLLET, L and GAULTIER, M Angiome du poumon Quoted by Sloan and Cooley "
32 ERF, L A, FOLDES I, PICCIONE, F V and WAGNER F B Pulmonary hemangioma with pulmonary artery-aortic septal defect *Am Heart J* 38 766–774 1949
33 ETTINGER, A, MAGENDANTZ H and RUSSO, E A Arteriovenous aneurysm of the lung *Radiology*, 53 261–267, 1949
34 FORSEE, J H, MAHOV H W and JAMES, L A Cavernous hemangioma of the lung *Ann Surg*, 131 418–423 1950
35 FRIEDLICH A, BING R J and BLOUNT, S G, JR Physiological studies in congenital heart disease Circulatory dynamics in the anomalies of arteriovenous return to the heart including pulmonary arteriovenous fistula *Bull Johns Hopkins Hosp*, 86 20–57, 1950
36 GANESAN, A P Pulmonary arteriovenous aneurysm Quoted by Sloan and Cooley "
37 GARLAND H G and ANNIG, S T Hereditary hemorrhagic teleangiectasia *Brit M J*, 1 700, 1950
38 GIAMPALMO A L angiomatosi polmonare arteriovenosa impossibilitazzante *Pathologica*, 40 61–94 1948
39 GIAMPALMO, A The arteriovenous angiomatosis of the lung with hypoxemia *Acta med Scandinav*, 139 1–67, 1950
40 GLENN, F, HARRISON, C S and STEINBERG, I Pulmonary arteriovenous fistula occurring in siblings, report of two cases *Ann Surg*, 138 886–891, 1953
41 GOLDMAN A Cavernous hemangioma of the lung secondary polycythemia *Dis of Chest* 9 479–486, 1943
42 GOLDMAN A Arteriovenous fistula of the lung Its hereditary and clinical aspects *Am Rev Tuberc*, 57 266–280, 1948
43 GOLDSTEIN, H I Heredofamilial angiomatosis *Arch Int Med*, 27 102, 1921
44 GRISHMAN, A, POPPEL, M H, SIMPSON, R S and SUSSMAN, M L Roentgenographic and angiocardiographic aspects of aberrant insertion of pulmonary veins associated with interatrial septal defect and congenital arteriovenous aneurysm of the lung *Am J Roentgenol*, 62 500–508, 1949
45 HEDENIUS, I Nogra ovanligare fall af lung bildning *Uppsala läkaref förh*, 456 1901–1902
46 HEDINGER, C, HITZIG, W H and MARMIER, C Über arterio-venose Lungenaneurysmen und ihre Beziehungen zur Osterschen Krankheit *Schweiz med Wchnschr*, 81 367–374, 1951
47 HEDVALL E Arteriovenous aneurysm in the lungs. *Acta tuberc Scandinav*, Suppl 21 32, 1949
48 HEPBURN, I and DAUPHINÉE, I A Successful removal of hemangioma of the lung followed by disappearance of polycythemia *Am J M Sc*, 204 681–685, 1942
49 ISRAEL, H L and GOSFIELD, E, JR Fatal hemoptysis from pulmonary arteriovenous fistula, report of a case *J A M A*, 152 47–48, 1953
50 JAMES R M Multiple cavernous hemangiomas of the lungs successfully treated by local resection of the tumors *Brit J Surg*, 31 270–272, 1944
51 JONES J C and THOMPSON, W P Arteriovenous fistula of the lung *J Thoracic Surg*, 13 357–373 1944
52 KUNZER W Beitrag zur Polycythaemia vera im Kindesalter *Zischr f Kinderh*, 66 130 1948
53 DE LANGE, C and VRIES ROBLES, G B Ueber Lungenangiome bei einem Säugling *Zischr f Kinderh* 34 304 1922–1923
54 LAWRENCE, E A and RUMEL, W R Arteriovenous fistula of the lung *J Thoracic Surg* 20 142–150, 1950
55 LINDÉN, L Hjärnabscess som följd av paradox embolı *Nord med*, 49 235–237, 1953
56 LEQUIME, J, DENOLIN, H, DELCOURT R, VERNIORY, A and CALLEBAUT, C Anévrysmes artério veineux pulmonaires et angiomatose généralisée *Acta cardiol*, 5 63–76, 1950
57 LINDGREN, E Roentgen diagnosis of arteriovenous aneurysm of the lung *Acta radiol*, 27 583–600 1946
58 LINDSKOG, G E, LIEBOW, A A, KALSEL, H and JANSEN, A Pulmonary arteriovenous aneurysm *Ann Surg*, 132 591–606, 1950
59 MAIER, H C, HIMMELSTEIN, A, RILEY, R L and BUNIN, J J Arteriovenous fistula of the lung *J Thoracic Surg*, 17 13–26, 1948
60 MAKLER P T and ZION, D Multiple pulmonary hemangiomata *Am J M Sc*, 211 261–266 1946
61 MALLORY, T B, CASTLEMAN, B and PARRIS E E Case records of the Massachusetts General Hospital *New England J Med*, 236 951–955, 1947
62 MARMIER, C and HITZIG, W H Multiple arteriovenöse lungenaneurysmen bei Morbus Osler *Radiol Clin*, 19 333–338, 1950
63 MOTEN, J H and ACKERMAN A J Hereditary hemorrhagic telangiectases with pulmonary arterio-venous fistula in two members of a family *Ann Int Med*, 29 775–802, 1948
64 MURI, J W Arteriovenous aneurysms of the lung *Dis of Chest*, 24 40–65 1953

65 NAFFZIGER, H C and STERN W E Quoted by Glenn et al 66
66 NIGHTINGALE J A Case of pulmonary arterio venous fistula *Brit M J* 2 402 1951
67 NIXON J W and PERRY J F Arteriovenous fistula of the lung and an associated heman gioma of the vertebra Case report *Dis of Chest* 21 108 1952
68 NOGRETTE P Anévrysmes artérioveineux pul monaires *Presse méd* 61 25 1953
69 PACKARD G B and WARNING J J Arteriovenous fistula of the lung treated by l gation of the pulmonary artery *Arch Surg* 56 725 740 1948
70 PUGSLEY H E and JAMES R M Arteriovenous aneurysm of the lung *Dis of Chest* 20 177–185 1951
71 QUEMERCH R Contribut on à l etude des anevrysmes pulmona res arterio-veineux Thèse de Lyon 1949
72 RAVINA A Ang omatose héréd taire hémor rhagique avec anévrysmes arterio veineux du poumon *Presse méd* 57 776–777 1949
73 READING B A case of congenital telangiectas s of the lung compl cated by brain abscess *Texas State J Med* 23 462 464 1932
74 ROBB G P and GOTTLIEB C Report of a case of pulmonary arteriovenous fistula in the left lower pulmonary field *Exper Med & Surg* 9 431 437 1951
75 ROBERTS D J and HUTCHINSON J E Symptom less pulmonary arteriovenous aneurysms or fistulas *Am J Roentgenol* 66 743–746 1951
76 ROBERTSON C K Arterio venous aneurysm of the lung with pulmonary tuberculosis *Brit J Tuberc* 44 58–61 1950
77 RODES C B Cavernous hemangiom s of the lung with secondary polycythem a *J A M A* 110 1914 1915 1938
78 RUNDLES R W Hemorrhag c telang ectas s with pulmonary artery aneurysm *Am J M Sc* 210 76–81 1945
79 RUNDSTRÖM G and SIGROTH K Two cases of vascular anomalies in the lung *Acta med Scandinav* Suppl 246 176–186 1950
80 SALVESEN H A Cyanose (arteriovenös fistel i lungen) *Tidsskr f d norske Lagefor* 67 460 1947
81 SALVESEN H A and MARSTRANDER F Arterio-venous f stula of the lung *Acta med Scandinav* 139 167 1951
82 SANTY P PAPILLON J and BRET J A propos d un cas d anevrysme artério-veineux pul monaire *J de rad ol et d'électrol* 31 581 1950
83 SEAMAN W B and GOLDMAN A Roentgen as pects of pulmonary arterio-venous f stula *Arch Int Med* 89 70–81 1952
84 SEGERS M REGNIER, M and DESOLIN H Tumeur pulmonaire pulsatile avec shunt artério-veineux *Acta cardiol* 5 156 162 1950
85 SEIP M Reticulocyte studies *Acta med Scandinav* Suppl 282 1 164 1953
86 SHENSTONE N S Report of a case of cavernous angioma of the lung *Brunn Med -Surg Tributes* pp 503 507 1942 Quoted by Sloan and Cooley 88
87 SISSON J H MURPHY G E and NEWMAN E V Multiple congenital arteriovenous aneurysms in the pulmonary circulation *Bull Johns Hopkins Hosp* 76 93 111 1945
88 SLOAN R D and COOLEY R N Congenital pulmonary arteriovenous aneurysm *Am J Roentgenol* 70 183 210 1953
89 SMITH H L and HORTON B T Arteriovenous f stula of lung associated with polycythemia vera report of a case in which the diagnosis was made clinically *Am Heart J* 18 589–592 1939
90 TALBOT T J and SILVERMAN J J Asymptomatic arteriovenous fistula of the lung report of a case with surgical cure *Arch Int Med* 90 569–574 1952
91 TOBIN J J Jr. and WILDER T C Pulmonary arteriovenous fistul s associated with hereditary hemorrhag c telangiectasis a report of their occurrence in a father and son *Ann Int Med* 38 868–876 1953
92 TROCHÉ P and SOULIÉ P Un cas d angiome du poumon avec cyanose *Arch d mal du coeur* 43 161 168 1950
93 WATSON W L Pulmonary arteriovenous aneu rysm A new surgical disease *Surgery* 22 919–929 1947
94 WHITAKER W Cavernous hemangioma of the lung *Thorax* 2 58–64 1947
95 WILKENS G D Ein Fall von multiplen Pul monalis-aneurysmen *Beitr z Klin Tuberk* 38 1 10 1918
96 WILLIAMS C F and FLINK, E B Hereditary hemorrhagic teleang ectasis in association with cerebral manifestations and pulmonary aneu rysm *J Lab & Clin Med* 32 1401 1947
97 WISSLER H Arteriovenöses Aneurysma der Lunge und Teleang ectasis haemorrhagica hered itaria Osler *Helvet paediat acta* 8 111–116 1953
98 WODEHOUSE G E Hemangioma of the lung A review of four cases including two not previously reported one of which was complicated by brain abscess due to H influenzae *J Thoracic Surg* 17 408 415 1948
99 YATER W M FINNEGAN J and GIFFIN, H M Pulmonary arteriovenous f stula (varix) *J A M A* 141 581 589 1949
100 ZANTY Anévrysme artério-veineux intrapulmonaire Guérison par pneumectomie *Presse méd* 57 411 1949
101 ZAVODNY F Quoted by Giampalmo 88

38

Hernia of Lung

EMIL A NACLERIO, M D, *New York, New York*

From the Thoracic Surgical Services of Harlem and Columbus Hospitals New York New York

HERNIA of the lung or pneumonocele is a condition in which any part of one or both lungs contained in a sac of parietal pleura protrudes beyond the normal confines of the thoracic cavity through an abnormal opening in the chest wall

A study of the literature indicates that certain cases reported as hernia of the lung were not true hernias but merely traumatic eviscerations or prolapse Prolapse of lung differs from a true hernia in that the lung tissue which protrudes beyond its normal boundaries is not contained within a distinct sac of parietal pleura Some authors emphasize that both prolapse and hernias should be classified as true lung hernias, since in each instance the lung has protruded beyond the confines of the thoracic cavity

Herniation of the lung is a rare condition Approximately 240 cases have been recorded in the literature the first case having been reported by Roland in 1499 [1] Contributions to this subject have been made notably by Montgomery and Lutz [2] who in 1925 reviewed all the cases reported up to that time, a total of 165 In addition they classified as many as possible according to etiology and location In 1933 Goodman[3] collected a total of 171 cases In 1946 Maurer and Blades[4] stated that "less than 185 cases have been recorded in the medical literature" They reported seven additional cases of their own In 1955 Hiscoe and Digman[5] brought the incidence of lung hernias up to-date and classified all the cases published since 1925 They found sixty eight cases in the literature between 1925 and June, 1954 bringing the total to 233

CLASSIFICATION

Hernias of the lung have been classified on the basis of location and etiology, following the outline suggested by Morel Lavallée[6] in 1849. This basic classification still accepted today is shown in Table I

According to Location There has been only

TABLE I
CLASSIFICATION

According to Location	According to Etiology
Diaphragmatic	Congenital
Thoracic	Acquired
Cervical	Traumatic
	Consecutive
	Spontaneous
	Pathologic

two year old male who was pinned to the ground by a cart wheel striking him in the abdomen Autopsy revealed a defect in the right hemidiaphragm through which the lung was herniated with strangulation and abscess formation Because of the difference in pressure relationships between the pleural and peritoneal cavities (pressures in the chest are less than atmosphere [negative] while in the abdomen the pressures are zero or positive), it would seem that this case was one of prolapse rather than herniation

The thoracic or intercostal type of hernia is the most common Of seventy eight case reports reviewed by Montgomery and Lutz,[2] there were sixty-two thoracic hernias, the remaining were cervical hernias The majority of thoracic hernias occur anteriorly near the sternum, where the pectoral muscles offer poor protection to the underlying structures In the regions covered by the trapezius latissimus dorsi and rhomboid muscles the incidence of these hernias is lowest A few may be found posteriorly near the vertebrae

FIG 1 Photograph of a patient demonstrating an acquired traumatic hernia The anterior two thirds of the 2nd left rib was removed because of neoplastic invasion

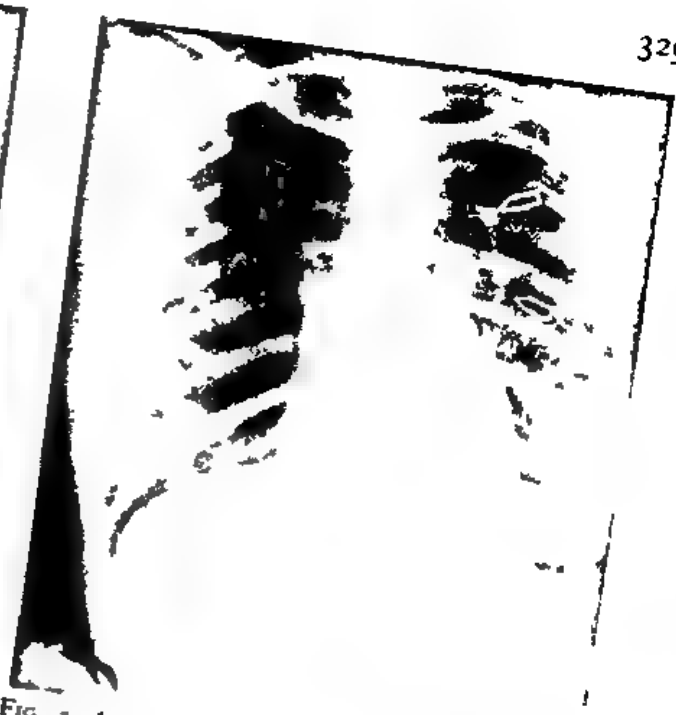

FIG 2 Arrows clearly demonstrate the mediastinal herniation This condition is not uncommonly associated with pneumothorax

where a relative weakness of the wall exists since the internal intercostal muscles extend only as far as the angle of the ribs Most of these hernias follow trauma whether it be a simple fracture or an extensive chest wall operation

The cervical hernias are the least common Up to 1938 there had been only twenty cases found in the literature To quote Maurer and Blades[4] Cervical hernias usually occur through the superior aperature of the thorax in the interval between the sternocleidomastoid and scalenus anticus muscles following some tear or deficiency in Sibson s fascia which normally limits the cervical excursion of the dome of the pleura Hernias in this location are most commonly congenital

According to Etiology The congenital hernias occur most commonly in the superior thoracic aperature or anteriorly in the intercostal spaces near the sternum In some instances there is difficulty in determining whether the hernia is congenital or not This is especially true when the hernia appears many months after birth

The great majority of acquired hernias are traumatic (Fig 1) Those that occur early after injury have been classified by Morel Lavallee as traumatic and those late after injury as consecutive This subdivision makes the classification unnecessarily complicated Most writers agree that this latter subdivision is superfluous as it signifies only a difference in time for the appearance of a traumatic hernia after injury

Spontaneous lung hernias occur as a result of a local decreased resistance in certain areas of the boundaries of the chest wall associated with abnormal increases in intrapulmonary air pressures Factors which further predispose to the development of the condition are chronic cough due to chronic bronchopulmonary disease lifting of heavy objects straining, glass blowing or playing of wind instruments or any other factors which cause increased intrathoracic pressure

Pathologic lung hernias may result from diseases involving the chest wall e g abscess of chest wall and breast empyema necessitatis and malignancies

MEDIASTINAL HERNIA

If mediastinal hernia is to be included in descriptions of hernia of the lung, the incidence



FIG 3 The defect is clearly visible on deep inspiration There were no complaints associated with the hernia except for concern because of the disfigurement Patient contrived a protective prosthesis that she wore most of the time

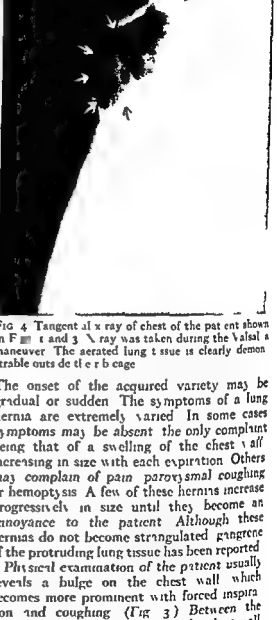

FIG 4 Tangential x ray of chest of the patient shown in Figs 1 and 3 X ray was taken during the Valsalva maneuver The aerated lung tissue is clearly demonstrable outside the thoracic cage

of lung hernia would be much higher since there are hundreds of these hernias not recorded While mediastinal hernias are not *related etiologically or pathologically to the* hernias under discussion Korol[9] believes that they should be included in the category of lung hernia since by definition a mediastinal hernia is a herniation of lung tissue which protrudes through the mediastinal septum into the opposite hemithorax The herniation in these cases occurs either anteriorly in the space between the sternum and the heart at the site of the atrophied thymus gland (Fig 2) or posteriorly between the esophagus and aorta below the level of the tracheal bifurcation Mediastinal hernias may occur in patients with emphysema of one lung associated with atelectasis and fibrosis or absence of the opposite lung or in patients in whom there has been abandonment of a long continued pneumothorax

CLINICAL RECOGNITION

A congenital hernia may be recognized immediately after birth or some time later The onset of the acquired variety may be gradual or sudden The symptoms of a lung hernia are extremely varied In some cases symptoms may be absent the only complaint being that of a swelling of the chest wall increasing in size with each expiration Others may complain of pain paroxysmal coughing or hemoptysis A few of these hernias increase progressively in size until they become an annoyance to the patient Although these hernias do not become strangulated gangrene of the protruding lung tissue has been reported

Physical examination of the patient usually reveals a bulge on the chest wall which becomes more prominent with forced inspiration and coughing (Fig 3) Between the phases of breathing a defect in the chest wall may be noted (Fig 1) It should be remembered that the hernia may be completely or partially obscured by the scapula or the heavy musculature of the latissimus dorsi or the anterior pectoral muscles In certain cases what seems to be a small bulge on the chest wall may appear as a huge hernia on the film

A tangential x ray film of the chest in the

area of the mass, taken during forced expiration, will reveal aerated lung tissue outside the rib cage (Fig 4) It is probable that in

from cold abscess of the chest wall, subcutaneous emphysema, soft tumors, e g, fibroma, lipoma and hemangioma of chest wall, and aneurysm of the intercostal vessels and aorta.

TREATMENT

The only treatment which will give permanent and satisfactory results is operative repair Medical treatment consisting of rest, change of occupation and the use of some retentive apparatus, namely, compression with pads and elastic devices (Fig 3), is purely palliative Surgery may be contraindicated in certain cases because of local factors at the hernia site or the poor general condition of the patient

Many methods of surgical repair have been advocated for defects of the thoracic wall Tuffier,[9] in 1891, reported a cure by freeing and ligating the hernial sac Vogler,[10] in 1898, proposed shifting periosteum or a bone flap from the sternum to cover the defect Vulpius,[10] in 1898 described a plastic operation performed by crossing strips of rib and securing them with silver wire This hernia recurred in a year Graham,[11] in 1922, packed the sac of a cervical pneumonocele with iodoform gauze The packing was removed on the fifth post operative day and the wound healed without recurrence of the hernia In 1935 Winkel[12] effected a cure in a case of traumatic intercostal hernia by obliterating the defect with woven strips of fascia lata Koontz,[13] in 1948, presented a preliminary report on the use of tantalum mesh for repairing hernias of the abdominal wall, and in 1950 Morrow[14] recorded the successful use of the same material in the closure of full thickness defects in the chest wall In 1952 Baxter and Shackelford[15] presented a simpler successful method of repairing a hernia with tantalum mesh

Maurer and Blades,[2] who have had the largest individual experience with the surgical treatment of lung hernia in recent times emphasize that excellent results can be obtained with any defect of the chest wall, regardless of size, with plastic repair procedures utilizing structures which are a part of the chest wall only, namely, the rib, periosteum or muscle They state that the most important feature is closure of the defect with sturdy bone or periosteum which will produce bone

Fig 5 Tangential x ray of chest of same patient *showing the lipiodol filling of the herniated lung*

SUMMARY

A review of the literature concerning lung hernias, revealing approximately 240 cases to date, is presented A true lung hernia is the protrusion of the lung and its pleural membrane

to three cases personally treated are included A classification of these conditions is presented along with pertinent data relative to clinical manifestations

REFERENCES

1 ROLAND DE VOLMOOIS sanatipot vol III chap XXV, p 144 In de Chauliac Guy Cyrugia 1499
2 MONTGOMERY, J G and LUTZ H Hernia of lung. *Ann Surg* 82 220 1925
3 GOODMAN H I Hernia of the lung *J Thoracic Surg*, 2 368 1933

4 MAURER, E and BLADES, B Hernia of the lung *J Thoracic Surg*, 15 77, 1946
5 HISCOE, D B and DIGMAN, G J Types and incidence of lung hernias *J Thoracic Surg*, 30 335, 1955
6 MOREL-LAVALLEE Hernies du poumon *Bull et mem Soc d chir de Paris*, 1 75–195, 1845–1847
7 BEALE, E C On a case of hernia of the lung through the diaphragm *Lancet*, 1 139–140, 1882
8 KOROL, E Hernia of the lung intercostal, cervical and mediastinal *Am Rev Tuberc*, 37 39 1938
9 [illegible]
10 [illegible]
11 [illegible] noma of thyroid *S Clin North America* 2 1493–1500, 1922
12 WINKEL, A H Hernia of the lung, report of a case outlining mode of fascia lata repair *J Thoracic Surg*, 4 627, 1935
13 KOONTZ A B The repair of ventral hernias with tantalum mesh preliminary report *South M J*, 41 214–217, 1948, Tantalum mesh in hernia repair experimental and clinical results *Tr South S A*, 60 394–403 1948
14 MORROW, A G The use of tantalum gauze in the closure of full thickness defects in the chest wall *Surgery*, 28 1016–1021, 1950 The use of tantalum gauze in the closure of a defect in the chest wall Ibid, 29 288–292, 1951
15 BAXTER, M D and SHACKELFORD R T Hernia of the lung method of repair with tantalum mesh *Arch Surg*, 65 856 1952

XV. THE PNEUMONIAS

39

The Pneumonias

P A BUNN, M D AND G L EASTMAN, M D,* *Syracuse, New York*

PNEUMONIA is acute inflammation of lung and its supporting framework Regardless of etiology or pathogenesis the clinical picture is characterized by fever, cough, production of purulent sputum and, on occasion, pleuritic pain In the more seriously ill patient dyspnea, cyanosis and exhaustion develop Similarly, physical signs are generally the same irrespective of etiology, namely, evidences of some degree of airlessness or consolidation of the involved lung, rales and restriction of respiration The degree to which these signs and symptoms develop and are observed, is due in the main to the extent of pulmonary involvement, the abruptness of onset and the relative preponderance of alveolar or interstitial tissue inflamed Although certain organisms may often stimulate a classical picture which can be considered diagnostic, there is sufficient variation in signs and symptoms in the multiple types of pneumonia that other than clinical evidences for etiology must be secured

As there are many different agents capable of producing pulmonary inflammation, classification of the pneumonias becomes arbitrary For example, and as is described later, bacteria as the etiologic agent, such as pneumococci, may be used to describe them, or anatomic involvement may be the description e g, lobar lobular, broncho, diffuse, interstitial, this classification being dependent upon the lung area involved and the type of inflammation therein Finally, the terms ' primary " and ' secondary ' are useful, mostly because they suggest the importance of pathophysiologic mechanisms in the pathogenesis of the disease (Table 1)

This report by definition must describe mainly that type of pneumonia caused by microbes, large or small, but this restriction should not in any sense be construed as suggesting that the only important pneumonias are of bacterial, viral or fungal origin, or that they are necessarily the most common forms in all segments of medical and surgical practice

Irrespective of the microbial cause of pneumonia and the over-all general effectiveness of therapy for them by a multitude of well advertised drugs, certain fundamentals in the understanding of the disease in an individual must always be considered Thus, the concept of primary or secondary pneumonia is important, for with it, the physician is faced with a signal decision, namely, is the lung the only source of trouble and/or is infection the single cause for disease in a patient?

Pneumonia caused by any agent rarely develops without either preceding lung injury or some sort of deteriorations in the individual s good health It is, therefore, an immeasurably worse disease in the very young or very old who cannot mobilize rapidly the needed defense mechanisms, in the cirrhotic whose reticulo-endothelial system is ineffective, or in the postoperative patient who cannot cough because his chest or abdomen is immobilized by pain The host with heart disease or diabetes, the person exposed to rapidly changing external temperature, the patient who has chronic lung disease of any order with obstruction to any part of the bronchial tree such as an adenoma or malignancy are similarly more susceptible to pneumonia than are healthy people, and they do poorly with it These and other many varying factors leading to an easier predisposition to pneumonia, cannot be ignored if for no other reason than that its therapy must be altered to fit the associated problems In many instances the accessory or adjuvant treatment

* Dr Eastman is a teacher of chest disease for the University of the State of New York Medical School at Syracuse supported by a joint fund for medical research and education State Committee on Tuberculosis and Public Health and the New York Heart Assembly of the State Charities Aid Association

of greater moment to the patient than the prescription of antibacterial substances

Differential diagnosis of disease in a patient suspected of having pneumonia should be considered in several parts The presence or absence of infection whether it be primary or secondary, is essential knowledge Location of the disease only in the lung is of course the first If infection is present, the species of offending pathogen must be recognized in order to design the best antimicrobial regimen It is perhaps impracticable to more than list the extrapulmonary diseases which can stimulate pneumonia or vice versa Pulmonary infarction acute obstructive atelectasis post operatively or from inhalation of a foreign body, acute cholecystitis or other abdominal crises myocardial infarction and trauma to chest wall are among the common diseases which occasionally mimic pneumonia It is not impracticable though to re emphasize that the physician must consider carefully that cough fever, sputum and chest pain are indeed arising as a direct result of pneumonia

TABLE I

OUTLINE OF PNEUMONIAS

I Primary Pneumonia
- A Viral rarely organizes (usually broncho)
  - (1) Acute respiratory disease with pneumonia
  - (2) Primary atypical pneumonia
  - (3) APC virus pneumonia
  - (4) Psittacosis
- B Bacterial capable of total resolution (usually lobar)
  - (1) Pneumococcal
  - (2) H influenza
- C. Bacterial often or generally associated with lung destruction (often lobar may be lobular)
  - (1) Klebsiella
  - (2) Staphylococcus
  - (3) Streptococcus
  - (4) Tuberculosis

II Secondary Pneumonia (can be of any pathologic description)
- A Incidental to generalized disease
  - (1) Viral
    - (a) Chicken pox
    - (b) Measles
    - (c) Influenza
  - (2) Rickettsial
    - (a) Q fever
  - (3) Bacterial
    - (a) Anthrax
    - (b) P pestes (pneumonic plague)
    - (c) P Tularensis
  - (4) Allergic
    - (a) Loeffler s pneumonia (tropical eosinophilia)
- B Chemical or Inhalant
  - (1) Lipoid
  - (2) War gases (certain)
  - (3) Smoke
- C Obstructive
  - (1) Pulmonary emphysema
  - (2) Adenoma or carcinoma
  - (3) Foreign body
  - (4) Mucus plugs
- D Associated with poor drainage ineffective cough abnormal airway action and/or depressed cough mechanisms
  - (1) Bronchiectasis
  - (2) Postoperative
  - (3) Neurological disease
  - (4) Paralytic states including
    - (a) Poliomyelitis
    - (b) Guillain Barre s disease
  - (5) Comatose any cause
  - (6) General debility and loss of cough reflex
  - (7) Medication with loss of cough reflex (e g morphine or codeine)

Laboratory isolation of the offending pathogen is the sine qua non of sensible therapy of pneumonia Other laboratory aids for the differentiation of the various types of infective pneumonia are as important In every instance a patient with suspected pneumonia should have a specimen of his sputum and blood examined for micro-organisms prior to the institution of even a single dose of drug Results of these examinations may not be available for interpretation for several perhaps forty eight hours and interim therapy may often be indeed usually is needed Adjustment to proper drug in proper amounts can be made when they are available This statement seems *sensible but the sequence is too frequently* omitted It would be presumptuous to describe laboratory technics for isolation of organism from blood or sputum, it is not presumptuous to suggest that a laboratory be allowed the opportunity to examine the body fluid uninfluenced by the presence of a drug within it Similarly, information about the type of pneumonia can be derived from examination of the patient s white blood cell count of his serum for heterophile agglutination or cold or type specific antibodies Roentgenograms of chest in varying positions are also needed information

One single suggestion for the obtaining of sputum from a patient who does not cough can be proffered Careful swabbing of posterior pharyngeal wall will often lead to the proper bacteriologic result and the procedure may make the patient cough In this way a small amount of lung secretion becomes available

immediately for examination A solid blow on the patient s chest may also result in a productive cough

Failure of patients with pneumonia to respond to any therapeutic regimen may be due to factors other than a poor drug choice or constitutional defects in the host He must enjoy reasonable efficiency of respiratory motion an active gag reflex, the ability to cough adequately enough to raise secretions integrity of bronchial mucosa without metaplasia and competent ciliary action Without these removal of the products of the inflammation or foreign bodies are infinitely more troublesome and the pneumonia can persist to cause further lung damage Similarly any local obstructive lesion such as new growth or extraneous bodies or previously formed anatomic defects and pockets of pus delay the body s ability to resolve inflammation With this organization supervenes and total remission is made impossible

Infective pneumonia should resolve completely and most do so with proper therapy Occasionally, as is discussed later purulent and non purulent complications develop Empyema pericarditis meningitis and pyoarthritis evolve from local and blood borne spread of organism from the pulmonary focus This progressive disease ensues in the presence of poor host defenses and generally becomes evident ten or so days after onset of the initial infection Each of these deserves special kinds of therapy such as drainage antibiotics and often surgery Similarly in the presence of infection of serious nature non purulent complications endanger life The acidosis of infection can lead to embarrassing fluid and electrolyte imbalance grave loss of chloride base heart failure and even paralytic ileus These too demand extra therapeutic measures

Perhaps the event which is least desirable and fraught with potential trouble is the pneumonia which fails to resolve either properly or promptly Under favorable circumstances pneumonia resolves completely within three or four weeks at the most sooner in some At the end of the fourth week roentgenograms should be clear If they are not some factor other than infection is undoubtedly present and the failure of resolution requires investigation Perhaps it is wise to recommend even insist that bronchoscopy be performed after the third week if resolution has not progressed satisfactorily in any patient over thirty five Bronchogenic carcinoma not infrequently becomes clinically evident for the first time at the onset of classical pneumonia

There are pitfalls in the diagnosis of pneumonia an index of suspicion that there is more than mere infection should be universal Perhaps the major negligence is failure to identify either aspirated material (safety pin bone peanut) or a new growth such as an adenia impressated mucous plug or carcinoma Rales may be missed a persistent inspiratory wheeze in the lateral position may not be heard and the historical account of coma or vomiting not obtained A tidy diagnosis can be secured only with these essential data Without them too any prediction of the potential course of the pneumonia would be unwarranted

All of these factors are necessary considerations in the understanding and management of a patient with pneumonia It is common experience to observe a patient s response to specific antimicrobial therapy as being satisfactory—even gratifying—without concomitant study of his problem It is tragic to observe the physician s chagrin at a patient s poor response to such treatment two weeks after its commencement because he failed to recognize an important underlying defect in health or lung which might have been remedied earlier

40

Chemotherapy in Acute Pneumonias

PAUL A BUNN, M D, *Syracuse, New York*

From the State University of New York Upstate Medical Center Syracuse N Y Laboratory work performed as part of the studies on acute pneumonia was supported by grants from Bristol Laboratories, Inc, Syracuse and from the Research Grants Committee of the American Trudeau Society, the Medical Section of the National Tuberculosis Association

SINCE 1936 acceptable clinical practice has dictated that each patient with pneumonia be treated with one or more antimicrobial agents Indeed, this habit has extended further, patients with respiratory complaints of any order now generally receive one or more antimicrobial agents, presumably as specific therapy, whether or not there are clinical, bacteriologic or roentgenographic evidences of respiratory infection Such consuetude is so common that the time-tested practices of defining etiologic agent of infection and/or defining pathologically and anatomically the infected portion of the respiratory tract early in its course are avoided Because the outcome of the majority of acute pulmonary infections is so successful with this type of treatment, without performance of precise diagnostic measures it is perhaps temerarious to suggest that acute pulmonary infections should be studied routinely in a more exhaustive fashion The purpose of this section, however, is to point up certain distracting elements in our knowledge and in the results of treatment of acute pneumonias, recognition of these defects might encourage more physicians to return to older habits of study of a patient and his infections in the hope that knowledge can increase It is emphasized that present customs of therapeusis are not necessarily proper or wise ones

MORTALITY RATE

The attainment of a truly satisfactory mortality rate in pneumonia has not yet been achieved [1] Acute respiratory infections including pneumonia still account for a significant number of deaths each year in every community In 1952, for example, more than 20 deaths per 100 000 population in New York State were caused by pneumonia (Fig 1) Mortality rates from 1900 to 1947

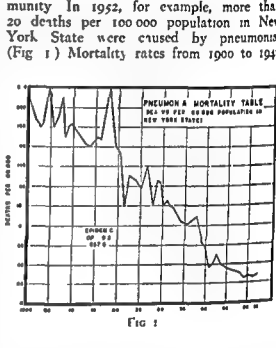

Fig 1

were reduced impressively, these successes due perhaps in some measure to the antipneumococcal serums and later to chemotherapeutic agents It is on the other hand, clearly shown that mortality rates in the past five years have not declined further, and that the number of deaths in 1953 and 1954 appears to be of the same order as those in the previous five years Failure to improve mortality rates is interesting because since 1949 at least six new agents have been described, and various combinations of older materials have been used with increasing frequency in the treatment of pulmonary infections

Similarly, superficial examination of case fatality rates in pneumonia reveals that there has been an impressive improvement in the survival figure of patients who have pneu

nonia Actually the over-all case fatality rate s now less than 5 per cent, a remarkable ac- omplishment in medicine (Fig 2) However, his, like the total mortality rate, has not shown gnificant change during the past five years hese observations demonstrate that some-

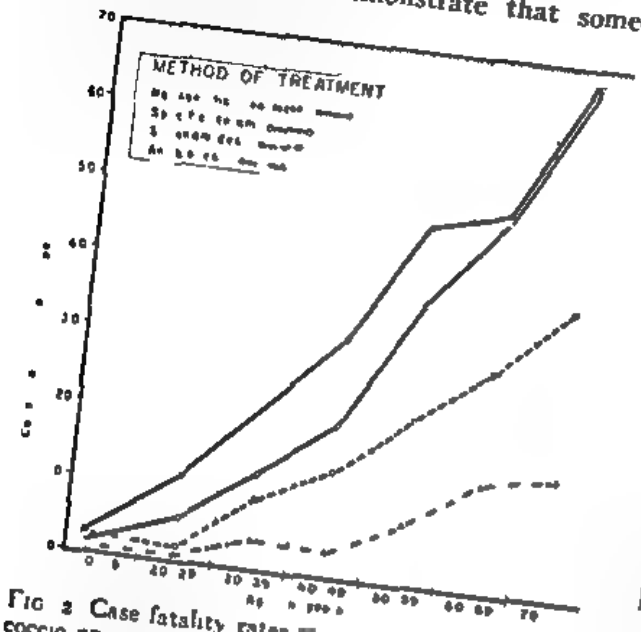

FIG 2 Case fatality rates in patients with pneumo coccic pneumonia in relation to age Redrawn from Dowling and Lepper

thing more than a specific antibacterial or antiviral treatment regimen is needed to control finally and effectively pneumonia in any community

Other features about pulmonary infections deserve explanation and demonstrate the necessity for careful study of each patient The fearfully high mortality rate is continuing in individuals over sixty-five, in infants under two years and in those who have other chronic and debilitating infections such as cirrhosis (Fig 2) Also the number of non fatal and non purulent complications following pneu monia has not been reduced significantly even with proper regimentation of antimicrobial therapy, indeed, some complications seem to occur more often This is particularly true in the number of cases in which reduced lung function develops on a permanent basis follow ing chemotherapeutic measures

We therefore cannot be satisfied that the present good therapy is necessarily best therapy for acute pneumonia It is a true challenge to the physician and surgeon to improve present morbidity and mortality figures This challenge can be met only if there is a further effort to understand the disease and the host who has the infection It will not be met if the disease is not studied in each individual and if therapy is designed in a strictly arbitrary fashion Three fundamental considerations in usage of

TABLE I

CLASSES OF ACUTE PRIMARY PNEUMONIA (EMPIRIC)

I Undifferentiated acute respiratory infection with pneumonitis
  Presumably of virus etiology generally occurs in young adults and has negligible mortality
II Pneumococcic pneumonia
  Less than 6% mortality with antimicrobial therapy complications occur in 10–15% of all cases
III Necrotizing pneumonia
  Less than 4% of all pneumonia caused by klebsiella streptococci and staphylococci associated with more than 30% mortality and 60% complication rate

drugs which if not ignored might lead to more successful treatment in a few will be discussed Perhaps if these were understood they could lead to other answers to the many problems

The treatment schedule of gram-positive coccal pneumonias is too often clumsy, expensive and prolonged Although not necessarily antibacterially improper, simpler regimens les sen the number of untoward side effects from drugs and without loss of therapeutic efficacy Therapy for the less common bacterial pneu monias must and can be improved and certain new recommendations will be presented Fi nally antibacterial treatment in certain com mon pulmonary infections is needless and worthless Without drugs dangerous and even fatal toxic reactions are averted

CLASSIFICATION OF INFECTIONS

For purposes of simplicity pulmonary infec tions are divided into primary and secondary groups The primary group is divided arbitrar ily into three major classes (Table I) The first and most common is undifferentiated acute respiratory infections with pneumonitis or primary atypical pneumonia of unknown etiology (A R D) which is characterized by acute non-destructive inflammation, primarily in the tracheobronchial tree The second class includes those bacterial pneumonias which are capable of total resolution without scar under the proper therapeutic program Pneumococci and streptococci are the typical examples The third group includes the pneumonias asso-

40

Chemotherapy in Acute Pneumonias

PAUL A BUNN, M D, *Syracuse, New York*

From the State University of New York, Upstate Medical Center Syracuse, N Y Laboratory work performed as part of the studies on acute pneumonia was supported by grants from Bristol Laboratories, Inc, Syracuse, and from the Research Grants Committee of the American Trudeau Society, the Medical Section of the National Tuberculosis Association

SINCE 1936 acceptable clinical practice has dictated that each patient with pneumonia be treated with one or more antimicrobial agents Indeed, this habit has extended further, patients with respiratory complaints of any order now generally receive one or more antimicrobial agents, presumably as specific therapy, whether or not there are clinical, bacteriologic or roentgenographic evidences of respiratory infection Such consuetude is so common that the time-tested practices of defining etiologic agent of infection and/or defining pathologically and anatomically the infected portion of the respiratory tract early in its course are avoided Because the outcome of the majority of acute pulmonary infections is so successful with this type of treatment, without performance of precise diagnostic measures, it is perhaps temerarious to suggest that acute pulmonary infections should be studied routinely in a more exhaustive fashion The purpose of this section, however, is to point up certain distracting elements in our knowledge and in the results of treatment of acute pneumonias, recognition of these defects might encourage more physicians to return to older habits of study of a patient and his infections in the hope that knowledge can increase It is emphasized that present customs of therapeusis are not necessarily proper or wise ones

MORTALITY RATE

The attainment of a truly satisfactory mortality rate in pneumonia has not yet been achieved [1] Acute respiratory infections including pneumonia still account for a significant number of deaths each year in every community In 1952, for example, more than 20 deaths per 100,000 population in New York State were caused by pneumonia (Fig 1) Mortality rates from 1900 to 1947

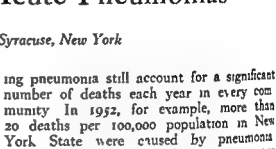

FIG 1

were reduced impressively, these successes due perhaps in some measure to the antipneumococcal serums and later to chemotherapeutic agents It is, on the other hand clearly shown that mortality rates in the past five years have not declined further, and that the number of deaths in 1953 and 1954 appears to be of the same order as those in the previous five years Failure to improve mortality rates is interesting because since 1949 at least six new agents have been described, and various combinations of older materials have been used with increasing frequency in the treatment of pulmonary infections

Similarly, superficial examination of case fatality rates in pneumonia reveals that there has been an impressive improvement in the survival figure of patients who have pneu

monia Actually the over-all case fatality rate is now less than 5 per cent, a remarkable accomplishment in medicine (Fig 2) However, this, like the total mortality rate, has not shown significant change during the past five years These observations demonstrate that some-

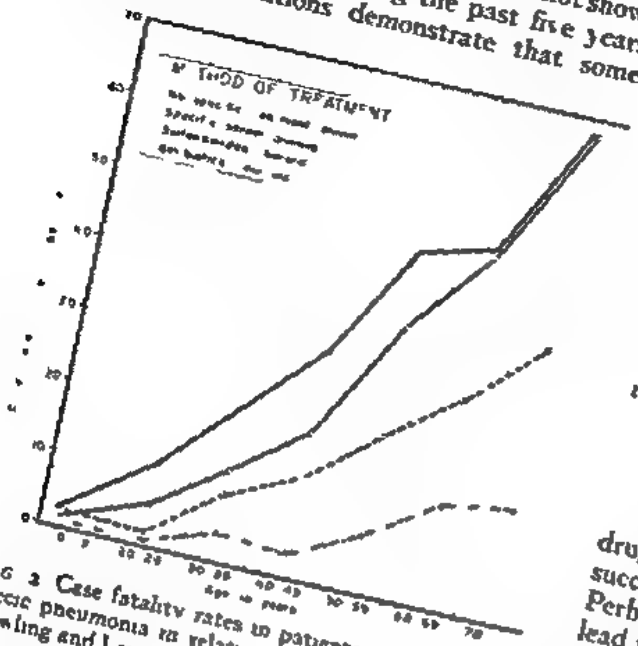

FIG 2 Case fatality rates in patients with pneumococcic pneumonia in relation to age Redrawn from Dowling and Lepper [1]

thing more than a specific antibacterial or antiviral treatment regimen is needed to control finally and effectively pneumonia in any community

Other features about pulmonary infections deserve explanation and demonstrate the necessity for careful study of each patient The fearfully high mortality rate is continuing in individuals over sixty five in infants under 0 years and in those who have other chronic and debilitating infections such as cirrhosis (Fig 2) Also, the number of non fatal and non purulent complications following pneumonia has not been reduced significantly, even with proper regimentation of antimicrobial therapy, indeed, some complications seem to occur more often [1] This is particularly true in the number of cases in which reduced lung function develops on a permanent basis following chemotherapeutic measures

We therefore cannot be satisfied that the present good therapy is necessarily best therapy for acute pneumonia It is a true challenge to the physician and surgeon to improve present morbidity and mortality figures This challenge can be met only if there is a further effort to understand the disease and the host who has the infection It will not be met if the disease is not studied in each individual and if therapy is designed in a strictly arbitrary fashion Three fundamental considerations in usage of

TABLE 1

CLASSES OF ACUTE PRIMARY PNEUMONIA (EMPIRIC)

I Undifferentiated acute respiratory infection with pneumonitis
Presumably of virus etiology, generally occurs in young adults and has negligible mortality

II Pneumococcic pneumonia
Less than 6% mortality with antimicrobial therapy complications occur in 10-15% of all cases

III Necrotizing pneumonia
Less than 4% of all pneumonia caused by Klebsiella, streptococci and staphylococci associated with more than 30% mortality and 60% complication rate

drugs which if not ignored might lead to more successful treatment in a few will be discussed Perhaps if these were understood they could lead to other answers to the many problems

The treatment schedule of gram positive coccal pneumonias is too often clumsy, expensive and prolonged Although not necessarily antibacterially improper, simpler regimens lessen the number of untoward side effects from drugs and without loss of therapeutic efficacy Therapy for the less common bacterial pneumonias must and can be improved, and certain new recommendations will be presented Finally antibacterial treatment in certain common pulmonary infections is needless and worthless Without drugs dangerous and even fatal toxic reactions are averted

CLASSIFICATION OF INFECTIONS

For purposes of simplicity, pulmonary infections are divided into primary and secondary groups The primary group is divided arbitrarily into three major classes (Table 1) The first and most common is undifferentiated acute respiratory infections with pneumonitis or primary atypical pneumonia of unknown etiology (A R D) which is characterized by acute non-destructive inflammation, primarily in the tracheobronchial tree The second class includes those bacterial pneumonias which are capable of total resolution without scar under the proper therapeutic program Pneumococci and streptococci are the typical examples The third group includes the pneumonias asso-

40

Chemotherapy in Acute Pneumonias

PAUL A BUNN, M D, *Syracuse, New York*

From the State University of New York, Upstate Medical Center Syracuse, N Y Laboratory work performed as part of the studies on acute pneumonia was supported by grants from Bristol Laboratories, Inc, Syracuse, and from the Research Grants Committee of the American Trudeau Society the Medical Section of the National Tuberculosis Association

SINCE 1936 acceptable clinical practice has dictated that each patient with pneumonia be treated with one or more antimicrobial agents Indeed, this habit has extended further, patients with respiratory complaints of any order now generally receive one or more antimicrobial agents, presumably as specific therapy, whether or not there are clinical, bacteriologic or roentgenographic evidences of respiratory infection Such consuetude is so common that the time-tested practices of defining etiologic agent of infection and/or defining pathologically and anatomically the infected portion of the respiratory tract early in its course are avoided Because the outcome of the majority of acute pulmonary infections is so successful with this type of treatment, without performance of precise diagnostic measures, it is perhaps temerarious to suggest that acute pulmonary infections should be studied routinely in a more exhaustive fashion The purpose of this section, however, is to point up certain distracting elements in our knowledge and in the results of treatment of acute pneumonias, recognition of these defects might encourage more physicians to return to older habits of study of a patient and his infections in the hope that knowledge can increase It is emphasized that present customs of therapeusis are not necessarily proper or wise ones

MORTALITY RATE

The attainment of a truly satisfactory mortality rate in pneumonia has not yet been achieved [1] Acute respiratory infections including pneumonia still account for a significant number of deaths each year in every community In 1952, for example, more than 20 deaths per 100,000 population in New York State were caused by pneumonia. (Fig 1.) Mortality rates from 1900 to 1947

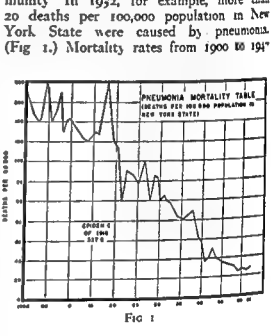

FIG 1

were reduced impressively, these successes due perhaps in some measure to the antipneumococcal serums and later to chemotherapeutic agents It is, on the other hand clearly shown that mortality rates in the past five years have not declined further, and that the number of deaths in 1953 and 1954 appears to be of the same order as those in the previous five years Failure to improve mortality rates is interesting because since 1949 at least six new agents have been described, and various combinations of older materials have been used with increasing frequency in the treatment of pulmonary infections.

Similarly, superficial examination of case fatality rates in pneumonia reveals that there has been an impressive improvement in the survival figure of patients who have pneu

monia Actually the over all case fatality rate is now less than 5 per cent, a remarkable accomplishment in medicine (Fig 2) However, this, like the total mortality rate, has not shown significant change during the past five years These observations demonstrate that some-

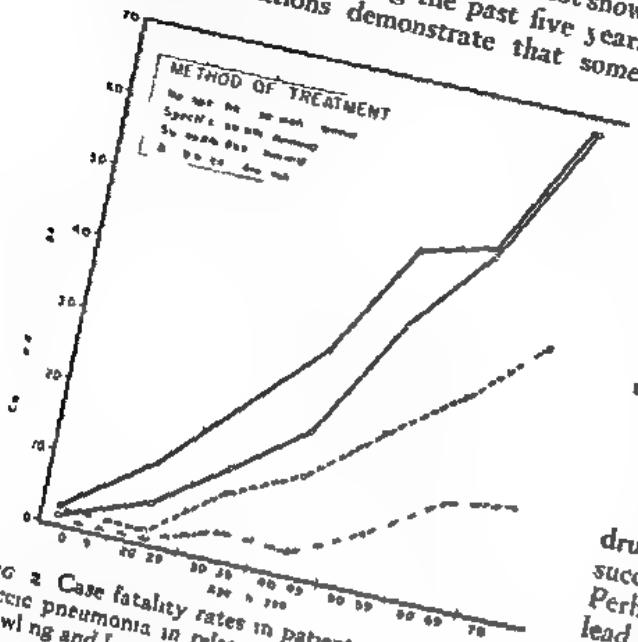

FIG 2 Case fatality rates in patients with pneumococcic pneumonia in relation to age Redrawn from Dowling and Lepper 1

thing more than a specific antibacterial or antiviral treatment regimen is needed to control finally and effectively pneumonia in any community

Other features about pulmonary infections deserve explanation and demonstrate the necessity for careful study of each patient The fearfully high mortality rate is continuing in individuals over sixty five, in infants under two years and in those who have other chronic and debilitating infections such as cirrhosis (Fig 2) Also, the number of non fatal and non purulent complications following pneumonia has not been reduced significantly, even with proper regimentation of antimicrobial therapy indeed, some complications seem to occur more often 1/This is particularly true in the number of cases in which reduced lung function develops on a permanent basis following chemotherapeutic measures

We therefore cannot be satisfied that the present good therapy is necessarily best therapy for acute pneumonia It is a true challenge to the physician and surgeon to improve present morbidity and mortality figures This challenge can be met only if there is a further effort to understand the disease and the host who has the infection It will not be met if the disease is not studied in each individual and if therapy is designed in a strictly arbitrary fashion Three fundamental considerations in usage of

TABLE 1

CLASSES OF ACUTE PRIMARY PNEUMONIA (EMPIRIC)

I Undifferentiated acute respiratory infection with pneumonitis
Presumably of virus etiology generally occurs in young adults and has negligible mortality

II Pneumococcic pneumonia
Less than 6% mortality with antimicrobial therapy complications occur in 10–15% of all cases

III Necrotizing pneumonia
Less than 4% of all pneumonia caused by klebsiella streptococci and staphylococci associated with more than 30% mortality and 60% complication rate

drugs which if not ignored might lead to more successful treatment in a few will be discussed Perhaps if these were understood they could lead to other answers to the many problems

The treatment schedule of gram positive coccal pneumonias is too often clumsy, expensive and prolonged Although not necessarily antibacterially improper, simpler regimens lessen the number of untoward side effects from drugs and without loss of therapeutic efficacy Therapy for the less common bacterial pneumonias must and can be improved and certain new recommendations will be presented Finally antibacterial treatment in certain common pulmonary infections is needless and worthless Without drugs dangerous and even fatal toxic reactions are averted

CLASSIFICATION OF INFECTIONS

For purposes of simplicity, pulmonary infections are divided into primary and secondary groups The primary group is divided arbitrarily into three major classes (Table 1) The first and most common is undifferentiated acute respiratory infections with pneumonitis or primary atypical pneumonia of unknown etiology (A R D) which is characterized by acute non destructive inflammation, primarily in the tracheobronchial tree The second class includes those bacterial pneumonias which are capable of total resolution without scar under the proper therapeutic program Pneumococci and streptococci are the typical examples The third group includes the pneumonias asso

ciated generally with high mortality, and with lung destruction, abscess formation, eventual fibrosis and emphysema in those few who survive Klebsiella organisms produce this variety most commonly, staphylococci and streptococci may also cause it Of all acute pulmonary infections, those caused presumably by viruses are sixfold more common than are the bacterial varieties Of the bacterial pneumonias, pneumococci are the responsible agents in approximately 90 per cent, Klebsiellas are responsible for about 4 per cent of the total and miscellaneous organisms cause the remaining

Secondary pneumonia, that is, a pulmonary complication following primary infection in some other part of the body, may be caused by any species of bacterium and will not be discussed Generally the pulmonary affliction is not necessarily the important part of the total infection Treatment is, of course, directed principally at the primary cause, the lung disease requiring added therapy

IDENTIFICATION OF ORGANISM

If any acute pulmonary infection is to be treated satisfactorily and to best advantage, the etiologic agent must be recognized and isolated In a sense it is unfortunate that the vast majority of bacterial pneumonias are of pneumococcal origin Because of their prevalence and because they are very susceptible to most antimicrobial agents, it might seem impractical to isolate routinely the causative organisms in patients with pneumonia This is not so, for unfortunately the 10 per cent of bacterial pneumonias, caused by other organisms which have varying susceptibilities to antimicrobial agents, have clinical courses closely simulating that of the pneumococcus To treat them properly, precise identification of the organisms is thus essential in every case

Identification of organisms generally is not a difficult task Because most pneumonias are caused by single strains of organisms rather than by two or three different pathogens the sputum is a good sample of the bacterial population causing infection within the lung *Pneumococcus, streptococcus, staphylococcus,* Klebsiella and others are readily recognizable, even by the untrained physician, on a gram-stained specimen This procedure, then, is the *first diagnostic procedure required* in the management of a patient who has an acute pulmonary infection Of course cultures are needed, but *identification* of the causative pathogen requires from eighteen to twenty *four hours and* often treatment cannot be so long delayed

Unlike the central nervous system and some other bodily tissues, penicillin as well as all other *presently used* antimicrobial agents penetrates readily, quickly and in good concentration into pulmonary tissue from blood Certainty of good *distribution of drug into an* infected lung is not, in most cases, therefore a knotty one if there is sensible prescription of drug /The major exception to this general rule is the *lung which is not normal* Pulmonary fibrosis and emphysema are associated with a decreased blood supply In such instances the barrier between serum concentration and amount of drug penetrating directly into the site of inflammation may be discrepant In order to overcome the barrier due to lack of blood supply, dosage of any drug must be increased Similarly, in the presence of acute pulmonary infections associated with tissue destruction dosage of drug must be increased for necrosis is characterized also by decreased blood supply It becomes essential, then, to recognize not only the etiologic agent but also the anatomic defect of penetration of drug into *area of inflammation that might exist at the* time the patient is infected Unless the drug does get into the inflamed area where the organisms are, there cannot be intimate drug bug exposure which is so necessary for effective and beneficial action

DRUG REGIMEN

Any treatment program must have certain attributes There must be as abrupt a halting of the clinical illness as is possible, the schedule must be associated with a high cure rate, it must be accompanied by the absence of, or a minimal amount of, progression of inflammation early in its course, and there must be a tolerably low relapse rate following cessation of the treatment It is therefore essential not only that the proper program be designed, but also that it be continued for as long as it seems necessary to accomplish these ends

There is no over all easy description of treatment which can apply to all infections It is certainly true that no drug presently available is capable of so sterilizing pulmonary infectious lesions that the host does not have to participate in the final eradication of organisms

Indeed he must. The most that can be accomplished with drug therapy is a prompt and continued decrease in bacterial population at the site of inflammation and a prevention of regrowth of these organisms With these, the host has an easier job of accomplishing the final sterilizing procedure which, of course, is necessary for the eventual cure Unless the host accomplishes this desirable end, the mobilization of his own effective defenses, the infection becomes fatal Although not possible of precise measurement, both cellular and humoral defenses play the final and essential role in the achievement of cure Drug, then, is necessarily continued for as long as the host is incapable of forming sufficient antibodies and other defenses or until they have been formed and are concentrated in effective levels at the inflamed site

In an otherwise healthy host with pneumococcal pneumonia, for example, sufficient antibody for cure is developed within a five day period, consequently, specific therapy need not be continued for a longer time Contrariwise, in the case of klebsiella pneumonia, antibody formation (although formed early) may not reach an adequate concentration for more then ten days In this instance treatment is continued for from two to three [illegible]

Similarly [illegible]
is slow in [illegible]
peak concc [illegible] for final eradication of all organisms For maximum effect, therefore, drugs are prescribed for many months or even years in cases of tuberculosis The host with an otherwise debilitating disease (such as cirrhosis or heart disease, diabetes or the like) also finds it difficult to produce antibody and other defenses rapidly, and their mobilization is delayed, sometimes indefinitely Therefore, drug therapy must be continued for longer periods of time in the individual who is known to be deficient in ability to form antibody than in the individual who is otherwise normal Duration of treatment consequently can be determined only by close clinical observation on the part of the physician at the bedside of the individual patient The physician has only certain minor laboratory procedures to aid him in this decision the white blood cell count, fever, sedimentation rate, general appearance of the patient, changes in physical signs in the chest, x ray, etc It is his own decision that treatment must be continued for a minimum of five days in all acute pneumonias, or longer in some individuals

With knowledge of invading microorganism, type of inflammation produced by it and the general health of the host, design of a dosage schedule of the proper drug can be outlined, i e, amount of first dose, interval between priming doses and route of administration In general, some bacteria exposed to an antagonist are killed, some are so affected that they cannot reproduce, and most at least are rendered non-infectious Furthermore, following termination of exposure to drug, the remaining viable organisms require a certain period of time for recovery prior to their becoming invasive again For example, in the case of pneumococcal pneumonia 100,000 units of penicillin maintain adequate pulmonary levels of drug for three to four hours, during all of which time organisms are dying or are non-invasive The recovery phase of pneumococci extends for four or six hours after the pulmonary levels of drug fall below effective concentration Thus a single dose of penicillin protects the host against further invasion by pneumococci for from seven to ten hours In this instance, then, intervals between 100,000 unit doses of penicillin need not be more than eight or nine hours Common regimens now in use for treatment of pneumococcal pneumonias include excessive and unnecessary amounts of penicillin Simpler programs, and yet as safe, certainly are far less expensive to the patient and reduce his chance of having an untoward reaction to the treatment itself This is our first recommendation treat as simply as the infection warrants To do so requires keen knowledge about the patient and his infection

Dosages of chlortetracycline, oxytetracycline, chloramphenicol, other tetracycline analogs and erythromycin are similarly designed, except that total daily dose should exceed 1 gm and preferably 1½ gm When insoluble drugs are used (which property assures a constant lower blood level), interval between dosages can of course be extended, dependent solely upon degree of insolubility and height of blood level Route of administration of drug is important only in that it must assure good absorption of the material into blood For instance, it is dangerous to administer an agent by mouth if the patient has any disturbance of gastrointestinal functions such as vomiting, distention or ileus Because there is

usually a discrepancy between amount of drug absorbed from the intestinal tract and that absorbed from a muscle depot, prescription of drug should include amounts sufficient to overcome the difference It requires five- to tenfold more of any one of the broad spectrum agents given by the oral route to equal blood levels obtained from an intramuscular or intravenous dose, in the case of penicillin three- to fivefold more by mouth is needed

In effect then choice of regimen in most instances depends *in major part upon convenience* to patient and physician, less important is size of dose and interval between doses *if the right drug has been chosen and the* physician understands the local lung problem well

Pneumonia developing one to *four days* postoperatively brings to light some of these factors which emphasize that there can be no standardized drug therapy for acute pulmonary infections Usually, and probably most often, the development of parenchymal shadows respiratory symptoms and fever in such patients is not due primarily to infection alone Because of pain anesthesia or narcosis the patient is unable to breathe properly, to aerate well and to clean the respiratory tree of the excessive secretions which are associated with anesthesia and pain A nidus for infection is set up Mechanical or physiologic obstruction produces atelectasis or collapse of lung segments large or small and this uniformly precedes and encourages growth of organisms in the area With removal of the cause of atelectasis and poor aeration the infection clears promptly Without it the infection cannot be resolved regardless of amount of drug administered Similarly, the individual in the postoperative period is incapable of rapidly or effectively mobilizing defense mechanisms

Recoveries from such infections then are not associated with antibacterial prescription, for they are of secondary importance The patient gets well as his ability to defend himself and to clean out his air passages is increased This is not to say that penicillin, or a combination of penicillin and streptomycin is not warranted in such complications Indeed they are However their usefulness is of a prophylactic nature They are used to prevent growth of a number of bacteria in the lung, making *the airless portions of the lung* less susceptible to spreading infection and this is their major usefulness

Although single drug therapy *for most pulmonary* infections is sufficient, there is an occasional real indication for the simultaneous administration *of two agents When a causative* pathogen is partially resistant to one or more antimicrobial agents often a second drug *increases the degree of effectiveness of the* first This is described in the treatment of Klebsiella pneumonia although an explanation *cannot be offered for what is apparently* synergism between drugs The use of two drugs in certain clear-cut instances will reduce the *opportunity for the emergence of organisms* resistant to one or the other of two agents For example in pulmonary tuberculosis the combined use of two antimicrobial agents (streptomycin and para aminosalicylic acid) is associated with the maintenance of sensitivity of Mycobacterium tuberculosis to *both drugs* for longer periods of time than occurs with the use of either of the aforementioned drugs Combination therapy is also needed in certain instances where more than one organism is involved in the production of the acute infection This is true frequently in acute exacerbations of pneumonitis associated with chronic bronchiectasis The indications for the use of two drugs in this instance are determined *by* careful evaluation of organisms in the sputum

There are clear reasons on the other hand why combined therapy *should be avoided* whenever possible The development of untoward side reactions to single drug is always a stated risk With the use of two *drugs that* risk is doubled With the use of three drugs it probably more than triples Although most *hypersensitivity phenomena do no more than* inconvenience the physician and the patient they can be serious on occasion even to the *point of death from anaphylaxis The avoid*ance then of an increased chance for hypersensitivity phenomenon to develop is a sensible *reason for the prescription of a single drug*

Finally the bacterial milieu in each of our body cavities is important for our general over *all good health A major and* unnecessary shift of bacterial flora from the administration of an antibiotic often causes unfortunate side reactions including biliary dysfunction gastrointestinal disturbances and bowel irregularities It is logical to presume that two drugs acting upon the bacterial flora of the intestinal tract

cause a much more major and deleterious shift in the flora than does one drug It is for this reason also that combined therapy should be avoided whenever possible

The philosophy should obtain, then, that the indications for the use of two drugs rather than one, must be that they supply the host with more benefit than the added dangers to him of combined drugs

PNEUMOCOCCAL PNEUMONIA

Pneumococcal pneumonia develops in individuals whose respiratory tree has been damaged in some fashion, such as by an irritant, a chemical or an infection It is an acute disease with striking signs and symptoms It is easily recognized by clinical picture The organisms are simple to identify in stained smears of the sputum, and the infection is practically always associated with a positive and diagnostic roentgenogram

The incidence of pneumonia has decreased appreciably in the past ten years but the disease is still a common one in present society Despite its frequency, man has a striking resistance to it The organisms are delicate ones, frequently present as parasites in the upper respiratory tree of man They produce no exotoxin and cause damage specifically in lung by invasion only Their pathogenic career in the human lung is unique because they do not destroy tissue The number of patients with pneumonia who have positive blood cultures continues to be high, approximately 20 to 25 per cent have bacteremia, and the incidence has not been changed with the advent of effective chemotherapy During the infection organisms are found in the edema zone surrounding the inflamed portion of lung On their invasion into pulmonary tissue the host responds with the immediate development of increased vascularity, with a concentration of many phagocytes and with the extra production of edematous fluid surrounding the area White blood cells are most effective in phagocyting organisms, and they become active within a very few hours of the onset of infection These cellular defenses eventually eradicate all organisms and because they do it so effectively, the host is left with no lasting immunity The participation of specific phagocytosis is needed for the successful outcome in every patient Other defenses are also quickly mobilized, particularly antibodies neutralizing the path[illegible] [illegible]aps

Th[illegible] [illegible] infection in patients who have pneumococci in the lung If the host and his lung are reasonably healthy, all goes well with rapid and complete resolution without scar and eventual eradication of all organisms with or without specific antibacterial treatment Almost any regimen of drug therapy is adequate With treatment, drugs kill the organisms early, rapidly and to a great degree, thus aiding the host while he is most acutely ill Antibody is formed in a four or five-day period Treatment with drug need be continued only for as long as antibody is not present in maximum concentration i e, for four to six days For maximal effect and for best results of treatment, the early institution of drug is needed With it febrile crisis and the clinical improvement of the patient occurs usually within thirty-six hours, without it, the crisis occurs after the seventh day Final resolution of the inflamed lung will require from ten to twenty days

In a less healthy host or in one who has a previously permanently damaged lung there is a delay in resolution and organization of the pneumonia occurs Fibroblastic invasion of the inflamed lung precedes the eventual development of pulmonary fibrosis and some degree of emphysema This occurs in 10 to 15 per cent of patients who have pneumococcal pneumonia That the host is incapable of resolving the pneumonia is unfortunate, but the outcome is not determined by the treatment Rather, the poor results are due to previous lung damage or inability of the host to defend himself effectively

In very ill old people or in infants or in those with another debilitating associated disease who cannot develop sufficient defenses, purulent complications and even death occur In such circumstances the polymorphonuclear leukocytes are overwhelmed, there is eventual gain on the part of the organism, spread of infection locally and by hematogenous route occurs, and the host loses life or lung In order to avoid these the antibiotic which is the most effective which acts the most rapidly and kills the most organisms is required, and it must be prescribed promptly Delay in treatment increases the opportunity for spread of infection and a poor result

Penicillin remains the drug of choice for

treatment of pneumococcal pneumonia Chlortetracycline, oxytetracycline, tetracycline, streptomycin, erythromycin and the sulfonamides kill less numbers of pneumococci, do so less rapidly and are more toxic to the host However, all are very effective weapons in its management Penicillin must, at least, be administered to the weak host Choice of drug is less important in the otherwise healthy person [2]

KLEBSIELLA PNEUMONIA

Klebsiella causes an acute pulmonary infection which is associated with rapid lung destruction, abscess formation and eventually, if the patient survives, with a permanently damaged lung

The organisms are plump, gram-negative, in diploid form and have a thick capsule Type A is the most common strain and causes the worst infection When present as an acute infection in the lung of man, there is an immediate mortality of almost 80 per cent without treatment, and a serious, even morbid, infection in the remaining With all treatment programs described to date mortality still exceeds 50 per cent in most series [2] It is the single bacterial pathogen in pneumonia which has remained without a satisfactory outline of treatment, despite the availability of ten or more antimicrobial drugs which in the test tube would appear to have some deleterious effect upon its growth

The acute disease in man is an abrupt, fulminating infection associated with tenacious, purulent and occasionally bloody mucoid sputum Delirium, often a low white blood cell count, low fever, jaundice and ileus are also commonly observed Despite the fulminat-

serious and uncontrolled diabetes or other debilitating diseases, or in patients who are capable of forming defenses in a most ineffective manner With these exceptional differences, the infection is like pneumococcal pneumonia and is often difficult to separate clinically

Pathologically, the infection is characterized by rapid tissue necrosis and, without good treatment, acute pulmonary abscesses within twenty-four to forty-eight hours of the onset of the pneumonia The disease spreads to many lobes because the organisms stimulate poor antibody response, even in the healthiest of hosts Despite acceptable treatment regimens three fifths of the patients who recover eventually have a chronic, often large lung abscess or other evidences of severe lung disease

TABLE II
RECOMMENDED REGIMEN OF TREATMENT FOR KLEBSIELLA PNEUMONIA

A Initial treatment
- (1) Aqueous penicillin—10 000 000 units daily in 8 or 12 divided intramuscular doses or by constant intramuscular drip
- (2) Streptomycin—2 gm daily in 2 doses
- (3) Tetracycline*—2–3 gm daily in 3 or 4 doses, or
  Sulfadiazine—6 gm daily in 4 oral doses

B After sensitivities are determined in laboratory
- (1) If organisms are susceptible to from 10 to 25 units of penicillin per ml discontinue the tetracycline or sulfonamide
- (2) If organisms are resistant to more than 25 units of penicillin per ml, discontinue penicillin

C Duration of treatment usually exceeds 14 days large doses of the two essential drugs are needed for a minimum of 7 days generally for 10 as infection resolves or organizes dosages can be reduced cautiously

* Oxytetracycline chlortetracycline tetracycline

Two regimens of therapy for Friedlander's pneumonia deserve comment The commonly used schedule is the administration of large amounts (2 to 3 gm) of streptomycin daily parenterally and either oxytetracycline in daily oral dosage of 3 or 4 gm or a sulfonamide [2] As a routine treatment, promptly instituted, this regimen has changed the mortality rates from 80 per cent to approximately 50 per cent It has been observed that many strains of klebsiella (approximately 50 to 60 per cent) are susceptible to penicillin in concentrations of from 10 to 12½ units per ml of serum [2] In cases caused by organisms with this degree of susceptibility, a combination of massive amounts of penicillin plus large doses of streptomycin daily effects cure more rapidly, more impressively and more effectively than the other program Twelve million units of penicillin parenterally and 2 to 3 gm of streptomycin daily for three or four days are the recommended dosages (Table II) Unfortunately penicillin susceptibility cannot be determined quickly enough Consequently, the use of three drugs (penicillin, streptomycin and one of the tetracycline analogs or a sulfonamide), all in large doses, seems the most practicable recommendation for the initial treatment

Actually, this program probably should be instituted promptly in all cases of klebsiella pneumonia and altered by the removal of penicillin only if the sensitivity tests in the laboratory later indicate that the organism is totally resistant to penicillin It has been our experience that certain patients with fulminating klebsiella infections can resolve them completely within ten to nineteen days with this regimen, as is true with pneumococcal pneumonia It is the only regimen in which this has been observed

The required element in this prescription is the prompt identification of and determination of sensitivity of the klebsiella in the laboratory This cannot be done accurately by medicated disk methods for most penicillin disks contain only 10 units of penicillin per cc and all klebsiellas automatically become resistant in fact by that method Serial dilution techniques are required to determine precisely the sensitivity of the organism to penicillin If the organism is susceptible to 25 units or less massive therapy with penicillin and streptomycin is indicated The sine qua non of the successful management of any patient with klebsiella pneumonia is the promptness with which the organism is identified and the quickness with which good treatment is instituted Single drug therapy or combination therapy in small doses is not sufficient a delay of twenty four hours can be fatal to a lung if not the host

An example of the problem of host organism relationship concerns the difference between pneumococcal and klebsiella pneumonia Both organisms are encapsulated are widely distributed in nature both cause acute pulmonary consolidation early in the courses which under the microscope are undistinguishable and both organisms have active antagonists in vitro in the form of streptomycin and penicillin respectively

In the human however, the two organisms cause significantly different diseases Pneumococcal pneumonia if treated properly subsides and resolves leaving no residual On the other hand within twenty four hours of the onset of klebsiella pneumonia lung destruction is evident inevitably in at least two-thirds of the cases some kind of lung alteration is observed and resolution is rarely completed rapidly Organization with eventual fibrosis emphysema and on many occasions bronchiectasis results this despite all presently used drug treatments The determining factor between the two infections is not the treatment but the response of the host to the bacterial infection In the case of klebsiella pneumonia the host fails to participate rapidly his lung is destroyed quickly and with this there is poor drug penetration both factors working to the disadvantage of the host This fact warrants great and concerted study at the moment there is not even a glimmer of an answer to the problem

VIRAL INFECTIONS OF LUNG

Much has been written about the efficacy of the various antimicrobial agents presently available upon the course of viral infections in the human In the presence of a known viral infection of pulmonary tissue antibacterial therapy is not necessary It is both illogical and associated with restricted risk of untoward reactions to the drug itself No presently available antibiotic is active against any but the largest of viruses, such as the rickettsias which are rare in this country Because secondary bacterial contaminants are also uncommon actually almost never observed during the course of viral pneumonia the administration of substances to prevent a bacterial contaminant in secondary fashion is not warranted

On the other hand the precise diagnosis of viral pneumonia early in its course cannot be made and on occasion is difficult to separate from a bacterial infection Similarly it is impossible to separate the treatable rickettsial pneumonias, such as Q fever and psittacosis from other viral infections Therefore it must be recommended that a broad spectrum antibacterial agent be administered for therapeutic use in any case in which the specific diagnosis is questionable and not possible by sputum smear It is emphasized that when administered the prescription is ordered for specific effectiveness and is not to be considered a prophylactic measure Dosage should therefore always be full and not lessened by thought that a secondary infection is being prevented and that it therefore requires lesser amounts of drug The choice of drug is not important. Tetracycline or any of its analogs chloramphenicol and erythromycin is probably equally efficacious Full dosage includes 1½ or 2 gm daily by mouth However in the patient whose gastrointestinal tract is functioning poorly parenteral administration is required

Because primary pneumonias due to viruses are by all odds the most common respiratory infections, it is logical to suppose that most patients with respiratory symptoms inevitably receive some antimicrobial treatment This can be condemned only in general terms Although the differential diagnosis can be exceedingly difficult, and although present habit has it that in the presence of any question the drug is given, it might be considered important now to reverse the tendency so that with the presumed diagnosis of a viral infection treatment is not given If, then, there is evidence that the infection is spreading that morbidity increases or that the sputum changes and does contain bacteria, proper drug therapy can be instituted later Perhaps a bacterial infection may be delayed in its resolution for three or four extra days by this technic Actually the physician must often philosophize He must be certain that he is accomplishing more good with treatment than harm It is the considered consensus of those who study pneumonia that the general thesis should be as follows No antimicrobial therapy for diagnosable infectious disease, in lung or elsewhere, caused by viruses is warranted

HOST

The treatment of pneumonia has undergone a rapid and wonderful change in the past fifteen years because of the advent of antimicrobial materials So much emphasis has been placed upon the regimenting of drugs that for the most part the host has been forgotten and details of the associated prescription of other substitutes for good health have been neglected

There is very little which is new in the matter A brief review, though, of those things which aid the host in his development of antibody and other protective defense mechanisms must be included in considering the fundamentals of the treatment of acute pulmonary infections After all, the host is by all odds the most important part of the triangle, and anything that the physician can do to increase health obviously aids in the response of the host to infection

It must be recalled that the individual with acute pulmonary infections in the past recovered without specific drug treatment Physicians often remember with some enthusiasm and pride the tricks which they prescribed to make a patient more comfortable during acute pneumonia and which helped in the successful management of the infection These should not be forgotten despite the presence of powerful drugs neutralizing the pathogenic career of a microorganism causing a human infection

Five separate therapies can be mentioned The patient should be put at rest in a room with an even temperature, to avoid extra body work in the matter of heat regulation He must be given mental as well as physical rest, with few demands upon him to entertain, to worry about the outcome or to fret about unessential matters Such things as clean linen cheerful surroundings and avoidance of all stresses which are unnecessary at the moment are imperative Most individuals with acute pulmonary infections are not hungry and therefore should not be required or forced to eat If fluids are supplied carefully, parenterally if necessary, so that electrolyte disturbances do not develop, absence of food does not alter the immediate outcome As the infection comes under control, the patient may be encouraged to eat as he desires, with or without salt Later during the period of recovery, a high caloric, high protein diet is desirable for the replacement of protein lost during the acute febrile phase of the illness It must be emphasized that the choice of diet early in the course of infection is unimportant

Oxygen therapy is frequently essential Dyspnea and cyanosis are the two cardinal signs for the administration of oxygen but actually any patient in pain or who is breathing with some difficulty should be given the benefit of this soothing medication It not only aids in promoting better aeration, but it also eases the distress of cough and this relieves pleural pain The mode of administration depends upon the patient's personality High concentrations of oxygen, as one obtains with a mask are not necessarily needed A tent or a nasal catheter is usually sufficient, increasing by only a few per cent the amount of oxygen in the medium in which the patient is living at the moment

Gastrointestinal distention must be eliminated, particularly if the drug being used to combat the infection is being administered orally Similarly, relief of distention allows the patient to breathe easier because motion of the diaphragm is not impaired Procedures to relieve distention are legend prostigmine

(½ mg every hour), enemas, Wangensteen tube suction, and turpentine stupes all have a place These nursing tricks actually, are just as essential for the eventual good health of the patient as is the proper administration of any drug

The relief of shock is imperative in the proper management of the patient with pneumonia Of the 5 per cent of individuals who die, development of cardiovascular shock is the major cause Blood or plasma is needed in the acute case Nor-epinephrine and possibly the use of ACTH as adjuncts to maintenance of blood pressure can be prescribed

Finally, there are miscellaneous therapies which make the patient's disease easier to endure The encouragement of cough during the stage of resolution shortens this period The patient does not have to phagocytize as much of the products of the inflammation if he removes them by coughing and expectorating Steam loosens a chronic, hard cough which is non-productive Antipyretics make the patient feel better Procaine nerve block or strapping of the chest is used for pain Codeine can be administered, but with some caution because of the problem of its interfering with needed respirations by its depressing action upon the respiratory center Lastly, for the individual who is alcoholic and has pneumonia, small amounts of intravenously administered alcohol may very well prevent the development of delirium tremens which event often is detrimental to his health and ability to overcome his infection

SUMMARY

The present treatment programs prescribed for the acute pneumonias have been helpful in reducing mortality and morbidity rates Attainment of truly satisfactory results however, has not been reached despite the availability of many antimicrobial agents Many infections simple to treat, such as pneumococcic pneumonia, have been made more complicated by the common prescription of antibiotics in excessive, clumsy and expensive fashion Other pneumonias, viral in origin, are being needlessly treated with drugs and probably often should not be Klebsiella pneumonia can be made a less morbid and mortal infection in certain instances by combined therapy with massive amounts of both penicillin and streptomycin, in addition to one of the tetracyclines

These and other considerations in the chemotherapy of acute pulmonary infections have been discussed Most importantly, however, it is emphasized that unless each patient with pneumonia is studied carefully and even exhaustively prior to prescription of drugs, knowledge will not be increased and the unsolved problems will remain needlessly enigmatic It has been shown that the morbidity and mortality of acute pulmonary infections can be reduced impressively, from 1900 to 1948 there were yearly improvements However, they are not yet perfect and should be better The empiric prescription of antimicrobial agents for all pneumonia may be lulling too many physicians into a state of false security about the infection Further careful and detailed studies into the many unanswered problems about pneumonia are warranted and are encouraged

REFERENCES

1 DOWLING H F and LEPPER M A Effect of antibiotics on fatality rates and incidence of complications in pneumococcic pneumonia Am J M Sc, 222 396–412 1951

2 BUNN P A Present trends in treatment of pneumonias New York State J Med 52 2005 2009 1952

3 BUNN P and CANARILL L. Laboratory observations to be reported

4 SMADEL, J E Present status of antibiotic therapy in viral and rickettsial disease Bull New York Acad Med 27 221 231 1951

41

Lipoid Pneumonia—Diagnosis

BRUNO W VOLK, M D, SAMUEL LOSNER, M D, ALEXANDER LEWITAN, M D AND LOUIS NATHANSON, M D, *Brooklyn, New York*

From the Department of Laboratories and the Department of Radiology, Jewish Chronic Disease Hospital Brooklyn, New York

LAUGHLIN[1] in 1925 reported for the first time the occurrence of lipoid pneumonia in four children who had been treated with menthol and albolene (mineral oil) for various nose and throat infections Autopsies performed in these cases revealed a bronchopneumonic process characterized by the presence of large phagocytes containing fat droplets which readily stained with Sudan III He succeeded in producing comparable bronchopneumonic lesions in the rabbit following the intranasal instillation of mineral oil Although liquid petrolatum causes the most pronounced and irreversible pulmonary lesions in man, other substances such as animal and vegetable oils have also been known to produce "proliferative pneumonitis" following intratracheal instillation in animals as shown by Guiesse Pellissier[2] in 1920 and Corper and Freed[3] in 1922

The various reactions to different oils such as animal or vegetable oil as well as liquid petrolatum were studied experimentally by Pinkerton in 1927 and 1928 [4,5] He demonstrated that neutral vegetable oils produced little damage with the exception of chaulmoogra oil which caused necrotizing pulmonary lesions while some animal oils as well as mineral oil led to a more pronounced tissue reaction with proliferation of multinucleated giant cells and macrophages The picture was similar to that in human pathology With the attention thus focused on this condition, lipoid pneumonia, also called oil aspiration pneumonia, became widely recognized and many excellent accounts with detailed description of the clinical and [illegible] to occur only in physically handicapped infants or in chronically debilitated adults afflicted with neurologic disorders as paralysis agitans, hemiplegia, pseudobulbar palsy or deformities interfering with normal swallowing such as cleft palate or harelip, it has also been observed in apparently healthy individuals [20,42–49] It seems to be fairly well established at the present time that the use of mineral oil as a throat lubricant or as a vehicle for nose drops as well as a laxative can cause chronic pulmonary lesions identical to those produced experimentally in animals

The great variation in the clinical picture and the frequently atypical and inconclusive roentgenographic findings make the diagnosis of lipoid pneumonia a difficult task, particularly in the absence of a definite history of intake of mineral oil Moreover, many patients afflicted with this condition are clinically asymptomatic [22,30] Oil aspiration pneumonia may be confused with other pulmonary dis [illegible] lesions, th [illegible] may have been of interest previously to the internist pediatrician or pathologist only, it has gained considerable differential diagnostic significance with the recent progress achieved by thoracic surgery The recognition of lipoid pneumonia appears of particular importance in those patients in whom a diagnosis of bronchogenic carcinoma is entertained because needless surgical intervention may be avoided whenever the correct diagnosis can be established clinically

It has been shown by us[21] that the diagnosis of lipoid pneumonia can be corroborated with a considerable degree of accuracy by correlating the roentgenographic findings with cytologic studies of the sputum[22] as well as of material aspirated from the lungs [22,24]

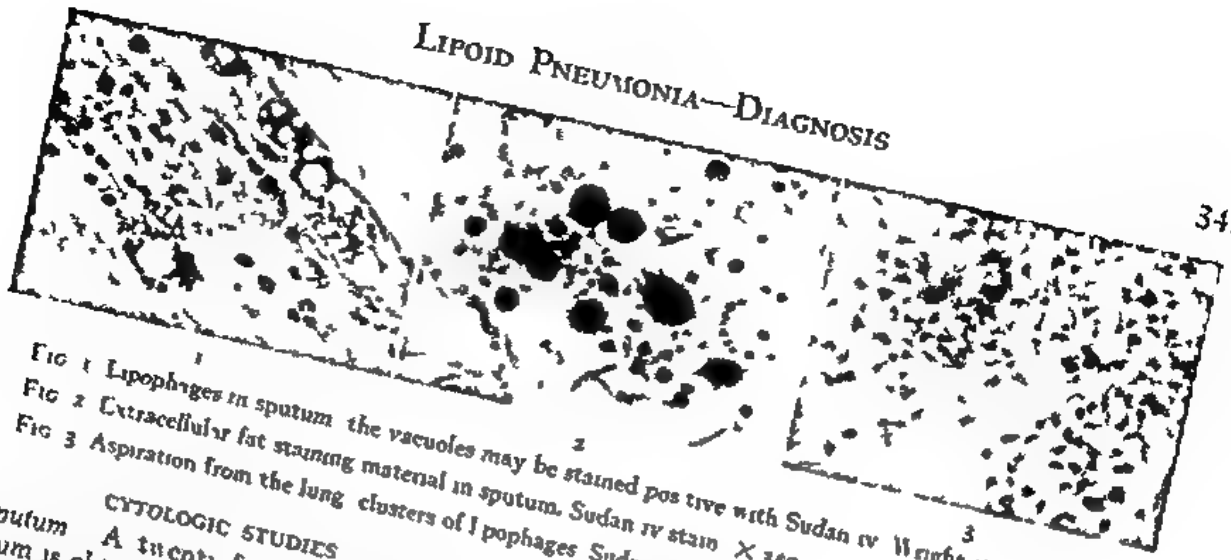

1 2 3

FIG 1 Lipophages in sputum the vacuoles may be stained positive with Sudan IV Wright stain × 500
FIG 2 Extracellular fat staining material in sputum. Sudan IV stain × 350
FIG 3 Aspiration from the lung clusters of lipophages Sudan IV stain × 400

CYTOLOGIC STUDIES

Sputum A twenty four hour collection of sputum is obtained daily for three to five consecutive days from patients whose history, physical examination and roentgenographic findings are suggestive of lipoid pneumonia The patient is placed on a strict fat free diet beginning four days prior to as well as through out the period of sputum collection A drop of sputum is deposited on each of four glass slides with a platinum loop, and a drop of saline is added to establish a thin spread If the sputum is thin and watery, the specimen is centrifuged for five minutes, and the sediment is then spread on a glass slide in a similar manner The slides are dried in the incubator Two of the slides are stained with Sudan IV and two with Wright's stain as modified by Lillie [2] The sputum is considered positive for lipoid pneumonia when the Wright stain shows the characteristic macrophages containing clusters of vacuoles (Fig 1) and also if these vacuoles stain orange-brown in Sudan IV or if abundant extracellular fat staining material is present (Fig 2)

Material Aspirated from the Lung The patients are prepared by the administration of 100 to 150 mg of demerol ® according to weight and age about forty five minutes prior to aspiration Younger and physically able individuals receive an additional 0 1 gm of secondal about one hour prior to the injection of demerol After local anesthesia of the site of aspiration carefully selected with the aid of roentgenograms of the chest a 19 gauge spinal needle with the stylet *in situ* is introduced to a depth of about 2½ inches within the lung tissue proper After removal of the stylet a 20 ml syringe is attached to the needle which under forceful aspiration is slowly withdrawn If at any point frank blood appears in the syringe suction is stopped at once and the withdrawal is completed A successful aspiration yields one or perhaps two blood tinged droplets of fluid These are ejected through the needle onto five slides where they are spread thinly The air dried smears are fixed in 10 per cent solution of formalin for three hours and then stained with Sudan IV and Wright's stain similar to the procedure employed for sputum

The aspirated material is considered positive when the characteristic lipophages, single or arranged in clusters and frequently transformed into giant cells are observed (Fig 3)

ROENTGENOGRAPHIC OBSERVATIONS

Roentgenographically, two main types of lipoid pneumonia can be distinguished (1) a circumscribed involvement within a lobe which can easily be mistaken for a tumor (Fig 4) and (2) a diffuse type which usually affects several lobes and is more commonly encountered During the acute phase lipoid pneumonia gives rise to soft densities within one or several lobes of the lungs which cannot be differentiated from any other form of pneumonitis Oil aspiration pneumonia has a predilection for the right middle and right lower lobes The upper lobes are primarily affected in bed ridden patients or infants In the presence of upper lobe involvement differentiation from pulmonary tuberculosis may be difficult at times Since lipoid pneumonia frequently undergoes fibrosis, it can cause a contraction of the involved area The surrounding lung tissue then appears emphysematous This fibrosis and contraction give rise to the characteristic "ground glass" appearance (Fig 5)

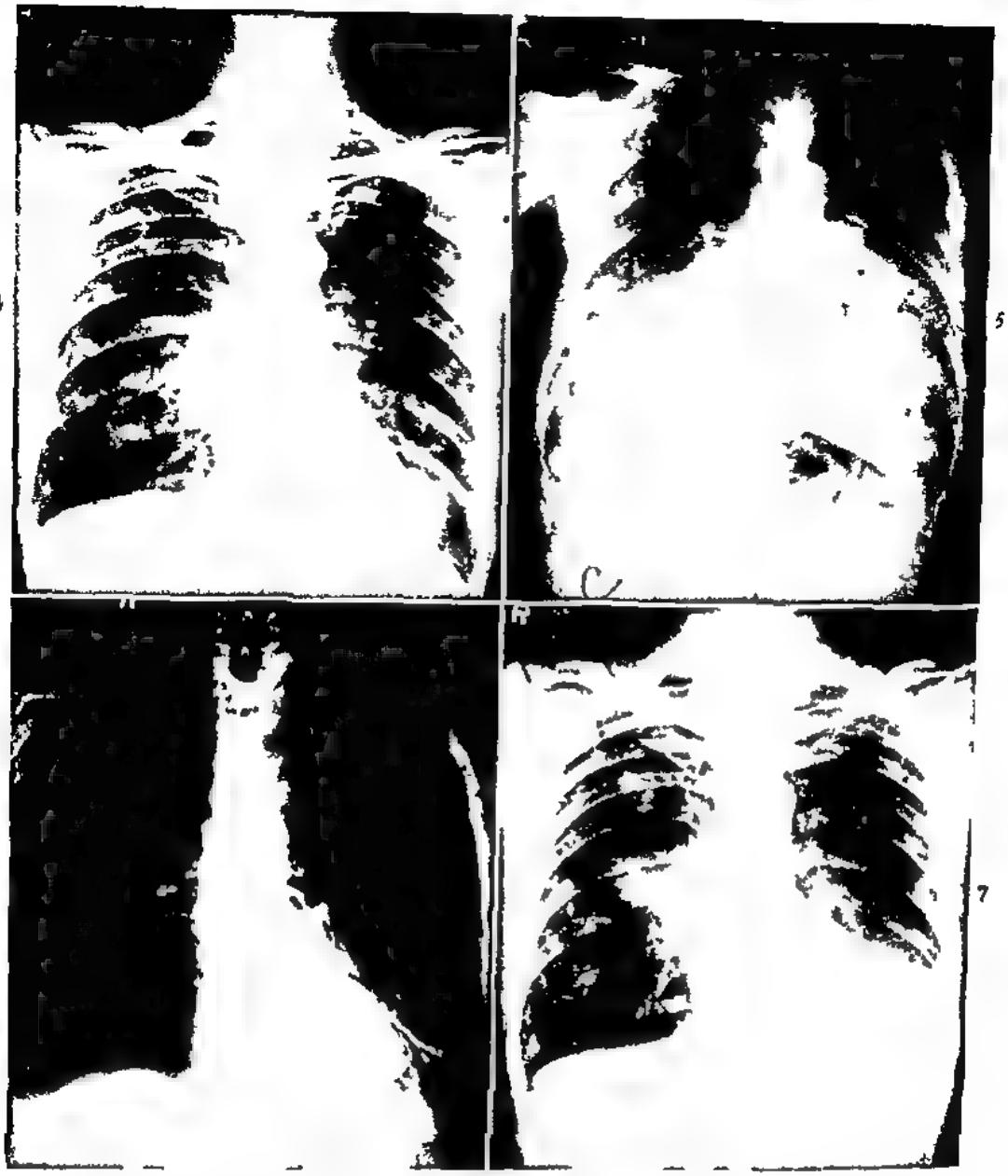

FIG 4 Circumscribed tumor like mass in the left lung There is enlargement of the right hilar shadow due to involvement of the apex of the right lower lobe not to be mistaken for hilar adenopathy

FIG 5 Massive involvement of both lower lobes Ground glass appearance as a result of contraction of the lesion and subsequent fibrosis No calcification seen

FIG 6 Lipiodol studies showing blockage of the terminal branches without filling of the alveoli (so-called dead tree effect)

FIG 7 Same patient as in Figure 4 two years later There is some progression of the disease on the left side with lobar involvement instead of the original tumor like mass There is also further progression of the involvement within the apical portion of the right lower lobe

This is the best known feature of lipoid pneumonia and represents a late phase of the disease Calcification and hilar lymphadenopathy are never observed roentgenologically If bronchographic studies are carried out, it can be noted that the bronchi skirt the mass and the terminal bronchioles are occluded and do not enter the lesion (Fig 6) There is no evidence of bronchiectasis or of progression to lung abscess It may be difficult at times to

differentiate the circumscribed lesions Contralateral involvement has invariably been demonstrated in all such instances when lamina graphic studies were done The contralateral involvement (Fig 7) may consist only of small patchy infiltrations but in conjunction with the mass lesion such a finding is helpful in establishing the diagnosis In the presence of a clinically suspected diagnosis of lipoid pneumonia a routine postero-anterior x ray of the chest may be inadequate In such instances oblique and lateral views will help to uncover lesions frequently hidden by the cardiac shadow

COMMENTS

In a previous study carried out on chronically ill patients the authors[21] were able to establish the diagnosis of lipoid pneumonia by a combined radiologic and cytologic approach Most of these patients gave long histories of mineral oil intake The clinical findings were not particularly characteristic but occasionally included such symptoms as productive cough dyspnea febrile exacerbations and chest findings associated with pulmonary consolidation In many instances however the patients were asymptomatic and the lesions were discovered by routine roentgenologic studies of the chest at times diagnosed as bronchogenic carcinoma particularly when circumscribed in appearance This differential diagnosis may be particularly tempting when a mass lesion is associated with hemoptysis This symptom has been observed though rarely in lipoid pneumonia [illegible] In such circumstances several writers have advocated exploratory thoracotomy with fresh frozen sections as a guide for the surgeon [illegible] The authors however believe that careful combined radiologic and cytologic evaluation may help in many instances to prevent unnecessary surgical intervention

Earlier writers have suggested that intra or extracellular oil globules may be used as an aid in the diagnosis of lipoid pneumonia [illegible] More recently Schneider demonstrated the presence of oil in aggregates of three successive morning sputums by covering a spread of the latter on a glass slide with cigarette or lens paper or by staining these oil droplets with scarlet red Nuessle[50] on the other hand reported that free fat globules may occur in normal individuals without any evidence of pulmonary disease In these instances he even noted occasional macrophages containing Sudan staining material While the authors concur with the observation that small amounts of sudanophilic material may be found in normal sputum, no lipophages were encountered in our control subjects Furthermore the diagnosis of lipoid pneumonia was entertained only in patients with abundant free sudanophilic material as well as with a distinct number of characteristic lipophages in the sputum These cytologic prerequisites were corroborated with the positive findings in the material aspirated from the lungs

It was observed previously by us[21] that in several patients serial daily sputum examinations were required before fat staining material was found even in patients whose chest roentgenograms were consistent with the diagnosis of lipoid pneumonia Whenever possible the direct aspiration from the lung was performed under the guidance of x ray films In those patients however who were negative radiologically but whose history and clinical symptoms were suggestive of lipoid pneumonia a point in the ninth intercostal space posteriorly and 3 inches to the right of the spinal column was selected for aspiration since in our experience the lesions were most frequently found in this location In a few instances repeated aspirations had to be performed before evidence of lipoid pneumonia was obtained

The only untoward effect encountered with this procedure in a few patients only was an asymptomatic short lasting pneumothorax as well as aspiration of blood which occurred in four of over eighty subjects The bleeding was never found to cause major complications except for the fact that the sputum remained blood tinged for about three or four days

Since Pinkerton's[41] classic studies of the reactions of oils and fats on pulmonary tissue in 1927 and 1928 little has been added to our knowledge on this subject Of the various agents producing the picture of oil aspiration pneumonia which include cod liver oil milk fat, iodized oil or mineral oil the latter is the most common cause of lipoid pneumonia since it is widely used as a laxative as well as a vehicle for nose drops throat lubricants or various oil-containing medications Mineral oil a hydrocarbon and not a fatty substance is capable of entering the bronchial tree without exciting the reflex inhibition It therefore flows



FIG. [illegible] Granuloma like lesion of the liver containing lipophages. The vacuoles may be stained with Sudan IV, Haematoxylin and eosin stain. × 150.

readily from the pharynx into the tracheobronchial tree. This has been shown in animal experiments by demonstrating that liquid petrolatum fails to produce a cough reflex and therefore does not stimulate reflex closure of the glottis.[5, 52] Many of the commonly used nose drops impair the ciliary activity and even destroy the respiratory epithelium.[53, 54] In addition, it was demonstrated experimentally that mineral oil hinders the ciliary movement mechanically by slowing or stopping the flow of mucus covering the cilia, thus considerably impairing their normal activity.[55] Cannon and Walsh[56] studied the development of oil granuloma experimentally by injecting purified mineral oil intratracheally into rabbits. They observed an initial pulmonary edema and postulated that the oil caused injury to the pulmonary capillaries which led to an increase in capillary permeability and seepage of albumin into the alveoli. A reticulum of collagenous fibers developed between the macrophages and within the alveoli. The oil became fixed in fibrous tissue, thus obliterating many of the air spaces. Within the fibrous tissue areas of necrosis surrounded by giant cells and epitheloid cells were found giving the microscopic picture of a granuloma.

In man the tissue reaction in the lung following ingestion of liquid petrolatum is similar to that of the experimental animal. Fine droplets of mineral oil are phagocytized by large macrophages called "foam cells" or "lipophages" which accumulate in large numbers at the site, filling the air spaces. Occasionally a mild inflammatory reaction develops temporarily in the alveoli, which may involve also the bronchioli and peribronchial tissue. Necrosis is hardly ever observed in the lung. However, a reticulum of collagenous fibers is laid down between the foam cells and the phagocytized material becomes fixed by the immobilized lipophages and the connective tissue which penetrates between the cells and also surrounds them. Since mineral oil is [illegible] by fibrous tissue and the alveoli are lined by cuboidal cells. Such lesions are practically permanent, constituting tumor like masses of granulomatous tissue and are called paraffinoma. It is this lesion which roentgenologically resembles a neoplasm.

Our previous studies suggest that macrophages frequently disintegrate, thus setting free the intracellular fat staining material. The oil may be expectorated or it may be carried to the regional hilar lymph glands. There are several cases on record in which [illegible] granuloma like lesions.[57, 58] In our own autopsy material such lesions were also observed in three instances in the liver (Fig. 8) and spleen and are believed to be embolic phenomena secondary to paraffinoma of the lung. In many instances the lipoid material liberated from the disintegrated lipophages may be reaspirated from the upper bronchial tree and returned to the alveoli, thus producing a vicious cycle by stimulating proliferation of macrophages and eventually causing fibrosis. This may account in part for the chronicity of the process even after oral or nasal intake of lipoid material has long been discontinued. Moreover, the lack of saponification of mineral oil makes its assimilation and absorption impossible. It is primarily in the chronic lesions that the sputums are negative for fat staining material, since the aspirated substance becomes encapsulated by connective tissue and since the alveolar ducts or respiratory bronchioles become plugged by inspissated material which had accumulated in the areas of consolidation. Hence it is believed that in these cases the transthoracic aspiration of material from the lungs offers a superior means to obtain the diagnostic lipophages.

The question whether liquid petrolatum has carcinogenic activity has been repeatedly brought forth through the years There are some experimental reports as well as occasional cases recorded in the literature For instance Shimkin[50,60] and Twort and Lyth[61] succeeded in the production of lung tumors in mice by intratracheal instillations of mineral oil These substances however were rather aromatic hydrocarbon like methylcholanthrene and benzopyrene and not saturated aliphatic hydrocarbons commonly called mineral oil More over most of these tumors originated from the alveolar epithelium and not in the bronchial tree There are several cases reported in which bronchogenic carcinoma was associated with a history of mineral oil intake for years suggesting a possible carcinogenic effect of this substance[49,52] However the majority of observers agree that there is not sufficient clinical or pathologic evidence so far to substantiate any carcinogenic properties of liquid petrolatum In our material of more than eighty patients with lipoid pneumonia many of whom were under constant medical supervision for as long as twenty years and most of whom were in the cancer age group there has not been a single instance of complicating bronchogenic carcinoma

Although the differential diagnosis of lipoid pneumonia appears to be of paramount importance in those patients in whom the roentgenologic findings simulate a pulmonary malignancy the diagnosis of lipoid pneumonia may also be of considerable value in those conditions which are mistaken for other low grade pulmonary infections bronchiectasis mycoses or sarcoidosis since the correct identification of these diseases may be helpful as to therapeutic procedures contemplated Furthermore the spread of the lesion can be prevented by discontinuing further intake of mineral oil or other oil containing medications when the diagnosis is established early

SUMMARY

1 Lipoid pneumonia occurs not only in chronically debilitated adults or in physically handicapped children but also has been observed in apparently healthy individuals Mineral oil is the most common cause of this condition since it is widely used as a mild laxative as well as a vehicle for oily nose drops throat lubricants or various oil containing medications

2 The differential diagnosis of lipoid pneumonia frequently causes considerable difficulty since this condition may be confused with other pulmonary diseases such as low grade infections tuberculosis fungus disease sarcoidosis or benign and malignant neoplasms

3 The recognition of lipoid pneumonia is of particular importance in those patients in whom a diagnosis of bronchogenic carcinoma is entertained because needless surgical intervention may be avoided

4 The clinical findings are not characteristic and include productive cough dyspnea febrile exacerbations and chest findings associated with pulmonary consolidation In many instances the patients are asymptomatic

5 The diagnosis of lipoid pneumonia can be established clinically with a considerable degree of accuracy by correlating the roentgenographic findings with cytologic studies of the sputum as well as of material aspirated transthoracically from the lung

6 The positive sputum contains lipophages and abundant amounts of free sudanophilic material while the material aspirated from the lung is considered positive when the characteristic lipophages single or arranged in clusters and frequently transformed into giant cells are found

7 The roentgenographic features indicative of lipoid pneumonia are discussed

8 The mechanism of the progressive nature of the disease after discontinuance of the inciting liquid petrolatum is suggested as being due to reaspiration of disintegrated lipophages

9 Early clinical recognition of lipoid pneumonia may prevent extensive spread of the pulmonary involvement by discontinuing the intake of mineral oil or other oil-containing medications

Acknowledgment The authors wish to express their appreciation to Mr Herbert A Fischler for the illustrations included in this study

REFERENCES

1 LAUGHLIN G T Studies of pneumonia following injections of oil *Am J Path* 1 4 7 1925

2 GUIESSE PELLISSIER, A Recherches sur l absorption de l huile dans le poumon *Compt rend Soc de biol* 83 809 192

3 CORPER, H J and FREED, H Intratracheal injection of oil for diagnostic and therapeutic purposes *J A M A*, 79 1739, 1922

4 PINKERTON, H Oils and fats their entrance into and fate in the lungs of infants and children a clinical and pathologic report *Am J Dis Child*, 33 259 1927

5 IDEM The reaction to oils and fats in the lung *Arch Path*, 5 380, 1928

6 IKEDA K The pathology of oil aspiration pneumonia (lipoid pneumonia) *Am J Clin Path*, 5 89, 1935

7 IDEM Oil aspiration pneumonia (lipoid pneumonia) clinical, pathologic, and experimental considerations *Am J Dis Child*, 49 985, 1935

8 IDEM Lipoid pneumonia of the adult type (paraffinoma of the lung), report of 5 cases *Arch Path*, 23 470, 1937

9 LANGDON, J Case of lipoid cell pneumonia *Rhode Island M J*, 18 65 1935

10 GRAYZEL D M and DU MORTIER, J J Pneumonia in children following aspiration of oil and fat clinical and pathologic report of 2 cases *Yale J Biol*, 6 599, 1934

11 BALL, F E Petrolatum oil pneumonia in an adult *Illinois M J*, 69 62, 1936

12 BAUMGARTNER, L. and ANGEVINE, D M Lipoid pneumonia and conditions that may favor its occurrence *Am J M Sc*, 192 252, 1936

13 GARRISON H F Lipoid pneumonia in children *South M J*, 26 322 1935

14 BROMER, R S and WOLMAN, I J Lipoid pneumonia in infants and children *Radiology*, 32 1, 1939

15 BISHOP, P G C Oil aspiration pneumonia and pneumolipoidosis *Ann Int Med*, 13 1327, 1940

16 CLELAND J B Two examples of lipoid pneumonia *M J Australia*, 2 481, 1943

17 PATERSON, J L. H An experimental study of pneumonia following the aspiration of oily substances lipoid cell pneumonia *J Path & Bact*, 46 151, 1938

18 MOEL, M and TAYLOR, H K Oil aspiration pneumonia *Am J Roentgenol*, 49 177, 1943

19 REWELL, R E Lipoid pneumonia, a pitfall in diagnosis *Brit M J*, 1 409, 1947

20 SCHNEIDER, L. Chronic benign pneumonitis, its discovery in older individuals with diminished or absent gag reflex *New York State J Med*, 48 520 1948

2 [illegible]

2 [illegible]

2 [illegible]

[illegible] 1947

25 FACQUET, M J and LANGEARD Deux cas d opac- [illegible]

26 [illegible]

durch Gebrauch von Mentholoel *Frankfurt* [illegible]

27 [illegible]

tion von Paraffinol bei therapeutischer Anwendung *Arch f Ohren-, Nasen- u Kehlkopfh* 136 40, 1933

28 COURCOUX, M A Image pulmonaire transitoire par vapeurs de l'huile de paraffine *Rev de la tuberc.*, 7 152, 1942

29 DAVIS K S Roentgenographic changes following the introduction of mineral oil in the lung with report of 3 cases *Radiology*, 26 131, 1936.

30 FREIMAN, D G, ENGELBERG, H and MERRIT, M H Oil aspiration (lipoid) pneumonia in adults. A clinicopathologic study of 47 cases *Arch Int Med*, 66 33 1940

31 VOLK, B W, NATHANSON, L., LOSNER, S, SLADE, W R and JACOBI, M Incidence of lipoid pneumonia in a survey of 389 chronically ill patients. *Am J Med*, 10 316, 1951

32 LOSNER, S, VOLK, B W, SLADE, W R, NATHANSON, L and JACOBI, M Diagnosis of lipoid pneumonia by sputum examination *Am J Clin Path*, 20 539 1950

33 FARBER, J E, CARPENTER, R and PELLICANO V Lipoid pneumonia, diagnosis by aspiration biopsy *Am Rev Tuberc*, 45 453 1952

34 NATHANSON, L. FRAENKEL, D and JACOBI M Diagnosis of lipoid pneumonia by aspiration biopsy *Arch Int Med*, 72 627, 1943

35 TCHERTKOFF, I G and ORNSTEIN, G B Bronchopulmonary disease attributed to the use of intranasal instillation of oily substances report of 10 cases *Quart Bull, Sea View Hosp*, 1 139, 1936

36 HASTINGS, E V Vascular lesions in lipid pneumonia (due to liquid petrolatum), pathogenesis and significance *Arch Path*, 49 453 1950

37 JANES, R M Lipoid pneumonia simulating bronchogenic carcinoma *J Thoracic Surg*, 16 451, 1947

38 JAMPOLIS, R W, McDONALD, J R and CLAGETT [illegible]

1953

39 RABINOVITCH J and LEDERER, M Lipoid pneumonia *Arch Path*, 17 160, 1934

40 HOUCK, G H Pulmonary oil tumors granulomata caused by intratracheal instillation of liquid petrolatum (lipoid or oil aspiration pneumonia), with report of case Medical Papers, Christian Birthday Volume, p 463 Baltimore 1936.

41 [illegible] neu [illegible] ic to [illegible]

42 [illegible] 35 [illegible] 261, 1940

43 CARR, R M Lipoid pneumonia with report of case *J. Kansas M Soc*, 41 381, 1940

44 CANNON, R R *Problem of lipid pneumonia*, brief review *J A M A*, 115 21-6, 1940.

45. PROPERT, S A Lipoid pneumonia *Brit M J*, 2 282 1940

46 MONSKY, D B and LAFFERTY C R Lipoid pneumonitis *J M A Alabama*, 11 267, 1942
47 LEVINE, M H and DE ANGELIS, C E Lipoid pneumonitis *M Bull Vet Admin*, 18 379 1942
48 HUMPHREY, A A and OLMSTEAD E G Lipid pneumonia in neuropsychiatric and debilitated patients *Dis of Chest*, 15 471, 1949
WOOD E H, JR Unusual case of carcinoma of both lungs associated with lipoid pneumonia *Radiology*, 40 193 1943
NUESSLE, W F The significance of fat in sputum *Am J. Clin Path*, 21 430, 1951
QUINN, L. H and MEYER O O Relationship of sinusitis and bronchiectasis *Arch Otolaryng*, 10 152, 1929
IERIE, A H In discussion of Pierson J W Some unusual pneumonias associated with aspiration of fats and oils *Am J Roentgenol* 27 572 1932
Y N The effect of camphor, eucalyptol and menthol on the nasal mucosa *Arch Otolaryng*, 11 48, 1930
54 FENTON, R A and LARSELL, O An experimental and clinical study of histiocytes in acute and chronic inflammation of the accessory sinuses *Laryngoscope* 43 233 1933
55 PROETZ, A W Effects of certain drugs on living nasal ciliated epithelium *Ann Otol, Rhin & Laryng*, 43 450, 1934
56 CANNON, P R and WALSH, T E Lipoid pneumonia and some potential dangers of intranasal medication *New Internat Clin*, 3 109 1938
57 PINKERTON, H and MORAGUES, V Paraffinoma of the lung with secondary tubercle-like lesions in the liver and spleen *Arch Path*, 29 691, 1940
58 YOUNG A M, APPLEBAUM H S and WASSERMAN, P B Lipoid pneumonia report of a case *J A M A*, 112 2406, 1939
59 SHIMKIN, M B Production of lung tumors in mice by intratracheal administration of carcinogenic hydrocarbons *Am J Cancer*, 35 538, 1939
60 IDEM Induced pulmonary tumors in mice I Susceptibility of seven strains of mice to the action of intravenously injected methylcholanthrene II Reaction of lungs of strain A mice to carcinogenic hydrocarbons *Arch Path*, 29 229, 1940
61 TWORT J M and LYTH, R The concentration of carcinogenic materials in mineral oils of distillation processes *J Hyg*, 39 161, 1939
62 SANTE L R The fate of oil particles in the lung and their possible relationship to the development of bronchogenic carcinoma *Am J Roentgenol*, 62 788, 1949

XVI. EMPHYSEMA

42

Chronic Pulmonary Emphysema*

MAURICE S SEGAL, M D, *Boston, Massachusetts*

Clinical Professor of Medicine Tufts University School of Medicine and Director Department of Inhalation Therapy and Lung Station (Tufts), Boston City Hospital

CHRONIC pulmonary emphysema can be defined as the diffuse progressive, obstructive and hypoxic type of chronic emphysema in which pathologic distention of alveoli has persisted for some time [1] It occurs with, or as a complication of, practically all pulmonary diseases particularly severe bronchial asthma, bronchiectasis, serious pulmonary infection, the pneumoconioses, sarcoidosis and tuberculosis T
diffuse
emphys
the diseases of the lung

SYMPTOMATOLOGY

Early manifestations consist of cough and dyspnea on exertion The dyspnea may be caused by such acts of exertion as laughing, coughing sneezing or straining The dyspnea is accompanied by hyperventilation Subsequently the dyspnea becomes progressively more severe and bronchospastic crises, resembling a paroxysm of bronchial asthma may occur

There is a tendency for the cough to become more troublesome, more persistent and readily initiated by various non specific irritants cold air, wind, fumes, dust smoke, etc

In the advanced stages of the disease, the above symptoms are more severe and in addition, there is easy fatigability, dyspnea at rest, orthopnea and cyanosis There may be evidence of heart failure The pulmonic second sound is usually accentuated and may be louder than the aortic second sound

In this advanced stage of chronic pulmonary emphysema the patient has a tendency to develop respiratory acidosis This may occur spontaneously in the course of the disease or be induced by the inadvertent administration of high concentrations of oxygen or respiratory depressing drugs The patient may complain of headache, confusion or irritability, and hypoventilation is usually noted If the respiratory acidosis is allowed to progress drowsiness delirium, coma and death follow The basic defective mechanism which is responsible for this syndrome is inadequate alveolar ventilation with marked retention of carbon dioxide

PHYSIOPATHOLOGY

The dynamic pressure relationships within the chest and between the intra- and extrathoracic spaces are essential to the normal airflow patterns of inspiration and expiration Bronchial or bronchiolar obstruction disturbs these airflows Normally, in expiration the cross sectional area of the bronchi is decreased When this decrease is markedly exaggerated it diminishes expiratory airflow and prolongs the expiratory time Increased resistance to expiration results in incomplete alveolar emptying or "trapping" of air in the alveoli (localized or generalized) This results in progressive overdistention of alveoli Finally, interalveolar septa may rupture, giving rise to blebs and bullae

The increased intra alveolar pressure will compress the surrounding normal alveoli and the bronchioles, especially during forced expiration or cough [2] This has actually been observed bronchoscopically and has been explained on the basis of an increased alveolar volume without a corresponding increase in the cross sectional area of the air passages During expiration the intra alveolar pressure rises above the intrabronchial pressure and

* Permission for the free use of material and sections from "Chronic Pulmonary Emphysema—Physiopathology and Treatment" by Dr M S Segal and Dr M J Dullano was granted by the publishers, Grune & Stratton Inc., New York, N Y

compresses the air passages This mechanism constitutes an expiratory check valve on the terminal bronchioles A vicious cycle is initiated and further alveolar distention and alveolar damage follow

The progressive increase in lung volume encroaches upon its surroundings, it depresses the diaphragms and the lungs push into the mediastinum As the alveoli enlarge and lose many of their septal walls (destruction of alveolar membrane) a decrease of alveolar capillary contact (reduction in surface area) results in the face of an increased alveolar volume A twofold disturbance in physiologic function now ensues

1 Ventilation in and out of these alveoli blebs and bullae is irregular and inadequate Part of the air does not come in contact with the capillary surface for gas exchange This constitutes in effect an increased dead space type of ventilation

2 Since most of the air within these enlarged alveoli is stagnant the blood will leave these alveoli without a significant decrease in its carbon dioxide content or an increase in its oxygen content This blood instead of becoming arterial remains venous and re enters the systemic circulation This results in an increased venous admixture and is manifested by hypoxia

As the disease progresses the disturbances in pulmonary ventilation will be followed by hypoxia and later on by hypercapnia Finally cor pulmonale develops and right heart failure ensues as a terminal event Pulmonary arterial hypertension of a chronic nature is the main disturbance which leads to cor pulmonale cardiac hypertrophy dilatation and finally failure This hypertension is due to a diminished pulmonary vascular bed secondary to actual destruction of alveolar capillaries and the effects of hypoxia Polycythemia and hyperolemia also contribute to the pulmonary arterial hypertension

MANAGEMENT

There appears to be an increasing incidence of chronic pulmonary emphysema in this country which may be related directly to the increase in industrial and environmental inhalant vapors gases fumes dusts and tars or indirectly to the increased incidence of respiratory infections or allergies under these circumstances These vary as irritants to the bronchioles produce progressive narrowing and eventually the typical overdistention of the lungs seen in emphysema This may well be the price we have to pay for our advances in living and in industry

The various factors responsible namely, allergic hormonal psychic occupational infectious, etc should be analyzed in every patient The preventive and therapeutic management of the patient with progressive bronchial asthma emphysema and/or suppurative disease of the lung all too often requires an economic prescription rather than one that can be written on the doctor s prescription pad Repeated and long periods of hospitalization along with a variety of mechanical breathing apparatus physiotherapeutic rehabilitation employing diaphragmatic breathing training antimicrobial and hormonal agents and the careful use of therapeutic aerosols and oxygen therapy make it possible to prolong life and restore many of these patients to a life of economic usefulness A diagrammatic summary of the physiologic measures proven of value (Fig 1) and a brief discussion of some of these measures follows

SYMPTOMATIC TREATMENT

The bronchitic cough is one of the most troublesome manifestations and may actually serve as the trigger mechanism for more extensive bronchiolar spasm and alveolar disintegration The expectorant antihistaminic preparations are well tolerated by many patients Hydrylin® compound has the advantage of aminophylline in combination with benadryl® Iodides may be taken to promote more adequate bronchial catharsis in the more severe chronic form of bronchitis

For the hacking paroxysmal cough we have found nonotine® very useful in doses 15 to 30 mg administered four times daily We have not observed any sedation or respiratory depressing effects with its continued use

In the sicker patients the tranquilizer thorazine® has proven a most helpful adjuvant Objectively the patient appears to become less concerned with his dyspnea The fatigue associated with the increased work of breathing resulting from the increased mechanical resistance and reduced compliance in the patient with chronic pulmonary emphysema appears, furthermore to be tolerated better with the use of thorazine® This is of particular interest

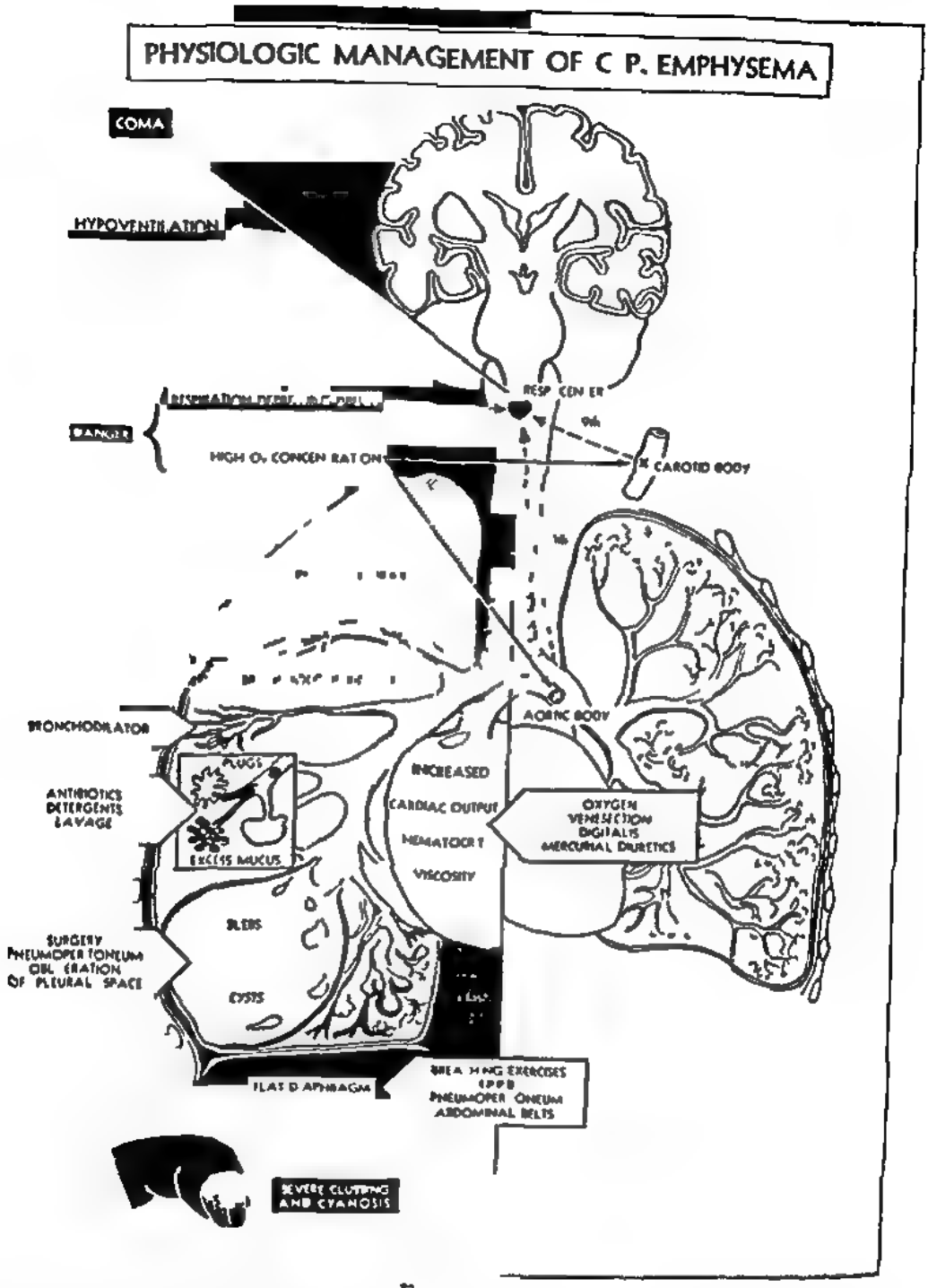

FIG. 1

in view of the fact that we have not been able to demonstrate any striking improvement in the pressure volume relationships in these patients In the very sick patient we employ an intramuscular injection of 25 to 50 mg morning and evening with one or more supplemental oral doses of 25 mg After several days the dosages should be reduced to maintenance schedule of 10 to 25 mg, two or three times daily

There are many oral medications combining aminophylline with ephedrine for the relief or prevention of mild but chronic bronchoconstriction The difficulty with most of these preparations resides in their *side reactions*, when using doses of aminophylline which are

large enough to achieve therapeutic re The addition of antinausea factors (loca central) to aminophylline has made it p s l to administer effective larger doses of n phylline with or without ephedrine barbiturate (dainites® and cardalin®) H g aminophylline blood levels (above o 5 per cent) may be necessary for more pers t bronchospasm particularly when ass with chronic bronchial asthma These le can be obtained by the use of aminopl solutions given by rectal or intr administration

BRONCHOCONSTRICTION AND INFECTION

Therapeutic aerosols (1) sympath n t et amines and (2) antimicrobial agents sh uld b employed for the relief of bronchosp s n l the management of bronchopulmonar tions We have found the vaponefrin® nel l zer most satisfactory for the production of th era peutic aerosols

Sympathomimetic Amines Aerosols of th e sympathomimetic drugs vaponefrin suprel® and dylefrin® have proved to be of great value for the relaxation of bronchospasm As little approximately o 05 to o 10 cc nebulized by three to six compressions of a hand bulb may abort or relieve a mild bronchospast c ep sode More severe bronchospasm may require o 5 to 1 o cc nebulized by continuous flows of oxygen with the Eliot Unit (face mask and a r pump) or by air pump This treatment gener ally requires five to fifteen minutes at 5 L./minute flo v A Y tube or s mple button like opening into the oxygen or air feed line allows interruption of aerosol production during exp ration The aerosols may be introduced along with intermittent positive pressure breathing (I P P B) with the Bennett valve th us obtaining the physiologic advantage of driving the therapeutic agent through partially obstructed airways A useless cough is often converted to a productive one by effective

depends on the predominating organisms their sensitivity and th e patient s tolerance to the drug itself Penicillin is generally th e primary drug employed for gram positive orga n sms strepto n vein may be added or used alone if gram negative bacteria are also present or emerge or if bronchorrhea persists

The antibiotic aerosols may be combined th equal amounts (e g 1 cc each) of a chodilator preparation and a detergent r s l such as alevaire® One-half cc of n o s nephrine® (1 per cent) may also be lded to an equal amount of the bronchodilator r more effective relief of bronchial edema

Crystalline penicillin is given in doses of 000 to 100 000 units and streptomycin in l ses of o 25 gm four times daily A course of l erapy may range from one to six weeks

Most of our patients have been able to raise sputum more easily while receiving these er sols The hazard of local or generalized llergic reaction to penicillin aerosol in patients v th underlying bronchial asthma must never be overlooked Bronchoscopic lavage may greatly enhance the subsequent value of bronchod lator and antibiotic aerosols in pa tients with associated bronchiectasis

Supplemental penicillin streptomycin or one of the broad spectrum antibiotics (aureo-mycin tetracyn or chloramphenicol) should be employed if there is evidence of a severe respiratory tract infection During the winter months we have employed as a preventive of such infection oral remonden® in doses of 50 000 units twice daily or tetracyn® or ponmycin® in doses of 100 mg twice daily

Paranasal sinus disease may be responsible for reinfection and the recurrence of cough and wheezing respirations Irreparable sino-bron chitic syndrome often follows in its wake Most of these patients have underlying allergy In the ambulatory patient we have found the cortisone nasal spray PAK units (vasocort® trisocort® cortef® neo-cortef®) very helpful anti inflammatory agents in restoring sino-tubal ventilation In the sicker patients these agents may be administered in 1 cc dosages alone or combined with the antimicrobial agent of choice (penicillin or streptomycin) They should be administered three or four times daily with the vaponefrin nebulizer with nasal tips employing the continuous oxygen air pump technic These agents are generally well tolerated nasally Postnasal drip with secondary cough is reduced nasal patency is restored and more restful sleep may follow

USE OF CORTICOSTEROIDS

The idea is appealing that irreversible fibrous changes following inflammatory pulmo-nary lesions can be prevented by periodic use

of the adrenocorticotropic or corticosteroid hormones, but it has not been substantiated

Patients with underlying hypersensitive disorders of the lung should be given a trial with the newer corticosteroid analogues when a reversal of physiologic function has not occurred after adequate therapy This trial may be made even in the presence of chronic cor pulmonale It should be kept in mind that the dominant defect, hypoxia, is responsible for the chronic cor pulmonale and associated changes When improvement of hypoxia does not follow treatment with bronchodilators and aminophylline and the use of intermittent positive pressure breathing and proper concentrations of oxygen (to be discussed), the rapid remission from the intractable bronchoconstriction made possible by these agents should be attempted

The presence of heart failure due to chronic cor pulmonale need not absolutely contraindicate the use of these agents, provided all the physiologic principles which will be outlined are followed for the management of such failure Temporary aggravation of such demonstrated by hepatic enlargement or leg edema occasionally may appear But relief from the effects of acute hypoxia superimposed on chronic hypoxia more than offsets the hazards of further heart failure Still greater improvement generally follows the use of digitalis mercurials and venesections after corticosteroid therapy

Fortunately, with the use of the newer analogues of cortisone and hydrocortisone, such as delta-9 hydelta-9 deltasone and meticorten, fewer and, generally, less severe side reactions have been noted in our patients Therapeutic and maintenance dosages one-quarter to one fifth those employed with the earlier corticosteroids have proved effective It has been possible to tailor the maintenance doses to as little as 1 mg three times a day in some patients Although less retention of sodium and fluid and loss of potassium (mineralocorticoids) is consistently noted, we have found the use of potassium replacement with simultaneous diuresis (potassium) quite helpful in patients on continuous therapy Also in view of a high incidence of peptic ulcer in patients with chronic pulmonary emphysema attention should be paid to digestive complaints and weekly guaiac testing of stools should be performed

BREATHING EXERCISES, ABDOMINAL SUPPORTS

Both active and passive breathing exercises may improve the ventilatory efficiency Barach and his associates emphasized the importance of developing diaphragmatic breathing by special training and daily practice The patient is taught to lower the diaphragm, manifested by protrusion of the abdomen during inspiration and to press with both hands below the umbilicus inward and upward during the latter third of expiration These procedures tend to restore the lost diaphragmatic excursions The expiratory phase may be carried out for the sick patient passively and may help in eliminating trapped air During these exercises the lips may also be kept pursed in expiration

They suggest practicing this at first lying down, with one hand on the abdomen and one on the chest, the patient should attempt to see that the abdomen protrudes forward during inspiration, with little or no chest movement After two minutes' trial the same exercise should be tried sitting up and then walking Some patients learn this procedure quickly and the movements soon become automatic Others, particularly patients with flat abdomens and military bearing, have considerable trouble with the same procedures

We generally advocate breathing exercises designed to improve the spine and chest relationships, as well as diaphragmatic function along with abdominal belts and skeletal support (orthopedic braces) when indicated as for example for kyphoscoliosis There are many types of abdominal supports (emphysema belts) to give the abdominal compression necessary to elevate the diaphragm to the level of expiration These should be worn during the day only, and they are very useful

A definite routine may be found more helpful than the occasional use of these procedures. The patients are instructed to take three to six inhalations of vaponefrin upon arising and one hour before lunch, supper and bedtime This is followed by rhythmic deep breathing exercises. After these exercises the diaphragmatic breathing exercises previously described are performed When possible, both of these exercise procedures should be repeated six to twelve times Training should be encouraged Fatigue should be avoided A skilled and interested physiotherapist may be quite helpful In co-

operative patients the results are worth the effort Exercises should stop in time for a fifteen to thirty minute rest period before each meal

PNEUMOPERITONEUM

Several groups of investigators have cited the usefulness of this form of therapy in chronic pulmonary emphysema following the pioneering use of pneumoperitoneum therapy in pulmonary tuberculosis by Banyai[8] In many patients the cough becomes more productive Less dyspnea is noted and tolerance to mild exercise increases Improvement in appetite and weight gain may be noted Such patients rest and sleep better

The indications for pneumoperitoneum therapy can be centered about the following basic concepts (1) The restoration or improvement of the dynamic function of the diaphragm is the main object The smallest amount of air necessary to restore the diaphragm to its normal position should be employed in contrast to pulmonary tuberculosis in which lung rest is the primary aim When successful elevation of the diaphragm with adequate motions has occurred as determined by fluoroscopic control refills are given at greater intervals (2) Some degree of pulmonary reserve should be present before starting pneumoperitoneum (3) The extent of active bronchostriction should be minimal Maximum improvement with bronchodilator aerosols and clearance of infection with antibiotics should be effected prior to instituting pneumoperitoneum therapy (4) Complete evaluation of anatomic integrity of the diaphragm (atrophic changes and presence of adhesions) should be made by fluoroscopic and x ray studies (5) When the syndrome of carbon dioxide retention with respiratory acidosis occurs and remains unrelieved by adequate intermittent positive pressure therapy with 40 per cent oxygen or adequate movements of the chest cage and diaphragm do not follow respirator chamber treatment immediate pneumoperitoneum should be instituted This has life-saving value

OXYGEN THERAPY

The sudden administration of high concentrations of oxygen in an attempt to relieve dyspnea hypoxia and cyanosis in patients with chronic pulmonary emphysema and pulmonary heart disease may be followed by the distressing symptoms of so-called carbon dioxide intoxication syndrome In these patients the medullary respiratory centers appear to have lost their sensitivity to the pCO_2 stimulus for respiration (centrogenic drive) The chemoreflex drive for respiration the hypoxic stimulus from the sensory nerve endings in the carotid and aortic bodies is mainly responsible for maintaining respiration in these patients The sudden injudicious relief of hypoxia may be followed by a breakdown in the homeostatic mechanisms sustaining respiration and further hypoventilation may ensue Greater increase in the arterial pCO_2 and content may follow and ultimately respiratory acidosis, with a drop in arterial pH These factors appear primarily responsible for producing weakness, headache air hunger neurologic manifestations drowsiness coma delirium and death which may develop progressively under such conditions

The carbon dioxide retention brings about a compensatory increase in the alkali reserve (metabolic alkalosis) and a fall in serum chlorides and increase in urine chlorides When respiratory acidosis supervenes with a drop in arterial pH intravenous sodium lactate therapy may be helpful

This troublesome syndrome should not occur if one does not further depress respiration by the use of the respiratory depressing drugs (morphine barbiturates, anesthetic agents) and if the sudden administration of high concentrations of oxygen to the chronically hypoxic patient is avoided A carefully graded program of oxygen therapy should be employed consisting of daily increases in concentrations at the beginning of therapy and a gradual daily reduction in concentrations toward its cessation

The acutely ill patient who needs oxygen should be treated by nasal catheter with humidified oxygen At the outset one should employ flows of 1 L/minute The flows may be increased 1 L daily until 6 L/minute flows of oxygen are obtained A concentration of 38 per cent oxygen in the inspired air can be obtained at this flow Some variations in the flow rates may be necessary from time to time

For the routine management of chronic pulmonary emphysema wherein oxygen is necessary at times and there is no evidence of marked increase in pCO_2 e g, in acute respiratory tract infections and during troublesome bouts

of bronchoconstriction oxygen may be ideally administered with the new type plastic Oxygen Face Tent (Eliot) The undesirable features of the nasopharyngeal catheter and of the more complex and expensive rubber face masks and oxygen tents are eliminated with this tent which is designed to administer oxygen in adequate concentrations for either brief or prolonged periods The tent fits comfortably over the lower portion of the patient s face and opens widely at the forehead for easy egress of exhaled gases and vapors Forehead and head straps insure its stability Humidified oxygen enters the face tent through a shower head dispersal system With oxygen flows of 6 L /minute we obtained average concentrations in the inspired air of 52 57 per cent oxygen and carbon dioxide was kept below 0 99 per cent

Various types of enclosing tents have been devised for administration of oxygen to patients who cannot tolerate any type of face apparatus We have found the Permatent (Eliot) capable of withstanding more than the average hospital abuse It is constructed of a clear heavy gauge durable vinyl plastic with adequate zippered entrances to the safety tilitable ice compartment or the patient An adjustable neck collar comfortably encloses the patient s head Two front portholes are present for the egress of carbon dioxide or for the admission of increased concentrations of water vapor antibiotic or bronchodilator aerosols The oxygen concentrations ranged from 50 to 70 per cent and the carbon dioxide accumulations have been consistently below 1 per cent when 10 to 14 L flow of oxygen was employed

MECHANICAL RESPIRATION

If the full blown carbon dioxide intoxication syndrome appears characterized by hypoventilation respiratory acidosis severe carbon dioxide retention and the comatose state mechanical respiration employing masks chambers or electrophrenic stimulation may have life saving value

Intermittent positive pressure with simultaneous bronchodilator aerosols should then be employed to maintain adequate ventilation and still provide adequate oxygen concentrations This type of therapy supplies the gas mixture under positive pressure during the inspiratory cycle usually through a mask device There are several types of units which supply intermittent positive pressure breathing in inspiration the Bennett MSA, Emerson Hallibrton and Eliot valves We are presently employing in our studies the Vent Al Aire a multipurpose air pressure breathing unit that combines the five therapeutic functions of (1) IPPB/I—intermittent positive pressure breathing during inspiration (2) EWNP—exsufflation with a rapid negative pressure (cough) (3) resuscitation—by means of alternating positive pressure on expiration (4) therapeutic aerosols—independent supply of therapeutic aerosols during inspiration only and (5) tracheal suction—aspiration

We have found the Bennett type cycling valve very satisfactory for administering intermittent positive pressure breathing during inspiration especially for use combined with the attached nebulizer in giving bronchodilator aerosols *The patient completely controls the cycling of the valve by his own respiration rhythm* An active inflation of the lungs occurs during inspiration under positive pressure from the cycling valve The rapid release of pressure at the start of expiration is followed by a high velocity expiratory gas flow This combined with the release of bronchoconstriction which follows the simultaneous inhalation of bronchodilator aerosols promotes better bronchial drainage The period of temporary hyperventilation helps to eliminate the excess blood CO_2 We have employed pressures of 10 to 20 cm of water with mixtures of air oxygen or helium oxygen depending upon the underlying causes for respiratory failure When necessary the apparatus can be manually operated as a controlled resuscitation valve by simple fingertip rhythmic cycling

With marked slowing of respiration the Drinker Emerson or Collins type of tank respirator may be used to give artificial respiration with oxygen therapy provided by a catheter, ABC face tent or a Bennett type cycling valve The major problem lies in the difficulty in synchronizing the patient s respirations with the cycle of the respirator

The patient who has secretions accumulated in the tracheobronchial tree especially when his cough is weak and ineffective may be helped by mechanical exsufflation with negative pressure (EWNP) Barach s suggested form for artificial coughing This can be accomplished with the Eliot Vent Al Aire or the OEM Cofflator units which create pos

tive pressure on inspiration and negative pressure on expiration The change over from positive to negative pressure is instantaneous so that a rapid expiratory flow rate is achieved During this expiratory negative phase the physiologic effects of a vigorous cough are generally accomplished Positive negative pressure breathing is safer than inspiratory positive pressure breathing alone in patients with circulatory inadequacy or in peripheral circulatory collapse The mean intrapulmonary pressure throughout the cycle was close to the baseline atmospheric pressure in our studies The negative expiratory phase pressure helps to reconstitute the venous gradient and cardiac output as well as prevent a further drop in blood pressure which may follow positive pressure on inspiration alone in patients with circulatory inadequacy

PULMONO-CARDIAC COMPLICATIONS

In the seriously ill patient hypoxia becomes more pronounced with repeated bouts of respiratory infections or bronchospasm As the homeostatic mechanisms are broken down pulmono cardiac changes appear Cyanosis clubbing polycythemia hypervolemia increased cardiac output and dilatation of the right ventricle may follow Pulmonary hypertension occurs inasmuch as the increased blood flow through the lungs from the increased cardiac output cannot be handled by distending the already reduced pulmonary vascular bed The pulmonary hypertension may lead directly to right ventricular hypertrophy Subsequent heart failure awaits the next trigger mechanism

The management of this seriously ill group of patients warrants more optimism than generally was believed before if one remembers that the physiologic changes described above are largely reversible although only temporarily The basic therapy should center about (1) relief of hypoxia (2) relief of bronchoconstriction and (3) management of infection

The hypervolemia must be overcome by *repeated phlebotomies* of 250 to 350 cc each The clinical evidence of venous plethora (fullness in the head etc) the imminence of heart failure and the hematocrit level should be the guides for venesection The pulmonary artery pressure may be lowered to normal levels following venesection The periodic use of *mercurial diuretics* combined with *phlebotomies* may be of great value even in the absence of clinical evidence of frank right sided heart failure The serum chlorides should be watched for they may be lowered in the group with metabolic alkalosis and low serum chlorides compensatory to the elevation of the pCO_2 especially in patients on a low salt regimen

Digitalis should be employed when there is evidence of right ventricular failure The indication for its use in the presence of failure exists regardless of considerations of high or low cardiac outputs In addition to digitalization salt restriction and ammonium chloride should also be used in the presence of right sided heart failure The use of ammonium chloride with supplemental potassium chloride (pot amide®) may be of help when the above procedures fail

REFERENCE

1 SEGAL M S and DELFANO M J Chronic Pulmonary Emphysema Physiopathology and Treatment New York 1953 Grune & Stratton Inc

2 PROCTOR D F HARDY J B and MCLEAN R Studies of respiratory air flow II Observations on patients with pulmonary disease *Bull Johns Hopkins Hosp* 87 255 1950

3 DAYMAN H Mechanics of air flow in health and in emphysema *J Clin Invest* 30 1175 1951

4 BILLY R L and COURNAND A Analysis of factors effecting partial pressures of oxygen and carbon dioxide in gas and blood of lungs theory *J Appl Physiol* 4 77 1951

5 WEST J R BALDWIN E DEF COURNAND A and RICHARDS D W JR Physiopathologic aspects of chronic pulmonary emphysema *Am J Med* 10 481 1951

6 BANYAI A L Pneumoperitoneum Treatment St Louis 1946 C V Mosby Co

Application of Pressure, Including Exsufflation, in Pulmonary Emphysema

ALVAN L. BARACH, M D, New York, New York

From the Department of Medicine, College of Physicians and Surgeons, Columbia University, and the Presbyterian Hospital and Goldwater Memorial Hospital, New York, N Y *This study was aided by a grant from the National Foundation for Infantile Paralysis*

THE respiration of patients with pulmonary emphysema is more seriously impaired by mechanical factors than in the case of any other chronic illness An attempt will be made in this presentation to describe the physiologic events that follow the use of various types of pressure applied to the lungs and the frame of chest wall and diaphragm surrounding them The effects of air pressure to inflate and deflate the lungs have been subjected to recent study, as well as physical forces applied by the patient himself, such as manual compression of the lower chest, pursed-lip breathing and breathing exercises which increase the relaxation pressure of the lungs

Since the disturbance in the functions of the lung was originally traced to progressive distention and rupture of the alveoli, this entity was called hypertrophic or vesicular emphysema, the term "diffuse obstructive emphysema" was used to emphasize the importance of bronchial constriction as a major cause of the clinical symptomatology [1]

Although the force exerted by the playing of wind instruments or by glass blowing has been discarded as an etiologic factor in the disease, undue inspiratory distention and expiratory check-valve mechanisms may result in the development of areas of increased pressure, especially in the apices where the soft tissues offer little counterprotection Other explanations include atrophic or degenerative changes in the parenchyma of the lung, perhaps associated with local ischemia of the tissues

The etiology of pulmonary emphysema is, however, obscure, the disease in most instances being of gradual onset accompanied by the symptoms of chronic bronchitis In approximately one-third of our male patients a previous history of viral disease, especially atypical pneumonitis, is obtained within a period of two to six months before the onset of dyspnea Studies on the pathology of pulmonary emphysema pertinent to this discussion reveal the following (1) The respiratory bronchiole is frequently lengthened as a stem like tube, presumably therefore susceptible to collapse by the distended alveoli surrounding it (2) Inflammatory and fibrous tissue changes in the bronchioles produce thickening and narrowing of the lumen (3) Impairment of the bronchial blood supply due to endarteritis of the smaller vessels impair nutrition of the lung parenchyma [2]

In this discussion of the pathophysiology of the disease emphasis will be accorded to those disturbances in respiratory function that especially lend themselves to the application of pressure, which we have included in the term "physiologic therapy," i e, therapeutic attempts to restore respiratory function toward the normal, primarily by the use of physical procedures It has been customary to assume that the earliest example of this approach was the administration of oxygen, which was followed by the introduction of other gases and the varieties of pressure breathing now in use In a recent study of artificial respiration,[3] however, mouth-to-mouth insufflation was first used by Tossach in 1743 and reported by him later [4] Biblical records provide an even earlier example of successful application of pressure as a therapeutic agent, Elisha

revived the son of a Shunamite woman who had been apparently dead for some time by putting his lips over those of the child's and breathing into his lungs (mouth insufflation) Although this form of intermittent pressure breathing is a safe and effective method of resuscitation of infants,[2] the use of intermittent pressure breathing for the treatment of pulmonary emphysema is controversial The employment of pressure breathing, however, whether continuous or intermittent, has a sound physiologic basis for its employment in such clinical disturbances of respiration as pulmonary edema and obstructive dyspnea Before discussing the varieties of pressures that may be used by the technician as well as by the patient, a consideration of some of the features of pulmonary emphysema will be presented

PATHOPHYSIOLOGY

Among the most conspicuous manifestations of impairment of respiratory function is a plainly discernible interference with diffusion of oxygen and carbon dioxide The oxygen saturation of the arterial blood is frequently decreased between 75 and 93 per cent either at rest or after exercise The CO_2 tension of the arterial blood becomes elevated as the disease progresses The factors responsible for this have been listed as follows (1) increase in residual air, namely, the volume of air present in the lungs after a deep expiration which impairs diffusion by enlarging the air column through which it takes place, (2) narrowing of the smaller bronchi as a result of inflammatory change, mucus or bronchospasm, (3) irregular aeration of the alveoli, (4) diminution of the functional respiratory surface due to the merging of small alveoli into larger air sacs, (5) progressive alveolar distention associated with check-valve mechanisms, in turn associated with bronchial constriction and impaired lung tension, (6) bronchial closure during rapid breathing and coughing, the degree varying with the relative increase in intrathoracic above the intrabronchial pressure, (7) impairment of the mechanics of breathing, including the problems encountered by the patient in effective ventilation due to a depressed, flattened diaphragm and the inefficient use of the accessory muscles of breathing Among these influences the unequal alveolar ventilation seems to be of primary importance since a large part of the tidal volume appears to be wasted on bullous, poorly diffusing areas of the lungs[3]

The factor of expiratory obstruction, noted more than a century ago by Laennec,[4] was then considered to be due to the presence of mucus in the bronchial tubes The relief of bronchospasm after administration of bronchodilator compounds and inhalation of 80 per cent helium with 20 per cent oxygen, confirmed by spirometric tracings, made it clear that expiratory obstruction of the smaller bronchi was a major factor in producing dyspnea in these cases

Recently, the ventilatory disturbance has been investigated by methods which simultaneously determined (1) the intrathoracic pressure, derived either by determining the alveolar pressure through a sudden interruption of the respiratory stream with a rapidly acting valve or by measuring the intrapleural and esophageal pressures, and (2) the respiratory air flow rate obtained by pneumotachygraphic records Through the use of these technics the wide swings of intrapleural pressure from negative to positive during ordinary respiration were shown to represent the increased pressure required to move air in and out of the lungs in patients with pulmonary emphysema The decreased recoiling force of the lung parenchyma (PL) was found to be only in small part the cause of the high pulmonary pressures required for ventilation since the pressures required to move air in the bronchioles were tremendously increased, particularly during the expiratory cycle[5]

The increased intrathoracic pressure developed to overcome resistance to flow of air was found to be mainly due to turbulent viscosity rather than tissue viscosity or the frictional movement of the lung itself, this conclusion was based in part on the finding that more pressure was required to move a gas of increased density, i e, argon-oxygen mixtures[6] The studies on retarded air flow in patients with pulmonary emphysema have revealed that bronchial closure is in part the result of impaired recoil of the pulmonary parenchyma which results in a lessened outward traction on the bronchial wall but also to the increased resistance to air flow (PV) during expiration When the pressure gradient between the alveoli and the cartilage-supported ends of the bronchi drops lower than the

intrapulmonary pressure, cessation of air flow through smaller bronchi occurs PT (Thoracic Pressure) = PL (Lung Pressure, negative in relation to atmosphere) plus PV (Pressure required to maintain gas flow, or drop in pressure from alveoli to pharynx)[9]

The concept of Christie[3] that the diseased portions of the lungs fill earlier than the more normal areas was traced to their decreased "elastic" pressure The dyspnea of the patient may be perhaps in large part due to the circumstance that a considerable proportion of the tidal volume enters bullous areas of the lung that are poorly supplied diffusing membranes and blood vessels It was also observed at operations that the diseased areas empty less well after inspiratory inflation because of the lessened elasticity or decreased elastic recoil[2] The use of an intermittent pressure-breathing device does not in fact result in increase in maximal minute ventilation, vital capacity or sustained clinical benefit, if simultaneous inhalation of bronchodilator aerosols is not provided[10 11] What happens to bullous areas of the lung inflated by I P P B during expiration is a point of interest in this connection Crenshaw[2] has observed at operations that after application of a constant inspiratory pressure the diseased regions in the lung resist deflationary pressure whereas the more normal parts can be readily emptied

The development of pressure breathing as a clinical method for the treatment of pulmonary edema and obstructive dyspnea consisted at first of the use of a continuous mask pressure of approximately 6 cm H_2O The effects of this degree of pressure were briefly summarized as follows (1) an increase in the diameter of the smaller bronchi during expiration in patients with bronchial asthma as determined by x-ray lipiodol films, (2) an increase in peripheral venous pressure of 40 per cent of the applied intramask pressure in normal subjects 60 to 70 per cent in patients with decreased pulmonary elasticity such as those with cardiac failure, (3) marked prolongation of the circulation time in patients with cardiac insufficiency, (4) disappearance of pulmonary edema and relief of obstructive dyspnea (5) a warning to discontinue pressure breathing if the systolic pressure fell 15 mm Hg below its control value[12] It was later found that expiratory pressure breathing provided by exhaling in a mask equipped with variably constricted orifices was effective in treatment of edema of the lungs although much less so in alleviating obstructive dyspnea Nevertheless, it was observed that pursed lip breathing which often takes place spontaneously in patients with pulmonary emphysema, was in effect a form of expiratory pressure breathing which also increased peripheral venous pressure and enlarged bronchial diameter with immediate decrease or disappearance of wheezing rales in the chest[13]

The development of pressure breathing as a method of increasing alveolar oxygen pressure during inhalation of 100 per cent oxygen took place at high altitudes as a technic for decreasing hypoxia It was noted then that mean pressures as high as 15 mm Hg whether obtained by continuous or intermittent pressure breathing reduced cardiac output[14 15] Lower mean pressures such as 5 to 7 mm Hg possessed a variable effect, at times being accompanied by reduction of cardiac output but in some cases of cardiac failure being followed by an increase in cardiac output[16-17] perhaps due to a restoration of tone of the cardiac muscle similar to the effect previously shown as the result of pressure breathing[11] or tourniquets applied to the legs in cases of pulmonary edema

Although it was reported some years ago that inspiratory lung inflating pressures followed by expiratory negative pressures had favorable effects on the circulation in dogs,[18] additional evidence was obtained that patients treated in the tank respirator adversely affected in respect to their circulatory status by pressure breathing (induced by intratank negative pressures of 15 cm H_2O) were favorably influenced by a combination of positive lung inflating and negative lung-deflating pressures[19]

Exsufflation and exsufflation with negative pressure introduced as mechanical methods of eliminating retained bronchial secretions provided an opportunity to study positive and negative pressure breathing in the following respects (1) The duration of application of inspiratory pressure was found to be a significant factor not only in increasing mean ventilatory pressure but in augmenting lung and tidal volume[11 20 21] Thus, with a positive inspiratory pressure of 40 mm Hg a tidal volume of 2 500 cc with a 1 6 second inspiration was increased to 3 800 cc with a

3 0 second duration of inspiration Since the hazard of tearing of an emphysematous bleb is more directly related to increase in lung volume than to pressure itself, it became evident that the duration of pressure should not be sufficiently prolonged as to result in undue pulmonary distention It was also clear that a tidal volume of 2 500 cc of the lungs might be achieved with a 20 mm Hg inspiratory pressure maintained for 2 5 seconds (2) The abrupt termination of inspiratory pressure between 20 and 40 mm Hg to minus 40 mm Hg in 0 02 seconds resulted in not only a high expiratory flow rate at the start of expiration but also in a mean venous pressure actually lower than that used with a 15 mm Hg inspiratory pressure, either in the tank respirator or in intermittent pressure breathing devices The graphic record on a Statham Strain gauge of the character of mask pressure curves of the various I P P B apparatus employed with E W N P, shown in Figure 1, reveals that the

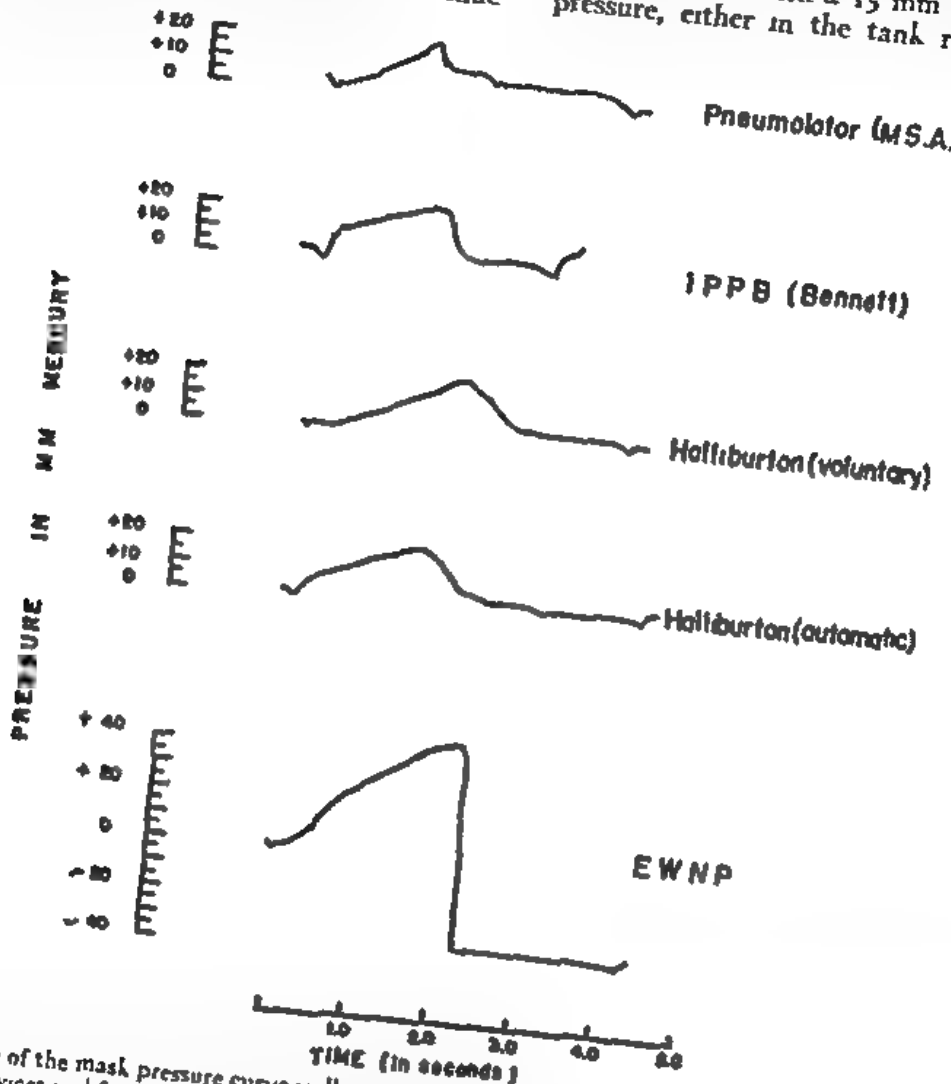

FIG 1 The shape of the mask pressure curve is illustrated for various types of supra atmospheric intermittent pressure-breathing devices and for exsufflation with negative pressure In the use of E W N P the duration of expiratory pressure is 0 02 seconds as compared to 1 second or more with the I P P B apparatus. The mean pressure over a complete respiratory cycle in the subject tested was 2 5 for the Pneumolator 7 2 with the Bennett, 5 1 for the Halliburton used with spontaneous respiration, 6 7 when used as an automatic resuscitation and −6 9 mm Hg with E W N P The low negative mean pressure with E W N P is due to a 2 second exposure to −40 mm Hg When the expiratory cycle is reduced in duration, the mean ventilatory pressure becomes atmospheric or even slightly above The graph illustrates that a mean ventilatory pressure produced by a peak 20 mm Hg pressure may be higher than that obtained with a peak 40 mm Hg pressure due to the abrupt cessation of pressure during expiration and the duration of the negative pressure selected

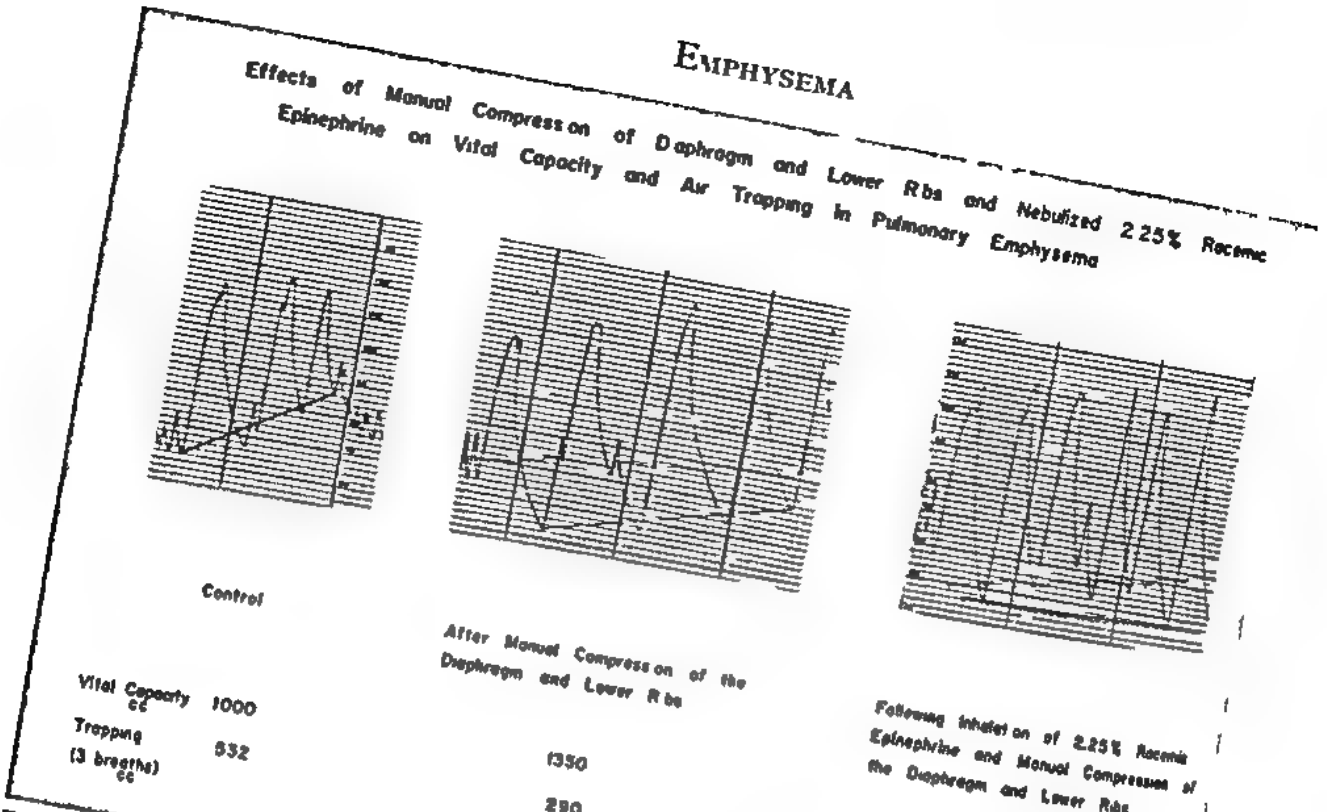

FIG 2 Manual compression of the thorax and upper abdomen resulted in diminished dyspnea a decrease in the trapping of air after three breaths from 532 to 290 cc and an elevation in vital capacity from 1 000 to 1 350 cc A still further improvement was manifested when this procedure was done after inhalation of a bronchodilator aerosol (0 5 cc vaponephrin) Trapping of air was then absent and the vital capacity rose to 1 500 cc

expiratory phase consumes at least 1 second or more in I P P B apparatus in contrast to a duration of expiration of 0 02 seconds with E W N P The mean pressure with E W N P is seen to be negative (minus 6 9 mm Hg) in contrast to elevated positive mean pressures between 2 5 and 7 2 and with I P P B 7 2 mm Hg Depending on the duration of the negative cycle the mean pressure may be made at or above atmospheric Since the highest expiratory air velocity begins at the termination of inspiration, when the diameter of the bronchi is maximally enlarged, a swift delivery of alveolar air from the bullous areas may take place before bronchial constriction takes place The reported increases in vital capacity that have followed the use of E W N P [21] may then be traced not only to elimination of obstructing mucous plugs but perhaps also to elimination of air previously trapped in the lungs, as has been demonstrated by the use of negative pressure breathing in the absence of administration of bronchodilator aerosols[11] and by manual compression of the lower ribs and upper abdomen, as seen in Figure 2 This maneuver, exercised with the palms placed on the lateral anterior margins of the lower three ribs and adjoining abdominal surface, is executed by a rapid series of three inward and upward thrusts of the hands, repeated on ten consecutive or alternate expirations The result of lessened alveolar distention is manifested by a variable increase in vital capacity between 200 and 1,000 cc In the instance seen in Figure 2 an increase from 1,000 to 1 350 cc in vital capacity occurred without administration of epinephrine and, when performed after inhalation of epinephrine, the vital capacity rose to 1,500 cc with complete absence of trapping of air This maneuver was previously shown to produce increased expiratory flow rates either when executed by itself or in conjunction with exsufflation [11 20] Following the combined use of bronchodilator aerosols and chest compression, the pulmonary ventilation is consistently decreased with a decrease in the difference between the pulmonary ventilation breathing air and breathing 100 per cent oxygen [11] Although the existence of pressure during the expiratory phase of I P P B would

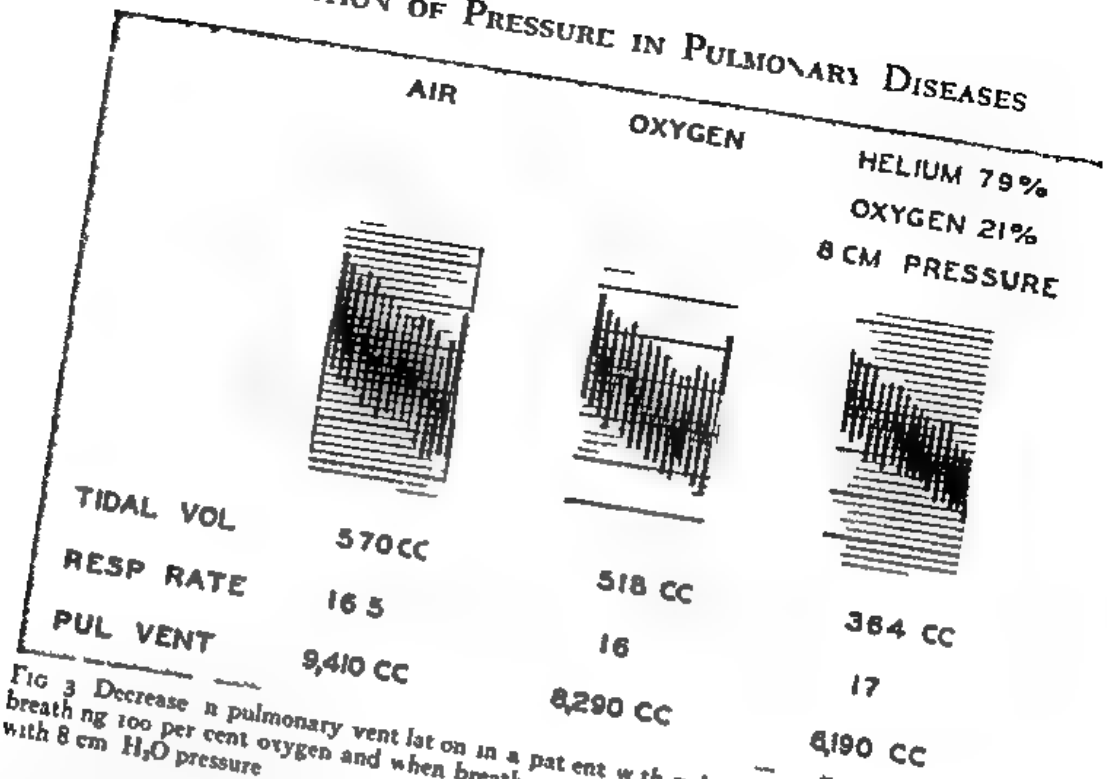

FIG 3 Decrease in pulmonary ventilation in a patient with pulmonary emphysema when breathing 100 per cent oxygen and when breathing 79 per cent helium 21 per cent oxygen with 8 cm H_2O pressure

have the advantages of maintaining a wider diameter in the smaller bronchi as well as a variable effect in preventing undue pulmonary congestion elimination of trapped air in the lungs has not been demonstrated by its use without simultaneous administration of bronchodilator aerosols [21]

Another example of the effect of purely physical factors in the relief of dyspnea in patients with pulmonary emphysema is shown in Figure 3 in which a more marked reduction in ventilation takes place as a result of inhaling a helium-oxygen mixture under 8 0 cm H_2O pressure from 9 410 to 6,190 cc than was found during the inhalation of 100 per cent oxygen Under these circumstances effective ventilation of the alveoli was presumably increased by widening of the bronchi and increased gas velocity of turbulent gas flow in regions of bronchial constriction

A similar relief of dyspnea is portrayed in Figure 4 in which a remarkable demonstration of prolonged expiration is recorded in a patient with pulmonary emphysema and fibrosis and chronic bronchitis Expiration consumed 86 per cent of the expiratory cycle a manifestation of the patient s own response to the need for adequate time to empty lungs through an evidently constricted bronchial airway Even though the helium-oxygen mixture employed contained the same concentration as that present in air its administration with a continuous pressure of 4 cm resulted in a decrease in pulmonary ventilation from 8 560 to 6 940 cc per minute with a decrease in tidal air from 955 to 534 cc The readiness with which bronchi in a patient of this type are susceptible to collapse has been commented upon in reference to the pneumotachygraphic studies of air flow Pressure breathing whether continuous or intermittent would be of symptomatic benefit by increasing bronchiolar pressure and increasing lung volume thereby preventing bronchial closure

Exsufflation with negative pressure makes use of a high lung inflating pressure to distend the bronchi sufficiently to pass air beyond occluding plugs of mucus As shown by the experimental studies of Bickerman[22] on the removal of mucin thorotrast mixtures and foreign bodies the diameter of the smaller bronchi of anesthetized dogs was enlarged twofold a critical factor in aerating the alveoli distal to the foreign substance Another favorable effect of a high pressure drop such as from a mask pressure of plus 40 to minus 40 mm Hg was considered to be the instantaneous expansion of gas approximately one-

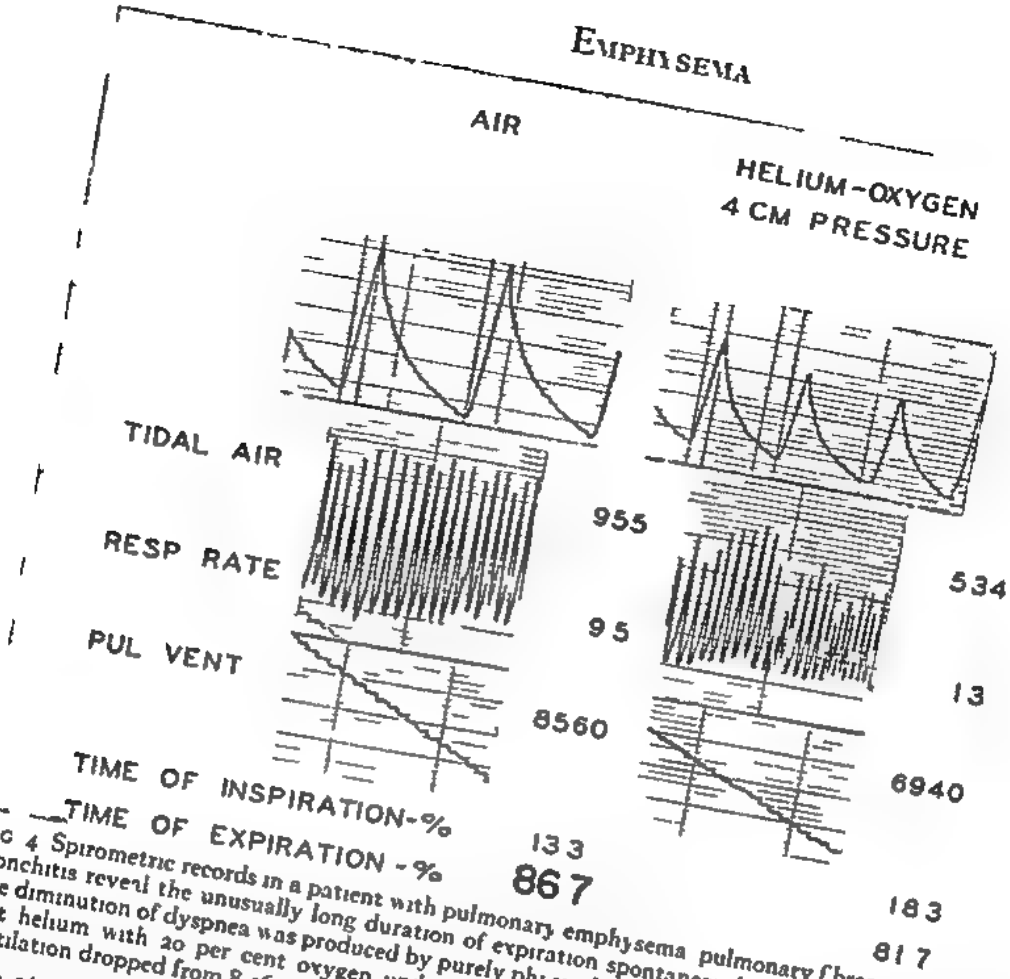

FIG 4 Spirometric records in a patient with pulmonary emphysema pulmonary fibrosis and chronic bronchitis reveal the unusually long duration of expiration spontaneously adopted by the patient The diminution of dyspnea was produced by purely physical effects namely the inhalation of 80 per cent helium with 20 per cent oxygen under continuous pressure of 4 cm H O The pulmonary ventilation dropped from 8 560 to 6 940 cc per minute and the tidal air from 955 to 534 cc

tenth of an atmosphere, which contributed the factor of explosive decompression originally used in the mechanical cough chamber The esophageal pressure being about half the mask pressure, a smaller pressure drop takes place between the bronchi and the mouth

No harmful effect has been observed in more than 4 000 treatments in over 400 patients treated In respect to the effect of this degree of positive pressure on the circulation it was pointed out that since the expiratory cycle was terminated in 0 02 seconds, the mean pressure of the respiratory cycle was not greater than that routinely used in I P P B and in the conventional tank respirator for patients with poliomyelitis In regard to the more important question of inflating the lung unduly it was previously suggested that the significant factor was the duration of application of pressure, thus when the time employed in inspiration was 1 6 seconds, a tidal volume of 2,500 cc was produced with a 40 mm Hg inspiratory peak pressure, but a doubling of the inspiration time produced 50 per cent increase in tidal volume If we were to disregard the factor of maximum explosive decompression an inspiratory pressure of 20 mm Hg is adequate to accomplish the main purpose of a full inflation of the lung and a corresponding increase in bronchial diameter The physiologic fact of the matter is that a greater degree of distention of the alveoli is accomplished with 20 mm Hg inspiratory pressure over a duration of 3 5 seconds, as shown by a tidal volume of 3,700 cc, than is achieved by a 40 mm Hg inspiratory pressure when applied for 2 seconds which results in a tidal volume of 3 200 cc in the same subject With an E W N P apparatus recently tested the time for inspiration was set at 2 0 and 2 5 seconds with an inspiratory pressure of 20 mm Hg, the resultant tidal volumes were 2 900 and 3 500 cc in the same subject However, the expiratory flow rates are substantially increased when the inspiratory pressure is raised from 20 to 30 mm Hg, with inspiration time 2 0 to 2 5 seconds

In patients with pulmonary emphysema the technic of application of E W N P is of consid

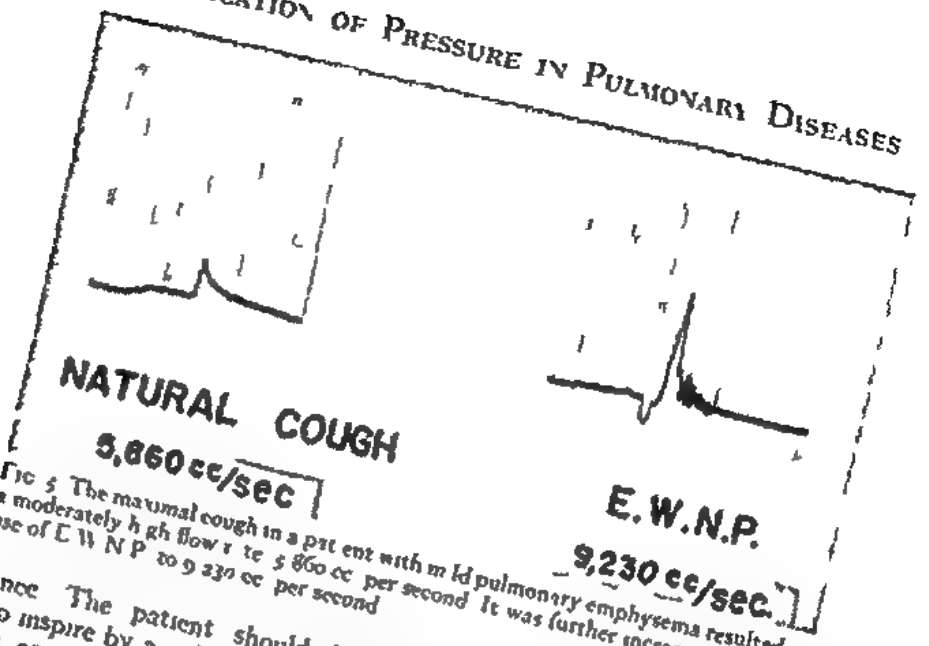

FIG 5 The maximal cough in a patient with mild pulmonary emphysema resulted in a moderately high flow rate 5 860 cc per second It was further increased with the use of E W N P to 9 230 cc per second

erable importance The patient should be instructed not to inspire by a voluntary effort nor to blow out or cough during expiration The volume of the air entering the lungs should inflate the chest inflation of lungs by applied air pressure alone prevents the inspiratory musculature from being maintained in a state of contraction at a time when abrupt deflation of the lung has been instituted In a recent survey of thirty clinic patients who had not been taught the passive method of lung inflation 30 per cent revealed a complete failure in respect to the demonstration by the pneumotachygraph of high expiratory flow rates in some continued inspiration was evident even after the tripping of the solenoid valve had developed an expiratory flow rate of 10 L per second at the mouthpiece

In patients with myasthenia gravis poliomyelitis and other neurologic disorders the maintenance of undue inspiratory contraction of the muscles of respiration naturally does not take place and effective elimination of retained mucopurulent sputum is readily obtained

When lung inflation has been satisfactorily accomplished expiration is initiated at a predetermined time interval with a sudden exposure of the upper respiratory passageway to a negative pressure of 40 mm Hg and to a current of air from a motor blower unit that has the capacity to produce a negative or suction flow of 10 L per second Expiratory flow rates measured at the mouth of between 6 000 and 10 000 cc per second have been found effective in promoting the movement of retained pulmonary secretions from the smaller bronchi into the upper respiratory passageway In cases of pulmonary emphysema low and ineffective flow rates are characteristically produced in their natural cough

Patients with pulmonary emphysema have been observed in whom substantial increase in the vital capacity has taken place even when little expectoration has followed its use It may be mentioned here that although bronchial secretions are frequently brought into the mouth in patients with neurologic disorders the use of E W N P in pulmonary emphysema is followed by a gradual movement of retained mucus into the upper respiratory passageway after a series of treatments and then expectorated by a slight or moderate coughing effort of the patient

As seen in Figure 5 the cough of maximal effort of the patient with mild pulmonary emphysema resulted in an expiratory flow rate at the start of expiration of 5 860 cc per second as compared to a flow rate of 9 230 cc per second produced by E W N P In severe cases of emphysema maximum expiratory flow rates in vigorous coughing are frequently below 3 000 cc per second Deflation of the chest takes place swiftly during the negative cycle, with a marked (6 cm) rise of the diaphragm into the chest and a marked shortening and narrowing of the bronchial tree The pressure drop of 60 to 70 mm Hg within the mask is initiated as mentioned heretofore, at a time when the bronchial tubes leading to the bullous

as well as to the more normal areas of the lung are widely dilated, the kinetic current of air thus produced may not only move secretions outward but also may deliver air from the more diseased as well as the more normal parts of the lung in a way not accomplished by forceful expiration of the patient

Other forms of pressure that have been applied by the patient himself in the treatment of pulmonary emphysema may be briefly mentioned Manual compression of the chest and upper abdomen, as indicated previously, represents a form of positive pressure applied to the thorax comparable to negative pressure applied to the upper respiratory passageway In pursed lip breathing air is slowly forced through constricted lips, in essence this is a type of expiratory pressure breathing The head down position makes use of the pressure of the viscera on the diaphragm which results in a conspicuous relief of dyspnea and an equally marked fall in pulmonary ventilation Any procedure which applies an upward pressure on the diaphragm or decreases the downward pull of the viscera on the diaphragm in effect aids the relaxation pressure of the lung The gorilla posture is of value to patients with pulmonary emphysema because it tends to prevent some of the physiologic handicaps induced in part by the erect posture, i e, hyperventilation of the periphery of the lungs especially at the apices which is produced by the upward and outward movement of the upper five intercostals the shoulder girdle and the neck muscles With diaphragmatic breathing the basal portions of the lungs as well as those near the hilum appear to be ventilated with a markedly more efficient diffusion of oxygen and carbon dioxide Methods which increase the intra abdominal pressure permit the diaphragm to assume a more convex shape as it extends into the chest, thereby promoting a favorable type of selective (lower lobe and hilar) pulmonary ventilation, this effect has been produced by pneumoperitoneum and abdominal belts

Although these patient applied procedures are presented in more detail in discussions of breathing exercises,[11 22–25] some of the physiologic features of the induced changes of the forces in action between the thorax and lungs deserve comment to complete this discussion of the effects of pressure

Physiologic effects of pursed lip breathing conducted in the manner described include an increase in bronchial diameter during the expiratory cycle and an increase in peripheral venous pressure.[11 1] Sibilant and sonorous rales frequently clear during its use This exercise reduced dyspnea during periods of exercise, in patients with latent or overt cardiac insufficiency, pulmonary congestion may be prevented by the induced, voluntary applied increased intrapulmonary pressure, which may in part explain the relief of shortness of breath following exertion Pursed lip breathing has, in fact, been effective in terminating acute pulmonary edema in a hypertensive patient in whom previous use of the expiratory pressure mask was equally effective With the employment of the procedures, the coughing of pink frothy fluid gradually stopped in twenty minutes

The physiologic basis of instituting increased diaphragmatic motion is that when the thorax is tilted toward the head, the increase in diaphragmatic excursion from 3 to 5 cm results in a more efficient alveolar gas exchange and a decrease of pulmonary ventilation of approximately 25 per cent[11 3] This ventilatory response is in itself a simple reliable test for the presence of anatomic pulmonary emphysema, perhaps superseding in value the comparative decrease in pulmonary ventilation shown by inhalation of 100 per cent oxygen as contrasted to air Since the arterial oxygen saturation and pCO_2 are either increased or unchanged in the presence of the lowered minute volume of respiration, the ventilatory equivalent, cubic centimeters of oxygen consumed per unit of ventilation, is remarkably increased by the upward visceral pressure a circumstance that led us to add a new term viscerodiaphragmatic breathing in the training practice of patients[25]

The minute volume of breathing is decreased to a variable extent as the posture of the patient changes from an erect sitting position to a 45 degree forward leaning posture As seen in Figure 6, a slight decrease in pulmonary ventilation occurred, from 10,930 to 10 66, cc, accompanied by an increase in the gas volume of the lungs, in this instance 215 cc The relaxation pressure of the lungs, or the recoil pressure of the lungs is increased 7 mm Hg when the downward pull of the viscera on the diaphragm is diminished by a change from the standing to the supine position[26] The vital

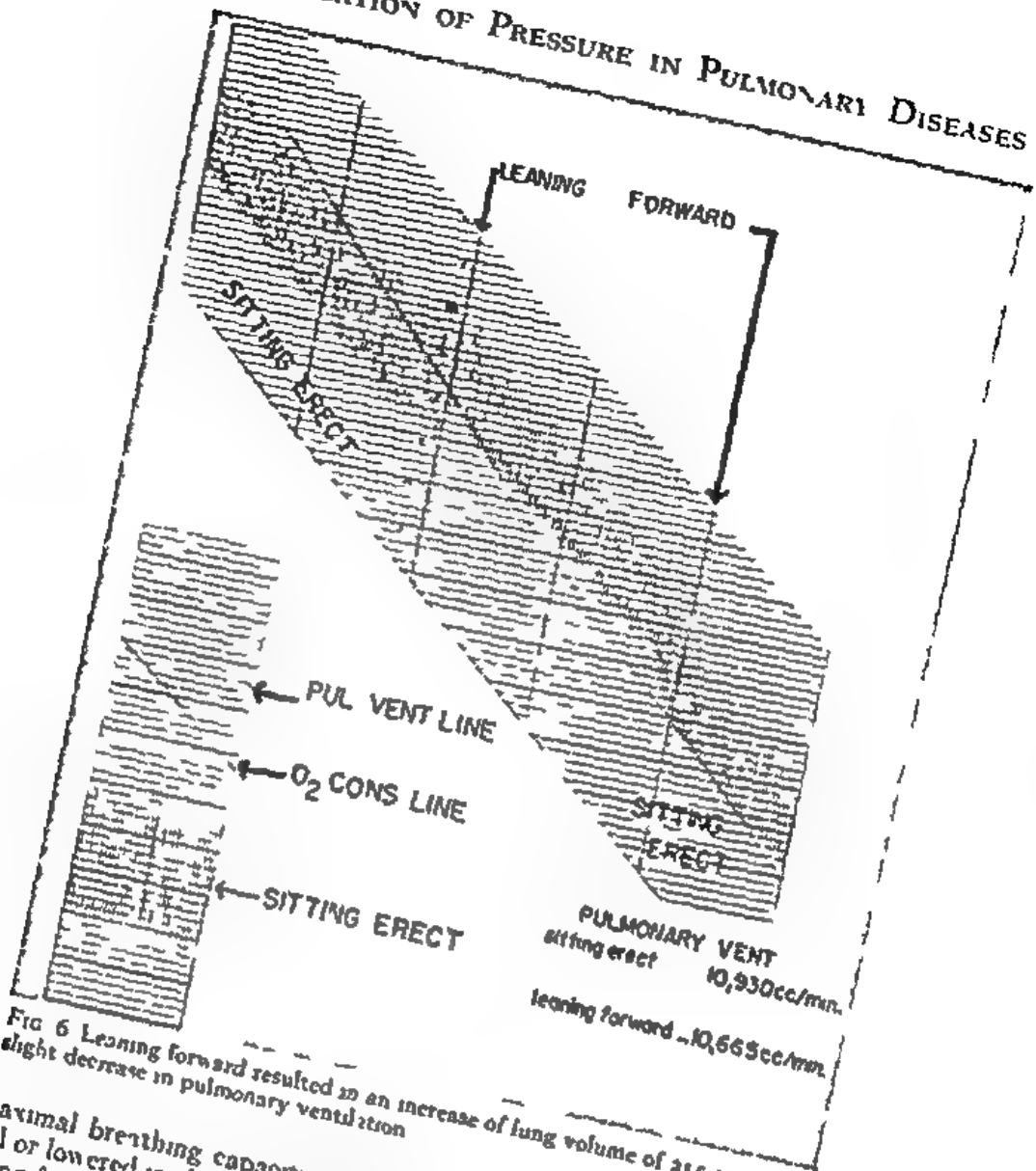

FIG 6 Leaning forward resulted in an increase of lung volume of 215 cc and a slight decrease in pulmonary ventilation

capacity and maximal breathing capacity are either unchanged or lowered in the head-down supine or leaning-forward positions, which indicates the limitations of these tests in estimating the clinical improvement and more efficient ventilation induced by diaphragmatic respiration The disadvantageous effects of the erect military posture, either sitting, standing or walking, include hyperinflation of the lung and a downward pull of the viscera which diminishes the retracting force of the lungs Breathing and postural exercise appears to have a valuable effect in the development of the capacity for moderate exertion

SUMMARY

The physiologic problems encountered by patients with pulmonary emphysema have been discussed with special reference to application of various types of pressure The functions of supra atmospheric pressure breathing, continuous or intermittent, were considered to be in the main (1) maintenance of a larger diameter of the small bronchi, which is an aid in ventilation in obstructive dyspnea, (2) a retarding influence on the inlet of blood into the heart and lungs, the degree of which is dependent on the mean applied intrapulmonary pressure, whether achieved by continuous or intermittent administration Use has been made of this circulatory response in the treatment of pulmonary edema and pulmonary congestion Pursed lip breathing, a form of expiratory pressure breathing is at times adopted by the patient and to a limited extent may fulfill both purposes The employment of

positive negative pressure breathing in resuscitation has the advantage of a nearly normal mean pressure, and is therefore indicated in patients in shock who require mechanical ventilation Exsufflation with negative pressure a form of positive-negative pressure breathing is characterized by the production of high expiratory flow rates Its function is that of aiding elimination of retained bronchial secretions but other effects may include an increased delivery of air from bullous parts of the lungs The mean ventilatory pressure of E W N P may be adjusted to a negative (subatmospheric) or a positive (supra atmospheric) pressure depending upon the length of the negative pressure cycle

Some of the effects of viscerodiaphragmatic breathing on the pressure relationships between the lung and its surrounding frame of thorax and abdomen are discussed, especially in respect to the decrease in pulmonary ventilation and dyspnea which is induced in patients with pulmonary emphysema

REFERENCES

1 Miller R D and Helmholtz H F The problem of pulmonary emphysema *M Clin North America* p 1051 1954

2 Crenshaw G L Surgical management of degenerative lung disease *J A M A* 156 1561 1954

3 Elam J O Brown E S and Elder J D Jr Artificial respiration by mouth-to-mask method *New England J Med* 250 749 1954

4 Tossach W Man dead in appearance recovered by distending lungs with air Medical Essays and Observations, 5th ed p 108 London and Edinburgh 1771 T Cadell & J Balfour

5 Christie R V Emphysema of the lungs *Brit M J* 1 4333 1944

6 Laennec R T H A treatise on the diseases of the chest in which they are described according to their anatomical characters and their diagnosis established on a new principle by means of acousticle instruments p 87 (Translated by John Forbes) Philadelphia 1823 James Webster

7 Dayman H G Mechanics of air flow in health and emphysema *J Clin Investigation* 30 1175 1951

8 Proctor D F Hardy J B and McLean R Studies on respiratory air flow *Bull Johns Hopkins Hosp* 87 225 1950

9 Frey L L Ebert R V Stead W W and Brown C C Mechanics of pulmonary ventilation in normal subjects and in patients with pulmonary emphysema *Am J Med.*, 16 80 1954

10 Fowler, W S Helmholtz H and Miller, R D Treatment of pulmonary emphysema with aerosolized bronchodilator drugs and intermittent positive-pressure breathing *Proc Staff Meet Mayo Clin* 28 743 1953

11 Barach A L Bickerman H A and Beck G J Advances in the treatment of non tuberculous pulmonary disease *Bull New York Acad Med* 28 353 1952

12 Barach A L Martin J and Eckman M Positive pressure respiration and its application to the treatment of acute pulmonary edema *Ann Int Med* 12 754 1938

13 Barach A L Fenn W O Ferris E. B and Schmidt C F The physiology of pressure breathing a brief review of its present status *J Aviation Med* 18 73 1947

14 Rahn H Otis A B Chadwick L E and Fenn W O The pressure-volume diagram of the thorax and lung *Am J Physiol* 146 161 1946

15 Motley H L Cournand A Werko L Dresdale D T Himmelstein A and Richards, D W Intermittent positive pressure breathing *J A M A* 137 370 1948

16 Barach A L. Eckman M Ginsberg, E Rumsey C. C Korr, I Eckman I and Besson G Studies on positive pressure respiration *J Aviation Med* 17 290 1946

17 Bickerman H A and Beck G J Pressure breathing with oxygen and helium-oxygen in pulmonary edema and obstructive dyspnea. *Bull New York Acad Med* 26 410 1946

18 Birnbaum G L and Thompson S A Mechanism of asphyxial resuscitation resuscitation with inert asphyxiating gas in advanced asphyxia *Surg Gynec & Obst* 75 79 1942

19 Maloney J B Elam J O Handford S W, Balla G A Eastwood D W Brown E S and Ten Pas R H Importance of negative pressure phase in mechanical respirators. *J A M A* 152 212 1953

20 Barach A L. Beck G J Bickerman H A Seanor E and Smith W H Physical methods simulating mechanisms of the human cough. *J Appl Physiol* 5 85 1952

21 Barach A L and Beck G J Exsufflation with negative pressure physiologic and clinical studies in poliomyelitis, bronchial asthma, pulmonary emphysema and bronchiectasis. *Arch Int Med* 93 825 1954

22 Bickerman H A Exsufflation with negative pressure (E W N P) elimination of radiopaque and foreign bodies from bronchi of anesthetized dogs *Arch Int Med* 93 698 1954

23 Bickerman H A and Beck, G J Physiologic factors in the treatment of hypertrophic pulmonary emphysema. *Ann Int Med* 36 607 1952

24 Barach A L Advances in the treatment of diseases of the chest *Cincinnati J Med* 30 131 149

25 Barach A L and Beck, G J The ventilatory effects of the head-down posit on in pulmonary emphysema *Am J Med* 16 55 1954

26 Otis A B Rahn H and Fenn W D Venous pressure changes associated with positive intrapulmonary pressures their relationship to the distensibility of the lung *Am J Physiol.*, 146 307 1946

Rationale of Pneumoperitoneum

ANDREW L. BANYAI, M.D., *Milwaukee, Wisconsin*

SUCCESS or failure of any therapeutic measure is predicated, first of all, upon correct diagnosis. It is therefore necessary to point out that the subject of this text is so called hypertrophic emphysema. Before resorting to any form of treatment of this condition it is mandatory to differentiate it from clinical entities with similar symptoms, and also to recognize the fundamental differences between this disease and senile emphysema. Briefly, so-called hypertrophic emphysema is a chronic pulmonary disease while senile emphysema is an involutional state a degenerative process associated with advanced age.

The essential physiopathologic substrate of so-called hypertrophic emphysema is composed of three deviations from normal. These are (1) bronchoalveolar changes, (2) muscular disturbances and (3) cardiovascular alterations. Intelligent, purposeful therapy should aim at their correction or amelioration.

Bronchoalveolar changes are noted in the form of distention, destruction and confluence of alveoli and in the form of stenosis or occlusion of bronchi and bronchioles either by spasm or by fibrosis or both. It is not irrelevant from the viewpoint of applicability of artificial pneumoperitoneum or any other method of treatment to recognize chronic, excessive cough as the principal factor in the etiology of emphysema. It is known that during the process of coughing the intrapulmonary pressure is increased. Compressed air contained in the lung is the expulsive medium which is instrumental in the removal of inflammatory exudate or other material from the air passages. The degree of pulmonary pneumatic hypertension during cough depends upon the force exerted by the expiratory muscles (rectus abdominis, the external and internal oblique and transverse abdominal, and also, the internal intercostal muscles). During a severe coughing spell the intrapulmonary pressure may rise to 200 mm. of mercury over and above atmospheric pressure. Cough as a reflex mechanism is a useful defense reaction of the body, nevertheless, even under the best of circumstances it represents undue stretch and strain upon the alveoli and the elastic elements of the lung. When this aerodynamic trauma is intense, frequent and protracted enough, its detrimental effect is inevitable.

Destruction of the alveoli and elastic elements of the lung inexorably follows chronic, severe, uncontrolled cough. The deleterious influence of cough upon these structures depends not only upon the severity of cough but also upon the pathologic conditions which are the incentive causes of cough and also upon the age of the patient. When as the consequence of infection the vitality of the lung tissue is impaired, or because of diminished blood flow through fibrosed vessels the nutrition of these tissues is below par, they become more vulnerable to the destructive force of tussic aerodynamic trauma. For an expedient orientation in the management of so-called hypertrophic emphysema, therefore, the role of cough as the most important causative factor must be accepted. At the same time it is well to remember that emphysema in itself may provoke cough. Emphysema leads to hypoxia. Hypoxia, in turn, results in increased irritability of the sensory nerve endings of the bronchial mucosa and thus induces more cough. Obviously this situation represents a vicious circle which if not broken may have grave consequences.

The alveoli are the specific end points for oxygen uptake and for the elimination of carbon dioxide. Extensive destruction of alveoli interferes with the normal respiratory function of the lung. The loss of alveoli and the consequent respiratory insufficiency are aggravated by the disappearance of the elastic elements of the lung. Because of the latter a functional deficiency develops in the lung as well as in the

muscles of the thorax, including the diaphragm The elastic elements exert a constant centripetal (hilusward) traction The centripetal traction is responsible for the expiratory contraction of the lung With pronounced loss of the elastic elements expiratory hilusward recoil of the lung is greatly reduced or it is entirely absent

The intrapleural negative pressure is another manifestation of the centripetal traction of the elastic elements of the lung The intrapleural negative pressure holds the lung in apposition to the chest wall, also it draws the chest wall inward This inward pull prevents abnormal distention of the thoracic cage through the force of the inspiratory muscles Moreover, the suction effect of the intrapleural negative pressure is instrumental in holding the diaphragm at its normal level

With marked loss of pulmonary elasticity, the thoracic cage is dilated (barrel chest) and the diaphragm occupies a constant, abnormally low position Both of these changes are of crucial importance relative to pulmonary ventilation and respiration Normally the centripetal traction of the elastic fibers of the lung is competent to maintain a physiologic and anatomic balance against the combined effect

intercostal cartilaginous portion of the internal intercostal levatores costarum and the superior and inferior serratus posticus muscles) With the loss or pronounced reduction of the centripetal traction—which is associated with a lessening or complete disappearance of the intrapleural negative pressure—the influence of the inspiratory muscles and of the pressure of atmospheric air are unopposed Consequently, the bony cage of the thorax is distended to an extent its anatomic limitations permit If this is so it can be readily appreciated that in this overexpanded condition the inspiratory muscles are unable to attain further distention of the chest wall Approximately 50 per cent of ventilatory failure in emphysema is explainable on this basis

Like the inspiratory muscles of the bony cage of the thorax the diaphragm becomes functionally incompetent in its characteristically low position in emphysema The serious implications of this positional change of the diaphragm become more obvious if one recalls the site of origin and normal location of this muscle Its muscular fibers originate from the posterior surface of the xyphoid process of the sternum from the inner surface of the costal cartilages and adjacent portions of the lower six ribs from the lumbrocostal arches and from the lumbar vertebrae During expiration the highest point of the dome of the diaphragm corresponds to the following bony landmarks in the anterior midline the xyphosternal notch in the mid clavicular line the lower surface of the fourth rib on the right side and the upper surface of the fifth rib on the left side the level of the angle of the scapula on the right side and 1 inch below the angle of the scapula on the left side and the level of the spine of the eighth thoracic vertebra The expiratory rise of the relaxed diaphragm is accomplished by the suction effect of the intrapleural negative pressure The latter is the same on both sides of the chest The equality of right and left intrapleural negative pressures assures mediastinal balance The right pleural cavity being larger than the left this equilibrium is made possible only by a low

peculiarity of the right apex of the lung and the higher position of the right hemidiaphragm is compared to the left

Decrease in or complete disappearance of the intrapleural negative pressure in emphysema permits the gravitational force of atmospheric air to distend the lung This change together with lack of upward suction are responsible for the characteristically low position of the diaphragm In advanced cases of emphysema the diaphragm may be found from 5 to 10 cm lower than its normal position Because of this further inspiratory descent may be slight or entirely absent I have noted in a number of instances twitching of the diaphragm (diaphragmatic athetosis) as an inspiratory equivalent Functional insufficiency of the diaphragm is a cardinal feature of emphysema From 37 to 47 per cent of air ventilated by the lung on quiet respiration is accounted for by the cyclic descent and ascent of the diaphragm

Years of experience have convinced me that artificial pneumoperitoneum is capable of restoring diaphragmatic function in patients with emphysema to an extent which is sufficient to relieve respiratory embarrassment or even

to restore normal physical workability Pathologic changes represented by extensive destruction of alveoli and elastic elements of the lung are irreversible Restitution of these tissues is a physical impossibility This fact means an inherent limitation in the treatment of this disease regardless of the type of therapeutic intervention Even so by improving diaphragmatic function one can utilize the remaining intact components of the lung

Artificial pneumoperitoneum is a simple and safe procedure which can be carried out by physicians of average manual dexterity Injections of 500 to 800 cc of air at weekly intervals bring about the desired result Technical details of this procedure and other pertinent information have been outlined by the author in previous publications At this time I wish to emphasize the following points concerning artificial pneumoperitoneum

1 Elevation of the diaphragm is attributable partly to the upward pressure of the air injected and partly to the neutralization of the subdiaphragmatic negative pressure Elevation of the diaphragm takes place when air occupies the subdiaphragmatic space Organs normally in apposition to the diaphragm (liver stomach spleen) are separated from it (visceroptosis)

2 Under the influence of artificial pneumoperitoneum the intrapleural pressure becomes more negative This greater negativity draws the diaphragm upward and the chest wall inward In consequence of the latter the inspiratory muscles of the chest wall are likely to regain some of their normal function and thus facilitate respiratory excursions of the chest wall Artificial pneumoperitoneum changes adiaphragmatic respiration into diaphragmatic respiration and simultaneously a dyspneic state into a eupneic one

3 In consequence of improved ventilatory function more oxygen reaches the lung and the inhaled air is evenly distributed The elimination of pulmonary pneumatic dyskinesia (faulty distribution of tidal air) is an important phase of the therapeutic potentiality of pneumoperitoneum Consequently oxygen saturation of the arterial blood is increased and its carbon dioxide concentration is decreased All patients with clinically manifest emphysema live in an inner environment of constant hypercapnia The latter results in symptoms which may be easily misinterpreted These include headache irritability lassitude malaise drowsiness somnolence confusion stupor and coma Hypercapnia may have a fatal termination In some extreme instances of hypercapnia artificial pneumoperitoneum may be life-saving

4 By re-establishing negative pressure in the pleural cavity or by increasing the negativity of the intrapleural pressure return of venous blood from the greater circulation to the heart is facilitated This is associated with a lowering of the venous pressure Exceptions to this rule are attributable to peculiar circumstances—extensive pulmonary damage by loss of specific tissues diaphragmatic fixation or atrophy severe cor pulmonale—but they do not invalidate the possible therapeutic benefits of this measure Increased negativity of the intrapleural pressure reconstitutes the gradient from the right ventricle to the capillaries of the pulmonary artery The resulting improved circulation in the lung contributes substantially to the correction of abnormal oxygen–carbon dioxide exchange and at the same time relieves the work of the right ventricle

5 Increased intraperitoneal pressure attained by pneumoperitoneum causes reflex relaxation of the peribronchial and peribronchiolar smooth muscles Bronchospasm may be an antecedent causative factor of emphysema By partial occlusion of the bronchial lumen spasm may result in a check valve mechanism This permits the inflow and prevents the outflow of air at sites distal to the constriction The consequent alveolar distention may end in rupture of the alveolar walls Bronchospasm is a common accompaniment of emphysema It is due either to coexistent pulmonary infection or fibrosis or to emphysematous changes themselves In any event, bronchospasm is a liability in that it interferes with the free passage of air current leads to dyspnea and increases cough irritability

6 There are two additional coincidental benefits of pneumoperitoneum treatment (1) alleviation of respiratory fatigue and (2) improvement in the cough mechanism with more forceful expectoration With the relief from peripheral venous stagnation reflex constriction of the renal vessels and consequent elevation of systemic blood pressure may be corrected

Artificial pneumoperitoneum has been used for the treatment of emphysema for more than a quarter of a century Empiric clinical observations as well as respiratory function

muscles of the thorax, including the diaphragm The elastic elements exert a constant centripetal (hilusward) traction The centripetal traction is responsible for the expiratory contraction of the lung With pronounced loss of the elastic elements, expiratory hilusward recoil of the lung is greatly reduced or it is entirely absent

The intrapleural negative pressure is another manifestation of the centripetal traction of the elastic elements of the lung The intrapleural negative pressure holds the lung in apposition to the chest wall also, it draws the chest wall inward This inward pull prevents abnormal distention of the thoracic cage through the force of the inspiratory muscles Moreover, the suction effect of the intrapleural negative pressure is instrumental in holding the diaphragm at its normal level

With marked loss of pulmonary elasticity, the thoracic cage is dilated (barrel chest) and the diaphragm occupies a constant, abnormally low position Both of these changes are of crucial importance relative to pulmonary ventilation and respiration Normally the centripetal traction of the elastic fibers of the lung is competent to maintain a physiologic and anatomic balance against the combined effect of the gravitational force of the atmospheric air and the outward pulling action of the inspiratory muscles of the thoracic wall (external intercostal, cartilaginous portion of the internal intercostal, levatores costarum and the superior and inferior serratus posticus muscles) With the loss or pronounced reduction of the centripetal traction—which is associated with a lessening or complete disappearance of the intrapleural negative pressure—the influence of the inspiratory muscles and of the pressure of atmospheric air are unopposed Consequently, the bony cage of the thorax is distended to an extent its anatomic limitations permit If this is so it can be readily appreciated that in this overexpanded condition the inspiratory muscles are unable to attain further distention of the chest wall Approximately 50 per cent of ventilatory failure in emphysema is explainable on this basis

Like the inspiratory muscles of the bony cage of the thorax, the diaphragm becomes functionally incompetent in its characteristically low position in emphysema The serious implications of this positional change of the diaphragm become more obvious if one recalls the site of origin and normal location of this muscle Its muscular fibers originate from the posterior surface of the xyphoid process of the sternum from the inner surface of the costal cartilages and adjacent portions of the lower six ribs, from the lumbrocostal arches and from the lumbar vertebrae During expiration the highest point of the dome of the diaphragm corresponds to the following bony landmarks in the anterior midline the xyphosternal notch, in the mid clavicular line the lower surface of the fourth rib on the right side and the upper surface of the fifth rib on the left side, the level of the angle of the scapula on the right side and 1 inch below the angle of the scapula on the left side and the level of the spine of the eighth thoracic vertebra The expiratory rise of the relaxed diaphragm is accomplished by the suction effect of the intrapleural negative pressure The latter is the same on both sides of the chest The equality of right and left intrapleural negative pressures assures mediastinal balance The right pleural cavity being larger than the left, this equilibrium is made possible only by a low position of the right apical region and by a high position of the hemidiaphragm on the right In this physiologic phenomenon lies the explanation of the hitherto unsolved topographic peculiarity of the right apex of the lung and the higher position of the right hemidiaphragm as compared to the left

Decrease in or complete disappearance of the intrapleural negative pressure in emphysema permits the gravitational force of atmospheric air to distend the lung This change together with lack of upward suction are responsible for the characteristically low position of the diaphragm In advanced cases of emphysema the diaphragm may be found from 5 to 10 cm lower than its normal position Because of this further inspiratory descent may be slight or entirely absent I have noted in a number of instances twitching of the diaphragm (diaphragmatic athetosis) as an inspiratory equivalent Functional insufficiency of the diaphragm is a cardinal feature of emphysema From 37 to 47 per cent of air ventilated by the lung on quiet respiration is accounted for by the cyclic descent and ascent of the diaphragm

Years of experience have convinced me that artificial pneumoperitoneum is capable of restoring diaphragmatic function in patients with emphysema to an extent which is sufficient to relieve respiratory embarrassment or even

to restore normal physical workability Pathologic changes represented by extensive destruction of alveoli and elastic elements of the lung are irreversible Restitution of these tissues is a physical impossibility This fact means an inherent limitation in the treatment of this disease regardless of the type of therapeutic intervention Even so, by improving diaphragmatic function one can utilize the remaining intact components of the lung

Artificial pneumoperitoneum is a simple and safe procedure which can be carried out by

tion have been outlined by the author in previous publications At this time I wish to emphasize the following points concerning artificial pneumoperitoneum

1 Elevation of the diaphragm is attributable partly to the upward pressure of the air injected and partly to the neutralization of the

2 Under the influence of artificial pneumoperitoneum the intrapleural pressure becomes more negative This greater negativity draws the diaphragm upward and the chest wall inward In consequence of the latter, the inspiratory muscles of the chest wall are likely to regain some of their normal function and thus facilitate respiratory excursions of the chest wall Artificial pneumoperitoneum changes adiaphragmatic respiration into diaphragmatic respiration and simultaneously a dyspneic state into a eupneic one

3 In consequence of improved ventilatory function, more oxygen reaches the lung and the inhaled air is evenly distributed The elimination of pulmonary pneumatic dyskinesia (faulty distribution of tidal air) is an important phase of the therapeutic potentiality of pneumoperitoneum Consequently, oxygen saturation of the arterial blood is increased and its carbon dioxide concentration is decreased All patients with clinically manifest emphysema live in an inner environment of constant hypercapnia The latter results in symptoms which may be easily misinterpreted These include headache, irritability, lassitude, malaise, drowsiness, somnolence, confusion, stupor and coma Hypercapnia may have a fatal termination In some extreme instances of hypercapnia artificial pneumoperitoneum may be life-saving

4 By re-establishing negative pressure in the pleural cavity or by increasing the negativity of the intrapleural pressure, return of venous blood from the greater circulation to the heart is facilitated This is associated with a lowering of the venous pressure Exceptions to this rule are attributable to peculiar circumstances—extensive pulmonary damage by loss of specific tissues, diaphragmatic fixation or atrophy, severe cor pulmonale—but they do not invalidate the possible therapeutic benefits of this measure Increased negativity of the

to the correction of abnormal oxygen-carbon dioxide exchange, and at the same time relieves the work of the right ventricle

5 Increased intraperitoneal pressure attained by pneumoperitoneum causes reflex relaxation of the peribronchial and peribronchiolar smooth muscles Bronchospasm may be an antecedent, causative factor of emphysema By partial occlusion of the bronchial lumen, spasm may result in a check-valve mechanism This permits the inflow and prevents the outflow of air at sites distal to the constriction The consequent alveolar distention may end in rupture of the alveolar walls Bronchospasm is a common accompaniment of emphysema It is due either to coexistent pulmonary infection or fibrosis or to emphysematous changes themselves In any event,

benefits of pneumoperitoneum treatment (1) alleviation of respiratory fatigue and (2) improvement in the cough mechanism with more forceful expectoration With the relief from peripheral venous stagnation, reflex constriction of the renal vessels and consequent elevation of systemic blood pressure may be corrected

Artificial pneumoperitoneum has been used for the treatment of emphysema for more than a quarter of a century Empiric clinical observations as well as respiratory function

studies attest to its value Of course it is recognized that it has its therapeutic limitations In selecting patients for this treatment the following possibilities should be kept in mind as causes of failure (1) anatomically and functionally irreversible, extensive loss of alveoli and elastic elements of the lung, with intact components insufficient for competent respiration under the best of circumstances, (2) widespread pulmonary fibrosis which not only replaces the major part of the essential elements of the lung but also by its solidity renders the lung virtually rigid and unexpandable, (3) sustained bronchospasm which cannot be alleviated by appropriate measures, (4) diaphragmatic adhesions which result in *fixation of this muscle and render its elevation* impossible, (5) atrophy of disuse of the diaphragm is a grave sequel of long standing emphysema, at this stage the diaphragm is functionally useless, (6) heart failure which cannot be corrected, and (7) uncontrollable complications which interfere with cardiorespiratory function

CONCLUSIONS

An analytic assaying of the pathogenesis and pathologic physiology of so-called hypertrophic emphysema points toward restoration of the normal position and function of the diaphragm as an expedient therapeutic measure Clinical observations and results have vindicated the postulate that artificial pneumoperitoneum is a serviceable treatment of this disease

REFERENCES

BANYAI A L Pneumoperitoneum Treatment. St Louis, *1946* C V *Mosby Co*

BANYAI A L. Hypertrophic emphysema its pathogenesis, pathomechanics and modern treatment. *M Rec & Annals* 46 351, 1952

BANYAI A L. So-called hypertrophic emphysema *Dis. of Chest* 25 25 1954

45

Pathogenesis and Management of Pneumoconiosis

ARTHUR J VORWALD M D Detroit Michigan

From the Department of Indu trial Med cine and H g ene Wayne Un vers ty College of Med cine Detro t M ch gan

CERTAIN clinical manifestations are frequently interpreted as the result of exposure to the inhalation of an air borne substance with little or no regard to the presence or absence of any pulmonary abnormality directly due to that exposure Thus the manifestations are often labelled as pneumoconiosis without a clear concept of the full meaning of that term and of the requirements essential for its clinical application

The term pneumoconiosis has come to be recognized generally as an entity which is due to the pulmonary depos tion of an inhaled particulate substance in the solid phase and has two distinct appl cations firstly as a condition unassociated with any significant pathology or clinical symptoms and secondly as a disease accompanied by specific inflammation of the lung and frequently associated with loss of pulmonary function and the occurrence of cl nical signs and symptoms of respiratory distress It will be noted that the definition l mits the term to a particulate substance Therefore living organisms and the majority of organic substances with their respective inflammatory allergic and toxic effects are excluded

PATHOGENESIS OF PNEUMOCONIOSIS

The nature of pneumoconiosis is determined by a number of variable factors which operate independently but which have a reciprocal relationship and wh ch must be appreciated in arriving at a diagnostic opinion Those factors may be cons dered according to two major categories namely those which pertain to the environment especially the air borne particulate substance and those concerning the person exposed to that environment *Environmental factors* (1) physical and chemical characteristics of the particulate substance suspended in the atmosphere at the breathing level of the exposed individual (2) concentration of the particulate substance in that atmosphere (3) biologic capacity of that particulate substance upon inhalation and deposition in the lung to produce pulmonary damage *Personal factors* (1) health status of the exposed individual especially as it concerns the respiratory tract and particularly the lung (2) duration of exposure to the inhalation of the particulate substance and its concentration in the lung (3) inherent variation in the manner in which d fferent exposed individuals respond to the inhalation and pulmonary deposition of the particulate substance

Physical and Chemical Characteristics of the Particulate Substance Studies to date indicate that spherical particles greater than 10 microns in diameter are seldom found in the air spaces of the lung This is apparently due to the fact that particles greater than 10 microns seldom if ever remain suspended in the atmosphere for any length of time or they are too large to pass the filtering mechanisms in the upper respiratory tract and the smaller bronchioles Thus the presence of those particles in the atmosphere can be largely eliminated from etiologic consideration Elongated particles of fibrous material such as asbestos are an exception to that rule Presumably the flexibility of these fibers and their ability to conform to the shape and dimension of the small air passage permits them to reach the respiratory bronchioles and occasionally the terminal alveolar space

Air borne spherical particles less than 3 microns in size are of paramount significance They constitute by far the greatest number discovered in the alveolar spaces and tissue Particles less than 0 5 micron are particularly dangerous not only because of their ability to remain suspended in the air and to be easily

inhaled, but also in view of the experimental evidence that particles of submicroscopic size, at least of certain substances, provoke pulmonary changes which are quite different from those caused by larger particles having the same chemical composition For example, when pure amorphous free silicon dioxide is disseminated as a fume with ultimate particles in the order of 0 1 micron or less in size, and inhaled by rabbits, it produces in them diffuse and cellular pneumonitis which is accompanied by early and profound respiratory distress This series of events does not occur in simple nodular silicosis which results from the inhalation and pulmonary deposition of crystalline free silicon dioxide in particles with a mean size between 1 and 3 microns in diameter

The chemical composition of the particulate substance to which the individual may have been exposed is, of course, of primary importance in the pathogenesis of pneumoconiosis The literature is replete with studies of pure particulates and their toxic action on tissues of the body It is not generally appreciated however, that the air borne contaminant may consist of a mixture of substances which necessitate careful analysis before they are quantitatively and qualitatively detected The mixed contaminant may provoke an entirely different hazard to the lung than either component of the mixture acting as a single agent The action of one component upon the other may cause agglutination of the particles in the atmosphere The resulting clumps become too heavy for prolonged suspension and too large for inhalation A classic example in that regard pertains to a particulate mixture of calcined gypsum which is inert, and crystalline free silica in the form of quartz dust Furthermore, one component of the mixture may coat the offending particle and thereby minimize or prevent its toxic action upon tissues of the body This appears to be the mechanism whereby the toxic action of particulate crystalline free silica is inhibited by powdered metallic aluminum or by hydrated alumina In contrast, the air borne particulates of a mixture of substances may induce a characteristic and frequently severe inflammatory reaction in the lung This is the case, for example, in the instance of exposure to the inhalation of zinc beryllium silicate powder with beryllium oxide in the free or uncombined state, and also of particulate carbonaceous material mixed with quartz dust

Atmospheric Concentration The concentration of the small particles suspended in the atmosphere at the breathing level of the exposed person is exceedingly important Obviously, the concentration determines in large measure the number that may be inhaled Just how high that concentration must be in the case of a specific aerosol, before demonstrable changes result in the lung are the subject of continued clinical and experimental study The toxic effects of many particulates have been prescribed in terms of maximum allowable concentration which must not be exceeded if damage to the respiratory tract and lung is to be avoided The values may not be applicable to every situation and they do not guarantee that health will be maintained on the part of the exposed individual Furthermore, some of the values are only tentative, pending more definite experience with the respective substance However, the values do provide a ready bench mark for engineering control measures and for guidance of the industrial hygienist and the physician

Biologic Capacity The inherent toxicity of the substance is perhaps the most important of all the factors outlined as determinants in the pathogenicity of pneumoconiosis Therefore, it is unfortunate that the precise toxicity of an inhaled particulate aerosol is so difficult to ascertain in the human subject This is true not only because the aerosol may be a mixture of substances, but also because the amount deposited in the lung and the duration of exposure cannot be determined with the desired degree of exactness In addition it is impossible to assess toxicity by examination of a single individual who in final analysis may be unusually susceptible or who may not reflect the identical situation involving other individuals exposed to the same aerosol Therefore many toxicity studies are based upon inhalation experiments with animals, wherein the atmospheric concentration of the particulate aerosol and the duration of exposure can be controlled and correlated with grades of tissue reaction at definite intervals of time While many experiments have failed to reproduce abnormal changes identical to those observed in man, it is true that animals provide at least indirect evidence of the probable fundamental principles which govern the toxicity of an atmospheric contaminant for human beings. In the absence of adequate experience with man the experimental evidence is extremely

valuable, at least insofar that it affords a guide for the understanding of similar evidence in man and also serves as a warning against human exposure beyond certain limits

Personal Factors Space does not permit an elaborate discussion of each and every factor which pertains to the exposed individual *per se* and which has reference to the pathogenicity and indeed to the management of pneumoconiosis The importance of the health status of the respiratory tract and lung is obvious Any abnormality in that status, either functional or pathologic, imposes an additional insult which may severely modify the generally accepted pattern of uncomplicated pneumoconiosis In this regard one need but recall the effects of increasing age, the adverse influence of chronic bronchitis and bronchiolitis, bronchiectasis, emphysema, pulmonary residuals of past infections, malignancies, and active infections such as tuberculosis Certainly, such abnormalities must be considered in evaluating the pathogenesis of pneumoconiosis and they should be viewed with extreme caution before attempting a cause and effect relationship

The duration of exposure bears, in general, a reciprocal relationship to the atmospheric concentration of the particulate aerosol Within certain limits a short exposure to excessive amounts of an aerosol in effective ranges of particle size will produce the same degree of pulmonary reaction as a longer exposure to more moderate concentrations An accurate occupational history is essential for an estimation of this time factor It may be difficult to obtain, particularly when information relative to a man's occupation in any given industry is so varied that a constant exposure to one type of aerosol seldom occurs A rock driller, for example, gives a history of employment in many different mines or quarries, each of which may involve work in rock of different composition Even in one mine the occupation of the miner covers many different jobs with exposure to dust from relatively pure ore to those with a high silica content Some men work exclusively underground, others in surface mills and still others are transferred from one job to another The aim of the history is to determine as exactly as possible the number of years, months weeks and days that a workman has spent at various jobs, and to correlate this information with the nature of atmospheric contaminant encountered in each of them The satisfactory history accounts for every day of his employment and particularly of his exposure to an aerosol

With respect to the factor of individual variation, it is obvious that not all individuals exposed to a particulate aerosol under presumably the same environmental conditions react alike Some are susceptible and respond early, others are partly or almost completely resistant This condition occurs both with the experimental animal and with man Various explanations have been offered to account for these differences, but none is entirely satisfactory. Inefficient nasal filtration physiologic peculiarities of the lungs, chronic infection of the respiratory tract, effectiveness of the lymphatic drainage system, quantity of dust deposited in the lungs, particle size, metabolic and g factors, and physiochemical differences been suggested as possible determinants influencing the degree of pulmonary reactio the individual man exposed to a dusty envi ment The physiologic response to clima factors such as humidity temperature a barometric pressure have also been considere The relative importance of each of these el ments in the pathogenesis of pneumoconiosi in some individuals and not in others remains to be determined

With due recognition of these factors it is apparent that, within limits, the types of uncomplicated pneumoconiosis fall into one of two categories namely, inert or harmless pneumoconiosis and active or harmful pneumoconiosis

Typical examples of the inert type are those pneumoconioses produced by particles of carbon, iron oxide, cement, gypsum and a host of other agents in pure or mixed state which initiate a reaction no more severe than that caused by any substance foreign to the pulmonary tissue The pulmonary deposition and the mild tissue reaction in those instances may be regarded often as the fortuitous happenings of everyday life and do not necessarily arise in consequence of a specific occupational exposure

The manner of primary distribution of an inhaled particulate aerosol in different parts of the normal lung is not entirely clear Whether that distribution is predominantly subpleural or is confined mainly to the deeper portions of the lung, involving some segments more than others, apparently depends upon a number of physiologic variables including vital capacity, tidal and residual air, and movement of the

lung diaphragm and chest cage In any event the inhaled particles that reach the terminal alveoli are taken up by large phagocytes, commonly called dust cells The function of these actively motile cells is to prevent accumulation of foreign particles in the alveolar spaces Many migrate into the bronchi and are expectorated Others find their way into the lymphatic system of the lung and are carried by it to the intrapulmonary lymphoid aggregates and the tracheobronchial lymph nodes Other phagocytes laden with particles find their way into the interstitial tissue comprising the alveolar walls There is debate concerning this phagocytic mode of deposition and transport It appears that some particles gain access to the alveolar tissue without the mediation of phagocytic activity That theory if correct, would explain in part diffuse interstitial pneumonitis provoked experimentally by certain substances such as some amorphous free silica aerosols with an ultimate particle size in the submicroscopic range

Particulate aerosols that reach the lymphatics are carried along the perivascular and peribronchial trunks to the intrapulmonic lymphoid masses that lie at the dividing points of the bronchi and vessels Many particles pass through these filter masses and eventually reach the nodes at the hilum of the lung In cases of prolonged inhalation of heavy concentrations of an inert dust these filtering masses may become more or less clogged so that the particles begin to accumulate in the lymphatic channels Massive exposure of this sort is usually accompanied by enlargement of the tracheobronchial lymph nodes As with any particulate substance a slight proliferation of connective tissue takes place both within these nodes and about the afferent lymphatic trunks in the lung These changes can often be visualized in roentgenograms of the chest as a widening of the root shadows and an exaggeration of the normal linear markings Such alterations appear only after many years of exposure to high concentrations of inert particulate aerosols Identical roentgenologic changes may also be seen in long standing cardiovascular disease and in certain infections they are also often incidental to old age Therefore, by themselves they may not be sufficiently characteristic to substantiate a [illegible]sis of pneumoconiosis

In regard to the active pne[illegible] it is clinically impossible to assess the capacity of a particulate aerosol to produce pulmonary damage by the examination of a single case In surveying large groups of men in the same industry who are apparently exposed to the same amounts of active particulates not all will be discovered to have developed such damage As cited previously, whether this is due to variations in individual susceptibility to varying effectiveness of the upper respiratory defense mechanisms to associated infections or to differences in exposure which are not detected by existing methods of history taking is still a matter of debate

Illustrative of the active or harmful pneumoconioses are those conditions such as silicosis and asbestosis Each is well established as a specific entity and therefore deserves special attention It is not intended to refer here to these two particular types in any great detail but a few aspects will be emphasized to illustrate certain focal points which may assist in the study of other pneumoconioses of the active type

It was formerly believed that only the crystalline forms of free silicon dioxide caused damage to the pulmonary tissue In recent years some of the amorphous forms and some of the silicates have come to be regarded with suspicion One at least—asbestos a hydrated magnesium silicate—has proved to be definitely irritating The pulmonary pathology of asbestosis and its appearance on roentgen films is distinct and can be differentiated from that of other pneumoconioses It causes a diffuse obliterating fibrosis which starts as collar like sheaths about the terminal bronchioles With increasing exposure and as the disease advances the fibrosis extends peripherally into the parenchyma of the lung often producing associated chronic fibrous pleuritis The tissue response is never nodular as in silicosis The fibrosis imparts to the chest roentgenogram a faint diffuse haziness throughout the lower lung fields which in the advanced cases has an appearance comparable to that of ground glass Occasionally, there are scattered granular and mottled shadows but they do not present the sl[illegible]ition of silicotic nodulation

[illegible] of pure crystalline sil[illegible] when in
[illegible] lung are first acted upon in the
s[illegible] is the case with an inert part cu
[illegible] Ti[illegible] are phagocytosed
by [illegible] that eventually find

their way into the alveolar tissue and the lymphatic system of the lung At this point, however, the tissue response becomes totally different Whereas inert particulates initiate little or no reaction within the lung, silica dust stimulates the tissue cells and produces an inflammation followed by proliferation of connective tissue Since the dust particles are transported into the lymphatics early, the first detectable evidence of this reaction appears in the lymphoid tissue about the vascular tree and in the lymph nodes at the root of the lung As these changes proceed, the efficiency of the pulmonary lymphatics as a draining and filtering system becomes impaired and inhaled silica particles can no longer be eliminated effectively from the alveolar spaces The dust-laden phagocytes tend to accumulate in all parts of the lung, first in and about small peripheral masses of lymphoid tissue and later in the alveolar septa themselves The silica particles thus become concentrated at focal points, a chronic inflammation occurs connective tissue forms and a characteristic silicotic nodule of hyaline fibrotic tissue results With continued inhalation of silica the number and size of these nodules increases In the course of time, barring infection the lung becomes studded with uniformly scattered, firm circumscribed nodules of fibrous tissue

The pathologic condition in the lung can now be recognized as silicosis on the roentgenogram which is the most reliable basis for a clinical diagnosis This is the stage of "nodulation" with discrete shadows, rather uniform in size, density and distribution, scattered throughout all portions of the lung fields In late stages the development of emphysema at the bases often disturbs the uniformity of the distribution

Not all silicotic conditions of the lung are manifested by simple nodule formation In many instances massive areas of fibrosis are present in one or more parts of the lung They are frequently bilateral and may be symmetric or asymmetric in distribution

The reason for the development of such areas is often difficult to determine and is still a subject of debate Some observers are of the opinion that these massive lesions result from conglomeration of previously existing discrete nodules of simple silicosis It cannot be denied that with continued inhalation of silica some nodules do increase in size and fuse locally to form small conglomerate foci Lesions of this type, however, are scattered throughout the lung and seldom become large enough to be confused with the massive areas of fibrosis If lesions of the latter type are the result of fusion of discrete nodules, they should have numerous points of origin scattered throughout the lung and eventually result in uniform and complete fibrosis of the entire organ It may be argued that a small portion of the lung received more dust than another and consequently a massive lesion developed To justify this view it must be demonstrated that more inhaled silica particles are deposited in certain areas of the normal lung than in others Observations on the lungs of experimental animals and those of early cases of uncomplicated human silicosis which come to autopsy have failed to substantiate this view They have likewise failed to confirm the opinion that localized atelectasis of the pulmonary tissue is the factor responsible for the diffuse fibrosis

A third possibility is the effect of other minerals associated with silica It is known that such dusts tend to accumulate at the periphery of silicotic nodules where they produce the formation of more or less cellular connective tissue Fusion of such reactions about contiguous nodules might conceivably be responsible for conglomerate foci But if this is true, such a process should result in diffuse generalized fibrosis

The most likely explanation for massive lesions of fibrosis is that they occur in regions of the lung which have been injured by infection Such injury leaves residual granulation or scar tissue and impairs the lymphatic drainage so that inhaled silica particles can no longer be eliminated effectively from those regions Accumulation of carbonaceous pigment or other particulates in pulmonary scars is well illustrated in specimens with apical foci of healed tuberculosis A common finding about almost any fibrotic or calcified tubercle is a peripheral zone of dust pigment often so concentrated as to obscure the microscopic characteristics of the lesion A similar change is also observed about many other scars of unknown etiology These observations lead one to believe that particles of inhaled dust accumulate in certain areas of the lung, not because more arrive at the focus but because fewer are eliminated by way of the lymphatic system The result is a localized accumulation of dust When the dust

is silicious, the excessive local concentration exerts its maximum effect, an unusual number of nodules develop and diffuse fibrosis results from the action of the silica on any pre-existing scar tissue

The majority of the massive fibrotic lesions of advanced silicosis are associated with foci of infection within the lung In most instances the etiologic agent is the tubercle bacillus When such lesions first develop the infection is most often latent, scar tissue continues to form at its periphery and the area increases in extent Ultimately the silica reactivates the encapsulated focus harboring the bacilli and the infection spreads very slowly Foci of this kind which are due to the combined action of tubercle bacilli and silica are generally designated as tuberculosilicosis

In many cases it is difficult to obtain clinical evidence of a bacillary infection within such lesions The usual picture of uncomplicated phthisis is frequently absent and the sputum often remains negative for acid fast bacilli even after examination of numerous specimens Repeated guinea pig inoculations are often necessary to demonstrate a positive sputum

Generally, however if the larger number of these massive lesions are followed long enough they will eventually reveal definite evidence of tuberculosis Although delayed the clinical symptoms and signs of infection will make their appearance and serial chest roentgenograms will show extension of the shadows which may ultimately go on to cavity formation

The presence of active infection within these lesions has been verified by autopsy Anatomically such lesions appear as irregular masses of firm grey or black fibrous tissue with linear extensions into the surrounding lung Often they extend to the pleura and are accompanied by dense pleuritic adhesions The tuberculous complication within the mass is identified by scattered islands and bands of granulation tissue, foci of caseation in various stages of organization or by cavity formation

tuberculosilicosis than in simple phthisis Apparently the massive fibrous tissue traps the tubercle bacilli and prevents their spread to distant foci

Not all manifestations of tuberculosis in the silicotic subject are of the massive fibrous type There are cases in which the infection localizes in and about pre existing silicotic nodules The center of the nodule becomes caseous and a zone of tuberculous inflammation is seen about its periphery This change results in an increase in size of the nodule and a loss of its sharp definition Roentgenologically the discrete nodular shadows seen in uninfected silicosis now have fuzzy indistinct borders This form is referred to as the ' perinodular type Clinically it is manifested by early symptoms of intoxication the presence of bacilli in the sputum and early termination

Although tuberculosis is the most frequent complication of silicosis other forms of pulmonary disease may also be involved Non specific chronic bronchitis and bronchopneumonia are perhaps more common than in the non silicotic individuals In certain industrial groups notably foundry employees the increased incidence of pneumonia has been attributed to the extreme changes in temperature and humidity rather than to the inhaled dust Experimental evidence fails to show that inhaled particulate silica has any influence upon a pneumococcal infection Bronchial spirochetosis occasionally complicates silicosis However, that infection responds favorably to treatment and appears to be incidental to the deposition of particulate silica in the lung Pulmonary carcinoma has been attributed to the irritating properties of inhaled silica but there is no real evidence that such malignancy is more frequent in silicotics than among subjects of the general population To date, therefore it has not been satisfactorily demonstrated that these particular complications bear an etiologic relationship to inhaled particulate silica

In addition to silicosis and asbestosis other special forms of active pneumoconioses could be cited These would include pneumoconiosis in coal miners diatomaceous earth workers certain foundry employees operators of induction furnaces and in subjects exposed to particulate aerosols of cobalt, cadmium manganese dioxide, chromates bauxite and beryllium oxide The pulmonary changes attending some of these various pneumoconioses are fairly well identified Their relation to the etiology and pathogenesis of pulmonary disease has received considerable attention For many of them, however, the body of evidence in regard to their action is not as great as with silicosis and asbestosis

MANAGEMENT OF PNEUMOCONIOSIS

Prevention remains the only reliable means for combating pneumoconiosis Thus far, specific therapeutic measures have not been discovered which have an appreciable effect upon an established pulmonary process resulting from the deposition of particulate aerosols in the lung

The field of prevention involves the collaborative effort of many persons not only the exposed subject but also individuals with special abilities who represent a number of professions These include physics chemistry engineering the social sciences hygiene and medicine The major burden of responsibility in this regard rests upon the industrial hygienists and the physician

The industrial hygienist is in a most favorable position to identify and to define a potential or actual health hazard possibly due to a particulate aerosol He better than anyone else is well acquainted with various instruments and technics for the collection and study of those aerosols Furthermore the industrial hygienist can ascertain the particular operation responsible for generation of the aerosol and thus can introduce precise measures for its control or elimination He knows the work habits of the men and can determine the frequency and duration of their exposure

The physician's part in prevention is equally important His study of the lungs of individuals gives evidence of a respiratory hazard possibly due to the inhalation of a particulate aerosol Accordingly he can detect those individuals already afflicted and can introduce therapeutic measures for their improvement He can appraise the nature and extent of their pulmonary impairment and thus give guidance for compatible activity and work But more important the physician can assist in the selection of individuals free from pulmonary disease who otherwise may be incapable of withstanding exposure to an atmospheric pollutant

The diagnosis and management of pneumoconiosis are contingent upon the following (1) evidence of disease in the lungs demonstrated in the roentgenograms (2) physical examination and other medical study to determine the nature and extent of pulmonary involvement and associated disability and (3) a history of exposure to a particulate aerosol adequate to produce pulmonary disease and to impair health

REFERENCES

Biological Aspects of Air Pollution an annotated bibliography Federal Security Agency Public Health Service Washington D C 1950

DRINKER, P and HATCH T Industrial Dust, 2nd ed New York 1954 McGraw Hill Book Company Inc

FAIRHILL, L T Industrial Toxicology Baltimore 1949 Williams & Wilkins Company

GARDNER, L U Reaction of the living body to different types of mineral dusts with and without complicating infection American Institute of Mining and Metallurgical Engineers Inc Mining Technology, No 929 1938

GARDNER, L U Pneumokoniosis *International Clinics*, vol 2 series 45 Philadelphia 1939 J B Lippincott Company

GARDNER, L U Etiology of pneumoconiosis *J A M A* 111 1925–1936 1938

GARDNER L U The pathology and roentgenographic manifestations of pneumoconiosis *J A M A* 114 535 545 1940

LANZA A J Silicosis and Asbestosis New York 1938 Oxford University Press

PATTY F A Industrial Hygiene and Toxicology New York 1949 Interscience Publishers Inc

Proceedings of the Ninth International Congress on Industrial Medicine London Bristol 1949 John Wright & Sons Ltd

Report to the Secretary of State for the Home Department on the Health of Cornish Miners Cd 2091 H M Stationery Office London 1904

Silicosis and Allied Disorders History and Industrial Importance Air Hygiene Foundation of America, Medical Series, Bulletin No 1 Pittsburgh 1937

Symposia on Silicosis, 1934 1935 1937 1939 1941 Saranac Lake N Y

Third International Conference of Experts on Pneumoconiosis Sydney International Labour Office, Geneva 1950

Threshold Limit Values for 1954 Am Conf of Govt Indust Hygienists, vol 9 pp 530–534 1954

VORWALD A J Pneumoconiosis, Beryllium Bauxite Fumes Compensation New York 1950 Paul B Hoeber Inc

VORWALD A J and LANDAU A Influence of dusts on tuberculous infection *Arch Path* 24 8–18 1937

VORWALD, A J and DELAHANT A B The influence of silica on the natural and acquired resistance to the tubercle bacillus *Am Rev Tuberc* 38 347–62 1938

VORWALD A J and KARR, J W Pneumoconiosis and pulmonary carcinoma *Am J Path* 14 49–57 1938

VORWALD A J DELAHANT A B and DUBORSKI M Silicosis and type III pneumococcus pneumonia an experimental study *J Indust Hyg & Toxicol* 22 64–74, 1940

VORWALD A J Pathologic aspects of acute pneumonitis and pulmonary granulomatosis in beryllium workers *Occup Med* 5 684–689 1948

VORWALD A J DURKAN T M PRATT P C and DELAHANT A B Diatomaceous Earth Pneumoconiosis Proceedings of the Ninth International

Congress on Industrial Medicine, London pp 725–741 Bristol, 1949 John Wright & Sons, Ltd

VORWALD A J Problems in Pneumoconiology Third International Conference of Experts on Pneumoconiosis, Sydney International Labour Office Geneva 1950

VORWALD, A J, PRATT, P C, DURKAN, T M, DELAHANT, A B and BAILEY, D A Siderosis a benign pneumoconiosis due to the inhalation of iron dust *Indust Med*, 19 151–180, 1950

VORWALD, A J *Variations in individual susceptibility* to industrial dusts inhaled into the lungs *Am Rev Tuberc*, 62 13–21, 1950

[illegible]

Technical Conference on Air Pollution p 48, New York, 1952 McGraw Hill Book Company, Inc

Silicosis and Asbestosis

O A Sander, M D, Milwaukee, Wisconsin

Although dust disease of the lungs can be traced far back in history, it did not become a serious problem until the introduction of mechanical processes in mining and manufacturing which greatly increased the amount of dust generated Engineering methods of protecting those exposed did not keep pace with the increasing speed of production Little thought was given to the early disabilities and deaths which were variously termed "consumption" "phthisis" and so on, and which in reality were cases of silicotuberculosis or advanced asbestosis The diseases were thought to be inherent in the industries and a part of the risk assumed by a worker when he entered such fields Not until the whole problem suddenly burst upon the public consciousness, through civil suits and newspaper publicity, did many industrialists realize that something had to be done

Similarly, medical science was unprepared for this epidemic of occupational diseases and its resulting hysteria We know how meager the teaching of occupational diseases of all kinds had been in our medical schools until recent years except for lead poisoning which came to light much earlier in the industrial era, probably due to the much shorter period of exposure required for the disease to develop and the dramatic onset of its symptoms Silicosis and asbestosis, on the other hand, are slow in their development, requiring years of exposure to atmospheres sufficiently high in silica and asbestos dust to produce even a recognizable change on the chest roentgenogram Further more, the onset of symptoms is far from dramatic, except for the few cases of silicotuberculosis which come to light with the first hemoptysis However, the greatest factor in delaying our recognition of the condition was the lack of good diagnostic chest roentgenography until about twenty five years ago The chest films used in 1915 in the first silicosis survey in the United States made in the Missouri lead mines showed only the grosser lung lesions and none of the finer details which we consider so essential for accurate diagnosis today

SILICOSIS

Silicosis remains the principal occupational disease of the lungs from the standpoint of numbers of workers involved because of the many industries which have had exposure to dust containing free silica, SiO_2 The major ones have been foundries, granite operations, sandblasting, mines containing quartz rock and sandstone wheel grinding Some of these no longer are causing silicosis because of the remarkably improved dust control in the past twenty years and the replacement of sandstone with the artificial abrasives The diagnosis of silicosis must be based on three fundamental criteria first, the characteristic nodular x-ray pattern, second, medical history and history of adequate exposure to dust containing crystalline-free silica, third, physical examination, laboratory and physiologic studies to determine if the silicosis has caused functional disturbance of the lungs

Diagnosis The nodular x-ray pattern due to individual fibrous nodules differs with the various silica exposure industries, depending upon the type and degree of the other components of the dust which tend to modify the silica reaction The root shadows, however, usually are enlarged and increased in density because of enlarged and fibrotic root lymph nodes This finding differentiates silicosis from siderosis or iron pigmentation which also causes a nodular x-ray pattern, but with which the root lymph nodes are not enlarged or increased in density Also, the generalized nodulation with siderosis usually is more discrete and never becomes confluent as silicotic nodulation occasionally does When silicotic nodules become conglomerate, other nodular shadows in the lungs may become less and less apparent as compensatory emphysema develops

Just as silicosis cannot be diagnosed during

life unless the roentgenogram shows evidence of nodulation, of equal importance is the history of sufficient exposure to dust which is capable of producing silicosis This is essential because there are some twenty different conditions and diseases which may look exactly like silicosis on a chest roentgenogram Some of these are siderosis and hemosiderosis, some fungous infections, non-specific pneumonitis, miliary tuberculosis, berylliosis, some forms of asbestosis, miliary metastatic carcinoma, mitral stenosis, sarcoidosis and polycythemia vera *Because of the great similarity of the* x-ray pattern of these conditions and silicosis, it is obvious that the latter cannot be diagnosed by x-ray alone

A detailed occupational history is an absolute essential with all nodular x-ray patterns This should start with the worker's first gainful employment Any jobs which involved dust exposure require detailed questioning regarding the type and degree of the dust It is not enough to say that a man has been a foundry worker or miner One must query What kind of foundry or mine? What job or jobs did he do? If a grinder, what was being ground and what was the composition of the abrasive wheels? If the wheels were made of an artificial abrasive rather than sandstone, silicosis cannot develop unless the castings being ground had sand scale on their surfaces With mining, silicosis cannot develop unless there had been drilling and blasting in rock containing more than 10 per cent crystalline-free silica These and many other details must be inquired into before any conclusions should be drawn No matter how suspicious the x-ray appearance, unless there was exposure to quartz or other crystalline-free silica dust in particle size ranges of 5 microns or less, in concentrations of more than five million particles for cubic foot and for time intervals of more than ten years, a diagnosis of silicosis is unwarranted The dust concentrations needed to produce silicosis vary inversely with the free silica content Most states now have codes defining the relative dust concentrations which may be considered safe

The medical history also is important for the diagnosis of silicosis The first and sometimes only symptom of disabling silicosis is a slowly increasing shortness of breath on exertion A dry or productive cough may or may not be present When this is marked and accompanied by a recognizable wheeze in the chest, bronchial irritation and obstruction usually are the cause, which may or may not be related to the silicosis or dust exposure Early discrete nodular silicosis usually causes *no symptoms referable to the chest When such* symptoms are marked in the presence of minimal nodular silicosis, other causes should be looked for Silicosis also does not cause loss of weight unless accompanied by active and open tuberculosis There may or may not be any chest pain with advanced cases and there is usually none with early cases When chest pain is present, it ordinarily is due to excessive coughing rather than to the silicosis *per se* Weakness, hemoptysis, digestive disturbances, night sweats, insomnia, dizziness and edema of the extremities are not characteristic of uncomplicated silicosis

A complete physical examination and laboratory and lung function studies are also needed before an opinion on the presence or absence of disabling silicosis can be given Objective signs on physical examination are few Changes in the appearance usually are not indicative of silicosis *per se* Decreased chest expansion usually is found only in advanced and complicated cases Physical examination of the chest is made primarily to determine if there is airway obstruction, [illegible]

fingers also should be looked for and may be [illegible]

if the roentgenogram suggests the possibility of complications. The blood sedimentation test is useful with periodic examinations to determine if active tuberculosis is developing [illegible] Simple nodular silicosis does [illegible] in- [illegible] ter- mining the extent of ventilatory impairment

in silicosis if any In general it may be stated that simple nodular silicosis usually reveals no measurable impairment of lung function unless accompanied by obstructive and unrelated emphysema Emphysema of a significant degree usually does not result from silicosis unless the latter is advanced Other causes for emphysema should be sought when it is found in a worker who has no more than minimal to moderately advanced simple nodular silicosis

The most reliable lung function tests of the simpler variety are the timed vital capacity and maximal breathing capacity determinations Both have been found to correlate well with residual air determinations, which usually do not need to be made Both of these tests however, require a maximal effort on the part of the person being tested which is difficult to obtain in many controverted patients *However*, when the tester breathes with the patient and continues to encourage him to give a maximal effort, reliable figures are obtainable Blood arterial oxygen saturation determinations are advisable both before and after exercise when the maximal expiration is consistently longer than 3 seconds and the maximal breathing capacity is materially below 100 L per minute Besides these lung function tests it often is valuable to determine the maximal excursion of the diaphragm, preferably recorded on a double exposure film Advanced silicosis and obstructive emphysema usually result in a significant decrease of the maximal diaphragmatic excursion, but simple nodular silicosis does not

Prevention Prevention is the most important feature of this disease and two aspects are recognized First silicosis can be prevented by proper dust control which includes exhaust ventilation, substitution of wet methods for dry, replacement of silica materials with non silica and the use of protective equipment These preventive measures are effective as proved by the complete absence of new roentgenographic evidence of silicosis in an increasing number of silica exposure industries in the past twenty years

The second aspect of prophylaxis is the prevention of disability in those who already have some silicosis This necessitates accurate differential diagnosis because of the benign pneumoconioses (particularly siderosis), which may simulate silicosis by x ray but which never became disabling The first advice which many physicians give their patients who are found to have nodular roentgen changes is that they leave their jobs Experience shows however, that even those with early silicosis should be kept at the work they were trained to do and every effort made to reduce the silica dust dissemination on their jobs to a minimum The only exceptions should be those patients with progressive tuberculosis or silicotuberculosis who either must be isolated if infectious or placed at light non dusty work if not

Fear caused by well meant but usually overexaggerated advice regarding the extent of the silicosis has caused more disablement in some trades than have the lung changes themselves Such iatrogenic or doctor-induced disability is as real to the patient as are the [illegible] 'Work that anges progressing to a dangerous stage with the improved dust control With few other diseases is the psychologic approach more important

Therapy Only advanced cases or those complicated by tuberculosis or emphysema require treatment In the author's experience less than 10 per cent ever become sufficiently disabling to require therapy and such cases are becoming fewer each year as preventive methods of the past two decades are showing their effectiveness

Advanced cases of silicosis which usually have considerable emphysema if disability is a factor, can be materially improved symptomatically by methods which promote drainage of retained bronchial secretions Bronchodilator drugs, such as neo-synephrine® (1 5 cc of 0 5 per cent) or isuprel® (6 to 8 drops of 1 200 solution), when placed in a nebulizer with 100 per cent oxygen and inhaled with the intermittent positive pressure technic proposed by Motley, have given very effective results The resulting improved ventilation, although temporary, has caused such a frank improvement in the morale and feeling of well being of many coal miners that this form of therapy is recommended for disabling silicosis and emphysema from any cause Courses of treatment may have to be repeated at rather frequent intervals, depending on the severity of the case

Other measures which must be a part of the therapeutic regimen are prevention and active treatment of colds and other respiratory infec-

tions, prevention as far as is possible of contacts with active cases of tuberculosis, and discouragement of smoking to reduce bronchial irritation and secretion to a minimum Any measures which will prevent bronchial obstruction are indicated The cough reflex, therefore, should not be subdued and codeine should be withheld unless the cough is severe Maintenance of the general nutrition of the patient also must be part of the treatment program Continuing graded exercise is especially necessary to prevent further atelectatic areas of the lungs from developing Support of the lower abdomen with its resulting support of the diaphragm will improve ventilation in many patients with advanced non obstructive emphysema, but is contraindicated when there is considerable bronchial obstruction Aluminum dust inhalation has been disappointing as a form of therapy except for some psychologic improvement in occasional cases

The relationship of silicosis and tuberculosis has been recognized for many years Most clinical and laboratory studies have shown a higher incidence of pulmonary tuberculosis in persons with silicosis than in the general population Tuberculosis, however, is the only lung infection which appears to be more prevalent with silicosis Such combined lesions of silicotuberculosis usually are more chronic than is tuberculosis alone and they tend to progress with an increasing overgrowth of fibrosis Tubercle bacilli commonly are not liberated in the bronchial tree for many years and occasionally never Sanatorium care is not only unnecessary but also inadvisable until the sputum or gastric contents show tubercle bacilli Streptomycin, PAS and INH® are no more effective in chronic closed silicotuberculosis than they are in chronic fibroid tuberculosis, but when the infection is open the patient should be treated precisely the same as a patient with active tuberculosis Surpris-

[illegible]

the extent that today new cases of silicotuberculosis are no longer seen except in the older workers who had exposure to the heavier dust concentrations in the past The increasing discovery and isolation of persons with active tuberculosis in the community as well as in industry also is helping to prevent new cases of silicotuberculosis, to such an extent that it soon will cease to exist as an occupational disease The pessimism of the past regarding the prognosis of silicosis should be replaced by a more optimistic outlook in the vast majority of cases, and those affected should share in that optimism

ASBESTOSIS

Asbestosis is a specific fibrosis of the lungs due to the inhalation of asbestos fibers, which chemically are a hydrated magnesium silicate They do not contain any free crystalline silica They appear to cause a mechanical plugging of the respiratory bronchioles and the longer fibers are more pathogenic than shorter ones Fibers less than 10 microns in length have been shown not to cause the disease in laboratory animals The characteristic asbestos bodies seen under the microscope in asbestosis lung sections are asbestos fibers with deposits of blood cells and blood protein on their surfaces The lung fibrosis resulting from these fiber inhalations appears to start as collars of fibrosis around the plugged bronchioles Whorled fibrous nodules which are the unit lesions in silicosis are rare, but occasionally are seen in areas of advanced fibrosis

Diagnosis As with silicosis the diagnosis must be based not only on the x ray pattern but also on adequate history of exposure plus physical and laboratory findings. The x ray pattern with this disease is somewhat unusual and not as clearly defined as with nodular silicosis, an indefinite haze over the lower lobes appears early, which progresses by slow increase in density and a gradual disappearance of the vascular shadows Some patients seem to progress through a soft and rather discrete nodular pattern Pleural adhesions which tend to increase are seen frequently, giving the common "shaggy heart" appearance The typical haze has been referred to as a "ground-glass appearance" Advanced cases commonly show marked emphysema and blebs

Because of the indefinite character of the x-ray pattern, the film technic must be of top quality with this disease Too often underexposed films and those with blurred vascular details due to too long exposure time are misread as showing asbestosis The films of markedly overweight persons also are often mis-

diagnosed for the same reason In addition, conditions which may simulate asbestosis by well taken x ray films are chronic passive congestion, bronchiectasis polycythemia and infiltrating malignant metastases from the mediastinum

Without a history of adequate exposure to asbestos fibers a diagnosis of asbestosis cannot be justified Prolonged exposures for more than fifteen years usually are necessary before x ray evidence of the disease becomes apparent, except where concentrations of the dust are extremely high If the laboratory evidence of the long fibers being the primary cause of asbestosis is valid, the permissible dust counts which have been established for the prevention of asbestosis are entirely incorrect All are based on the number of fibers per cubic foot which are less than 10 microns in length, which it now appears are innocuous More detailed laboratory studies to establish permissible concentrations of harmful amounts of asbestos fibers seem to be indicated Until these are available only rough estimates of safe limits of dustiness with asbestos fibers must suffice

The medical history of asbestosis is quite similar to that of disabling silicosis, in that shortness of breath on exertion is the most striking symptom There is a general belief, however, that minimal changes by x ray are more disabling with asbestosis than with silicosis Whether or not this is true remains to be demonstrated Cough and expectoration are not characteristic symptoms and when present are most likely due to other causes The same is true for pain in the chest

Prevention As with silicosis, prevention involves not only a reduction of asbestos dust exposure in the working environment but also reassurance of those patients who have minimal x-ray changes that these findings are of no significance, provided their future exposure to asbestos dust is minimal Unlike silicosis, asbestosis does not seem to progress after the dust exposure stops or is materially reduced In the author's experience numerous cases of asbestosis diagnosed as first and second stage in 1943 had not progressed visibly by 1953 in spite of these workers continuing their regular jobs in an asbestos textile plant under markedly improved conditions of dust control

Treatment The symptomatic relief of disabled patients most likely cannot be effected with the same therapy suggested for disabling silicosis Bronchospasm and retained bronchial secretions seems to be much less apparent factors in disabling asbestosis than in disabling silicosis This looks like a paradox since the basic pathologic change appears to be bronchiolar obstruction, but this obstruction looks more irreversible Effective therapy for disabling asbestosis has not been demonstrated

As for complications, unlike silicosis, American experience has not shown any increased incidence of tuberculosis with asbestosis Also, recognized American cases of asbestosis have not shown any more lung cancer than that in the general population, although British experience suggests that there may be a causal relationship

CONCLUSIONS

In conclusion, silicosis and asbestosis are preventable diseases Experience in the past ten years has shown not only a decreasing incidence of new cases as recognized by x ray, but also fewer and fewer affected workers are becoming disabled This is due not only to lower and lower dust exposures in most industries but also to lessened opportunities for tuberculosis contacts in our communities and industries, and to an even greater extent to an increasing optimism on the part of the medical profession on the prognosis of these dust diseases The pessimism of the past is being replaced by the

47

Beryllium Poisoning (Berylliosis)

H E Tebrock, M D, *New York, New York*

The term "beryllium poisoning" is all-inclusive and may be liberally interpreted as any pathologic condition resulting from exposure to beryllium By way of definition, berylliosis (beryllium poisoning) is a general disease characterized clinically by pulmonary insufficiency and having the major pathologic changes in the lung It results from the inhalation of finely divided beryllium compounds The characteristic lesion is a granuloma The clinical course of berylliosis ranges from acute to chronic, and for the purposes of this discussion we will limit ourselves to the chronic type of the disease which is the more prevalent and the more difficult to manage.

Possibly as many as 500 cases of chronic berylliosis have occurred in the United States since the first reports of the disease in 1946 Of this group over 100 have been exposed to beryllium in fluorescent lamp phosphors alone, the remainder to a variety of products containing beryllium Epidemiologic studies indicate that there was a potential exposure to beryllium oxide proved in all these cases which was not true for the other compounds of beryllium It followed, therefore, that beryllium oxide (actually the presence of free beryllium oxide) was the common denominator in causing chronic berylliosis.

The pathologic anatomy in chronic berylliosis is characterized by diffuse granulomatosis very much like sarcoidosis The lungs are voluminous and emphysematous with scattered fine nodules, and diffuse fibrosis, which is interstitial and nodular and is associated with the granulomatous reaction Giant cells are prominent in the picture and are of the Langhans type

The symptoms at the time of onset of the chronic disease may be variable Following termination of exposure, the onset is often delayed from months to a period as long as eleven years before the appearance of symptoms However, it is not uncommon to find roentgenologic changes preceding clinical symptoms by as much as two years The first clinical symptoms may be mild with vague indisposition, slight but persistent weight loss, weakness, easy fatigability and occasional cough (usually non-productive and occurring most frequently in the mornings) Exertional dyspnea may often be the presenting symptom Cyanosis and clubbing of the fingers is a frequent observation in advanced chronic cases Sooner or later symptoms of cardiac decompensation add to the distress of the patient, ending up with chronic cor pulmonale Rapid and shallow breathing is characteristic, and in chronic berylliosis the alterations are similar to the disturbances seen in silicosis or cardiac disease Interstitial changes in the lung disturb the Hering Breuer reflex, and the variable shunts will also have varying effects upon the patient's vital capacity Significant reduction in vital capacity may be expected from engorgement of the pulmonary vessels alone With pulmonary hypertension and right heart strain, there is often engorgement of the liver which may lead to abdominal pain, nausea and vomiting giving the impression of general intoxication The essentials for diagnosis of berylliosis are (1) Occupational history of significant exposure to beryllium compounds, (2) a characteristic type of onset and clinical disease, (3) radiologic findings consistent with berylliosis, (4) clinical laboratory findings consistent with the disease, and (5) chemical findings of beryllium in tissues or urine Because of the similarity of the granuloma of beryllium with that of sarcoidosis, diagnosis by biopsy is not always completely definitive

X RAY MANIFESTATIONS

Although the radiologic changes have certain definite characteristics, the x ray alone will not and should not serve as the single factor to determine the diagnosis All of the patterns including the fine discrete granularity and nodularity from 2 to 5 mm and the enlarge-

ment of the tracheal bronchial nodes can be simulated by other diseases However clear cut roentgenographic signs in the early stage of the chronic disease are characterized by diffuse finely granular haziness with some degree of obscuration of the parenchymal markings With advance in time the finely granular shadows later take on a fine nodular aspect simulating miliary tuberculosis and between these shadows lobular emphysema is evident Later on there is a tendency toward a confluence of the smaller nodules with larger nodules appearing These do not reach the size seen characteristically in late silicosis but they may

teristic diffuse nodular roentgen picture the lesion must be distinguished from miliary tuberculosis from radiopaque deposits such as siderosis and stannosis and from the finely granular appearance occasionally seen in the rheumatic diseases

For purposes of convenience many clinicians divided the chronic beryllosis x ray pattern into three stages (1) *The stage of granularity* which is a finely granular diffuse haziness with some sparing of the apices and extreme bases where there is often compensatory emphysema (2) *The stage of reticulation* when a reticulant type pattern is superimposed on the Stage 1 granular background Often there is slight fuzziness and enlargement of the hilar areas (3) *The stage of nodulation* when there is distinct nodulation up to 5 mm in size which does not coalesce cavitate or calcify and gives the appearance of a large flake snow storm Cor pulmonale with right sided cardiac enlargement is common at this stage

TREATMENT

[illegible]

treatment was completely symptomatic and supportive Pulmonary insufficiency requires frequent or consistent use of oxygen even at rest In mild cases general supportive treatment with exercise to the limit of comfort is indicated in the more severe cases bedrest and continued oxygen therapy are necessary Penicillin streptomycin aerosol therapy is of value in dealing with intercurrent infections but does not appear to alter the course of the underlying disease Specific treatment designed to aid in the elimination of beryllium such as BAL

[illegible]

gen is required There is increased vital capacity return of energy noted improved appetite weight increase reduction in dyspnea and cough heightened morale and some degree of

[illegible]

several years it is quite apparent that corticosteroid therapy will not effect a cure in chronic berylliosis but very definitely will make the patient more comfortable and possibly retard and prevent progression of the disease to a more fibrotic state The evident symptomatic improvement the x ray changes and the sense of well being induced by corticosteroid therapy have warranted its continued use and thus far has provided the one single modality which has been of some benefit to these patients

Further research in the field of therapy has shed light on the promise of utilizing chelating agents which might either filter out the accumulated beryllium or immobilize the beryllium so that it cannot be further instrumental in producing pulmonary changes Dr J Schubert of the Argonne National Laboratories has been most instrumental in producing a chelating drug ATA (Aurin Tricarboxylic Acid) which at this stage of its development appears to be toxicologically safe and theoretically sound in approach Provisions are under way to observe a group of patients utilizing ATA as a chelating agent in the hope of producing a better drug than those now available in the management of this very difficult disease

SUMMARY

In summary it might be said that with our greater knowledge of the epidemiology and toxicology of beryllium we can to a great measure prevent the occurrence of this fatal disease by proper medical engineering controls

Unfortunately at this stage of our knowledge we can offer the patient with chronic berylliosis only early diagnosis by annual x ray surveys of exposed populations Upon diagnosis it remains

a matter of continued supportive therapy along with the judicious use of cortisone or ACTH and the promise of fruitful research in the field of the chelating agents

On the basis of the epidemiologic data indicating that beryllium oxide (free) was the cause of the disease, high and low beryllium phosphors used in fluorescent lamp manufacturing were examined for the presence of free beryllium oxide X-ray and electron diffraction and crystallographic studies indicate that the upper limit of solubility of beryllium oxide in the phosphor lattice is of the order of 3 per cent and that when amounts of beryllium oxide in excess of 3 per cent are present, a two-phase system occurs with free beryllium oxide present

Clinically, we have sufficient proof at this stage of our observations to support the fact that only those exposures that are in contact with free beryllium oxide come down with the disease, whereas other exposures in the absence of free beryllium oxide are free of disease

48

Mycotic Infections

ARTHUR Q PENTA M D, *Schenectady, New York*

From the Department of Broncho-Esophagology Ellis and St Clare s Hospitals Schenectady N Y and the Department of Medicine Temple University Medical School Philadelphia Pa

THE study of the mycotic infections of the lungs makes up one of the most interesting chapters in the field of non tuberculous diseases of the chest In their close resemblance, both as to the symtomatology and radiologic findings with that of tuberculosis, the pneumomycoses offer a challenge to the diagnostic ability of the internist, chest specialist and radiologist Since the tendency today in tuberculosis is to lay even greater stress on methods of investigation which will enable an early diagnosis to be made, although it be presumptive only, there will be correspondingly a greater delay in carrying out diagnostic procedures which are extremely essential in the differential diagnosis of the two conditions

Clinically, these pulmonary infections are of interest mainly because of their resemblance to tuberculosis and undoubtedly they occur more often than is generally suspected or recognized As in tuberculosis, the chief symptoms are cough, loss of weight night sweats fever, dyspnea, purulent sputum and hemoptysis Moreover, the physical signs are compatible with a tuberculous infection except that in general tuberculosis has a predilection for the apical regions whereas the mycoses invade chiefly the hilar middle and lower pulmonary fields From a radiologic examination no definite help can yet be expected except that atypical shadows in radiograms of the lungs suspected of being tuberculous should promote more decisive bacteriologic investigation and the carrying out of a tuberculin test which, if negative may prove of some diagnostic value

During the past decade numerous articles have appeared in the literature describing the various forms of pulmonary mycoses It is a significant fact that in many of the reported cases the diagnosis was either established very late in the course of the disease or was con-

author has seen several fatal cases of chronic pneumomycoses in which a tentative diagnosis of tuberculosis had been made previously In spite of the fact that the sputum in these patients had been repeatedly negative for tubercle bacilli, not until very late in the course of the disease had any thought been given to the possibility of this type of infection The sooner it is realized that the final diagnosis of the mycoses rests with the laboratory, which should be employed as soon as possible, the greater will be the opportunity to effect a complete cure in many of these cases

HISTORICAL CONSIDERATION

A search of the available literature dealing with the subject of fungi and fungous disease reveals that the science of mycology was in existence long before that of bacteriology It may be said to have begun in the days of Charles II when Hooke, in 1677, constructed a magnifying lens with which he examined the yellow spots so often present on the leaves of the damask rose [1] He found that they consisted of filamentous fungi which he believed arose from decaying matter by a process of spontaneous generation This initial discovery soon was followed by much work and a considerable number of published articles appeared in the scientific periodicals of the time However, it was not until the discovery of the thrush fungus by Lagenbeck in 1839 that parasitic fungi in man began to attract attention In 1843 Charles Robin classified this fungus as Oidium albicans In the same year (1839), soon after Lagenbeck announced his discovery, Schonlein found another important fungus, the fungus of Flavus In 1844 the fungus of ringworm was discovered by Gruby, and two

years later Eichstedt discovered the fungus of pityriasis versicolor

The science of mycology continued to attract attention until the great discoveries by Pasteur[2] and Koch in the field of bacteriology This immediately brought the study of bacteria to the foreground and mycology was replaced in the background where it has remained until recent years

MYCOLOGIC AND CLINICAL CLASSIFICATION

Since the time of Robin[3] Wernicke,[3] Busse[4] Gilchrist and Stokes[5] Rixford,[6] Montgomery and Ormsby,[7] and Castellani and Ashford,[8] many attempts have been made to classify and identify the fungi pathogenic for man In recent years Jacobson,[9] Dodge,[9] Stovall,[9] and Smith and McBryde[10] have added greatly to our knowledge of this subject In a study of the fungi one finds so much disagreement among students of the subject regarding the botanical and pathogenic classification that it seems best to consider these organisms in connection with the disease that they are known to cause

For the purpose of clinical study the pneumomycoses may conveniently be divided as follows

Yeast like fungi In their simplest form these reproduce by budding and may form a mycelium This group includes Saccharomyces Monilia, Torula histolytica Oidium, Blastomyces, Coccidioides immitis, Histoplasma capsulatum and Sporothrix

Mold like fungi The fungi of this group are characterized by the presence of a stalk with a spore-bearing head which forms fruiting branches and which support specialized cells celled conidia This group includes Aspergillus, Penicillium and Mucor

Higher bacterial forms The fungi of this group are characterized by branching mycelia which break up into segments as conidia with clubbed ends and radiating threads This group includes Actinomycete (acid fast and non acid fast anaerobic and aerobic), Nocardia and Streptothrix

BRONCHOMONILIASIS

Monilia infection of the lungs represents chronic and slowly progressive inflammation in which pathogenic monilia is understood to play a cardinal etiologic role The pulmonary form is caused by a yeast like fungus which falls under the classification of Monilia albicans. The organism is oval in shape and measures from 3 to 10 microns in diameter It reproduces by budding and produces septate hyphae which intertwine to form a mycelium.

The condition was first recognized by Castellani[12] in 1905 among the tea workers of Ceylon and for a time it was thought to be a tropical or subtropical disease Numerous cases have since been reported from various parts of the world. The first instance of infection to be observed in this country was the case reported by Boggs and Pincoff in 1915[13] in the *Bulletin of the Johns Hopkins Hospital* Bronchopulmonary moniliasis is no longer considered a rare disease, although the diagnosis must be made with extreme caution since the organism is often found in association with many types of bacteria in common respiratory infection particularly in the sputum of patients suffering from pulmonary tuberculosis The organism is extremely saprophytic and may, if the pulmonary tissue resistance becomes markedly lowered, find fertile soil to overgrow completely the primary bacteria

During the past several years it has been well known that broad spectrum antibiotic therapy has been responsible for a further increase in the incidence of gastrointestinal and pulmonary moniliasis This so-called secondary fungous infection is due to the fact that this type of therapy may remove both gram positive and gram negative organisms yet leave in their wake an overgrowth of resistant bacteria and yeasts A rather distressing number of fatal fungous infections complicating antibiotic therapy have already been reported in the recent literature[14] Today, we have come to realize that one of the hazards of antibiotic therapy, in the dislocation of the bacterial population, may lead to serious secondary infection

Mode of Infection Monilia is resistant to drying and, like the tubercle bacilli, may live indefinitely in dust and a dry environment The occurrence of this condition among the tea tasters and the coolies working in the dust of tea factories in India, among the pigeon feeders who handle dried bird food and among the peddlers of dried fruit and straws in Egypt strongly points, as in tuberculosis, to inhalation as the most probable means of transmission.

Bronchomoniliasis may be recognized in one of three forms, the mild, the intermediate, and the severe

1 2

FIG 1 Generalized pulmonary moniliasis in a ten year old boy This is the youngest patient with moniliasis ever seen by the author

FIG 2 Pulmonary moniliasis in a twenty five year old man having a fatal termination

In the *mild* type the patient merely complains of a slight cough without temperature elevation or the appreciable physical signs of pulmonary disease The sputum is scanty and mucoid in character The diagnosis usually made at this time is that of chronic bronchitis As the condition progresses the cough becomes more marked, the sputum increases in amount and the patient begins to complain of asthmatoid like wheezing In many instances the diagnosis is changed from that of chronic bronchitis to that of asthmatic bronchitis and eventually these patients are referred to the allergist for treatment

In the *intermediate* form the clinical symptoms and physical signs are more exaggerated There is a persistent low grade fever, the cough is more troublesome and the entire picture may closely resemble early pulmonary tuberculosis

The *severe* form of the disease is chronic in type and usually terminates fatally The pulmonary involvement may be unilateral or bilateral and there is frequently an associated pleural involvement The general clinical picture is that of pulmonary tuberculosis In this type, as in the intermediary form, there is usually a yeast like odor to the sputum This is a very important clinical symptom and should be closely watched for in sputum from chronic pulmonary cases in which there is repeated absence of tubercle bacilli

The sputum of patients suffering from bronchomoniliasis is usually copious and has been described by various authors as "curdy," "lumpy" and "gruel-like" Not infrequently the sputum is hemorrhagic

Except that this disease usually involves the middle and lower pulmonary fields the radiologic studies are not distinctive and simply reveal diffuse pulmonary infiltration with or without cavity formation The entire radiologic picture is generally interpreted as (1) advanced pulmonary tuberculosis, (2) suppurative pneumonitis, (3) mycotic pneumonia (Figs 1 and 2)

Diagnosis and Treatment - The final diagnosis of bronchomoniliasis rests with the laboratory,[13] which should be employed as soon as possible The history of chronic pulmonary infection, with repeated absence of tubercle bacilli from the sputum, should lead one to consider the possibility of a mycotic infection A very important clue is sometimes given by the yeast like odor of the sputum It is generally agreed by the medical mycologists that M albicans is the only species of genus Monilia which is pathogenic to man and should be regarded as responsible for the development of pulmonary moniliasis Sputum from suspected cases of tuberculosis should be examined routinely for fungi If the first examination reveals no tubercle bacilli the sputum should

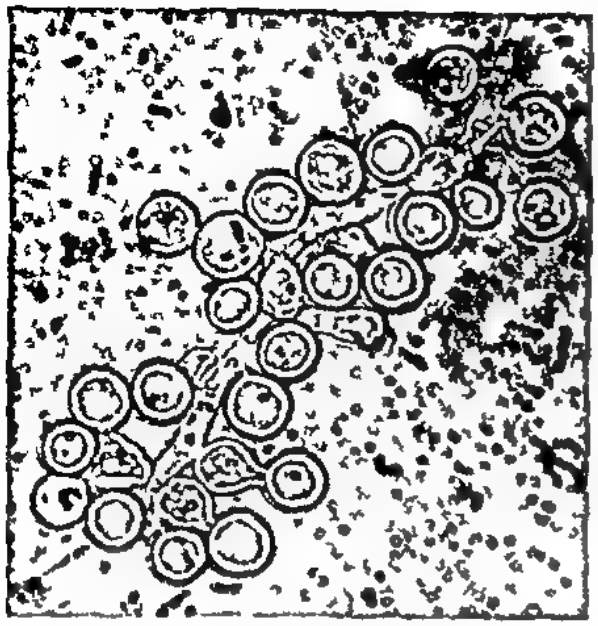

FIG 3 Chlamydospore formation in Monilia albicans massed along the hyphae (Courtesy of Jacob H Swartz and Elements of Medical Mycology New York 1943 Grune & Stratton)

then be cultured on Sabouraud's media In hospitals and sanatoriums where a trained bronchoscopist is available it is recommended that the sputum to be cultured be obtained by bronchoscopic aspiration thus avoiding the possibility of oral contamination (Fig 3)

Potassium iodide is the drug of choice in this condition as it is for many of the other mycoses The best results are obtained when the drug is given in small doses at the beginning of treatment The author prescribes 5 gr three times daily and gradually by the daily addition of 3 gr the dosage may be brought up to 60 to 80 gr three times daily If during the oral administration the patient becomes nauseated and unable to retain the drug it is temporarily discontinued and 10 cc of a 2 per cent sodium iodide solution is given intravenously for a period of several days Ethyl iodide inhalations are another method of iodide therapy and excellent results have been obtained by using this method alone in preference to the use of the oral potassium iodide administration

In the mild bronchial form excellent results are sometimes obtained by the intratracheal instillation of a 40 per cent iodized oil One patient treated by the author[12] could not tolerate the oral administration of potassium iodide Therefore four instillations of 5 to 10 cc of lipiodol® were given at weekly intervals Aerosol inhalations of an antifungal drug such as zephiran® chloride in the strength of 1 3000 using 3 to 5 cc three times daily has proved very effective in the bronchial allergic form of moniliasis Actidione® a by product in the manufacture of streptomycin has also been reported of some value in the treatment of the pulmonary form of moniliasis Stovall[9] and others recommend the use of gentian violet given intravenously in the dosage of 5 mg /kg of body weight

Martin and Smith[14] have called attention to the similarity of many of the pathologic and clinical features of the various pulmonary mycoses to tuberculosis and suggest that an allergic state similar to the hypersensitiveness seen in tuberculosis would not be surprising They further call attention to the value of skin testing with the causative fungus before any form of therapy is considered Iodides are given cautiously and only if the patient shows a negative or weakly positive skin reaction If the patient exhibits a marked skin reaction an attempt is made to reduce the sensitivity by vaccine therapy before iodides in any form are given From their experience they have found iodides distinctly harmful if the patient is strongly allergic

At the present time a vigorous search is underway to discover newer antifungal agents Many antifungal antibiotics have been reported in the recent literature for the treatment of moniliasis Thus far they have not found widespread use because of inherent toxicity or other unfavorable properties As these agents undergo a more thorough study they may prove clinically more acceptable Mycostatin® one of the first antifungal antibiotics to be developed is very effective in the treatment of intestinal moniliasis resulting from protracted oral treatment with antibiotics against intestinal bacteria The drug is given orally in dosage of 500 000 unit tablet three times daily If intestinal fungi as shown by stool examination are not adequately suppressed the dosage may be doubled Unfortunately because the drug can only be administered orally and is so poorly absorbed in the intestinal tract it cannot be depended upon for systemic effects Candidin® and candicidin® antifungal antibiotics produced by Streptomyces viridoflavus have been shown to exhibit a marked inhibitory effect in vitro against a number of filamentous fungi

FIG 4 Culture of blastomyces showing spherical or oval budding cells fruit bearing aerial hyphae and mycelium (Courtesy of David T Smith M D, Dept of Bacteriology, Duke Univ Medical School)

but are less active against Monilia albicans Although still in the experimental stage, these antifungal antibiotics have great possibilities as therapeutic agents

CRYPTOCOCCOSIS (TORULOSIS)

Torulosis is caused by a yeast like fungus, Torula histolytica, which reproduces only by budding without mycelial or endospore formation Torulae are widely distributed in nature They are found on trees, flowers, fruits, insects and grasses, and they have also been recovered from canned butter and canned milk T histolytica, when obtained from fresh material such as sputum, pus or spinal fluid and examined under the microscope unstained, may easily be mistaken for lymphocytes They are ovoid or spherical cells, measuring 3 to 15 microns in diameter, and are enclosed by a definite cell wall which stains well with methylene blue

A study of the reports of the recorded cases of systemic torulosis reveals that the infecting parasites have, primarily, a predilection for the tissues of the cerebrospinal system [32] The symptoms resulting from the central nervous system invasion closely resemble the symptoms of tuberculous meningitis, intracranial neoplasm or abscess The last two conditions are so realistically simulated that subtemporal and suboccipital decompressions have been erroneously performed in an effort to establish a diagnosis [31]

Primary pulmonary torulosis is a rarity, and when found is usually an associated complication and secondary to cerebrospinal torulosis In view of the fact that torulae are widely disseminated in nature, it has been suggested that the portal of entry is by way of the respiratory and digestive tracts

Once the condition is diagnosed no time should be lost in instituting massive iodide therapy Pulmonary resection has been reported as effecting a complete cure [15]

BLASTOMYCOSIS

Blastomycosis, commonly known as Gilchrist's disease, is caused by a yeast-like fungus which appears in the lesion as an oval or spherical body, having a diameter of 10 to 20 microns consisting of finely granular protoplasm It is enclosed in a double-contoured, highly refractive hyaline capsule Multiplication in the tissues takes place by budding, however, some mycologists have reported reproduction by sporulation On examination of cultures spherical or oval budding cells, fruit-bearing aerial hyphae and mycelium may be seen (Fig 4)

the natural reservoir of the fungus is in nature Unfavorable hygienic surroundings, according

FIG 5 Roentgenogram of patient with blastomycosis which responded to several weeks of intensive iodide therapy

to Stober, seem to play a determinative role in its causation Martin and Smith in a recent complete study of the condition state that although patients infected with this fungus have been found in all decades of life no *systemic infections have thus far been described* in a patient under the age of twelve years or over the age of seventy

Mode of Infection Inhalation of contaminated dust or air probably plays the most important role in the transmission of the fungus deep into the respiratory tract Recently a few cases have been reported in which there was a direct transmission of the disease from man to man Evans reported a case of a pathologist who received a puncture wound on his finger while performing a necropsy on a patient with systemic blastomycosis A primary infection developed at the site of the needle puncture and four months later blastomyces were demonstrated by biopsy and culture

Mode of Onset The cutaneous manifestations which are a characteristic feature of pulmonary blastomycosis may precede the onset of pulmonary symptoms In their absence the condition is generally confused with that of tuberculosis In a recent survey of the reported cases of pulmonary blastomycosis to date nearly half have had no evidence of cutaneous lesions

Pulmonary Involvement Blastomycotic infection of the lungs constitutes the most frequent form of the systemic type of the disease The clinical manifestations of the disease may have an acute or rapid onset or the initial symptoms may resemble those of a cold or influenza and be so transient and mild as to escape the patient s attention When acute in type the infection is usually ushered in with a chill pain in the chest and symptoms of an acute respiratory infection which closely *simulates the onset of lobar pneumonia*

Diagnosis and Treatment The course of the disease is chronic with exacerbations and remissions The symptoms and the clinical course of the disease closely resemble those of pyemia and advanced pulmonary tuberculosis

The diagnosis can be definitely established only by the isolation and identification of the infecting organism Frequently when the skin lesions are present the diagnosis may be established by a recognition of the nature of the cutaneous lesions and the demonstration of the blastomyces in pus from the abscesses or in a biopsy of the tissue Early in the disease the roentgenograms according to Potter[16] usually show a dense irregular shadow extending from the hilum toward the periphery of the *lung In pulmonary infections of obscure* etiology in which blastomycosis is suspected a skin test and complement fixation reaction should be performed

Pulmonary blastomycosis is highly fatal reaching a mortality much higher than that of tuberculosis In an analytic study of 117 reported cases Martin and Smith[14] found that the mortality rate was 78 per cent

The drugs of choice in the treatment are 2 hydroxystilbamidine and potassium iodide They may be used either alone or in a combined form of therapy Stilbamidine[45] may be given intravenously in the dosage of 2 to

3 mg /kg of body weight The drug is dissolved in a solution of 5 per cent glucose in distilled water and administered by a slow intravenous drip Schoenbach et al [9] recommend that liver function tests and renal studies should be carried out before this form of therapy is instituted, since the drug may produce liver and renal damage when given over a long period of time When iodides are employed, the course and method of treatment are similar to the one previously outlined for the treatment of moniliasis

Martin and Smith recommend skin testing with standardized blastomyces vaccine before any form of therapy is considered From their experience in the treatment of moniliasis they have also found that iodides are distinctly harmful if the patient is strongly allergic Before instituting any form of iodide therapy in patients who show a marked allergic reaction, they recommend that an attempt be made to reduce the sensitivity by giving small desensitizing doses of vaccine In recent years, due to the great progress made in the field of thoracic surgery, pulmonary resection has come to play an important part in the treatment of blastomycosis and other pulmonary fungous infections In some clinics devoted to the diagnosis and treatment of pulmonary diseases iodides and vaccine therapy are first employed in the acute phase of blastomycosis in the hope of converting the disease to a chronic, well stabilized lesion which will be suitable for surgery (Fig 5)

COCCIDIOIDOMYCOSIS

Coccidioidomycosis is a chronic infectious disease caused by the fungus Coccidioides immitis It presents itself as a well defined disease of the skin or as a general infection involving both the skin and the internal organs It is protean in its clinical manifestations and often presents a clinical picture closely resembling that of pulmonary tuberculosis and blastomycosis, both in symptoms and physical signs The etiologic fungus, which morphologically closely resembles the blastomycete, appears in the tissues and in the pus from granulomatous lesions as an oval or spherical body surrounded by a double contoured hyaline capsule The size varies from 5 to 50 microns in diameter It differs from the blastomycete chiefly in multiplying in the tissues by sporulation, instead of by budding,

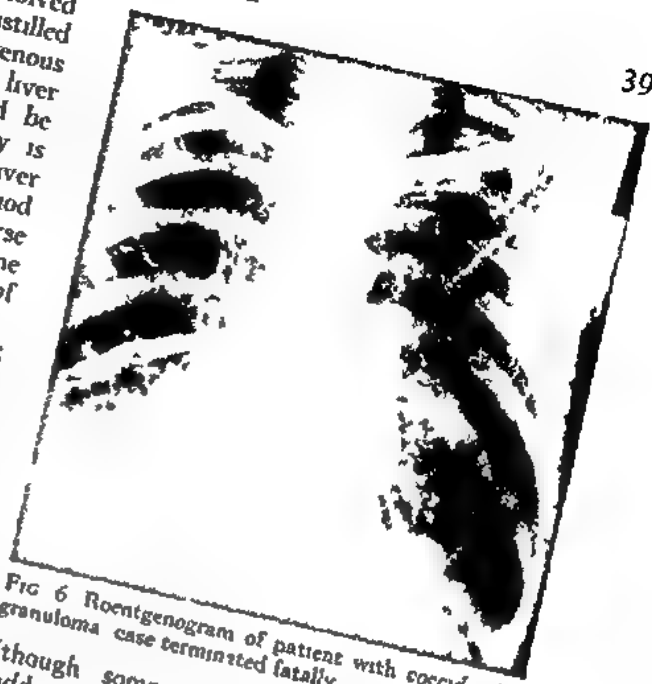

FIG 6 Roentgenogram of patient with coccidioidal granuloma case terminated fatally

although some mycologists have observed budding in fresh preparations of pus (Figs 6 to 8)

In a statistical study of the disease by far the largest number of reported cases have been from southern California and the San Joaquin Valley Recently a small number of cases has been reported from other portions of the United States [11] The condition was first described in this country by Rixford in 1895 [8] Persons of all ages and of either sex may be affected The highest incidence of the disease appears to be in regions where there is prolonged hot, dry weather favorable to the dissemination of the spores In 1936 the State Department of Health of California reported that since the initial case in 1895 a total of 450 cases with 224 deaths had occurred

Trimble,[12] in an excellent review of the subject, calls attention to the fact that coccidioidomycosis should no longer be considered a rare disease confined to the southwestern part of the United States and certain parts of South America. It was shown that during World War II a high incidence of infection occurred in military personnel who were stationed in endemic areas The author, located many miles from the southwestern part of the United States, has already seen a number of cases in his own community

As in blastomycosis, cutaneous lesions may precede the onset of the pulmonary symp



FIG 7 Coccid o des in t ssue section of lung show ng double-contoured hyal ne capsule with formation of endospores

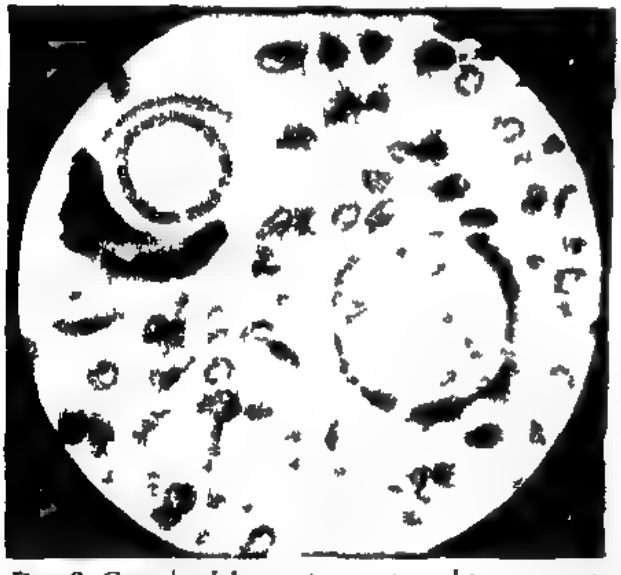

FIG 8 Coccid a dal immit s in sta ned t ssue prepa ration showing organisms contain ng typ cal endospores

toms[11] However it is more common in coccidioidal granuloma to obtain a history of respiratory infection several weeks before the appearance of the external lesions Dickson[12] described a condition called valley fever which is characterized by a cold or bronchopneumonia often with a relatively high fever and the appearance of painful erythema nodosum This he stated was the primary infection with coccidioides

Trauma seems to be a predisposing factor and lesions often develop at the site of the traumatized area Involvement of the epiphyseal ends of the long bones is very common in this condition Many of the patients also develop large subcutaneous fluctuating abscesses from which pus can be aspirated with ease In 1936 through the courtesy of Dr Newton Evans pathologist at the Los Angeles County Hospital the author[13] had the good fortune to see several such cases in which many large nodular subcutaneous fluctuating masses were present

From a study of the roentgenograms of many of these cases Evans and Ball[19] make the following comment A diffuse shadow at times simulating pneumonia occurs in many cases and involves the right lower lobe twice as frequently as any other part of the lung field though it may occur in any portion and twice as frequently in both hilar regions as in one In many cases the lesions are those of a disseminated miliary tuberculosis'

Differential diagnosis of coccidioidal granuloma offers the following difficulty (1) miliary bronchopneumonia (2) miliary tuberculosis

primary focus of coccidioidal granuloma may remain dormant in the lungs for many years In the acute coccidioidal infections some observers have estimated that the period of incubation is between two to three weeks

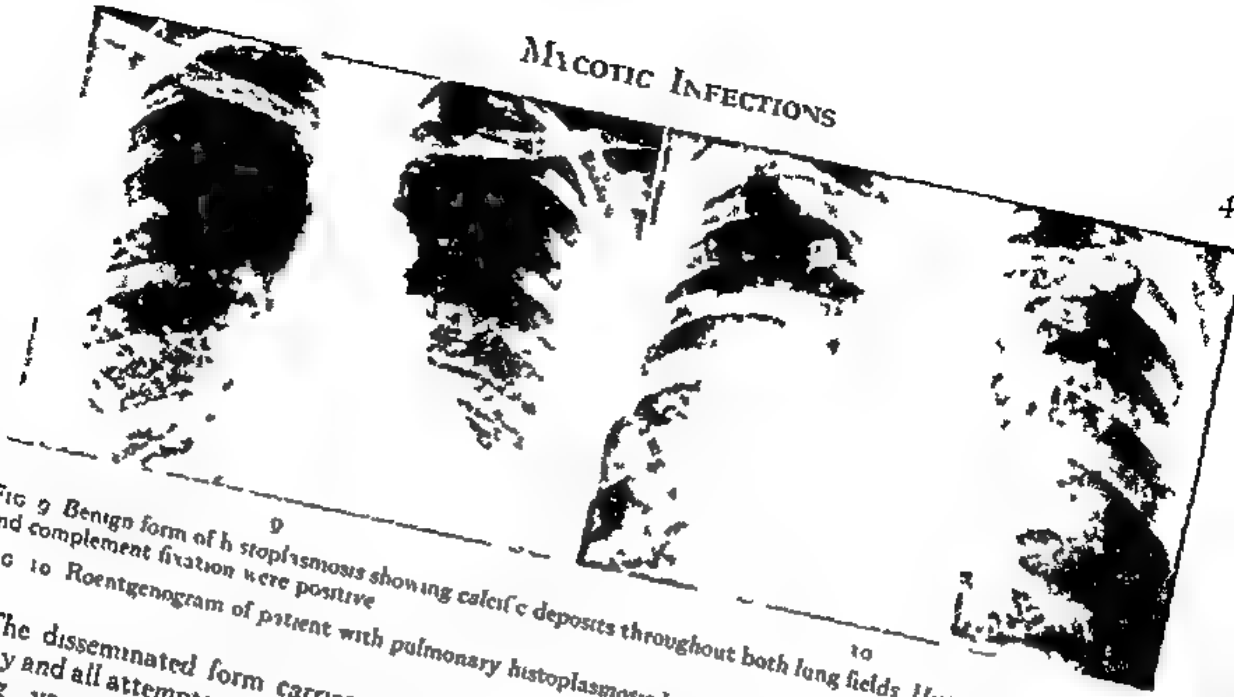

9 10

FIG 9 Benign form of histoplasmosis showing calcific deposits throughout both lung fields Histoplasmin skin test and complement fixation were positive

FIG 10 Roentgenogram of patient with pulmonary histoplasmosis having a fatal termination

The disseminated form carries a high mortality and all attempts in the medical treatment using various antifungal agents such as prodigiosin, sodium caprylate ethyl vanillate, stilbamidine and some of the newer aromatic diamidines, have proved unsatisfactory In the skin form Ball has obtained encouraging results from the use of iodine in concentrated form Tomlinson and Bancroft[20] expressed the opinion that the use of antimony and potassium tartrate, in addition to roentgen therapy, is of value Jacobson[21] obtained fair results in a number of cases by intramuscular injections of colloidal copper combined with cutaneous injections of coccidioidin

The most encouraging results to date in the treatment of the well defined granulomatous lesions with or without cavity formation has been brought about by pulmonary resection In 1950 Cotton[17] reported a large series of cases in which he obtained excellent results by surgical intervention Many of the patients on whom he operated had been under medical treatment for a long period of time and showed evidence of beginning cavity formation Since pulmonary resection today has become such a relatively safe procedure it should be employed more often in the treatment of this disease

HISTOPLASMOSIS

In 1906 Darling while working in Panama first described the condition of histoplasmosis and isolated the causative fungus, Histoplasma capsulatum The disease presents a variety of clinical and radiologic manifestations Primary histoplasmosis occurs most often in the lungs, usually runs a benign course and the resulting resolution of the filtrate generally leaves areas of multiple calcification in the parenchyma and regional lymph nodes The progressive disseminated form of histoplasmosis carries a high mortality In the fatal form of the disease the primary lesion is generally located in the mouth and upper respiratory tract Primary pulmonary lesions are difficult to differentiate from a variety of acute and chronic infections of the lungs including acute respiratory disease, viral pneumonia, other mycotic infections and tuberculosis (Figs 9 and 10)

The causative fungus, H capsulatum, is a small encapsulated oval shaped yeast like fungus measuring 1 to 3 microns in diameter It differs from all other fungi pathogenic for man in that the organism is primarily a parasite of the reticuloendothelial system It is usually found in the mononuclear cells in peripheral blood smears, sternal bone marrow smears and in the cytoplasm of endothelial cells The presence of the organism in sputum and gastric washings should stimulate further bacteriologic and serologic studies Furcolow[21] an outstanding authority on histoplasmosis, describes several serologic tests as aids in the diagnosis of this disease Following a positive histoplasmin test he and his associates recommend the following procedures (1) complement

FIG 11 Histoplasma capsulatum showing fungus with distinctive tuberculated border



FIG 12 Histoplasma capsulatum (magnified) showing a well defined tuberculated border (Courtesy of Department of Medicine Mayo Clinic)

fixation (2) collodion or red cell agglutination and (3) precipitin test (Figs 11 and 12)

At the present time there is no specific therapy for the treatment of histoplasmosis Fortunately the great majority of patients with this disease recover without any form of special treatment Christie and his associates[22] at Vanderbilt University have used ethyl vanillate with some encouraging results Other investigators have found some value in the use of iodides combined with actidione therapy In localized lesions pulmonary resection has produced a curative result

SPOROTRICHOSIS

The pulmonary form is occasionally seen in this country although by far the greatest number of cases have come from Europe The largest number of reported cases in this country have occurred in the Mississippi River basin The causative agent is a yeast like fungus of either the Schenkii or Beurmanni type It multiplies by budding and in cultures it forms a mycelium composed of freely branching septate hyphae which in turn give rise to secondary conidia

Infection may take place under various conditions and through a variety of agencies Infected plant or vegetable matter carrying the organisms directly into an area of broken skin or mucous membrane probably constitute the most common source of infection Foerster reported a series of cases in which the infection was acquired by pricking with the thorn of the barberry shrub Certain insects notably flies, wasps and ants frequently carry and harbor the sporotricha parasites and the bite or sting of these insects may carry the organisms in the tissues and cause active infection

The cutaneous lesions which develop in this condition are difficult to differentiate from the primary lesions of syphilis cutaneous tuberculosis and the ulceroglandular type of tularemia The fungi[23] of the Sporothrix group are very sensitive to the iodides and many of the reported cases have shown a complete cure following a short course of treatment In the more resistant cutaneous lesions unfiltered x ray radiations are used in combination with the iodides

ASPERGILLOSIS

Pulmonary aspergillosis is commonly caused by a mold like fungus Aspergillus fumigatus possessing a stem and a stalk with a spore bearing head Due to their resemblance to a brush this group of fungi derive their name from the word aspergillum a brush which is used in the Catholic church for the sprinkling of holy water (Figs 13 to 15)

There are three varieties of pathogenic Aspergillus—A fumigatus A flavus and A niger—which under conditions of lowered bronchial pulmonary resistance may cause an infection in the respiratory tract The infection caused by these molds frequently runs a chronic course and the causative parasites seem to have a special affinity for the tissues of the pulmonary system Occasionally the skin sinuses and the external auditory canal are also involved In this group of fungi there are also many non pathogenic forms[23] which are used to good advantage commercially for the ripening of Roquefort cheese and the production of citric acid

The first case of aspergillus infection in man was reported by Bennet in 1843 [24] Virchow[25]

first determined the identity of the parasites in 1856 Dieulafoy[25] reported the occurrence of aspergillosis among the pigeon feeders of France Renon[26] described the same condition among the workers in the hair sorting industry and isolated A fumigatus as the causative

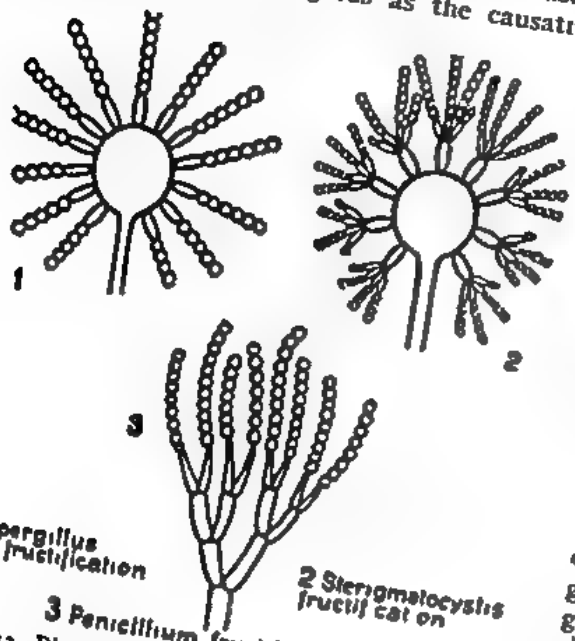

FIG 13 Photograph of aspergilli showing stalk and spore-bearing head

agent In all of the previously reported cases the disease terminated fatally In 1890 Widal[27] described clinically several cases of pulmonary aspergillosis occurring in persons who were engaged in fattening pigeons for the Paris market

In 1926 Mary Lapham[28] reported ten cases of primary pulmonary aspergillosis from an obscure village in the Blue Ridge Mountains and divided the cases into two groups the wet or parenchymatous type and the dry or interstitial type She also called attention to a definite relationship to asthmatic attacks in certain cases

Most pathologists describe the pulmonary form as falling into two characteristic groups a superficial and a deep form In the former are included cases of bronchitis catarrhal or asthmatoid which run a fairly benign form The deep, or ulcerative type depends upon the dosage and the ability of the endotoxins of the mold to cause necrosis of lung tissue analogous to the action of tuberculin in causing caseation in pulmonary tuberculosis The asthmatic

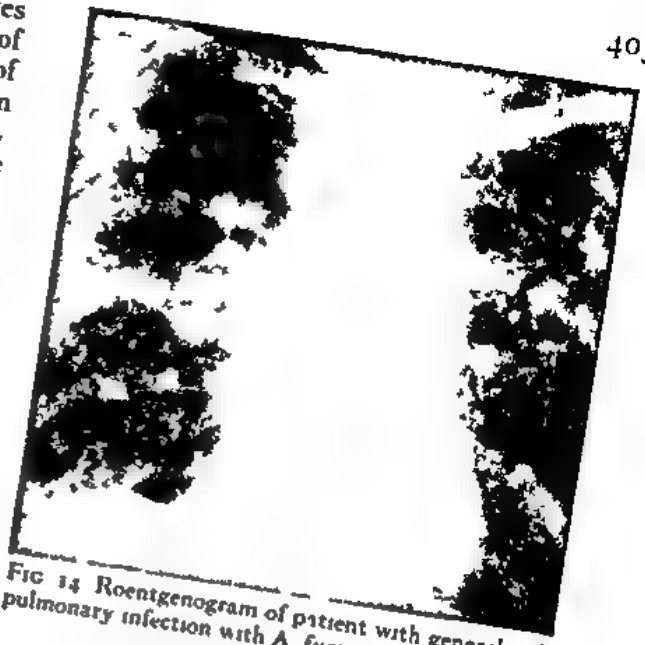

FIG 14 Roentgenogram of patient with generalized pulmonary infection with A fumigatus

type of aspergillosis has resulted in the addition of a new chapter to the field of allergy Allergists are well aware of the frequency of aspergillus sensitivity in asthma and allergic rhinitis Today no allergic study is complete unless the skin testing for molds is performed

Pulmonary aspergillosis, clinically and pathologically, so closely resembles pulmonary tuberculosis that it usually escapes recognition and is diagnosed as tuberculosis The only roentgenologic findings which may be of diagnostic value is that in aspergillosis, migratory lobar and segmental atelectasis is commonly observed

Hinson Moon and Plummer,[29] in a recent and comprehensive review of the subject, call attention to the similarity of the radiologic findings with those seen in the so-called pulmonary eosinophilia (Loeffler's syndrome) They further call attention to the fact that in the eight cases which they recently reported a high blood eosinophilia was a constant finding

Climatic, occupational and regional conditions may have some bearing on the development of this disease In certain parts of the United States aspergillus infection does not seem to be of the severe pathogenic type The majority of the cases having a fatal termination have been reported from Europe

In the treatment of this condition particular attention must be paid to an existing allergic state Various antifungal drugs previously



FIG 15 Aspergillus, showing stalks and spore-bearing heads The basal stems are not shown in this photograph (Courtesy of Dr N S Plummer London)

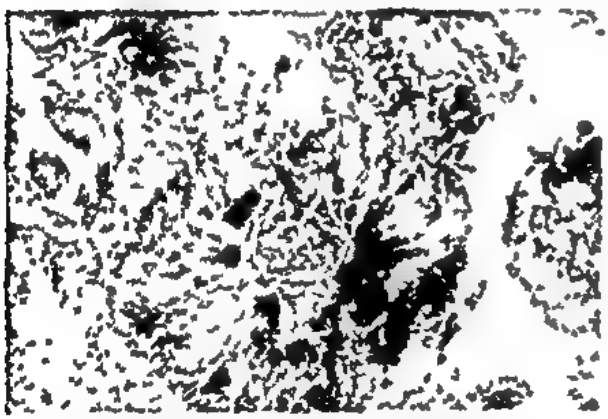

FIG 16 Colony of ray fungus isolated from sputum bronchoscopically aspirated from patient with pulmonary actinomycosis (Courtesy of Dr C B Schoempeslen Winnipeg, Canada)

FIG 17 Crushed actinomyces granule from fresh sputum unstained under high power magnification showing the clubs or rays In culture and stained preparations these are not seen

described for the treatment of other mycosis, combined with ACTH and cortisone therapy,

ectatic involvement, pulmonary resection is the treatment of choice

ACTINOMYCOSIS

Bollinger first described this disease in

the fungus in man, and later Ponfick pointed out the identity of the human and bovine infections The first case of the disease to be recognized in this country was reported by Murphy in 1885 In 1923 Sanford[9] collected a total of 6-8 cases of actinomycosis from all the available sources in the United States and expressed the opinion that the number of cases represented only a small proportion of the actual number of victims suffering from this disease Since Sanford's comprehensive study many more cases have been reported from all portions of the country

Actinomycosis may be caused by any one of several species of fungi of the genus Nocardia, Actinomyces or Streptothrix[11] The diagnosis of actinomycosis in any of its forms is ultimately dependent upon the finding of the

characteristic sulphur like granules containing the ray fungus This causative agent is present in the lesion and in the pus in the form of spherical or irregularly rounded grayish or yellow granules When these so-called sulphur granules are crushed between slide and cover glass and examined with the microscope under high power, one sees an indefinite mass of tangled fibers and debris Pus cells are found at the center, and at the periphery there is a dense network of interlacing filaments which at their extreme margin show the refractive club or rays It is important that one sees both the rays and mycelium before establishing a definite diagnosis (Figs 16 and 17)

Pulmonary actinomycosis is often fatal, and although this condition is often confused with tuberculosis, the clinical and pathologic course is quite different There is no other pulmonary condition in which there is a tendency on the part of the disease to burrow its way in all directions From a single lesion in the lungs one sees many sinuses radiating in all directions The involvement of the neighboring organs by direct extension is a striking feature of this disease Invasion of the pleura and peripleural tissues is almost invariable, and usually leads to the formation of adhesive pleurisy Erosion of the ribs, perforation of the intercostal spaces in one or more places and superficial thoracic abscesses are often found Invasion of the pericardium and the mediastinum with erosion of the vertebra takes place with regular frequency (Fig 18)

Israel[28] has divided the clinical course of the disease into three stages In the first or bronchopulmonary, stage the process does not extend beyond the limits of the pulmonary tissue Incidentally, it is in this stage that the condition might be amenable to surgery, for Actinomyces are usually anaerobic and with the entrance of air, which follows the free opening of the many sinus tracts and the resection of the circumscribed diseased tissue, a complete cure may be effected Unfortunately, one almost never sees a patient in this early stage Involvement of the pleura marks the beginning of the second, or pleurothoracic, stage while invasion of the thoracic wall termi-

FIG 18 Roentgenogram of thirty five year old patient with pulmonary actinomycosis This patient had been under observation for tuberculosis for several weeks (Courtesy of Dr C B Schoemperlen Winnipeg Canada)

FIG 19 The terminal or fistulous stage of actinomycosis so commonly seen not too long ago in many of our sanatoriums and general hospitals

nates in the third, or fistulous, stage It is in this stage that we most commonly see the condition This classification presents a useful picture of the usual progress of the disease (Fig 19)

The medical treatment of this condition makes up one of the gloomy chapters in the history of medicine Because of the seriousness of the condition numerous attempts have been made to discover some therapeutic agent which would arrest the progress of the disease and alleviate the sufferings of the patient As yet, however, nothing specific has been discovered to accomplish this end with any degree of certainty In 1937 Myers reported successful treatment in five of his six cases of actinomycosis affecting different portions of the body by the oral administration of thymol Employing Myers' method, in 1939 Etter and Schumacher[30] reported a case of pulmonary actinomycosis successfully treated by thymol Their patient received 30 gr of thymol daily for a period of seventeen days Other investigators have reported successful treatment by the use of massive doses of potassium iodide Because of the numerous respiratory infections responding to the sulfonamides and antibiotic therapy these agents have been used in combination with iodides Bevan[2] advocates the use of copper sulphate in ¼ gr doses several times daily Non-specific protein therapy has been successfully employed by Epstein in two cases of actinomycosis Penicillin has proven to be quite an effective drug in the treatment of this disease

[illegible]

the

sur

made today in the field of thoracic surgery, there is great hope that the pulmonary form of this disease may be successfully treated by the thoracic surgeon

SUMMARY AND CONCLUSIONS

In this brief review of the mycotic infections of the lungs the author has attempted to emphasize the following

1 The close resemblance between this type of infection and that of pulmonary tuberculosis

2 Pneumomycotic infections undoubtedly occur more often than is generally suspected or recognized, and in obscure pulmonary infections the possibility of this condition should always be considered

3 The importance of the laboratory as an indispensable means of establishing the early diagnosis

4 Once the diagnosis has been definitely established, antifungal therapy, as previously outlined, should immediately be instituted In suitable cases pulmonary resection may effect a complete cure

REFERENCES

1 CASTELLANI, A Fungi and fungous diseases *Arch Dermat & Syph*, 16 383 571, 714, 1927 17 61, 194 354 1928
2 JACOBSON H P Fungous Diseases. Springfield, Ill., 1932 Charles C Thomas
3 *Centralbl f Bakt*, 12 859 1892
4 LORD F T Diseases of the Bronchi, Lungs and Pleura Philadelphia 1915 Lea & Febiger
5 *Bull Johns Hopkins Hosp*, 7 129 1896
6 STORTS, B P Coccidioidal granuloma simulating brain tumor in a child four years old *J A M A*, 112 1334–1335 1939

[illegible]

9 [illegible] mycosis *J A M A* 91 1346–1351, 1928
10 SMITH, D T and MCBRYDE, A Pulmonary abscess in children *South M J*, 26 686–692, 1933
11 GOLDWORTHY N E Pulmonary actinomycosis caused by acid fast species of actinomyces. *J Path & Bact*, 45 17–27, 1937
12 IKEDA, K Monilia infection of lungs *Am J Clin Path*, 7 376–388, 1937
13 PENTA, A Q Fungous diseases of the lungs *Journal Lancet*, 55 131–135, 1935
14 MARTIN, D S and SMITH, D T Laboratory diagnosis of blastomycosis by culture and by complement fixation *J Bact*, 31 70, 1936
15 FROIO, G F and BAILEY C P Pulmonary cryptococcosis report of case with surgical cure *Dis of Chest* 16 354, 1949
16 POTTER, H E *Am Quart Roent*, 2 243, 1910
17 TRIMBLE, H G Coccidioidomycosis *Dis of Chest* 20 588 1951
18 DICKSON E C Valley fever of San Joaquin Valley and fungous coccidioides *Calif & West Med.*, 47 151–155, 1937
19 EVANS, N and BALL, H A Coccidioidal granuloma *J A M A*, 93 1881–1884 1929
20 TOMLINSON C C and BANCROFT P Granuloma coccidioides *J A M A* 102 36–38 1934
21 SALVIN S B and TURCOLOW, M L Precipitins in human histoplasmosis *J Lab & Clin Med*, v 43
22 CHRISTIE, A, MIDDLETON J C, PETERSON J C and MCVICKAR, D L Treatment of disseminated histoplasmosis with ethyl vanillate *Pediatrics* 7 7 1951
23 Beitrage z Lehre von den beim Menschen vorkommenden pflanzlichen Parasiten *Virchows Arch f path Anat.*, p 557, 1856.
24 *Virchows Arch f path Anat*, p 15, 1878
25 DIELLAFOY, CHANTEMESSES, WIDAL and RENON

26 LORD, F T Diseases of the Bronchi Lungs and Pleura Philadelphia, 1915 Lea & Febiger
27 LORD F T Ibid
28 LAPHAM M E Aspergillosis of the lungs and its association with tuberculosis J A M A 87 1031 1033 1926
29 HINSON K F W MOON A J and PLUMMER N S Thorax 7 317 1952
30 ETTER L E and SCHUMACHER, F L Pulmonary actinomycosis recovery after thymol therapy J A M A 113 1023 1024, 1939
31 ROBERTSON W E ROBERTSON H F RIGGS H and SCHWARTZ L Torulosis involving the human cerebrum J A M A 113 482 484 1939
32 GILL, W D Torula mycosis in man with special references to involvement of upper respiratory tract Tr Am Laryng Rhin & Otol Soc 40 247-262 1934
33 THOM C Penicillia Baltimore 1930 Williams and Wilkins Co
34 BROWN C JR. PROPP S GUEST M C. BEEBE R T and EARLY L Fatal fungous infections complicating antibiotic therapy J A M A vol 152 1953
35 Personal communication Research Department of E R Squibb & Sons, February 1955
36 TABER, W A VINING L C and WAKSMAN S A Candidin a new antifungal antibiotic produced by Streptomyces viridoflavus J Antibiotics & Chemother no 4 April, 1954
37 LECHEVALIER, H A ACKER R F CORKE C. T HAENSELER C M and WAKSMAN S A Candidin a new antifungal antibiotic Mycologia 45 155-171 1953
38 SNAPER J SCHNEID B McVAY L and LIEBEN F Pharmacology and therapeutic value of diamine derivatives particularly of hydroxystilbamidine Tr New York Acad Med 14 269, 1953
39 SCHOENBACH E B MILLER J M and LONG P H The treatment of systemic blastomycosis with stilbamidine Ann Int Med 37 31 1952

Histoplasmosis

Lt Col Thomas F Puckett, m c, *Hattiesburg, Mississippi*

From the Laboratory Service Fitzsimons Army Hospital Denver, Colorado

Histoplasmosis is a highly infectious mycosis caused by Histoplasma capsulatum and presents a variety of clinical, pathologic and roentgenologic manifestations Although first described by Darling in Panama in 1906[1] as a protozoon the organism was later shown to be a fungus[2] and was placed in the Fungi Imperfecti by Conant in 1941[3] Skin testing surveys have shown the disease to be highly endemic in the Mississippi and Ohio Valleys and along the Appalachian mountains In certain local areas sensitivity to intradermal histoplasmin may be as high as 80 per cent of the adult population Fringe areas of lesser sensitivity extend outward from these regions[4]

It is now well established that the usual route of infection is the respiratory passage giving rise to a primary focus or primary foci within the lungs The extensive studies of Christie and Peterson[5] and Furculow and his associates[6] have shown that most histoplasmoses exist in the form of a relatively benign primary pulmonary infection Primary histoplasmosis is clinically indistinguishable from common upper respiratory infections and may be asymptomatic It usually has a short benign course and healing may result in complete resolution More frequently healing leaves one to many discrete, scattered, fibrotic or more often calcified lesions in one or more lobes In a small percentage of cases the primary form is progressive resulting in disseminated histoplasmosis usually characterized by involvement of all organs of the body Disseminated histoplasmosis is usually fatal and has been shown to occur more frequently at both extremes of the life span[7] The disseminated form has been covered in a number of excellent reviews[7–10]

One characteristic of histoplasmosis is its tendency to occur in epidemics following exposure in heavily contaminated areas by groups of persons Epidemic histoplasmosis is characterized by widespread involvement of the lungs, a severe and frequently prolonged illness but is rarely fatal Grayston and Furcolow[11] have recently studied thirteen epi [illegible] an extensive three year follow-up of a small epidemic in one family[11]

There is increasing evidence that a chronic active form of pulmonary histoplasmosis exists that closely mimics pulmonary tuberculosis Some of these cases may be reinfection histoplasmosis As an example Johnson and Batson's case contained an apical cavity, fibrotic infiltrations in the contralateral apex, and scattered calcified lesions in the remainder of the lung fields[12] Sutliff and his associates[14] reviewed eleven cases of chronic pulmonary histoplasmosis called attention to the location frequently being in the upper lobes and mentioned that the process was usually fibrocavitary It is apparent that this form of the disease is intermediate between uncomplicated primary histoplasmosis and widely disseminated histoplasmosis in its course It is also this form that appears to be amenable to definitive surgical therapy[10 15 16]

OBSERVATIONS

The present series consists of sixty seven cases from which pulmonary tissue, hilar nodes or both were removed and H capsulatum was identified in the resected material It is emphasized that in all cases the disease process is believed to have been stabilized The cases are therefore probably best classified as healed or healing primary histoplasmosis Thirty of these cases have been previously reported[17 18] Nine patients were white women and fifty-eight were white men In all cases there was a history of residence in known endemic areas for periods of from one to twenty years Table 1 shows the patients by age group

Almost one-half of the patients were in the age group twenty-one to thirty years It should be borne in mind that patients in the

Army are predominantly young males As already mentioned disseminated histoplasmosis is more common at both extremes of the normal life span During the intermediate period of life more cases seem to occur in young adult males, probably due to more frequent exposure A

TABLE 1
AGE GROUPS FOR SIXTY SEVEN PATIENTS WITH PULMONARY HISTOPLASMOSIS

Age (yr)	No of Cases
18 to 20	4
21 to 30	31
31 to 40	22
41 to 50	8
51 to 60	1
61 to 70	1

similar predominance in adult males has been noted in other fungous diseases [20]

The preoperative diagnoses varied greatly Many of the cases were referred to Fitzsimons Army Hospital with a diagnosis of "tuberculoma" and others as "coin lesion" of the lung A presumptive diagnosis of histoplasmosis was made in several cases that were asymptomatic, were positive reactors to intradermal histoplasmin and negative reactors to intradermal coccidioidin and tuberculin Focalized coccidioidomycosis was considered in those patients with residence in endemic areas Some patients showing multiple nodose lesions by roentgenograms and having a positive reaction to tuberculin were given a presumptive diagnosis of tuberculosis and a few underwent trial courses of chemotherapy for tuberculosis without change in the roentgenograms The diagnoses of lymphoma or sarcoid were considered in several cases showing only hilar node enlargement One patient showing a cavity was thought to have tuberculosis as a positive reaction to both histoplasmin and tuberculin was present The diagnosis of neoplasm was entertained in several patients in the older age groups In one case the pulmonary lesion was thought to be metastatic since the patient had had a malignant tumor elsewhere In no instance could the presumptive diagnosis of histoplasmosis be confirmed by cultural methods preoperatively

SYMPTOMATOLOGY

Thirty one patients in this series were completely asymptomatic and the lesions were found by routine chest roentgenograms taken for reenlistment, annual physical examinations or, in three cases, in connection with investigation of complaints other than those referable to the pulmonary system Eight patients complained of malaise, easy fatigue and weight loss varying from 10 to 25 pounds over periods up to two years Eight patients had blood-streaked sputum on one or more occasions One patient had two bouts of frank hemoptysis Eight patients had fever (the highest 103°F) and all fevers were associated with symptoms referable to the upper respiratory tract Ten patients complained of transient pleural pain Fifteen patients estimated their onset to coincide with a rather mild but prolonged upper respiratory infection Five cases presented the typical symptoms and clinical findings of a middle lobe syndrome [11] Three of these cases are being reported in detail elsewhere [22]

In four cases the lesions were considered incidental findings in pulmonary tissue removed for the therapy of other conditions One patient had proven tuberculosis with lesions in both the right upper and right lower lobes Under prolonged chemotherapy the upper lobe lesions regressed but residuals remained The lower lobe lesion did not change Thoracotomy was performed and residual lesions from both lobes were removed The lower lobe lesion was found to be histoplasmosis with no tuberculosis in the segment of lung removed The upper lobe contained caseonodose tuberculosis In one case the left lower lobe was removed because of bronchiectasis Five discrete 0 3 to 0 5 cm nodules containing H capsulatum were present deep in the lung parenchyma The third case, a twenty-nine year old white man, had a left upper lobectomy for palliative treatment of bronchogenic carcinoma This patient gave a history of a spontaneous pneumothorax and large emphysematous blebs were present in the apex An 0 5 cm isolated lesion containing H capsulatum was present adjacent to the tumor Another patient gave a history of spontaneous pneumothorax on three previous occasions Wedge resection of apical emphysematous blebs was performed and a 1 0 cm partially calcified nodule containing H capsulatum was present in the subpleural region It is not believed that histoplasmosis contributed to spontaneous pneumothorax in the latter two cases

Physical examination was non contributory

Histoplasmosis

Lt Col. Thomas F Puckett M C Hattiesburg Mississippi

From the Laboratory Service Fitzsimons Army Hospital Denver Colorado

Histoplasmosis is a highly infectious mycosis caused by Histoplasma capsulatum and presents a variety of clinical pathologic and roentgenologic manifestations Although first described by Darling in Panama in 1906[1] as a protozoon the organism was later shown to be a fungus[2] and was placed in the Fungi Imperfecti by Conant in 1941[3] Skin testing surveys have shown the disease to be highly endemic in the Mississippi and Ohio Valleys and along the Appalachian mountains In certain local areas sensitivity to intradermal histoplasmin may be as high as 80 per cent of the adult population Fringe areas of lesser sensitivity extend outward from these regions[4]

It is now well established that the usual route of infection is the respiratory passage giving rise to a primary focus or primary foci within the lungs The extensive studies of Christie and Peterson[5] and Furculow and his associates[6] have shown that most histoplasmoses exist in the form of a relatively benign primary pulmonary infection Primary histoplasmosis is clinically indistinguishable from common upper respiratory infections and may be asymptomatic It usually has a short benign course and healing may result in complete resolution More frequently healing leaves one to many discrete scattered fibrotic or more often calcified lesions in one or more lobes In a small percentage of cases the primary form is progressive resulting in disseminated histoplasmosis usually characterized by involvement of all organs of the body Disseminated histoplasmosis is usually fatal and has been shown to occur more frequently at both extremes of the life span[7] The disseminated form has been covered in a number of excellent reviews[7, 8]

One characteristic of histoplasmosis is its tendency to occur in epidemics following exposure in heavily contaminated areas by groups of persons Epidemic histoplasmosis is characterized by widespread involvement of the lungs a severe and frequently prolonged illness but is rarely fatal Grayston and Furcolow[11] have recently studied thirteen epidemics and called attention to the frequency of disseminated pulmonary calcification following recovery Loosli and his associates published an extensive three year follow up of a small epidemic in one family[12]

There is increasing evidence that a chronic active form of pulmonary histoplasmosis exists that closely mimics pulmonary tuberculosis Some of these cases may be reinfection histoplasmosis As an example Johnson and Batson's case contained an apical cavity fibrotic infiltrations in the contralateral apex and scattered calcified lesions in the remainder of the lung fields[13] Sutliff and his associates[14] reviewed eleven cases of chronic pulmonary histoplasmosis called attention to the location frequently being in the upper lobes and mentioned that the process was usually fibrocavitary It is apparent that this form of the disease is intermediate between uncomplicated primary histoplasmosis and widely disseminated histoplasmosis in its course It is also this form that appears to be amenable to definitive surgical therapy[10, 15, 16]

OBSERVATIONS

The present series consists of sixty seven cases from which pulmonary tissue hilar nodes or both were removed and H capsulatum was identified in the resected material It is emphasized that in all cases the disease process is believed to have been stabilized The cases are therefore probably best classified as healed or healing primary histoplasmosis Thirty of these cases have been previously reported[17, 18] Nine patients were white women and fifty-eight were white men In all cases there was a history of residence in known endemic areas for periods of from one to twenty years Table 1 shows the patients by age group

Almost one-half of the patients were in the age group twenty-one to thirty years It should be borne in mind that patients in the

Army are predominantly young males As already mentioned disseminated histoplasmosis is more common at both extremes of the normal life span During the intermediate period of life more cases seem to occur in young adult males, probably due to more frequent exposure A similar predominance in adult males has been noted in other fungous diseases [19 20]

TABLE 1

AGE GROUPS FOR SIXTY SEVEN PATIENTS WITH PULMONARY HISTOPLASMOSIS

Age (yr)	No of Cases
18 to 20	4
21 to 30	31
31 to 40	22
41 to 50	8
51 to 60	1
61 to 70	1

The preoperative diagnoses varied greatly Many of the cases were referred to Fitzsimons Army Hospital with a diagnosis of "tuberculoma" and others as "coin lesion" of the lung A presumptive diagnosis of histoplasmosis was made in several cases that were asymptomatic, were positive reactors to intradermal histoplasmin and negative reactors to intradermal coccidioidin and tuberculin Focalized coccidioidomycosis was considered in those patients with residence in endemic areas Some patients showing multiple nodose lesions by roentgenograms and having a positive reaction to tuberculin were given a presumptive diagnosis of tuberculosis and a few underwent trial courses of chemotherapy for tuberculosis without change in the roentgenograms The diagnoses of lymphoma or sarcoid were considered in several cases showing only hilar node enlargement One patient showing a cavity was thought to have tuberculosis as a positive reaction to both histoplasmin and tuberculin was present The diagnosis of neoplasm was entertained in several patients in the older age groups In one case the pulmonary lesion was thought to be metastatic since the patient had had a malignant tumor elsewhere In no instance could the presumptive diagnosis of histoplasmosis be confirmed by cultural methods preoperatively

SYMPTOMATOLOGY

Thirty one patients in this series were completely asymptomatic and the lesions were found by routine chest roentgenograms taken for reenlistment, annual physical examinations or, in three cases, in connection with investigation of complaints other than those referable to the pulmonary system Eight patients complained of malaise, easy fatigue and weight loss varying from 10 to 25 pounds over periods up to two years Eight patients had blood-streaked sputum on one or more occasions One patient had two bouts of frank hemoptysis. Eight patients had fever (the highest 103°F) and all fevers were associated with symptoms referable to the upper respiratory tract Ten patients complained of transient pleural pain Fifteen patients estimated their onset to coincide with a rather mild but prolonged upper respiratory infection Five cases presented the typical symptoms and clinical findings of a middle lobe syndrome [21] Three of these cases are being reported in detail elsewhere [22]

In four cases the lesions were considered incidental findings in pulmonary tissue removed for the therapy of other conditions One patient had proven tuberculosis with lesions in both the right upper and right lower lobes Under prolonged chemotherapy the upper lobe lesions regressed but residuals remained The lower lobe lesion did not change Thoracotomy was performed and residual lesions from both lobes were removed The lower lobe lesion was found to be histoplasmosis with no tuberculosis in the segment of lung removed The upper lobe contained caseonodose tuberculosis In one case the left lower lobe was removed because of bronchiectasis Five discrete 0 3 to 0 5 cm nodules containing H capsulatum were present deep in the lung parenchyma The third case a twenty nine year old white man, had a left upper lobectomy for palliative treatment of bronchogenic carcinoma This patient gave a history of a spontaneous pneumothorax and large emphysematous blebs were present in the apex An 0 5 cm isolated lesion containing H capsulatum was present adjacent to the tumor Another patient gave a history of spontaneous pneumothorax on three previous occasions Wedge resection of apical emphysematous blebs was performed and a 1 0 cm partially calcified nodule containing H capsulatum was present in the subpleural region It is not believed that histoplasmosis contributed to spontaneous pneumothorax in the latter two cases

Physical examination was non-contributory

or gave non specific information as would be expected in stabilized lesions of the type removed In one case there was pleural effusion following pleural pain with slight dyspnea Thoracentesis on five occasions over a period of two years yielded up to 500 cc 's of sterile fluid with cell counts up to 1,400 per cu mm , with *95 per cent polymorphonuclear cells* Decortication of pleura and wedge resection of pulmonary tissue containing a granuloma due to H capsulatum were performed This patient had a positive tuberculin test and one cannot be certain that his effusion was due to histoplasmosis No other case in this series was known to have had pleural effusion

LABORATORY DATA

Routine examinations of the blood and urine were performed on all patients There were no significant deviations from normal Increased sedimentation rates were noted at some time in fourteen of the cases The highest was 43 mm per hour (Wintrobe)

Bacteriology Attempts to culture the organism from resected material in the present series have given disappointing results In contrast to other fungi H capsulatum is known to be fastidious in its growth habits and various investigators have reported difficulty in culturing the organism and in reproducing the disease in animals [23 24] On the other hand Ajello and Runyon[25] were able to infect mice with a single spore and there seems to be little difficulty in isolating the organism from disseminated or active primary cases when fresh sputum is used as suggested by Kurung [26] Almost all patients in the present series had preoperative cultures of sputum and gastric washings for fungi and acid fast bacilli all with negative results Three methods of culturing material from resected specimens were tried Originally scrapings from the cut surface of granulomas were emulsified and the material inoculated on culture plates Later generous portions of resected tissue from each patient were ground emulsified and plates inoculated Finally on the advice of Furcolow,[27] material from the lesions was ground and emulsions were injected intraperitoneally into several mice After fourteen days one group of animals was sacrificed, their livers and spleens were emulsified and this material was inoculated on culture plates After sixty days the remaining animals were sacrificed and similar cultures made All specimens were cultured on B H I * blood agar with streptomycin and penicillin added after the method of Howell [23] Duplicate plates were inoculated, one group incubated at room temperature, one at 37°c In addition other standard media were occasionally used

TABLE II
RESULTS OF INTRACUTANEOUS HISTOPLASMIN COCCIDIOIDIN AND TUBERCULIN IN SIXTY-THREE CASES

Histoplasmin	Coccidioidin	PPD		No of Cases
		0 00002 mg	0 005 mg	
+	+	−	+	3
+	+	−	−	4
+	+	+		8
+	−	−	+	11
+	−	+		16
+	−	−	−	20
−	−	−	+	1

Note + positive reaction − negative reaction

Specimens were also cultured for acid fast bacilli using Petragnani's medium The only cultures positive for H capsulatum were those from a cavitary lesion and from a parenchymal lesion in a case presenting a middle lobe syndrome All cultures for acid fast bacilli were negative Tissue sections stained by the periodic acid Schiff (PAS) stain[28] were positive for H capsulatum in all cases Direct smears and tissue stains for acid fast bacilli were negative in all cases

Cutaneous Reaction Table II shows the results of intracutaneous histoplasmin coccidioidin and tuberculin in the sixty three cases that were tested

There is much controversy over the value of the intradermal histoplasmin test to other than the epidemiologist It is known that as many as 50 per cent of the disseminated cases may give a negative reaction[29] when in the terminal phase It has been established that a high percentage of cases of disseminated coccidioidomycosis may not react to intradermal coccidioidin It is well known that overwhelming tuberculosis may result in anergy to tuberculin In the disseminated fungus diseases and in overwhelming tuberculosis the diagnosis is rarely a problem and may be readily con

* Brain heart infusion

firmed by direct smears and cultures of appropriate material It is in the focalized lesion that the intradermal tests are most valuable and help to guide the thinking of both clinician and pathologist In the present series one patient did not react to histoplasmin Unfortunately we were unable to repeat this test after organisms were found in the lesion Obviously if patients react to two or more antigens, the information gained is of less value to the clinician In a significant number of cases, however, (twenty in this series) patients react only to histoplasmin and the information obtained is of material value in evaluating the lesion Intradermal coccidioidin in the *usual strength* is less reliable however,[29] and negative reactions do not rule out inactive focalized coccidioidomycosis

Serologic Studies Complement fixation tests and collodion agglutination tests were performed by the Army Medical Service Graduate School on thirty patients The complement fixation test was negative in fifteen cases, was positive at 1 5 dilution in five cases 1 10 dilution in five cases, 1 20 dilution in two cases, 1 40 dilution in two cases and 1 64 dilution in one case The collodion agglutination test was negative in twenty three cases, positive at 1 10 in three cases, 1 20 in three cases, and positive at 1 40 in one case

Like other laboratory tests the serologic tests for histoplasmosis are of most value to those who have studied and understand their pitfalls and limitations At the present time new antigens are being developed and the problem of cross reaction with other antibodies is being studied A precipitin test has been developed that shows promise for use in early acute primary histoplasmosis an area where the complement fixation test has been of little value [30] Nevertheless there are some generalizations that can be made on the basis of present information and some patterns that are fairly consistent and useful for diagnosis and prognosis [31] In acute primary self limiting histoplasmosis the complement fixing antibody appears early with a peak titer of 1 80 to 1 2560 within six weeks of the onset These titers remain for only a short time and by the fourth month the titer is usually 1 20 or less In chronic histoplasmosis the titer remains higher (1 160 or more) and clinical improvement is accompanied by a gradual fall In advanced generalized histoplasmosis the titers are low or antibodies are not demonstrable Cutaneous or mucocutaneous histoplasmosis has low titer or no titer as determined by the complement fixation test Cross reaction with an antigen from Coccidioides immitis is rare, if present is of low titer (1 20 or less) and is accompanied by much higher homologous levels Sera from all types of histoplasmosis will react with antigens of Blastomyces dermatitidis, however Cross reactions in the collodion agglutination test in which histoplasmin is used as an antigen are more extensive and positive results from this test can be interpreted only as presumptive evidence of a mycotic infection The results of serologic studies of the present series are consistent with the inactive or healing lesions that were found to be present

PATHOLOGY

The intralobar location of the lesions in the sixty four cases studied were as follows right upper lobe, twelve, right middle lobe, fourteen, right lower lobe, eleven, left upper lobe, twelve, and left lower lobe, seventeen Two cases in which lesions were removed from two different lobes are included

Thoracic Cavity Hilar or mediastinal nodes only were removed in three cases Masses of nodes varied from 1 0 cm to 2 5 cm in diameter, were firm and rubbery All contained large conglomerate foci of necrotic material in which organisms could be found In four patients presenting the middle lobe syndrome the nodes about the hilum were enlarged (Fig 1) and contained necrotic foci, their enlargement compressed bronchi giving rise to symptoms of obstruction A fifth patient also had enlarged nodes compressing the middle lobe bronchus but in addition there were focal partially hyalinized necrotic lesions within the adjacent pulmonary tissue In the latter case hilar nodes were calcified, had

nodes
in an
conta
were
hilar
eleven
were

nodes represent the central component of a primary complex analogous to that seen in

FIG 1 H stoplasmos s l lar node result ng i m ddle lobe syndrome note compress on of bronchus

FIG 2 H stoplasmos s note pleural plaque keystone laminated appearance and central necrot c focus

tuberculosis and coccidio domycosis In the present series it would appear that the central component is ordinarily small In forty eight cases hilar and mediastinal nodes were described by the surgeon as normal (thirty five cases) or were not mentioned in the operative report (thirteen cases) The experience of Schulz[32] has been that the central component of the complex is frequently large He believes that this discrepancy is best explained by the fact that his cases were in infants which may represent a true primary infection resembling tuberculosis while adults with localized lesions may represent reinfection disease Another factor to be considered is the duration of the disease In Schulz s cases the disease was of only a few months duration In the present series the onset could not be determined with accuracy in many cases but a review of previous roentgenograms the presence of calcium in some lesions and the histology of the lesions lead one to believe that most lesions were of more than one year s duration at the time of removal It is probable that with stabilization and resolution of perifocal reaction the involved lymph nodes may decrease in size

In the one case with a history of pleural effusion there was fusion of visceral and parietal pleura necessitating decortication Microscopic examination of the pleura removed showed a chronic non specific fibrous pleuritis with no granulomas epithelioid reaction or necrotic foci and no organisms could be found As already mentioned the effusion was sterile One cannot therefore be certain that the effusion and pleuritis were due to histoplasmosis In six other cases fibrous adhesions to the parietal pleura or across interlobar septa were described Adhesions were small usually apical were associated with pulmonary disorder other than histoplasmosis or were present in patients reacting to intradermal tuberculin In no instance were there adhesions between parietal pleura and thickened visceral pleura over parenchymal lesions containing H capsulatum

Gross Appearance of Lesions The parenchymal lesion or lesions removed varied from 1 5 cm to 3 5 cm in diameter They were usually round occasionally ovoid and their consistency varied from stony hard to firm and rubbery The majority were located in the immediate subpleural region and approximately one-half were associated with a round oval or stellate pleural plaque that was fused to the more peripheral portion of the lesion The color of the plaque varied from a pearly pinkish gray to a light yellowish tan probably according to the age of the lesion Infrequently there were o r cm nodules within the pleura a short d stance from the main plaque representing spread by pleural lymphatics

Usually the pleural plaque extended into the main mass of the lesion to form a keystone. In the older lesions there was a tendency for

the cut surface to show a concentric laminated appearance with deposits of pigment at the interfaces between the laminations (Fig 2)

that presented a softer appearance than the remainder of the lesion Often this focus contained soft granular necrotic material in other cases it was soft but rubbery

Approximately one-half of the cases consisted of a single isolated sharply demarcated lesion such as that already described (Fig 3) Frequently there were one or more satellite lesions that varied from 0 2 cm in diameter to a size almost equal to the main lesion Occasionally there were multiple nodose discrete lesions with smaller lesions present in the pleura and along vessels and bronchioles probably representing lymphatic spread from the original lesions Where multiple lesions were present they all appeared to be of the same age

In one case the lesion was a 2 0 by 3 0 cm cavity from the left apex The pleura was thickened and puckered over the cavity and no gross bronchial communication could be demonstrated The cavity was lined by soft friable necrotic material and the adjacent pulmonary tissue was firm had a granular cut surface with prominence of the small bronchi and vessels

Microscopic Appearance The microscopic appearance of the lesions was quite uniform The larger lesions appeared to represent encapsulated foci of coagulative pneumonia in which alveolar outlines could be readily discerned except in the central necrotic portion The latter area was usually made up of amorphous material and calcification if present appeared to have started in the periphery of this focus In a few cases there was not a loss of alveolar outlines in the central necrotic focus but the material contained within the ghost outlines took the green counterstain of the PAS stain more intensely than elsewhere in the lesion Lesions with this configuration had no central calcification Organisms were always found in or immediately adjacent to these central areas never around the peripheral portion where fibrosis was marked nor were they scattered diffusely through the entire lesion

The peripheral portions of the larger foci

FIG 3 Roentgenogram of focalized histoplasmosis typical of the condition seen in many cases

were made up of dense fibrous tissue usually enclosing a thin zone of epithelioid cells There was usually a slight to moderate lymphocytic infiltration around the periphery Occasionally small bronchioles could be seen entering the peripheral fibrotic areas and in two cases cartilage could be seen incorporated within the fibrous tissue indicating previous communication with a larger bronchus

The wall of the cavitary lesion was made up of dense fibrous tissue lined by necrotic material and cellular debris A small bronchus was seen to enter the cavity and there was a patent bronchocavitary junction There was squamous metaplasia of the bronchial epithelium and it extended into the cavity to line the lumen for a short distance giving way to the necrotic material that lined the remainder of the cavity Organisms were scarce but were present in giant cells and mononuclear cells embedded in the necrotic material

The reaction within adjacent pulmonary tissue varied somewhat probably with the age of the lesion In many cases there was no reaction other than thickening of alveolar walls in contact with the fibrous portion of the lesion Other cases notably those with adjacent satellite lesions showed small foci of organized pneumonia thickening of interlobular septa vascular thickening and endarteritis and non



FIG 4 Histoplasma capsulatum in necrotic focus (PAS stain)

specific bronchitis and peribronchiolitis The most marked reaction was in the case containing a cavity in which there was a granulomatous pneumonia with lobular distribution In other cases there were small epithelioid tubercles as well as hyalinized scars representing healed necrotic foci Organisms were not found outside of the encapsulated foci or outside of the cavity nor were they found in the small epithelioid tubercles showing no necrosis There was no suggestion that the larger lesions were formed by conglomeration of smaller foci In some cases small lesions were fused but did not break down at the point of fusion

The lesions within lymph nodes were also quite uniform In general almost the entire nodal architecture was replaced by a granular amorphous necrotic mass that was irregular and appeared to have been formed by conglomeration of adjacent foci In some cases there were thin zones of fibrous tissue surrounding these lesions Organisms were present in small aggregates clusters or scattered singly in no constant region within the necrotic areas

The pleura overlying the parenchymal lesions showed dense fibrous thickening with little or no inflammatory reaction Occasionally there were encapsulated necrotic lesions containing organisms within the pleura More frequently there were round hyalinized scars in which no organisms could be identified

COMMENTS

In the past there has been a tendency on the part of some surgeons as well as pathologists to consider all isolated subpleural granulomatous lesions as tuberculomas This was based upon gross and microscopic appearance but in the absence of demonstrable tubercle bacilli It has been known since Cox and Smith s paper in 1939[33] that coccidioidomycosis may leave a residual lesion grossly indistinguishable from the so-called tuberculoma The present writer has shown that histoplasmos s may leave residual lesions that are grossly indistinguishable from either of the above lesions[17] More recently Zimmerman[34] has studied a group of thirty five so-called tuberculomas from the files of the Armed Forces Institute of Pathology He was able to find H capsulatum in nineteen cases C immitis in three cases Mycobacterium tuberculosis in six cases and no organism in seven cases It is pertinent to re-emphasize that except for the presence of the offending organisms there are no clear cut gross or microscopic characteristics by which isolated granulomas due to histoplasmosis coccidioidomycosis or tuberculosis may be separated It might be added that since we have adopted the periodic acid Schiff stain as a routine procedure in the study of pulmonary granulomas we have come to regard the classic tuberculoma as an uncommon lesion

The present writer has emphasized the difficulties in identifying H capsulatum in focalized lesions[17] The study of additional cases has shown the need for further emphasis Organisms cannot be identified in necrotic foci when sections are stained with hematoxylin and eosin as used for routine stains In our experience the periodic acid Schiff stain as modified by Kligman and Mescon[35] has proved to be a most satisfactory procedure because it preserves the morphology of the organism (Fig 4) Unfortunately it is not specific for cytoplasm and it is therefore frequently necessary to use the oil immersion lens for confirmation as concretions cellular inclusions and other

artifacts may simulate H capsulatum Fre-

preparing sections and in many cases to section all material remaining after cultures are taken

Classically H capsulatum has been described as an intracellular inhabitant and most descriptions state that it is infrequently found extracellularly That is not the case with organisms found in the central necrotic portions of granulomas In the latter regions they may be

may assume a somewhat atypical morphology in that there may be more than the usual number of elongated and distorted forms, the central mass may be smaller and the limiting membrane thinner than in organisms seen with active disease The present writer believes that these characteristics are manifestations of

older lesions that are histologically stabilized

There have been no known recurrences or post operative spread of histoplasmosis in the patients from this series The postoperative follow up has been three years in ten patients and slightly over two years in fifteen patients

SUMMARY

Pulmonary histoplasmosis is a common disease entity that achieves surgical importance mainly because of its propensity to leave residual foci that mimic tuberculosis neoplasms or other diseases

It is believed that organisms in these stabilized residual foci in most instances are non viable They commonly show atypical morphology and attempts to culture them from resected lesions has been disappointing

It is emphasized that special staining procedures and meticulous care in examination should be given all granulomatous lesions A complete history and the response to intradermal antigens should be known at the time the tissue is examined

REFERENCES

1 DARLING S T A protozoon general infection producing pseudotubercles in the lungs and focal necrosis in the liver spleen and lymph nodes. *J A M A* 46 1283–1285 1906

2

3 Histoplasma capsulatum *J Bact* 41 563 580 1941

4 PALMER C E Geographic differences in sensitivity to histoplasmin among student nurses *Pub Health Rep* 61 475 487 1946

5 CHRISTIE A and PETERSON J C Benign histoplasmosis and pulmonary calcification *Am J Dis Child* 72 460–464 1946

6 FURCOLOW M L MANTZ H L and LEWIS I Roentgenographic appearance of persistent pulmonary infiltrates associated with sensitivity to histoplasmin *Pub Health Rep* 62 1711 1718 1947

7 PARSONS R S and ZARAFONETIS C D J Histoplasmosis in man report of 7 cases and a review of 71 cases *Arch Int Med* 75 1 23 1945

8 MELENEY H E Histoplasmosis (reticulo-endothelial cytomycosis) a review *Am J Trop Med* 20 603–616 1940

9 HODGSON C H WEED L A and CLAGETT O T Pulmonary histoplasmosis review of published cases and report of an unusual case *J Thoracic Surg* 20 97 104 1950

10 HODGSON C H WEED L A and CLAGETT O T Pulmonary histoplasmosis summary of data on reported cases and report of two cases treated by [illegible]

11

1953

12 LOOSLI C G PROCKNOW J J TAUZI F GRAYSTON J T and COTES L W Pulmonary histoplasmosis in a farm family a three-year follow up *J Lab & Clin Med* 43 669–695 1954

13 JOHNSON H E and BATSON R Benign pulmonary histoplasmosis *Dis of Chest* 14 517 524 1948

14 SUTLIFF W D HUGHES T ULRICH E and BURKETT L L Active chronic pulmonary histoplasmosis. *Arch Int Med* 92 571 586 1953

15 BETTAG O L Pulmonary resection for histoplasmosis *J Thoracic Surg* 22 434 438 1951

16 CRADDOCK, W L An evaluation of the pulmonary features of systemic fungus disease *Mil Surgeon* 114 5 20 1954

17 PUCKETT T F Pulmonary histoplasmosis a study of twenty two cases with identification of H capsulatum in resected lesions. *Am Rev Tuberc* 67 453 476 1953

18 FORSEE J H PUCKETT T F and HAGMAN F E Surgical considerations in focalized pulmonary histoplasmosis *J Thoracic Surg* 26 131–139 1953

19 SMITH C E BEARD R R WHITING E G and ROSENBERGER, H G Varieties of coccidioidal infection in relation to the epidemiology and control of the diseases *Am J Pub Health* 36 1394 1402 1946

F G 4 Histoplasma capsulatum n necrot c focus (PAS sta n)

specific bronchitis and peribronchiolitis The marked reaction was in the case contain e a granulomatous In other cases there were o ubercles as well as hyalinized scars representing healed necrotic foci Organisms were not found outside of the encapsulated foci or outside of the cavity nor were they found in the small epithelioid tubercles showing no necrosis There was no suggestion that the larger lesions were formed by conglomeration of smaller foci In some cases small lesions were fused but did not break down at the point of fusion

The lesions within lymph nodes were also quite uniform In general almost the entire nodal architecture was replaced by a granular amorphous necrotic mass that was irregular and appeared to have been formed by con glomeration of adjacent foci In some cases there were thin zones of fibrous tissue sur rounding these lesions Organisms were present in small aggregates clusters or scattered singly in no constant region within the necrotic areas

The pleura overlying the parenchymal lesions showed dense fibrous thickening with little or no inflammatory reaction Occasionally there were encapsulated necrotic lesions containing organisms within the pleura More frequently there were round hyalinized scars in which no organisms could be identified

COMMENTS

In the past there has been a tendency on the part of some surgeons as well as pathologists to consider all isolated subpleural granulomatous lesions as tuberculomas This was based upon gross and microscopic appearance but in the absence of demonstrable tubercle bacilli It has been known since Cox and Smith s paper in 1939[33] that coccidioidomycosis may leave a residual lesion grossly indistinguishable from the so-called tuberculoma The presen writer has shown that histoplasmosis may leav residual lesions that are grossly indistinguish able from either of the above lesions[17] More Zimmerman[34] has studied a group of lomas from the logy eteen

He was able to fin d cases C immitis in three cases Mycobacterium tuberculosis in six cases and no organism in seven cases It is pertinent to re-emphasize that except for the presence of the offending organisms there are no clear cut gross or microscopic characteristics by which isolated granulomas due to histoplasmosis coccidio idomycosis or tuberculosis may be separated It might be added that since we have adopted the periodic acid Schiff stain as a routine procedure in the study of pulmonary granu lomas we have come to regard the class tuberculoma as an uncommon lesion

The present writer has emphasized the difficulties in identifying H capsulatum in focalized lesions[17] The study of additional cases has shown the need for further emphasis Organisms cannot be identified in necrotic foci when sections are stained with hematoxylin and eosin as used for routine stains In our experience the periodic acid Schiff stain as modified by Kligman and Mescon[35] has proved to be a most satisfactory procedure because it preserves the morphology of the organism (Fig 4) Unfortunately it is not specific for cytoplasm and it is therefore frequently necessary to use the oil immersion lens for confirma tion as concretions cellular inclusions and other

artifacts may simulate H capsulatum Frequently there are only one or two areas within a single granuloma in which organisms may be found It is therefore, advisable to use care in preparing sections and in many cases to section all material remaining after cultures are taken

Classically H capsulatum has been described as an intracellular inhabitant and most descriptions state that it is infrequently found extracellularly That is not the case with organisms found in the central necrotic portions of granulomas In the latter regions they may be found in clusters in pairs and scattered singly with only an occasional ghost of a cell outline about them In the older lesions the organisms may assume a somewhat atypical morphology in that there may be more than the usual number of elongated and distorted forms, the central mass may be smaller and the limiting membrane thinner than in organisms seen with active disease The present writer believes that these characteristics are manifestations of degeneration and that the organisms are probably not viable This concept is supported by our difficulty in culturing organisms from these older lesions that are histologically stabilized

There have been no known recurrences or postoperative spread of histoplasmosis in the patients from this series The postoperative follow up has been three years in ten patients and slightly over two years in fifteen patients

SUMMARY

Pulmonary histoplasmosis is a common disease entity that achieves surgical importance mainly because of its propensity to leave residual foci that mimic tuberculosis, neoplasms or other diseases

It is believed that organisms in these stabilized residual foci in most instances are nonviable They commonly show atypical morphology and attempts to culture them from resected lesions has been disappointing

It is emphasized that special staining procedures and meticulous care in examination should be given all granulomatous lesions A complete history and the response to intradermal antigens should be known at the time the tissue is examined

REFERENCES

1 DARLING S T A protozoon general infect on producing pseudotubercles in the lungs and focal necrosis in the liver spleen and lymph nodes J A M A 46 1283 1285 1906

2 DE MONBREUN W A The cultivation and cultural characterist cs of Darling s Histoplasma capsulatum Am J Trop Med 14 93–125 1934

3 CONANT N F A cultural study of the l fe-cycle of H stoplasma capsulatum J Bact 41 563 580 1941

4 PALMER C E Geographic d fferences in sensitivity to histoplasmin among student nurses Pub Health Rep 61 475 487 1946

5 CHRISTIE, A and PETERSON J C. Benign histoplasmosis and pulmonary calcification Am J Dis Child 72 460–464 1946

6 FURCOLOW M L MANTZ H L and LEWIS I Roentgenographic appearance of persistent pulmonary inf ltrates associated with sensitivity to histoplasmin Pub Health Rep 62 1711 1718 1947

7 PARSONS R S and ZARAFONETIS C. D J Histoplasmosis in man report of 7 cases and a review of 71 cases Arch Int Med 75 1 23 1945

8 MELENEY H E Histoplasmos s (reticulo-endothelial cytomycos s) a review Am J Trop Med 20 603–616, 1940

9 HODGSON C H WEED L. A and CLAGETT O T Pulmonary histoplasmos s review of published cases and report of an unusual case J Thoracic Surg 20 97–104 1950

10 HODGSON C. H WEED L A and CLAGETT O T Pulmonary histoplasmosis summary of data on reported cases and report of two cases treated by lobectomy J A M A 145 807–810 1951

11 GRAYSTON J T and FURCOLOW M L. The occurrence of histoplasmosis in epidemics—epidemiological studies Am J Pub Health 43 665–676 1953

12 LOOSLI C G PROCKNOW J J TAUZI F GRAYSTON J T and COMBS, L W Pulmonary histoplasmos s in a farm family a three-year follow up J Lab & Clin Med 43 669–695 1954

13 JOHNSON H E and BATSON R Benign pulmonary histoplasmosis Dis of Chest 14 517–524 1948

14 SUTLIFF W D HUGHES F ULRICH E and BURKETT L L Active chron c pulmonary histoplasmos s Arch Int Med 92 571 586, 1953

15 BETTAG O L. Pulmonary resection for histoplasmos s J Thoracic Surg 22 434 438 1951

16 CRADDOCK, W L An evaluation of the pulmonary features of systemic fungus disease Mil Surgeon 114 5–20 1954

17 PUCKETT T F Pulmonary histoplasmosis a study of twenty two cases with identif cation of H capsulatum in resected lesions, Am Rev Tuberc 67 453 476, 1953

18 FORSEE J H PUCKETT T F and HAGMAN F E Surg cal cons derations in focal zed pulmonary histoplasmosis. J Thoracic Surg. 26 131–139 1953

19 SMITH C. E BEARD R R WHITING E G and ROSENBERGER, H G Varieties of coccid o dal infection in relat on to the ep demiology and control of the diseases Am J Pub Health 36 1394 1402 1946.

20 SCHWARTZ J and BALM, G L Blastomycosis Am J Clin Path, 21 999–1029, 1951
21 GRAHAM, E A, BUFORD, T H and MAYER, J A Middle lobe syndrome Postgrad Med, 4 29–34, 1948
22 ADLER, R H, MANTZ, F A, JR and WARE, P F The middle lobe syndrome and its relationship to certain aspects of middle lobe disease To be published
23 HOWELL, A, JR The efficiency of methods for the isolation of Histoplasma capsulatum Pub Health Rep, 63 173–178 1948
24 PRIOR, J A, SASLAV S and COLE C R Experiences with histoplasmosis Ann Int Med, 40 221–244 1954
25 AJELLO L and RUNYON, L C Infection of mice with single spores of Histoplasma capsulatum J Bact, 66 34 40, 1953
26 KURUNG J The isolation of Histoplasma capsulatum from sputum Am Rev Tuberc, 66 578–587, 1952
27 FURCOLOW M L Personal communication
28 KLIGMAN, A M and MESCON, H The periodic acid Schiff stain for the demonstration of fungi in animal tissue J Bact, 60 415 1950
29 PUCKETT T F Hyphae of Coccidioides immitis in tissues of the human host Am Rev Tuberc, 70 320–327, 1954
30 SALVIN, S B and FURCOLOW, M L Precipitins in human histoplasmosis J Lab & Clin Med, 43 259–274 1954
31 CAMPBELL, C C and BINKLEY, G E Serologic diagnosis with respect to histoplasmosis coccidioidomycosis and blastomycosis and the problem of cross reactions J Lab & Clin Med 42 896–906, 1953
32 SCHULZ D M Histoplasmosis a statistical morphologic study Am J Clin Path, 24 11–26, 1954
33 COX A J and SMITH, C E Arrested pulmonary coccidioidal granuloma Arch Path, 27 717–734, 1939
34 ZIMMERMAN, L E The demonstration of histoplasma and coccidioides in so-called tuberculomas of the lung Arch Int Med To be published

50

Surgical Considerations in Coccidioidomycosis

BERT H COTTON, M D, GEORGE A PAULSEN, M D *Los Angeles, California* AND
J W BIRSNER M D, *Bakersfield, California*

COMPLICATIONS of pulmonary coccidioidomycosis present a problem of national interest, for the disease is now widely spread in our population During World War II the Armed Forces had to place millions of troops in the endemic areas of the United States Fully 25 per cent of reported infections occurred at that time among military personnel [1] Residual complications among veterans are so widespread that most of the Veterans Administration hospitals have written papers on the problems of coccidioidomycosis—complicated, uncomplicated and with coexisting disease In addition, many installations in endemic areas were reopened during the Korean conflict

Other factors besides the military have contributed to the increase Rapid postwar expansion of population in Los Angeles County, a region of minor endemicity, has resulted in a immitis Today over the Valley's four lane highways there is a continual populous movement of business personnel, truckers vacationers and migratory laborers

Southern portions of those Southwestern states which border on Mexico are endemic areas and in nearly all of these there have been similar expansions in population As a result of all these population shifts and of increased transportation facilities the disease may today be seen anywhere in the United States or, for that matter, anywhere in the world [1]

An idea of the increase in coccidioidomycosis is furnished by the fact that from 1892 (the year Wernicke first reported the disease) until 1936 there were only 400 odd cases reported in the entire world literature [2] On the other hand one of us (J W B) has reviewed 750 cases of coccidioidomycosis and nearly all of them were seen within the past decade in Kern County California

Complications of pulmonary coccidioidomycosis which may occur as sequelae of the acute infection were stressed by us in a previous publication [3] These complications are (1)

TABLE I
RESECTION IN PULMONARY COCCIDIOIDOMYCOSIS

Type of Operation	Melick's Modified Series	Authors Series
Pneumonectomy	4	14
Lobectomy	56	41
Segmental lobectomy	20	35
Pulmonary resection with decortication	7	9
Decortication	1	1
Totals	88	100

of the complications of coccidioidomycosis create diagnostic problems for the thoracic surgeon

The first significant statistical data on surgery in pulmonary coccidioidomycosis were compiled by Melick,[4] who polled all members of the American Association for Thoracic Surgery as well as a large group of other physicians who might have had occasion to perform excisional surgery in treating this disease Dr Melick's collected series modified by withholding from it the data we contributed in our previous paper, is now compared to our current series in tabular form (Table I)

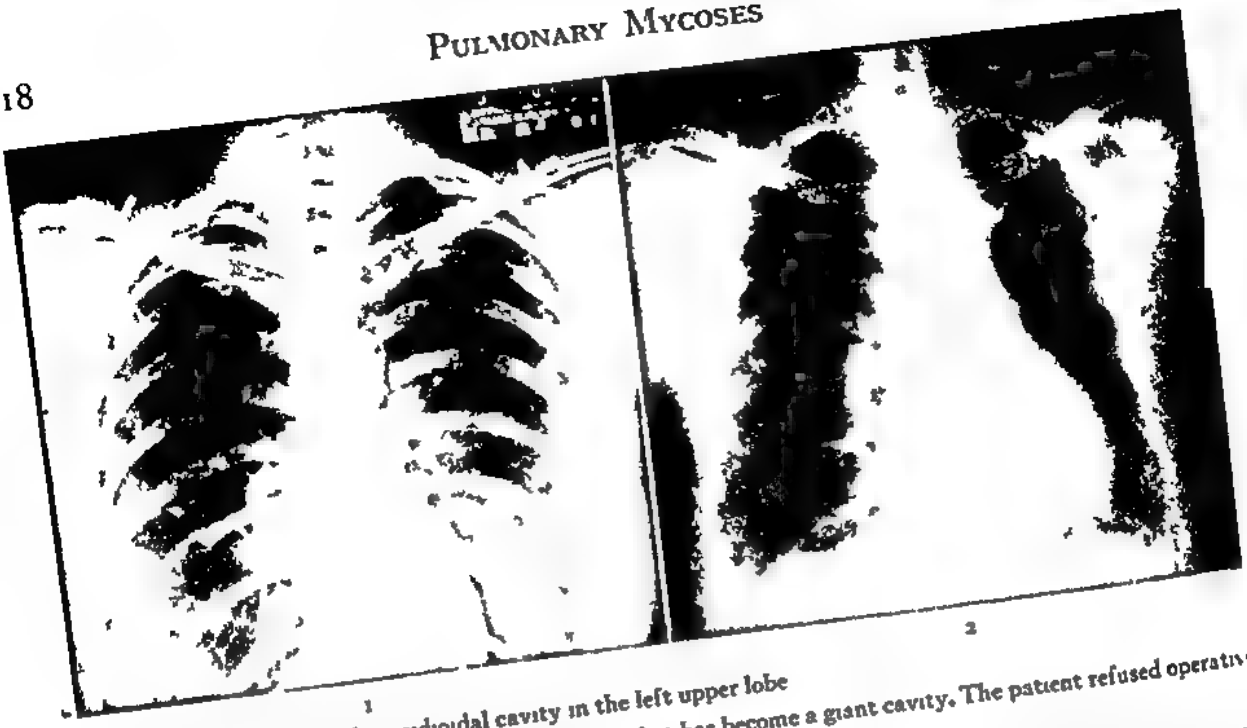

1 2

FIG 1 Typical thin walled coccidioidal cavity in the left upper lobe

FIG 2 Chronic coccidioidal cavity in left upper lobe that has become a giant cavity. The patient refused operative treatment and died one year later of hemorrhage

In the 750 cases of pulmonary coccidioidomycosis that were reviewed 100 patients underwent surgical treatment From medical observation of these 100 cases, endoscopic examinations surgical findings and reviews of pathologic specimens, we have evolved the following indications for operation (1) giant cavity, (2) secondarily infected cavity, (3) check valve cavity, (4) ruptured cavity (pleural effusion, spontaneous pneumothorax, empyema, bronchopleural fistula, non expansile lung), (5) coccidioma (6) hemoptysis (continued, severe) (Figs 1 to 6)

COCCIDIOIDAL CAVITIES

Most cavitations are "cyst like" and silent on auscultation The acute phase of the cavity appears with the disease's parenchymal infiltration and disappears with resolution of the infiltration The cavity is then chronic in nature and persists without a zone of fibrosis

Persistent pulmonary cavities cause the greatest possible concern to the attending physician from the standpoint of diagnosis prognosis and treatment Collapse therapy frequently fails Our postsurgical examinations of specimens showed such failures to result from two conditions In the first of these the cavity, although appearing thin walled roentgenographically, was actually enclosed by a dense fibrinous wall that collapsed with difficulty even when subjected to direct manual pressure In the second condition dense adhesions joined the cavity wall to the thoracic cage We therefore believe that the treatment of choice is the surgical removal of all existing cavities otherwise many distressing complications and symptoms may be expected to occur

If the cavity is under constant medical management the onset of such complications and symptoms may be postponed for years How ever, the word *postponed* is used advisedly Even under the best medical management it is not at all likely that the complications will be prevented

The coccidioidal cavity parallels the problem of lung abscess or bronchiectasis Patients with one of these latter conditions must be kept under constant medical care, with vigorous treatment during upper respiratory infections and usually they must receive a daily small dose of antibiotic Similarly, the persistent coccidioidal cavity must be kept under constant symptomatic and radiographic observation It will eventually be seen to enlarge Complications will then shortly ensue and resection will be necessary

The fear that an operation will stimulate dissemination is one of the principal reasons for delaying resection In this connection it is worth pointing out that dissemination occurs in a ratio of 1 400 cases of all types in the

3

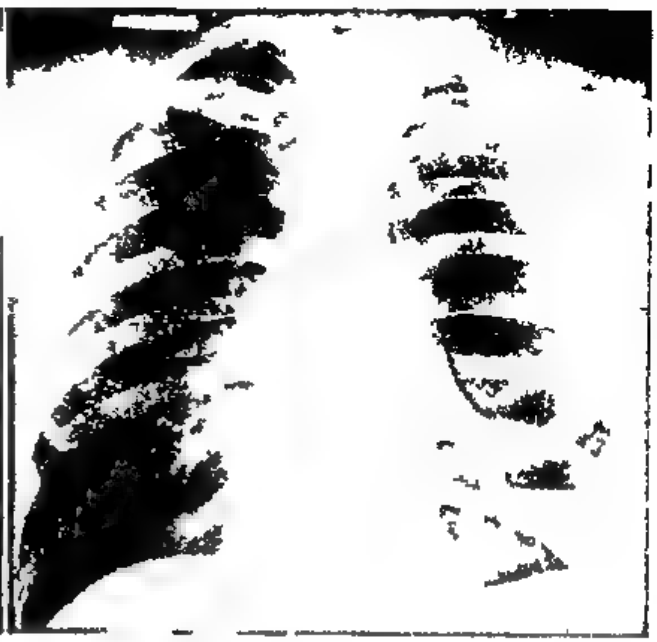

4

FIG 3 A co n les on n the r ght upper lobe wh ch proved to be a cocc d oma

F G 4 Left spontaneous pneumothorax w tl pers stent bronchopleural f stula and m xed empyema

5

6

F G 5 Preoperat ve bronchogram show ng a large cocc dio dal cav ty in the r ght lower lobe

FIG 6 Case of pulmona y cocc d m domycos s wh ch could be confused w th bronchogen c carc noma of the r ght h lum

white male (of 1 100 cases in the Negro male) and least often of all in the female unless she contracts the fungus in the last trimester of pregnancy[8]

The problem of delay as opposed to operat on brings us back then to the complications which indicated operation

1 *Giant Cavity* We have arbitrarily desig nated any cavity larger than 5 cm as a giant cavity A cavity of this size is obviously in need of surgical treatment because of the in creased possibility of hemoptysis or of rupture with empyema or of other severe compl cations

2 *Infected Cavity* We bel eve that the cause of a cavity s progressive enlargement is secondary infection The size and rapidity of

cavity formation is directly proportional to the degree, extent and duration of infection Secondary infections are a common finding and frequently they mask the primary infection

3 *Cavity with Check valve Mechanism* The check valve mechanism has been explained as arising in either of two ways (1) as made possible by the membrane formed by secondarily infected cavities, and (2) as being caused by the endobronchial disease that is present in the draining bronchus In our opinion it is this mechanism which causes a cavity to rupture and bring about subsequent complications Thus when serial roentgenograms reveal a cavity to be in the process of enlarging, an emergency operative procedure is indicated in order to prevent cavity rupture

4 *Ruptured Cavity* The various complications which the ruptured cavity can cause are

Pleural effusion This is the most common complication It occurs as the result of rupture of a small subcortical abscessed cavity The effusion is treated by aspiration, however, if a thickened pleura develops surgical intervention is necessary

Spontaneous pneumothorax This complication occurs after the rupture of a cavity having a residual large, open bronchus One can expect associated empyema Immediate operative treatment is recommended to close the fistula and to clean the pleural space Decortication as well as closure of the fistula will be necessary

Empyema The sooner the empyema undergoes surgical treatment, the fewer technical difficulties will be encountered In cases of empyema which have persisted for a number of months, a great deal of parenchymal damage will have been caused by secondary infection This not only increases the operating time but also lowers the patient's pulmonary reserve since increased amounts of pulmonary tissue will have to be sacrificed

Bronchopleural fistula In the treatment of bronchopleural fistula—necessarily an operation in an infected field—we have used an extrapleural type of decortication and a wedge removal of the cavity All patients so treated have recovered without complications

Non expansile lung Two causes are responsible for this condition namely, pleural effusion which has not been adequately treated and delay in the surgical treatment of a ruptured cavity

5 *Coccidioma* A coccidioma is a form of focalized lesion of the pulmonary infection and can be either a true coccidioma or a pseudococcidioma The pseudococcidioma is a small cavity filled with inspissated material The coccidioma is a granulomatous lesion of extreme importance, for it falls into the group of so-called coin lesions It is important not only to the radiologist in differentiating from carcinoma on roentgenograms but also to the surgeon in differentiating from carcinoma on the operating table In addition, unless the pathologist is aware of coccidioma as a diagnosis, he is apt to designate the specimen a granulomatous lesion or a tuberculoma Any granulomatous lesion of undetermined etiology should be treated as a suspected coccidioma and the material subjected to culture, animal inoculation and careful scrutiny in order to reveal the spherules of C immitis

The three indications for surgical treatment of coccidioma are (1) when the lesion falls into the group of coin lesions and must be removed for differential diagnosis, (2) when the lesion shows any degree of enlargement for this is a sign that a secondary infection is brewing, (3) when the coccidioma cavitates creating the potential of a secondarily infected cavity

6 *Hemoptysis* This is our only indication for surgery that is a symptom rather than a pathologic finding It is a highly important indication for when hemoptysis occurs there is always the chance of a life threatening situation as the result of erosion into one of the larger blood vessels We are familiar with one case in which a large cavity eroded in this manner, causing massive hemoptysis and the subsequent death of the patient

SURGICAL CONSIDERATIONS

Once the acute phase of the disease has passed risk of dissemination following surgery is almost negligible In no instance have we performed surgery for any focalized coccidioidal infection until a full six months or more following the acute stage of the infection We have seen cavities close during the six month period, but we have never seen a cavity close after six months In view of this, we believe there should be a six month interval between resolution of the acute stage of the disease and surgical treatment

Our preoperative work-up includes localization of the cavity in an attempt to determine whether or not localized resection will be possible or whether lobectomy will have to be performed A bronchogram is always done next, for in a great many cases we have found bronchiectasis associated with the cavity or within the area of the infection We believe that pulmonary coccidioidomycosis is primarily an endobronchial disease, and consequently the chances are good of bronchiectasis being present Following the bronchogram we wait six weeks before scheduling the patient for the operative procedure

Operation is carried out in the routine fashion of other pulmonary resections, such operations being performed as lobectomy and segmental or wedge resection depending upon the location of the lesion Lobectomies are performed by the individual ligation technic as it is used by most thoracic surgeons Sometimes in performing wedge resection lung tissue around the cavity is found to be infected and the zone of involvement of the lung is greater than the immediate area of the actual cavity In this case, instead of the wedge resection a segmental resection is performed or a lobectomy This is done since mattress sutures through infected lung tissue would almost surely result in a bronchopleural fistula We would rather sacrifice greater amounts of lung tissue than run such a risk

After a wedge resection the resected lobe is closed in the manner of a fan Closure is brought about, in both infected and non infected cases, by a mattress suture which interlocks with the lung tissue, giving the silk suture an appearance similar to the links of a chain We have found this type of pulmonary tissue closure to be a most effective one even in the treatment of infected pleural cavities

In all cases of the series diagnosis was confirmed either pre- or postoperatively by one or more of the following laboratory procedures complement fixation test, sputum examination, culture, animal inoculation or histologic examination

There has been considerable discussion in the recent literature in regard to complications following operative treatment for coccidioidal infections Few complications occurred in our series, and we have had excellent results in treating those complications which did occur This makes us wonder if there are not other circumstances—possibly in the surgical technic, in the evaluation of the case or in some other factor—which may explain the complications that are reported to follow operative treatment

All of the patients did well in the series except three There was one postoperative death, and in two patients complications followed treatment Further cavities developed in these two patients and secondary operations were performed One patient's second cavity was of tuberculous origin The other patient's was coccidioidal, apparently either a small cavity was missed at the time of surgery or a small coccidioma "shelled out" to become a large cavity These two patients, like the others in the series, are now back at work

COMMENTS

It is occasionally easier to make a diagnosis of coccidioidomycosis in vivo than by examination of the pathologic specimen The coccidioidal cavity allows recovery of spherules from the sputum during the acute phase of the disease, but it may lose its identity in the presence of a superimposed infection of tubercle bacilli or pyogenic organisms "Masking" of this type may explain the poverty of data in the literature on excisional surgery in the treatment of pulmonary coccidioidomycosis, for it often happens that a case preoperatively considered to be coccidioidomycosis is reported instead by the pathologist as "granuloma, etiology unknown"

The recoveries without complications which followed the operations in this series have been remarkable Decortication, for instance, was performed in the presence of an active coccidioidal empyema and there was complete reexpansion of the lung, the wound healing by primary intention These results led us to conclude that suitability for operation is a determination that can be made without regard to the etiology of the pathologic condition and without regard to such problems as whether or not the disease is in a dormant or an active phase

It has long been known that in cases which involve an extremity alone, amputation can arrest the disease and save the life of the patient In a somewhat analogous manner, resection for pulmonary coccidioidomycosis can be used to prevent death and is effective in arresting the disease process Resection

does not cause dissemination to the skeletal and nervous system, and it may even prevent dissemination Postponement of surgery for fear of dissemination does not seem justified

Consequently we believe that the conclusion of our preliminary paper ■ now established Insofar as the surgeon ■ concerned in his determination of treatment, all laboratory findings should be disregarded, evaluation being made of the pathologic lesions alone

SUMMARY

1 The findings are presented of a series of 100 cases of pulmonary coccidioidomycosis treated by surgical methods

2 Once important only in endemic areas, pulmonary coccidioidomycosis is today a problem of national importance

3 A review ■ given of the indications for surgery

4 The coccidioidal cavity is, like lung abscess or bronchiectasis, an operable condition Delay of surgery is dangerous

5 The risk of operation causing dissemination is negligible

6 Attention ■ called to the evaluation of the pathologic specimen, particularly "granuloma, etiology undetermined"

7 The rationale for surgery should be based on mechanical considerations, completely disregarding the etiologic agent, C immitis, or other co-existing pulmonary fungi or tuberculosis

REFERENCES

1 TRIMBLE, H G Coccidioidomycosis a review *Dis of Chest*, 20 588-610, 1951

2 STITT, E R, CLOUGH, P W and CLOUGH, M C Practical Bacteriology Haematology and Animal Parasitology, 9th ed., p 214 Philadelphia, 1938 Blakiston Co

3 COTTON B H and BIRSNER, J W Surgical treatment in pulmonary coccidioidomycosis preliminary report of thirty cases *J Thoracic Surg* 20 429-442, 1950

4 MELICK, D W Excisional surgery in pulmonary coccidioidomycosis *J Thoracic Surg*, 20 66-71 1950

5 SMITH C E Diagnosis of pulmonary coccidioidal infections. *California Med*, 75 387-391, 1951

XIX. PARASITIC DISEASES

51

Animal Parasitic Infections

RODNEY C. JUNG, M.D., *New Orleans, Louisiana*

[illegible] *Tohn and Tulane Visiting*

WHILE in most parts of the United States bronchopulmonary disease of parasitic etiology is uncommon, it occurs frequently elsewhere Parasitic involvement of the lungs should be looked for particularly in those regions abounding in parasitic infections of other organs and systems, such as tropical countries especially and those with poor sanitation or crowding

Cases of autochthonous infection with certain of the animal agents do not occur in the United States (e g, paragonimiasis), and with others only infrequently (e g, malaria) On the other hand ascariasis, strongyloidiasis, hookworm infection and visceral larva migrans are prevalent in certain parts of this country, particularly the Southeastern states, and must be considered in the diagnosis of pulmonary disease there Amebiasis and toxoplasmosis, both of which are capable of presenting as bronchopulmonary disease, are cosmopolitan in distribution

For the present discussion parasites have been classified as Protozoa or as Metazoa, the latter including flatworm and roundworms

PROTOZOA

The protozoan bronchopulmonary diseases have in common one important feature The infective organism multiplies within the body of the host Infection thus may spread from one part of the body to another in the fashion of bacterial infections Several protozoan infections, including malaria, visceral leishmaniasis, toxoplasmosis and Chagas' disease, are characteristically systemic, and the pulmonary manifestations are but a facet, albeit sometimes an important one, of the entire disease In visceral leishmaniasis and Chagas' disease pulmonary involvement, though demonstrable by the pathologist, rarely attains clinical importance On the other hand, malaria and toxoplasmosis have both been recognized to cause serious lung disease

Malaria That pneumonia occurs more frequently in malarious patients than in the general population has been shown, but this may be explained in several ways It may be related to the rainy season of tropical countries which brings a peak incidence of both malaria and pneumonia for different reasons; the debilitating effect of the malaria may increase the susceptibility of the patient to pneumonia, or the malaria may directly cause the lung disease In falciparum malaria the pneumonitis is more directly related to the parasitic infection than in vivax or quartan, for Plasmodium falciparum makes the erythrocytes sticky, causing them to agglutinate and to adhere to vessel walls, thereby totally or partially occluding small vessels The anoxic endothelium allows the extravasation of blood and fluid manifested grossly as petechial hemorrhages and edema Applebaum and Shrager (1944) classified pneumonia complicating malaria as viral, bacterial or malarial [illegible] administration of antibiotics or sulfonamide drugs to attack secondary bacterial infection if present

The most convenient effective therapy of malaria is with amodiaquin (camoquin®) since a single dose of three tablets totalling 600 mg will usually suffice to end an attack. This may be repeated the next day Chloroquine diphosphate (aralen®) may be given in a dose of 1 gm immediately on diagnosis, 0 5 gm after six hours and 0 25 gm. twice a day thereafter for two days In the case of falciparum infec-

tion therapy of the attack is sufficient In vivax malaria there is a risk of relapse In selected cases primaquine diphosphate may be given in a dose of 26 mg three times a day for fourteen days to kill the exoerythrocytic forms This will also destroy gametocytes the form of the parasite infective for mosquitoes

Toxoplasmosis In contrast to the systemic vascular disease in falciparum malaria there is a systemic reticuloendotheliosis in toxoplasmosis Early toxoplasmosis is an acute generalized infection In adults as well as infants it may present as a pneumonitis In two fatal cases (Pinkerton and Henderson 1941) microscopic examination of the lungs showed a severe interstitial pneumonitis cuboidalization of the alveolar lining and interstitial organization The alveoli and bronchioles contained fibrinopurulent exudate In both instances the clinical picture was one of an atypical pneumonitis and death was apparently due to respiratory failure

Diagnosis in such acute fulminating cases is usually based on postmortem demonstration of the causative organism in the tissues because the possibility of the infection is not considered earlier The infection can be diagnosed during life in several ways Biopsy of the skin lymph nodes bone marrow liver or spleen may reveal bodies compatible with Toxoplasma but definite diagnosis on purely morphologic grounds is difficult Inoculation of mice or hamsters with blood bone marrow splenic puncture material cerebrospinal fluid or sputum is a relatively sensitive procedure although care must be taken to rule out latent infections in the animals The Sabin Feldman (1948) dye test may be used to demonstrate a rising titer of antibodies against the organism The intradermal and complement fixation tests are likely to be negative in the early stage of the disease

A satisfactory treatment for toxoplasmosis has not yet been developed Sulfonamides and pyrimethamine have been found to have a beneficial but not curative effect in experimental animals

Amebiasis In amebiasis the disease is not systemic but local The presence of Entamoeba histolytica in the chest may be assumed always to be secondary to intestinal infection A lung abscess rarely may be the result of metastasis via the blood streams from sites of infection in the colon or liver More commonly a liver abscess ruptures through the diaphragm and into the right lung causing a lung abscess or hepatobronchial fistula or into the pleural space causing amebic empyema (Ochsner and DeBakey, 1936) Frequently an amebic liver abscess will provoke a right diaphragmatic pleurisy and serosanguineous effusion without actual amebic infection above the diaphragm

The characteristic signs and symptoms of amebic liver abscess are loss of weight fever hepatomegaly hepatic pain and tenderness and leukocytosis Anteroposterior and lateral x rays of the chest show a bulge in the right leaf of the diaphragm which is usually anterior and medial On fluoroscopy the right leaf of the diaphragm usually does not move with respiration Absence of one or more of these signs and symptoms is not grounds for rejection of the diagnosis History of precedent diarrhea is usually unobtainable and frequently no amebas are demonstrable in the stool Extraintestinal amebiasis is rare before the age of puberty and is much commoner in men than in women

One of the principal causes of delayed diagnosis of amebic hepatic abscess is the presence of misleading pulmonary symptoms associated with an effusion of the right pleural space that obscures the level and contour of the diaphragm The commonest incorrect diagnoses noted by the writer have been post pneumonic empyema and carcinoma of the lung metastatic or bronchogenic with pleural involvement Rupture of an amebic liver abscess into a bronchus may produce pneumonia of acute onset with cough productive of the character istic anchovy sauce pus which may be mistaken for the bloody sputum of early lobar pneumonia A more carefully taken history may reveal in such a case that before the acute onset of pleuritis pain and cough there had been a period of tenderness and discomfort in the right upper quadrant of the abdomen over a period of several days or weeks Examination of the sputum may reveal the presence of trophozoites of E histolytica When a hepatobronchial fistula is present x ray will frequently show a subdiaphragmatic collection of air

Amebic abscess should be considered in every case of disease of the base of the right lung with right pleural effusion not because amebic disease of pleura and lungs is very common but because it can be cured if properly treated and

FIG 1 Amebic abscess of liver with serosanguineous pleural effusion not containing amebas *A*, Before thoracentesis level of diaphragm obscured *B* After thoracentesis diaphragm found to be greatly elevated *C*, After aspiration of liver abscess lateral view showing large abscess with fluid level Characteristic pus containing amebas was obtained from the abscess

will kill if not The error of surrendering the patient to a diagnosis of metastatic malignancy is particularly grievous

Diagnosis is established by demonstration of trophozoites of E histolytica in sputum pleural fluid or aspirate from subphrenic or hepatic abscess This should be done only after the patient has had a day or two of treatment as described below Even if trophozoites are not found in pus aspirated from the liver, [illegible] usually the case, the characteristic anchovy appearance of the material is adequate for the diagnosis This grayish red to chocolate-colored fluid is not accurately called "pus" since it contains relatively few neutrophils but consists of blood and digested host tissue

Treatment is by administration of chloroquine diphosphate or emetine or both Chloroquine diphosphate [illegible] given in a dose of 0 5 gm twice a day for two days then 0 25 gm twice a day for twenty one days If response to the chloroquine is not evident within the first week, treatment with emetine hydrochloride is justified This is given in deep subcutaneous injections in a dose of 1 mg per kg of weight per day for ten days The dose on no single day is to exceed 65 mg and the drug should not be given more than ten days Because of its toxic effect, particularly on the heart muscle, the patient should be at bed rest throughout emetine therapy and for a few days thereafter Aspiration (closed drainage) of the hepatic abscess is usually helpful and sometimes necessary for cure When secondary bacterial infection exists, as it always does if a bronchus has been entered, broad spectrum antibiotics are indicated together with the amebicidal drugs A course of therapy for intestinal amebiasis, e g, bismuth glycolylarsanilate (milibis®) 0 5 gm three times a day for eight days, should always be given concurrently even if amebas are not demonstrated in the stool

METAZOA

Metazoan parasites are the source of powerful allergens Those species which spend all or part of their lives in the tissues or in sites where these substances may be absorbed, characteristically produce a picture of allergic sensitization in their hosts The deleterious effect of the sensitization reaction is greater than the damage caused by mechanical or toxic means A relatively light infection may thus be fatal because of a profound host reaction

The types of reaction seen in metazoan infections vary There may be atopic reactions with urticaria, bronchiolospasm bronchial edema, and asthmatic dyspnea Fleeting lung shadows accompanied by peripheral eosinophilia (*cf* Loeffler's syndrome) may be seen Granulomatous lesions may be produced in various organs, probably at sites containing the parasites or [illegible] concentration of their products These usually contain large numbers of eosinophils and Charcot Leyden crystals Jacques (1952) has suggested that chronic infection with larval helminths may be a cause of sar-

FIG 2 Patch of pneumonia n r ght base in case of Loeffler s syndrome presumably due to m grat ng Ascaris larvas

FIG 3 X ray f ndings in case of bronchopulmonary strongylo d as s due to adult worms in bronch (Cour tesy of Dr C M Gor lon U S P H S Hosp tal Carville La)

coidosis Chronic and possibly subacute infec tion with some metazoan parasites may cause an allergic angiitis systemic in distribution

Roundworms The life cycles of Strongy loides stercoralis Necator americanus Ancylo stoma duodenale and Ascaris lumbricoides are all characterized by a migration of larvas through the lungs. Strongyloides and the hookworms Necator and Ancylostoma enter the body of the host through the skin pene-trate into subcutaneous vessels and are carried to the lungs The larvas are filtered out in the capillary bed of the lungs and rupture into the alveolar spaces Thereafter they migrate up the bronchi and trachea to the pharynx are swallowed and proceed to develop into adults in the small intestine The tissue reaction to worms passing through the lungs plus the me-chanical trauma caused by them produces pneumonitis Strongyloides larvas may become infective before leaving the bowel or while adherent to the perianal skin These may pene trate intestinal mucosa or skin to produce hyperinfection Therefore in strongyloidiasis there may be repeated episodes of pneumonitis related to successive swarms of hyperinfecting larvas In ascariasis the portal of entry is the mouth When eggs containing Ascaris larvas are swallowed they hatch in the small intes tine the larvas penetrate the bowel wall into venules and are carried through the liver to the lungs where the migration is completed as described previously for Strongyloides and the hookworms

The great majority of cases of pneumonia due to the above worms are subclinical although they may produce striking x ray shadows In others the symptoms are mild consisting mostly of a dry cough Symptoms may be severe in a few cases when the number of larvas is very large or sensitization is par ticularly great Symptoms may be asthmatic or pneumonic depending on whether the bronchospastic or exudative reaction pre-dominates Komo (1902) observed prostrating pneumonia with dyspnea and hemorrhagic sputum in a volunteer who experimentally swallowed an immense dose of Ascaris eggs

Similar pulmonary manifestations have been observed in visceral larva migrans (due to infection with larvas of the dog ascarid Toxo-cara canis) and creeping eruption (cutaneous infection with larvas usually of a hookworm normally infecting dogs and cats Ancylostoma

braziliense) In one fatal case of visceral larva migrans death was due to respiratory failure precipitated by a systemic eosinophilic granulomatosis (Brill et al 1953)

Experimental evidence in dogs has shown that Strongyloides instead of passing on to the intestine may reach the adult state and oviposit in the bronchial epithelium (Faust 1933) Several human cases probably representing the same phenomena have occurred In this condition there is a chronic bronchitis and surrounding it a pneumonitis possibly related to the activities of the migrating larvas The x ray shadow is therefore relatively fixed rather than fleeting Eosinophilia may be absent If rhabditoid larvas (not filariform) are found in the sputum the diagnosis is established

The pneumonitis produced by migrating larvas of Ascaris Ancylostoma Necator and Strongyloides can be treated symptomatically with bronchospasmolytic and antihistaminic drugs Antibiotics may be given to combat or prevent secondary bacterial infection Cortisone will terminate the allergic reaction but is recommended only for the rare patient who is critically ill because of his pulmonary disease There is no method of attacking the larval worms in the lungs Treatment of the intestinal infection in each case is advisable

Ascariasis may be treated with 1 to 3 gm of piperazine citrate daily for one or two weeks In case of failure crystoids of hexylresorcinol should be used in single dose treatments of 0 6 to 1 0 gm Crystoids must be swallowed whole or burns about the mouth will be produced

Hookworm infection of the intestines may be treated with tetrachlorethylene in soft gelatin capsules It is preferably given in the morning after an overnight fast in a dose of 0 05 to 0 06 cc per pound of body weight with a maximum dose of 4 0 to 5 0 cc No purge is necessary (Carr et al 1954)

Creeping eruption due to cutaneous infection with hookworm larvas is best treated by freezing the advancing end of the serpiginous lesion with dry ice or ethyl chloride spray Several treatments usually are necessary

Intestinal strongyloidiasis is treated by the administration of gentian violet medicinal in enteric-coated tablets (Seal Ins Seal Ins Laboratories) timed to release in one and one-half hours The most effective course has been found to be one in which the tablets are given three times daily one hour before meals for four days On the first day each dose amounts to 1 gr but the dose is increased by 1/2 gr each day so that on the fourth day 2 1/2 gr is given three times Although this treatment is the most effective that has been observed by the writer only 50 to 60 per cent of patients are freed of their infections Most of the other patients are improved symptomatically and their infections are apparently reduced There is no way of attacking Strongyloides in the lungs but frequently pulmonary signs and symptoms will subside with treatment of the intestinal infection when the pulmonary manifestations are attributable to migrating larvas in hyperinfection

In trichinosis and filariasis transient pulmonary infiltration and occasionally hemoptysis may occur as part of the systemic disease but these are of no great clinical significance Of greater importance is the damage done by the Trichinella larvas to the muscles of respiration which may lead to asphyxia or hypostatic pneumonia

Trichinosis is acquired by the ingestion of raw or poorly cooked meat (usually pork) containing encysted larvas of T spiralis Ordinarily by the time the diagnosis is made no specific treatment is possible, although piperazine may reduce the eventual severity of the infection by eliminating some of the adult worms if the diagnosis is made early Cortisone and ACTH are of value in ameliorating the more severe reactions The disease is best attacked by prevention This is accomplished in the home by thoroughly cooking meat before consumption and by commercial packers by freezing or irradiating it with x rays In endemic areas swine should not be fed garbage or meat trimmings unless it is cooked

Schistosomiasis is infection with one of the blood flukes Schistosoma haematobium S mansoni or S japonicum S haematobium causing vesical schistosomiasis, is found in many foci scattered over Africa with particularly high incidence in the Nile Valley Portugal and in the Middle East S japonicum causing intestinal and hepatic schistosomiasis is found predominantly in China Japan and the Philippine Islands S mansoni also causing intestinal and hepatic schistosomiasis is found in the Nile delta in the African Tropics and in Brazil Venezuela Dutch Guiana and

the West Indies Remarks will be confined to schistosomiasis mansoni since it is becoming an increasingly more important problem in this country with the influx of Puerto Ricans into several of our large cities

The schistosomes require an intermediate host, an aquatic snail, in the body of which the parasites multiply greatly Free swimming larval forms (cercarias) are discharged from the snail The human being is infected by contact with water containing the infective cercarias The worms, now called metacercarias, having penetrated the skin, enter the bloodstream and after a relatively prolonged migration through the circulation lodge in tributaries of the superior and inferior mesenteric veins where copulation and subsequently oviposition take place

During the period of migration there may be no symptoms, or pulmonary involvement may be manifested as bronchitis pneumonitis or bronchopneumonia Frequently eosinophilia is present, and there may be other so called 'toxemic symptoms afternoon fever, chills, dyspnea, non-productive cough, facial edema, urticaria, abdominal pain and anorexia

Chronic pulmonary disease is produced by eggs carried by the blood stream from the site of oviposition in the mesenteric veins to the lungs or the adult may be carried via caval blood to pulmonary arterioles and oviposit An inflammatory reaction surrounds the eggs with the development of abscesses, pseudotubercles, fibrosis and calcification Exudate containing chronic inflammatory cells and eosinophils may collect in the alveoli Rupture of pseudotubercles into alveolus or bronchus may permit eggs to be found in the sputum

Chronic pulmonary schistosomiasis mansoni has been classified according to clinical manifestations as (1) bronchopulmonary with symptoms including hemoptysis, simulating tuberculosis, (2) pulmonary endarteritis which results in arterial hypertension of the pulmonary circulation and (3) the cardiopulmonary form, cor pulmonale, which is the consequence of the prolonged pulmonary arterial hypertension (Meira, 1942)

This classification, while useful, is not peculiar to schistosomiasis but may be applied to other chronic granulomatous bronchopulmonary diseases The interesting difference in schistosomiasis is that the pulmonary arterial hypertension may not be as closely related to the scarring resulting from granulomas as formerly thought De Faria (1934) has presented necropsy data showing that granulomas and scarring may be scarce in cases of cor pulmonale with schistosomiasis and that the arterial hypertension responsible for the heart disease may be the result of vascular disease not spatially related to the eggs

Treatment of schistosomiasis is with antimonials (potassium antimony tartrate or fuadin) administered parenterally As chronic pulmonary lesions are almost invariably accompanied by some degree of hepatic cirrhosis this factor should be weighed before the hepatotoxic antimonial is given

The lung fluke, Paragonimus westermanni, is widely distributed in the Far East and is also found in parts of Africa and northern South America Its life cycle is complicated by the requirement of a second intermediate host (crab or crayfish) in addition to the first intermediate host, a snail The infection is acquired by ingesting the encysted cercarias of the fluke contained in the muscles of uncooked crustaceans The metacercarias emerge from the cysts in the host's small intestine and then migrate through the intestinal wall into the peritoneal cavity, through the diaphragm and both layers of pleura into the lung and eventually lodge in or nearby the smaller bronchioles A chronic inflammatory reaction or granuloma develops about the worm and its eggs Pseudotubercles and abscesses are formed and are followed by fibrosis Atelectasis, cysts and abscesses may be found distal to the worm Abscesses containing eggs may rupture, disseminating eggs to new sites where additional lesions are produced

The disease is characteristically a chronic one, with cough and hemoptysis, the latter frequently profuse Diagnosis is by demonstration of eggs in the sputum Treatment by administration of potassium antimony tartrate or emetine has been said to produce temporary improvement but to date no satisfactory therapy has been developed

Other flatworms of importance in the production of bronchopulmonary disease are the cestodes, Taenia solium, the pork tapeworm, and Echinococcus granulosus, the dog tapeworm Echinococcosis is discussed in the following chapter

Infection with T solium is acquired by eating inadequately cooked pork infected with the larval parasite or cysticercus The adult stage which then develops lives in the human intestine and causes no serious disease On some occasions however man may be infected by the larval parasites This may be done by the ingestion of eggs passed by a human being infected with the adult worm (possibly the same individual) or by the eggs in an infected person being carried by reverse peristalsis to the stomach then back down to the intestine In either case the eggs may hatch and the released onchospheres migrate through the tissues and blood stream lodging in many different organs including the lungs They then develop into cysticerci

Tissue reaction to the worms occurs and with it toxemic symptoms A granulomatous lesion and fibrous encirclement develops about the worm Eventually the parasite dies and becomes calcified

The cysticerci reach a size of about 5 by 10 mm Depending upon location they may produce pressure symptoms even after death of the parasites In chest x ray they appear as oval or round opacities particularly striking in appearance when calcified Treatment is limited to surgical removal of accessible cysts

REFERENCES

APPLEBAUM I L and SHRAGER J Pneumonitis associated with malaria *Arch Int Med* 74 155 162 1944

BRILL R CHURG J and BEAVER P C Allergic granulomatosis associated with visceral larva migrans *Am J Clin Path* 23 1208 1215 1953

CARR H P SARDA M E P and NUÑEZ N A Anthelmintic treatment of uncinariasis *Am J Trop Med & Hyg* 3 495 503 1954

DE FARIA J L Cor pulmonale in Manson s schistosomiasis I Frequency in necropsy material pulmonary vascular changes caused by schistosome ova *Am J Path* 30 167 195 1954

FAUST E C Experimental studies on human and primate species of Strongyloides II The development of Strongyloides in the experimental host *Am J Hyg* 18 114 132 1933

JACQUES W E Relationship of nematode larvae to generalized sarcoidosis *Arch Path* 53 550–557 1952

KOINO S Experimental infections on human body with ascarides *Jap M World* 2 317–320 1922

MEIRA J A Estudo clinico das formas pulmonares da esquistasomíase mansônica *Arq de cir clin e exper* 6 1 136 1942

OCHSNER A and DEBAKEY M Pleuropulmonary complications of amebiasis *J Thoracic Surg* 5 225 258 1936

PINKERTON H and HENDERSON R G Adult toxoplasmosis *J A M A* 116 807–814 1941

SABIN A B and FELDMAN H A Dyes as microchemical indicators of a new immunity phenomenon affecting a protozoon parasite (toxoplasma) *Science* 108 660 663 1948

52

Hydatid Cysts

LOUIS R DAVIDSON, M D, *New York, New York*

IT is generally agreed that the lung after the liver, is the organ of man s body which is most frequently infested with hydatid disease This condition is the result of the development of the cystic or larval state of the tapeworm, Taenia echinococcus Hydatid cysts of the lung were clinically known to the ancients In modern times considerable impetus to the study of this tapeworm disease of man has been afforded by the work of Deve, the eminent French authority, the studies of Harold Dew of Australia and the writings of Jose Arce the Argentinean surgeon These include among other matters the different manifestations of hydatid cyst such as metastatic and secondary hydatid disease The geographic distribution of this condition "is dependent on its incidence and distribution in reservoir hosts particularly sheep cattle and pigs'



FIG 1 Depicting the natural history of the Taenia echinococcus (From VEGAS M H Hydatid Cysts of the Lung in Children Buenos Aires 1928 Imprenta Lamb y Cia Ltd)

Native cases are uncommon in this country but they are far from infrequent in sheep-raising countries such as Argentina Uruguay,

New Zealand, Australia Italy, Syria, Greece and Algiers

THE CYST IN MAN

A hydatid cyst can grow in the human and yet remain symptomless Cysts of the lung of

FIG 2 Taenia echinococcus showing all segments (From DAVIDSON L R Hydatid cyst of the lung J Thoracic Surg 13 471 512 1944)

course not palpable, are revealed almost exclusively by roentgenograms which as in other pulmonary lesions are most important in the diagnosis of the condition

The development (Fig 1) of the cyst in man is readily understood if a few brief moments are given to the study of the evolution of the taeniae (adult state) and the larva Of course where there are sheep there are dogs The infected dog (also the wolf and jackal) is the definitive host in its small intestine worms or taenia (Echinococcus granulosus) are found The intermediate or reservoir hosts are many, but most commonly infested are the sheep pigs and man Man is an 'accidental host as far as the further biological development of the parasite is concerned human infestations represent a dead end (Dew) Man then, does not take part in the continuation of the cycle The untainted dog is infested by ingesting the organs of animals usually the sheep which have been afflicted with fertile hydatid cysts (containing scolices) One notes that the hydatid cyst in man is the result of the development of an ovum or ova in one or more organs of man The ovum has its origin in the T echinococcus which resides as a parasite in the dogs' intestines This worm is very small (Fig 2) Its length is about 0 5 cm A chain of segments forms the entire tapeworm It is

ment that eggs are discharged The head is provided with four suckers and is armed with many hooklets by which the taeniae fasten themselves to the intestinal mucosa of the dog An infested animal contains many hundreds or thousands of worms, in turn these taeniae discharge into the feces innumerable ova which gain entrance into man (the intermediate host) usually through contaminated water or vegetables

When the egg lodges in man's stomach, the gastric juice digests the external coat thus freeing the hexacanth (six thorn) embryo (Fig 3) Subsequently it migrates through the gastric wall or the duodenum entering the venules lodging in the first barrier the liver If this shelter is hurdled the embryo passes through the inferior vena cava into the right



FIG 3 Hexacanth (six thorn) embryo (From DAVIDSON L H J Thoracic Surg 13 471–512 1944)

side of the heart and then is filtered out of the blood stream by the lung

Let us consider that it remains and develops in this latter organ (Fig 4) and there assumes what is called the larvated stage The embryo in growing empties its center The vacuolation continues so that at a certain point one finds a small vesicle which contains fluid The expanding embryonal wall is composed of two zones the inner nucleated wall (germinal layer) and the outer non nucleated wall (laminated layer) From the former wall masses of cells which become vacuolated protrude

into the vesicle's cavity. These capsules form the proliferative vesicles or brood capsules which in turn give rise to the scolices These are the heads or the source of new worms Most of these capsules and scolices are pinched off the germinal layer and sink in the hydatic

FIG 4 A, germinal layer, B, laminated layer, C, adventitia, D, proliferative vesicle, E, scolices, F, hydatid sand (From ARCE, J Arch Surg, 42 3, 1941)

fluid (aqua de roca, crystalline fluid), becoming what has been called "hydatid sand" The fluid-containing bag, composed of two layers of hydatid sand (Fig 5A and B), is the hydatid vesicle. As the vesicle, which is the parasite, grows, the organ in which it resides reacts to its presence forming a perivesicular layer or adventitia or pericyst Obviously this is formed by the host The connective tissue layer which surrounds the hydatid vesicle forms, with the latter, the hydatid cyst The adventitia embraces the hydatid vesicle However, it is not united to it This holds true in

in a sheep instead of man; further imagine that the infested organ of this slaughtered animal is eaten by a dog The scolices are ingested and enter the dog's small intestine where they become attached to the mucosa developing into T. echinococcus. Obviously the entire cycle is repeated Nothing will be mentioned about daughter cysts which occasionally develop, except to indicate that they are usually the result of a mechanical, infectious or toxic influence and usually they are biologically sterile, that is to say, they are without scolices or proliferative vesicles On the other hand, a fertile cyst, if ruptured or aspirated, may discharge scolices (Fig 6) into the surrounding tissue, thus causing the origin of new cysts which are known as secondary cysts (secondary hydatidosis) This leads to the obvious truism that when operating one must not permit any of the hydatid fluid or hydatid sand to contaminate the incisional or operative wound In addition, for this reason, among others, one should never aspirate a hydatid cyst except at the time of operation

Again if the primary cyst erodes into a vessel, metastatic hydatidosis results

The main difference between primary and secondary cysts is that the former develops from the ova and the latter grow from the scolices

The fluid and the membranes in the simple cyst are bacteriologically sterile Of course,

adventitia becomes infected or damaged thereby altering the integrity of the germinal and laminated layers along with the contents with resulting death of the vesicle In consequence of this the cyst is usually septic and the hydatid vesicle virtually falls apart The contents are necrosed and fragmented

BIOLOGIC FEATURES

Susman has very pithily discussed the biologic features and their relationship to the incidence of the disease and its distribution in different organs" I take the liberty of quoting him verbatim

"1 The ova are hardy and resistant, the scolices are delicate and labile In practical terms this means that the intermediate host may become infected long after the ova have been excreted by the dog but the dog will become infected only if he eats the scolex-bearing cysts while they are still fresh and unruptured

'2 Only a small percentage of human beings, dogs and sheep are susceptible to infection

'3 Many ova that reach the intermediate host fail to develop into cysts and many cysts abort at an early stage

"4 The distribution of cysts in the body varies from country to country and from species to species In Australia and New Zealand about 23 per cent of the cysts in human beings occur in the lungs in Iceland the percentage given by Icelandic investigators is only 1 5 per cent Cattle have proportionately more pulmonary cysts than sheep, and pigs have fewer Cysts are rare in the horse, and a very high percentage of them occur in the liver

5 The parasite may die at any time for no apparent reason or as the result of rupture or pyogenic infection It may become a caseous mass very like a tuberculous focus

"6 The rate of growth of these cysts is not known It has often been said that most patients become infected in childhood although the disease may not be diagnosed until adult life But radiology has shown that a hydatid cyst may become apparent in a matter of months if infection did actually occur in childhood in these persons then for many years the cysts were too small to cast any appreciable shadow and then they suddenly took on rapid growth Furthermore daughter cysts may appear in radiograms taken during the first year after rupture of a mother cyst It is probable that primary and secondary cysts have different rates of growth and the rate of growth varies from animal to animal, as well as in the small animal

FIG 5A Membranes extracted from patient (From DAVIDSON L R J *Thoracic Surg* 13 471 512 1944)

7 It is not known when and where the ova hatch out But we do know that the embryos enter the portal circulation and that explains why most hydatid cysts are found in the liver One or more embryos may pass through the liver and reach the lungs which are the second most frequent site of cysts Again some embryos pass through the lungs and enter the general circulation Thus cysts may develop in any part of the body, but the total number in other organs and tissues is much less than the number in the lungs and liver Cysts in different parts frequently coexist

'8 Hydatid cysts grow by quiet pressure necrosis of surrounding structures and any tissue may become seriously eroded including bones and blood vessels '

In the lung the parasite develops into a hydatid vesicle with its surrounding adventitia (Fig 7), the latter is covered by a thin con

FIG 5B Germinal layer and laminated layer (From DAVIDSON L. R J Thoracic Surg 13 471 512 1944)

FIG 6 Scolices with cupping (From DAVIDSON L. R J Thoracic Surg 13 471 512 1944)

centric layer of atelectasis The enlarging cyst, through an adventitial defect, impinges upon a bronchiole whose wall, in turn, may contact the outer surface of the laminated layer As the cyst increases in size, the bronchiole is eroded thus permitting the pervesicle space to communicate with the bronchiole Now through various acts such as coughing and straining, air insinuates itself between the "banana skin and fruit" Then more air surrounds the vesicle causing the pervesiculum pneuma In most instances further changes are noted If the membranes tear, fluid enters the bronchiole and the act of coughing is stimulated If a larger opening occurs in the membranes, air enters the vesicle and a double-dome arch, Cumbo's sign, is produced Finally, when the echinococcus membranes sink into the cavity and float upon the remaining fluid, the camalote formation is noted This was first described in 1924 *

SYMPTOMS

It is necessary, for the understanding of the symptoms and signs, to recognize the difference between simple and complicated cysts which may be either peripheral or central The simple or ordinary cyst generally is silent Cough is usually the first symptom and, of course, is non productive Occasionally there is companion chest pain Later the cough may be productive and accompanied by hemoptysis Later, when the cyst enlarges, dyspnea may manifest itself This symptomatology does not reveal the possibilities of an exact diagnosis The physical examination often suggests the diagnosis, but of course it is not unmistakable "In countries with echinococcus infested zones the place where the patient lives is of the utmost importance"

DIAGNOSIS

Diagnosis is difficult at the best Laboratory methods are quite valuable, yet these procedures are not unequivocal Eosinophilia is not present in dead or suppurating cysts Even in intact cysts the positive blood picture is not always present. Writers differ, yet one may state that eosinophilia is present when the percentage of eosinophils is over 4 per cent Of course, other conditions produce this picture If a high eosinophilia count is obtained, one or the other of the biologic reactions which are about to be described should be present before a diagnosis is made The complement fixation test (Weinberg) is not invariable Of all, the intradermal test of Casoni is most reliable although it is not constant Certain diagnosis is made only when hooklets (Fig 8), scolices or laminated membranes are found

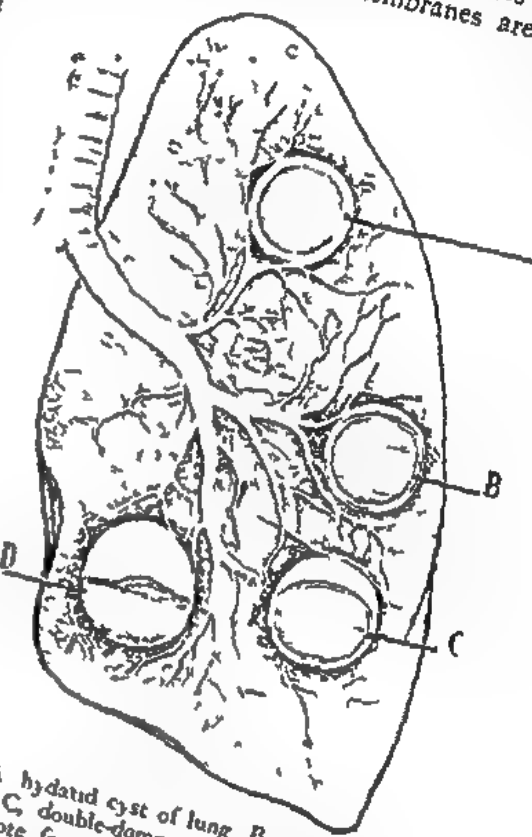

FIG 7 A hydatid cyst of lung B, pervesicular pneuma C, double-dome arch (Cumbo's sign) D camalote formation (From ARCE J Arch Surg 42 11, 1941)

However, in complicated cysts one can make a positive diagnosis when a characteristic x-ray picture is found noting the pervesiculum pneuma, Cumbo's sign, or camalote formation In the following case a preoperative diagnosis was made simply upon the basis of such an x-ray

M N, a white adult man who was worn as a ship's steward, was born in Portugal had lived in Argentina a part of his early L In May 28, 1937, at the time of his first adm sion to the United States Marine Hospital Stapleton, Staten Island, New York, he wa thirty-five years of age One month before, while on board ship, he was struck by a swing-ing door and suffered a lacerated wound of the back Two days later pain developed in his left



FIG 8 Hooklets from scolices (From DAVIDSON, L R J Thoracic Surg 13 471–512, 1944)

chest On June 3rd he spat blood An x-ray picture of the left upper lobe revealed a dense circular shadow "the size of a hen's egg" A diagnosis of a superior sulcus tumor was made

His second admission was March 10, 1939, when he entered the Marine Hospital because of an infected right leg Again a chest x-ray disclosed the same shadow as that noted earlier There had been no weight loss, night sweats, fever, cough or hemoptysis On this occasion an additional diagnosis was made by the x-ray department, that is, fibroma of the lung or a benign mass

On March 14, 1941, the patient was again seen because of a blow suffered in the left [illegible] Of [illegible] mass was [illegible] pical [illegible] copy was done again and bronchograms made All these examinations were negative

It was learned that this patient had been admitted to Ellis Island Hospital as far back as September, 1934, at which time he had had cough, fever and blood-tinged expectoration At no time had the tubercle bacillus been found The x-rays always showed the circular shadow in the apex of the left upper lobe

His last admission into the United States Marine Hospital at Stapleton was November 12, 1941, at which time he was suffering from pain in the left side of the chest, hemoptysis and cough The sputum was negative for tumor cells On fourteen different occasions his sputum was negative for the tubercle bacillus At this point I saw the patient for the first time X-rays were presented which permitted an immediate and unequivocal diagnosis (Fig 9A and B) of a complicated hydatid cyst On January 30, 1942, operation was performed A section of the left fourth rib was removed and the soft tissues were draped The lung was adherent to the parietal pleura The cyst was opened and suction was used Much degenerated tissue was obtained and remnants of structures which looked like "empty grape skins" were extracted The defect was packed with gauze soaked with 5 per cent formalin Later the gauze was removed and dry gauze packing was introduced The wound was dressed every other day The



9A 9B

FIG 9 A frontal view again note perivesicular pneumatosis B lateral view note perivesicular pneumatosis (From DAVIDSON L R J Thoracic Surg 13 471 512 1944

healing of the lung The patient gained 20 pounds in weight The pathologic report indicated the presence of mucopurulent putty like material Here and there there were cheese like masses There were no hooklets laminated membrane or scolices The patient is at this time working as a seaman

If the hydatid cyst ruptures into the pleural cavity, grave consequences may ensue, an anaphylactic shock manifests itself quite rapidly However, it may be lessened or relieved by the use of adrenalin Anaphylaxis is obviously the result of the absorption of the antigen in an individual who has been sensitized by the development of the hydatid vesicle in the lung

TREATMENT

Medical treatment is unavailing Puncture of the cyst whether for the purposes of diagnosis or treatment is mentioned merely to be condemned It follows then that surgery is the only treatment What cysts should receive intervention and when should operation be performed? There is some difference of opinion However one must ask In what group is the cyst? Is it simple or complicated? Central or peripheral? Simple cysts offer no symptoms occasionally there is a slight unproductive cough with some spitting of blood If the parietal pleura is contacted by the cyst there may be some pain Complicated cysts frequently reveal pathognomonic x ray signs As in a putrid lung abscess the presence or absence of pleural adhesions determines the type of surgical therapy Regardless of the presence or absence of pleural synechia, the essence of treatment is identical The chest wall is opened the adventitial wall is incised and the membranes are removed A one-stage operation in the absence of adhesions is neither simple nor without a definite risk Central cysts should not be attacked unless they are draining poorly and are accompanied by fever Even then caution is suggested

Lobectomy may be indicated for serious or recurrent hemoptysis intensive complicating

bronchiectasis, a centrally located cyst or a markedly infected cyst

The chest wall opening is made over the site of the peripheral cyst which previously has been revealed by x-ray With the presence of adhesions between the visceral and parietal pleura definitely established, and after the parietal pleura has been exposed, the adventitia is entered and the membranes and contents are removed If when the parietal pleura is exposed the lung is found unadherent, the surgeon may produce adhesions by packing the wound with gauze About two weeks later the packing is removed and the adhesions will be noted between the visceral and parietal pleura Then the adventitia is incised and the vesicle extracted On the other hand, a one-stage operation is conducted by projecting the lung through the wound in the parietal pleura This is accomplished through the use of a tight-fitting gas mask, at the appropriate moment the pressure in the bag being increased to about 10 cm of water, positive pressure Another type of one-stage operation for the unadherent lung is performed by transfixing the lung pleurae and part of the chest wall with sutures outside of the cyst area Thus the lung is held to the chest wall preventing a large pneumothorax This procedure is not looked upon with favor

The cyst itself is treated in different ways Of course, the wound should always be meticulously draped before the cyst wall is opened After an exploratory needle has been thrust into the cyst fluid is withdrawn Some complicated cysts have no fluid but this is usually known before the operation Some operators inject 2 per cent formalin into the cyst after the fluid has been aspirated In any event, the pericyst is incised and the membranes are extracted from within the adventitia In a simple aseptic cyst the adventitia may be completely sutured In most cysts the pouch (adventitial membrane) should be marsupialized and drainage established Septic complicated cysts may be repeatedly packed with gauze until healing has been established

Hydatid cysts have been found in practically every organ of the human body Fortunately the cyst is usually single, although on rare occasions two or more cysts are found and sometimes in one organ or part Multiple organ infection occurs in less than 2 per cent of the cases As in bronchiectasis, so in hydatid disease, the infestation usually first manifests itself in children In man the liver is involved in about 75 per cent of the cases, the lung is infested in about 10 per cent of the patients studied Peculiarly, and in contradistinction to this, in the squirrel the lung is involved in 98 per cent of the cases and the liver in 0 2 per cent (Den) This is said to be in consequence of the fact that the hepatic capillaries of this animal are readily enlarged, thus permitting the parasite to filter through In addition, some biologic peculiarity rather than circulatory effect may influence the site of the lodgement of the embryo

All hydatids begin as simple cysts, but in the lung when the cyst enlarges, it involves a bronchus or bronchiole into which it leaks and from which the dissecting air is obtained The contents may be evacuated through the bronchus permitting a spontaneous cure On the other hand, the cyst may be contaminated and all fertile elements are destroyed The scolices die and the membranes are destroyed

Daughter cyst formation is rare in the lung and as already noted it is the result of some complication

G T, a thirty eight year old laborer, was born in Syria and came to this country at the age of ten He was admitted to the Post Graduate Hospital on September 25, 1940 with complaints of inability to use his lower extremities, decrease in sensation of these extremities and tumor in the left chest wall

Twenty-three years before he had suffered from recurrent abscesses over the sacral and lumbar regions They were allegedly tuberculous in nature They did not heal for some time and then only when he exposed the parts to direct sunshine Six years before admission a painless, barely discernible mass was noted in the chest wall on the left side, posteriorly Three years before admission he complained of pain in this area and was x rayed by eminent Philadelphia radiographers who diagnosed his condition as a tuberculous process Almost two months before admission he first complained of loss of sensation in the lower extremities One morning shortly thereafter he could barely walk The patient could not flex his legs He said that they were dead" There were no urinary or gastrointestinal disturbances

The patient was a well nourished, robust, young adult man whose gait was severely impaired A non tender mass was noted on the

left side of the chest, mainly in the posterior axillary region extending from the sixth to the tenth ribs Over the sacrum there were depressed pale scars There was bilateral weak-

bladder or bowel disturbance Below the fourth lumbar vertebra there was some patchy hyperesthesia A spinal tap was negative The spinal Wassermann and the blood Wassermann and Kahn tests were negative

X rays revealed cystic like degenerative changes with marked expansion involving the ninth rib on the left side and invasion of the neighboring soft tissues with encroachment on the pulmonic field with pleural retraction There was a left paramediastinal mass There was erosion of the seventh rib and invasion of the posterior 2 inches of the eighth rib The lesion also invaded the left transverse processes of the arches of the seventh eighth and ninth dorsal vertebrae There was no eosinophilia A working diagnosis was made of either a benign tumor undergoing malignant changes or an extensive tuberculous process It was decided to perform a biopsy On September 28th the first operation was performed, consent having been obtained for a biopsy only A tumefaction was found particularly in the area of the ninth rib over which an incision was made The chest wall muscles were barely opened when some fluid appeared in the wound Upon enlarging the wound an amazing number of daughter cysts accompanied by fluid and hydatid sand were disgorged to the surface The ninth rib was found to be destroyed, and the seventh and eighth ribs eroded More surprisingly, however a multiloculated supra- and infracostal cyst of definite proportions was found Aspiration of the contents was performed and the wound was packed

On October 19th the previous incision was enlarged and extended passing through the back muscles The cavity was almost ruthlessly and completely unroofed using in the main, large biting rongeurs After the wound was saucerized, cleaned and painted with formaldehyde, a large leg roll was packed into it

The pathologist reported daughter cysts, laminated connective tissue and scolices The specimen consisted in the main of dense fibrous scar tissue with lymphoid and plasma cell infiltration The hydatid fluid was bacteriologically sterile

Fracture boards were placed beneath the patient's mattress a Knight brace with a chin and occiput extension was worn He did receive a short period of *galvanic stimulation to the* lower extremities Postoperatively intradermal and complement fixation tests were negative For some time before his discharge (February 6, 1941) he had been up and walking about the ward although he had been admitted to the hospital in a wheelchair

On January 6 1943 he was readmitted to Post Graduate Hospital, still wearing the spinal brace At this time he had no ankle edema although this condition had been present at the time of discharge On examination two discrete, though not too well defined palpable fluctuant masses were noted over the left erector spinae muscle at about the level of the ninth dorsal vertebra On January 9th these cysts were operated upon being isolated and aspirated The walls were removed intact The area was packed with 10 per cent formalin gauze About three days postoperatively this patient who had gained considerable weight and was now definitely obese, developed a rash which was thought to have resulted from the formalin packings These were discontinued The x rays disclosed much improvement, particularly good fusion of the dorsal vertebra At the time of this communication he was walking well, eating well and feeling better than he had in many years He was working as a laborer and was not wearing the brace

In this connection, it is proper to relate that the acceptance of this case, in which daughter cysts were found, as one originating in the lung must be questioned Of course, superficially at least its picture is that of an intrathoracic hydatid cyst Dew has stated that "whenever an intrathoracic cyst is found to contain daughter cysts, an hepatic origin should be suspected and this should lead to an investigation of the diaphragmatic region" However, we are not sure but that this cyst did not originate in the vertebral column Possibly an implantation first appeared in the pedicle, body or lamina of the vertebra This presumably began when the patient was a boy in Syria Many years later the soft tissues were invaded by extension Just before he was seen cyst formation within the spinal canal reached such a stage that pressure was exerted upon the

cord and concordant symptoms appeared This, of necessity, is a very slow process because decompression probably had occurred time and again by extraspinal extension Of course, the accuracy of the observations made at the time of the operation may be questioned The history, findings and postoperative neurologic improvement must permit of the biting inference that this was not a pulmonary hydatid but rather it was a hydatid cyst originating in the spinal column

Again, according to Dew, "the prognosis in vertebral hydatid disease is almost hopeless as regards complete cure This is due to the impossibility of removing by surgical means all diseased bone to the multiplicity of osseous cysts to the certainty of recurrent pressure on the cord and to the risks of infection" It is also noted in this case that at the time of the operation when unsuspected scolex containing fluid was evacuated, these premature heads were undoubtedly implanted in the operated wound thereby permitting of the growth of a recurrent or a secondary hydatid cyst

Almost all authorities deprecate the aspiration of the hydatid cyst In many instances this procedure has been followed by death Even if death does not result, infection of the cyst and/or contamination of the pleural cavity are probabilities Even if the foregoing do not occur, there is always the possibility of creating the presence of a lifeless foreign body in the lung In fact, the death of the parasite does not remove the patient from the possibilities of danger Finally, let it be said, it takes many years to learn whether leakage around a puncture needle occurred with subsequent implantation of scolices in the chest wall

It is not unusual to have a simple cyst leak and rupture into a bronchus or bronchiole If this progresses the fluid and the membranes may be extruded, permitting a spontaneous cure If only the fluid is expelled, the membranes remain and one may expect an infection or abscess formation Paradoxically, these complicated cysts may possess one virtue, that is a pathognomonic radiograph may be obtained As already indicated, a preoperative diagnosis was made in view of the presence of a perivesicular pneuma This feature has been most adequately described by Arce and Zehbe

There is but one treatment of hydatid cysts and that is surgical The absence or presence of adhesions modifies the plan of attack If there are definite adhesions, the rib overlying the cavity is removed and the contents are in turn extracted

Most authorities insist, particularly with a simple cyst that one should never think that the adhesions are either quantitatively or qualitatively what one desires Therefore the operation should be performed in either two stages or, if in one stage, the lung should not be permitted to retract into the thoracic cage This is prevented by using increased anesthetic gas or oxygen pressure Finally, the localization is very well noted by a spot shot It follows then that the impression is that a pulmonary hydatid cyst should be operated upon in two stages or in one stage using increased anesthetic pressure of 10 cm of water when the cyst is approached

Estevez discusses the injection of 2 per cent formalin into the cavity after it has been punctured and aspirated Dew most emphatically insists that this medicament should never be used in the lung or pleura Of course under all circumstances both the incisional wound and the pleural cavity should be well protected during the operation The aspirating unit must be functioning and immediately at hand Fluid is not always obtained from a complicated cyst After the cyst has been removed the adventitia may be closed tightly or it may be sutured to the chest wall bringing a drain from the pulmonary defect (marsupialization)

Biologic reactions are encountered in many ways As in all helminthic diseases, eosinophilia is noted This is not a constant finding The Weinberg test, which has been confirmed, is a complement fixation test One must possess a fresh antigen properly tested Although more reliable than the leukocyte count it too is not always reliable The best type of test is that which involves an intradermal reaction and is known as the Casoni test A positive reaction (like a Mantoux test) presents a wheal and a surrounding area of erythema

The diagnosis of pulmonary hydatid cyst is difficult, particularly in the United States where it is a rare condition Since this cyst becomes complicated quite often, certain differences arise which add to the problem In brief, one may be suspicious of a case if there is a history of cough, pleural pain, hemoptysis and/or a febrile reaction particularly if the patient has been an inhabitant of some infested

area X-rays may be of great help and other laboratory findings as indicated may be helpful Cysts usually are in the lower lobe and occur more frequently in males

REFERENCES

1 ARCE, J Echinococcus cyst of the lung *Surg, Gynec & Obst*, 75 67–73 1942
2 ARCE, J Recidivation in adventitia of occluded cyst *Bol d Inst clin quir*, 18 609–617, 1942
3 ARCE, J and BREA M M Intrapleural rupture of cyst, case *Bol y trab Acad argent de cir*, 25 1234 1241, 1941
4 ARCE, J Echinococcus cyst of lung *Arch Surg*, 43 789–802, 1941
5 ARCE, J and IVANISSEVICH, O Multiple hydatido sis, case with recovery after partial lobectomy *Bol y trab Soc de cir de Buenos Aires*, 22 263–267, 1938
6 ARCE, J Therapy *Dia méd*, 10 613–617 1938
7 DÉVÉ F "Air calotte" is not necessarily a pathognomonic roentgen sign *An Inst modelo de clin med*, 18 7–23 1937
8 DEVÉ, F Spontaneous suffocating pneumothorax due to intrapleural rupture of experimental cysts in rabbits. *Compt rend Soc de biol*, 124 220–223 1937
9 DÉVÉ, F Experiments proving that ingestion of echinococcus by way of digestive tract does not cause secondary echinococcosis *Compt rend Soc de biol*, 114 669–671, 1933
10 DÉVÉ, F Metastatic echinococcosis in experimental animals and in man *Prensa méd argent*, 19 957–966, 1932
11 DEVÉ, F Secondary bronchogenic echinococcosis *Compt rend Soc de biol*, 107 438 441 1931
12 DÉVÉ, F Pathogenesis of pneumothorax following hydatid cyst *Presse méd*, 39 53–54, 1931
13 DEW, H R Extrapleural thoracoplasty for non collapse of intrathoracic hydatid cyst *J Coll Surgeons, Australasia*, 1 226–229 1928
14 DEW, H R Hydatid Disease Its Pathology, Diagnosis, and Treatment Sydney, Australia 1928 Australasian Medical Publishing Co, Ltd
15 ESTEVEZ, R Surgical therapy *Rev med de Chile*, 67 1290–1316, 1939
16 SUSMAN, M P Hydatid disease as it affects the thoracic surgeon *J Thoracic Surg*, 26 111, 1953

53

Foreign Bodies in the Bronchopulmonary Tract

WALTER H MALONEY, M D, M SC., *Philadelphia, Pennsylvania*

From The Department of Laryngology and Broncho-Esophagology Hahnemann Medical College and Hospital Philadelphia, Pennsylvania

THE basic understanding upon which modern diagnosis and treatment of pulmonary disease is founded had its origin in the experience gained in the solution of foreign body problems From these observations came the explanation of the mechanical features which produce the wheeze, obstructive emphysema and atelectasis The relative incidence of foreign body problems becomes smaller and smaller as this field of medicine progresses This is due in part to prophylaxis but more so to the wider application of bronchoscopy in the diagnosis and treatment of all pulmonary diseases Today foreign body work is a small part of the bronchologist's practice However, the principles involved in these problems are basically important and can be applied to all phases of pulmonary disease

This subject cannot be covered without first acknowledging the main source of knowledge and authority From the pioneer work of Chevalier Jackson carried on by his associates and students has come a vast storehouse of information [1-48] Any treatise must of necessity refer to these works and merely add the author's own interpretation and emphasis to the various aspects of the subject of foreign bodies in the bronchopulmonary tract

Etiology Age appears to be the most significant factor in the etiology of foreign bodies [1-4] By far the greatest number of cases occur in children

Size and shape of the foreign body help determine its location and symptomatology Those too large or irregular to pass through the larynx will either lodge in the hypopharynx or enter the esophagus Occasionally they will lodge in the larynx usually precipitating an acute respiratory emergency because of resulting laryngeal obstruction As the foreign bodies become smaller, they will lodge further down in the tract Size and shape determine whether they will pass through the larynx since the glottic chink has its greatest measurement in the anteroposterior diameter with a relatively small width, greatest in the posterior aspect

Carelessness on the part of adults contributes to the problem not only for themselves but also for the children under their care This is particularly true of foreign bodies held in the mouth a practice which is quickly mimicked by children In the older age groups physical disability and senility contribute to the problem

To list all of the various types of foreign bodies is virtually impossible In the many detailed analyses published[1-2,4-48] it is apparent that vegetal foreign bodies are the most numerous and occur principally in children While bones usually lodge in the esophagus, those that do enter the respiratory tract are commonly overlooked Grasses are rare but their ratchet like action which drives them deeper and deeper into the bronchi makes them a difficult problem for removal Metallic foreign bodies such as screws, pins and nails are common Dental plates are uncommon but teeth are frequently seen Coins are rare since it is easier for them to pass into the esophagus than into the trachea because of the necessity of turning from the coronal plane to the sagittal plane to get through the glottic chink Endogenous foreign bodies, such as broncholiths are rare Of those foreign bodies which do enter the bronchopulmonary tract, the highest number lodge in the bronchus, next in the trachea and the smallest number remain in the larynx

Pathologic Physiology The mechanism of partial and total obstruction of the trachea or bronchi is basic to the understanding of the action of foreign bodies in the bronchopulmonary tract

Chevalier Jackson has best described it as follows [4-8] *Bypass valve* action occurs when the foreign body is of a size and shape or lodged at a point where air can pass by it on both inspiration and expiration Since there is no obstruction to the flow of air, there will be no change in the x ray picture and very little will be found on physical examination other than possibly a wheeze

As the air space around the foreign body decreases due to edema of the mucosa or to the further progress of the foreign body into the smaller bronchi, the *check valve* phenomenon occurs This is based on the change in the lumen of the bronchi with enlargement during inspiration and decrease during expiration As a result, when the air space reaches a point where air can enter on inspiration but is trapped on expiration, the picture of obstructive emphysema occurs When the foreign

mittent which complicates diagnosis

The final stage is the *stop valve* phenomenon where neither inspiration nor expiration results in air exchange and the portion of lung involved becomes completely atelectatic

There are two other basic mechanisms which should be described Holinger explained them clearly in his paper on bronchial obstruction [3] The first is the mechanism by which subcutaneous emphysema is produced Partial obstruction of a bronchus which produces obstructive emphysema causes an increase in the alveolar pressure This may be enough to form bullae beneath the visceral pleura Air from rupture of these bullae will travel along the subpleural space to the hilus of the lung then up the mediastinum to the neck and out under the skin Rupture of the bullae into the pleural cavity results in a sudden pneumothorax This usually precipitates an acute emergency calling for needle aspiration and a

pulmonary capillary blood pressure resulting in transudation of serum into the alveolar spaces An increase in intrabronchial and intra alveolar negative pressure causes exudation into the alveoli The combination of the increased negative pressure and the increased pulmonary capillary blood pressure results in pulmonary edema and circulatory failure

DIAGNOSIS

The first step toward accurate diagnosis is a high index of suspicion coupled with a careful history In many cases a positive history of foreign body can be elicited, but there are enough cases in which the incident occurred when the patient was unaware of it due to sleep coma anesthesia, etc, or the patient was too young to give a history and the incident occurred out of sight or sound of the responsible party Thus there is need for a high index of suspicion on the part of the physician when confronted with a complaint or physical finding in the bronchopulmonary system which appears to have an "obscure etiology"

A review of actual case histories shows that many physicians refuse to accept the patient's story of aspiration of a foreign body [9] The patient's plea for x ray examination is disregarded and this, coupled with a superficial physical examination, results in the patient's being sent back home to await the inevitable sequelae which follow the long lodgment of a

awareness of the need for complete study including x ray and diagnostic bronchoscopy

Usually there will be an episode of coughing

comes negligible or disappears During this interval there is little or no respiratory distress, and it is not until edema infection and suppuration appear that symptoms of cough, wheeze and dyspnea recur The patient then

and treatment

Keeping in mind the basic pathologic physiology and anatomy, it is not difficult to bring to mind the symptomatology and physical signs found in these problems They vary with the location, size, shape and length of lodgment of the foreign body

The foreign body in the larynx produces hoarseness, pain, dysphagia, cough and often stridor

When the foreign body is in the trachea and freely movable, the patient will describe a slapping on inspiration and expiration The examiner will hear at the open mouth what Jackson has called the "audible slap" and feel the palpable thud as the foreign body is trapped at the larynx by the vocal cords during cough or forced expiration A wheeze, when present, is best heard at the open mouth It is usually heard when the foreign body lodges somewhere in the trachea and becomes stationary The cough is often "brassy" in character Actual stridor may be present The larger the tracheal foreign body and airway obstruction, the greater will be the inspiratory effort with associated retraction of the suprasternal areas and intercostal spaces C L Jackson has stressed the importance of bilateral emphysema as a sign in tracheal foreign bodies and one which is frequently overlooked It is often confused with bilateral bronchial obstruction due to multiple foreign bodies

Foreign bodies in the bronchi result in cough wheeze, dyspnea and the wide variety of signs and symptoms previously discussed They are those seen in the various stages of bronchial obstructions and resulting distal pulmonary disease? X-ray studies, including fluoroscopy, inspiration and expiration films, are valuable

Partial obstruction resulting in obstructive emphysema causes limited chest expansion, hyper resonance and decreased or absent breath sounds on the involved side A wheeze is usually heard over the involved bronchus but may be transmitted over all of the chest Fluoroscopy will show the mediastinal swing to the uninvolved side on expiration plus the flattened diaphragm on the involved side

With complete atelectasis there will be decreased to absent breath sounds dullness to percussion and decreased expansion on the involved side No wheeze is heard Fluoroscopy will not show a mediastinal swing Films will show shift of mediastinum to the atelectatic side which is constant on inspiration and expiration The diaphragm will be elevated on the involved side There may be compensatory emphysema of the uninvolved side which may confuse both the radiologist and bronchoscopist as to the true location of the foreign body

Appropriate film studies will also disclose other mediastinal abnormalities, esophageal pathologic conditions and paravertebral disease Additional diagnostic x ray aids include planigraphy and bronchography As is apparent from our previous discussion, the radiologist s report may be completely negative, and diagnosis and treatment must depend entirely on h tory and physical examination

The differential diagnoses must include all c the diseases of the bronchopulmonary system As Jackson has said, "A wheeze may be any thing from peanuts to cancer" In addition to the primary diseases of the bronchopulmonary tract, obstructive phenomena in the esophagus, whether by foreign body or other disease such as diverticulum or tumor, may compress the trachea and simulate a tracheal foreign body Cardiovascular anomalies are of growing importance today and are increasing as a differential diagnostic factor in bronchopulmonary disease Compression of the trachea or bronchi by an anomalous vascular structure will produce any of the basic obstructive features already described

TREATMENT

The treatment of foreign bodies of th bronchopulmonary tract is, with very fe exceptions removal via the natural pathwa by peroral bronchoscopy Jackson report that only 2 to 4 per cent will be coughed up spontaneously

The instrumentarium is essentially that needed for diagnostic and therapeutic bronchoscopy in general All that should be added are the few basic foreign body forceps peculiar to the individual problem at hand A manikin board is necessary for practice Magnets should be added for ferrous foreign bodies However, it is not within the scope of this paper to go into the detailed problem of foreign body extraction For this information the reader is referred to the basic textbooks on peroral endoscopy which thoroughly and adequately cover this subject 4-6 To repeat this information here would be at best inadequate and superfluous

inadequate instrumentarium unless an impending fatality necessitates heroic action Anything else must be considered "meddlesome" and invariably complicates the final solution

Where the location of the foreign body is in the distal segmental bronchi beyond endoscopic vision, biplane fluoroscopic guidance is necessary[56] If this is not available, the patient should be referred to an institution with such facilities With the use of this special x-ray equipment the percentage of foreign body removal rises to 99 per cent There is certainly no justification for thoracotomy and possible lobectomy for removal of such foreign bodies because this equipment is not available in one s own institution

The problem of treatment or management varies with the location and characteristic of the foreign body Laryngeal foreign bodies demand immediate attention Care must be taken to avoid dislodging it into the trachea or doing irreparable damage to the larynx Although the great majority of foreign body extraction is best handled under local anesthesia, general anesthesia may be preferred in problems where absolute immobility of the patient at the time of application of the forceps and extraction is necessary Tracheal foreign bodies, too, demand immediate attention At any moment complete obstruction of the airway may occur with asphyxiation of the patient

Occasionally edema of the larynx or an irregular shape to the foreign body will not allow its return via the larynx This will require tracheotomy for adequate room to remove it

It is generally true that the sooner the foreign body is removed, the easier the solution and the quicker the recovery However, in problems in which suffocation or other complications are not of major concern, it is better to complete a thorough and adequate

copy A duplicate foreign body should be obtained and removal practiced on the manikin board before it is attempted on the patient This is much better than rushing into such a problem with inadequate study and preparation, improper instruments and, above all, assistants who are not acquainted with the problems involved Do not allow yourself to be forced into a situation where your better judgment tells you that it is not the proper thing to do

While the laryngeal and tracheal foreign bodies are usually obvious on bronchoscopic examination the bronchial foreign body may be obscured by edema, stenosis granulation tissue or secretions Repeat bronchoscopies are indicated in these circumstances Often it is only after resolution of the infection and establishment of proper drainage that the foreign body becomes apparent

On occasion a non-opaque foreign body will require thoracotomy and resection for final diagnosis and treatment, the operative diagnosis being the end result of a long standing foreign body, i e , lung abscess, stenosis of the bronchus or bronchiectasis Also, the opaque foreign body beyond the reach of the costophrenic bronchoscope and biplane fluoroscopic technic will require thoracotomy for removal

Not all foreign bodies enter via the larynx Penetration through the chest wall may result in a problem where the location is such that it can be removed via the bronchoscope with biplane fluoroscopic assistance More often thoracotomy is required for removal

PROGNOSIS

In the routine uncomplicated foreign body problem properly handled, extraction and uneventful recovery should be expected However, a certain number of cases terminate fatally for reasons beyond the power of the physician to circumvent, for example, the tracheal foreign body which suddenly obstructs while the patient is en route to the hospital, or perforation of the trachea or bronchi with mediastinitis which does not respond to chemotherapy and surgical drainage Fulminating tracheobronchitis and suppurative lung disease may cause extensive morbidity and mortality Vegetal foreign bodies such as peanuts cause severe mucosal irritation and will cause obstruction due to secretion, edema and granulation tissue However, many of the complica-

postoperative period the problem of infection,

respiratory embarrassment due to obstruction, or mediastinal complication should be recognized early. Immediate treatment is necessary to prevent unnecessary morbidity or mortality

Postoperative x-rays are necessary in all cases whether symptoms are present or not Persistent physical findings and/or x-ray findings indicate the need for careful follow-up with repeat bronchoscopy and occasionally bronchograms There may be a residual fragment of foreign body or a granuloma, stenosis or bronchiectasis which requires active treatment

It is generally true that the lungs have unusual recuperative power The vast majority of foreign body problems become completely asymptomatic even in the face of roentgen evidence of residual bronchiectasis Asymptomatic bronchiectasis of foreign body etiology does not warrant resection on roentgen evidence alone However, there are a certain number of cases with active suppurative disease requiring resection of the involved segment

SUMMARY

1 From the pioneer work in foreign body problems by Chevalier Jackson, his contemporaries and students, has come a fundamental [illegible] of [illegible] in [illegible] nose [illegible] cases with an obscure etiology or in those cases in which response to treatment is not what *experience has taught you to expect*

3 The most important factor in the incidence of foreign bodies is carelessness on the part of the patient or the responsible adult. Children are the greatest offenders and [illegible] commonly found.

4 A positive history with negative physical examination and x-rays demands diagnostic bronchoscopy The symptomless interval is misleading

5 Foreign body extraction should be carried out only after proper study and preparation, and with adequate instrumentarium and assistance unless asphyxia or fatality is imminent

6 The vast majority of foreign bodies can be removed successfully via peroral bronchoscopy with complete asymptomatic recovery

REFERENCES

1 CLERF, L. H Foreign bodies of the air and food passages *Surg., Gynec & Obst.*, 70 328–339 1940.

2 HOLINGER, P H, ANDREWS A H JR and RIGBY R G Foreign bodies in the air and food passages. *Eye, Ear, Nose & Throat Monthly*, 22 415–424 1943

3 HOLINGER, P H and RIGBY, R G Bronchial obstruction in infants and children *M Clin North America* 30 105–119, 1946

4 JACKSON, C and JACKSON, C. L. Diseases of the Air and Food Passages of Foreign Body Origin. Philadelphia, 1936 W B Saunders Co

5 JACKSON C. and JACKSON, C. L. Diseases of the Nose, Throat and Ear *Philadelphia, 1945* W B Saunders Co

6 JACKSON, C. and JACKSON C. L. Broncho-Esopha [illegible] W B Saunders Co.

7 LE [illegible] *Proc*

8 N [illegible] food Rhin

9 RICHARDS, L. G Medical progress, foreign [illegible] respiratory tract *New England J Med.*, 245 141–146, 1951

54

Acquired Atelectasis and Massive Pulmonary Collapse

EMIL A NACLERIO, M D, *New York, New York*

From the Thoracic Surgical Services of Harlem and Columbus Hospitals, New York New York

ATELECTASIS literally means incomplete expansion (ateles = incomplete ectasis = expansion) For this reason, strictly speaking it should be confined to the congenital condition in which the lung fails to change from the fetal to the fully expanded state In clinical practice it has come to be synonymous with collapse, or the change from a condition of complete to one of incomplete pulmonary expansion, without evidence of any inflammatory or other morbid deposits Apneumatosis active collapse atelectatic collapse and massive collapse are names which have been used to describe this condition It has been emphasized that probably no other diagnosis related to pulmonary disease has been abused as much as that of atelectasis The postmortem examination of lungs of patients demonstrating x ray shadows incident to a variety of conditions often fails to reveal what is strictly defined as atelectasis [1] Actually, the proper terms for these conditions are 'acquired and 'congenital' atelectasis *

ACQUIRED ATELECTASIS

In general the causes of acquired atelectasis may be divided into two groups (1) compression atelectasis and (2) bronchial obstruction In the latter group the peculiar condition known as massive collapse of the lung has been included

Compression Atelectasis When external pressure is exerted on the lung with consequent expulsion of the contained air a part or the whole of the lung may collapse The common causes may be the presence of fluid or air in the pleural space Removal of ribs paralysis of the diaphragm growths in the chest wall or chest cavity are other causes The part of the lung affected is that which is pressed on In this type of collapse bronchial drainage is almost always present, and when the pressure is relieved the lung usually re-expands In certain instances namely, empyema or hemothorax of long standing the lung is unable to re-expand because of the tissue reaction that has taken place over the pleural surfaces

Bronchial Obstruction The chief cause of atelectasis is bronchial obstruction The area of collapsed lung depends upon the size of the bronchus which is occluded When obstruction of a main bronchus takes place, atelectasis of the corresponding whole lung occurs When obstruction of a primary division of a main bronchus takes place collapse of one lobe of the lung occurs If obstruction occurs in the peripheral bronchi segmental or lobular atelectasis or collapse of a small group of alveoli may occur

It would be impossible to enumerate all the conditions under which bronchial obstruction occurs The most common primarily are disease processes which affect the bronchopulmonary system Not infrequently, pathologic lesions involving the mediastinum e g the lymph nodes esophagus heart and great vessels predispose to bronchial obstruction On occasion, lesions of the vertebrae may be contributing factors The conditions have been conveniently divided by Holinger and Andrews [2] into three groups (1) intrabronchial (2) endobronchial and (3) extrabronchial The following is the outline of the etiology of bronchial obstruction

- I Intrabronchial Obstructions
  - A Endogenous
    - 1 Secretions
    - 2 Exudates
    - 3 Broncholiths
    - 4 Contents of ruptured lymphnodes

* For congenital atelectasis see page 314

B Exogenous
  1 Foreign bodies
  2 Aspirated stomach contents
II Endobronchial Obstructions
  A Congenital web
  B Non specific inflammatory processes
    1 Edema
    2 Infiltration
    3 Cicatricial stenosis
  C Specific inflammatory processes
    1 Tuberculosis
      (a) Edema
      (b) Infiltration
      (c) Granulomas
      (d) Ulceration
      (e) Stenosis
    2 Syphilis
    3 Rhinoscleroma
    4 Leprosy
  D Distortion of the walls
    1 Kinking
    2 Twisting
  E Neoplasms
    1 Benign
    2 Malignant
III Extrabronchial Obstructions
  A Inflammatory
    1 Enlarged lymph nodes
    2 Mediastinal abscess or phlegmon
    3 Lesions of the vertebra
  B Cysts
    1 Pulmonary
    2 Mediastinal
  C Emphysema
  D Neoplasms
    1 Mediastinal
    2 Pulmonary
    3 Esophageal
  E Cardiovascular
    1 Aneurysm
    2 Heart
      (a) Dilatation of left auricle
      (b) Enlargement (congenital heart disease)
      (c) Anomalies
  F Esophageal foreign bodies

According to Holinger and Andrews,[2] the intrabronchial obstructions present the most striking and illustrative examples of the various effects of bronchial obstruction Into this division fall the cases of intrabronchial foreign bodies the bronchial obstructions produced by exudates in laryngotracheobronchitis, atelectasis produced by the thick plugs of asthma and postoperative massive collapse of the lungs

[illegible]

and of firm consistency These areas are usually sunken below the surrounding surface of the healthy lung When there is obstruction of one or two major lobar bronchi, an extensive atelectasis occurs This collapse and shrinkage [illegible]

It is now known that numerous openings allowing a collateral circulation of air, exist between the segments of a lobe This mechanism is of major clinical significance from the standpoint of the prevention of lobular atelectasis and infection As Van Allen and *Lindskog*[3] *point out, were it not for this mech*anism, lobular atelectasis would be occurring continually, as a small bronchiole may be blocked so readily by a minute plug of mucus during sleep They also add that "a bronchial tree made up of blindly terminating branches would be as inefficient as a blood vascular system consisting of end vessels" However, if the intercommunications are closed by secretion or damaged by disease, a lobular atelectasis will invariably follow bronchial obstruction Also, it has been clearly shown that the essential factor which exists in the formation of the linear "plate-shaped" atelectasis occurring at the bases of the lungs, especially in patients with multiple rib fractures, coma, kyphoscoliosis and after abdominal operations, is the *absence of collateral ventilation through shal*low breathing[4] Shallow breathing may result from narcosis or if breathing is impeded by pain or paralysis of the respiratory muscles.[4] Fleischner,[5] who described this condition from necropsy findings, was the first to explain its formation adequately According to him, an obstruction of a segmental bronchus causes the collapse of a portion of the lobe The collapsed segment then retracts, and as the surrounding healthy alveoli undergo compensatory dilatation, the affected tissue assumes a linear shape, occupying a horizontal position rather than the usual triangular density radiating from the hilus Keyser[6] was able to confirm these observations

Clinical Manifestations The symptoms usually vary with the cause and with the extent of the atelectatic involvement If small areas of lung are involved, there may be an absence of signs or symptoms, larger areas may cause severe dyspnea The plugging of the larger bronchi in addition to incapacitating dyspnea may cause rapid shallow respirations tachycardia and often cyanosis If the obstruction is removed, the symptoms may disappear rapidly When a whole lung is involved a flattening and immobility of the affected side of the chest is usually present The trachea and mediastinal structures are appreciably displaced toward the affected side The percussion note is dull over the collapsed lung Hyperresonance or tympany may be heard over the overstretched lung The breath sounds may be diminished or absent

Diagnosis The diagnosis of atelectasis can be established usually by x ray examination Whatever the cause, certain roentgenographic characteristics are always present The atelectatic area appears in the roentgenogram as a dense consolidation homogeneous in character On occasion, these areas are indistin-

[illegible]

e

f

value in these conditions

Prognosis The prognosis depends upon the underlying cause If the obstruction disappears spontaneously or is removed, the atelectasis generally disappears If there is secondary exudate formation, the accumulation of edematous fluid or the development of fibrous tissue, pneumonitis, pulmonary edema or pulmonary fibrosis, respectively, may result

Treatment The treatment of atelectasis, whenever possible, is mainly preventive and *is directed to the causes which have given or are* likely to give rise to the condition The object is (1) to remove the bronchial obstruction and (2) to obtain adequate pulmonary ventilation In simple or lobular atelectasis generally no treatment is necessary as the condition usually clears spontaneously Patients with persistent atelectasis for a few days require bronchoscopic examination Whenever the atelectasis is secondary to a foreign body, bronchoscopic intervention is mandatory In some instances in which the bronchial orifice is the site of unyielding disease, e g, fibrosis or tumor, only lobectomy or pneumonectomy is adequate In certain cases in which atelectasis results from extrabronchial lesions surgery may prove of value

ACUTE MASSIVE COLLAPSE OF THE LUNG

This term is usually restricted to an acute collapse of a large area of one or both lungs The condition is most often a postoperative complication * Occasionally, it results from other causes, e g, asthma, pneumonia, aspiration of foreign material (blood, water, solids) and paralysis such as that in diphtheria or poliomyelitis

While differences of opinion exist regarding the mechanism by which acute massive collapse is produced, most physicians believe that a combination of factors prevail They are (1) immobilization or diminished activity of the diaphragm and the muscles of respiration, (2) obstruction of the bronchial tree and (3) obtundation of the cough reflex Jackson[7] has demonstrated that bronchial obstruction by thick secretions is present in the majority of patients postoperatively He further emphasized that bronchoscopic removal of the secretions, if accomplished in the early stages, is successful in relieving the atelectasis in a large percentage of cases

In cases in which it is most difficult to demonstrate an obstructive element, it is assumed that a reflex bronchial constriction, in association with increased secretion, may be the cause of atelectasis In this regard de Takats[8] and his associates have shown experimentally that blunt injuries to the chest as well as intra abdominal manipulations may cause reflex bronchial spasm He was able to prevent the condition experimentally by preliminary vagal section Henderson[9] has emphasized the importance of decreased activity and bed [illegible]

the pooling of mucus in the bronchi In this way atelectasis is favored This explains the occurrence of atelectasis in patients with neuro-

[illegible]

ollapse

There

is dyspnea, pain in the chest, tachycardia and tachypnea of a shallow character (40 to 60 per minute) The temperature ranges from 100°

* For postoperative pulmonary atelectasis see page 451

to 104°F and the leukocyte count from 10,000 to 20,000 per cu mm In severe cases the heart and mediastinum are drawn right over to the affected side X ray examination reveals a dense opacity with displacement of the heart and mediastinum to the affected side of the chest, with an immobility of the corresponding hemidiaphragm which is displaced upward The motions of the affected side are markedly limited and the breath sounds are diminished or absent

The condition has to be differentiated from pneumonia, pulmonary embolism, pleural effusion and pneumothorax

Treatment The cause, if detected should be removed at once In these situations bronchoscopic aspiration is almost always indicated and, when it is should be performed immediately Other important measures are included in the following section on postoperative pulmonary complications

REFERENCES

1 SPAIN D M Acute non aeration of lung pulmonary edema versus atelectasis *Dis of Chest* 25 550, 1954
2 HOLINGER P and ANDREWS A H Bronchial obstruction signs, symptoms and diagnosis *Am J Surg* 54 193 1941
3 VAN ALLEN C M and LINDSKOG G E Intra alveolar pores *Surg Gynec & Obst* 53 16, 1931
4 BAARSMA P R, DIRKEN, N J and HUIZINGA E Collateral ventilation in man *J Thoracic Surg* 17 252 1948
5 FLEISCHNER, F Atelektase und Gerichteter Kollaps der Lunge *Fortschr a d Geb d Rontgenstrahlen* 53 607 1936
6 KEYSER S Nederl Tijdschr Geneesk, 6084 193 Cited by Baarsma P R et al 4
7 JACKSON C and LEE W E Acute massive collapse of the lungs *Ann Surg* 82 364 1925
8 DE TAKATS G FENN, G K and JENKINSON E G Reflex pulmonary atelectasis *J A M A* 120 686 1942
9 HENDERSON, Y Atelectasis massive collapse and related postoperative conditions *Bull New York Acad Med* 11 639 1935

55

Postoperative Pulmonary Complications

ROBERT M JANES, M D, Toronto, Canada

From the Department of Surgery, The Banting Institute, University of Toronto, Toronto Canada

POSTOPERATIVE pulmonary complications occur when obstruction develops in the lumen of the bronchial tree or in the blood vessels of the lung The bronchial obstruction is commonly due to the patient's failure or inability to rid himself of his own secretions but may result from the aspiration of foreign material, such as blood, gastric or intestinal secretions or tissue It is generally held that the usual vascular accident is the lodgment in a pulmonary artery of an embolus or emboli formed of thrombi displaced from peripheral vessels There is, however, another school of thought which contends that a more frequent occurrence is primary thrombosis in the pulmonary artery Cummine and Lyons[1] have advanced this hypothesis, and Dew[2] of the same school has only recently supported this point of view and suggested that efforts to prevent pulmonary embolism by the ligation of peripheral veins have failed because they were founded upon a wrong concept

It is fortunate that many of the measures which can be employed to lessen the incidence of bronchial complications are equally important in reducing the frequency of vascular occlusion For the sake of clarity it is necessary, however, to discuss the two conditions under separate headings

ATELECTASIS

The term "atelectasis" was used first by Jörg in 1835 In 1811 Schenck described what would now be interpreted as atelectasis of the lungs in children dying shortly after birth In 1828 M Louis recognized in adults the condition which we know now as postoperative pulmonary atelectasis Clinical interest in the condition may be said to date from William Pasteur's presentation in 1890[3] and, on this continent wide recognition was given to the publication of Scrimger in 1921[4] It took some time to establish bronchial obstruction as the causative factor and to differentiate the condition from pulmonary embolism

It is more likely to occur in men than in women, in those suffering from an acute or chronic bronchial disease, including that produced by smoking, and at least in northern climes, in the winter than in the summer months Age and chronic debility contribute to its occurrence It is far more common after abdominal, and particularly upper abdominal operations than after other procedures Pulmonary edema, which is more likely to occur in cardiac insufficiency, in burns and probably following chest trauma, aids in its development

Diagnosis Recognition of the condition depends primarily upon familiarity with its clinical picture and an awareness, particularly on the part of the house staff, of the necessity for attention to the chest in the postoperative period An elevation of temperature, pulse and respiration within forty-eight hours after operation is the warning sign There may be a vague sense of dyspnea or inability to fully aerate the lung There may or may not be decreased movement of the chest on the side affected Decreased resonance is usually present but may be difficult to detect Diminished air entry is always present and there are usually fine and medium moist rales in the early stages Elevation and some decrease in movement of the diaphragm is almost the rule after upper abdominal procedures Great difficulty often arises in deciding whether the patient is suffering from atelectasis alone or atelectasis which is a complicating factor of a subphrenic collection In a gross lesion the screen and x-ray will confirm the diagnosis but in a diffuse patchy lesion due to the blocking of many small bronchi, the clinical findings are more important. Many such cases of patchy atelectasis are undoubtedly diagnosed

1A 1B

FIG 1 A and B postero-anterior and lateral films showing class c left lower lobe atelectasis

2A 2B

FIG 2 A pulmonary embolism three weeks after hysterectomy B same case two weeks later

as chronic bronchitis while the more massive lesions are still all too frequently labeled as postoperative pneumonia Bronchopneumonia is almost inevitable if the block cannot be removed from the bronchus but it is not the primary lesion Should pneumonia supervene a small proportion of cases will develop abscess and bronchiectasis or both Occasionally when there is a massive block of a lower lobe or even a main bronchus the onset is sudden and severe with great respiratory distress cyanosis, great anxiety and a sense of impending death

3A 3B

FIG 3 A uterine injection of iodol after the completion of a menstrual period B chest film four days later showing iodol in lung Clinical picture of pneumonia

such cases may be difficult to distinguish from massive embolism Mortality from atelectasis is small but the morbidity associated with it is great (Figs 1 to 3)

PROPHYLAXIS

The Preoperative Period Patients suffering from acute respiratory infections should not be operated upon unless operation is imperative It is probably wise to postpone operation for two to three weeks although with the use of antibiotics a somewhat shorter interval may suffice

The smoker with chronic bronchial irritation should stop smoking for a period of at least *two to three weeks and if the bronchial changes* are severe somewhat longer

Patients with bronchiectasis or severe chronic bronchitis should be placed upon postural drainage for ten days to two weeks In those patients with copious sputum this is best accomplished by a period upon an inclined frame with the head 15 to 18 inches lower than the feet Antibiotics should usually be given

It is the patient with thick tenacious sputum who is particularly liable to atelectasis and for that reason one doubts the wisdom of giving atropine It is better to give expectorant mixtures which liquefy the sputum and make it easier to raise or to use a steam tent in the pre- and postoperative period

Operations upon a patient with a full stomach should be avoided If an anesthetic must be given too soon after food a stomach tube should be passed and particularly in the presence of intestinal obstruction a duodenal tube should be utilized during the operation

The necessity for deep breathing in the postoperative period and the need for coughing to clear secretions should be discussed with the patient before operation particularly in those thought likely to develop chest complica

no evidence that inhalation anesthesia carries a greater risk of postoperative atelectasis than does spinal anesthesia An unusually high incidence after inhalation anesthesia is more likely to be related to poor preoperative preparation inexpert administration of the anesthetic and inadequate postoperative care Similarly the anesthetic agent seems to make little difference The use of local anesthesia may lessen the danger but does not remove it

The lightest level of inhalation anesthesia that is adequate for the surgical procedure

would seem desirable The anesthetic agent should be stopped as soon as possible in order that the cough reflex may return shortly after completion of the operation Heavy preoperative sedation and particularly the use of long acting barbiturates should be avoided Spinal anesthesia in association with long acting heavy sedation is undesirable

Aspiration of mouth secretions or intestinal contents should be avoided by the use of suction In cases in which the danger is great it is wise to depress the head of the table so that secretions will gravitate into the mouth where they may be aspirated In operations on the upper air passages mouth and throat aspiration of secretions or blood into the trachea should be prevented by the use of an intratracheal tube with a cuff or packing in the pharynx

Following many operations upon the chest and always when there is any question of the presence of secretions or blood in the tracheobronchial tree the air passages should be cleared by suction and if there is any doubt a bronchoscope should be passed before the patient leaves the table

The Postoperative Period The introduction of recovery rooms to which all patients are returned from the operating room has reduced pulmonary complications Skilled attention from specially trained personnel is always available together with all necessary equipment

Whenever possible patients should be placed in bed upon their side not upon their back when they leave the operating table and preferably the foot of the bed should be raised In this position secretions gravitate into the mouth and may be sucked out when necessary Sedatives should be withheld until bronchial secretions have been cleared by coughing Deep breathing and coughing should be insisted upon at frequent intervals It is apparently true that morphine depresses the activity of the cilia in the bronchial tree but few patients will breathe deeply or cough if the efforts are too painful The necessity for deep breathing [illegible] the patient co-operates and does deep breathing and coughing ten to fifteen minutes after the [illegible]

chest and diaphragm moderate support lessens the pain of coughing and imparts a sense of security Carbon dioxide inhalation is useful in those patients who otherwise refuse to cough and breathe deeply but it should not be used as a substitute for good nursing control Particularly in chest cases intercostal nerve block should be used when pain is interfering seriously with the clearing of secretions Gastric and intestinal suction tubes undoubtedly increase nasal pharyngeal and tracheal secretions but their value in controlling distension outweighs these disadvantages Their use should be discontinued however as early as possible In certain cases the prophylactic use of antibiotics is advisable Finally active movement in bed and early ambulation tend to lessen the incidence of chest complications Elevation upon a Gatch frame undoubtedly makes the clearing of secretions more difficult interferes with aeration of the lung bases and encourages immobility The nurse should not be allowed to elevate the Gatch frame for longer than half hour periods until the patient [illegible] bed and preferably not

upon the opposite side and encouraged to cough forcibly while the chest and abdomen are supported by the hands of the attendant Continuous short hacking coughs are useless and merely tire the patient In certain cases the use of catheter suction as advocated by Haight is useful If these attempts are not successful within a relatively few hours particularly if the area is large bronchoscopy should be employed Bronchoscopy becomes necessary fairly frequently in postoperative chest cases and following severe chest injuries and head injuries but should be required rarely in others If the obstructing material is not removed early extensive blocking of the smaller air passages develops air is absorbed from the lung distal to the obstruction and no force can be developed to dislodge the offending material Re expansion under such circumstances is certain to be slow and infection is likely to enter by way of the bronchi If antibiotics are not being given when the lack of aeration is recognized they should be started

at once It is best to prevent atelectasis by suitable prophylactic measures and failing this, to recognize it in its early stages when it can be relieved as a rule by a somewhat more

that it is her responsibility to insist upon these measures being carried out If the patients are given a reasonable explanation of why these exercises are necessary, they will, with few exceptions, co-operate It is in those exceptions, for the most part, that the use of carbon dioxide becomes necessary

VASCULAR COMPLICATIONS

The tendency to thrombosis in the postoperative period is probably related more to immobilization in bed than to any specific changes in the blood or vessels as a result of the operation Analyses of the cases of thrombosis from various hospitals have shown that the condition is not, in fact more common in patients upon surgical than medical wards It

heart action seems a definite predisposing factor, and in relation to this a period of prolonged uncontrolled operative and postoperative shock would appear to increase the likelihood of its occurrence Strangely, so far as I am aware, prolonged operations during purposely produced periods of hypotension have not increased its incidence Infection was thought at one time to be a predisposing factor but no noticeable decrease in frequency over a number of years became evident with the virtual elimination of infection The liberation of thromboplastin from damaged tissues and the increase in platelets and fibrinogen in the postoperative period would seem important The greatest tendency to thrombosis is present seven to ten days after operation, however, and not in the immediate postoperative period Furthermore, thrombosis of major vessels is uncommon after the major tissue injury of thoracoplasty, certainly it is no more frequent than after appendectomy and herniotomy Increased viscosity of the blood whether from polycythemia or simple dehydration is apparently a contributing factor On the other hand, uncontrolled anemia and low blood volume seem to increase its incidence Confinement to bed in the preoperative period increases the danger

It is apparent, therefore, that although no specific factor can be held responsible for the occurrence of thrombosis, it has occurred more frequently under certain conditions In the preoperative period excessive concentration of the blood should be overcome, anemia and low blood volume should be corrected, infection should be controlled if possible and a good heart action should be encouraged Reasonable activity should not only be permitted, but also insisted upon up to the time of operation During operation unnecessary tissue injury should be avoided and blood loss should be substituted for by transfusion Prolonged pressure upon the calves of the legs with the possible damage to endothelium should be avoided and when used, stirrups should cause the least possible interference with vessels and circulation in the legs

In the postoperative period the very things that have been suggested to decrease bronchial complications are important in lessening the incidence of thrombosis—frequent change of position, if possible with the active participation of the patient, and deep breathing which improves venous circulation in the chest In addition, there should be active movement of the limbs, particularly the ankles and toes, since this pumps the blood out of the veins of the legs and maintains an active circulation Fowler's position should not be allowed until such time as the patient is moving freely without assistance, and preferably not until he is out of bed Under all possible circumstances the patient should be out of bed and taking a few steps about the bed within twenty four to forty-eight hours Leithauser insists that this is too late and that all patients should be out of bed the day of operation[5] When he is up he should not be permitted to sit inactive in a chair for more than short periods of twenty to thirty minutes

Treatment If the usually recognizable evidences of thrombosis in the peripheral veins appear in spite of these precautions, the administration of anticoagulants is usually indicated When evidences of thrombosis are minimal and confined to the calf muscles the application of an elastic bandage and continued exercise and ambulation, as advocated

FIG 4 Fat embolism

by Leithauser seems effective and is probably safe [5] The ligation of major veins in an effort to prevent pulmonary embolism does not seem to have been effective, and although perhaps *justifiable occasionally, it should not be undertaken lightly* The Sydney school of course maintains that it has no place because the peripheral manifestations are only part of changes which are also present in the lung [2]

The diagnosis of a frank pulmonary embolism is not difficult as a rule although without doubt many lesser cases of infarction are common it may be confused with atelectasis at times, but in general atelectasis occurs early in the postoperative period and the vascular changes late Chest films confirm the clinical history and findings in many cases but there may be no recognizable changes in the x ray in *the early stages of quite extensive infarction*

Treatment consists of the use of anticoagulants and the reinstitution of activity as soon as possible In the presence of massive infarction the congestion and swelling lead to a decrease in the size of the lumens of the bronchi and increased secretions Stagnation of secretions makes it easier for pathogenic bacteria to enter by way of the bronchial tree and set up an infection in the devitalized area For this reason the use of antibiotics is indicated

FAT EMBOLISM

Fat embolism may be expected to occur following injuries to long bones, particularly fractures, and occasionally following operative or other trauma to areas in which there is an extensive deposition of fat I venture to say that in the experience of most of us it has been recognized infrequently On the other hand Musselman, Glas and Grekin thought that 52 per cent of 109 injured patients probably had fat embolism [6] Forty one of 125 cases of fatal accidents studied by Robb-Smith showed evidence of gross pulmonary involvement [7] The pathogenesis of the condition is still in doubt It is suggested that embolism occurs when fat globules liberated from the supporting fibrous tissue of the bone marrow are sucked into torn veins Gauss thought that the veins in the bone marrow were held open by the bony wall and unable to collapse as elsewhere [7] Scuder thought the more toxic oleic acid was more likely to be responsible than neutral fat [7] Harris Perrett and McLachlin established that 0 9 cc of neutral human fat per kg of body weight was the lethal single dose for rabbits but *if repeated doses not exceeding 0 5 cc* each were used as much as 0 15 cc per kg of body weight could be given without death although marked pulmonary signs and ataxia and incoordination were produced [8]

The usual history is that of injury, most often a fracture, followed by a short interval (one to three days) in which the only symptoms are related to the injury Pulmonary signs and symptoms develop and consist of cough and sputum with at first impairment of air entry and a few rales and later consolidation Cerebral changes appear drowsiness confusion and finally coma Pallor is a striking feature a hemoglobin level as low as 30 per cent was reported by Harris [8] There is some evidence that shock adds to the seriousness of the occurrence The cerebral changes rather than the pulmonary seem to be the cause of death Many mild cases undoubtedly recover having shown only minor pulmonary symptoms and cerebral confusion

The diagnosis depends upon the history of injury the related symptomatology, more or less characteristic radiographic chest find

ings, the presence of fat in the urine in some cases, and in some, the finding of skin petechiae. (Fig 4)

Early immobilization of fractures is said to be prophylactic Probably no treatment is very effective but the use of oxygen and antibiotics is said to be indicated

LUNG ABSCESS

The majority of lung abscesses are caused by aspiration of infected material, a relatively small proportion are embolic in origin In most series of abscess published some years ago 20 to 25 per cent followed operation, the majority of these operations being upon the upper air passages A few follow aspiration of a major foreign body, such as a tooth, a crown from a tooth or a piece of tonsil Usually, however, a minute portion of septic material lodges in one of the smaller terminal bronchi and it is not realized that there is anything amiss until, in an effort to discover the origin of persistent fever and perhaps pleural pain and cough, an x-ray is made Occasionally at the end of ten days to three weeks a considerable volume of pus is coughed up, but more frequently there is a gradual increase in the amount of sputum raised Aspiration of a considerable quantity of gastric or intestinal contents may induce pneumonia of a septic character and eventually multiple abscesses The mortality from such accidents is high

A lung abscess may be produced by a sterile or septic embolus In the latter case the abscess contains at first only a single organism, for example, Staphylococcus aureus, derived from a focus of osteomyelitis In the former an originally sterile infarct becomes infected with mouth organisms by way of the bronchial tree and the abscess contains the same mixed bacterial flora as though it had resulted from aspiration alone without the predisposing sterile infarction As would be expected septic emboli are frequently multiple

The prevention of aspiration of septic material depends upon careful preparation of those patients in whom the accident could be expected and the expert administration of the anesthetic It is a wise precaution to give antibiotics to the patient known to have had a sterile infarction The use of antibiotics and a minimum of trauma to septic areas will lessen the likelihood of septic infarction Early recognition of the pneumonic focus and adequate antibiotic therapy will abort a high percentage of incipient or potential abscesses at an early stage Lung abscess has now become a rare postoperative complication

REFERENCES

1 CUMMING H G and LYONS R N Study in intravascular thrombosis with some new conceptions of mechanism of coagulation *Brit J Surg*, 35 337–363 1948

2 DEW H Postoperative intravascular thrombosis *Ann Roy Coll Surgeons England*, 13 1–16, 1953

3 PASTEUR, W L Respiratory paralysis after diphtheria as a cause of pulmonary complications with suggestions as to treatment *Am J M Sc*, 99 242 1890

4 SCHRUGER, F A C Postoperative massive collapse of the lung *Surg Gynec & Obst*, 32 486, 1921

5 LEITHAUSER, D J Early Ambulation and Related Procedures in Surgical Management Springfield Ill 1946 Charles C Thomas

6 MESSELMAN M M GLAS W W and GREEN T D Fat embolism *Arch Surg* 65 551–556 1952

7 Editorial Fat embolism *Lancet* 1 196, 1952

8 HARRIS, R I PERRETT T S and MCLACHLIN A Fat embolism *Ann Surg*, 110 1095–1114 1939

XXIII. FUNDAMENTAL CONSIDERATIONS IN PULMONARY SURGERY

56

Indications for Pulmonary Resection

EMIL A NACLERIO, M D, *New York, New York*

From the Thoracic Surgical Services of Harlem and Columbus Hospitals New York New York

THE advent of pulmonary resection has unquestionably revolutionized the *modus operandi* of lung diseases and today many patients suffering from primary malignancy, bronchiectasis, certain tuberculous lesions and numerous other chronic pulmonary conditions have an excellent chance of becoming completely well

Formerly primary carcinoma of the lung was invariably fatal To establish the diagnosis was to pronounce the patient's death sentence Also presenting a hopeless problem were certain cases of pulmonary tuberculosis, especially those with bronchial occlusion Bronchiectasis is another condition which had no satisfactory solution Before the advent of bronchography it was frequently unrecognized and numerous cases were incorrectly diagnosed as unresolved pneumonia Many of these patients were admitted to sanatoria with the mistaken diagnosis of pulmonary tuberculosis In addition numerous patients with varied undiagnosed pulmonary conditions either recovered or succumbed as a result of progression of the disease The autopsy findings in such cases tend to be those of advanced stages of the lesion

However, with the successes obtained through surgical exploration and resection of lung tissue, associated with continued careful correlative teamwork with members of the allied specialties and laboratory services, knowledge relative to pulmonary diseases has increased appreciably and has made an understanding of the diagnosis and management of these disorders of general importance Therefore, it has become advisable that the practicing physician, internist and pediatrician cooperate with the surgeon in the evaluation of patients with pulmonary disease, especially those who are not improving under a medical therapeutic regimen In this way additional diagnostic procedures may be suggested and instituted, in some instances operable cases which may be benefited by surgery may be selected

Fortunately in almost all instances pulmonary resection is an elective procedure, thus allowing ample time for adequate preoperative investigation of the patient by x ray films of the chest, bronchograms endoscopy and differential function tests In this respect the thoracic surgeon may be far better informed concerning the nature, location and extent of the pathologic process than the surgeon who explores for internal disease in other regions of the body However, if the cause of the disease process cannot be established, surgery should not be delayed At exploration the true nature of the lesion can often be determined and a final decision as to the extent of resection necessary can be ascertained

Pulmonary resection may be defined as the removal of an entire lung (pneumonectomy) the removal of one or more lobes of one or both lungs (lobectomy or bilobectomy of right middle and lower lobes), the excision of a bronchopulmonary segment of one or more lungs (segmental resection, unilateral or bilateral), or the resection of a portion of a lung smaller than a bronchopulmonary segment (local or wedge excision)

In this chapter the author attempts merely [illegible] require [illegible] com [illegible] will be [illegible] pe of disease being treated, cardiac disease, pulmonary insufficiency, advanced age, or a combination of factors that combine to form the

so-called "poor surgical risk" may preclude surgical intervention

INDICATIONS FOR PULMONARY RESECTION

Removal of an entire lung or portion of a lung may be indicated in conditions in which the pulmonary tissue is so seriously diseased by neoplasm, infection, vascular damage or injury that its retention will either interfere with the well being of the patient or cause his death These conditions may be classified as follows

I Primary new growths of the lung
- A Malignant
  - 1 Carcinoma
  - 2 Alveolar cell tumor
  - 3 Sarcoma
- B Questionably malignant
  - 1 Bronchial adenoma
- C Non malignant
  - 1 Hamartoma
  - 2 Fibroma
  - 3 Chondroma
  - 4 Lipoma
  - 5 Myoblastoma

II Metastatic "solitary new growths"

III Lipoid pneumonia (paraffinoma)

IV Chronic suppurative diseases
- A Bronchiectasis
- B Lung abscess
- C Gangrene of the lung

V Chronic pulmonary disease with varying degrees of atelectasis pneumonitis and abscess formation (which do not clearly fall into the classification of either bronchiectasis or lung abscess)
- A Chronic pneumonitis cholesterol type
- B Middle lobe syndrome
- C Mucoid impaction of bronchi
- D Spreading suppurative pneumonitis

VI Tuberculosis
- A Bronchial stenosis
- B Destroyed lung or lobe
- C Tuberculous bronchiectasis
- D Tuberculoma
- E Thoracoplasty failure
- F Uncontrollable lower lobe disease
- G Tension and thick walled cavities

VII. Cystic diseases of the lung
- A Non parasitic cysts and cyst like cavities
  - 1 Congenital pulmonary cyst
  - 2 Cystic bronchiectasis
  - 3 Epithelialized cavities following pulmonary suppuration
  - 4 Pneumatocele (localized alveolar or lobular ectasia)
  - 5 Emphysematous bullae
  - 6 Pulmonary blebs
  - 7 Intralobar bronchopulmonary sequestration
- B Parasitic cysts
  - 1 Echinococcic (hydatid) cyst

VIII Fungous infections
- A Actinomycosis
- B Nocordiosis
- C Coccidioidomycosis
  - 1 Specific types of cavities
    - a Giant cavity
    - b Secondarily infected cavity
    - c Blocked cavity
  - 2 Rupture of cavity
  - 3 Non expansible lung
  - 4 Hemoptysis
    - a Continued
    - b Severe
  - 5 Coccidioma, expanding lesion
  - 6 Failure of medical and collapse therapy
- D Blastomycosis
- E Histoplasmosis
- F Aspergillosis
- G Cryptococcosis

IX Cavernous vascular lesions
- A Arteriovenous fistula
- B Capillary hemangioma
- C Endothelioma

X Traumatic injury to lung
- A Large hematoma
- B Expanding hematoma
- C. Profuse or continuing pulmonary hemorrhage
- D Massive subcutaneous emphysema with tension pneumothorax following pneumonolysis

COMMENTS RELATIVE TO DISEASE PROCESSES

Primary New Growths of the Lung

Malignant The principles involved in the removal of pulmonary tissue are simple and

obvious Applied to carcinoma the procedure is basically the same as that accepted for the treatment of gastric, colonic rectal and mammary lesions of a similar nature Today surgeons agree upon the removal of the entire organ which contains the cancerous lesion together with its regional lymphatics Pneumonectomy with resection of mediastinal glands meet these basic surgical requirements offering certain patients a chance of cure and palliation to others In rare cases notably peripheral tumors cure can be obtained by simple lobectomy Lobectomy is also the treatment of choice in patients with a low respiratory reserve a poor cardiovascular system and advanced age In these cases the procedure *should be considered palliative in nature* In patients with malignancy of the lung with mediastinal and chest wall extension a palliative pneumonectomy may be justifiable since the associated secondary infection usually

of lung carcinoma a competent pathologist will aid the surgeon in arriving at an accurate diagnosis Segmental resection or lobectomy may be necessary to establish the diagnosis since a small piece of tissue removed from the periphery of the diseased lung need not be representative of the *pathologic process*

Alveolar cell tumor This rather uncommon neoplasm has been referred to as alveolar cell carcinoma bronchiolar carcinoma and pulmonary adenomatosis Ultimately unless resection is successful the patient dies of asphyxia pneumonia or metastases Its treatment of choice is conservative pulmonary resection This implies lobectomy If the disease extends beyond the lobe with demonstrable lymph node metastases pneumonectomy with mediastinal node dissection is necessary

Sarcoma of the lung Primary sarcoma of the lung is a rare tumor and is treated by surgery similarly to carcinoma The prognosis in these cases appears to be relatively more *favorable* than carcinoma *The diagnosis in these cases is* made only after resection They may not occur locally for long periods of time after resection

Questionable Malignant Neu Growth Bronchial adenoma sometimes referred *to as* carcinoid cylindroma mixed tumor and endothelioma accounts for approximately 80 per

TABLE I*

SALIENT FEATURES OF BRONCHIAL ADENOMA AND BRONCHOGENIC CARCINOMA

	Bronchial Adenoma	Bronchogenic Carcinoma
Average age	37 4 yr	53 2 yr
Sex	Male to female—1 1	Male to female—3 8 1
Average duration of disease before surgery is instituted	5 9 yr	11 3 mo
Clinical picture	Hemorrhages often profuse with sudden onset and termination in termittent episodes of pneumonitis with healthy intervals bronchiectasis common	Hemorrhages usually blood streaked and continuous progressive secondary pulmonary complaints without healthy intervals
X ray findings	Tumor frequently not visible only shadows incident to obstruction are seen	Tumor frequently seen
Bronchoscopic picture	Often pedunculated small pink or yellowish in color carina always sharp and mediastinum free biopsy frequently followed by bleeding	Usually irregular fungating ulcerogranulomatous, non pedunculated, gray or grayish yellow carina frequently blunted and mediastinum fixed bleeding minimal
Metastases	Occasionally regional lymph nodes rarely distant	Regional and distant metastases frequent
Amenability to surgical cure	*Almost 100%*	*10%*
Survival	Long duration	Short duration

* From Naclerio and Langer [1]

cent of the benign bronchogenic growths and is still the subject of much controversy The indecision is due chiefly to accumulated evidence toward consideration of these tumors as potentially invasive and malignant However it is regarded by many as essentially benign A review by Langer and the author of fifteen bronchial adenoma and 305 carcinoma patients treated by Overholt indicates that the conditions should be considered as different and essentially benign rather than as belonging to two grades or stages of the same neoplasm The salient differences are shown in Table I

Bronchoscopic removal was employed in the past for patients in whom there was no serious damage distal to the growth However this method of treatment has been practically abandoned for the following reasons local recurrences danger of serious uncontrollable hemorrhage inability to remove adequate amounts of tumor (the portion of the tumor outside the bronchus is often larger than the intraluminal portion) and in approximately [illegible] per cent of the cases there is evidence of metastases The metastatic lesion may be localized to the regional or mediastinal lymph nodes or may be widespread throughout the body Pulmonary resection is therefore indicated Lobectomy is usually adequate except when the situation of the adenoma necessitates pneumonectomy

Non malignant New Growths Less common tumors of the lung include hamartoma fibroma chondroma osteochondroma lipoma and myoblastoma These tumors possess the features of benign tumors elsewhere in the body i e they are well localized usually round and lack the invasive properties of malignant tumors Frequently they cannot be distinguished from the intrathoracic malignant tumors Fortunately they are almost always near the lung surface and accessible for biopsy Lobectomy is the treatment of choice in dealing with these neoplasms In some instances local excision will suffice while in others segmental resection should be considered

Metastatic Solitary New Growths

Metastatic tumors of the lung are extremely frequent and are associated with many diagnostic difficulties Clinically and roentgenologically they may mimic tuberculosis pneumoconiosis and primary tumor of the lung However solitary pulmonary metastases do occur and may be indistinguishable from a primary growth Surgical removal of a solitary lung metastasis is indicated under certain conditions since there are in the literature enough reports of long survival of patients to make extirpation a rational method of treatment If the primary malignancy has been removed and has been under clinical control for a period of time and a solitary lung lesion is the only sign of metastatic disease resection of lung by local excision, segmental repair or lobectomy may be justifiable In rare instances pneumonectomy may be the treatment of choice

Lipoid Pneumonia

This chronic disease caused by ingestion of oil into the alveolar spaces and sometimes referred to as pulmonary paraffinoma, may simulate atypical pneumonia lobar pneumonia tuberculosis neoplasm infarction a solitary metastatic lesion or bronchiectasis It has been emphasized that pulmonary paraffinoma can mimic lung cancer clinically, radiographically, grossly at the operating table and is even mistakenly called cancer on frozen section In these cases needless pneumonectomy is performed when lobectomy is the treatment of choice According to Davis et al the importance of this disease should not be minimized because it is often disabling In addition they mention that this disease may sometimes be fatal

Chronic Suppurative Diseases

Bronchiectasis This disease may involve a whole lung one lobe two or more lobes a bronchopulmonary segment or more frequently multiple bronchopulmonary segments in both lungs Surgical removal of the affected part constitutes the only rational treatment In properly selected cases cure is practically certain Pneumonectomy is indicated when there is extensive involvement of all lobes in one lung When the lesions are limited to one or two lobes lobectomy and bilobectomy of right middle and lower lobes should be performed Patients with bilateral disease are candidates for palliation or cure with the use of bilateral segmental pulmonary resection performed in two stages

Lung Abscess and Pulmonary Gangrene It is extremely difficult and sometimes impossible to make a differential diagnosis between lung

abscess and pulmonary gangrene In either case one is dealing with destruction of tissue and for this reason there is a tendency to consider the two conditions together The term pulmonary gangrene is ordinarily applied to a massive necrosis of lung tissue without tendency to localization This disorder is much less frequent since the advent of antibiotic agents Secondary infection of the contents of a simple purulent abscess may lead to spreading gangrene On the other hand, some cases of gangrene of the lung become limited and after expectoration of necrotic tissue, the anaerobic infection subsides and a simple abscess remains

Satisfactory results obtained today in the treatment of lung abscess are accounted for by the more prompt application of surgery and,

is chronic with associated lung damage such as fibrosis, bronchiectasis, atelectasis (the chronicity of the case constitutes the most frequent indication), (2) when multiple cavities exist in one or more lobes, (3) when there is persistent disease following drainage operations, (4) when a bronchogenic neoplasm is suspected as an underlying cause, (5) when the lung abscess is associated with a retained foreign body, and (6) when the condition is found in

ing drainage On the other hand, lobectomy is well tolerated by children

Chronic Pulmonary Disease with Varying Degrees of Atelectasis, Pneumonitis, Abscess and Bronchiectasis Formation

Chronic Pneumonitis, Cholesterol Type. The descriptive term "chronic pneumonitis, cholesterol type," has been used to designate a clinical entity variously described for many years as a subacute chronic interstitial or fibrous pneumonia[6] This condition is characterized by the deposit within the pulmonary parenchyma of high concentration of cholesteral and cholesterol esters In the majority of these cases a preoperative diagnosis of cancer of the lung is made Since the pneumonic process usually involves the entire lobe, lobectomy usually suffices in effecting a cure[7]

Middle Lobe Syndrome This disease entity, a middle lobe atelectasis of non tuberculous origin with suppurative changes, has been described by Graham et al[8] Inflammatory processes involving the middle lobe and on occasion the lower or upper lobes on the right side may result in enlargement of the peribronchial lymph nodes Since the lymph nodes are so arranged about the middle lobe bronchus only moderate enlargement of them will cause complete bronchial occlusion resulting in atelectasis Secondary infection will invariably lead to pneumonitis, lung abscess or bronchiectasis In these cases a middle lobe lobectomy is the only satisfactory method of treatment

Mucoid Impaction of the Bronchi This descriptive terminology designates a disease entity found in patients with an underlying condition of asthma or chronic constrictive bronchitis The mucoid impaction of the bronchi results from a localized accumulation of inspissated mucus in the bronchi This condition may simulate neoplasm, abscess and tuberculosis clinically and roentgenologically According to Shaw[9] who has described this entity, indications for resection are (1) persistence of suppuration with destruction of mucus, (2) repeated hemoptyses from the associated cystic bronchiectasis, and (3) the necessity of ruling out neoplasm when the diagnosis is not certain

Spreading Suppurative Pneumonitis This condition has been described by Sellors et al[10] as a non specific inflammation with cavity formation, in some instances leading to death from toxemia but more often to permanent damage to the lung[6] They emphasize that "radical excision of a lung or lobe may be the only method of saving the life of certain patients, in others whose life is not in immediate danger, it may be the only method of dealing with the lesion"

Tuberculosis

In pulmonary tuberculosis the use of potent antimicrobial agents in combination with surgical therapy has rendered previously dangerous procedures relatively safe At the present time most thoracic surgeons agree that the

lobe,

reu-

loma, (5) thoracoplasty failure, (6) uncontrollable lower lobe disease, and (7) tension and thick-walled cavities

Indications for resection are debatable in patients who have either a small non-cavitary fibrocaseous residuum or small closed cavities In these cases the "Snip operation" or local excision method of treatment has been advocated [illegible] Further trial is necessary before an adequate evaluation of the procedure can be made

Cystic Diseases of the Lung

These diseases are of special interest because the term "cystic diseases of the lung" has been used to designate a wide variety of pathologic entities The lesions involved in this group are congenital pulmonary cyst, cystic bronchiectasis, epithelialized cavities following pulmonary suppuration, pneumatocele (localized alveolar or lobular ectasis), chronic interstitial pneumonitis with emphysema, emphysematous bullae, pulmonary blebs and echinococcic hydatid) cyst Intralobar bronchopulmonary sequestration may be conveniently added to this group

The presence or absence of an epithelial lining in these lesions controls the symptomatology and for the most part dictates the treatment Epithelialized cysts are best treated by pulmonary resection similarly to bronchiectasis and chronic abscess

Pulmonary cysts not lined with epithelium, i e, emphysematous blebs and bullae are not generally understood A thorough knowledge of the existing condition and associated alteration in the physiodynamics of the chest is necessary in planning the best type of therapy In some cases pulmonary blebs and bullae, even when large, can be asymptomatic and frequently will disappear spontaneously These patients are obviously not candidates for surgery In other cases in which there is obstruction to the egress of air in the bronchus (check valve mechanism) the cyst will balloon out and acquire large dimensions, in extreme cases filling the larger portion of both pleural cavities and causing incapacitating dyspnea Until a few years ago there had been no satisfactory treatment for this condition Herd and Avery[illegible] reported on fifteen patients with large emphysematous bullae and two with bronchogenic cysts who were greatly benefited by intracavitary (Monaldi) suction Others have experienced good results with lobectomy and pneumonectomy Langer and the author[illegible] described the use of local excision technic with excellent results This procedure is contraindicated, however, in the presence of an epithelial lining In cases in which a low respiratory reserve exists the use of intracavitary suction may prepare the patient for thoracic exploration and definitive surgical therapy.

In intralobar bronchopulmonary sequestration a lesion exists when there is essentially a cystic condition in a segment of a lower lobe, supplied by an anomalous artery arising from the lower thoracic or upper abdominal aorta The treatment of choice in these cases is either segmental resection or lobectomy The author has had experiences with three such cases, one having been reported in 1950[illegible]

Pulmonary hydatid disease may also constitute an indication for pulmonary resection When spontaneous expectoration and evacuation is present, healing may occur without complications In patients in whom secondary infection of the cyst with abscess formation is seen, the condition should be treated as a pulmonary abscess Lobectomy offers the only chance for cure when repeated hemoptysis occurs and may be considered in the presence of many scattered cysts in one lobe

Fungous Infections

Resection may be the therapy of choice in selected chronic localized pulmonary fungous infections that remain after adequate medical treatment has been instituted

Actinomycosis Surgery is reserved for those cases with irreversible damage to the lung This damage may be based in part on secondary pyogenic invaders Pleural contamination invariably requires surgical drainage, but pulmonary lesions usually drain through the bronchi The mortality in untreated pulmonary actinomycosis is not known but may approach 90 per cent This has been materially reduced but not eliminated by sulfonamide penicillin-iodide therapy, supplemented by surgical excision of one or more lobes[illegible]

Nocardiosis In this condition pulmonary resection may be required when the differential diagnosis from neoplasm remains in doubt[illegible]

Coccidioidomycosis Most patients with pulmonary coccidioidomycosis are asymptomatic Some may have moderate to severe symptoms. Frequently some patients with moderate to extensive lung infiltrations become asymptomatic but may harbor a thin wall cavity which persists for months and years If a patient has persistent cough and associated expectoration

of sputum the cavity area should be removed by wedge resection segmental resection or lobectomy [14] Cotton outlines the indications for resection as follows [6] (1) Specific types of cavities giant cavity, secondarily infected cavity and blocked cavity, (2) rupture of cavity, (3) non expansible lung (4) hemoptysis continued and severe (5) coccidioma expanding lesion (6) failure of medical and collapse therapy

Blastomycosis Buechner et al [17] state that the management of blastomycosis should simulate that of pulmonary tuberculosis They suggest that [illegible]

sults in pulmonary blastomycosis just as streptomycin and para aminosalicylic acid combined with surgery have improved the prognosis of tuberculosis

Recent discovery of the effectiveness of stilbamidine in the treatment of pulmonary blastomycosis has apparently altered the prognosis of this disease Acree et al [18] on the basis of short term observations state that the prognosis of pulmonary blastomycosis is excellent when treated with 2 hydroxystilbamidine followed by surgical resection if necessary

Histoplasmosis As yet there is no specific

performed for cavitational disease According to Puckett[19] pulmonary histoplasmosis is a common disease entity which achieves surgical importance mainly because of its propensity to leave residual foci that mimic tuberculosis neoplasm or other diseases

Aspergillosis In bronchopulmonary aspergillosis localized abscesses should be drained and granulomatous areas excised if possible Gerstl et al [21] and Yesner and Hurwitz[22] had success with pulmonary resection for localized manifestations of this disease

Cryptococcosis Baker[23] refers to three cases of pulmonary cryptococcosis treated successfully by resection Dormer et al [24] reported a case in a twelve year old boy treated successfully by pneumonectomy Postoperatively meningeal symptoms developed and positive inoculation in the guinea pig was obtained from the spinal fluid These symptoms responded to large doses of iodides and the patient was discharged two weeks later Froio and Bailey [25] in reporting a successful cure emphasized that pulmonary cryptococcosis without meningeal involvement is unusual and suggest that if the disease is local and can be diagnosed and removed before meningeal spread has occurred the patient may be cured It should be mentioned that the primary pulmonary lesion may be inconsequential or never detected and the patient appears with a brain or meningeal lesion

Cavernous Vascular Lesions

These lesions are large and complex communications between the pulmonary arteries and veins Synonyms and related terms of these lesions are arteriovenous fistula (varix) arteriovenous aneurysm hemangioma and telangiectasis [26] The presence of an arteriovenous fistula with or without symptoms is sufficient indication for surgical treatment Treatment of this condition consists of surgical interruption of the fistula or excision of the vascular mass Because of the difficulties associated with ligating the communication between the artery and the vein local or segmental resection is the procedure of choice In most patients however lobectomy or pneumonectomy is necessary because of the size and location of the vascular channels Maier [7] has pointed out that because of the possibilities of associated vascular anomalies one should be certain that adequate channels remain for the return of blood to the left side of the heart

Capillary hemangioma and endothelioma are rare in the lungs and when they occur have the characteristics of similar tumors elsewhere In these cases segmental resection may be the treatment of choice [26]

Traumatic Injury to Lung

In the case of perforating or penetrating injuries to the lung conservative measures are usually sufficient Occasionally however it is imperative to enter the chest whereupon segmental repair and local excision may suffice If a hematoma exists which is of sufficient size to involve an entire lobe lobectomy is indicated In the event of an expanding hematoma which threatens to perforate either lobectomy or pneumonectomy is advisable depending upon the location of the hematoma [27] Occasionally damage may be so extensive that pneu

monectomy offers the only hope of controlling hemorrhage and shock Emergency thoracotomy must be performed in some instances of closed pneumonolysis when early massive subcutaneous emphysema with tension pneumothorax or profuse hemorrhage into the pleural cavity occurs Treatment may then consist of segmental repair, local excision or resection

SUMMARY

1. An outline of conditions which may require pulmonary resection is presented

2 Serious cardiac disease, borderline ventilatory function, advanced age or a combination of factors that combine to form the so-called "poor surgical risk" may preclude surgical intervention

3 Brief comments relative to the disease processes outlined are made

REFERENCES

1 NACLERIO, E A and LANGER, L. Adenoma of the bronchus review of fifteen cases *Am J Surg*, 75 532 547, 1948

2 SWEET R H Thoracic Surgery p 172 Philadelphia 1950 W B Saunders Co

3 BERG, B and BURFORD, T H Pulmonary paraffinoma (lipoid pneumonia) *J Thoracic Surg* 20 418–428, 1950

4 DAVIS E W and HAMPTON A O BECKMAN, F E, WINSHIP, T Lipoid pneumonia simulating tumor *J Thoracic Surg*, 28 212 219 1954

5 NACLERIO, E A and HOCHBERG, L A Segmental resection in pulmonary surgery *Am J Surg*, 79 488–498, 1950

6 WADDELL, W R, SNIFFEN R C and WHYTEHEAD, L L The etiology of chronic interstitial pneumonitis associated with lipid deposition *J Thoracic Surg* 28 135–144 1954

7 WADDELL, W R, SNIFFEN, R C and SWEET R H Chronic pneumonitis—its clinical and pathologic importance Report of 10 cases showing interstitial pneumonitis and unusual cholesterol deposits *J Thoracic Surg*, 18 707 737, 1949

8 GRAHAM, E A, BURFORD, T H and MAYER, J H Middle lobe syndrome *Postgrad Med* 4 29–34, 1948

9 SHAW, R R Mucoid impaction of bronchi *J Thoracic Surg*, 22 149–163 1951

10 SELLORS T H, BLAIR, L G, HOLCHTON L E, THOMPSON, V C and PRYCE, D M Spreading suppurative pneumonitis *Thorax* 1 146 181, 1946

11 RYAN, B J, MEDLAR L M and WELLES E S Simple excision in the treatment of pulmonary tuberculosis *J Thoracic Surg*, 23 327–340, 1952

12 HEAD, J R and AVERY, L E Intracavitary suction (Monaldi) in the treatment of emphysematous bullae and blebs *J Thoracic Surg*, 18 761–776, 1949

13 NACLERIO L A and LANGER, L Pulmonary cysts special reference to surgical treatment of emphysematous blebs and bullae *Surgery*, 22 516–524, 1947

14 SMITH D T Therapy for the systemic fungous infections *New York State J Med*, 54 2303–2309 1954

15 LINDSKOG, G E and LIEBOW, A A Thoracic Surgery and Related Pathology New York, 1953 Appleton-Century Crofts, Inc

16 COTTON, B H and BIRSNER, J W Surgical treatment in pulmonary coccidioidomycosis *J Thoracic Surg*, 20 429–443 1950

17 BUECHNER, H A, ANDERSON, A E, STRUG, L H, SEABURY, J H and PEABODY, J W, JR Pulmonary resection in the treatment of blastomycosis *J Thoracic Surg*, 25 468–470, 1953

18 ACREE, P A, DECAMP, P T and OCHSNER, A. Pulmonary blastomycosis—a critical analysis of medical and surgical therapies, with a report of six cases *J Thoracic Surg*, [illegible] 2 1954

19 HODGSON, C. H, WEED, L A and CLAGETT, O T Pulmonary histoplasmosis review of published cases and report of an unusual case *J Thoracic Surg*, 20 97, 1950

20 PUCKETT T F Pulmonary histoplasmosis *Am J Surg*, 90 92, 1955

21 GERSTL, B, WEIDMAN, W H and NEWMAN, A V Pulmonary aspergillosis Report of two cases [illegible]

22 [illegible] 310 1950

23 BAKER R D Resectable mycotic lesions and acutely fatal mycoses *J A M A*, 150 1579, 1952

24 DORNER B A, FREEDLANDER, J, WILES, F J and SIMON, F W Tumor of the lung due to cryptococcus histolyticus *J Thoracic Surg*, 14 322 1945

25 FROIO, G F, and BAILEY, C P Pulmonary cryptococcosis Report of a case with surgical cure *Dis of Chest*, 16 354 359 1949

26 LIEBOW, A A Tumors of the lower respiratory tract Atlas of Tumor Pathology, Section V, [illegible]

27 [illegible] J W V, JR Article to be published

65

Antimicrobial Agents

NICHOLAS D D ESOPO M D, *West Haven Connecticut*

A GREAT deal has been learned about anti tuberculosis drugs during the past nine years yet many questions remain unanswered relating to drug regimens and to the influence of chemotherapy in general upon the indications for thoracoplasty, resection and bed rest Diverse clinical practices appear to give equally satisfactory results In fact, few applications of chemotherapy can be carried out with a deep conviction that they are the best Many clinical studies are incomplete It seems best, therefore, to discuss the present status of chemotherapy of pulmonary tuberculosis simply as an interpretation of the clinical and laboratory data upon which current clinical practices now rest

CHANGES IN THE MORPHOLOGY OF TUBERCULOUS LESIONS*

The antituberculosis drugs we now have are chiefly bacteriostatic and their therapeutic effect results from the suppression of tubercle bacilli in the tuberculous lesion Morphologic changes in the lesions are not qualitatively different† from those which occur in the natural course of the disease or with bed rest and collapse therapy Morphologic changes can be described as if they occurred in three different types (1) the non necrotic lesion, (2) the solid necrotic lesion and (3) the necrotic lesion which has liquefied and sloughed to form a cavity This is an oversimplification which the clinician may find useful as he follows the evolution of lesions on serial x rays during chemotherapy

The non necrotic lesion comprises both the non necrotic tuberculous lobular pneumonia *per se* and the so-called non specific "perifocal reaction' The term 'tuberculous lobular pneumonia' is reserved for the inflammatory process due to the tubercle bacillus itself, the term "perifocal reaction has been given to the collections of cells which are presumably a non specific response to tuberculoprotein in a hypersensitive host Emphasis is placed upon the non necrotic character of both types of exudates quite apart from their pathogenesis In both processes the inflammatory cells are viable and there has been no death of lung tissue The earliest change noted by x ray after the institution of chemotherapy is believed to be the resolution of non necrotic lesions This is represented by the rapid clearing of x ray shadows during the first several months of chemotherapy Clinical observation suggests that resolution of non necrotic lesions occurs more promptly and more rapidly with chemotherapy than with any other therapy However, the contribution of chemotherapy is neither the rate nor extent of resolution rather it is that resolution is predictable and progressive

The second type is the solid necrotic lesion In this lesion the cells of the exudate and parenchyma of the lung are dead but the process has not progressed to autolysis and liquefaction The lesion is a coagulated mass of necrotic material which becomes surrounded by a capsule of fibrous tissue The tuberculoma is a large necrotic lesion of this type Solid necrotic lesions are influenced to a minimal [illegible] or they [illegible] surrounded by small [illegible] by a decrease in size of the total lesion and a sharper definition of its borders

The third variety is the necrotic lesion which has progressed to liquefaction and sloughing to form an air containing cavity Its response to chemotherapy is a reduction in size and,

* Medlar s excellent monograph should be consulted The behavior of pulmonary tuberculous lesions A pathological study *American Review of Tuberculosis and Pulmonary Diseases* Suppl March 1955

† Some pathologists believe that the non specific inflammation occurs to a lesser extent during chemotherapy resulting in a particularly thin capsule around necrotic lesions and fewer pleural adhesions

under the best circumstances complete closure The closure of cavities is in reality a process of their filling in with inspissated necrotic material This occurs not only when cavities close under the influence of drugs but also in the natural course of the disease and with other forms of therapy Only in exceptional instances does the necrotic inner wall of the cavity slough out completely so that uninfected granulating surfaces organize into a scar Filled in or closed cavities therefore are not healed in a morphologic sense Much is gained when an open necrotic lesion is made airless since this is an environment in which tubercle bacilli do not freely multiply However as Medlar has shown so well detailed examination of the resected filled in cavity often reveals one or more bronchioles traceable into its interior These bronchioles containing necrotic debris pierce the fibrous connective tissue wall of the filled in cavity The risk is that they can become the pathway to relapse if the material in the filled in cavity should liquefy and empty Whether or not the virulence of the bacilli in the closed necrotic lesion has been modified during chemotherapy will be discussed presently

Cavity closure does not always follow successful bacterial suppression by potent antituberculosis agents Sputum cultures may be negative for months and yet cavities may remain open Rarely does the necrotic inner wall of such open cavities slough out completely resulting in a cyst like structure lined with either connective tissue or bronchial epithelium In the majority necrotic portions of the cavity wall remain in which tubercle bacilli are found Such open cavities are often thin walled and resemble emphysematous bullae which so often occur in lungs that have been heavily involved The two structures cannot be distinguished by x ray

In summary it may be said that after maximal resolution of lesions has occurred and all cavities have closed the lesions that remain are necrotic They are either solid unsloughed lesions which changed little or not at all during chemotherapy or they are filled in cavities Roentgenographically it is not possible to differentiate the two types both may cast sharply defined and even linear shadows While there is considerable doubt about the best therapy of the residual necrotic lesions after chemotherapy, there is no question about their morphology It may be added that cavities which do not close during chemotherapy are open necrotic lesions which very probably harbor viable tubercle bacilli even though the sputum cultures may be negative

BACTERIOLOGY OF TUBERCULOUS LESIONS UNDER CHEMOTHERAPY

During the past several years the viability* of tubercle bacilli in resected lesions has received considerable attention It has long been known that tubercle bacilli may not survive in tuberculous lesions during the natural course of the disease 1–4 Recently it has been possible to study bacilli in lesions resected at operation usually after chemotherapy The bacteriology of these lesions can be satisfactorily interpreted only when the clinical conditions under which the resections were carried out are clearly set forth The factors which have the most bearing on the viability of bacilli are whether the chemotherapeutic regimen is an original or retreatment course whether streptomycin is administered daily or twice weekly the duration of preoperative chemotherapy the bacteriology of the sputum during the two to three-month interval preceding resection and finally the morphology of the resected lesion whether it is open (i e an air-containing cavity) or closed

The bacteriology of resected lesions in a series reported from Sunmount Veterans Administration Hospital was studied in lesions resected after a definite clinical therapeutic target point had been reached* This point is defined as the time when (1) all the cavities have closed (2) the sputum or gastric cultures are consistently negative† and (3) maximum resolution of lesions on roentgenograms has occurred In the patients who received streptomycin 1 0 gm every day and PAS 12 0 gm daily only 5 2 per cent of resections yielded lesions from which viable bacilli were demonstrated by culture or animal inoculation In patients treated with streptomycin 0 5 gm daily and PAS 12.0 gm daily the incidence of lesions with viable bacilli was 17 per cent while in those treated with streptomycin 1 0 gm twice weekly and PAS 12 0 gm daily the incidence was 35 per cent The majority of the lesions (approximately 70 per cent)

* Throughout this chapter viability of tubercle bacilli means the capacity to multiply on artificial culture media or to cause infection in susceptible animals It is recognized that bacteria may do neither and yet be alive

† Usually this means three months In extensive lesions a longer period of negative cultures was required

harbored bacilli visible on smear or stained sections These data have been confirmed by other investigators In a series of 125 patients reported by Steele[6] 8 per cent of resections yielded lesions with viable bacilli In the series of Falk et al[7] (which included both original and retreatment cases) 12 per cent of resected cases had viable bacilli The lesion in which non-viable bacilli are found may be either a filled-in cavity or a solid necrotic lesion which had never sloughed The size of the filled in cavity does not seem significant Large filled-in cavities often contain myriads of bacilli on stained smear which are not viable by animal inoculation or culture On the other hand, viable bacilli can be recovered from the majority of resected open cavities (air containing cavities) even after very prolonged courses of [illegible] therapy had an incidence of viable bacilli of 50 per cent as compared to 8 per cent* in those treated with daily SM and PAS for the same length of time The difference in the incidence of viable bacilli in the two groups emphasizes the necessity of controlling new culture methods by standard technics in order to take into account factors such as regimen and duration of chemotherapy

If bacilli in closed necrotic lesions are dead, [illegible] There [illegible] that [illegible] chemotherapy it had been shown that bacilli in many tuberculous lesions could not be cultured [illegible] Solid necrotic lesions which are now sometimes resected without preoperative chemotherapy often have non-viable bacilli within them On the other hand, viable bacilli can be demonstrated in open cavities even after very long courses of chemotherapy It is evident, therefore, that bacilli may die in necrotic lesions never exposed to antituberculosis drugs, on the contrary, bacilli in open lesions exposed to very long periods of chemotherapy are usually viable It seems clear that it is the morphology of necrotic lesions, not chemotherapy, which is the factor most closely related to the death of bacilli, if indeed they are dead

Does the finding of non-viable bacilli in closed necrotic lesions have practical clinical applications? Recovery from tuberculosis under natural conditions depends chiefly upon the closure of open necrotic lesions We have seen that prolonged chemotherapy can bring about this morphologic change In the writer's opinion, the principal contribution of the data on the viability of bacilli in closed necrotic lesions is to encourage clinical studies to explore the value of chemotherapy as definitive therapy The clinical significance of these laboratory data will be learned not by devising new methods of testing the viability of bacilli, but rather by the fate of those patients whose closed necrotic lesions were not resected after treatment with prolonged chemotherapy In the [illegible]

really dead It is suggested that chemotherapeutic agents or substances in closed necrotic lesions may have modified the growth characteristics of bacilli in such a way that standard culture methods may be inadequate to test their viability Dubos[8] has called attention to certain products of tissue necrosis in tuberculous lesions, i e, fatty acids, spermine and lactic acid, which are strongly tuberculostatic and even tuberculocidal Such inhibitory substances may be adsorbed upon the bacilli preventing their multiplication Recently Hobby[9] has investigated this aspect of the problem with a bovine albumin technic to neutralize components of necrotic lesions This method has yielded viable bacilli from closed necrotic lesions in eleven of fifteen patients—an incidence of 73 per cent * The albumin technic was not controlled by standard media Without controls it is impossible to assess the significance of certain factors of the clinical material from which the lesions were obtained Most of the patients in Hobby's series received streptomycin twice weekly preoperatively, the duration of chemotherapy was on the average less than eight months, and some received retreatment courses of chemotherapy These factors may account in large part for the high incidence of viable bacilli In the Sunmount study, for example, patients who received twice weekly streptomycin and daily PAS and came to resection after from four to eight months of chemo-

* Hobby's results have not been confirmed in three separate studies [10-12]

quoted six resections in the streptomycin 1 gm twice weekly–PAS 12 gm daily group yielded three positive lesions, additional data bring these to five positive lesions of ten resections, the incidence of positive lesions remaining the same (50 per cent)

meantime these data are bound to influence the indications for the resection of closed necrotic lesions

DRUG RESISTANCE

Drug resistance* is the most important cause for the failure of combined chemotherapy after we exclude from consideration patients with extensive destruction of lung tissue Failure of chemotherapy usually means failure of cavity closure With our present drugs the sustained bacterial inhibition necessary to achieve cavity closure can be attained only by the preservation of bacterial sensitivity

Data from a Medical Council Research Study indicate that INH is at least as effective as PAS in preserving the sensitivity of bacilli to streptomycin[9] In patients treated with SM INH only 8 per cent of positive cultures were resistant to SM at the end of three months and 0 per cent at the end of six months of therapy On the other hand streptomycin is effective in preserving sensitivity to INH In patients treated with SM INH the incidence of INH resistance at the end of three and six months was 11 and 50 per cent respectively These results suggest that INH may be more effective in preserving bacterial sensitivity to streptomycin than is streptomycin in preserving sensitivity to INH However in the Medical Research Council study streptomycin was administered daily for only the first three months after that the SM dosage was usually reduced to 1 0 gm twice weekly It would not be surprising to learn that streptomycin is less effective in preserving INH sensitivity when it is administered twice weekly rather than daily The effectiveness of streptomycin in preserving INH sensitivity has also been demonstrated in the cooperative study of the Veterans Administration Army and Navy[11] These data also indicate that PAS maintains sensitivity of bacilli to INH as well as it does to streptomycin Combined chemotherapy effectively reduces the chances of bacterial resistance but the threat of resistance is always present Two general principles may be followed to prevent or delay it The first is the continuous and uninterrupted administration of combined drugs The second is the closure or resection of cavities which have not closed during the first four to six months of treatment There is a strong association between bacterial resistance and the presence of open cavities During chemotherapy sputum cultures may remain negative for months in the presence of large open cavities However as long as cavities remain open bacteriologic relapse and resistance may occur even if chemotherapy is continued uninterruptedly Every effort therefore should be made to close or resect large cavities In combined SM PAS therapy procedures to this end need not be undertaken before the fourth to fifth month except when cavities are very large With small open cavities (2 cm or less) the risk of bacterial relapse and resistance is slight It may be pointed out that when bacteriologic relapse occurs resistance is more frequent with the daily SM PAS regimen than with twice weekly SM daily PAS The relationships between open cavities bacteriologic relapse and resistance during therapy with INH regimens have not yet been sufficiently clarified In the meantime it seems best to assume that in these regimens also the open cavity invites bacterial relapse and resistance

VIRULENCE OF BACILLI EXPOSED TO ANTIMICROBIAL AGENTS

In experimental animals bacilli resistant to streptomycin have the same degree of virulence as the parent strains and clinical experience bears this out Bacilli resistant to INH however are often avirulent for animals[12 14] Virulence appears to vary with different species mice are susceptible to INH resistant organisms guinea pigs are usually not The avirulence of INH resistant strains is related in only a general way to the degree of INH resistance Most of the avirulent strains are highly resistant to INH but a few are INH sensitive On the other hand some highly resistant strains are quite virulent for guinea pigs[14] These apparent inconsistencies may be due to a mixed bacterial population It is believed by some that the sensitive strains in a population which is predominantly resistant may account for its virulence

The virulence of INH resistant strains may be inconstant Certain avirulent cultures become virulent in time If the explanation in the preceding paragraph is correct this

* Bacilli capable of growth in 10 μg of streptomycin per ml of media are considered to have a degree of resistance which is clinically significant The corresponding values for PAS and INH* are 10 and 1 μg per ml of media respectively The value for INH is uncertain but when infection can be established in guinea pigs by strains resistant to 1 μg of INH doses of INH comparable to those used in man do not protect the animals

may be due to a relative increase in the proportion of sensitive bacilli in the total bacterial population

Does the phenomenon of avirulence of INH resistant strains have any bearing on the treatment of human tuberculosis? Several clinical observations indicate that the emergence of INH resistant strains is detrimental to the patient under therapy The appearance of INH resistant bacilli in man is frequently though not always, attended by an increase in the number of bacilli being discharged in the sputum Worsening of the disease during INH therapy as revealed by x ray changes or clinically is usually associated with the emergence of INH resistant bacilli *in vitro* Furthermore, there is no direct relationship between the clinical course of the patient and the virulence of organisms for laboratory animals lesions can progress while INH resistant bacilli recovered in the sputum may be non pathogenic for guinea pigs [14 15] Finally when the patient with bacilli resistant to INH is treated with streptomycin combined with INH INH fails to prevent SM resistance bacilli become resistant to streptomycin just as if streptomycin alone were used One cannot escape the conclusion that the emergence of INH resistant strains is disadvantageous to the patient and everything should be done to prevent their occurrence

EFFICACY OF CHEMOTHERAPY REGIMENS

Studies of the therapeutic efficacy of several drug regimens are now in progress In a study being conducted by the U S Public Health Service a comparison of the regimens INH SM and INH PAS suggests that there is no superiority of one over the others [16] Moreover, three drugs given simultaneously have shown no advantage over combinations of only two drugs Two dosages of INH 3 and 10 mg /kg showed no significant therapeutic differences but the larger dose caused appreciably greater toxicity In this study SM INH had a slight but consistent superiority over SM PAS [17] At the end of the forty weeks of therapy 68 per cent of patients treated with SM PAS had negative cultures as compared to 82 per cent in the SM INH group X ray improvement was slightly greater in the SM INH treated patients, 78 per cent as compared to 71 per cent in the SM PAS group

In a preliminary evaluation by the Veterans Administration Army and Navy Study Units [19] the therapeutic efficacy of all three regimens INH PAS INH SM and SM PAS, showed no significant differences At the eighth month of therapy sputum conversion had occurred in 70 per cent of patients in the three regimens X ray improvement was also similar—approximately 50 to 60 per cent [illegible] V A Army showed INH [illegible] superior to [illegible] cially in advanced cases [illegible] The Tuberculosis [illegible]

1 0 gm of streptomycin was administered daily, but in the V A Army and Navy Studies streptomycin was administered 1 0 gm twice weekly The difference in the frequency of streptomycin administration may be significant

It is emphasized that studies of the comparative efficacy of combined drug regimens are incomplete Moreover, the data obtained thus far assess the regimens chiefly in terms of x ray changes and sputum conversion We must still await a definitive evaluation in terms of the incidence of cavity closure and relapse In the meantime no one regimen appears to be significantly superior to the others

In the light of these data the choice of a regimen for the individual patient is a decision which may depend chiefly upon the risks of bacterial resistance once having excluded from consideration toxicity and hypersensitivity manifestations On theoretic grounds it would seem best to avoid using the two major drugs, SM and INH in the initial course of treatment but to select rather a regimen of one major and one minor drug Of the two combinations of a major and minor drug there is some justification for choosing SM PAS instead of INH PAS If bacterial resistance should occur INH could be available when the need for retreatment arises In single drug therapy INH may be superior to SM for at least two reasons its greater efficacy in miliary and meningeal tuberculosis and the fact that resistance to INH may not be as disadvantageous as resistance to SM

When cases are retreated the regimens to be employed depend upon the sensitivity of bacilli to drugs previously used Here the physician must have *in vitro* sensitivity tests to all drugs including PAS in order to prescribe the best retreatment regimen When

bacilli are resistant to PAS, the retreatment regimen of choice is certainly SM INH However, the combination of oxytetracycline (terramycin®) 1 to 2 gm daily and SM 1 0 gm twice weekly may be used This should not be understood as suggesting that TM with SM is as effective as INH with SM, rather that TM has the action of PAS in preventing SM resistance It is not known whether terramycin delays resistance to streptomycin to a clinically significant degree when streptomycin is administered daily

When bacilli are resistant to both SM and PAS INH may be paired with either pyrazinamide or oxytetracycline However the efficacy of these regimens is not yet established The combination of PZA INH is effective in experimental animals,[19] and preliminary results* suggest that it may be useful in man[20] PZA however is a hepatotoxic drug and at this writing is not yet available for routine use Data on the regimen of INH TM are incomplete but TM appears to be partially successful in maintaining sensitivity to INH[21] Terramycin is effective in maintaining bacterial susceptibility to INH only when it is administered in dosages of 4 5 gm daily

Patients whose organisms are resistant to both SM and INH may be treated with viomycin 2 0 gm twice weekly combined with PAS, 12 gm daily Viomycin is not a particularly effective drug but it is always worth a trial[22]

A new anti tuberculous drug cycloserine produced from *Streptomyces orchidaceus* has become available While its relative efficacy has not yet been assessed it appears almost certain that it is not a first line drug It is now being investigated in combination with other anti tuberculous drugs There is a considerable bibliography

When bacilli exhibit a moderate rather than a high degree of resistance to drugs the selection of the proper drugs may be difficult In general it is best to avoid using a drug to which bacilli are moderately resistant because of the risk of later developing resistance to the drug with which it is paired Moderate resistance may be defined in the case of streptomycin as growth of bacilli in 10 but not in 100 μg per ml for PAS as growth in 10 but not in 100 μg per ml and for INH as growth in 1 0 but not in 5 0 μg per ml

Multiple drug therapy dates from 1948 and has been advocated in the chemotherapy of tuberculosis ever since Indeed it has been considered improper to prescribe single drugs except in unusual circumstances Recent experience with isoniazid however, seems to have cast doubt upon this concept In the U S Public Health Study isoniazid alone was as effective as either SM INH or PAS-INH in non cavitary disease[23] Deuschle et al[24] recently described an encouraging experience with a group of patients treated with isoniazid alone for one year Such clinical trials should be encouraged not only because of the practical advantages of single drug therapy but also because they challenge what has been regarded a fundamental principle of chemotherapy However until more is learned about the late results of single drug therapy combined chemotherapy should be considered obligatory in clinical practice

OPTIMUM DURATION OF CHEMOTHERAPY

The optimum duration of chemotherapy in the treatment of pulmonary tuberculosis is not known From 1946 to 1948 when streptomycin was our only antituberculosis drug duration was limited chiefly by bacterial resistance Tubercle bacilli usually became highly resistant by the third month of therapy, after which there was little if any advantage in continuing Now the duration of chemotherapy may be indefinitely prolonged because combined drugs tend to prevent bacterial resistance

The problem of the optimum duration of chemotherapy may be considered in patients in three radiographic bacteriologic phases (1) when all cavities have closed and sputum cultures have become negative (2) when cavities have remained open but the sputum has been negative, and (3) when the patient s cavities have remained open and the sputum is positive When maximal resolution of lesions has occurred, patients in the first phase have attained the therapeutic target point previously described and thus appear to be in a particularly favorable condition How much more chemotherapy is required is not known Realizing the disadvantage of stopping drugs prematurely many physicians are now inclined to advise chemotherapy for very

* Further experience has shown that the combination of PZA INH is as effective as either SM INH or PAS INH it may in fact be somewhat more effective than either of these two regimens, though this is not yet certain[18] The toxicity of PZA however remains an important deterrent to its routine use

long periods of time Undoubtedly the amount and character of disease, the patient's previous experience with tuberculosis, the history of relapse and various socio-economic conditions such as the necessity to return to work are factors taken into account Patients with minimal lesions are often treated for one year or more even though the initial lesion may have been extremely small Currently the optimum duration of drugs is the subject of a control study by hospitals in the Veterans Administration, Army and Navy Study In this study once the target point is reached additional chemotherapy depends upon random selection, alternate patients being treated for either six or twelve months This study is not complete since it is obvious that its assessment must be in terms of relapse rates Until more precise data are at hand, it is believed that chemotherapy should be continued in this group of patients for at least six months beyond clinical goals more or less comparable to the "therapeutic target point"

The problem of the duration of chemotherapy is more complex in the second phase, i e, in the patients whose cavities remain open but whose sputum cultures are negative It has been pointed out that because of the risks of bacterial relapse and resistance every effort should be made to collapse or resect open cavities Often, however no procedure can be performed to close cavities There are no reliable guides to the duration of chemotherapy in such patients Some physicians believe that drugs should be continued indefinitely As long as cavities remain unclosed, there is always the risk of relapse, either during chemotherapy or after its termination

The writer does not wish to imply that the two phases just described can always be distinguished It is often impossible to rule out the presence of open cavity This is an especially difficult decision in confluent lesions located high in the apex of the lung It is impossible in many instances to differentiate between open cavities and emphysematous bullae Such patients should be treated as if an open cavity were present Collapse or resection should be performed whenever possible, the alternative is the continuation of drugs

In the third phase patients fail to achieve both closure of all cavities and sputum conversion When cavity closure and sputum conversion have not occurred by the sixth and certainly the eighth month of uninterrupted original chemotherapy, it is improbable that they will occur by the continuation of the same drugs Other drugs or other therapeutic procedures, such as surgery, will be found necessary When neither of these alternatives is feasible, the current course of chemotherapy should be continued and terminated only when it is judged to be no longer beneficial to the patient The chief guides here are unequivocal clinical deterioration or progressive worsening of disease by x ray The sensitivity of the organisms in vitro is not a reliable criterion

SURGERY AND CHEMOTHERAPY

In practice the relationships between surgery and chemotherapy are approached from two diverse points of view In one, surgery is performed as early as possible, chemotherapy being employed in a secondary role In the other view, surgery is performed either late in the course of chemotherapy or not at all if drugs have been particularly effective When chemotherapy is used as primary therapy, each case of pulmonary tuberculosis falls at one time or another into the three phases in which the duration of chemotherapy was discussed (1) All cavities are closed and sputum cultures are negative, (2) there are one or more open lesions but sputum cultures are negative, (3) there are open lesions and sputum cultures are positive As a primary therapy chemotherapy is successful in the first pattern only, in the remaining two it has failed The majority of minimal or moderately advanced cases (NTA 1950) treated with original uninterrupted chemotherapy will attain the first phase closed lesions and negative sputum A number of the more favorable far advanced cases will also reach [illegible] of lesions

1950 the morphologic characteristics of residual necrotic lesions, specifically the potential bronchial communications of filled in cavities, stimulated a clinical study in which all residual necrotic lesions were resected This study[illegible] and others[illegible] which followed demonstrated that residual necrotic lesions can be resected [illegible] and [illegible] on [illegible] ic

lesions, however, have raised some doubt

about the necessity for resecting them It is to be expected that in practice the use of surgery in the treatment of these lesions is influenced by the interpretation of these bacteriologic data If the bacilli in residual necrotic lesions are dead there is no need for resection if on the other hand bacilli are not dead the morphologic features of the lesions might possibly warrant resection We must conclude that at the present time we do not know the clinical significance of either the morphology or bacteriology of these lesions A three-year follow up of resected and non resected residual necrotic lesions which attained the target point under prolonged chemotherapy has shown no differences in relapse rate thus far * More data of this kind are necessary A control study on the indications for resection of closed necrotic lesions is in progress in several Veterans Administration Army and Navy Hospitals

A considerable number of patients fall into the second clinical pattern open cavities and negative sputum culture This phase is often temporary since in many instances the sputum becomes positive again The integration of resection or thoracoplasty with chemotherapy is therefore of great importance The probability of cavity closure on drugs alone* may be assessed and whenever it seems unlikely surgery should be performed while the sputum is still negative The tuberculous complications of resection are minimal in this phase

In the third phase are the patients whose cavities have not closed and sputum has remained positive during chemotherapy Usually these cavities are large many patients have been treated before and organisms are resistant to major antituberculosis drugs These cases are failures of chemotherapy and their management is often no different from that in the prechemotherapy era Occasionally it is possible to add other drugs which may diminish the risks of surgical complications In general thoracoplasty rather than resection will be preferred if surgery can be performed

When surgery is employed as primary therapy it is undertaken as soon as the patient s general condition has improved and the number of bacilli in the sputum has diminished In this approach surgery is performed *before* maximum resolution of lesions has occurred under the influence of chemotherapy Advanced lesions in which chemotherapy is bound to fail are often treated in this way Early surgery is advocated too because bacterial resistance is apt to occur rapidly in advanced lesions

Small localized lesions also are resected after a brief period of chemotherapy which is employed here in a prophylactic role The rationale of this practice is that the resolution of non necrotic lesions during a long course of chemotherapy may not result in a less extensive surgical procedure or that a wedge resection is no more advantageous than a segmental resection or that complications will be no greater and no saving of lung tissue will result if surgery is performed later No doubt these are valid assumptions in many cases and it has been amply demonstrated that early surgery can be carried out with few complications

There is no reason to advocate one or the other of these two fundamental therapeutic points of view We do not know enough about the interrelations of surgery and chemotherapy to do so In practice the therapeutic problems presented by the individual case will usually incline the medical surgical team toward one or the other approach However the two therapeutic points of view in the writer s opinion have a bearing upon the investigation of the indications for surgery during chemotherapy In the far advanced especially the very far advanced cases chemotherapy as primary therapy fails so often that surgical procedures may be planned almost from the very start of chemotherapy What we need to investigate here is the proper timing of surgery especially how long surgical procedures may be delayed without running the risk of bacterial resistance

In minimal and moderately advanced cases however these alternate therapeutic points of view will have a decided effect upon the development of surgical indications Most m

* Closure of cavity is chiefly related to size and location In the VA Army and Navy Study (1956) the incidence of cavity closure in cases treated with original chemotherapy for one year without resectional surgery was between 60 and 70 per cent in cases where the largest cavity measured between 1 and 2 cm in diameter Cavity closure occurred in 45 55 per cent of cases where the largest cavity was between 2 5 and 3 5 cm in diameter while in those cases with cavities larger than 4 cm in diameter the incidence of cavity closure was between 20 and 40 per cent Cavities high in the apex of the lung those in contracted segments, and those in the midst of dense necrotic disease have less tendency to close during chemotherapy or any other form of therapy)

mal and moderately advanced cases treated with original chemotherapy can be brought to the phase of closed necrotic lesions with consistently negative sputum The policy of early surgery, with chemotherapy in a prophylactic role, does not foster the investigation of chemotherapy as a definitive therapy in these cases It is entirely possible that resection is not necessary to prevent relapse of these lesions The early resection of small or moderate-sized lesions is often advocated as a saving of time and hospitalization This may be an advantage at present However, if ambulatory chemotherapy and home chemotherapy have the success they promise, the objection of long hospitalization and loss of time from work will largely pass

In the literature it is often impossible to recognize the relationships between surgical procedures and chemotherapy because factors which are known or presumed to be related to tuberculous complications and relapse are not documented The most important are whether the course of chemotherapy used was original or retreatment, whether, if a retreatment course, organisms were sensitive or resistant whether chemotherapy was continuous or interrupted, the duration of preoperative chemotherapy, whether sputum cultures were positive or negative during the several months preceding operation, whether open cavity or cavities were present preoperatively, whether maximal resolution of lesions had occurred prior to operation, the size of the residual necrotic lesions which were resected, the duration of chemotherapy postoperatively, and the bacteriology and morphology of the resected lesions A better description of the disease at the time chemotherapy was begun would also be instructive, especially the number of cavities, the size of the largest cavity and whether the cavities were unilateral or bilateral Often relatively little can be learned from the data recorded except a very general idea of operability, mortality and complications

SUMMARY

In the treatment of pulmonary tuberculosis three combinations of antituberculosis drugs, SM-PAS, SM INH and INH-PAS,* appear equally effective Differences between them, however, may be evident upon completion of studies now in progress If these regimens were equally effective, the selection of SM-PAS for initial therapy would leave INH, the more versatile of the two major drugs, in reserve for retreatment if it should become necessary Drug resistance is effectively delayed by all three combinations of drugs, but the particular advantages, if any, of one combination over another in this respect have not yet been clarified Toxicity of drugs is now a relatively unimportant consideration either in the selection of a regimen or in the duration of chemotherapy

Whatever regimen is employed, there is now general agreement that uninterrupted drug therapy should be continued for at least one year, or six to twelve months after a target point of (1) closure of all cavities, (2) persistently negative sputum cultures and (3) maximal resolution of lesions, has been achieved However, the optimum duration of chemotherapy is not known

The changes in the morphology of tuberculous lesions following the use of drugs do not differ qualitatively from those occurring with other forms of therapy However, resolution is prompt and predictable Solid necrotic lesions are affected relatively little Cavity closure is usually a process of their filling in with necrotic material and potential bronchial communications can often be demonstrated between the filled in cavity and the bronchial tree Filled in cavities are not healed in a morphologic sense and thus there may be a rationale for resecting them Yet bacilli are non viable in closed necrotic lesions in 85 to 95 per cent of resections There is no general agreement, however that such bacilli are in fact dead In the meantime the interpretation of these bacteriologic data is bound to influence the indications for resection of closed necrotic lesions The relationships between surgery and chemotherapy not only involve the interpretation of the morphology and bacteriology of closed necrotic lesions, but depend also upon whether the primary role in the treatment of pulmonary tuberculosis is given to chemotherapy or to surgery /

* Supplied by Pfizer Laboratories, Brooklyn N Y The editor wishes to acknowledge a grant from Pfizer toward the preparation of this book.

REFERENCES

1 SWEANY H C Age Morphology of Primary Tubercles Springfeld Ill 1941 Charles C Thomas.

2 SWEANY H C Age characteristics of tubercles Am Rev Tuberc 46 329 1942

3 SWEANY H C LEVINSON S A and STADNICHENKO A M S Tuberculous infection in people dying of causes other than tuberculosis. Ibid 48 131 1943

4 CANETTI, G Le bacille de Koch dans la lesion tuberculeuse du Poumon France, 1946 Editions Médicales Flammarion
5 D'ESOPO, N D, BERNSTEIN, S, DECKER, A M RALEIGH J W and STEENKEN, W Jr Bacteriology of lesions resected during chemotherapy Transactions of the Twelfth Conference on the Chemotherapy of Tuberculosis, Veterans Administration, Washington, D C, February 1953
6 STEELE, J D The bacteriology of resected tuberculous pulmonary lesions Ibid
7 FALK, A, KAUFMAN, J E and TUCKER, W B Resectional surgery in pulmonary tuberculosis with a bacteriologic study of the resected tissue Ibid
8 DUBOS, R J Viability of tubercle bacilli in vitro with and without chemotherapy Am Rev Tuberc, 67 874, 1953
9 HOBBY, G L, AUERBACH, O, LENERT, T F, SMALL, M J and COWER, J V The late emergence of M tuberculosis in liquid cultures of pulmonary lesions resected from humans Am Rev Tuberc, 70 191, 1954
10 MITCHISON, D A Tubercle bacilli resistant to isoniazid, virulence and response to treatment with isoniazid in guinea pigs Brit M J, 4854 128, 1954
11 Medical Research Council Report Emergence of bacterial resistance in pulmonary tuberculosis under treatment with isoniazid, streptomycin plus PAS and streptomycin plus isoniazid Lancet, 2 217, 1953
12 Transactions of the Thirteenth Conference on the Chemotherapy of Tuberculosis, Veterans Administration, Washington, D C, February, 1954
13 BARNETT, M BUSHBY, S R M and MITCHISON, D A Isoniazid resistant strains of tubercle bacilli their development and stability Lancet 1 314, 1953
14 STEENKEN W, Jr and WOLINSKY, E Virulence of tubercle bacilli recovered from patients treated with isoniazid Am Rev Tuberc 68 548 1953
15 Panel Discussion Relationship between the emergence of resistance to INH by tubercle bacilli and their pathogenicity for experimental animals and (as estimated by relapse) for man Transactions of the Twelfth Conference on the Chemotherapy of Tuberculosis, Veterans Administration, Washington, D C, February, 1953
16 Progress report on therapeutic and toxic effects of combinations of isoniazid streptomycin, and para-aminosalicylic acid United States Public Health Service Cooperative Investigation of Antimicrobial Therapy of Tuberculosis Am Rev Tuberc 69 1 1954
17 MOUNT, F W, JENKINS, B E and FEREBEE, S H Control study of comparative efficacy of isoniazid, streptomycin isoniazid, and streptomycin para aminosalicylic acid in pulmonary tuberculosis therapy Am Rev Tuberc 68 264, 1953
18 Transactions of the Thirteenth Conference on the Chemotherapy of Tuberculosis Veterans Administration, Washington D C, February 1954
19 McCUNE, R and TOMPSETT, R Effect of pyrazinamide—isoniazid and other anti tuberculous drugs on populations of M tuberculosis in experimental animals Ibid.
20 MOYER, R E Results of long term chemotherapy with pyrazinamide and isoniazid on human tuberculosis Transactions of Thirteenth Conference on the Chemotherapy of Tuberculosis, Veterans Administration, Washington D C, February, 1954
21 Unpublished data
22 HOBBY, G Viomycin Summary of a four year evaluation. Transactions of Twelfth Conference on the Chemotherapy of Tuberculosis, Veterans Administration, Washington, D C, February, 1953
23 ECKLEY G Evidence suggesting differential effects of various drug regimens in pulmonary tuberculosis Transactions of Thirteenth Conference on Chemotherapy of Tuberculosis, Veterans Administration Washington D C, February, 1954
24 DEUSCHLE, K, ORMAND L, ELMENDORF, D, Jr, MUSCHENHEIM, C and McDERMOTT, W The course of pulmonary tuberculosis during long term single drug (isoniazid) therapy Am Rev Tuberc 70 228 1954
25 BIEHL, J P and VILTER, R W Effects of isoniazid on pyridoxine metabolism Transactions of Thirteenth Conference on Chemotherapy of Tuberculosis, Veterans Administration, Washington D C, February 1954
26 RYAN, B J, MEDLAR, E M and WELLER, E S Simple excision in the treatment of pulmonary tuberculosis J Thoracic Surg, 23 327, 1952
27 STEELE, J D NARODICK, B G and CADDEN, A V The influence of long term chemotherapy on the surgery of pulmonary tuberculosis J Thoracic Surg, 26 459, 1953
28 MURPHY J D A study of the factors influencing the success of segmental resection for pulmonary tuberculosis Transactions of Thirteenth Conference on the Chemotherapy of Tuberculosis, Veterans Administration Washington, D C, February, 1954
29 RALEIGH, J W, D'ESOPO, N D, OSGOOD, C K and CAMPBELL, A M Relapse following streptomycin para aminosalicylic acid therapy for pulmonary tuberculosis Ibid
30 RALEIGH, J W, KAZLOWSKI J BROSBE, E A STEENKEN, W, Jr Bacteriology on resected lesions. Transactions of the Fourteenth Conference on the Chemotherapy of Tuberculosis Veterans Administration Washington, D C February, 1955
31 BERNSTEIN, S, FALCO, E. B, D'ESOPO, N D The effect of prolonged incubation on the recovery of tubercle bacilli from resected pulmonary lesions Ibid
32 HALL, W H, FALK, A, LYON, R H Growth and drug resistance of tubercle bacilli from pulmonary tuberculous lesions after prolonged combined chemotherapy Transactions of the Fifteenth Conference on the Chemotherapy of Tuberculosis, Veterans Administration Washington, D C, February, 1956
33 Ibid
34 Medical Research Council Report Various combinations of isoniazid with streptomycin or with PAS in the treatment of pulmonary tuberculosis Brit M J, 4911 435, 1955

66

Tuberculosis As Affected by Antibiotics

OSCAR AUERBACH, M D, *East Orange, New Jersey*

From the Laboratory Service, Veterans Administration Hospital East Orange, N J Read in part at the Primeras Jornadas Medicas, Instituto Nacional de Neumologia, Mexico City, Mexico June 13–19, 1954

CHANGES in pulmonary tuberculosis brought

drugs is used, as long as tubercle bacilli remain sensitive to the drugs This would speak for the fact that the drugs neutralize the action of the organisms and healing changes become the dominant feature of the tuberculous process

In the usual course of events, when no chemotherapy is employed, pulmonary tuberculosis is characterized by progression of the disease with concomitant repair The natural evolution of the tuberculous process is the development of a cavity in the upper lobe In a small percentage of instances this may close without the aid of collapse therapy Generally, the cavity enlarges and, with the dissemination of tubercle bacilli to other parts of the lung, new areas of tuberculous pneumonia develop which may either liquefy and form cavities or may become walled off by the elements of repair The spread of the disease to other parts of the lungs would continue until pulmonary insufficiency resulting from extensive disease would terminate the patient's life It is of interest that the duration of the disease in these individuals was less than two years in the great majority of instances More than 80 per cent of this group showed intestinal tuberculosis and more than 40 per cent had laryngeal

procedures were applied when the cavities were still limited to the upper lobe and before extensive spread of the disease had occurred Success was dependent upon closing the communication between the cavities and the draining bronchi

There is another and much smaller group of patients in whom the tuberculous cavity remained limited to one or both upper lobes These patients lived for many years with open cavities from whose sputum tubercle bacilli were always recovered Yet, in spite of this, there was no spread of the disease to other parts of the lungs These patients generally died of some disease other than tuberculosis and rarely showed evidence of intestinal or laryngeal tuberculsosis

A comparative study of pulmonary tuberculosis before and after the advent of chemotherapy is beset by several difficulties Chemotherapy and pulmonary tuberculosis are synonymous today, so that simultaneous comparative studies with untreated patients is not possible The material presently at hand is that which is removed by resectional surgery which is becoming available in increasing amounts due to two factors (1) As a result of prolonged chemotherapy in cases of pulmonary tuberculosis soon after its origin, the disease undergoes extensive resolution and the process is limited to a portion of a lobe or lung (2) As a result of technical advances in thoracic surgery, portions of the lung can be removed with much greater facility Thus the only comparative material is that which is available before the extensive use of chemotherapy Much of this material is from autopsies although many surgical specimens are also available

It is our opinion that when lung specimens of chronic pulmonary tuberculosis after antibiotic therapy are compared with those in which no such therapy was used striking differences are observed In making this study we believe that it is important to compare cases of similar duration A comparative study should answer the question as to whether the end results of healing are the same whether antibiotics are used or not

The comparison between both groups is made

chiefly on surgically resected lesions In some instances however, autopsy material is utilized Comparisons will be made of the cavity encapsulated necrotic foci and the surrounding lung tissue

TUBERCULOUS CAVITY (BEFORE CHEMOTHERAPY)

The development of the cavity occurs from a tuberculous pneumonia which has first undergone necrosis and then liquefaction After the evacuation of the necrotic contents the cavity has a characteristic gross and microscopic appearance The cavity which generally lies a few millimeters beneath the pleura has a thin wall in which three layers may be distinguished The inner yellow layer is composed of non liquefied necrotic fragments The middle red zone is made up of tuberculous vascular granulation tissue The outer grey layer which represents the organized perifocal reaction is surrounded by firm lung tissue which represents perifocal reaction lying in the alveolar spaces Characteristic of all tuberculous cavities is the fact that the inner necrotic lining of the cavity wall is continuous with the ulcer of the draining bronchus The necrotic lining of the bronchial ulcer is also surrounded by a layer of granulation tissue The partial destruction of the bronchus with narrowing of the lumen causes a check valve mechanism at this site This results in the mechanical enlargement of the cavity since more air enters the cavity than can escape

Cavity Progression In untreated cases as the disease advances there is concomitant healing Progression of the disease may occur either from within the cavity or extension from without The process from within is that the tubercle bacilli within the lumen bathe the cavity wall and a progressive necrosis results When this occurs the zone of granulation tissue and part of the outer wall of fibrosis become incorporated within the necrotic zone Although the nuclei in these layers have become disintegrated the former structure of these zones is still discernible Concomitant with the progressive necrosis a new layer of vascular granulation tissue forms around it and beyond this a new area of perifocal reaction develops

The process from without is that new areas of tuberculous pneumonia may develop in the immediate proximity of the cavity and extend to involve it in the necrotic process It may liquefy and pour its contents into the lumen of the cavity

Thus as a cavity grows older there is progression both from within and without There is a concomitant repair of these areas of progression in the form of new granulation tissue and organization of the recently developed areas of perifocal reaction The thickness of the cavity wall is dependent upon the extent of organized perifocal reaction which occurs over a period of time The new areas of activity occur irregularly within the cavity wall As a result of this the thickness of older cavities is irregular

Cavity Healing Spontaneous healing of tuberculous cavities may occur without the aid of collapse therapy although it is extremely difficult to obtain a true incidence of this occurrence The closure and healing of tuberculous cavities has occurred with much greater frequency as a result of the various forms of collapse therapy Healing with obliteration of the cavity lumen is well documented in the literature In the days prior to chemotherapy the pathologist s experience with these lesions was obtained chiefly from autopsy material since resectional surgery for tuberculosis preceded the use of antibiotics by a short period Death in these cases was often due to a cause other than tuberculosis

Healing of a tuberculous cavity may occur in one of two ways (1) With obliteration of the lumen and (2) with the lumen of the cavity remaining open

1 *Healing with obliteration of the lumen* We have previously pointed out that this is by far the more frequent form of cavity healing The end result of this type is either an inspissated (filled in) cavity or a radial scar Healing of this form occurs by the approximation of the ulcerated bronchial surfaces at the bronchocavitary junction Collapse therapy does much in these cases to bring this about Following the approximation of the bronchial surface proliferation of granulation tissue in this region continues until the apposing surfaces join and the lumen is obliterated If the granulating surfaces unite firmly the occlusion will be lasting and the cavity permanently closed In all instances in which an inspissated cavity or a radial scar exists the draining bronchus ends blindly either in the wall of the cavity or in an area of fibrosis connecting with the wall of the inspissated cavity

66

Tuberculosis As Affected by Antibiotics

OSCAR AUERBACH, M D East Orange, New Jersey

From the Laboratory Service Veterans Administration Hospital East Orange N J Read in part at the Primeras Jornadas Medicas Instituto Nacional de Neumologia Mexico City Mexico June 13 19 1954

CHANGES in pulmonary tuberculosis brought about by chemotherapy are striking and consistent It is of interest also that the changes *are similar no matter what combination of*

dominant feature of the tuberculous process

In the usual course of events when no chemotherapy is employed, pulmonary tuberculosis is characterized by progression of the disease with concomitant repair The natural evolution of the tuberculous process is the development of a cavity in the upper lobe In a small percentage of instances this may close without the aid of collapse therapy Generally, the cavity enlarges and with the dissemination of tubercle bacilli to other parts of the lung, new areas of tuberculous pneumonia develop which may either liquefy and form cavities or may become walled off by the elements of repair The spread of the disease to other parts of the lungs would continue until pulmonary insufficiency resulting from extensive disease would terminate the patient s life It is of interest that the duration of the disease in these individuals was less than two years in the great majority of instances More than 80 per cent of this group showed intestinal tuberculosis and more than 40 per cent had laryngeal

extensive spread of the disease had occurred Success was dependent upon closing the communication between the cavities and the draining bronchi

There is another and much smaller group of patients in whom the tuberculous cavity remained limited to one or both upper lobes These patients lived for many years with open cavities from whose sputum tubercle bacilli were always recovered Yet in spite of this there was no spread of the disease to other parts of the lungs These patients generally died of some disease other than tuberculosis and rarely showed evidence of intestinal or laryngeal tuberculsosis

A comparative study of pulmonary tuberculosis before and after the advent of chemotherapy is beset by several difficulties Chemotherapy and pulmonary tuberculosis are synonymous today, so that simultaneous comparative studies with untreated patients is not possible The material presently at hand is that which is removed by resectional surgery which is becoming available in increasing amounts due to two factors (1) As a result of prolonged chemotherapy in cases of pulmonary tuberculosis soon after its origin the disease undergoes extensive resolution and the process is limited to a portion of a lobe or lung (2) As a result of technical advances in thoracic surgery, portions of the lung can be removed with much greater facility Thus the only comparative material is that which is available before the extensive use of chemotherapy Much of this material is from autopsies although many surgical specimens are also available

It is our opinion that when lung specimens of chronic pulmonary tuberculosis after antibiotic therapy are compared with those in which no such therapy was used striking differences are observed In making this study we believe that it is important to compare cases of similar duration A comparative study should answer the question as to whether the end results of healing are the same whether antibiotics are used or not

The comparison between both groups is made

chiefly on surgically resected lesions In some instances however autopsy material is utilized Comparisons will be made of the cavity encapsulated necrotic foci and the surrounding lung tissue

TUBERCULOUS CAVITY (BEFORE CHEMOTHERAPY)

The development of the cavity occurs from a tuberculous pneumonia which has first undergone necrosis and then liquefaction After the evacuation of the necrotic contents the cavity has a characteristic gross and microscopic appearance The cavity which generally lies a few millimeters beneath the pleura has a thin wall in which three layers may be distinguished The inner yellow layer is composed of non liquefied necrotic fragments The middle red zone is made up of tuberculous vascular granulation tissue The outer grey layer which represents the organized perifocal reaction is surrounded by firm lung tissue which represents perifocal reaction lying in the alveolar spaces Characteristic of all tuberculous cavities is the fact that the inner necrotic lining of the cavity wall is continuous with the ulcer of the draining bronchus The necrotic lining of the bronchial ulcer is also surrounded by a layer of granulation tissue The partial destruction of the bronchus with narrowing of the lumen causes a check valve mechanism at this site This results in the mechanical enlargement of the cavity since more air enters the cavity than can escape

Cavity Progression In untreated cases as the disease advances there is concomitant healing Progression of the disease may occur either from within the cavity or extension from without The process from within is that the tubercle bacilli within the lumen bathe the cavity wall and a progressive necrosis results When this occurs the zone of granulation tissue and part of the outer wall of fibrosis become incorporated within the necrotic zone Although the nuclei in these layers have become disintegrated the former structure of these zones is still discernible Concomitant with the progressive necrosis a new layer of vascular granulation tissue forms around it and beyond this a new area of perifocal reaction develops

The process from without is that new areas of tuberculous pneumonia may develop in the immediate proximity of the cavity and extend to involve it in the necrotic process It may liquefy and pour its contents into the lumen of the cavity

Thus as a cavity grows older there is progression both from within and without There is a concomitant repair of these areas of progression in the form of new granulation tissue and organization of the recently developed areas of perifocal reaction The thickness of the cavity wall is dependent upon the extent of organized perifocal reaction which occurs over a period of time The new areas of activity occur irregularly within the cavity wall As a result of this the thickness of older cavities is irregular

Cavity Healing Spontaneous healing of tuberculous cavities may occur without the aid of collapse therapy although it is extremely difficult to obtain a true incidence of this occurrence The closure and healing of tuberculous cavities has occurred with much greater frequency as a result of the various forms of collapse therapy Healing with obliteration of the cavity lumen is well documented in the literature [illegible] In the days prior to chemotherapy the pathologist s experience with these lesions was obtained chiefly from autopsy material since resectional surgery for tuberculosis preceded the use of antibiotics by a short period Death in these cases was often due to a cause other than tuberculosis

Healing of a tuberculous cavity may occur in one of two ways (1) With obliteration of the lumen and (2) with the lumen of the cavity remaining open

1 *Healing with obliteration of the lumen* We have previously pointed out that this is by far the more frequent form of cavity healing The end result of this type is either an inspissated (filled in) cavity or a radial scar Healing of this form occurs by the approximation of the ulcerated bronchial surfaces at the bronchocavitary junction Collapse therapy does much in these cases to bring this about Following the approximation of the bronchial surface proliferation of granulation tissue in this region continues until the apposing surfaces join and the lumen is obliterated If the granulating surfaces unite firmly the occlusion will be lasting and the cavity permanently closed In all instances in which an inspissated cavity or a radial scar exists the draining bronchus ends blindly either in the wall of the cavity or in an area of fibrosis connecting with the wall of the inspissated cavity

66

Tuberculosis As Affected by Antibiotics

OSCAR AUERBACH, M D, *East Orange, New Jersey*

From the Laboratory Service Veterans Administration Hospital, East Orange N J Read in part at the Primeras Jornadas Medicas, Instituto Nacional de Neumologia, Mexico City, Mexico, June 13–19 1954

CHANGES in pulmonary tuberculosis brought about by chemotherapy are striking and consistent It is of interest also that the changes are similar no matter what combination of drugs is used, as long as tubercle bacilli remain sensitive to the drugs This would speak for the fact that the drugs neutralize the action of the organisms and healing changes become the dominant feature of the tuberculous process

In the usual course of events, when no chemotherapy is employed, pulmonary tuberculosis is characterized by progression of the disease with concomitant repair The natural evolution of the tuberculous process is the development of a cavity in the upper lobe In a small percentage of instances this may close

new areas of tuberculous pneumonia develop which may either liquefy and form cavities or may become walled-off by the elements of repair The spread of the disease to other parts of the lungs would continue until pulmonary insufficiency *resulting from extensive disease* would terminate the patient's life It is of interest that the duration of the disease in these individuals was less than two years in the great majority of instances More than 80 per cent of this group showed intestinal tuberculosis and more than 40 per cent had laryngeal tuberculosis It is in this group of patients that collapse therapy was frequently employed in an attempt to close the cavities Generally, the procedures were applied when the cavities were still limited to the upper lobe and before extensive spread of the disease had occurred Success was dependent upon closing the communication between the cavities and the draining bronchi

There is another and much smaller group of patients in whom the tuberculous cavity remained limited to one or both upper lobes These patients lived for many years with open cavities from whose sputum tubercle bacilli were always recovered Yet, in spite of this, there was no spread of the disease to other parts of the lungs These patients generally died of some disease other than tuberculosis and rarely showed evidence of intestinal or laryngeal tuberculsosis

A comparative study of pulmonary tuberculosis before and after the advent of chemotherapy is beset by several difficulties Chemotherapy and pulmonary tuberculosis are synonymous today, so that simultaneous comparative studies with untreated patients is not possible The material presently at hand is that which is removed by resectional surgery which is becoming available in increasing amounts due to two factors (1) As a result of prolonged chemotherapy in cases of pulmonary tuberculosis soon after its origin, the disease undergoes extensive resolution and the process is limited to a portion of a lobe or lung (2) As a result of technical advances in thoracic surgery, portions of the lung can be removed with much greater facility Thus the only *comparative material is that* which is available before the extensive use of chemotherapy Much of this material is from autopsies although many surgical specimens are also available

It is our opinion that when lung specimens of chronic pulmonary tuberculosis after antibiotic therapy are compared with those in which no such therapy was used striking differences are observed In making this study we believe that it is important to compare cases of similar duration A comparative study should answer the question as to whether the end results of healing are the same whether antibiotics are used or not

The comparison between both groups is made

chiefly on surgically resected lesions In some instances however autopsy material is utilized Comparisons will be made of the cavity encapsulated necrotic foci and the surrounding lung tissue

TUBERCULOUS CAVITY (BEFORE CHEMOTHERAPY)

The development of the cavity occurs from a tuberculous pneumonia which has first undergone necrosis and then liquefaction After the evacuation of the necrotic contents the cavity has a characteristic gross and microscopic appearance The cavity which generally lies a few millimeters beneath the pleura has a thin wall in which three layers may be distinguished The inner yellow layer is composed of non liquefied necrotic fragments The middle red zone is made up of tuberculous vascular granulation tissue The outer grey layer which represents the organized perifocal reaction is surrounded by firm lung tissue which represents perifocal reaction lying in the alveolar spaces Characteristic of all tuberculous cavities is the fact that the inner necrotic lining of the cavity wall is continuous with the ulcer of the draining bronchus The necrotic lining of the bronchial ulcer is also surrounded by a layer of granulation tissue The partial destruction of the bronchus with narrowing of the lumen causes a check valve mechanism at this site This results in the mechanical enlargement of the cavity since more air enters the cavity than can escape

Cavity Progression In untreated cases as the disease advances there is concomitant healing Progression of the disease may occur either from within the cavity or extension from without The process from within is that the tubercle bacilli within the lumen bathe the cavity wall and a progressive necrosis results When this occurs the zone of granulation tissue and part of the outer wall of fibrosis become incorporated within the necrotic zone Although the nuclei in these layers have become disintegrated the former structure of these zones is still discernible Concomitant with the progressive necrosis a new layer of vascular granulation tissue forms around it and beyond this a new area of perifocal reaction develops

The process from without is that new areas of tuberculous pneumonia may develop in the immediate proximity of the cavity and extend to involve it in the necrotic process It may liquefy and pour its contents into the lumen of the cavity

Thus as a cavity grows older there is progression both from within and without There is a concomitant repair of these areas of progression in the form of new granulation tissue and organization of the recently developed areas of perifocal reaction The thickness of the cavity wall is dependent upon the extent of organized perifocal reaction which occurs over a period of time The new areas of activity occur irregularly within the cavity wall As a result of this the thickness of older cavities is irregular

Cavity Healing Spontaneous healing of tuberculous cavities may occur without the aid of collapse therapy although it is extremely difficult to obtain a true incidence of this occurrence The closure and healing of tuberculous cavities has occurred with much greater frequency as a result of the various forms of collapse therapy Healing with obliteration of the cavity lumen is well documented in the literature [illegible] In the days prior to chemotherapy the pathologist s experience with these lesions was obtained chiefly from autopsy material since resectional surgery for tuberculosis preceded the use of antibiotics by a short period Death in these cases was often due to a cause other than tuberculosis

Healing of a tuberculous cavity may occur in one of two ways (1) With obliteration of the lumen and (2) with the lumen of the cavity remaining open

1 *Healing with obliteration of the lumen* We have previously pointed out that this is by far the more frequent form of cavity healing The end result of this type is either an inspissated (filled in) cavity or a radial scar Healing of this form occurs by the approximation of the ulcerated bronchial surfaces at the bronchocavitary junction Collapse therapy does much in these cases to bring this about Following the approximation of the bronchial surface proliferation of granulation tissue in this region continues until the apposing surfaces join and the lumen is obliterated If the granulating surfaces unite firmly the occlusion will be lasting and the cavity permanently closed In all instances in which an inspissated cavity or a radial scar exists the draining bronchus ends blindly either in the wall of the cavity or in an area of fibrosis connecting with the wall of the inspissated cavity

After closure of the bronchus the cavity wall contracts quite rapidly Since most cavities contain large necrotic masses within the lumen and along the inner wall, these become inspissated and form the core of the obliterated cavity Simultaneously, the wall of the cavity through an increase of collagen fibrils is converted into a zone of hyalinized connective tissue This in turn is surrounded by a wider *area of loose connective tissue* which represents the organized perifocal reaction This zone *is generally* wide because in most instances the cavity closed after the tuberculous process had been present for some time As we have already stated, the width of the cavity wall is dependent upon the extent of the organization *of perifocal reaction and that this increases with the age of process Collapse* therapy aids in the thickness of the cavity wall by entrapping the perifocal reaction within the alveoli

Radial scars generally result when at the time of the closure of the cavity there are only a few necrotic fragments within the cavity lumen After the space is obliterated the granulation tissue invades and replaces the necrotic material Subsequently, the granulation tissue is converted into connective tissue As this occurs there is a contraction of the tissues forming the cavity which results in a radial scar The peripheral portions of the scar taper off among the surrounding alveolar septa which they thicken The contraction also *results in a stretching and tearing of the surrounding* alveolar septa leaving dilated air sacs, often with bleb formation

2 *Healing with an open cavity—open healing* The healing of such cavities may occur in the presence *of draining bronchi* which open widely into the cavity lumen Although there are isolated reports in the literature,[4 18 20 22–8] [illegible] There are two com-

persistent absence of tubercle bacilli from the sputum, (2) the transformation of the tuberculous granulation tissue of the cavity wall into *a non specific fibrous tissue*

In the days prior to chemotherapy we observed only two cases of open healing in over 2 000 autopsies on individuals with chronic pulmonary tuberculosis The inner surface of *these cavities is lined by a smooth, grey or red* surface and their walls are thick The bronchi opening into these cavities are widely patent an[illegible] ch[illegible] *open" as in* "closed" healing types There is a gradual transformation of the wall into fibrous tissue at the expense of the specific tuberculous elements

One of the two cases showed an epithelialized surface while the other wall was composed only of connective tissue *The cavity walls in both* instances were thick

TUBERCULOUS CAVITY (AFTER CHEMOTHERAPY)

The administration of drugs is generally *begun after the tuberculous cavity has been present for some time It is our opinion that* there are striking changes brought about by the use of antibiotics and are as follows (1) clearing of the perifocal reaction, (2) effect on the progression of the cavity, (3) more rapid healing of the cavity wall (4) re epithelialization of the bronchus at the bronchocavitary junction with extension into the inner wall of the cavity, (5) more frequent inspissation of cavity contents and (6) more frequent "open" healing

Clearing of the Perifocal Reactions We have previously shown that one of the most readily observed changes following chemotherapy is to reduce perifocal reaction to a minimum [41] This observation has been confirmed by others [42 43] Most of the clearing of the shadows observed in serial roentgenograms following the institution of therapy is the result of the dissolution of the perifocal reaction

It is obvious that the best effect can be obtained when the drugs are administered before the extensive organization of the perifocal reaction has taken place Thus the third or outer layer of the cavity wall is either extremely thin or, in some instances, absent (*Fig 1a.*) The thinness of this layer depends upon the nearness which the drugs were first given after the formation of the cavity Similar untreated cases will show a *variably wide* alveolar filling process, cellular in its inner aspect and serous in the peripheral parts (Fig 1b)

Comparing treated and untreated cavities of similar anatomic age, *the chemotherapeutically* treated cavity is much thinner with an area of resilient lung tissue lying between it and the

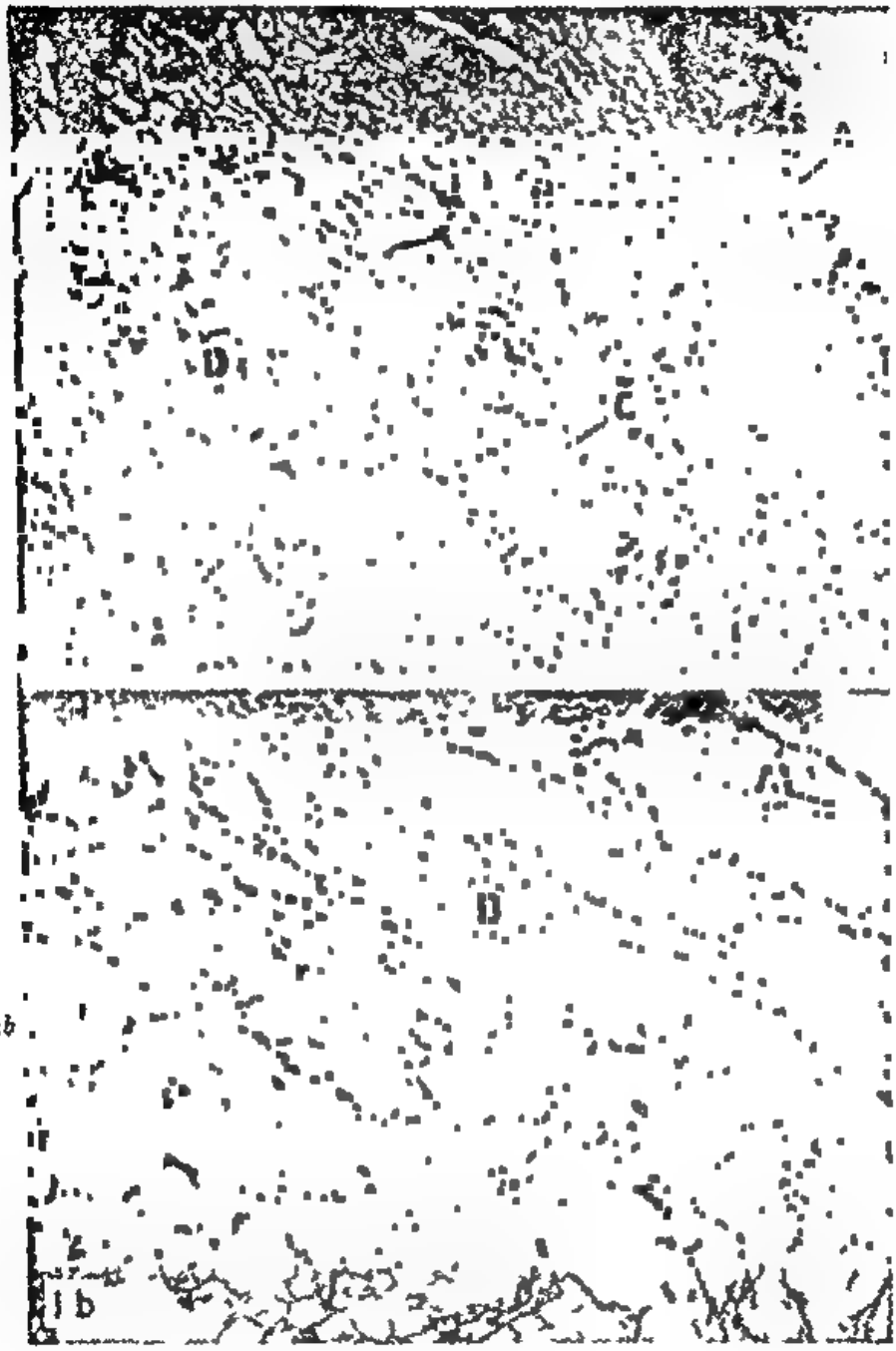

[illegible]

wall.

overlying pleura The cavity wall in the untreated cases is much thicker and often blends with a thickened, overlying pleura (Fig 2)

Effect on the Progression of the Cavity The administration of the drugs very soon alters the course of the tuberculous cavity In untreated cases healing changes keep pace with progression Progression, as we have already stated, occurs from within or without the cavity There is both macroscopic and microscopic evidence that progression is halted This is seen in absence of signs of progression from within and also the absence of new tuberculous foci rupturing into the lumen of the cavity Further evidence is seen in the lack of formation of new perifocal reaction around the cavity wall, new perifocal reaction indicating new activity in the tuberculous cavity

More Rapid Healing of the Cavity Wall We believe that this is difficult to assess The evaluation can be made only by knowing the approximate age of the cavity (from clinical studies) and by determining whether the healing changes are greater than those of similar age in untreated cases These changes must be striking and out of proportion to the age of the cavity, because healing changes occur in the natural course of the disease Thus the healing changes in the cavity wall, as evidenced by collagen connective tissue, are far out of proportion to what would be expected in cases such as those which had not had the benefit of chemotherapy

Re epithelialization of the Bronchus at the Bronchocavitary Junction The outstanding feature of drug therapy in tuberculosis is the healing of tuberculous ulcers with re epithelialization The drugs thus appear to exert their greatest effect of superficial surfaces The necrotic lining of the bronchus at this site is replaced by the granulation tissue The epithelial regeneration occurs from the intact epithelium just proximal to the ulcer The regenerated epithelium is generally flattened or squamous in character and extends onto the inner wall of the cavity for variable distances (Fig 3b) It generally stops where the cavity wall is lined by a pyogenic or a necrotic surface We have never seen regeneration occur over a necrotic surface

More Frequent Inspissation of Cavity Contents It is our opinion that the re-epithelialization disrupts the check valve mechanism which existed at the entrance of the ulcerated bronchus into the cavity and which allowed more air to enter than to leave the cavity As a result of this distention of the cavity no longer occurs and contraction of granulation tissue in its wall results in decreased size of the cavity As the granulation contracts the caseous contents within the cavity lumen become inspissated The fluid within the necrotic debris is absorbed As the process of healing continues calcium salts are deposited in the necrotic zone and the zone of granulation tissue is gradually converted into hyaline connective tissue

The end result in these cases is an inspissated cavity with a communicating bronchus (Fig 3a and b) Comparing the healed cavity after chemotherapy with that healed without the use of drugs, it is found that in treated cases the bronchus is patent, while in those untreated no bronchial communication can be demonstrated

It is not an unusual experience to find that a



FIG 2 The patient was a twenty seven year old white man whose onset of pulmonary tuberculosis began several years prior to his death He received no chemotherapy Coronal section of the lung shows a thick walled cavity occupying almost all of the right upper lobe (A) The greatly thickened pleura (B) fuses with the cavity wall The right lower lobe which shows large areas of fibrosis is the seat of bronchiectasis (C)

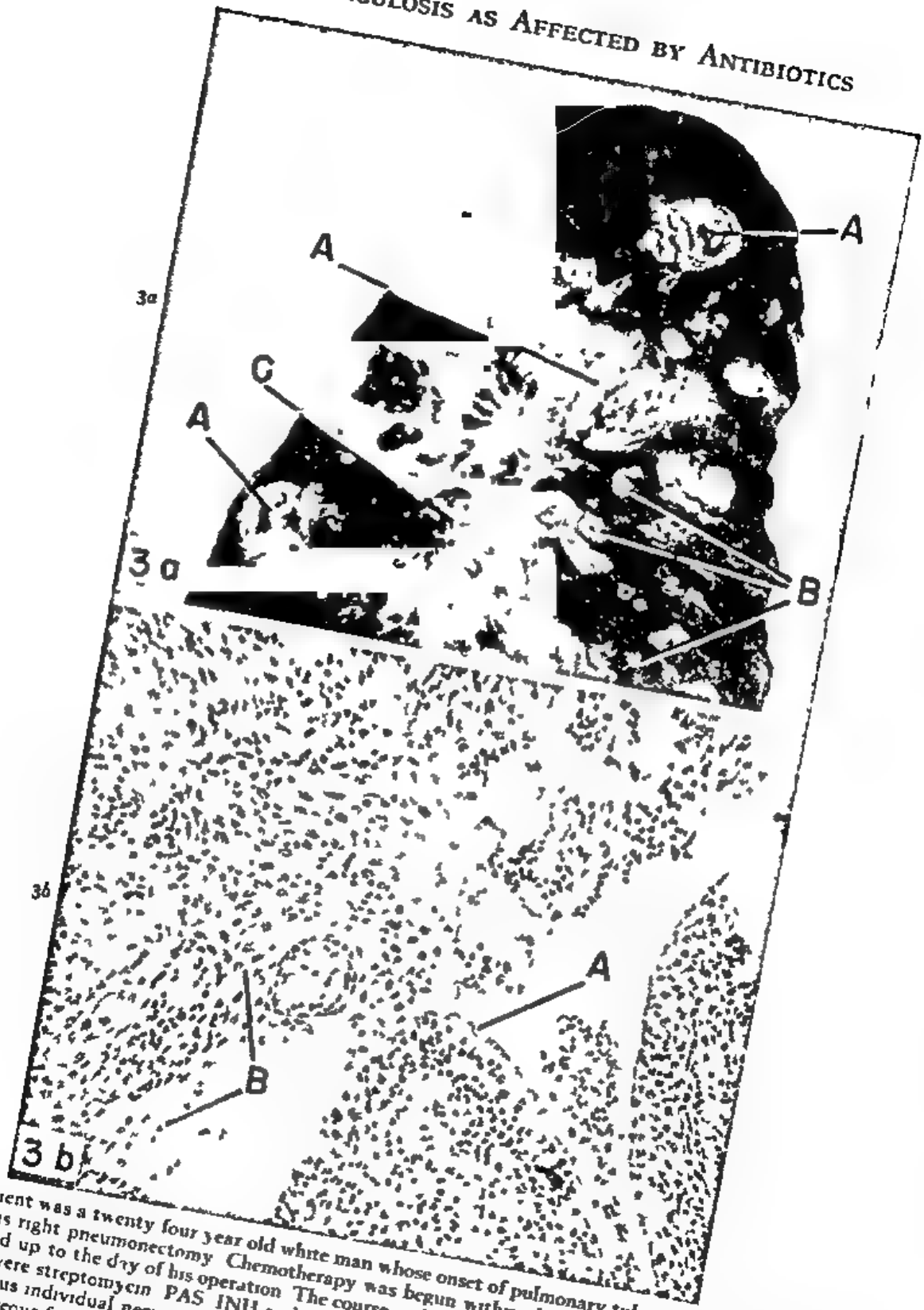

FIG 3 (a) The patient was a twenty four year old white man whose onset of pulmonary tuberculosis was two and a half years before his right pneumonectomy Chemotherapy was begun within the same month as the onset of his illness and continued up to the day of his operation The course and regimen of the drugs varied during this period The drugs utilized were streptomycin PAS INH and viomycin A coronal section of the right lung shows the lung occupied by numerous individual necrotic foci Some of these represent inspissated (filled in) cavities (A) Others are encapsulated, caseous foci which had never liquefied (B) some of these contain calcium salts (C) The capsules around all the necrotic foci are thin There is an absence of pulmonary fibrosis and emphysema In spite of extensive disease, the lung is not greatly reduced in size (b) Photomicrograph of the bronchocavitary junction of one of the inspissated cavities in Figure 3(a) shows the columnar epithelium of the intact bronchus (A) That which lines the adjoining cavity is thick squamous in character (B) The epithelium of the cavity lies on granulation tissue

cavity, which by roentgenographic studies had been observed to close, will subsequently show an annular shadow at the same site We have observed secondary liquefaction of the inspissated, necrotic contents within the lumen of the cavity. It is our impression that neutrophils are secreted into the bronchial lumen and extend into the inspissated cavity among the calcified necrotic fragments This results in a sequestration, liquefaction and evacuation of the cavity contents

In the light of the above observations, the important question arises as to whether the inspissated cavity with a patent bronchus is a potential source of danger Extensive microbiologic studies have been and are being carried out to answer this question [35–38]

More Frequent "Open" Healing Open healing is observed with increasing frequency after long-term chemotherapy We believe that this form of healing may occur after evacuation of an inspissated cavity or there may be open healing from the onset, the latter being the more frequent mode of healing The end result is the same in either form

Re-epithelialization of the bronchus is undoubtedly an important factor in the increased incidence of this form of healing In untreated cases the check-valve mechanism results in a retention of the necrotic contents within the cavity As a result of the healing of the ulcerated bronchial surface and re epithelialization wider drainage is now possible

Healing of these cavities occurs through the invasion of the necrotic lining by the surrounding vascular granulation tissue In occasional instances the epithelium may extend from the bronchus along the inner wall of the cavity on the granulation tissue Subsequently, with the increase of collagen, the granulation tissue is converted into hyaline connective tissue These cavities communicate with bronchi

ENCAPSULATED NECROTIC FOCI

These represent areas of tuberculous pneumonia which have undergone necrosis but have not become liquefied One of the factors which determines the development of liquefaction and cavity formation is the size of the focus although this does not appear to be the only factor Generally, the smaller the size of the original area of tuberculous pneumonia, the greater is the chance for encapsulation

As the area of tuberculous pneumonia undergoes necrosis there is a concomitant development of tuberculous granulation tissue at its periphery The granulation tissue encloses the necrotic zone completely and in our experience no bronchi communicate with it If bronchi were to communicate with these, there would always be the possibility that they are a possible source of danger It has been our experience that the entrance of neutrophils, which liberate the proteolytic enzymes necessary to liquefy necrotic foci, may come through the lumen of the bronchus

The zone of granulation tissue and perifocal reaction around the necrotic center are similar to that present in the cavity wall As the process of healing continues, the granulation tissue is converted into hyalinized, connective tissue forming the inner part of the capsule, while that portion of the perifocal reaction which is not eliminated becomes organized into an outer and wider zone of loose connective tissue The ultimate fate of the perifocal reaction depends upon the patency of the draining bronchi and lymphatic channels proximal to these involved areas If the bronchi and lymphatic vessels are clear, the peripheral portion is either expectorated or absorbed by the lymphatic channels Collapse therapy, by its compression of the bronchi and lymphatic channels, prevents the elimination of the perifocal reaction and thus results in more extensive organization of the perifocal reaction

Contraction of the necrotic foci results in a stretching and tearing of the surrounding alveolar septa with the formation of emphysematous areas in these regions Bleb formation generally occurs around the larger foci

Encapsulated Necrotic Foci after Chemotherapy The essential change brought about by antibiotics is in the thickness of the capsule As a result of the clearing of the perifocal reaction, there is either only a very narrow or no loose connective tissue zone around the inner hyalinized connective tissue capsule The inner hyalinized zone is of a width similar to that in cases in which no antibiotics were employed and represents the end stage of the tuberculous process Thus healed encapsulated, caseous foci showing the favorable effect of chemotherapy are different from similar healed necrotic areas without drugs in that the outer loose connective tissue capsule of the latter is thicker (Fig 3a)

Pulmonary Fibrosis and Emphysema Resulting from Tuberculous Foci The basic tuberculous process in the lung takes place in the alveolar spaces and results in a tuberculous pneumonia Generally, the smaller the size of these foci, the greater will be the opportunity for organization of the pneumonia This is best seen in the acinous nodose foci where the process develops in the lung tissue beyond the terminal bronchiole It also occurs in areas where the tuberculous pneumonia occupies only a small part of a lobule Organization of the tuberculous pneumonia occurs before the development of necrosis The fibrinocellular exudate within the alveoli is invaded by fibroblasts, epithelioid cells Langhans' giant cells and collagen fibers These elements replace the exudate and are attached to the surrounding alveolar septa which are thickened by similar cells As the collagen fibers increase at the expense of the cellular elements, an irregular area of fibrosis remains which is surrounded by stretched and torn alveolar septa

Pulmonary fibrosis may also replace smaller necrotic foci The zones of granulation tissue around the necrotic foci gradually invade and replace the caseous centers As the collagen fibers increase in number they compress and replace the surrounding cells and capillaries of the granulation tissue As the granulation tissue is transformed into connective tissue, there is a gradual contraction of the focus Thus the end result is an irregular scar smaller than the necrotic focus which it replaces As the focus contracts it stretches the surrounding alveolar septa to which it is attached resulting in a perifocal emphysema

Emphysema in pulmonary tuberculosis is a concomitant part of the destruction and resultant contraction of the lung parenchyma Thus as the tuberculous process progresses with necrosis and surrounding fibrosis a compensatory dilatation of the surrounding air sacs develops Since the lung parenchyma is a contiguous elastic structure, any replacement of it must be compensated by the surrounding intact portion This is done by a stretching of the surrounding elastic fibers When the thinned fiber cannot stretch far enough it ruptures

Pulmonary Fibrosis and Emphysema after Chemotherapy There is an over all decrease in the amount of fibrosis and emphysema in patients who have received chemotherapy over a long period of time when compared with cases of similar duration in which the patients received no drug chemotherapy This is true particularly when the drugs have been given soon after the onset of the illness This decrease is due both to the elimination of the perifocal reaction resulting in decreased fibrosis and to the fact that in prolonged chemotherapy dissemination is minimal or absent We have been impressed with the fact that there are many less non necrotic tuberculous foci after chemotherapy than in non-treated patients Acinous nodose foci a common tuberculous lesion before chemotherapy, are an extremely infrequent finding Thus there are two important ways in which the development of pulmonary fibrosis in pulmonary tuberculosis is greatly reduced by the use of antibiotics

Emphysema which results from the contraction resulting in the formation of fibrosis, is also diminished as a result of the prolonged use of antibiotics The extent of the emphysematous areas around necrotic foci and in subpleural regions is far less than in comparable cases which have not had the benefit of chemotherapy

As a result of the greatly lessened pulmonary fibrosis and emphysema in patients receiving prolonged chemotherapy there is a greater lung volume than in similar untreated patients Intact lung parenchyma which rarely contains scars widely separates the necrotic foci (Fig 3a)

CONCLUSIONS

Pulmonary tuberculosis is greatly altered by the prolonged use of antibiotics Inspissated cavities are observed with much greater frequency than in the prechemotherapy era Re epithelialized bronchi communicate with these cavities The walls of the cavities are thinner than those of similar ages which have received no antibiotics Necrotic foci are also surrounded by thinner capsules than foci of similar ages not having the benefit of chemotherapy The decreased thickness of the areas of fibrosis around the cavities and necrotic foci is the result of the elimination of the perifocal reaction Open healing of tuberculous cavities occurs more frequently under the influence of prolonged chemotherapy The end result in such cases is a relatively thin cavity wall composed of hyalinized connective tissue with a complete loss of specific tuberculous elements

Much less frequently is there epithelialization of such cavity walls

Pulmonary fibrosis and emphysema are greatly lessened as a result of the prolonged use of antibiotics, thus a lessened decrease in the lung volume

Acknowledgment The author gratefully acknowledges the cooperation of the Medical Illustration Departments of the Veterans Administration Hospital East Orange, N J, the Veterans Administration Hospital, Brooklyn, N Y and Sea View Hospital, Staten Island N Y

REFERENCES

1 HANSEMANN D Über Heilung und Heilbarkeit der Lungenphthise *Klin Wchnschr* 39 745 1902
2 HART C Über die Heilbarkeit und Heilung tuberkulöser Lungenkavernen *Ztschr f Tuberk* 35 253 1922
3 BACMEISTER A Das Kavernenproblem in seiner klinischen Bedeutung *Beitr z Klin d Tuberk* 67 157 1927
4 HUEBSCHMANN P Pathologische Anatomie der Tuberkulose Berlin 1928 Julius Springer
5 GILBERT M Deux observations anatomo-cliniques concernant la guerison de cavernes tuberculeuses du poumon *Rev de la tuberc* 12 979 1931
6 CORYLLOS P N How do rest and collapse treatment cure pulmonary tuberculosis? *J A M A*, 100 480 1933
7 SWEANY H C The changes of pulmonary tuberculosis as a result of treatment *Am Rev Tuberc* 32 544 1935
8 MCPHEDRAN R M and LONG E R Clinical and pathologic notes on a case of healed pulmonary tuberculosis *Arch Path* 20 168 1935
9 GRAEFF S Die Kaverne der Lungentuberkulose vom pathologisch anatomischen Standpunkt aus *Ergebn d ges Tuberk Forsch* 7 257 1935
10 AMBERSON J B The process of resolution in pulmonary tuberculosis *Am Rev Tuberc* 33 269 1936
11 JACQUEROD M The Natural Processes of Healing in Pulmonary Tuberculosis Translated by J D Sinclair New York 1926 William Wood and Co
12 TCHERTKOFF I G and BOBROWITZ I D Spontaneous closure of tuberculous pulmonary cavities *Quart Bull Sea View Hosp* 1 173 1936
13 VON KARWOWSKI J Pathologisch anatomische Beiträge zur Frage der aktiven Behandlungsmethode der grossen und pleuranahen tuberkulösen Kaverne *Beitr z Klin d Tuberk* 89 59 1937
14 DERSCHEID G and TOUSSAINT P Necroses tuberculeuses et cavernes pulmonaires processes de guérison *Presse méd* 45 1739 1937
15 PINNER M Pathology of Pulmonary Collapse In Alexander s The Collapse Therapy of Pulmonary Tuberculosis Springfield Ill 1937 Charles C Thomas
16 ROBERTS L and PAGEL W Behaviour of tuberculous cavities in the lung under artificial pneumothorax treatment *Brit M J* 2 1258 1938
17 WURM H Pathologische Anatomie d Heilungsvorgaenge b d Tuberkul Lungenkaverne In Heinkremer Schmidt Kollapstherapie der Lungentuberkulose p 33 Leipzig 1938 Thieme
18 PAGEL, W and SIMMONDS F A H The healing of cavities *Am J M Sc* 197 281 1939
19 AUERBACH O and GREEN H The pathology of clinically healed tuberculous cavities *Am Rev Tuberc* 52 707 1949
20 PINNER M Healing of tuberculous cavities *Am Rev Tuberc* 42 731 1940
21 SHAMASKIN A Inspissated cavity *Am Rev Tuberc* 44 310 1941
22 PAGEL, W and SIMMONDS F A H Cavity healing and bronchial occlusion *Am J M Sc* 203 177, 1942
23 BOBROWITZ I D The round pulmonary tuberculous focus *Am Rev Tuberc* 47 472 1943
24 LOESCH J Closure of tuberculous cavities *Am Rev Tuberc* 50 500 1944
25 LOESCH J Closure and healing of tuberculous cavities *Am Rev Tuberc*, 58 322 1948
26 STUDY R S and MORGENSTERN P Prognosis of inspissated cavities *Am Rev Tuberc* 59 53 1949
27 SAUGMAN C Dauerfolge der Pneumothoraxbehandlung bei Lungentuberkulose *Ztschr f Tuberk* 34 425 1931
28 PAGEL, W Zur Enstehungsgeschichte und Kausistik der Lungentuberkulose *Beitr z Klin d Tuberk* 79 383 1931–32
29 ALEXANDER H Zum Problem der Tuberkulosen Kaverne *Beitr z Klin d Tuberk* 86 424 1935
30 PAGEL, W and ROBINSON H J Spontaneous cavity healing *Papworth Res Bull* 1 37 1936
31 AUERBACH O and STEMMERMANN G N Anatomic changes in tuberculosis following streptomycin therapy *Am Rev Tuberc* 58 449 1948
32 MAHON H Pathology of pulmonary tuberculosis as modified by streptomycin therapy *Am Rev Tuberc* 61 543 1950
33 SILVERTHORNE M D and SILVERMAN G The effect of streptomycin on the morphology of the tuberculous lesion *Am Rev Tuberc* 61 525 1950
34 AUERBACH O KATZ H L and SMALL, M J The effect of streptomycin therapy on the bronchocavitary junction and its relation to cavity healing *Am Rev Tuberc* 67 173 1953
35 O BRIEN E J MILLER A C CHAPMAN P T KOSTER K and O ROURKE P V The present chaos regarding resection of residual caseous lesions in pulmonary tuberculosis *J Thoracic Surg* 26 441 1953
36 D ESOPO N D RYAN B J and MEDLAR E M Prolonged therapy with streptomycin—PAS A clinical pathological correlation P 78 Tr of 10th Conference on Chemotherapy of Tuberculosis held under the Auspices of the U S Veterans Administration Army and Navy Jan 25 28 1951
37 RYAN B J MEDLAR E M and WELLES E S Simple excision in the treatment of pulmonary tuberculosis *J Thoracic Surg* 23 32 1952

38 D'ESOPO N D, BERNSTEIN, S and DECKER, A M, RALEIGH, J W and STEENKEN, W, JR. Bacteriology of lesions resected during chemotherapy, p 228 Tr of 12th Conference of Chemotherapy of Tuberculosis, held under the auspices of the U S Veterans Administration, Army and Navy Feb 9–12 1953

39 MEDLAR, E M, BERNSTEIN, S and STEWARD D M A bacteriologic study of resected tuberculous lesions Am Rev Tuberc 66 36 1952

40 STEENKEN, W JR and WOLINSKY E Methods of determining the viability of tubercle bacilli a critique, p 269 Tr of 12th Conference on Chemotherapy of Tuberculosis held under the auspices of the U S Veterans Administration Army and Navy, Feb 9–12 1953

41 STEELE J D NARODICK B G and CADDEN A V The influence of long term chemotherapy on the surgery of pulmonary tuberculosis J Thoracic Surg, 26 459 1953

42 GRANVILLE, G E JENKINS D E, COOLEY, D A DE BAKEY, M E, WHITCOMB F C and HALPERT B Cultural properties of M tuberculosis in resected pulmonary lesions of patients treated with streptomycin and para aminosalicylic acid Am Rev Tuberc 68 727, 1953

43 FALK A, KAUFMAN J E and TUCKER, W B Resectional surgery in pulmonary tuberculosis with a bacteriologic study of the resected tissue, p 216 Tr of 12th Conference on Chemotherapy of Tuberculosis held under the auspices of the U S Veterans Administration Army and Navy, Feb 9–12 1953

44 DUBOS R J and HIRSCH J G The antimycobacterial activity of a peptide preparation derived from calf thymus J Exper Med 99 55 1954

45 HOBBY, G H, AUERBACH O, LENERT T F, SMALL, M J and COMER J V The viability of tubercle bacilli in tuberculous lesions following chemotherapy Am Rev Tuberc, 70 191, 1954.

Fatal Pulmonary Hemorrhage in Tuberculosis

J Robert Thompson, M D, *Chicago, Illinois*

Fatal hemorrhage is not an uncommon cause of death in patients afflicted with pulmonary tuberculosis Perhaps the most disturbing feature is that many of the individuals who are stricken have passed the acute phase of their illness and apparently are on the road to recovery

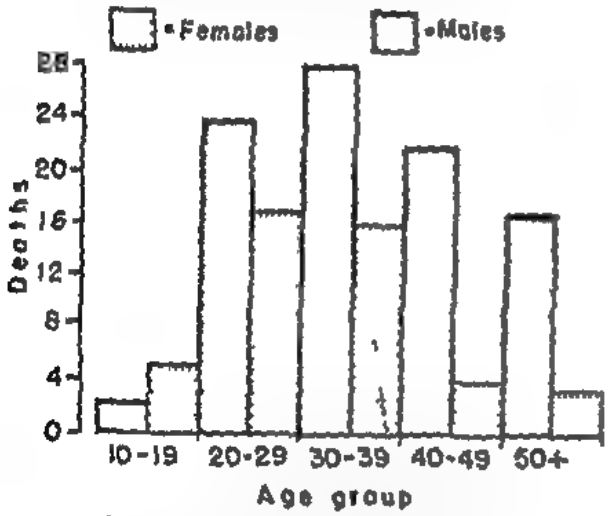

Fig 1 Graph depicting the incidence of fatal pulmonary hemorrhage according to age and sex

The incidence of fatal hemorrhage has been estimated by different authors to be from 1 to 5 per cent [1] A survey of 2,830 autopsies at the Municipal Tuberculosis Sanitarium revealed that 138 cases (4 87 per cent) died in this manner Of this total, ninety-three were men and forty-five were women, and the greatest incidence was in the age group thirty to thirty-nine years (Fig 1) The youngest and oldest individuals to suffer fatal hemorrhage were eleven and sixty-five years of age, respectively Of the 138 only 57 gave a history of having had any previous bleeding or hemorrhage The chronicity of the disease was certainly a factor, the interval of time varying from one month to twenty-one years, and thirty-three patients gave a history of having had the disease for a period of four years or over Twenty-eight had pneumothorax for varying lengths of time, the maximum being four years, however, their disease was of such a nature that in only a few instances was any beneficial effect noted clinically and no relationship to hemorrhage could be shown The most common complication was amyloidosis, thirty-one cases (22 per cent) showed gross

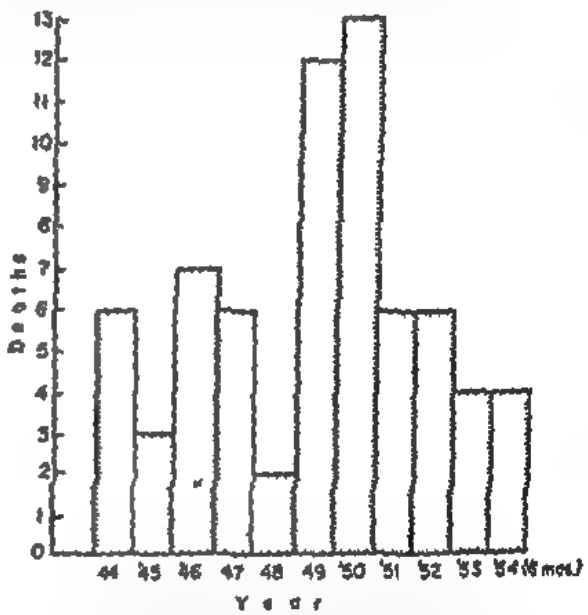

Fig. 2 Graphic comparison of the number of deaths from fatal pulmonary hemorrhages during the last ten years

and/or microscopic evidence of amyloid degeneration (this is about the same percentage as is seen routinely in our autopsy work) There was one case each of hypertensive heart disease, chronic glomerulonephritis, syphilis, silicosis, nutritional cirrhosis and cor pulmonale with failure

There is no chronologic pattern as to the occurrences of these fatal hemorrhages. For example, in the years 1933, 1934 and 1935 several were recorded, and the next comparable number was in the middle 1940's, however, the highest total for any single year occurred in 1950 (Fig 2) In spite of the chemotherapeutic and surgical measures employed in the

past few years the incidence of fatal hemor
rhage has remained about the same Since
chronicity is a factor it stands to reason that
procedures which prolong the course of the
disease also increase the likelihood of sudden
fatal hemorrhage This is especially true in
cases which are far advanced at the time of
admission to the sanitarium One cannot dis
count the observations of Petersen[1] in which
he correlated hemorrhage episodes in the
tuberculous patient with conditional changes
in the meteorologic environment These epi
sodes he associated with blood pressure in
creases attributable to pressor changes
One usually associates fatal pulmonary
hemorrhage with the rupture of an artery
adjacent to or a part of a parenchymal cavity
wall following an aneurysmal dilatation These
dilatations have been termed Rasmussen's
aneurysms as Dr Vald Rasmussen was the
first to describe them in 1868[2] The number of
these lesions identified varies greatly in differ
ent institutions and perhaps to some extent in
proportion to the time spent dissecting the
specimens Proliferative and reparative proc
esses usually prevent aneurysmal formation
within tuberculous cavities by occluding the
blood vessels before their walls are destroyed
Because of the magnitude of the hemorrhage
and the destructive and/or reparative processes
going on in the lung it is almost impossible to
demonstrate the site of bleeding This is espe
cially true in those cases in which the bleeding
apparently results from the rupture of an
aneurysm whereas bronchial lesions which
perforate or erode the adjoining vessel can be
demonstrated with relative ease Rasmussen
pointed out in his article that many men before
him had attempted to explain the causes and
mechanisms of fatal pulmonary hemorrhage
but had been rather unsuccessful in their
attempts Laennec supported the idea that fre
quently pulmonary hemorrhage came about by
a diapedesis of blood through the bronchial
mucus membranes A factor favoring this
theory was that vessels in the vicinity of the
cavity especially in the fibrous wall were
usually obliterated This was true also for
vessels which traversed the cavity however
we know now that many of these vessels remain
open Andral was of the opinion that there
were three possible sources of pulmonary
hemorrhage first that seen in conjunction with
a tuberculous endobronchitis however he was
not in a position to demonstrate the actual
bleeding point second bleeding in cases of
pulmonary apoplexy (it is assumed that by
this he meant vascular disturbances such as
hemorrhagic infarctions) and third hemor
rhage from a cavity In this instance Andral
was able to demonstrate a bleeding vessel in
only one case—a vessel that was enclosed in a
trabeculum crossing the cavity
Rokitansky was about the only writer who
had described cases such as simulated those of
Rasmussen According to Rokitansky the
copious hemorrhages seen in tuberculosis arose
from branches of the pulmonary arteries situ
ated in the condensed walls of cavities espe
cially bronchiectatic cavities He was of the
opinion that the vessel walls became macer
ated jelly like and soft due to exposure to the
contents of the cavity and necrotic processes
in the wall of the cavity and gave rise to
would burst and a massive hemorrhage would
take place The lesion he described as either
a split like fissure in the vessel or the separation
of a portion of the vascular wall gave rise to
a punched out defect Very frequently this
punched out defect was seen in an aneurysmal
dilatation of the vessel toward the cavity
Rasmussen's observations were based on the
examination of eleven patients who died during
a violent hemoptysis Eight of these were
patients in whom there was a rupture of a
vessel running in the wall of the cavity and
the other three were instances of rupture of an
aneurysm of the aorta into the bronchus or into
the pulmonary tissue itself Of the eight cases
in which hemorrhage was due to a rupture of a
vessel adjacent to a cavity four demonstrated
rupture of a small sac like aneurysm which
had developed on a branch of a pulmonary
artery running in the wall of the cavity and
four showed dilatation or ectasia of a branch
of the pulmonary artery with operculated
rupture These aneurysms varied in size from
that of a pea to a walnut The wall varied in
thickness and in those which had not ruptured
the wall was seen to be two or three times
thicker than the rest of the vessel The lesions
were sometimes multiple and the vessels on
which the aneurysms were located averaged
from 1 to 3 mm in diameter
Plessinger and Jolly[3] studied a series of
667 cases from the years 1938 to 1947 and of
these forty nine died of massive pulmonary
hemorrhage In twenty nine of these cases

they were able to demonstrate an aneurysmal dilatation of a vessel On the basis of their histologic studies they describe the incriminative vessel as usually running tangential to the wall of the cavity As the vessel broached the wall of the cavity it passed through its own diseased pulmonary tissue and started to dilate slightly Concomitantly a variable degree of endothelial thickening usually occurred so that the lumen of the vessel was slightly constricted Similar obliterative endothelial changes were observed in the other large vessels in the vicinity of the cavity wall Serial sections revealed that the vessel wall proper dilated eccentrically the dilatation taking place only on the side toward the lumen of the cavity Finally a point of rupture of the media was encountered A great deal of emphasis is placed on the presence of a fibrin clot in every unruptured aneurysm and in some of the ruptured aneurysms They are in agreement with Rasmussen s theory that this clot may occasionally plug the rent in the aneurysmal sac and thus prevent a fatal hemorrhage for some time

O Leary[6] reported a death occurring in a nine month old infant in which instance a recently ulcerated cavity eroded a large vessel Certainly some of the cavities seen appear to be so rapidly excavating that proliferative changes in the neighboring blood vessels do not take place

Codina Suque and Mansilla Delicado[1] believed that bleeding might be the result of a profuse diapedesis of blood into the alveolar spaces quite removed from an active tuberculous process or at least from an ulcerating lesion They were of the opinion that what was commonly considered to be posthemorrhagic seeding probably represented hemorrhagic areas complicating pre-existing tuberculous foci The pre existing tuberculous involvement we would assume to have been a recent bron

lost but the impingement on functional lung parenchyma which accounts for death

Quirogi[4] points out that fatal hemorrhage may be the result of a rapidly ulcerating caseous pneumonia (necrotic pneumonia of Sabourin) or from a rupture of small vessels constituting the vascular make-up of cavity

FIG 3 Section through the lung showing Rasmussen s aneurysm in the medial portion of a cavity surrounded by dark red clotted blood A small rent was found in the wall of the aneurysm which was responsible for the fatal hemorrhage

walls However we have not seen sufficient evidence of bleeding from granulation tissue such as lines most tuberculous cavities to account for a fatal hemorrhage in any of the cases studied Klosk[3] reported a case of fatal hemorrhage due to rupture of a large branch of the pulmonary artery without aneurysmal formation—a circumstance he considered unique

The inconsistency of the mechanism of fatal hemorrhage can best be illustrated by the following case reports

CASE REPORTS

CASE 1 E S a forty three year old Negro man was admitted to the sanitarium approximately one year after the onset of his illness He had been streaking for three weeks prior to admission and on the second hospital day he suffered a severe hemorrhage and expired one hour later

Pathologically, the lungs were emphysematous and on section multiple cavities were seen There was a 3 5 cm cavity in the upper portion of the right lung which had a heavy walled aneurysm 1 5 cm in diameter within it (Fig 3) Careful dissection revealed a rupture

FIG 4 A section through the left lung showing a large cavity in the apex filled with clotted blood and a small cavity in the mid portion with a probe extending from the branch of the right pulmonary artery into the cavity

of this aneurysm which was responsible for the fatal hemorrhage

CASE II M J was a thirty five year old foreign born white woman whose husband had died from pulmonary tuberculosis one year before her admission Her health was good she maintained, until one month before coming to the sanitarium Physical examination was essentially normal except for the chest which revealed dullness to percussion over the left lung and harsh breath sounds over both apices X ray film inspection revealed considerable involvement of the left lung and the sputum was positive for acid fast bacilli Her course was progressively downhill and she died six months after admission to the sanitarium with laryngeal and intestinal complications Death however was sudden with massive pulmonary hemorrhage

Pathologic examination of this lung (Fig 4) revealed a 7 cm cavity in the apex which was filled with a dark red blood clot There was a smaller cavity measuring 2 5 cm in diameter in the upper part of the lower lobe which was filled with what appeared to be an older clot and into this cavity protruded a 1 5 cm aneurysmal dilatation of the pulmonary artery Careful dissection revealed a rent in the wall of this aneurysmal dilatation which was the source of the bleeding

CASE III A P a thirty five year old Negro woman entered the sanitarium approximately six months after the onset of illness She had been coughing and expectorating considerable material prior to admission and there was an occasional blood streaked sputum She was known to have had hypertension for some time and her blood pressure on admission was 195 120 Previously induced pneumothorax on the right obscured the physical findings but x ray film revealed considerable disease in the right lung with most involvement apparently in the mid lung field In spite of supportive therapy her disease progressed and was complicated by severe tuberculous laryngitis Approximately sixteen months after admission to the sanitarium she expired suddenly with massive pulmonary hemorrhage

A middle section of the lungs showed a large cavity in the left lower lobe with a heavy fibrous wall surrounding it and pneumonic consolidation in the adjacent parenchyma The remainder of the lungs showed a flooding of the acini with blood (Fig 5) No residue of an earlier infection could be found and because of the nature of this lesion it was considered a young adult primary infection Dissection failed to reveal any aneurysmal dilatation of a vessel the source of hemorrhage was apparently the erosion of a branch of the pulmonary artery

CASE IV W N was a forty three year old white man whose mother had died from pulmonary tuberculosis when he was seven years of age He was in fairly good health until four years before admission at which time he had a severe cold with a cough and pulmonary tuberculosis was diagnosed He had been in and out of the sanitarium on numerous occasions, usually leaving against medical advice Six months before final admission he suffered severe

FIG 5 Close up of the right lower lobe to show the flooding of acini with blood

FIG 6 Close-up of the larynx and upper portion of the trachea with a huge blood clot in place as was found at the time of postmortem examination

pulmonary hemorrhage and continued to have blood streaked sputum afterward He was a known alcoholic and physical examination revealed a poorly nourished white male who showed evidence of marked weight loss (50 pounds) with physical findings of a markedly enlarged liver, dullness over the right lung field and many rales over the entire right lung

marked albuminuria, positive congo red test for amyloidosis, evidence of liver malfunction and sputum positive for acid fast bacilli He had a sudden massive pulmonary hemorrhage and expired

Pathologically, there was a huge dark red blood clot projecting out of the larynx (Fig 6) and on sectioning the lungs one saw that there was cavitation in both upper portions, that on the right being more extensive and most of the cavities were filled with dark red clotted blood Extensive dissection failed to reveal the point of rupture of the pulmonary artery The cyst-like cavities in the upper portion of the right lung communicated with bronchi and apparently represented old tuberculous cavities which had undergone "open-healing"

CASE V S T, a forty three year old Negro man who was born in Memphis, Tennessee, had worked as a sand blaster for fourteen years The onset of his illness was approximately one year before admission to the sanitarium His chief complaint was weakness, there had been one episode of hemoptysis Approximately two weeks after entering the sanitarium he suffered a massive fatal hemorrhage

Sagittal sections revealed a large cavity in the right lung surrounded by consolidated parenchyma Small firm nodulations were felt in portions of the lung The left lung showed a cavity in the mid portion and there were several caseous infiltrates noted in the lung parenchyma, especially in the upper portion Smaller ulcerocaseous lesions were noted throughout the right lung The lymph nodes were hard and rubbery in consistency and on section showed whorls of fibrous tissue indicative of some degree of silicosis None of the cavities showed a definite limiting fibrous wall and careful dissection failed to reveal a bleeding point This undoubtedly represents a case of

FIG 7 Close up to illustrate ulceration of a main bronchus note the clot in place and the small ptic defect superior to it

erosion of a vessel wall by one of these rapidly ulcerating lesions

CASE VI T I, a sixty one year old white foreign born woman was known to have pulmonary tuberculosis for at least nine years before admission to the sanitarium During that time she had three or four acute febrile episodes but at no time did she require sanitarium care Her husband had died from tuberculosis about six years before and x ray films were taken periodically to determine the status of her pulmonary lesion A febrile episode two months before admission was accompanied by high temperature pain in the chest cough fatigue and weight loss and she expectorated a few cc of yellowish sputum which was positive for acid fast bacilli Sanitarium care was recommended Aside from a blood pressure of 170/100 physical findings upon admission were limited chiefly to the right lung which revealed slight dullness on percussion and limited excursions No rales were heard in the chest at the time of admission During her stay in the sanitarium she was given a course of streptomycin for approximately ninety days with some improvement Bronchoscopy revealed a tuberculous endobronchitis on the right with bronchostenosis Because of this finding right pneumonectomy was considered but she refused surgery She was ambulatory for the most part during her stay in the sanitarium and occasionally showed some bloody streaking of the sputum Approximately eighteen months after admission to the sanitarium she experienced a massive pulmonary hemorrhage

A mid section of the lung showed several fibrocaseous infiltrations scattered throughout the right lung with some fibrosis and retraction of the right apex A rather large solitary fibrocaseous lesion was noted at the periphery of the right mid lung field There was marked ulceration of the mucosa of the mainstem bronchus and the secondary bronchi on the right In the anterior portion of the lower lobe bronchus a few centimeters from its origin a large oval defect was noted (Fig 7) This defect was almost entirely filled by an organized blood clot however there was a small elliptical opening superior to the clot through which a probe could be passed to communicate with the adjacent pulmonary artery This case demonstrates well the erosion of a main vessel by a long standing tuberculous endobronchitis

CASE VII M P a sixty one year old white woman, foreign born gave a history of having had the flu several times For one year prior to admission she had slow progressive loss of weight and a few days before suffered a rather severe hemoptysis with streaking of the sputum every day thereafter She entered a private hospital where a diagnosis of tuberculosis was made Her sputum was positive for acid fast bacilli and other laboratory examinations were negative with the exception of low grade hypochromic anemia On bed rest over a period of six months she gradually improved but suddenly expired with a massive pulmonary hemorrhage

At autopsy a defect was found in the left upper lobe bronchus This defect measured 6 mm in diameter and the base of it was formed by a firm peribronchial lymph node (Fig 8) In the right main bronchus the mucosa was extremely thin and transparent and pigmented peribronchial nodes could be seen shining through The hemorrhage arose from the bronchial artery which was eroded by the hard tuberculous node

CASE VIII H Z a twenty six year old white man was visiting friends in the city when he suffered a pulmonary hemorrhage and was admitted to the sanitarium as an emergency He had never been treated in a tuberculosis sanitarium but he stated that at the age of two years he had whooping cough which necessitated hospitalization for twenty four months Subsequently when he was admitted



8



9

FIG 8 Close-up to show the black peribronchial node projecting through the anterior wall of the right main bronchus, and the clotted blood filling the lumen distally

FIG 9 Close up showing the necrotic lesion and the slightly enlarged hilar lymph node The node contained some small caseous infiltrations

to grammar school a chest x-ray film was taken and his parents were informed that there was considerable scarring of his lungs compatible with healed tuberculosis In the years following he was hospitalized frequently because of his "weakened" condition He stated that recently he had developed slight cough with a very small amount of expectoration, experienced some chest pain and had mild dyspnea on exertion Occasionally there were evening temperature elevations up to 101°F.

Physical examination revealed a well developed and well nourished white man apprehensive and acutely ill Examination of the chest showed impaired resonance and bronchial breathing over the right base Sputum specimen was negative for acid fast bacilli Three days after admission to the sanitarium he suffered a severe pulmonary hemorrhage and expired

A mid-section of the lung disclosed a few small fibrocaseous tubercles in the upper portion of each lung These tubercles appeared to be fairly well encapsulated At a point in the right bronchus where the upper lobe bronchus takes its origin there was a ne[illegible] approximately 1.0 cm. in diameter (F[illegible] a section of this le[illegible] revealed that t[illegible] bronchial wall [illegible] d in this process. This f[illegible] a branc[illegible] bronchial artery [illegible] onsible

massive hemorrhage that was seen The parenchymal disease was quiescent.

COMMENTS

Probably a massive hemorrhage produces death by suffocation, although in some instances, the loss of blood itself may be sufficient to terminate a cachectic individual. An estimation of the actual blood loss is difficult, as one must consider the amount of blood coughed up and expelled and that found in the lung and gastrointestinal tract at the time of postmortem examination. There is not much doubt that, in some cases, the total volume approximates 1,000 cc Most patients die suddenly following a massive hemorrhage, and do not present the picture of exsanguination. The amount of blood necessary to produce death by suffocation probably varies greatly and is dependent upon several factors When the main airways are filled to overflowing (as seen in Figure 6) undoubtedly the individual is asphyxiated by his own blood On the other hand, collections of blood in the functional

[illegible]

individual even though the volume of blood is [illegible]

[illegible]ce of a definite aneurysm has been

the exception instead of the rule in the routine examination of lungs from fatal hemorrhage cases at this institution It was impossible to identify the bleeding vessel in many cases, however, this is true in instances of hemorrhage from other organ systems A compilation of the findings in eighty consecutive cases is listed below

Bleeding Point	No of Cases
None identified	61
Pulmonary artery (no aneurysm)	8
Rasmussen aneurysm	6
Bronchial artery	5
Total	80

Even though the caliber of the involved vessels varied considerably in different cases no correlation could be made between the size of the vessel and the magnitude of the hemorrhage or the rapidity of death Profuse hemorrhage from the small bronchial arteries correspond to hemorrhages from the larger pulmonary artery branches because of the differences in pressure The pressure in the lesser (pulmonary) circulation is estimated to be about one sixth (mean value) that of the greater (systemic) circulation Since the bronchial artery is derived from the aorta, the pressure no doubt is consistent with systemic pressure When the lung has widespread involvement, the amount of blood flowing through the pulmonary arteries to the affected parts is proportionately reduced and the pressure is correspondingly less Recent work by Marchand et al[5] has shown that the pattern of the bronchial arteries varies considerably in disease, however, the pressure within the vessels probably is not altered to any appreciable degree In the two instances (Cases VII and VIII) in which the bronchial artery was the source of bleeding, the lesion was located near the main trunk of the vessels Whether the smaller ramifications of the vessel are ever involved is questionable, it is our belief that a branch of the pulmonary artery is the most likely source of hemorrhage at any point in the lung distal to the secondary bronchi

The cases presented emphasize the multiplicity of mechanisms involved in fatal massive hemorrhage It is true that many cases show a ruptured Rasmussen's aneurysm (and the incidence of this lesion varies with different institutions) but the majority reveal only an erosion of a branch of the pulmonary artery without any significant aneurysmal dilatation

SUMMARY

A survey of 2,830 autopsies at Municipal Tuberculosis Sanitarium, Chicago, was made and a report of 138 patients whose deaths were attributable to pulmonary hemorrhage were analyzed Selective cases were described in detail to illustrate the different mechanisms of massive hemorrhage and a review of the literature given

REFERENCES

1 [illegible]

2 [illegible]

3 [illegible] course of chronic pulmonary tuberculosis clinically arrested *Quart Bull Sea View Hosp* 3 176, 1938

4 LOPEZ, Q M Las hemoptisis terminales en la tuberculosis del adulto *Semana méd*, 1 877 1946

5 MARCHAND, P, GILROY J C and WILSON V H Anatomical study of bronchial vascular system [illegible] aneurysms and fatal hemorrhage in pulmonary tuberculosis *Am Rev Tuberc*, 60 589 1949

9 RASMUSSEN V Hemoptysis especially when fatal in its anatomical and clinical aspects Translated by W D Moore *Edinburgh M J*, 14 385 1868



8



9

FIG 8. Close-up to show the black peribronchial node projecting through the anterior wall of the right main bronchus, and the clotted blood filling the lumen distally

FIG 9 Close-up showing the necrotic lesion and the slightly enlarged hilar lymph node The node contained some small caseous infiltrations

to grammar school a chest x-ray film was taken and his parents were informed that there was considerable scarring of his lungs compatible with healed tuberculosis In the years following he was hospitalized frequently because of his "weakened" condition He stated that recently he had developed slight cough with a very small amount of expectoration, experienced some chest pain and had mild dyspnea on exertion Occasionally there were evening temperature elevations up to 101°F

Physical examination revealed a well developed and well nourished white man apprehensive and acutely ill Examination of the chest showed impaired resonance and bronchial breathing over the right base. Sputum specimen was negative for acid-fast bacilli Three days after admission to the sanitarium he suffered a severe pulmonary hemorrhage and expired

A mid-section of the lung disclosed a few small fibrocaseous tubercles in the upper portion of each lung. These tubercles appeared to be fairly well encapsulated At a point in the right bronchus where the upper lobe bronchus takes its origin there was a necrotic area approximately 1 0 cm in diameter (Fig 9) and a section of this lesion revealed that the entire bronchial wall was involved in this necrotizing process This lesion eroded a branch of the bronchial artery and was responsible for the massive hemorrhage that was seen The parenchymal disease was quiescent.

COMMENTS

Probably a massive hemorrhage produces death by suffocation, although in some instances, the loss of blood itself may be sufficient to terminate a cachectic individual. An estimation of the actual blood loss is difficult, as one must consider the amount of blood coughed up and expelled and that found in the lung and gastrointestinal tract at the time of postmortem examination. There is not much doubt that, in some cases, the total volume approximates 1,000 cc Most patients die suddenly following a massive hemorrhage, and do not present the picture of exsanguination. The amount of blood necessary to produce death by suffocation probably varies greatly and is dependent upon several factors When the main airways are filled to overflowing (as seen in Figure 6) undoubtedly the individual is asphyxiated by his own blood. On the other hand, collections of blood in the functional parenchyma in a lung partially destroyed by a previous disease (as seen in Figure 5) and with limited reserve may likewise asphyxiate an individual even though the volume of blood is not so great.

The presence of a definite aneurysm has been

the exception instead of the rule in the routine examination of lungs from fatal hemorrhage cases at this institution It was impossible to identify the bleeding vessel in many cases however this is true in instances of hemorrhage from other organ systems A compilation of the findings in eighty consecutive cases is listed below

Bleeding Point	No of Cases
None identified	61
Pulmonary artery (no aneurysm)	8
Rasmussen aneurysm	6
Bronchial artery	5
Total	80

Even though the caliber of the involved vessels varied considerably in different cases no correlation could be made between the size of the vessel and the magnitude of the hemorrhage or the rapidity of death Profuse hemorrhage from the small bronchial arteries correspond to hemorrhages from the larger pulmonary artery branches because of the differences in pressure The pressure in the lesser (pulmonary) circulation is estimated to be about one sixth (mean value) that of the greater (systemic) circulation Since the bronchial artery is derived from the aorta the pressure no doubt is consistent with systemic pressure When the lung has widespread involvement the amount of blood flowing through the pulmonary arteries to the affected parts is proportionately reduced and the pressure is correspondingly less Recent work by Marchand et al[5] has shown that the pattern of the bronchial arteries varies considerably in disease however the pressure within the vessels probably is not altered to any appreciable degree In the two instances (Cases VII and VIII) in which the bronchial artery was the source of bleeding the lesion was located near the main trunk of the vessels Whether the smaller ramifications of the vessel are ever involved is questionable it is our belief that a branch of the pulmonary artery is the most likely source of hemorrhage at any point in the lung distal to the secondary bronchi

The cases presented emphasize the multiplicity of mechanisms involved in fatal massive hemorrhage It is true that many cases show a ruptured Rasmussen's aneurysm (and the incidence of this lesion varies with different institutions) but the majority reveal only an erosion of a branch of the pulmonary artery without any significant aneurysmal dilatation

SUMMARY

A survey of 2 830 autopsies at Municipal Tuberculosis Sanitarium Chicago was made and a report of 138 patients whose deaths were attributable to pulmonary hemorrhage were analyzed Selective cases were described in detail to illustrate the different mechanisms of massive hemorrhage and a review of the literature given

REFERENCES

CODINA SLQUE J and MANSILLA DELICADO R F Consideraciones sobre un caso de hemoptisis mortal *Rev clin espan* 3 528 1941

2 GOLDBERG B Clinical Tuberculosis The Pathology of Pulmonary Tuberculosis by R H Jaffe 5th ed vol 1 pp A105 A157 Philadelphia F A Davis Co 1946

3 KLOSK E Unusual form of fatal hemorrhage in course of chronic pulmonary tuberculosis clinically arrested *Quart Bull Sea View Hosp* 3 176 1938

4 LOPEZ Q M Las hemoptisis terminales en la tuberculosis del adulto *Semana méd* 1 877 1946

5 MARCHAND P GILROY J C and WILSON V H Anatomical study of bronchial vascular system and its variations in disease *Thorax* 5 207 1950

6 O LEARY C Death from haemoptysis occurring in infant of nine months *Tubercle* 19 513 1939

7 PETERSEN W F The Patient and the Weather vol 4 pt 2 pp 663-670 Ann Arbor Mich Edwards Brothers Inc 1937

8 PLESSINGER V A and JOLLY P N Rasmussen's aneurysms and fatal hemorrhage in pulmonary tuberculosis *Am Rev Tuberc* 60 589 1949

9 RASMUSSEN V Hemoptysis especially when fatal in its anatomical and clinical aspects Translated by W D Moore *Edinburgh M J* 14 385 1868

68

Indications for Treatment in Children*

EDITH M LINCOLN, M D, *New York, New York*

From the Department of Pediatrics New York University College of Medicine, and the Chest Clinic of the Children's Medical Service, Bellevue Hospital, New York, N Y

EVERY form of tuberculosis may be seen in children However, the great majority of clinical pictures are manifestations of primary or first infection pulmonary tuberculosis and are due to local progression of the disease at the portal of entry or to complications due to metastasis through the lymphohematogenous route Chronic pulmonary tuberculosis, often called reinfection tuberculosis, occurs much more rarely in the child than in the adult Moreover, the clinical course and the treatment of chronic pulmonary tuberculosis is essentially the same at all ages Therefore, this presentation will be limited to a discussion of the indications for treatment of primary tuberculosis and of the many complications which constitute its clinical picture [1]

GENERAL MANAGEMENT OF THE TUBERCULOUS CHILD

Every child with active primary tuberculosis, regardless of the presence or absence of symptoms, is entitled to excellent general care and supervision A child with uncomplicated primary tuberculosis need not be treated in a hospital or sanatorium unless his home is inadequate for his care or the source case remains in the home Limitation of activity is desirable during the early months of the disease even if the child is afebrile The child need not be kept in bed nor indoors, but play must be supervised and toys selected to minimize excitement and overactivity Children of school age who are past the acute stage of the disease may attend school if afebrile and provided physical activities can be restricted Excessive exposure to sunlight should be avoided, and the child with active tuberculosis should be shielded from measles and given gamma globulin if exposed Diet should be liberal in calories and in foods high in protein and fat, and supplementary vitamins should be given

The degree and duration of conservative treatment will vary with the extent of tuberculous disease but, in general, activity is increased gradually after six months have passed and most restrictions are lifted after a year since most observers agree that more than 90 per cent of serious complications occur within the first year after the diagnosis of primary tuberculosis

SELECTION OF CASES FOR SPECIFIC THERAPY

The selection of patients who need specific antimicrobial therapy in addition to conservative treatment is based largely on the estimated prognosis of each individual patient It is obviously mandatory to treat patients with forms of tuberculosis who had a high death rate prior to the use of specific therapy Meningitis and miliary tuberculosis, which were practically 100 per cent fatal before chemotherapy, must of course be treated In addition there are two other main causes of death in tuberculous children for which treatment is essential (1) locally progressive primary pulmonary tuberculosis with cavitation and bronchogenic spread and (2) various forms of hematogenous tuberculosis more protracted than miliary in which multiple foci of tuberculosis are produced by blood stream invasion [2] Such forms of tuberculosis must be treated as a lifesaving measure In untreated meningitis the average duration from first symptom to death was only nineteen and a half days Therefore, once the diagnosis of meningitis is established it is important to give the most efficient antimicrobial agents, streptomycin and isoniazid together and in maximum dosage, changing

* This study was aided by grants from the committee on Medical Research of the American Trudeau Society, medical section of the National Tuberculosis Association from the Division of Research Grants and Fellowships of the National Institutes of Health, Public Health Service, from Parke Davis and Company

the dosage to a level less likely to cause toxicity when the patient seems to be making a clinical recovery and when the sugar content in the cerebrospinal fluid is returning to a normal level Treatment should be continued for at least a year Many schemes of therapy of tuberculous meningitis have been reported and there is certainly no one method that invariably cures the disease[1,4] The essentials for success are early diagnosis prompt and vigorous therapy and prolonged treatment *

Most clinicians treat miliary tuberculosis as intensively as meningitis because of the previous high mortality rate using both streptomycin and isoniazid and reducing the dosage only after definite clinical and roentgen improvement However, excellent results have been reported without the use of streptomycin *

In miliary tuberculosis it is important that isoniazid be continued, although not in maximum dosage, for a year in an effort to prevent the development of meningitis

Except in meningitis and miliary tuberculosis it seems neither necessary nor wise to treat tuberculosis with a combination of the two most effective antimicrobial agents Tuberculosis is by nature a chronic disease and it would seem better whenever possible to reserve one potent antituberculous agent for possible later use It must be borne in mind that no drug known at present effects a complete cure The object of therapy is not eradication of the disease but the achievement of bacteriostasis sufficient to supplement the patient's natural resistance to tuberculosis

Because of its minimal toxic side effects and ease of administration isoniazid rather than streptomycin is often used in the therapy of protracted hematogenous tuberculosis and locally progressive primary tuberculosis It

OUTLINE OF SPECIFIC THERAPY*

CHEST CLINIC OF THE CHILDREN'S MEDICAL SERVICE OF BELLEVUE HOSPITAL (JANUARY, 1956)

Tuberculous Meningitis		
Streptomycin	Intramuscular for 6 months	× 1 0 gm daily for minimum period of 1 month or until cerebrospinal fluid sugar has been normal for 1 week thereafter b i w
Isoniazid	Oral for 12 months	× 10 20 mg /kg daily for 4 to 6 weeks thereafter 10 mg /kg
Promizole	Oral for 2 years	× 0 25 to 8 0 gm daily
Mil ary Tuberculosis		
Isoniazid	Oral for 1 year	× 10 mg /kg daily for 4 to 6 weeks thereafter 7 mg /kg
Promizole	Oral for 2 years	× 0 25 to 8 gm daily
Streptomycin	Intramuscular for 4 months	× 1 0 gm daily later b i w in some cases streptomycin is omitted
Relapse	Repeat original course of therapy	

In other forms of tuberculosis wh ch require therapy isoniazid is given daily in doses of 5 10 mg /kg with daily PAS or promizole or streptomycin is given daily or b i w on weight basis comb ned with daily PAS or promizole Streptomycin and isoniazid are rarely given together except as a lifesaving measure Therapy is frequently prolonged for a year or more For asymptomat c primary tuberculosis use isoniaz d alone or in comb nation with PAS or promizole for a year

Dosage Schedule for Streptomycin (weight basis)

0 3 gm —under 10 lb
0 4 gm —10 through 19 lb
0 5 gm —20 through 39 lb
0 6 gm —40 through 59 lb
0 75 gm —60 through 89 lb
1 0 gm —90 lb and over

Ison azid	Given by mouth every 12 hours In case of vomiting same amount may be given intramuscularly
Promizole	Given by mouth every 6 hours In absence of signs of toxicity a gradual step like increase from 0 5 gm is made every few days until a blood level of 1 3 mg per cent is obta ned (taken 2½ 3 hours after a dose of prom zole)
PAS	Para aminosalicyl c acid Given by mouth every 4 hours for 3 or 4 daily doses 0 5 gm /kg /24 hours up to maximum of 12 gm da ly dose
Streptomycin	A 1 0 gm da ly dose is sometimes divided in two for comfort of the patient Smaller doses are given as single daily injections except in small or emaciated patients

* Subject to modification for individual cases

* An outline of specific therapy of tuberculosis in use in the Chest Clinic of the Children s Med cal Service of Bellevue Hospital is appended for those who wish suggestions for more detailed schemes of treatment

need not be given in maximum dosage except in patients with fulminating disease Treatment should always be prolonged for at least a year and longer if necessary until three to six months after the disease is apparently controlled and signs and symptoms have disappeared In cavitating primary tuberculosis the disease is considered under control when cultures from gastric washings have been negative cavities have been closed and roentgenograms stabilized for a period of six months If these objectives cannot be reached surgical removal of the residual disease should always be considered while the patient is still receiving antimicrobial therapy The duration of specific therapy after surgery is usually dependent on the pathologic findings in the resected specimen

If streptomycin is used in the treatment of these complications it should always be used in combination with a secondary drug such as PAS (para aminosalicylic acid) or promizole® because the emergence of resistant organisms may be delayed by this method and the value of each drug enhanced by their combined use Most physicians prefer to use isoniazid also in combined therapy in the same manner but excellent investigators advocate the use of isoniazid alone [5]

Formerly two of three children with protracted hematogenous tuberculosis or cavitating primary tuberculosis died of tuberculosis With specific therapy practically all survive However it may be wise to emphasize that just as in tuberculous meningitis prompt diagnosis and consistent prolonged therapy results not only in a better survival rate but also in less residual disease in the survivors

In addition to the patients in whom specific treatment is indicated to save life antimicrobial treatment may be useful in alleviating symptoms or in shortening the course of the disease With treatment most forms of tuberculosis of the skin will heal rapidly and draining cutaneous sinuses close promptly thus often permitting surgery of the underlying tuberculous disease in bones or nodes The potential danger of dissemination following surgery can be minimized by protecting the tuberculous patient with antimicrobial therapy during a surgical procedure and for a short time thereafter Specific therapy will usually give rapid relief from harassing symptoms in the uncommon cases of tuberculosis of the gastrointestinal and genitourinary tracts in children as well as frequently producing roentgen evidence of anatomic healing In these forms of tuberculosis in which antimicrobial therapy is not used as a lifesaving measure the two major drugs

sis of the bones and nodes great chronicity is often exhibited with periods of spontaneous remission even when no specific therapy is used In such cases the indications for therapy are never sharply defined and it is difficult to evaluate the results of treatment Nevertheless attempts at specific therapy are always justified provided isoniazid and streptomycin are not employed together and toxicity from either drug is avoided

In still another group of complications of primary tuberculosis there is no apparent response to antimicrobial therapy and therefore no clear indication for specific treatment For example in endobronchial tuberculosis caused by caseous nodes encroaching on the bronchi neither the symptoms nor the appearance on bronchoscopy shows an apparent response to therapy [6] Progression of the disease has been repeatedly observed while the patient is receiving antimicrobial therapy Therefore the presence of endobronchial tuberculosis caused by primary tuberculosis does not constitute a clear indication for specific therapy In many cases the lesion will undoubtedly heal as well without therapy However, in infants with severe symptoms or whenever bronchogenic dissemination seems likely to occur the use of antimicrobial therapy would seem to be indicated to control the spread of the disease rather than to treat the local condition

When streptomycin was the only very effective antimicrobial agent asymptomatic primary tuberculosis was also included in the group of cases in which therapy was not clearly indicated The use of streptomycin did not prevent complications, a notable example being the development of meningitis in children under treatment for miliary tuberculosis Moreover, evidence of local response of the primary complex was not obtained The addition of isoniazid to the list of antimicrobial agents may change the indications for the treatment of asymptomatic primary pulmonary

tuberculosis There is as yet no definite evidence that isoniazid hastens the resolution of the primary complex However, there is evidence that clinical meningitis does not develop in children, even in those with miliary tuberculosis, who are receiving adequate treatment with isoniazid Studies of carefully controlled series of children with primary tuberculosis, in which the patients to be treated are selected at random, are needed to prove the effectiveness of isoniazid in the prevention of meningitis as well as the proper dosage and necessary duration of therapy Such studies are now in progress and the results will determine whether treatment with isoniazid will be indicated in every child with roentgen evidence of primary tuberculosis, even if the child is free from symptoms The desirability of treating children with a positive tuberculin test as the only evidence of tuberculosis is unsettled Some investigators question whether the acquired immunity in the treated child will equal the immunity obtained without specific therapy For the present, each patient should be considered individually

Antimicrobial therapy has already had a marked beneficial effect on the prognosis of primary tuberculosis in children [7] On the children's tuberculosis ward of Bellevue Hospital the death rate from 1930 through 1946 was 21 5 per cent, after the introduction of streptomycin the mortality was only 5 per cent annually Following the addition of isoniazid the rate fell to 1 5 per cent The prognosis of primary tuberculosis may be improved still further if proof is obtained that meningitis and other major complications can be prevented by treating all children with primary tuberculosis

It is obvious that the indications for the use of antimicrobial therapy vary greatly in different forms of primary tuberculosis in children In some complications the use of specific treatment is mandatory as a life-saving measure, in others it is highly recommended because it alleviates symptoms, may limit or prevent crippling effects or produce anatomic healing In still other complications the indications for therapy are not clear because of the ill-defined responses obtained Finally there is accumulating evidence that at some time in the future the mere diagnosis of active primary pulmonary tuberculosis, even in an asymptomatic child, may constitute an indication for treatment with isoniazid

REFERENCES

1 LINCOLN, E M, SEWELL, E M and ANASTASIADES A A The treatment of primary tuberculosis in children *Postgrad Med* 16 422, 1954

2 LINCOLN E M Hematogenous tuberculosis in children *Am J Dis Child*, 50 84–103 1935

3 DEBRE R The prognosis of tuberculous meningitis *Am Rev Tuberc*, 65 168, 1952

4 LINCOLN E M and SIFONTES, J E Tuberculous meningitis in children *M Clin North America*, 37 345–362, 1953

5 DRUSCHLE K ORMOND, L, ELMENDORF D, JR, MUSCHENHEIM, C and MCDERMOTT, W The course of pulmonary tuberculosis during long term single drug (isoniazid) therapy *Am Rev Tuberc*, 70 228–257, 1954

6 DALY, J F, BROWN D S, LINCOLN, E M and WILKING, V N Endobronchial tuberculosis in children *Dis of Chest* 22 380, 1952

7 LINCOLN E M Course and prognosis of tuberculosis in children *J A M A*, 9 623 632, 1950

69

Surgical Treatment

NORMAN J WILSON M D, *Brookline, Massachusetts,* ORLANDO ARMADA M D, WILLIAM B O BRIEN M D AND WILLIAM V VINDZBERG M D, *Wallum Lake, Rhode Island*

From the Rhode Island State Sanatorium and the Overholt Thoracic Clinic Boston Mass

TODAY we are in the midst of a *revolution* in the treatment of pulmonary tuberculosis that began with the introduction of streptomycin for general use in 1947 The intervening years have witnessed the evolution of our present day concept of prolonged, uninterrupted drug therapy with the advent of paraaminosalicylic acid in 1949 isoniazid in 1951, and more recently pyrazinamide These powerful antimicrobial drugs have proved to be capable of controlling a large percentage of the minimal and early moderately advanced lesions In addition, they have proved to be remarkably effective in controlling toxicity, reducing excessive secretions, and bringing the patient into immunologic balance with his disease rather promptly Even though cavitation or areas of caseation may persist the drugs usually control the resolvable, pneumonic component of the disease process The treatment of persisting cavities, areas of caseation and destroyed segments have become the lot of the thoracic surgeon in the drug era

It is only natural that our concepts of surgical treatment have been changing continuously and rapidly during this period All surgical procedures, especially resection, have been made safer by the better preparation of patients and the protection offered during surgery by the drugs These facts plus improved anesthesia and increased experience on the part of the surgeons have caused resection to boom into its present place as the most commonly used surgical procedure in treating pulmonary tuberculosis (Fig 1) Permanent collapse, especially of the type afforded by the extraperiosteal plombage technic, has maintained considerable favor in some clinics Phrenic paralysis and pneumothorax have been literally abandoned Antimicrobial therapy alone has supplanted these procedures in the treatment of early exudative or cavitary lesions Experience has taught us that other procedures are more effective in permanently controlling those lesions which have already created irreversible pathologic changes in lung tissue

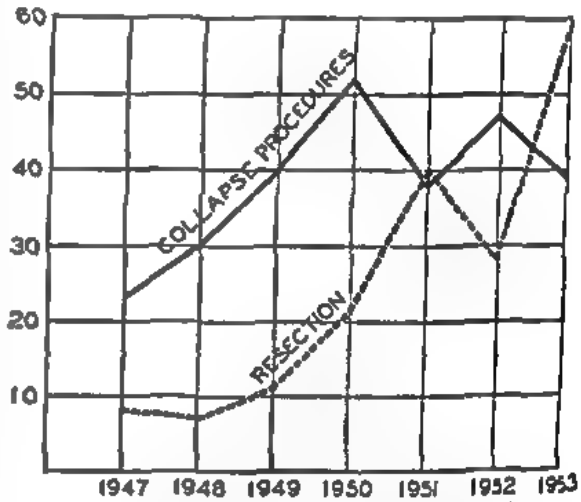

FIG 1 This graph shows the increased use of surgical procedures especially resection, during the drug era between 1947 and 1954

In this era of rapidly changing concepts, it seems obvious that any dogmatic statement regarding the use of various procedures is out of order As a result, the authors have elected to present our experience and the concepts used at the Rhode Island State Sanatorium during the drug era between January, 1947, and January, 1954 The discussion will be limited to the treatment of parenchymal lesions Only the 411 unilateral surgical problems (not unilateral disease) will be considered Eighty patients treated during this time with bilateral surgery have been excluded from this study because they are too complex for analysis, different procedures being used on the two sides in a high percentage

The status of the 411 patients was evaluated

in July, 1954 providing a minimum of six months and a maximum of seven and one half years of observation following operation, 260 were *followed for at least two and one-half* years and 335 for at least one and one-half years

PREOPERATIVE EVALUATION OF SURGICAL PATIENTS

The patient's history is thoroughly reviewed The duration of disease, the number of exacerbations, the social status of the patient, his ability to co operate in long term treatment and the history of previous drug therapy are vital points Those with disease of long duration, chronic alcoholics, and those with previous or interrupted courses of drug therapy are less [illegible]

groups However, the paradox of the situation is that they are in need of surgical treatment more often than the more favorable groups and, therefore, constitute a significant portion of our surgical patients

The roentgenograms from the beginning of the illness are reviewed Only in this way can the major involvement the degree of resolution and the proper evaluation of existing lesions be ascertained A residual lesion involving a lobe or segment is frequently the only visible remnant of extensive disease that previously involved the major portion of one or both lungs In such cases marked reduction of function must be suspected In addition, the surgeon is apt to find at operation numerous nodules of varying size not seen on the x ray Postero anterior, right and left anterior oblique views and postero-anterior laminagrams are routine Lateral laminagrams are taken occasionally and probably will be used routinely *when we gain more experience with them These* special x ray studies are invaluable in localizing the disease and frequently demonstrate even cavitary lesions previously not seen by routine methods

All prospective surgical candidates are fluoroscoped Diaphragmatic and rib function are evaluated This observation when combined with the patient's history, physical examination, serial x rays and his ability to climb stairs gives a fairly accurate picture of his respiratory function In addition, most patients have routine ventilatory studies including vital capacity, timed vital capacity and maximum breathing capacity Those who *have any evidence of limitation of function* and almost all candidates for bilateral surgery are subjected to bronchospirometry to determine the function of each lung separately The proper evaluation of respiratory function is considered to be of paramount importance Otherwise, the surgery which may cure the tuberculosis may leave the patient a hopeless, miserable cripple

Bronchoscopy has been performed routinely Stenosis and residual ulceration are uncommon in these days of drug therapy Residual redness of the mucosa is seen occasionally, but is not considered to be of importance even when resection is contemplated If an ulcerating or granulating process is discovered, every attempt should be made to control the bronchial disease by a proper drug regimen prior to surgery

CONTRAINDICATIONS TO SURGERY

The following conditions are the only absolute contraindications to surgery which we recognize regardless of the operation to be performed (1) Inadequate cardiac reserve, (2) inadequate respiratory function to withstand the proposed procedure and (3) the existence of another disease process that is either uncontrollable or fatal

Diabetes is not a contraindication to surgery In fact we believe that the prompt control of both the diabetes and tuberculosis is essential These patients are treated more energetically than the non diabetic patients Surgery is used in a higher percentage

In our opinion surgery is not contraindicated by *pregnancy* prior to the last trimester However, it is preferable to carry such patients to *term on medical therapy if possible*

Persisting toxemia and *spreading infection* are rarely a problem now that we have more than one effective antimicrobial agent However, occasionally such a patient is encountered [illegible]

or an adequate resection promptly change the

course of such patients These patients do not necessarily have a low resistance to their disease Not infrequently a careful pathologic study of a resection specimen will show bronchial strictures or large areas of caseation which have been mechanical factors militating against successful medical and drug therapy Also, most of these patients have a low blood volume as a result of prolonged toxemia Adequate transfusion will bring about a remarkable change in their clinical condition and enable them to undergo surgery without undue risk

Age alone is not a contraindication to surgery The youngest patient in this group was eight years and the oldest was sixty-six years of age Many were over sixty years of age Patients in the fifty's were common As long as a patient's physical condition and physiologic reserves are adequate to withstand the required operation, we believe he should be operated upon These elderly patients have *tolerated surgery of all types remarkably well* We disagree strongly with those who deny [illegible] because of their

exist as "good chronics" To die by inches inside an institution separated from friends and family is a severe and unjustifiable sentence to place on many of these elderly people

COLLAPSE THERAPY

Indications The *indications for the various* collapse procedures will be given under the appropriate headings In general, however, the indication for collapse is residual cavitation [illegible]

significant amount of normal lung Residual cavity under 4 cm in diameter in the apical-posterior segments of the upper lobes constitutes the ideal indication Collapse therapy *has no place today in the treatment of cavities* in other positions, basal disease solid lesions or those associated with bronchiectasis Most cavities over 4 cm in diameter and most destroyed lungs are treated preferentially by resection although, occasionally, coercing circumstances such as drug resistance or contralateral disease may cause the surgeon to elect thoracoplasty.

Staged Thoracoplasty A conventional thoracoplasty is performed in stages, the superior ribs being resected first The first rib and all transverse processes are removed Prior to 1950, this was the most commonly used collapse procedure *In the early years of the drug era,* patients were not prepared for or protected during thoracoplasty except in the substandard risks, streptomycin being reserved in case resection would be necessary at a later date

Conventional thoracoplasty has the following disadvantages (1) Multiple stages with the associated physical and mental strain *for the* patient, (2) multiple operations increase the cost of surgery and also limit the number of patients who can be treated in a given unit of time, (3) slow conversion of sputum, (4) paradoxical motion of the chest wall which interferes with both respiration and the cough mechanism This predisposes to retention of bronchial secretions, spread of disease, and anoxemia, (5) deformity resulting from the scoliosis and abnormal position of shoulder *girdle caused by resecting the first rib and* transverse processes

Because of these disadvantages, conventional thoracoplasty was abandoned by us in 1950 Since then, the standard thoracoplasty case with cavity under 4 cm in diameter has been treated with plombage thoracoplasty to be described later When larger cavities are treated by collapse, we employ a thoracoplasty performed from below-up (Fig 2) The lower stage is performed first and, at the same time an extrapleural *mobilization of the cavity area* is performed The anterior portion of the lung is not mobilized This wipes the cavity from the gutter area and from within the circle of the first rib and transplants it to a more lateral and anterior position The cavity is placed thus into a more ideal position for collapse when the upper ribs are resected In addition, the cavity frequently decreases in size between stages because of relaxation afforded by the mobilization This type of mobilization differs *from that performed with the first* stage of a conventional thoracoplasty in that the narrowed thoracoplasty field below created by the first stage prevents the cavity from being dropped into a wide cushion of *resilient lung* tissue The first rib is resected but all transverse processes are preserved We have found it unnecessary to remove the processes if the gutter is completely developed and packed with oxycel This has been the most effective collapse procedure for these advanced cases in our

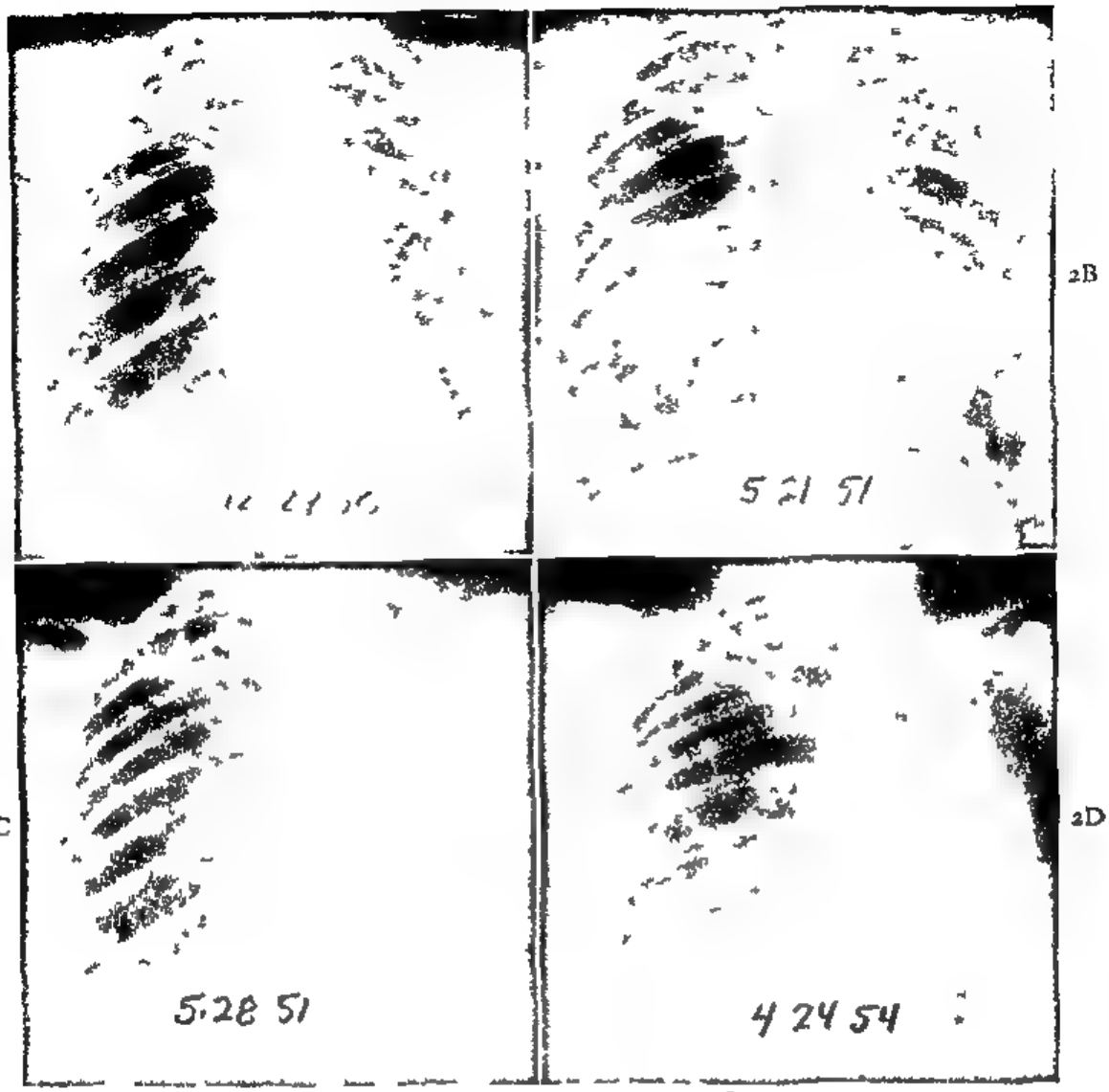

hands Its one disadvantage is that the extrapleural space is entered and may predispose to tuberculous wound infection This has occurred in one case

One hundred six patients were treated with staged thoracoplasty. In eighty four (79 per cent) the disease was controlled by the thoracoplasty alone Twenty two had subsequent surgical procedures At present fourteen patients (13 per cent) are dead and ninety-two (87 per cent) are living Eighty seven patients (94 5 per cent) of the living patient group are completely well

The reader is again reminded that 94 of these 106 were operated upon prior to January, 1952, and 80 before January, 1950 None of these had the benefits of prolonged chemotherapy and many had no drug therapy at all Case

living patients are well speaks for a concept we

3A 3B

FIG 3A and B A preoperat ve roentgenogram of a seventeen year old boy adm tted to the sana torium on July 10 1948 Laminagrams revealed a cav ty measur ng 3½ by 2½ cm B roentgenogram after f rst stage of plombage thoracoplasty

have held for many years namely that the patient who gets well with permanent collapse has a lasting cure that is hard to beat

EXTRAPERIOSTEAL PLOMBAGE THORACOPLASTY

This operation (Fig 3) was first performed at our institution in 1949 Since then it has been found to be so safe and effective that it has become our favorite collapse procedure The ideal indication is the persisting cavity under 4 cm in diameter in the apical or posterior segments of the upper lobes The collapse is created at one operation The periosteum is stripped only from the undersurface of the first rib The number of ribs and the length of ribs stripped of periosteum below the first rib depends upon the extent and distribution of the lesion as determined by oblique roentgenograms and laminagrams The collapse is designed to compress the diseased areas and to avoid collapsing normal segments of the lung As many as eight ribs have been stripped at one operation In spite of this one of the outstanding features of this operation is the lack of shock The ribs are left intact and the extraperiosteal space is snugly packed with 1½ inch lucite spheres inside a polyethylene wrapping (This prevents the spheres from migrating between the ribs and makes their removal at any later time a simple procedure)

FIG 3C Same case as F gure 3A and B Roentgenogram of May 14 1954 four years after operat on The pat ent is cl n cally well and working

One week follo ing operation the anti microbial drugs are stopped unless there is an active endobronchial lesion or a contralateral lesion that indicate their use Only in this way can the collapse failures be determ ned early If drugs are continued the sputum may remain negative even though the disease is uncontrolled We like to have collapse therapy work

on its own merits and likewise believe it is important to pick up our failures early After four months of careful sputum studies a decision as to further surgery is made If the sputum is negative a second stage is performed removing the plombage and resecting the previously deperiostealized sections of ribs The first rib and all transverse processes are left intact to avoid significant deformity If the sputum remains positive a resection is performed and the second stage of the thoracoplasty completed at the same time Thus regardless of the success or failure of the plombage the patient s treatment consists of a maximum of two operations

One of the problems to be settled is the safety of leaving the plombage in place and avoiding the second stage Our experience to date would indicate that the plombage material is well tolerated for periods up to two or three years However more time will be required to settle this question For this reason a two-stage operation is performed on the younger good risk patients In those over fifty five years of age in the bilateral cases and in those with marginal functional reserves we have performed one stage procedures leaving the plombage permanently in place There has been only one infection of the extraperiosteal space This occurred in the first few months after operation and was caused we believe by a technical error during the first stage when the extrapleural space was entered and widely exposed

The advantages of plombage thoracoplasty are many The collapse is created at one operation Conversion of sputum occurs rapidly Paradoxical motion of significance is eliminated As a result there is less interference with respiration and cough Retained secretions and spreads are truly rare Fewer stages reduce the strain on the patient and the cost of surgical treatment The first rib and all transverse processes are preserved so that no significant clinical deformity occurs even though the roentgenogram shows a slight scoliosis Functional studies have shown that the functional loss is small and is more predictable than with either staged thoracoplasty or resection One of the greatest advantages is that the failures can be treated with resection with a total of two operations The treatment of collapse failures is certainly an easier task and is more successful than is the case with resection failures

Another factor of great importance is that this procedure as is true with any thoracoplasty, can be used with much more safety than resection in those patients who harbor bacilli resistant to the antimicrobial drugs Last but not least of the advantages is that experience has taught us that this is the simplest and safest of all major surgical procedures used in treating tuberculosis

One hundred forty patients have been treated with unilateral extraperiosteal plombage thoracoplasty In 120 (86 per cent) it was successful The twenty failures have undergone resection No deaths have occurred from any of the operative procedures and no deaths caused by tuberculous infection have occurred Three have died two of coronary occlusions and one of metastatic carcinoma One hundred thirty seven (97 8 per cent) are living and of these 127 (92 7 per cent) are completely well Three patients are known to be alive and active but we were unable to get accurate follow up data for evaluation

The results with this procedure have been so good that we have been reluctant to shift as completely to resection as have most clinics

Extrapleural Procedures Four extrapleural pneumothoraces have been performed This procedure was used chiefly in young patients who had not attained full growth Thoracoplasty is not used in these young patients because of the marked scoliosis and deformity that results These were done prior to 1951 Today such patients would be treated either by resection or extraperiosteal plombage delaying the second stage until after full growth had been attained

Nineteen extrapleural plombage thoracoplasties have been performed The indication here has been the poor risk patient with marginal respiratory function This procedure has the advantage of leaving the thoracic cage intact and is reversible at any time during the postoperative period since the plombage can be removed without creating paradoxical motion of the chest wall As our experience with the extraperiosteal plombage has increased the extrapleural approach has been used less and less We have not had the disastrous experience with this procedure recorded in the literature This is attributed to the following factors (1) protection of drugs (2) careful selection of patients (3) leaving the mediastinal pleura intact and (4) removing

the plombage at the end of four to six months and performing a thoracoplasty of a type that preserves the first rib and the transverse processes

These procedures have been limited to the treatment of small cavities above the level of the second anterior rib This explains the good results All twenty three of the patients are alive and well In one case the follow up data are inadequate The remaining twenty-two are well and have a persistently negative sputum

Summary of Results with Collapse Therapy The following statistics include the morbidity and mortality of the original collapse procedures plus those of all other procedures used subsequently in the treatment of the patients

1 Two hundred sixty nine were treated initially by collapse therapy between 1947 and 1954 Sixty four per cent were operated upon before the era of long term chemotherapy (1952)

2 Eleven (4 0 per cent) tuberculous complications occurred during the postoperative period of sixty days

3 Thirty (11 per cent) tuberculous complications occurred late

4 There were two (0 7 per cent) postoperative deaths These occurred in those treated by staged thoracoplasty prior to 1950 Since 1950 176 collapse therapy patients have been treated with no postoperative deaths

5 Fifteen (5 5 per cent) have died following the sixty day post operative period

6 Two hundred fifty two (93 per cent) of the patients are living and of these 236 are clinically well with negative sputum This represents 88 5 per cent of the total group or 94 per cent of the 252 living patients

7 The study of the 163 treated by collapse procedures other than staged thoracoplasty is quite significant There were no post operative deaths Only three late deaths have occurred caused by coronary occlusion in two and metastatic carcinoma in one One hundred sixty (98 per cent) patients are living and of these 149 (93 per cent) are completely well Of the remaining eleven four are known to be alive but we have inadequate follow up data on them four are clinically well but have either a positive sputum or unstable roentgenogram and three have either active or progressive disease

CAVERNOSTOMY

Cavernostomy is used rarely In two instances of giant cavitation it was combined with thoracoplasty The cavernostomy was performed prior to the thoracoplasty to reduce the size of the cavity and thus limit to some extent the amount of collapse required

In only one case has cavernostomy been used alone This patient previously had bilateral pneumothorax and was left with a large cavity in the superior segment of the right lower lobe Her respiratory reserve contraindicated resection Cavernostomy followed several months later by a muscle flap plastic closure of the residual cavity was effective in controlling her disease

Cavernostomy ■ used occasionally as a palliative procedure in hopeless cases with large cavities causing excessive cough and expectoration Dramatic symptomatic relief frequently is accomplished

Open cavernostomy is used at our clinic This is performed in one stage if the pleura is adherent and in two stages if it is free

RESECTION

In the chemotherapeutic era resection has increased in popularity until it is now the most commonly used of all surgical procedures in treating pulmonary tuberculosis This has been the result of improved anesthesia increased experience with resection and the effect of the antimicrobial agents which bring the patient to surgery in better condition and protects him during the postoperative period Many clinics now boast that they rarely use any other surgical procedure In our opinion this can be said only if operation is withheld from many patients who should be treated surgically Any team of physician and surgeon who is willing to extend their surgical program to include the aged and those with marginal function must be willing and capable of using not only resection but every type of collapse procedure and occasionally even cavernostomy

Although all types of resection are being employed more frequently the use of segmental resection has increased phenomenally It is an especially appealing operation to physician surgeon and patient in that it permits extirpation of the offending lesion with the preservation of almost a maximum of normal lung tissue The acceptance of seg

mental resection as a rational approach in the treatment of tuberculosis was delayed by the concept that tuberculosis is a disseminated disease Even though this is true exploration of early tuberculous lesions has demonstrated that the major necrotic lesion is often confined to one or two segments In addition the drugs frequently cause such complete resolution of the disease process that the residual necrotic lesion is well contained in a segment or even a subsegment of the lung These facts plus the surgeons increased experience with the procedures have led to its acceptance

Indications The following are considered to be absolute indications for resection (1) Associated suppuration (2) tuberculous bronchiectasis (3) thoracoplasty failure (4) bronchial stenosis (5) uncontrolled lower lobe disease (6) tuberculoma like lesions whether they represent true tuberculomas or inspissated cavities and (7) cavity in an inexpandable lung with or without associated empyema following pneumothorax

Resection is considered to be the operation of choice in the following types of cavities (1) Giant cavities, (2) cavities which have manifested evidence of recurring tension and poor drainage (3) cavities in poor position for collapse such as those which hug the mediastinum and (4) cavities in the anterior segment of upper lobes or lying below the fifth rib posteriorly so that a large volume of normal lung would be sacrificed in collapsing them

Where widely disseminated predominantly unilateral disease has created a destroyed lung we prefer to use resection although thoracoplasty can be used with success in many of these cases We believe that resection is more effective and reduces the number of operations Gaensler and Strieder[1] have shown that thoracoplasty over destroyed lungs causes significant reduction of maximum breathing capacity whereas resection adds little if any functional impairment

Resection may be indicated to control hemorrhage that has been refractory to all other methods of treatment This is a rare indication We have never encountered it When it does arise it represents the most serious of situations and should be performed only as a life-saving procedure

One of the biggest problems that has arisen as a result of drug therapy is the question concerning which residual lesions should be resected A negative sputum is no longer a reliable guide because of the suppressive action of the drugs The examination of resected specimens has proved that our present x ray technics including laminagraphy are not entirely reliable Cavities are found at times in the specimen when not suspected preoperatively However it is more common to find no cavity when one has been indicated by the roentgenographic study Our policy has been to resect any residual necrotic focus 2 cm or over in size and totally destroyed segments or lobes As time goes by and more experience with long term chemotherapy evolves we may find that resection of many such lesions is unnecessary to cure the patients and prevent recurrences On the other hand we may learn that these residual foci are a source of recurrence and that drug therapy has merely delayed the day of exacerbation The problem of whether the tubercle bacilli are dead or alive in the residual focus has never been of concern to us We are aware that many of these organisms will not grow on culture or produce disease in the guinea pig However until much more bacteriologic and clinical evidence is available we have decided to consider the bacilli to be virulent and capable of causing exacerbation of disease

The smaller residual areas of caseation have been treated medically Wedge excision of such foci have not been part of our surgical program A high percentage of patients remained well with this type of disease even before the drug era

Primary versus Secondary Drug Treated Cases The ideal case for resection is the patient with unilateral localized disease under treatment with primary uninterrupted drug therapy Our experience has led us to the conclusion that resection can be used in such cases with safety at any time provided the following criteria exist (1) Adequate respiratory reserve (2) resection is the primary surgical approach to the problem (3) the lesion is confined within the unit of lung to be resected whether this be segment lobe or an entire lung and (4) resection is applied as soon as ideal conditions have been secured with bed rest and antimicrobial drugs This means that toxemia and excessive bronchial secretions have been eliminated and that active lesions in other areas of the lung have been controlled

Once these criteria have been met, resection can be performed with safety regardless of the operative procedure used The presence of open cavity and or positive sputum have not altered statistics Likewise those resected with *only a few weeks of preoperative drug therapy* have withstood operation just as well as those who have had six months or more of preparation Once resection has been decided upon there is little justification to sacrifice the patient's time to permit inspissation of a cavity or further contraction of irreversibly damaged lung

Our experience has been different with those patients who have had previous courses of drug therapy The morbidity and mortality are higher in this group of patients In addition longer periods of preoperative preparation seem to reduce the number of complications If possible, such patients should be treated with those drugs found to be effective by sensitivity studies on the sputum Many other factors in addition to previous drug therapy contribute to the increased trouble incurred in treating these patients They have disease of longer duration, a higher percentage have had previous collapse or surgical treatment, and their average respiratory reserve is lower Several patients in this group resistant to streptomycin and isoniazid have been treated with pyrazinamide This drug has been very effective in protecting them from tuberculous complications

The type of tuberculosis, the functional reserves of the patient, and the availability of effective chemotherapy are factors which determine good or bad results much more than the type of resection used

Results Table I summarizes the results with resection The morbidity and mortality rates for pneumonectomy and lobectomy plus segmental resection are higher because the worst cases fall into these groups

TABLE I

RESECTION FOR UNILATERAL SURGICAL PROBLEMS—1947 TO 1954

	Pneumonectomy	Lobectomy	Lobectomy plus Segmental	Segmental	Wedge
Number of cases	68	70	9	24	3
Postoperative tuberculous complications	8	2	1	2	0
Late tuberculous complications	13	6	1	0	0
Postoperative deaths	2	1	1	1	0
Late deaths	5	0	2	1	0
Living patients	61 (90%)	69 (98 6%)	6 (67%)	22 (92%)	3 (100%)
Per cent of living patients well with negative sputum	93	93	100	96	100

Thirteen (7 5 per cent) of the 174 resections had tuberculous complications in the postoperative period fistula with empyema five contralateral spread or exacerbation three sinuses in wound two, ipsolateral exacerbation one, contralateral pleural effusion one and extrapulmonary tuberculosis one

Twenty (11 5 per cent) late tuberculous complications occurred fistula with empyema one empyema two, contralateral exacerbation eight, stump ulcer seven and ipsolateral exacerbation two

There were five (2 9 per cent) postoperative deaths caused by fistula and spread one, pulmonary edema one, pulmonary insufficiency one pulmonary embolus one and blood dyscrasia one

The eight (4 6 per cent) late deaths were caused by coronary occlusion one cor pulmonale three fatal hemorrhage from an empyema space one, progressive tuberculosis two and leukemoid metaplasia one This last

complication was considered to be due to tuberculosis of the bone marrow although never proved

One hundred sixty one (92 5 per cent) of the 174 patients are alive and 151 (94 per cent) of these are clinically well Fifty per cent of the patients were operated upon prior to January 1952 and did not have the benefit of long term chemotherapy

POSTSURGICAL CARE OF PATIENTS

During the first three months following surgery patients are kept on modified bed rest Bathroom privileges and permission to eat in a dining room in the convalescent ward is permitted The patient s activity is slowly increased during the next seven to nine months During this time the sputum is carefully studied and periodic roentgenograms are taken The patient is then considered for discharge from the sanatorium The majority of patients are then ready to return to part time work and most of them return to their previous occupations

Prolonged chemotherapy is given following all resections since it is assumed that tuberculous tissue was transected and new lesions were created even though they may not be manifest Prolonged chemotherapy is also prescribed for collapse therapy patients who have had bilateral surgery or have had active lesions in other areas of the lung other than the collapsed area Drug therapy is stopped one week following the optimal collapse procedures so that the failures can be discovered

SUMMARY

The introduction of antimicrobial drugs has created radical changes in the surgical treatment of pulmonary tuberculosis Resection is now used more frequently than any other procedure However our statistics indicate that the prognosis depends more on the control of the open lesion than upon the type of surgery used This is demonstrated by the fact that between 93 and 96 per cent of the living patients treated by the various surgical procedures are clinically well In our experience the lesion adequately controlled by collapse has an equally good prognosis as those resected The key to successful surgical treatment of tuberculosis is the selection of the simplest and safest procedure which will permanently control the disease

REFERENCE

1 GAENSLER E H and STRIEDER J W Progressive changes in pulmonary function after pneumonectomy *J Thoracic Surg* 22 1 34 1951

Resection in Children and Adolescents

MORRIS RUBIN, M D, *New York, New York*

IN less than a decade a radical change has taken place in the treatment of pulmonary tuberculosis The sanatorium "rest cure" no longer occupies its time-honored position Bed-rest is now used as an adjunct to more direct and definitive measures and for comparatively short periods of time It is becoming so difficult to find the requisite indications for inducing pneumothorax that this treatment is rapidly being abandoned in many institutions The recent popularity of therapeutic pneumoperitoneum as a "holding"-type of treatment is on the wane Extrapleural thoracoplasty, once the mainstay in surgical treatment, is now used to a limited degree

The current treatment of pulmonary tuber

combination with resection when indicated The latter is utilized not only for cavitary disease or for a smoldering focus discharging acid fast bacilli, but also for relatively circumscribed disease, temporarily under control, but which may be a hazard to the individual upon his resumption of normal activities

The place of resectional surgery in the treatment of pulmonary tuberculosis, as outlined, is being applied almost exclusively to adults In children and adolescents it is practically an unexplored field for several reasons First, there are few institutions which admit and provide prolonged care for children with tuberculosis Second, the belief is widely held that tuberculosis in younger age groups behaves in extremes that the disease represents a primary infection and is either innocuous in the vast majority, or else an acute generalized infection leading to a fatal issue Although the recent introduction of antituberculosis drugs has modified medical opinion as to the dire prognosis associated with hematogenous tuberculosis, the basic concepts of the evolution of the disease have remained unchanged Few physicians realize that in a certain proportion of children, pulmonary tuberculosis behaves much in the same manner as it does in adults and that in these a sharp distinction between so-called childhood and adult types of tuberculosis is not valid

Shortly following the introduction of specific antituberculosis agents, which help to bring about a resolution of the exudative component of the tuberculous process, the need arose for treating children with residual caseous foci or permanently damaged lung tissue It was decided to apply resectional treatment as was being employed in adults This plan was adopted in 1949 and a preliminary report on thirty children and adolescents was published in 1952[1] The initial results, based on a six-month to a three-year follow-up, warranted the conclusion that resection had a definite place in the treatment of pulmonary tuberculosis in children Since then a total of sixty-two children and teenagers have been treated in this manner In addition to determining the place of resectional surgery in children, this study afforded an unusual opportunity of correlating the various clinical pathologic patterns of tuberculosis

CLINICAL DATA

As shown in Table I there were fifty three females and nine males, the majority Negro and Puerto Rican girls The known duration of illness prior to surgery is shown in Table II As noted, a considerable number had been hospitalized for two years or longer, some on repeated occasions A few selected cases were operated upon within six months of the onset of their illness The timing of resection was based largely on the course of the disease as seen in sequential chest x rays When a patient failed to improve, resection came into consideration The operative procedures performed are shown in Table III It should be noted that

limited resections were possible in forty-seven and pneumonectomy in only eleven

The various types of lesions resected are shown in Table IV The material lent itself to a division of two major groupings (1) the primary infection, encountered almost exclusively in children under ten years of age and (2) tuberculosis in the adolescent, which was more apt to resemble tuberculosis in the adult Each group was found to possess distinctive clinical, roentgenologic and morphologic features presenting different problems in treatment Table IV is a composite of certain clinical and morphologic characteristics which typified the several subgroups The table is not to be construed as a classification of tuberculosis in the strict sense of the term rather as types of disease which may present indications for resection

TABLE I
DISTRIBUTION OF DISEASE

Age (Onset of Disease)	Number
2 to 5 yr	3
6 to 10 yr	10
11 to 15 yr	31
16 to 19 yr	18
Race	
Negro	33
Puerto Rican	19
White	14
Sex	
Females	53
Males	9

TABLE II
KNOWN DURATION OF ILLNESS PRIOR TO SURGERY

Months	No of Patients
2 6	8
7 12	25
13 18	12
19–24	5
25 30	3
31–36	5
37 42	1
4 3 yr	2
5 yr	1

TABLE III
OPERATIVE PROCEDURES

Procedure	No of Patients
Segmental resections (8)	
Apicopost (L U L)	6
Lateral (R M L)	2
Lobectomies (39)	
R U L	14
R U L and R M L	1
R M L and R L L	2
R M L	3
R L L	5
L U L	10
L U L and sup seg L L L	2
L L L with seg L U L	1
L L L and R U L	1
Pneumonectomies (11)	
Right	6
Left	5
Attempted resections (4)	
Resection not performed due to extent of disease	2
Cardiac arrest	1
Frozen hilum due to lymph nodes	1

TABLE IV
TYPES OF TUBERCULOUS LESIONS RESECTED

Primary tuberculosis
1 Large stationary caseous focus
2 Primary cavity
3 Persistent atelectasis
(a) Segmental
(b) Lobar shrunken middle lobe
4 Postprimary bronchiectasis
5 Bronchostenosis destroyed lung

Tuberculosis in the adolescent
6 Caseonecrotic foci
(a) Solitary
(b) Confluent nodular
7 Caseocavitary tuberculosis
8 Tuberculosis of small bronchi
9 Bronchiectasis destroyed lobe
10 Minimal lesion

PRIMARY TUBERCULOSIS

Large Stationary Caseous Focus

CASE 1 P W, a three year old Negro boy whose mother had tuberculosis was admitted to Seton Hospital on December 29 1951, with bacilli prior to antibiotic therapy He was given streptomycin and later isoniazid with considerable resolution of the lesion A large round focus persisted in the lateral segment of the middle lobe (Fig 1B, C) On December 17, 1952 fifteen months after the discovery of the lesion, the lateral segment of the middle lobe was resected At operation numerous filmy adhesions were encountered between lung and chest wall

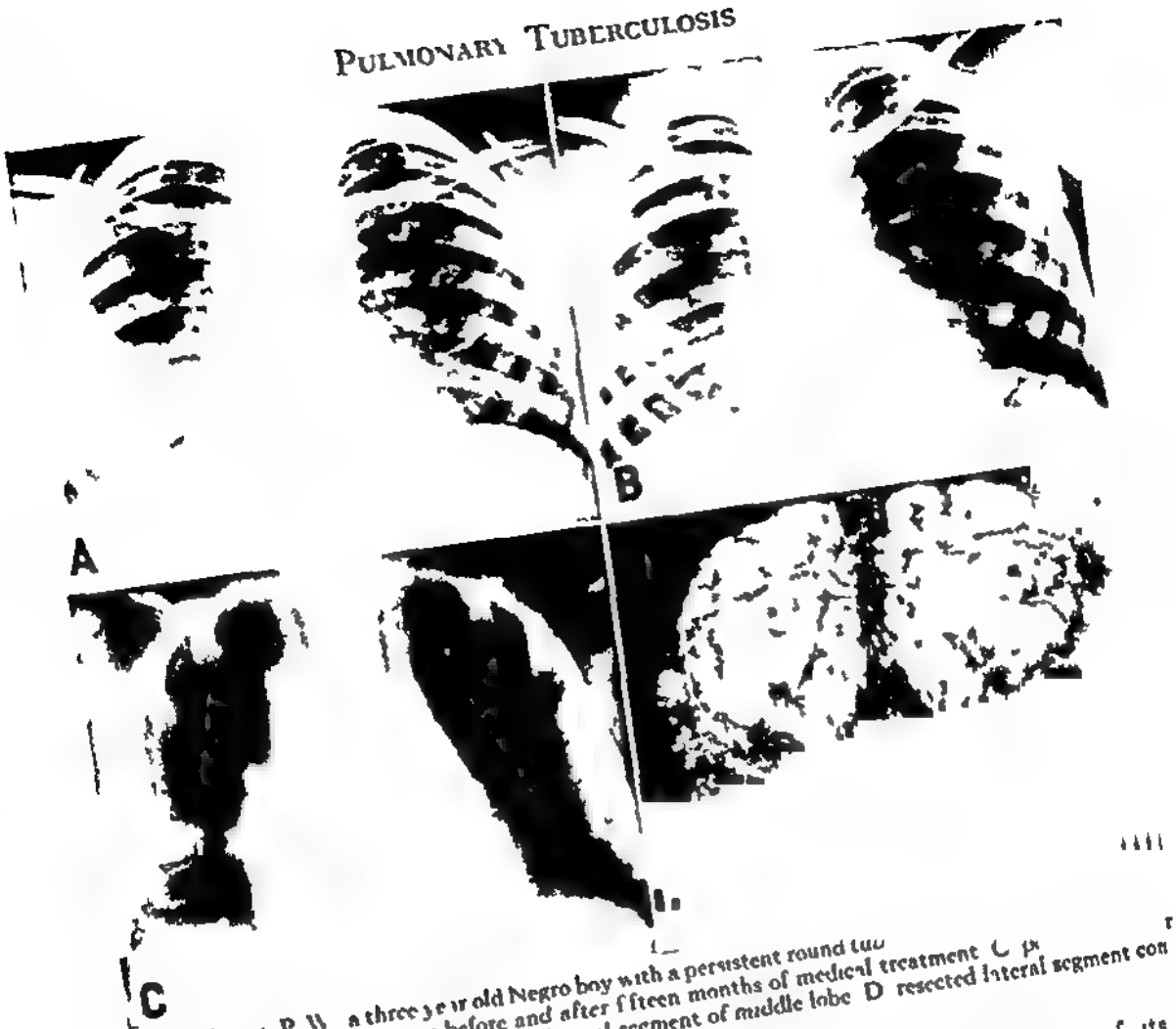

FIG 1 CASE I P W a three year old Negro boy with a persistent round tuberculoma of the middle lobe A and B routine x rays before and after fifteen months of medical treatment C p tomogram showing large round mass in lateral segment of middle lobe D resected lateral segment consists of atelectatic lung surrounding a large caseous focus

The lateral segment of the middle lobe was atelectatic and contained a hard, round mass about the size of a hazelnut The hilar nodes were enlarged The child made an uneventful recovery and has remained well Gross examination of the specimen showed the segment of lung occupied for the most part by a firm rounded well defined caseous focus, measuring 3 by 2 5 cm (Fig 1D) It was not encapsulated was compressing but did not involve the adjacent bronchi On microscopic examination the mass was composed of caseous material surrounded by a thin rim of fibrous tissue It was subdivided by thin fibrous bands into smaller caseous foci many of which contained deposits of calcium Occasional tubercles were seen in the mucosa of the larger bronchi

Comment The indication for resecting this type of primary tuberculosis presented itself in only two cases The caseous focus in this patient undoubtedly represented a primary lesion It was excised because of its large dimension after fifteen months of treatment

Primary Cavity

CASE II C S, a seven year old white girl developed a respiratory infection in October 1951 A chest x ray revealed a collapsed right upper lobe (Fig 2A) A large round mass within this area of density was interpreted as a calcified paratracheal lymph node (Fig 2B) Admission gastric cultures were positive for acid fast bacilli A bronchoscopy on May 2, 1952, revealed no gross involvement of the major bronchi The patient received a course of streptomycin without any change in the radiographic appearance of the lesion On May 8, 1952 right upper lobe lobectomy was performed At operation a shrunken and fibrotic lobe was found which contained a hard round mass about the size of a walnut This mass had simulated the enlarged paratracheal node

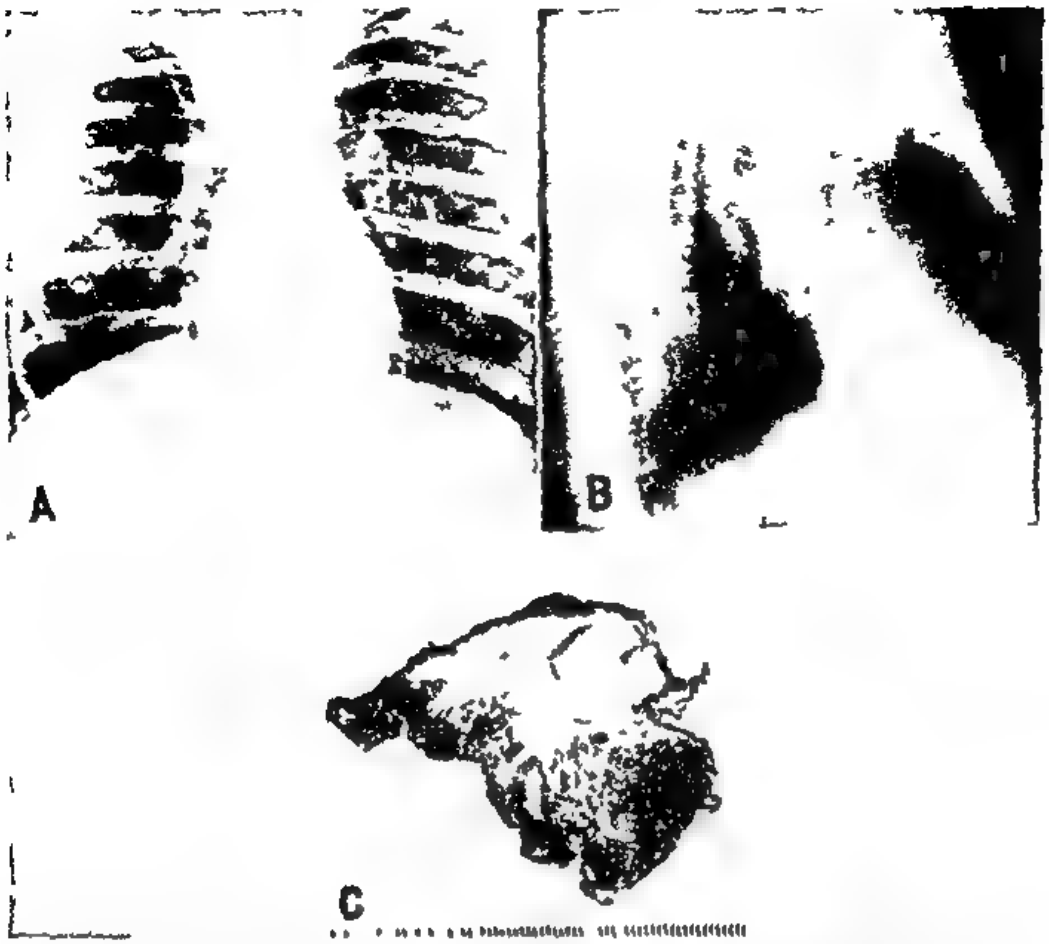

FIG 2 Case II C S, a seven year old white girl with a chronic respiratory infection Gastric cultures were positive for acid fast bacilli A x-ray of chest on admission revealed a shrunken right upper lobe B, lateral tomogram shows a rounded mass interpreted as a paratracheal lymph node C, the resected lobe is shrunken and fibrotic with a cavitated primary caseous focus simulating a tuberculous lymph node

mentioned previously No difficulty was encountered in the hilar dissection The patient was discharged after an uneventful convalescence She is well and attending school The specimen consisted of a shrunken lobe with thickened visceral pleura which, on cut section, revealed a large caseous mass with a central cavity about the size of a dime (Fig 2C) The cavity was filled with necrotic caseous material The lobe was markedly fibrotic with thickened, distorted bronchi On microscopic examination the wall of the cavity was composed of very cellular fibrous tissue There was destruction of an adjacent bronchus by tuberculous granulation tissue

Comment Resection was performed in this case for a persistently shrunken lobe with occasionally positive gastric cultures The caseocavitary lesion probably represented a primary focus The degree of fibrosis within the lobe indicated disease of longer duration than the history indicated

Persistent Segmental Atelectasis

CASE III J R, a four year old Puerto Rican boy, was admitted to Seton Hospital on March 24, 1952 with a history of cough of six months' duration A chest x ray taken on admission revealed an extensive consolidation of the left upper lobe (Fig 3A) Additional x-rays, including tomography, suggested areas of cavitation within this area There was widening of the mediastinum due to enlarged lymph nodes One gastric culture was positive for acid-fast bacilli In June, 1952, streptomycin was started and given for a total of 44 gm Isoniazid was added in October, 1952 Serial chest x rays over a period of one year showed considerable diminution in the size of the lesion (Fig 3B) Bronchoscopy on

FIG 3 Case 11 J R a four year old Puerto Rican boy with a six month history of illness prior to admission to the hospital Gastric cultures on admission were positive for acid fast bacilli A routine x ray before treatment showing extensive consolidation of the left upper lobe B x ray of chest after twelve months medical therapy showing residual disease in the left upper lobe At operation an area of segmental collapse was encountered

February 27 1953 revealed no endobronchial disease An area of density persisted in the left upper lobe the nature of which could not be determined The child was explored on March 26 1953 one year after admission Considerable hilar induration was encountered due to enlarged lymph nodes The left upper lobe contained an area of atelectasis in the anterior segment which on palpation contained numerous small nodules Similar nodules could also be felt in the lingula and in the apex of the left lower lobe The atelectatic area alone was excised over clamps The postoperative course was uneventful The child has remained well since discharge The specimen consisted of a shrunken segment of lung which on microscopic examination showed focal atelectasis Peribronchial tubercles were noted throughout the specimen

Comment It was difficult from the clinical and bizarre radiographic findings to determine the nature of the residual area of consolidation in the left upper lobe The atelectatic segment was probably an area of absorption collapse so-called epituberculosis which in this case could not be differentiated from caseocavernous tuberculosis

Lobar Atelectasis Shrunken Middle Lobe

CASE IV M B a ten year old Negro girl, developed a cough one month prior to admission to Seton Hospital A chest x ray showed involvement of the right middle lobe (Fig 4A and B) Sputum and gastric cultures were persistently negative for acid fast bacilli Bronchoscopy in February 1953 showed redness and swelling of the mucosa around the orifice of the middle lobe bronchus The patient was treated with streptomycin from November 1952 to April 1953 Although there was considerable improvement radiographically [illegible] ted after resected Except for a portion of the medial segment which was aerated the lobe was shrunken and nodular Hilar induration required excision of the lobe by the clamp technic The patient s postoperative course was uneventful She is well and attending school Pathologic examination of the shrunken lobe disclosed two large caseous lymph nodes encircling and compressing the middle lobe bronchus Within the parenchyma there were irregular caseous foci (Fig 4D) Microscopically the caseous masses were surrounded by a broad rim of very vascular and cellular tuberculous granulation tissue which in turn was surrounded by atelectatic lung parenchyma

Comment The indication for resecting the middle lobe was the persistent atelectasis It was surprising how much caseous disease the lobe contained

Postprimary Bronchiectasis

CASE V L K an eleven year old Negro girl was found to have a density in the right upper lobe in a chest x ray taken after her mother s death from tuberculosis The patient was treated in another hospital for eleven

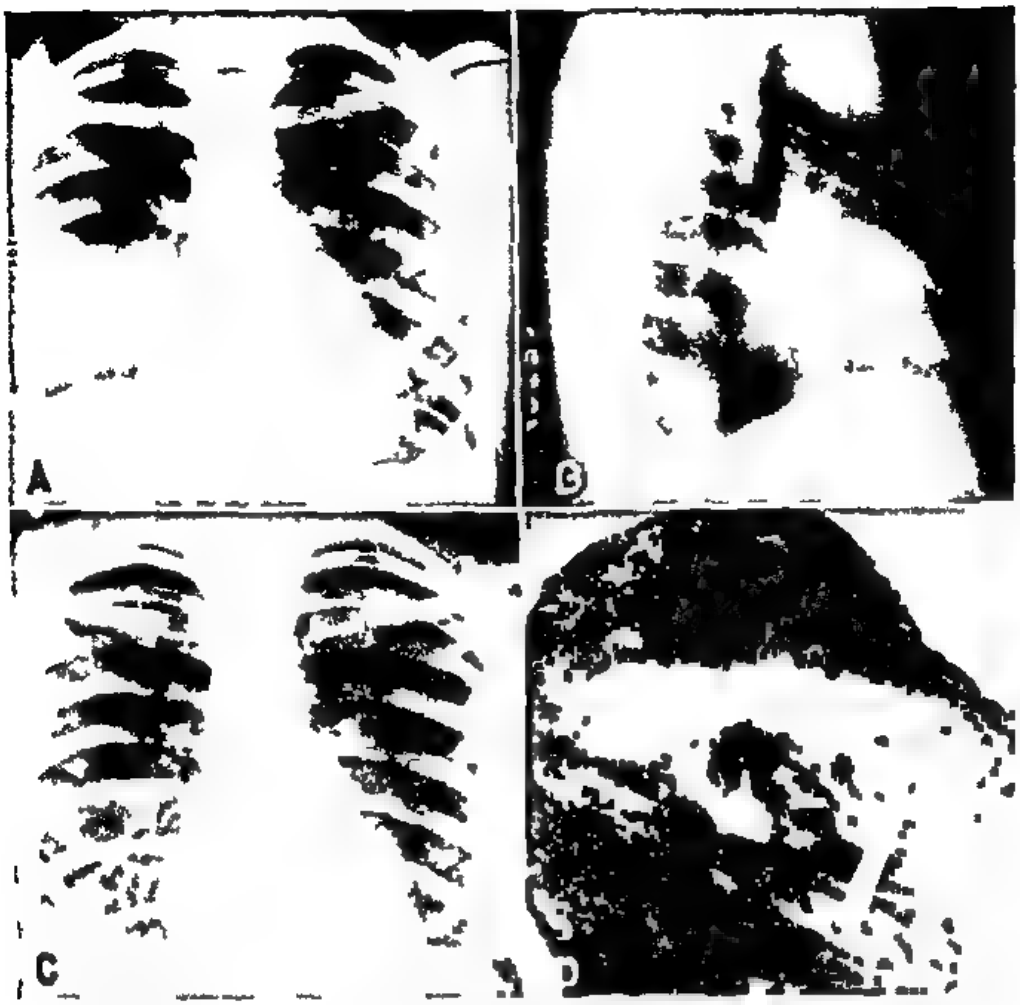

FIG 4 Case V M B a ten year old Negro girl with tuberculosis of the right middle lobe A and B admission x rays showing consolidated middle lobe C, residual disease present after fifteen months medical treatment D specimen shows caseous tuberculosis of the lobe and hilar lymph nodes

months before her admission to Seton Hospital Gastric cultures were occasionally positive for acid fast bacilli X ray of the chest revealed an oval density in the right upper lobe which in the lateral view could be localized to the anterior segment (Fig 5A) The patient was given a course of streptomycin In April 1949 of streptomycin In August 1949 fever again developed and the patient was found to have left pleural effusion which cleared spontaneously in a few months Bronchoscopy on March 12 1951 showed edema around the orifice of the right upper lobe bronchus Serial chest x rays revealed a shrunken anterior segment of the right upper lobe (Fig 5B) Sputum cultures continued to show acid fast bacilli On April 4 1951 right upper lobe lobectomy was performed At operation an atelectatic anterior segment was found which on palpation was firm and nodular The apical and posterior segments appeared uninvolved The patient made an uneventful recovery and has been well since her operation (Fig 5C) The specimen showed partial compression of the lobar bronchus by a hard lymph node The anterior segmental bronchus was completely occluded by a dense scar Distal to this scar the bronchi were dilated and the lung parenchyma atelectatic (Fig 5D) On microscopic section tubercles were noted in the mucosa and submucosa of the involved bronchi

Comment The indications for resection were the positive gastric cultures and the persistent bronchiectasis The involved hilar node and the dense scar within the anterior segment of the lobe probably represented a healed primary complex

FIG 3 Case 1 J R a four year old Puerto Rican boy with a six month history of illness prior to admission to the hospital Gastric cultures on admission were positive for acid fast bacilli A routine x ray before treatment showing extensive consolidation of the left upper lobe B x ray of chest after twelve months medical therapy showing residual disease in the left upper lobe At operation an area of segmental collapse was encountered

February 27 1953 revealed no endobronchial disease An area of density persisted in the left upper lobe the nature of which could not be determined The child was explored on March 26 1953 one year after admission Considerable hilar induration was encountered due to enlarged lymph nodes The left upper lobe contained an area of atelectasis in the anterior segment which on palpation contained numerous small nodules Similar nodules could also be felt in the lingula and in the apex of the left lower lobe The atelectatic area alone was excised over clamps The postoperative course was uneventful The child has remained well since discharge The specimen consisted of a shrunken segment of lung which on microscopic examination showed focal atelectasis Peribronchial tubercles were noted throughout the specimen

Comment It was difficult from the clinical and bizarre radiographic findings to determine the [illegible] in wa[illegible] lapse so-called epituberculosis which in this case could not be differentiated from caseo cavernous tuberculosis

Lobar Atelectasis Shrunken Middle Lobe

CASE IV M B a ten year old Negro girl, developed a cough one month prior to admission to Seton Hospital A chest x ray showed involvement of the right middle lobe (Fig 4A and B) Sputum and gastric cultures were persistently negative for acid fast bacilli Bronchoscopy in February 1953 showed redness and swelling of the mucosa around the orifice of the middle lobe bronchus The patient was treated with streptomycin from November 1952 to April 1953 Although there was considerable improvement radiographically atelectasis of the lateral segment persisted after fifteen months observation (Fig 4C) On December 17 1953 the right middle lobe was resected Except for a portion of the medial segment which was aerated the lobe was shrunken and nodular Hilar induration required excision of the lobe by the clamp technic The patient s postoperative course was uneventful She is well and attending school Pathologic examination of the shrunken lobe disclosed two large caseous lymph nodes encircling and compressing the middle lobe bronchus Within the parenchyma there were irregular caseous foci (Fig 4D) Microscopically the caseous masses were surrounded by a broad rim of very vascular and cellular tuberculous granulation tissue which in turn was surrounded by atelectatic lung parenchyma

Comment The indication for resecting the middle lobe was the persistent atelectasis It was surprising how much caseous disease the lobe contained

Postprimary Bronchiectasis

CASE V L K an eleven year old Negro girl was found to have a density in the right upper lobe in a chest x ray taken after her mother s death from tuberculosis The patient was treated in another hospital for eleven

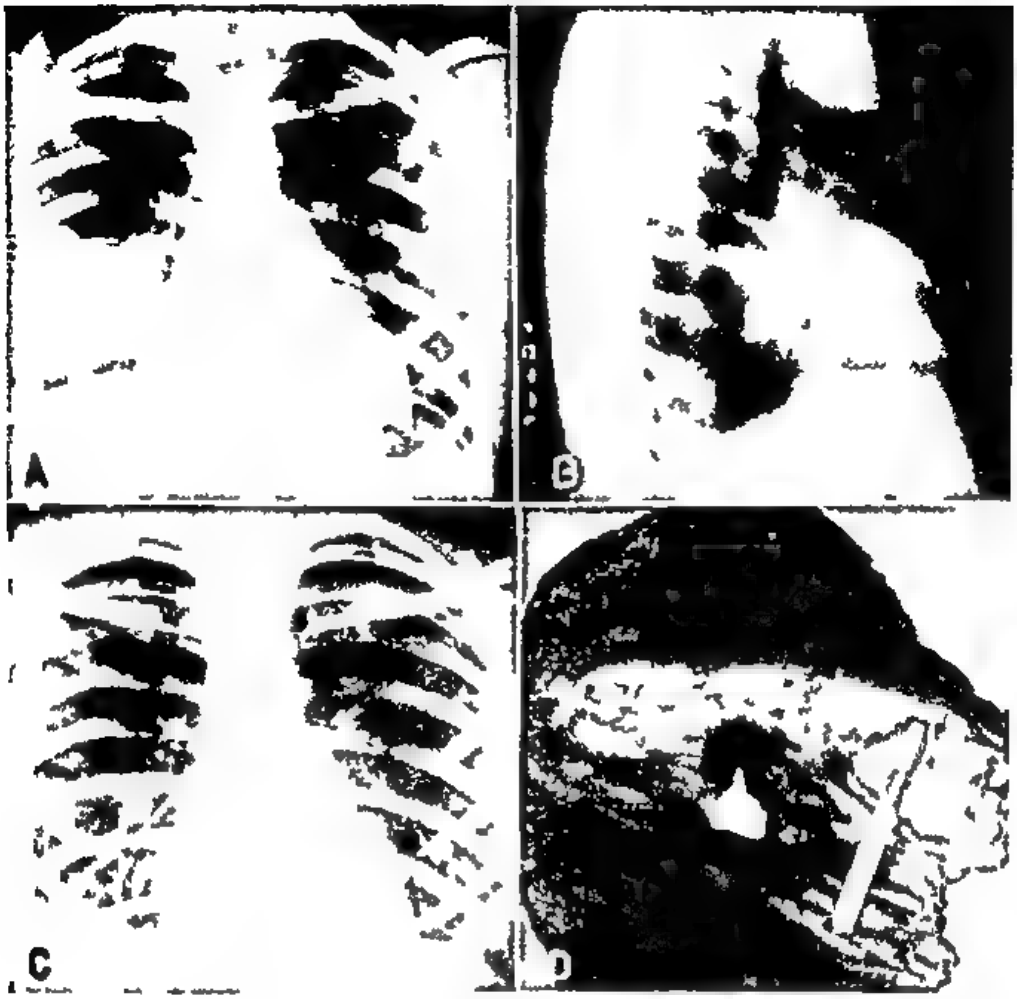

months before her admission to Seton Hospital Gastric cultures were occasionally positive for acid fast bacilli X ray of the chest revealed an oval density in the right upper lobe which in the lateral view could be localized to the anterior segment (Fig 5A) The patient was given a course of streptomycin In April 1949 [illegible] of streptomycin In August 1949 fever again developed and the patient was found to have left pleural effusion which cleared spontaneously in a few months Bronchoscopy on March [illegible] 1951 showed edema around the orifice of the right upper lobe bronchus Serial chest x rays revealed a shrunken anterior segment of the right upper lobe (Fig 5B) Sputum cultures continued to show acid fast bacilli On April 4 1951 right upper lobe lobectomy was performed At operation an atelectatic anterior segment was found which on palpation was firm and nodular The apical and posterior segments appeared uninvolved The patient made an uneventful recovery and has been well since her operation (Fig 5C) The specimen showed partial compression of the lobar bronchus by a hard lymph node The anterior segmental bronchus was completely occluded by a dense scar Distal to this scar the bronchi were dilated and the lung parenchyma atelectatic (Fig 5D) On microscopic section tubercles were noted in the mucosa and submucosa of the involved bronchi

Comment The indications for resection [illegible] primary complex

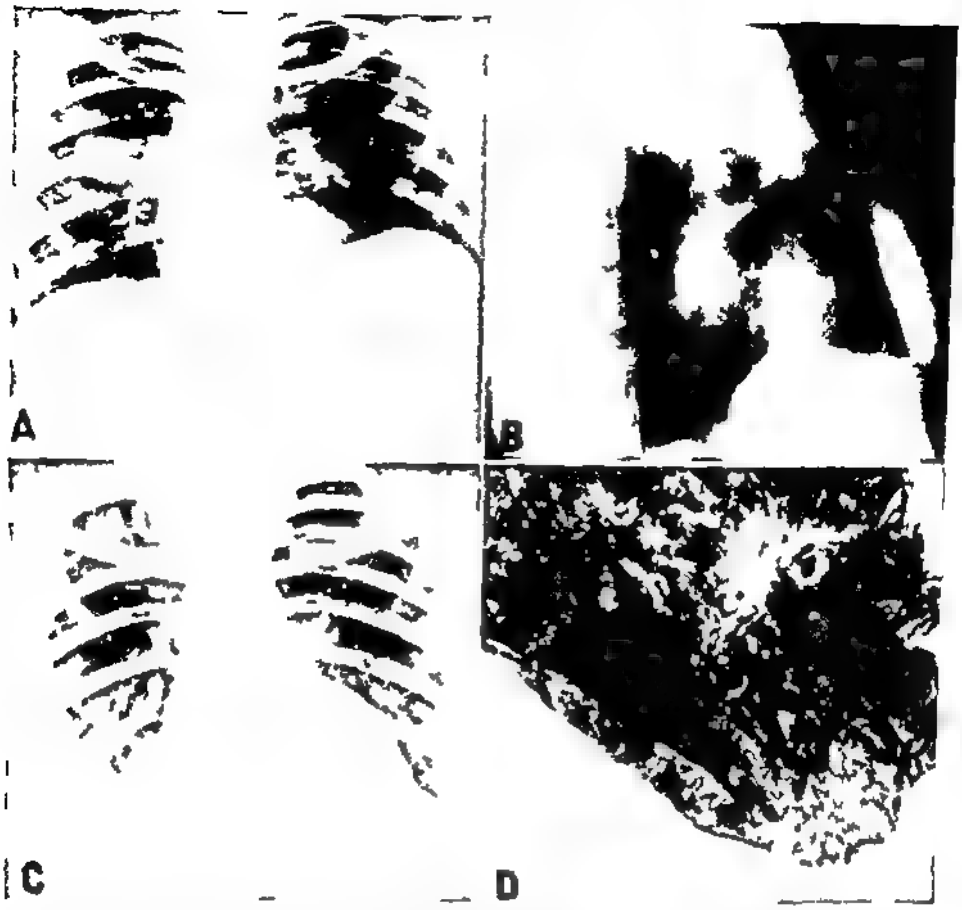

FIG 5 Case V L K an eleven year old Negro girl with an eleven month history of tuberculosis A admission x ray shows an area of density in the anterior segment of the right upper lobe B lateral tomogram after twenty-eight months treatment shows an atelectatic anterior segment Gastric cultures intermittently positive C, x ray of chest 8 x months after operation D resected right upper lobe contains a dense central scar and a shrunken bronchiectatic anterior segment

Bronchostenosis Destroyed Lung

CASE VI M M, an eight year old Puerto Rican girl was admitted to Seton Hospital on January [illegible] 1951 with a history of cough and *fever of one month s duration* Chest x ray revealed complete opacification and contraction [illegible]

vealed stenosis of the left main bronchus below [illegible]

absence of filling of the upper lobe bronchus (Fig 6B) On August 23 1951, left extrapleural pneumonectomy was performed A markedly shrunken and fibrotic left lung was found The postoperative course was uneventful The patient is well and attending school The specimen consisted of a completely destroyed lung replaced by dense scar tissue (Fig 6C) The bronchi [illegible] fibrous [illegible] were pre [illegible] the only evidence of the initial tuberculous infection was the presence of an occasional tubercle with giant cells

Comment The destroyed lung as encountered in this girl resulted from bronchial obstruction by tuberculosis of the hilar nodes The predilection of the left main bronchus to stenosis as a result of childhood tuberculosis is borne out by the preponderance of left pneumonectomies performed for this type of lesion.[2]

TUBERCULOSIS IN THE ADOLESCENT

Caseonecrotic Tuberculosis Solitary Focus

CASE VII M W, a thirteen year old Negro girl was admitted to Seton Hospital on June 30,

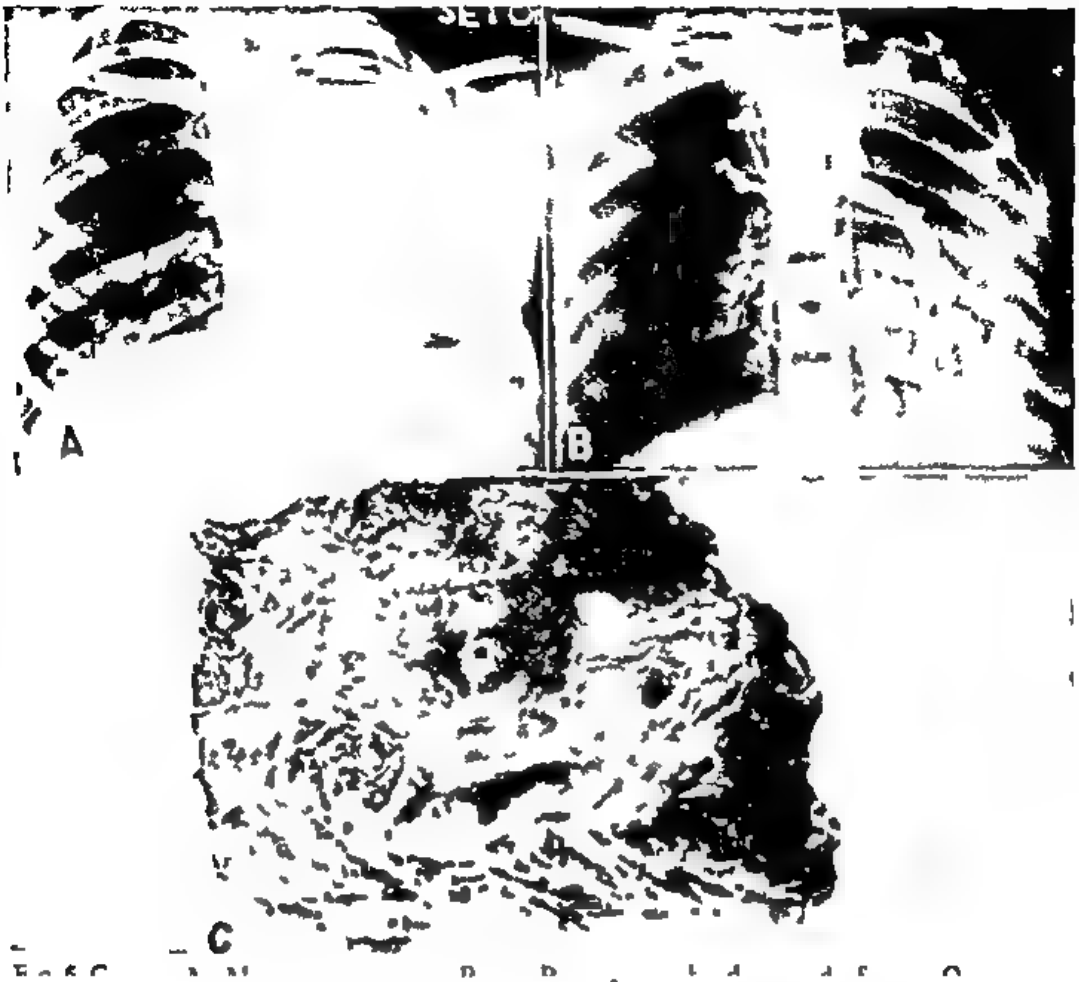

tissue

1950, with a history of pulmonary tuberculosis discovered three months previously Routine chest x ray revealed an infiltration with central cavitation in the right upper lobe (Fig 7A) Sputums were positive on direct smear for acid fast bacilli In October, 1950 right pneumothorax was induced but soon abandoned because of extensive pleural adhesions She was placed on streptomycin and PAS with little change in the radiographic appearance of the lesion On March 6 1951 right upper lobe lobectomy was performed Postoperatively there was some delay in the re-expansion of the remaining middle and lower lobes The patient s convalescence was otherwise satisfactory The patient is well and attending school The resected lobe was found to contain an irregularly shaped caseous mass about 3 cm in diameter with a rim of lung tissue (Fig 7B) Microscopically the mass consisted of caseation surrounded by a zone of tuberculous granulation tissue and atelectatic lung The bronchi and hilar nodes were uninvolved There was little evidence of fibrous encapsulation around the lesion

Comment The central cavitation noted radiographically in this case was not confirmed by the pathologic findings The lack of healing of the disease as seen by the absence of perifocal fibrosis after one year of treatment is to be noted Such foci probably represent primary tuberculosis in the adolescent

Caseonecrotic Tuberculosis Confluent Nodular

CASE VIII M M, a thirteen year old Puerto Rican girl, had hemoptysis in February, 1950 She had been hospitalized elsewhere

FIG 10 Case xi C S, a thirteen year old Puerto Rican girl with bilateral pulmonary tuberculosis A, admission x ray shows bilateral disease with large cavity in the right lower lobe B, *after thirty two months of medical treatment tomogram still shows a* residual cavity in a shrunken and bronchiectatic right lower lobe C, resected lobe contained extensive bronchiectasis and caseous tuberculosis

Tuberculosis of Small Bronchi

CASE X T F, a 15 year old Puerto Rican girl, was found to have a minimal tuberculous lesion in a survey chest x-ray in April, 1950 She was given streptomycin by her physician for six months, which was continued for an additional four months at the Morrisania City Hospital After her transfer to Seton Hospital on January 4, 1951, right pneumothorax was induced, but soon abandoned Gastric cultures were repeatedly positive for tubercle bacilli Bronchoscopy revealed edema of the orifice of the right upper lobe bronchus which subsided after a course of aerosol streptomycin and penicillin Right upper lobe lobectomy was performed on May 7, 1951 The partly shrunken lobe contained many small nodules in the apical and posterior segments The postoperative course was uneventful Two months later bronchoscopy was performed to cauterize an ulceration of the bronchial stump The patient is well and working full time as a bookkeeper On cut section, indistinctly demarcated caseous [illegible] showed extensive endobronchial and peribronchial tuberculosis In some areas the bronchial mucosa was ulcerated, in others, peribronchial tubercles were penetrating into the bronchial lumen

Comment The specimen in this patient showed predominantly bronchial tuberculosis with involvement of the entire lobe The extent of disease noted in the specimen was in sharp contrast with the minimal radiographic findings

Bronchiectasis Destroyed Lobe

CASE XI C. S, a thirteen year old Puerto Rican girl, was found to have bilateral pul-

monary tuberculosis with a large cavity in the right lower lobe (Fig 10A) The patient was treated with pneumoperitoneum streptomycin and PAS but her condition deteriorated Improvement was noted for the first time in 1952 after the administration of isoniazid During the following year her condition improved sufficiently to warrant consideration of resection of the shrunken right lower lobe which still showed a cavity (Fig 10B) Preoperative bronchoscopy revealed narrowing and crowding of the bronchi in the right lower lobe Functional studies showed adequate pulmonary reserve On November 24 1953 a right lower lobe resection was performed At operation a markedly shrunken and indurated lobe was found adherent to adjacent structures requiring extrapleural mobilization The postoperative course was uneventful The patient was discharged and has remained well since her operation The resected lobe was found to be shrunken and bronchiectatic (Fig 10C) The dilated bronchi were filled with inspissated caseous material and had a grey shaggy lining The atelectatic parenchyma contained confluent caseous foci Microscopic examination revealed some of the bronchiectatic cavities to be lined with a thick hyaline membrane others with tuberculous granulation tissue some of which contained remnants of bronchial epithelium

Comment In this patient tuberculosis caused complete destruction of the right lower lobe Prolonged antituberculosis treatment combined with resection achieved arrest of the disease

Minimal Lesion

CASE XII H W a thirteen year old Negro girl was found to have a small lesion in the left upper lobe during an x ray survey in March 1949 She was admitted to Seton Hospital on May 5 1949 and was discharged as an arrested case after ten months of bedrest She was readmitted in March 1951 for reactivation of the lesion and was given a course of PAS Following discharge the sputum again became positive and the patient was admitted for a third time in March 1952 (Fig 11A) The patient was placed on streptomycin and PAS Bronchoscopy showed redness and swelling of the left upper lobe orifice which cleared with aerosol streptomycin On July 31 1951 resection of the apicoposterior segment of the left upper lobe was performed The patient made an uneventful recovery On cut section the specimen showed caseous foci from a pinhead up to 2 5 cm occupying the entire thickness of the resected segment (Fig 11B) Some were well defined others poorly so. Microscopic examination showed the foci to consist of caseation surrounded for the most

part by a broad zone of very cellular and vascular granulation tissue studded with recent tubercles Some of the foci had a thin fibrous capsule Scattered tubercles were noted throughout the parenchyma

Comment This adolescent Negro girl demonstrates the instability of a minimal apical tuberculosis Although the treatment during the first and second admissions may have been inadequate, according to present standards, it is doubtful if more intensive medical treatment alone would have healed the disease

OBSERVATIONS

In dealing with pulmonary tuberculosis in childhood one is concerned with two types of disease (1) primary infection in the very young and (2) postprimary disease in the adolescent Not infrequently overlapping occurs, postprimary disease appearing in the child and primary in the adolescent. With the decline in tuberculosis late primary infection is occurring with increasing frequency In the young primary tuberculosis tends to regress spontaneously and the management is medical Surgery may be required in the treatment of sequelae of the initial infection These are (1) the large, stationary primary focus (2) the primary cavity, (3) the persistently shrunken lobe, (4) symptomatic, postprimary bronchiectasis, and (5) the destroyed lung

The primary focus may require resection if it is large and fails to regress or undergoes cavitation Of the few such cases resected in this series, the caseous nature of the lesions was impressive The significance of the primary focus as a potential site of later activation was shown by Nassau and Pagel [3] In a study of thirty-two lobectomies and forty five pneumonectomies, in patients with an average age of twenty three years they were able to differentiate three types of lesions (1) large, round foci which were clear-cut instances of primary foci, (2) primary cavities and (3) large, round foci in addition to calcified primary complexes found elsewhere The first group consisted of twelve cases in which the majority were symptomless discovered in routine or mass x ray survey Liquefaction was found in most of these foci, four showed early cavitation and caseous endobronchitis Primary cavitation was found in eleven cases Of the eight cases in the third category, inspissated cavities could be identified in two The authors concluded that the lesions encountered especially the cavities, must be regarded as potential or actual sources of phthisis The large size of the lesions predisposed them to cavitation The implication is clear that large primary foci which show no evidence of further regression are preferably treated by excision This applies particularly to young Negro or Puerto Rican children with poor resistance to tuberculosis

Pulmonary atelectasis due to primary tuberculosis is frequently encountered in children The right middle lobe is particularly vulnerable to collapse Graham and Hutchison [4] found the right middle lobe involved in thirteen of thirty cases of absorption collapse in primary tuberculosis in childhood As a rule re-aeration occurs when the infection in the hilar nodes regresses Persistent atelectasis presents a problem in management The children are usually in good health, the sputum or gastric washings do not contain tubercle bacilli Aeration can occasionally be achieved by bronchoscopic aspiration or removal of caseous masses within the lumen Many children, however are found to have normal bronchoscopic findings since the obstruction is usually beyond endoscopic visualization Persistent atelectasis of the lung may require resection The five middle lobes resected in this series contained caseous tuberculosis, several of which probably represented the primary focus It is doubtful if these lobes would ever have become restored to normal since they had been collapsed for long periods of time, the shortest for one year The majority of so-called "middle lobe syndromes" encountered in adults have their origin in childhood [5] Cariens and Hellstrom [6] in a study of twenty three cases of bronchial obstruction found that in children with intrabronchial lesions only six of thirteen treated bronchoscopically showed re-expansion of the shrunken lobe in six months In those with normal bronchoscopic findings where the obstruction was more distal the collapse persisted the affected lobes being the seat of fibrosis and bronchiectasis

As might be expected from the frequency of atelectasis, bronchiectasis is also a frequent complication of primary tuberculosis in children [7–11] In the majority the disease is symptomless and requires no special treatment Surgery may be indicated if secondary infection supervenes, or if the bronchiectatic lung is the source of positive sputum or gastric cultures as

illustrated in Case IV The importance of post-primary bronchiectasis as a source of positive sputum is brought out by Dijkstra[12] who in 1952, reported six resections performed for this reason Bronchography was necessary to delineate the disease in most of the patients In a nine year old boy a totally destroyed left lung with extensive bronchiectasis was found comparable to Case IV in the present series In the remaining five all teenagers the tubercle bacilli disappeared from the gastric cultures and sputum after resection of the involved segments The need for resection of a totally destroyed lung is obvious

The indications for resection of pulmonary tuberculosis in the adolescent are comparable to those in adults and require little comment The pathologic findings in the resected specimens have been very informative The unstable and progressive nature of the disease is in keeping with the predominantly caseous nature of the disease Particularly dangerous in this age group are the minimal apical lesions which may remain clinically dormant for a long period of time and then reactivate Experience has shown that these foci tend to break down and excision is the treatment of choice after a suitable period of preparation with antituberculosis agents

SUMMARY

An analysis of sixty two children and adolescents with pulmonary tuberculosis treated by resection revealed the fact that the indications for surgery are influenced largely by the age of the patient Children under the age of five rarely require surgery because one is usually dealing with a regressive primary disease Resection may be required for irreversible changes in the parenchyma or sequelae due to bronchial obstruction

In children six to ten years of age resection has a wider field of application In this age group one is more apt to encounter sequelae of the primary infection such as a shrunken lobe bronchostenosis or bronchiectasis Some children in this age group may have post primary disease identical to that in the adolescent

Resection is more often indicated for tuberculosis in the adolescent The destructive nature of the disease which may not respond sufficiently to antituberculosis treatment calls for more radical measures

REFERENCES

1 RUBIN M and MISHKIN S Resection for pulmonary tuberculosis in children and adolescents. *Surg Gynec & Obst* 95 751 1952

2 BATELHO G M CHAPCHAP, A PEREIRA H L G and CARDEIRO H V Pneumonectomy in the treatment of tuberculosis in children *Dis of Chest* 20 642 1951

3 NASSAU E and PAGEL, W The early changes of pulmonary tuberculosis in lobectomy specimens *Tubercle* 32 120 1951

4 GRAHAM S and HUTCHISON J H Absorption collapse in primary tuberculous infection in [illegible]

plicating primary tuberculous infection *J Pediat* 41 740 1952

8 WILLIAMS H and ANDERSON C. Bronchiectasis and bronchostenosis following primary tuberculosis in infancy and childhood *Quart J Med* 22 295 1953

9 DICKEY L H Primary pulmonary tuberculosis as a cause of bronchiectasis in children *Dis of Chest* 21 260 1952

10 JONES E M PECK W M and WILLIS H S Bronchiectasis following primary tuberculosis *Am J Dis Child* 72 296 1946

resection *Acta tuberc Scandinav* 26 Fascicle 3 1952

13 DIJKSTRA C Resection therapy for so called minimal lesions *Acta tuberc Scandinav*, 28 Fascicle 3 4 1953

14 BENTLEY I J GRZYBOWSKI S and BENJAMIN H Tuberculosis in Childhood and Adolescence [illegible]

Am J Dis Child 79 30, 1950

17 AUERBACH O Tuberculosis in the adolescent *Am J M Sc* 201 60 1941

18 AUERBACH O Tuberculosis in children *Am J Dis Child* 75 595 1948

19 TSAI P I and BASHE W J JR The complications and sequelae of primary pulmonary tuberculosis *Quart Bull Sea View Hosp* 11 129 1950

71

Segmental Resection

J Maxwell Chamberlain, M D, *New York, New York*

In the surgical management of pulmonary tuberculosis segmental resection is now an established and accepted procedure [1–23] It can be used in all stages of pulmonary tuberculosis *provided the major offending focus is limited* to one or two segments of the lobe The percentage of sputum conversion is high and with experience the morbidity and mortality rates are low *The operative technic is moderately* intricate and demands a great deal of postoperative vigilance When the operation is performed early, it avoids prolonged hospitalization and, by corollary, reduces the task of rehabilitation Its greatest virtue, of course, is its preservation of pulmonary function as was intended by its originator, Dr E D Churchill[9] and other early workers [10 23]

BASIC PATHOLOGY

Pulmonary tuberculosis usually begins as a "patch" of indolent pneumonia confined to the upper and posterior segments of the lobes as reported by Medlar and others [24–30] Less frequently it may involve a lobe or the entire lung but regardless of its dimensions it begins as pneumonia The pneumonia may take three courses (1) resolution, (2) fibrosis or (3) caseation necrosis If resolution of the exudative element occurs, the alveolar walls remain intact, no function is lost and ultimately *all evi* dence of the disease disappears from the chest film If fibrosis occurs, the area is replaced by "scar" tissue (the productive reaction), alveolar function is lost and the x-ray film always reveals the site of the insult In other instances small "patches" of pneumonia coalesce to form a large conglomerate area *If the vascular* nutrition to the center of this area is lost, caseation necrosis occurs and the alveolar architecture is destroyed Usually one or more small bronchi communicate with the necrotic area, and should liquefaction of this caseous material occur, the area "shells out" to form a cavity

Probably all three factors are at work in *every lesion There is some resolution, some* fibrosis and some caseation necrosis It is the necrotic focus, and especially the size of this *focus, that threatens the patient's future wel* fare Through liquefaction of this necrotic area bronchial dissemination of the disease may occur Segmental or subsegmental resection per*formed at the proper time is designed to avoid* such spreads

BASIC PHYSIOPATHOLOGY

The functional advantages of leaving behind only one of three segments of a lobe was at first debatable It was reasoned, however, that as a functional unit it contributed its bit to the total function and as a "filler" it prevented excessive distention of the residual lung components and in this way preserved their function We now know by actual bronchospirometric measurement performed on a series of these patients before and after segmental resec- [illegible] *and in some* [illegible] ments will enlarge to compensate for the healing and contraction in the diseased segments For example (Fig 1), adhesions between the right posterior segment and the chest wall (A) will not permit enlargement and upward *movement* of the lower lobe as healing and contraction occur in the apical and posterior segments (B) However, with the hilum of the lung as an axis, a counterclockwise enlargement of the anterior segment and the middle lobe is often observed On the other hand if adhesions *exist between the right apical segment* and the thoracic vault (Fig 1C) as healing and contraction occur, the lower lobe enlarges and rises high in the pleural cavity (Fig 1D) In [illegible] *for the anterior* [illegible] mental [illegible] adhe- [illegible] leuritis

seems to prevent not only the contraction of the diseased segments but also any significant enlargement of the healthy components

INDICATIONS

The main indication for segmental resection is the necrotic lesion Necrotic lesions may be small, medium or large and still confined to one or two segments of a lobe Not only is the size of the necrotic focus important but also its duration, and especially the amount of associated exudative or pneumonic disease

The duration of the lesion is significant because it ■ difficult in the chest film to distinguish the boundaries between shadows due to exudative, fibrotic or necrotic disease It may be reasoned, though not without an element of doubt, that if the lesion has been present in serial x-rays for some time, it is predominantly a fibrocaseous lesion. In other words, the acute exudative or pneumonic elements have probably resolved If, however, the shadow is being viewed for the first time this assumption may be inaccurate.

The size of the necrotic focus is important because the small foci are drained in most instances by small bronchi and the large ones are drained by large bronchi It seems reasonable to suppose that the caseous material undergoing liquefaction will drain more easily

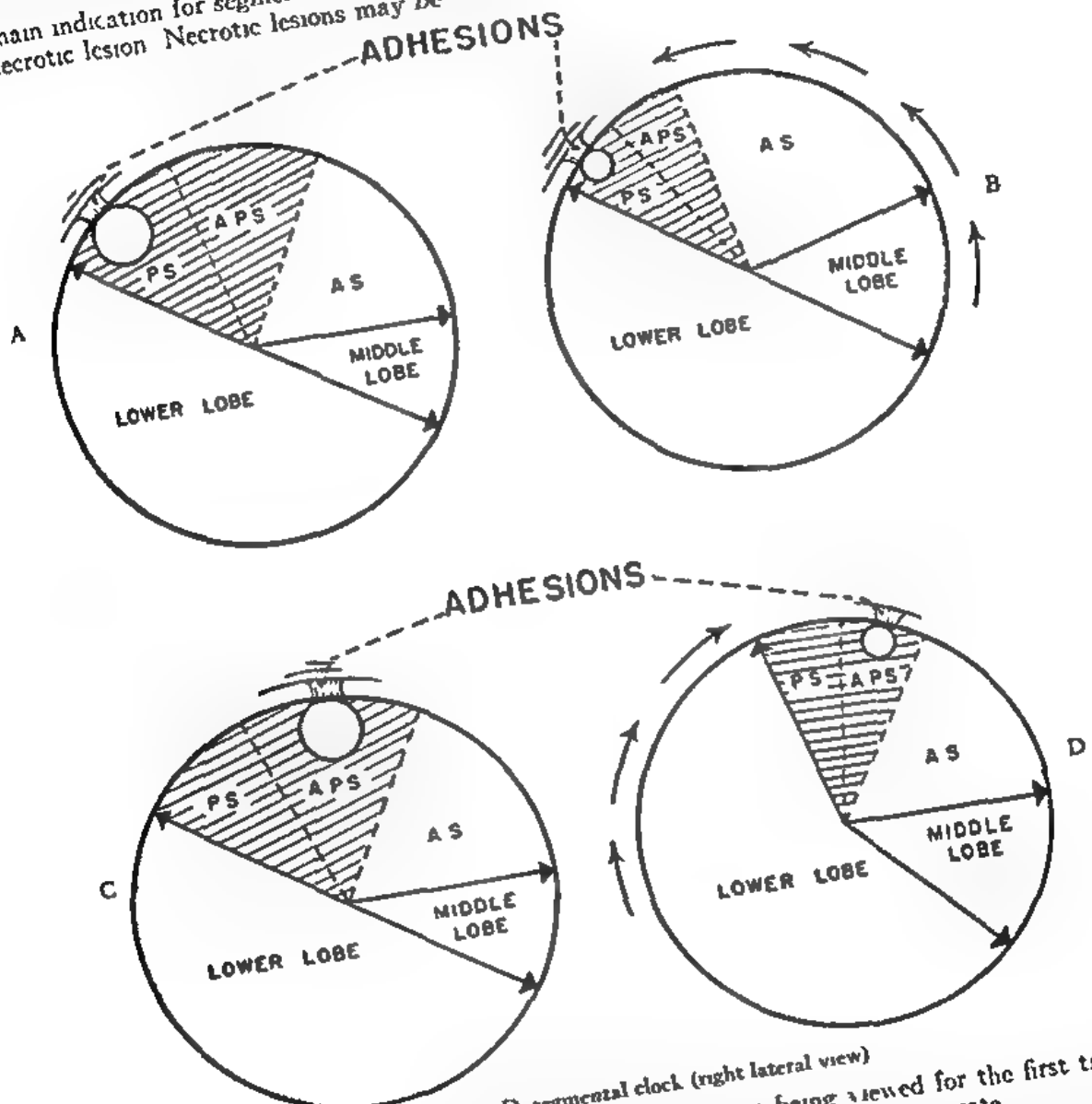

FIG 1 A to D segmental clock (right lateral view)

through a large bronchus than through a small one, and perhaps it follows that it "spreads" more easily as well These points require further proof

gical procedure to be reduced Emergency operations have been successfully performed in the presence of acute tuberculous pneumonia in the presence of hemorrhage, cavity rupture and extensive pneumonic "spreads" but in general major thoracic procedures, including thoracoplasty, should not be done in the presence of significant exudative or pneumonic disease

The ideal indication for segmental resection is the fibrocaseous lesion with or without a cavity and devoid of an exudative element The focus should be of such size and duration that mature medical opinion is doubtful of the patient s future security

PREOPERATIVE STUDY AND PREPARATION[17]

Lateral section laminagraphy stressed by Klopstock[1] gives an extremely valuable preview to the thoracotomy The phrase bloodless thoracotomy' applied to laminagraphy seems justifiable to those accustomed to its use Perhaps no other preoperative study is more helpful to the surgeon [illegible] The exact location of the disease, and especially the appearance of the segments to be left behind may be learned from these lateral laminagraphic sections As experience in the use of laminagraphy increases it is rare for the surgeon to perform a lobectomy when a segmental resection was intended If a segmental resection is contemplated resection is unnecessary, the chest being entered through an intercostal incision since a tailoring surgical procedure after a segmental resection is usually avoided

The specific antibiotics are given for variable lengths of time prior to the operation but always until the exudative element surrounding

operation

TECHNIC OF OPERATION

The segments to be removed have been decided upon prior to operation as a result of lateral laminagraphy, and the bronchi to these segments are immediately isolated and clamped before unnecessary manipulation or mobilization of the lung (There are anatomic exceptions to this plan) After the segmental bronchi have been clamped and divided the lobe [illegible] then mobilized with impunity since secretions can no longer be expressed into the bronchial tree

subsegment

Isolation, ligation and division of the arteries are next accomplished Preservation of the intersegmental veins is desirable when only one segment [illegible] removed but when two segments are removed it is necessary to remove the intersegmental vein with the specimen The intersegmental plane is then developed by gentle traction and dissection as described by Clagett [illegible] Bleeding from the raw area is meticulously controlled No effort is made to cover the raw area with pleura as was previously de-

were the raw area to be closed, in all probability the sutures would cut out in the next few days during deep breathing or coughing The bronchus is then reamputated and closed with interrupted silk sutures Pleuralization of the bronchial stump is not always done Usually the residual segment or adjacent lobe seals the bronchus upon complete re expansion Two tubes are left in for drainage and re expansion One tube is anterolateral and fixed with a suture to the pleura of the thoracic vault The other tube is low and in a posterolateral position The wound is closed in anatomic layers and a small narrow dressing is applied in order to facilitate auscultatory examination of the chest during the immediate postoperative period The large tight dressing physiologically simulates the so called captive lung mechanism Unilateral tidal loss is significant [illegible] The two tubes are connected to a "Y" tube and placed upon active suction

POSTOPERATIVE REGIMEN

The residual segments are inflated at the completion of the hilar dissection and the intrapleural suction is established simultaneously with wound closure Approximately 200 cc [illegible] saline solution are left in the pleural cavity to dilute the small amount of blood which gravi

tates to the dependent parts of the hemithorax during wound closure The dilution of blood by the saline solution prevents clot formation and helps to insure patency of the tubes during the early postoperative period Most of the saline solution is immediately removed by the suction system as wound closure is completed A compact portable suction pump is used to maintain the desired intrapleural pressure during transportation from the operating room This maneuver, though not essential, is an additional precaution to insure immediate and complete re expansion of the residual lung components

At first the patient's position in bed is on the side of the operation Later he is turned to his back and for effective coughing he is allowed to assume the sitting position Young people with muscular diaphragms will tolerate slight elevation of the foot of the bed This allows the fluid to gravitate to the thoracic vault and keeps the costophrenic angle sharp The fluid is then removed through the upper tube and the pleural reaction is confined mainly to the thoracic vault "Pleurisy" which binds or fixes the diaphragm may significantly influence function Pleural reaction in the thoracic vault is of little functional significance

Intrapleural suction is usually set at a minus 15 to 25 cm of water Pressures at a minus 5 to 10 cm of water are physiologic End operative studies on the bronchospirometric contribution of the individual lung have revealed that pleural suction in the range minus 5 to minus 16 in fact results in a control subtidal ipsilateral ventilation Maximum tidal volume occurs with negative pressures in the range of minus 18 to minus 20 It should be noted [illegible] that rem[illegible] requires a [illegible] and bronchioles must not be come occluded by blood or secretions if the [illegible] a segmental atelectasis On the other hand, if a good reverse air flow is maintained up through the bronchioles and out through the small alveolar leaks, secretions do not collect to account for subsegmental or segmental atelectasis In our experience active suction does not prolong alveolar leaking In the majority of cases the tubes can be removed in forty eight to seventy-two hours Tubes are never removed at night It seems preferable to remove them in the morning when a full complement of nurses and doctors is available, should a pneumothorax develop A roentgenogram is taken a few hours after the tubes have been removed with a portable chest x ray machine to determine the degree of lung expansion A sterile trocar, cannula and catheter are always available and suction is re-established immediately should a "late leak" develop Complete and early re expansion seems essential in the prevention of an empyema or bronchopleural fistula

Patent airways, large and small, are essential to successful re expansion Ciliary action, bronchial peristalsis (elongation and fore shortening of bronchus during the respiratory cycle) and cough are the patient's protection against spreads and atelectasis The patient is urged by the nurse to take thirty deep breaths every half hour during his waking hours Furthermore he is encouraged to help turn himself in bed frequently This exercise promotes deep breathing However, intratracheal suction each morning and night during the first forty-eight hours is perhaps the most important postoperative assistance the patient can be given Its disagreeable aspects, if nothing else, assures patient cooperation throughout the day whenever he is urged to cough by the nurse in attendance

Pain is caused by the incision, muscle spasm, the divided ribs and the pleura Little can be done about the incisional pain The muscle spasm can be reduced by frequent passive and active shoulder girdle exercises Fixation of the divided ribs during closure will prevent pain arising from the fracture site, but pain from the pleura is more difficult to control The parietal pleura is very sensitive and the visceral surface of the residual segments is altered, (1) by operative manipulation (gauze abdominal pads, sponges, etc), and (2) by the precipitation of fibrin as a result of the mild but ever present hemothorax The movements of these residual lung components against the parietal pleura, plus the pleural irritation of the drainage tubes, are probably responsible for most of the pain This theory is supported further by the fact that patients after a pneumonectomy have much less pain than patients after a lobectomy or a segmental resection

The control of pain is extremely important

since coughing and deep breathing are painful Narcotics not sedatives will control pain Their frequent use is encouraged in moderate doses The use of narcotics in chest disease earned its bad reputation in the primordial stages of our learning Modern vigilant nursing and a regimented postoperative plan will not allow the patient to slip into narcotic coma and drown in his own secretions

Specific antibiotics are used routinely after operation They are continued for various lengths of time as determined by the attending physician usually for not less than three months The non specific antibiotics are used one day before surgery at operation and for the first week after surgery Non tuberculous empyema and wound infections have played no significant role in our experience Transfusions are used during and after operations to maintain blood volume Usually 1 500 to 2 000 cc of blood is given each patient

Ambulation is permitted during the first two weeks after operation to encourage costal and diaphragmatic breathing Early restricted activity may lead to high fixation of the diaphragm and cause a corresponding decrease in respiratory function The patient returns to bed after two weeks and remains there usually for three months except for lavatory privileges Activity is then increased again

The use of oxygen in segmental resection is important in the older patient but it is rarely necessary in the young patient with good coronary circulation The temporary costal and diaphragmatic restriction after operation creates a shunt and the oxygen saturation of the blood does not return to normal for a variable number of days In the older patients the coronary circulation is an unknown factor In this group the generous and prolonged use of nasal oxygen is encouraged Nasal oxygen

diaphragm is a frequent postoperative complication which may embarrass respiration Clear fluids are given the first day supplemented by intravenous fluids if necessary On the second day nourishing liquids soups custards etc are usually tolerated However an unexplained elevation in pulse rate in a patient who is not vomiting may be an indication for gastric decompression In muscular young men gastric distention is not as obvious as in atonic women or older men Acute gastric distention therefore should be suspected in every muscular young man whose fluid intake is adequate but who remains thirsty runs a rapid unexplained pulse and is not vomiting

An upright x ray film is taken on the first postoperative day with a portable machine A second is taken on the day the tubes are removed (usually the second or third postoperative day) A third is taken on the fourth or fifth postoperative day After that the patient is well enough to stand for fluoroscopy at frequent and regular intervals Such vigilance is necessary since late leaks seem to occur in about 5 to 10 per cent of the patients and immediate intercostal intubation will avoid the complications associated with the unexpanded lung On several occasions we have had to intubate a patient more than twice A late leak developed in one patient on the fourteenth postoperative day one day before discharge In another patient it did not develop until the forty first postoperative day The late leak is considered a minor complication because these patients need not return to the operating room for intubation and it is extremely rare for the late leak to progress and cause a major complication such as empyema or bronchial fistula

COMMENTS

Pulmonary tuberculosis is usually bilateral though not necessarily bilaterally active The advocates of segmental resection must admit that only the major offending focus or foci are removed by this procedure The foci are almost always present in the opposite lung or in the residual lung components on the side of the operation but it should be remembered that these foci are also present in patients successfully treated by other forms of therapy such as bed rest pneumothorax or thoracoplasty Removal of *all* of them is technically impossible and probably unnecessary The decision to remove other foci is dependent upon size and location

The actual size of the hazardous lesion is difficult to estimate in centimeters Usually a large lesion is more hazardous than a small one but on the other hand a small lesion in a patient without resistance can be more hazardous than a much larger one in a patient who seems unable to handle his disease Furthermore it is

noted by those in the field of experimental research, by the pathologist and by the clinician, that lesions in the anterior and dependent segments of a lobe are less hazardous than those in the posterior and apical segments Cavities located anteriorly are recalled only because they are exceptions to the rule or because they began in the apical posterior segments and extended into the anterior and dependent areas A lesion requiring resection in the superior segment of the lower lobe may safely remain in the tip of the lingula To molest the various lobes by attempting to remove locally all foci, large and small, without regard for location ignores this basic information and subjects the patient to unnecessary morbidity and perhaps mortality This belief is based upon not only our recent and short experience with the segmental resection, but upon a comparatively long experience with the thoracoplasty procedure for instance, though the therapy has changed, the location of tuberculosis is the same Therefore, there must have been foci anteriorly in the days when the thoracoplasty was our most popular form of surgical therapy Yet our thoracoplasty failures were not usually due to the "breakdown" of lesions anteriorly where the collapse was least, but due to unclosed cavities posteriorly where the collapse was greatest It is not implied however that tuberculosis located anteriorly should not be respected

Overdistention of the residual segments after segmental resection is less than after lobectomy and pneumonectomy Physiologically respiratory function is inversely proportional to the degree of emphysema caused by overdistention Lung elasticity is variable,[9] and in all patients with tuberculosis there exists a variable amount of emphysema Laennec without a microscope, described focal emphysema surrounding every healed and contracted lesion The physiologic effects of overdistention are much more noticeable in the older patient with horizontal ribs and a thick anteroposterior diameter than in the slender young patient with oblique ribs and a comparatively narrow chest There must be a limit to the amount of distention a lung can tolerate before actual alveolar wall destruction occurs The speed and duration of overdistention are also factors Tuberculosis is an indolent disease which heals slowly As healing and contraction of the diseased segments occur, a slow compensatory enlargement of the healthy parenchyma takes place The undesirable aspects of *suddenly* demanding a single lobe to fill one chest after a lobectomy has led us to believe that a small tailoring procedure should be done simultaneously

Overdistention may or may not be responsible for the "breakdown" or reactivation of disease in the residual segments A point less debatable is the fact that should a breakdown occur the emphysematous patient does poorly with tuberculosis and usually to an extent inversely proportional to the amount of emphysema It is thought that one of the factors responsible for such a response in the emphysematous patient is the interference with the cleansing mechanism The patient's protection against "spreads" is enhanced by an effective cleansing mechanism (1) ciliary action, (2) bronchial peristalsis and (3) cough Bronchial peristalsis consists of changes not only in the diameter of the bronchial lumen but changes as well in the length of the bronchus during inspiration and expiration In the overdistended lobe the bronchus is not only distorted by its new position but is relatively fixed and permanently elongated The amount of foreshortening is reduced Furthermore, the amount of residual or 'stagnant' air is increased and the amount of tidal or "movable" air is reduced and an effective cough is dependent upon *movable* air Therefore overdistention is undesirable not only from a physiologic viewpoint but from a pathologic one as well

Obliteration of the dead space simultaneous with the segmental resection is done to avoid complications When an obliterative pleuritis is present, the adhesions may prevent the compensatory enlargement of the healthy components and a rather large space remains after the resection of two or more segments This space may be obliterated in two ways (1) by a small tailoring thoracoplasty (costectomy) and (2) by extraperiosteal plombage without rib removal

The small tailoring costectomy removes short segments of second, third and fourth ribs posteriorly The first rib may or may not be included If not, the periosteum on its lower surface is mobilized with the others The risk of the additional surgery and the paradoxical chest seems justifiable

The extraperiosteal plombage reduces scoliosis and the amount of paradox The procedure

[illegible] the same as described except that the periosteum on the outer surface of the ribs is preserved the ribs are not removed and the extraperiosteal ' plomb may consist of (1) the patient s own subscapular collection of blood, (2) many sheets of gelfoam® or (3) a plastic sponge encased in a polyethylene bag

TABLE I
NINE DEATHS

Primary Operation—3 (1 [illegible]%)		
W M	2nd postoperative day	?Coronary occlusion
G A	4th postoperative day	Contralateral pneumonia
W T	12th postoperative day	Lower nephron nephrosis
Secondary Operation for Bronchopleural Fistula—4(1 3%)		
Other—2 (0 7%)		
A M	[illegible] mo postoperatively of bronchopleural fistula	
G S	2 3 r postoperatively of alcoholism	

In obliterative pleuritis mobilization of the lower and middle lobes is not done when the preoperative fluoroscopy reveals good movement of the diaphragm Should the lobes be mobilized the diaphragm usually rises to follow their ascent into the thoracic vault The division of the many adhesions provokes oozing and ' sweating of blood which may result in a hemothorax to bind and restrict diaphragmatic movement The functional loss from a small tailoring surgical procedure in the thoracic vault is less than that due to the risk of diaphragmatic fixation

RESULTS

A series of 300 consecutive patients who had [illegible] for pulmonary tuberculosis are [illegible] (Table I)

The type of operative procedure was as follows 210 (70 per cent) had segmental resection only 32 (10 7 per cent) had lobectomy plus segmental resection 31 (7 per cent) had bilobar segmental resection 35 (11 7 per cent) had local excisions only 2 (0 7 per cent) had right upper and middle lobectomies combined with resection of the superior segment of the right lower lobe The significant major complications were bronchopleural fistula tuberculous empyema and spread (Table II) In addition one patient had hemorrhage from a small pulmonary vessel and required reopening of the wound for ligation Another patient required decortication twenty four days after operation to obtain complete re-expansion of the lung

There were nine deaths (Table III) Three patients died as a result of the operation Patient W M, who was apparently progressing satisfactorily, died suddenly on the second postoperative day presumably from coronary artery disease Autopsy did not definitely disclose cause of death Patient G A did very well for two days after operation X ray review at that time showed clear lung fields but late in the afternoon of the second day the patient began to show signs of contralateral pneumonia Death occurred two days later Postmortem examination revealed the contralateral lung to be heavy, gelatinous and essentially free of purulent secretions Four patients died as a result of secondary operations to correct bronchopleural fistula and tuberculous empyema M P had hemorrhage from a subclavian artery which was involved in the tuberculous empyema Control was impossible and he died two days later D G died of an anesthetic accident after pneumonectomy had been completed for bronchopleural fistula L. G died nine days after thoracoplasty and partial resection of the right lower lobe to correct bronchopleural fistula The fistula was controlled but

TABLE II
THREE HUNDRED SEGMENTAL RESECTIONS FOLLOWED ONE TO FIVE YEARS

	No	Per cent
Living and well	281	93 7
Living with disease	10	3 3
Dead	9	3 0

TABLE III
MAJOR COMPLICATIONS

	No	Dead	Persistent	Controlled
Bronchopleural fistula	16(5 3%)	5(1 7%)		11(3 7%)
Empyema	13(4 3%)	5(2 7%)	1(0 3%)	7(2 3%)
Spread	9(3%)	5(1 7%)	1(0 3%)	3(1%)

the limited functioning lung tissue was not sufficient to support the patient F W died after multiple procedures to correct fistula which persisted A M died nine months after operation with a persistent bronchopleural fistula An acute bronchitis was the contributing factor to the final episode G S had a segmental resection for tuberculosis and was well with negative culture and clear x ray films but he was found dead in bed apparently due to alcoholism two years after operation

TABLE IV
EXACERBATIONS

Resolved	5 (1 7%)
Antibiotics only	6 (2%)
Additional surgery	7 (2 3%)
Persistent	18 (6%)
Total	

There have been eighteen exacerbations in the entire series (Table IV) Eleven have resolved with further surgery or antibiotic therapy seven persist About two thirds of these occurred immediately or within the first six months and the remainder at scattered later intervals after operation The late exacerbations have not represented a serious problem in these patients

Eight patients had planned bilateral resection and two required unplanned contralateral resection for pre existing disease

SUMMARY

1 The basic pathology of tuberculosis is an indolent pneumonia which may (1) resolve (2) fibrose or (3) caseate Usually all three elements are present in every lesion

2 The basic physiology is not significantly changed by segmental resection because only the diseased components are removed and compensatory mechanisms have already been effected

3 The indication for segmental or subsegmental resection is a fibrocaseous lesion with or without cavitation confined to one or two segments of a lobe but still large enough that mature clinical opinion is doubtful of the patient s future security

4 The preoperative preparation is the same as for any major operation with special attention to laminagraphy and especially lateral laminagraphy

5 An anatomic segmental resection is done for moderate and far advanced lesions In minimal lesions a wedge resection or local enucleation is possible Subsegmental resections may also be done anatomically

6 Postoperative care must be vigilant Patent airways (intratracheal suction) the control of pain, the use of antibiotics the obliteration of dead space by complete reexpansion of the lung using active suction and checked by frequent postoperative x ray examinations are important to a successful result

7 Tuberculosis is usually bilateral though not bilaterally active Only the major active focus is removed by segmental resection The importance of other foci is dependent upon the size and location Anterior foci are less hazardous than those posteriorly

8 The problem of overdistention is not great after segmental resection but obliteration of the dead space is essential to success Occasionally a periosteal plombage procedure without resection of the ribs is done in deference to this principle

9 In obliterative pleuritis mobilization of the lung is not done when the preoperative fluoroscopy reveals good diaphragmatic movement The functional loss is less if a small tailoring surgical procedure is done in the thoracic vault

REFERENCES

1 GILBERT L Pulmonary resection report of early results *Quart Bull Sea View Hosp* 9 222 233 1947

2 CHAMBERLAIN J M and KLOPSTOCK R Segmental resection in pulmonary tuberculosis Preliminary report *Tr Nat Tuberc A* 45 181 1950

3 KLOPSTOCK R Discussion of Paper by Scannell J G An anatomic approach to segmental resection *J Thoracic Surg* 18 72 1949

4 CHAMBERLAIN J M and RYAN C H Segmental resection in pulmonary diseases *J Thoracic Surg* 18 109 1950

5 SAYSON P C Discussion of Paper by Chamberlain J M and Ryan C H Segmental resection in pulmonary diseases *J Thoracic Surg* 19 220, 1950

6 CHAMBERLAIN J M and KLOPSTOCK, R Further experiences with segmental resection in pulmonary tuberculosis *J Thoracic Surg* 20 845 853 1950

7 PLIEGO J and CHAMBERLAIN J M Pre and post operative treatment in pulmonary segmental resection *Rev mex de tuberc* pp 36–47 Nov Dec 1950

8 CHAMBERLAIN J M Pulmonary segmental resection in tuberculosis *Rev mex de tuberc* pp 48–54 Nov Dec 1950

9 CHAMBERLAIN J M STOREY C F KLOPSTOCK, R and DANIELS C. The small pulmonary lesion —surgical management *Tr Nat Tuberc A* 47 226-231 1951

10 MEYER, A MONOD O BRUNEL, M and PESLE G Segmental resection of lung *Bull et mem Soc méd d hôp de Paris* 67 262 269 1951

11 CONKLIN W S and WESTERBERG H Segmental resection *J A M A* 146 633-641 1951

12 FORSEE J H JENIPEL, C W and SALZER J M *Recent advances in pulmonary resection Ann Int Med* 35 417 431 1951

13 KRAAN J K Segmental resection in pulmonary tuberculosis *Nederl tijdschr v geneesk* 95 3375 3381 1951

14 MARMET A TAUBERT M DE BEAUJEU M ACKERMAN F and MICHEMBLE M Small series of segmental resection in pulmonary tuberculosis in sanatorium environment *Rev Tuberc* 15 999-1002 1951

15 EERLAND L D Results of resection therapy (seg *mental resection lobectomy pneumonectomy)* in pulmonary tuberculosis during the period 1943 1951 KoninKlijke Nederlandse Akademie von Wetenschappen *Proceedings Series* 54 332 341 464 468 1951

16 MONOD O MEYER A PESLE G COURY C BOURIDIN I and BATON D Segmental resection in pulmonary tuberculosis *Am Rev Tuberc* 16 33 1952

17 MONOD O PESLE G and GHAZI Segmental resec tion in pulmonary tuberculos s *J de med de Bordeaux* 129 32 34, 1952

18 NUBOER T F Segmental resection in pulmonary tuberculosis *Poumon* 8 41 50 1952

19 MANNES P Tuberculosis of inferior lobes and seg mental resection *Acta tuberc belg* 43 39-54 1952

20 DOR NATALLI DU COTELL and CARCASSONE Seg mental resection one case of resection of the apical posterior segment in tuberculosis of the lung *Marseille med* 89 133 135 1952

21 MURPHY T D and RAYL, I S Segmental resection for pulmonary tuberculos s *D s of Chest* 23 160-165 1952

22 MARMET A TAUBERT M DE BEAUJEU M ERNEWEIN F and PETIT M Ind cation for seg mental resection in tuberculosis *Lyon méd* 186 280-284 1952

23 ZERBINI E J Segmental resection in the treatment of pulmonary tuberculosis *Rev paulista de med* 44 247 256 1952

24 MARMET A Segmental resection for tuberculosis *Strasbourg med* 3 298 300 1952

25 DERHAM G Ind cations for partial pulmonary resection in tuberculosis *Rev med Suisse Rom* 72 373 377 1952

26 FORSTER, E MAIER, A and KEILING L. S x cases of segmental resection for pulmonary tuberculo- sis *Strasbourg med* 3 681-689 1952

27 STOREY C. F and ROTHMAN B F Segmental resection in the surgical treatment of pulmonary tuberculosis *J Internat Coll Surgeons* 19 53-68 1953

28 OVERHOLT R D WOODS R M and WILSON N G Segmental resection in tuberculos s *D s of Chest* 23 255 265 1953

29 CHURCHILL, E D and BELSEY R Segmental pneumonectomy in bronchiectas s *Ann Surg* 109 481 1939

30 BLADES B Conservation of lung t ssue by partial lobectomy *Ann Surg* 118 353 1943

31 BROCK R C Anatomy of the Bronchial Tree

32

Surg 15 227 1946

33 OVERHOLT R H and LANGER L Ne v tec n que for pulmonary segmental resection Its appl ca tion in treatment of bronchiectasis *Surg, Gynec & Obst* 84 257 1947

34 MEDLAR E M Incidence of tuberculous pul monary cavities in unexpected deaths invest gated at necropsy *Arch Int Med* 8 407 1947

35 MEDLAR E M and SASANO K J A study of pathology of experimental pulmonary tuberculo- sis in the rabb t *Am Rev Tuberc* 34 456 1936

36 DOCK, W Ap cal local zation of phthisis its s g nif cance in treatment by prolonged rest in bed *Am Rev Tuberc* 53 297 1946

37 DANIELS C F CHAMBERLAIN J M and FORD J M Emergency resect on for pulmonary

38

1949

39 KANE I Sectional Rad ograph y of the Chest New York, 1953 Springer Publ shing Compny Inc

40 CHRISTIE R V Elastic properties of emphysem atous lungs and their clinical s gn f cance *J Clin Investigation* 13 2 9-294 1934

41 CINCOTTI J J and WATSON T R Unpubl shed data

Pneumotherapy

James H Cullen, M D, *Albany, New York*

Those forms of treatment that indirectly attack the cause of a disease usually wax and wane in popularity, whereas specific therapy, such as antisera, chemotherapy or hormones which eliminate or correct the disease process, remain constantly in use changing only in details of administration Pneumothorax and pneumoperitoneum are certainly examples of indirect therapy which attempt to correct the effects of the tissue destruction caused by the tubercle bacillus but do not attack the organism directly Their popularity has varied considerably from time to time and even in treatment centers geographically close together there often is a marked difference in the frequency of their use

The purpose desired in applying pneumotherapy, as in any collapse procedure, is relaxation of the diseased lung parenchyma As a result of the relaxation and decrease in the size of the diseased area of the lung, cavity closure and conversion of the sputum to negative are facilitated. Pulmonary hemorrhage from a tuberculosis cavity is often controlled in the same manner In common with all other forms of treatment in tuberculosis, the more recent the disease, the less its extent, the smaller the cavities, the more likely a good result will be obtained

The popularity of pneumothorax and pneumoperitoneum in the New York Metropolitan area between 1945 and 1952 is shown in Figure 1, taken from a study by Lowell [1] This shows the decline in pneumothorax refills after 1947 and the concomitant increase in pneumoperitoneum Over the same period but including 1953, the number of pneumothoraces induced follows a similar curve but the fall starts two years later, the peak of 1,200 initial pneumothoraces being reached in 1949 and falling to 277 in 1953 During this same period thoracoplasties reached a height of 927 in 1949, and in 1953, 317 were done Lobectomies and pneumonectomies have remained constant from 1951 through 1953 (415 and 387) During this period from 1945 to 1953 the number of patients under treatment in the reporting hospitals remained fairly constant, so the number of procedures done from year to year can be fairly compared

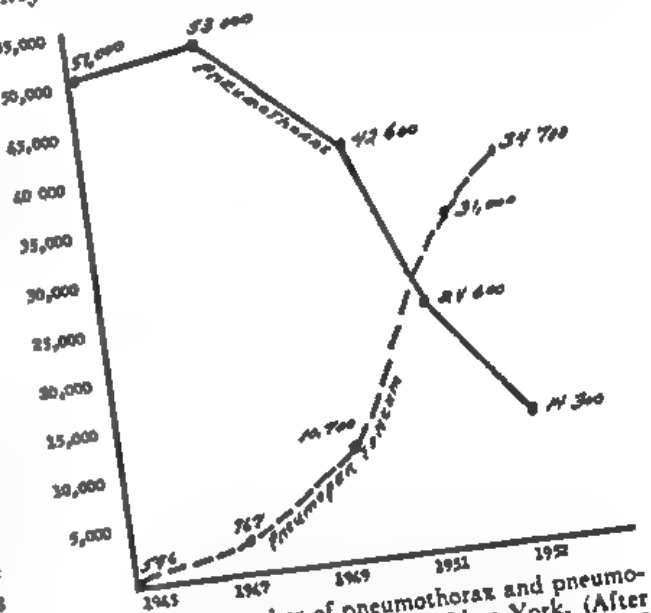

Fig 1 Yearly number of pneumothorax and pneumoperitoneum refills in Metropolitan New York. (After A M Lowell of the New York Tuberculosis and Health Association)

The decline in the use of artificial pneumothorax in the treatment of tuberculosis seems to have occurred coincidental with the development of other methods of treatment, and with an increased awareness of the adverse long-term effect of its complications such as empyema, unexpandable lung and the loss of pulmonary function The results, in terms of sputum conversion from positive to negative, of some collapse and resection procedures are shown in Figure 2

The first bar represents the 47 per cent conversion obtained in cavitary disease with pneumoperitoneum as reported by Trimble

et al [2] There was a one- to ten year follow up although in 84 per cent of the cases pneumoperitoneum was initiated in the last five years of the study The next bar shows the 57 per cent sputum conversion in the first year of therapeutic pneumothorax as reported by Mitchell [3]

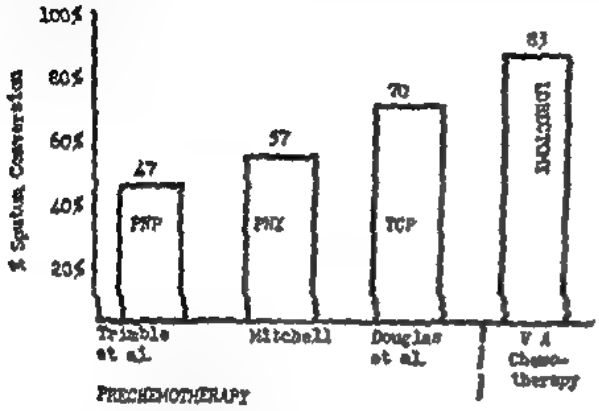

FIG 2 Comparative results of treatment

However 17 per cent of these reactivated their disease in the next ten years and ten to twenty years after induction there were only 39 per cent good results In the third bar are the 70 per cent sputum conversions following thoracoplasty reported by Douglas and Bosworth [4] In a ten year follow up there were 12 per cent relapses The first three groups of patients were all treated in the prechemotherapy era whereas the final bar represents the 83 per cent conversion occurring within eight months after lobectomy done during the course of combined chemotherapy as reported by the Thirteenth Chemotherapy Conference [5] These patients were operated upon in various hospitals all over the country and it probably gives a good representation of the immediate results to be expected in patients suitable for a resection such as lobectomy

As is seen in Figure 2 the immediate results of pneumothorax are very little better than pneumoperitoneum and are inferior to those of thoracoplasty If only primary thoracoplasties (thoracoplasties performed on patients who never had any other collapse procedure) are considered 75 to 85 per cent sputum conversion is to be expected which increases still further the disparity between the results of thoracoplasty and pneumothorax In addition to this there are in 80 per cent or more of pneumothoraces adhesions which should be cut by pneumonolysis in order to obtain a good selective collapse as has been frequently reported most recently by Birath [6] of Sweden

Another reason for the decline in popularity of pneumothorax is the high incidence of serious complications especially in reports of long term studies Figure 3 presents the incidence of the complications of pneumothorax lobectomy and pneumoperitoneum The first

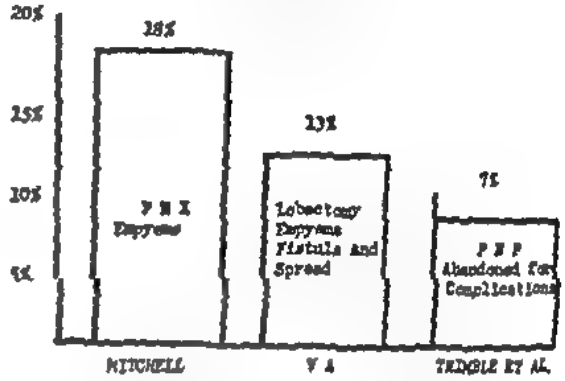

FIG 3 Complications of treatment

bar represents just one complication of pneumothorax namely empyema which was reported by Mitchell [3] to occur in 18 per cent of the cases he studied Even so this one complication was more frequent than the sum total of the major complications of lobectomy of 13 per cent as reported by the Thirteenth Chemotherapy Conference [5] This 13 per cent incidence of complications is higher than the true figure as many patients had more than one complication such as fistula plus empyema but these were each counted separately Pneumoperitoneum has the least complications In the series of Trimble et al [2] 7 per cent were discontinued because of complications Again it is seen that pneumothorax is in a less favorable position than other procedures

That pleural effusion is not completely prevented by chemotherapy given before and after the induction of pneumothorax is shown in the report of Birath [6] Without prior chemotherapy 27 per cent of his patients developed fluid in the first six months of pneumothorax which lasted for two months or more whereas when combined chemotherapy was given before and during pneumothorax 7 per cent developed an effusion that persisted for over two months There were 3 per cent empyemas in the first group none in the second As these pneumothoraces are maintained the incidence of fluid can be expected to increase still further

Finally it has been shown time and again that the maintenance of pneumothorax is associated with a definite and often considerable

able loss of pulmonary function This loss is more closely associated with the amount of pleural and diaphragmatic involvement than with the loss of pulmonary parenchyma as a result of disease

It is probably the general recognition of the fact that the long term results are not nearly as good as the immediate results, and the appreciation of the seriousness and frequency of complications that has led to the decline in the use of pneumothorax The improved surgical results and use of chemotherapy have also been important factors in its fall from favor in the treatment of tuberculosis At the present time one cannot predict the place that pneumothorax will have in the future in the treatment of pulmonary tuberculosis We are now in a wave of reaction against it but eventually the pendulum may swing back to its more frequent use although I do not believe it will ever again be used as extensively as it was in the 1930's and early 1940's A good long-term study, preferably controlled, of its use combined with chemotherapy is badly needed to determine its place in the present day therapy of tuberculosis However, the studies of the prechemotherapy era seem to indicate that if other measures can control the disease, the long term results will be better and complications will be less than they would be with pneumothorax The only undisputed indication for pneumothorax at present is pulmonary hemorrhage uncontrollable by other means where it sometimes stops the bleeding

As was shown in Figure 1, the popularity of pneumoperitoneum has increased as that of pneumothorax declined The combined total of pneumothorax and pneumoperitoneum refills of 49 000 in 1952 almost reaches the peak of 54 000 refills in 1947 According to Lowell[1] in 1953 a total of 1,000 pneumothoraces and pneumoperitoneums (277 and 729 respectively) were induced In the peak years of 1947 and 1949 1,200 pneumothoraces were started From this it can be seen that pneumotherapy is almost as popular as ever

It is seen in Figure 2 that in the prechemotherapy era the immediate sputum conversion rate following pneumoperitoneum is not as great as that with pneumothorax and this has been the general experience and is not limited to the studies of Trimble et al[2] and Mitchell[3] Of course, exact comparisons between different studies cannot be made because of differences in patient characteristics duration and thoroughness of follow-up, and concomitant therapy available

Since sputum conversion is a little less frequent than with pneumothorax, it is probably the very low incidence of distressing or serious complications, as shown in Figure 3 which tipped the balance so much in favor of pneumoperitoneum at the expense of pneumothorax Bobrowitz[8] has listed all the complications of pneumoperitoneum associated with 24,750 refills in 561 patients Weight loss was by far the most common and occurred in 62 per cent of the patients Although peritoneal fluid occurred in 4 7 per cent, it was a cause of termination of pneumoperitoneum in only 1 7 per cent Pain early in the course of pneumoperitoneum was a common occurrence but usually subsided as the treatment was continued Hernia occasionally occurred during treatment Acute appendicitis was usually a more serious disease than in those without pneumoperitoneum because of atypical signs and its failure to localize The two most dangerous complications were pneumothorax often associated with mediastinal emphysema and air embolism They had just two instances of each of these

The location of the cavity in the lung does not effect the incidence of cavity closure and sputum conversion as was shown in the report of Trimble et al[2] The results of pneumoperitoneum are much more influenced by cavity size and duration of disease than the position of the cavity The pressure changes and relaxation of lung parenchyma as a result of the elevation of the diaphragms and reduction in thoracic volume, are transmitted equally throughout the pulmonary tissue unless restrained by adhesions The larger the cavity and the more fibrotic the disease the less are the chances of good result

Early in the use of pneumoperitoneum a phrenic crush was frequently done as an associated procedure sometimes before and sometimes after the induction of the pneumoperitoneum It was thought that by paralyzing the diaphragm on the more involved side the additional diaphragmatic elevation would improve the chances of cavity closure However, in the studies of Trimble et al[2] and Mitchell et al[3] the incidence of good results was no greater in those patients receiving combined pneumoperitoneum and phrenic crush than in those who received pneumoperitoneum alone As a

well known, the loss of diaphragmatic motion causes a loss of one-quarter to one-third of the ventilatory function of the involved side In addition the force of coughing is interfered with and this becomes especially important if *major thoracic surgery becomes necessary. All* too often a "temporary phrenic crush" leads to permanent total or partial diaphragmatic paralysis, especially if the procedure is repeated In the absence of pneumoperitoneum Mitchell[10] found 6 per cent total paralysis and 26 per cent partial after a single phrenic crush, and this increased to 11 and 35 per cent, respectively, when multiple operations were performed In the presence of pneumoperitoneum Mitchell et al[8] found 42 per cent total and 9 5 per cent partial paralysis, one to four years after [illegible]
of th
matic [illegible]
tages, and the fact that equally good results with pneumoperitoneum are obtained without it that the combined procedures are used much less frequently than formerly

Although it remains to be conclusively demonstrated, there are some studies which indicate that pneumoperitoneum instituted early (first two months) in the course of long-term combined chemotherapy improves the results In a report by Brinkman et al[11] the authors found that pneumoperitoneum started in the first month of chemotherapy increased the incidence of cavity closure at eight months to 86 per cent whereas in similar cases treated with chemotherapy without pneumoperitoneum cavity closure occurred in 62 per cent Sputum conversion showed a similar difference of 81 and 67 per cent, respectively, in favor of the *addition of pneumoperitoneum* The differences in the two groups of cases were especially marked when the original cavities were 2 cm or over in size Moyer and Schwartz[12] found that pneumoperitoneum added to combined chemotherapy increased the incidence of cavity closure but not of sputum conversion In neither of these studies were concurrent controls used selected in a random manner as to those treated with and without pneumoperitoneum Because of this one might question the differences found as representing inapparent, unconscious bias in the selection of cases for the group receiving or not receiving pneumoperitoneum to their respective advantage or disadvantage The Veterans Administration—Army—Navy Chemotherapy Cooperative Study has embarked on a controlled study with random selection of patients into groups receiving and not receiving pneumoperitoneum but the results have not been reported as yet

Since these studies indicate that in cavitary disease chemotherapy and pneumoperitoneum *combined seem to give better results than* chemotherapy alone, serious consideration has to be given to using both procedures in all cases with cavity especially if over 2 cm in size The experience at Trudeau[11] suggests that the results are much better if the pneumoperitoneum is instituted soon after the introduction of chemotherapy rather than later Ordinarily one would reserve pneumoperitoneum for anticipated chemotherapy failures or *individuals receiving chemotherapy who had* not obtained cavity closure and sputum conversion by the fourth to sixth month Using pneumoperitoneum in most cases with cavitary disease is not without its disadvantages in spite of the low incidence of serious complications with this procedure As was shown in the report by Bobrowitz,[8] 62 per cent of the patients receiving pneumoperitoneum lost weight and in addition, it is moderately uncomfortable It *requires refills at about ten day intervals for a* year or more, which chain the patient to their doctor and interfere with movement from place to place In view of these minor but distressing disadvantages and our reluctance to treat all patients in the same routine manner, it is obvious that there is an urgent need for reasonably accurate criteria that will detect those cases in which chemotherapy alone will fail, and which would be helped by combined *chemotherapy and pneumoperitoneum* Until such information is available, it is recommended that pneumoperitoneum be instituted in cases in which it is anticipated the chemotherapy alone will fail (because of cavity size more chronic disease, older age patients extent of disease) It is also important to decide early during a course of chemotherapy *which* cases are not responding rapidly as to cavity closure and sputum conversion and in these start pneumoperitoneum without delay Pneumoperitoneum is especially needed in those patients who are not suitable for surgical procedures, such as thorocoplasty and resection Pneumoperitoneum is also often *helpful* in controlling pulmonary hemorrhage

SUMMARY

1 The reasons for the decline in popularity of therapeutic pneumothorax such as its pleural complications and its effect on pulmonary function are discussed

2 The need for re evaluation of pneumothorax combined with chemotherapy is recognized but it must await reports of long-term results

3 Pneumoperitoneum is replacing pneumothorax in popularity and is needed in anticipated or demonstrated chemotherapeutic failures, especially if thoracic surgery is not applicable

4 The use of pneumoperitoneum early in the course of chemotherapy in the presence of cavitary disease is discussed At present the evidence is conflicting as to the advantage of the addition of pneumoperitoneum to chemotherapy over the results obtained in long term chemotherapy alone

REFERENCES

1 LOWELL, A M Tuberculosis in New York City 1953 p 18 New York 1954 New York Tuberculosis & Health Assoc

2 TRIMBLE H G, EATON, J L CRENSHAW, G L and GOURLEY, I Pneumoperitoneum in the treatment of pulmonary tuberculosis Am Rev Tuberc, 52 433 1948

3 MITCHELL, R S Artificial pneumothorax a statistical analysis of 557 cases initiated 1930–1939 and followed in 1949 1 Am Rev Tuberc, 64 1, 1951

4 DOUGLAS R and BOSWORTH, C B The after-history of pulmonary tuberculosis II Thoracoplasty ten year follow up Am Rev Tuberc, 69 930 1954

5 Transactions of the Thirteenth Conference on the Chemotherapy of Tuberculosis Veterans Administration—Army—Navy, 1954

6 BIRATH D G The initial period of artificial pneumothorax Dis of Chest, 24 245 1953

7 MITCHELL R S Artificial pneumothorax a statistical analysis of 557 cases initiated 1930–1939 and followed in 1949 IV Incidence mortality, and factors associated with complicating tuberculous empyema Am Rev Tuberc 64 127, 1951

8 BOBROWITZ I D Complications of pneumoperitoneum therapy Dis of Chest 24 82, 1953

9 MITCHELL, R S, HIATT, J S McCAIN, P P, EASON H F and THOMAS C D Pneumoperitoneum in the treatment of pulmonary tuberculosis Am Rev Tuberc 50 306 1947

10 MITCHELL, R S Phrenic nerve interruption in the treatment of pulmonary tuberculosis II Complications and sequelae of phrenicolysis Am Rev Tuberc, 60 168 1949

11 BRINKMAN G L RALEIGH J and MITCHELL, R S The use of pneumoperitoneum as an adjunct to the prolonged streptomycin para amino salicylic acid treatment of pulmonary tuberculosis Am Rev Tuberc, 69 963 1954

12 MOYER R E and SCHWARTZ W S Results of addition of pneumoperitoneum to long term chemotherapy Transactions of the Thirteenth Conference on the Chemotherapy of Tuberculosis Veterans Administration—Army—Navy, 1954

XXV. BRONCHIECTASIS, ABSCESS, AND CYSTIC DISEASE

73

Bronchiectasis

FRANCIS M WOODS M D *Brookline Massachusetts*

From the Herbert Thoracic Clinic Boston Massachusetts

BRONCHIECTASIS means dilatation of bronchi this is a pathologic situation usually associated with chronic infection and involving the secondary and smaller bronchi It is the result of a variety of diseases Although described by L [illegible] t [illegible] tween a normal and a dilated bronchus nor between the uninflamed and the chronically infected bronchus Nor can any clear distinction be made between a dilated suppurative bronchus and a lung abscess with communicating bronchus The changes may involve the *bronchi only or they may spread out into the* adjacent parenchyma The bronchial walls may be diffusely dilated into tubular types or irregularly dilated into saccular types The muscle elastic and cartilage components may be partially or completely replaced by fibrosis and inflammation If the fibrosis spreads out into the parenchyma the involved segment may be more or less contracted and consolidated and the term atelectasis is commonly [illegible] lobe and the [illegible] combination of these segments may be involved The anterior segment of the upper lobe and the superior segment of the lower lobe come next in frequency

ETIOLOGY

Ordinarily the cause of a given case of bronchiectasis cannot be ascertained The history is usually much more prolonged than that of tumors or foreign bodies in the bronchi but it is known that bronchiectasis does develop beyond such obstructions It seems logical therefore that some partial obstruction preceded the development of bronchiectasis [illegible] glands resulted from a preceding infection or caused infection in the obstructed bronchi is impossible to say A history of protracted pneumonia tuberculosis or pertussis is not unusual Two factors obstruction and infection seem to be necessary The usual distribution in the dependent bronchi suggests that gravity acts as a significant additional obstructive factor

SYMPTOMATOLOGY

There is no consistent correlation between the extent of the symptoms and the extent of the disease Characteristically there is chronic [illegible] fever malaise and increased cough and expectoration are common Hemoptysis is far commoner than previously supposed In the absence of roentgen evidence of parenchymal disease in the lung (and assuming that heart disease and hypertension and blood dyscrasias are excluded) bronchiectasis is the most likely cause Strangely hemoptysis due to bronchiectasis frequently occurs unassociated with cough or sputum and it is then referred to as dry bronchiectasis Dyspnea suggests extensive involvement or related fibrosis and emphysema Clubbing of the fingers weight loss weakness and inanition are usually seen in advanced cases It is important to realize that minimal demonstrable bronchiectatic changes may be associated with considerable symptoms

and conversely extensive changes may occur with few, if any, symptoms

DIAGNOSIS

Positive diagnosis depends on bronchography However, physical examination may reveal rales in the distribution of dilated bronchi These may be inconstant, appearing only with clinical exacerbation Dullness and decreased breath sounds may be noted in contracted areas Plain chest x ray reveals no abnormality if the inflammation does not extend beyond the bronchi, but in more advanced cases there are increased lung markings or densities where fibrosis and inflammation extends out into the parenchyma'

In order to visualize bronchi they must be outlined with contrast media just before x rays are taken This procedure is called bronchography Our technic consists of anesthetizing the pharynx with a spray of 10 per cent cocaine Premedication should include a barbiturate Five to 10 cc of 2½ per cent cocaine is dripped into the trachea leaning the patient to the left for part of the injection to assure anesthetizing the left bronchus A single rubber catheter (No 18) is passed between the vocal cords and the patient lies on the tilting fluoroscopic table The tip of the catheter is placed beyond the carina on the side to be studied first Forty per cent lipiodol is injected through the tube slowly The patient is rotated and tilted and the tube is moved in any convenient sequence to allow outlining of all the segments on the side to be studied Immediately the patient stands and a postero-anterior and lateral x ray is taken In adults 6 to 10 cc of lipiodol is sufficient to outline one side more may flood the alveoli and result in obscuring the bronchi Rapid coordinated steps result in the best bronchograms, for the lipiodol may diffuse rapidly into alveoli After the first side is done the tube is changed to the opposite side which is outlined in the same way Now postero anterior and both obliques are taken—the latter at 30 degrees The catheter is withdrawn and the patient is encouraged to cough up the oil and is placed in the Trendelenburg position to promote drainage of the lipiodol All films are full sized, 6 foot plates, since spot films waste time and do not give comparison of normal and dilated bronchi Most children under eight years cannot cooperate sufficiently, therefore, they are given deep ether anesthesia An endotracheal tube is inserted, and a polyethylene tube passed through the endotracheal tube is used for the introduction of lipiodol The procedure is otherwise as in adults except that the x-ray films are taken in a recumbent position At the close of the procedure the bronchial system is easily cleared by suction

In the near future water soluble media may well replace lipiodol Although not fully perfected, they have the advantage of being rapidly eliminated whereas lipiodol may adhere to the bronchi or alveoli for many weeks Pulmonary resections within three to four weeks of lipiodol bronchography are more likely to be complicated

At the time of operation additional evidence can be obtained concerning abnormal segments which may not have been recognized in the bronchograms Bronchiectatic segments may feel crepitant and inflate or deflate perfectly normally but usually there is some induration and or nodulation in an abnormal segment and inflation and deflation are retarded. Marked delay in deflation is called air-trapping.

TREATMENT

Bronchiectasis as a general rule does not progress from segment to segment Treatment is, therefore based on extent of symptoms The extent of symptoms does not necessarily

Prevention As always, prevention is the best treatment Adequate and prompt care of all pulmonary and bronchial infections, particularly pertussis in children, pneumonia and tuberculous infections should reduce the incidence of bronchiectasis Foreign bodies in the bronchus should be removed promptly bronchoscopically and, if necessary, surgically

Non surgical Non-surgical methods are recommended for the control of exacerbations of symptoms, for preparation for surgery, and in postoperative recovery In mild cases they are in themselves adequate In widespread cases they are used as the best palliation possible They are mechanical and antibiotic and chemotherapeutic

Mechanical methods promote better drainage of secretions and improve alveolar ventilation Cough should not be suppressed by medication, but encouraged since it is the normal method of expulsion of secretions Medications

XXV. BRONCHIECTASIS, ABSCESS, AND CYSTIC DISEASE

73

Bronchiectasis

FRANCIS M WOODS M D *Brookline Massachusetts*

From the O erbolt Thoracic Cl nic Boston Massachusetts

BRONCHIECTASIS means dilatation of bronchi

tween a normal and a dilated bronchus nor between the uninflamed and the chronically infected bronchus Nor can any clear distinction be made between a dilated suppurative bronchus and a lung abscess with communicating bronchus The changes may involve the bronchi only or they may spread out into the adjacent parenchyma The bronchial walls may be diffusely dilated into tubular types or irregularly dilated into saccular types The muscle elastic and cartilage components may be partially or completely replaced by fibrosis and inflammation If the fibrosis spreads out into the parenchyma the involved segment may be more or less contracted and consolidated and the term atelectasis is commonly though incorrectly applied to such fibrotic contracted segments The dependent segments are the only ones involved in most instances Thus the basal segments of the lower lobes middle lobe and the lingula are the usual sites Any combination of these segments may be involved The anterior segment of the upper lobe and the superior segment of the lower lobe come next in frequency

ETIOLOGY

Ordinarily the cause of a given case of bronchiectasis cannot be ascertained The history is usually much more prolonged than that of tumors or foreign bodies in the bronchi but it is known that bronchiectasis does develop beyond such obstructions It seems

glands resulted from a preceding infection or caused infection in the obstructed bronchi is impossible to say A history of protracted pneumonia tuberculosis or pertussis is not unusual Two factors obstruction and infection seem to be necessary The usual distribution in the dependent bronchi suggests that gravity acts as a significant additional obstructive factor

SYMPTOMATOLOGY

There is no consistent correlation between the extent of the symptoms and the extent of the disease Characteristically there is chronic cough productive of small or large amounts of green or yellow globules of sputum In severe cases it may be fetid Superimposed episodes of frank pneumonia or, at least bronchitis with fever malaise and increased cough and expectoration are common Hemoptysis is far commoner than previously supposed In the absence of roentgen evidence of parenchymal disease in the lung (and assuming that heart disease and hypertension and blood dyscrasias are excluded) bronchiectasis is the most likely cause Strangely hemoptysis due to bronchiectasis frequently occurs unassociated with cough or sputum and it is then referred to as dry bronchiectasis Dyspnea suggests extensive involvement or related fibrosis and emphysema Clubbing of the fingers weight loss weakness and inanition are usually seen in advanced cases It is important to realize that minimal demonstrable bronchiectatic changes may be associated with considerable symptoms

and conversely extensive changes may occur with few, if any, symptoms

DIAGNOSIS

Positive diagnosis depends on bronchography However, physical examination may reveal rales in the distribution of dilated bronchi These may be inconstant, appearing only with clinical exacerbation Dullness and decreased breath sounds may be noted in contracted areas. Plain chest x ray reveals no abnormality if the inflammation does not extend beyond the bronchi, but in more advanced cases there are increased lung markings or densities where fibrosis and inflammation extends out into the parenchyma'

In order to visualize bronchi they must be outlined with contrast media just before x rays are taken This procedure is called bronchography Our technic consists of anesthetizing the pharynx with a spray of 10 per cent cocaine Premedication should include a barbiturate Five to 10 cc of 2½ per cent cocaine is dripped into the trachea leaning the patient to the left for part of the injection to assure anesthetizing the left bronchus A single rubber catheter (No 18) is passed between the vocal cords and the patient lies on the tilting fluoroscopic table The tip of the catheter is placed beyond the carina on the side to be studied first Forty per cent lipiodol is injected through the tube slowly The patient is rotated and tilted and the tube is moved in any convenient sequence to allow outlining of all the segments on the side to be studied Immediately the patient stands and a postero-anterior and lateral x ray is taken In adults 6 to 10 cc of lipiodol is sufficient to outline one side, more may "flood" the alveoli and result in obscuring the bronchi Rapid coordinated steps result in the best bronchograms, for the lipiodol may diffuse rapidly into alveoli After the first side is done, the tube is changed to the opposite side which is outlined in the same way Now, postero-anterior and both obliques are taken—the latter at 30 degrees The catheter is withdrawn and the patient is encouraged to cough up the oil and is placed in the Trendelenburg position to promote drainage of the lipiodol All films are full sized, 6 foot plates, since spot films waste time and do not give comparison of normal and dilated bronchi Most children under eight years cannot cooperate sufficiently, therefore, they are given deep ether anesthesia An endotracheal tube is inserted, and a polyethylene tube passed through the endotracheal tube is used for the introduction of lipiodol The procedure is otherwise as in adults except that the x ray films are taken in a recumbent position At the close of the procedure the bronchial system is easily cleared by suction

In the near future water soluble media may well replace lipiodol Although not fully perfected, they have the advantage of being rapidly eliminated whereas lipiodol may adhere to the bronchi or alveoli for many weeks Pulmonary resections within three to four weeks of lipiodol bronchography are more likely to be complicated

At the time of operation additional evidence can be obtained concerning abnormal segments which may not have been recognized in the bronchograms Bronchiectatic segments may feel crepitant and inflate or deflate perfectly normally, but usually there is some induration and/or nodulation in an abnormal segment and inflation and deflation are retarded. Marked delay in deflation is called air-trapping.

TREATMENT

Bronchiectasis as a general rule does not progress from segment to segment Treatment is, therefore, based on extent of symptoms The extent of symptoms does not necessarily [illegible]

Prevention As always, prevention is the best treatment Adequate and prompt care of all pulmonary and bronchial infections, particularly pertussis in children, pneumonia and [illegible] recommended for the control of exacerbations of symptoms, for preparation for surgery, and in postoperative recovery In mild cases they are in themselves adequate In widespread cases they are used as the best palliation possible They are mechanical and antibiotic and chemotherapeutic

Mechanical methods promote better drainage of secretions and improve alveolar ventilation Cough should not be suppressed by medication, but encouraged since it is the normal method of expulsion of secretions Medications

XXV. BRONCHIECTASIS, ABSCESS, AND CYSTIC DISEASE

73

Bronchiectasis

FRANCIS M WOODS, M D, *Brookline, Massachusetts*

From the Overholt Thoracic Clinic, Boston, Massachusetts

BRONCHIECTASIS means dilatation of bronchi, this is a pathologic situation usually associated with chronic infection and involving the secondary and smaller bronchi It is the result of a variety of diseases Although described by Laennec in 1808, its importance came to light in the last three decades, with the diagnostic use of iodized oil No sharp line can be drawn between a normal and a dilated bronchus nor between the uninflamed and the chronically infected bronchus Nor can any clear distinction be made between a dilated suppurative bronchus and a lung abscess with communicating bronchus The changes may involve the bronchi only or they may spread out into the adjacent parenchyma The bronchial walls may be diffusely dilated into tubular types or irregularly dilated into saccular types The

[illegible]

into the parenchyma, the involved segment may be more or less contracted and consolidated, and the term atelectasis is commonly

[illegible]

the basal segments of the lower lobes, middle lobe and the lingula are the usual sites Any combination of these segments may be involved The anterior segment of the upper lobe and the superior segment of the lower lobe come next in frequency.

ETIOLOGY

Ordinarily the cause of a given case of bronchiectasis cannot be ascertained The history is usually much more prolonged than that of tumors or foreign bodies in the bronchi, but it is known that bronchiectasis does develop beyond such obstructions It seems logical, therefore, that some partial obstruction preceded the development of bronchiectasis.

[illegible]

glands resulted from a preceding infection or caused infection in the obstructed bronchi is impossible to say A history of protracted pneumonia, tuberculosis or pertussis is not unusual Two factors, obstruction and infection, seem to be necessary The usual distribution in the dependent bronchi suggests that gravity acts as a significant additional obstructive factor

SYMPTOMATOLOGY

There is no consistent correlation between the extent of the symptoms and the extent of

[illegible]

frank pneumonia or, at least, bronchitis with fever, malaise and increased cough and expectoration are common Hemoptysis is far commoner than previously supposed In the absence of roentgen evidence of parenchymal disease in the lung (and assuming that heart disease and hypertension and blood dyscrasias are excluded) bronchiectasis is the most likely cause Strangely, hemoptysis due to bronchiectasis frequently occurs unassociated with cough or sputum and it is then referred to as "dry bronchiectasis" Dyspnea suggests extensive involvement or related fibrosis and emphysema Clubbing of the fingers, weight loss, weakness and inanition are usually seen in

[illegible] to realize that

[illegible]ges

[illegible]ms

1B 1C

FIG 1D Case 1 Resected middle lobe on the right and the basal segments of the lower lobe on the left showing markedly thickened and dilated bronchial tubes with extension of the inflammation into the parenchyma which is fibrotic and contracted

to decrease the viscosity of secretions such as ammonium chloride potassium iodide and other expectorants are useful in making cough more effective Inhalation of detergents such as alevaire which may be given via a nebulizer are very valuable Positioning the patient with the head hanging low over the side of a bed or table is called postural drainage Often a patient by taking a few minutes of postural drainage once or twice a day will evacuate his secretions so well as to eliminate cough for the rest of the day In severe situations it may be necessary to aspirate secretions directly from the bronchial system either by transtracheal catheter or bronchoscopy

In the event of oxygen want oxygen is administered by simple nasal catheter mask or tent The catheter is preferred as effective simple and interfering least with patient comfort and nursing care Intermittent positive pressure oxygen administered through a Burns valve* has proved invaluable in more severe oxygen want This valve administers oxygen under regulated pressure with inspiration With expiration the pressure drops down to atmospheric allowing complete exhalation Since a larger volume of oxygen is forced into the lung there is a more satisfactory force for the expulsion of secretions Since exhalation is unimpeded no carbon dioxide accumulation takes place Alevaire and antispasmodics may be nebulized through a parallel system with these valves

Antibiotic and chemotherapeutic agents are used to control acute infections and minimize chronic ones Broad spectrum drugs are usu

or drugs used should ideally be chosen after sensitivity study We hesitate to recommend indefinite use of antibiotics and chemotherapeutics because of the danger of superinfection Prolonged antibiotic and chemotherapeutic treatment in low doses may be justified in certain instances of widespread disease with severe symptoms The status of this question is not yet clear

Surgical Excision of all pathologic segments is the ideal treatment and offers the best probability of permanent relief of symptoms It is undertaken only after the best preliminary improvement has been obtained by non surgical methods If bronchiectasis is completely localized to excisable segments complete relief can be expected Compromise with the principle of complete excision is indicated however when bronchiectasis involves so many segments that excision of all would lead to significant pulmonary insufficiency Compromise may also be indicated if the segments not involved by bronchiectasis are poorly functioning because of asthma emphysema or other abnormality Obviously younger people will tolerate greater pulmonary tissue loss than older individuals with lesser cardiac and pulmonary reserve Less functional loss will be sustained in removing completely destroyed segments than segments which are still functioning to some degree Pulmonary function studies may help to evaluate borderline cases but gross observations such as ease of climbing stairs use of accessory respiratory muscles the degree of emphysema and general vitality of the patient are all useful In less than ideal cases one may compromise by only excising the worst segments or in severe situations

FIG 1A Case 1 Plain chest x ray showing density in the lower lung field caused by bronchiectasis with inflammation extending out into the lung parenchyma

* Available through the Mine Safety Appliance Company Pittsburgh Pa the Emerson Company Cambridge Mass and V Roy Bennet and Associates Los Angeles California

1B 1C

FIG 1D Case 1 Resected middle lobe on the right and the basal segments of the lower lobe on the left showing markedly thickened and dilated bronchial tubes with extension of the inflammation into the parenchyma which is fibrotic and contracted

by depending only on postural drainage expectorants and antibiotics

At operation the thorax is opened on the side of involvement If the disease is bilateral the side of greatest involvement is opened first *The lung is completely freed of adhesions* and before excision is started all the evidence is evaluated First what areas of bronchiectasis can be determined by the bronchogram? Second what segments are indurated nodular or covered by dense adhesions? Third what areas trap air inflating slower and deflating slower than the normal segments as the anesthetists assist respiratory exchange? Finally in what areas have rales been heard and pneumonitis occurred?

All diseased segments are removed using individual hilar technics whether total lobes or segments are to be removed Occasionally a small diseased subsegment can be simply removed by the less anatomic clamp-and cut technics The perfection of technics of segmental resection in the hands of Overholt and his co-workers and others has led to the salvage of many normal functioning segments Since the basal segments of the lower lobes are commonly involved and the superior segments usually not involved the latter constitute an important salvage That such salvaged segments function is suggested by the studies of Overholt Walker and Etsten[8] and confirmed by clinical observation of such patients

Segmental resection implies salvage of normal segments and increases the possibilities of bilateral excision Bilateral simultaneous excision has been done in very good risk patients with well localized problems but is not an established procedure Usually an interval of several months should occur between sides Actually many patients experience such relief after the first operation that often the second one can be indefinitely postponed

CASE REPORTS

CASE I H B, a thirty five year old house wife had pneumonia four times in eleven years There was a long standing history of chronic cough and purulent expectoration with marked increase in the year before operation Blood streaked sputum and wheeze had occurred She had always been malnourished Examination revealed many rales front and back in the lower right chest Plain chest x ray (Fig 1A) showed density in the right lower lung

FIG 2A Case II Plain chest x ray showing advanced bronchiectasis The plain x ray of the chest is clear

The superior segment of the lower lobe (S) was normal as was the left side The anterior segment of the upper lobe (A) showed questionable dilatation At thoracotomy in May 19,1 the basal segments of the lower lobe and the middle lobe were removed The anterior segment of the upper lobe felt normal and did not trap air it was not removed The patient s vitality weight and strength have all improved Her respiratory symptoms have vir

of

be

safely eliminated The danger of future trouble is minimal Figure 1D shows on the left the basal segments Note the marked thickening and irregularity of the bronchi which do not narrow as they reach the periphery The middle lobe on the right shows even more advanced involvement with extension of the fibrosis into the parenchyma This is the cause of the density in the plain x ray film

CASE II M L a twenty six year old housewife gave a long standing history of cough purulent sputum minor hemoptyses and many



FIG. 2B and C. Case . B. oblique view showing advanced bronchiectasis in the lingula (L) and in the basal segments of the left lower lobe (B). C. left anterior oblique view shows moderately advanced bronchiectasis in the middle lobe (M) and the basal segments of the right lower lobe (B). Also this view shows the advanced bronchiectasis already described on the left side. Despite advanced bronchiectasis it was not necessary to operate upon this patient who had few symptoms.

respiratory infections. Examination in 1952 showed rales at both lung bases, front and back. Plain chest x-ray (Fig. 2A) was essentially clear. B. L.

cases of the middle (M) and the basal segments of the right lower lobe (B) are best seen.

The patient had never received any therapy whatsoever. She was placed on postural drainage and given an intensive short course of broad spectrum antibiotics and expectorants. When seen two years later her symptoms remained so minimal that excisional therapy was not contemplated.

Comments. It is unusual for such advanced bronchiectasis to be easily controlled but it is to be emphasized again that extent of bronchographic changes and symptoms do not neces

sarily correspond Surgical intervention is recommended for patients with recurring or intractable symptoms provided that bronchiectasis is sufficiently localized

SUMMARY

Bronchiectasis means dilatation of bronchi and is usually associated with chronic cough expectoration and frequent respiratory infections Permanent relief can be offered those patients whose disease is reasonably localized by surgical excision Postural drainage and antibacterial therapy offer temporary relief Therapy is guided by extent of symptoms and not by extent of bronchographic changes for the two do not necessarily correspond and bronchiectasis does not ordinarily spread from segment to segment

REFERENCES

1 WEINSTEIN L. GOLDFIELD M and CHANG, TE WEN Infections occurring during chemotherapy—a study of their frequency type and predisposing factors *New England J Med* 251 247 255 1954

2 OVERHOLT R H WOODS F M and RAMSAY B H Segmental pulmonary resection *J Thorac Surg* 19 207 220 1950

3 OVERHOLT R H WALKER J H and EYSTEN B Pulmonary function after multiple segmental resection for bronchiectasis *J Thorac Surg* 25 40–54 1953

74

Bronchiectasis in the Older Patient

HELEN S PITTMAN, M D, *Boston, Massachusetts*

From the Pulmonary Clinic Massachusetts General Hospital Boston Mass

BRONCHIECTASIS in older persons is essentially a medical disease It is a condition which we can rarely expect to cure, rather, the place of the physician is to keep the patient in as good condition and as nearly symptom-free as possible [1] In most of these patients we are dealing not with bronchiectasis alone but also with variable degrees of pulmonary fibrosis and emphysema The disease is usually bilateral and quite diffuse, although major areas of involvement may be expected to be found in the lower portions of the lungs Less commonly the disease is due to a localized bronchial obstructive process This may be endobronchial tuberculosis, bronchial adenoma, foreign body or very rarely bronchogenic carcinoma In these situations the bronchiectasis will usually be limited to the segment or lobe distal to the obstruction

Basic problems of management depend upon the symptoms and the underlying disease

DIAGNOSTIC PROCEDURES

These should be individualized and not routine, and include the following

1 *Examination of Sputum* Routine cultures are worthless as they will reveal a mixed flora

Search for tubercle bacilli should be carried out carefully when the x ray suggests past pulmonary tuberculosis or when localized disease could be due to bronchial tuberculosis

Cytologic examination by Papanicolaou technic is indicated when there is repeated blood streaking It is, however, often unsatisfactory due to large amounts of pus in the sputum In bronchial adenoma cytology is not diagnostic

2 *X rays* Ordinary technic postero-anterior and lateral films with the addition of postero-anterior grid film will usually give the necessary information

Bronchograms should not be made routinely simply to confirm the radiologist's suspicion of bronchiectasis If, however, surgery is being contemplated, a carefully executed bronchogram is important in outlining the areas of normal bronchial pattern as well as the diseased portions

3 *Diagnostic Bronchoscopy* This should be carried out whenever there is a question of bronchial obstruction, inflammatory or neoplastic, and when there is bleeding The latter is particularly important in the presence of

THERAPEUTIC PROCEDURES

These should be planned in relation to symptoms

1 *Cough and Sputum* Cough which helps to raise secretions is useful A dry, irritating, unproductive cough is useless and measures should be taken to suppress it In general, one should encourage the raising of secretions during the day Simple expectorants, such as potassium iodide, syrup of hydriodic acid or terpin hydrate, are usually effective aids to this When sputum is copious it is important to try to have it raised in advance of each meal

head down position because of dizziness It may be tried cautiously for a very few minutes and, if the patient tolerates the position, it will prove useful It should be remembered that the function of postural drainage is to start the upward flow of secretions to a point where the cough reflex will be effective in completing the raising of sputum In this connection it is worth while to mention smoking Most doctors urge patients with cough to omit tobacco

Certainly excess smoking contributes to coughing However, it is well to remember that inhaled smoke is often an effective stimulus to cough which raises sputum A dry cough, particularly one which interferes with sleep, should be suppressed by codeine at night and before meals A vaporizer or steam kettle at the bedside is useful in controlling irritative cough at night A DeVilbiss No 149 runs a full eight hours without attention

2 *Intercurrent Respiratory Infections* These people are never free of infection in the respiratory tract The basic lesion of bronchiectasis is twofold chronic infection of the tissues of the bronchial wall as well as changes in size and shape of the bronchi These underlying changes make patients particularly vulnerable to colds, and their colds always are "chest colds" with acute bronchitis at least and frequently areas of pneumonitis Because of this bacterial reservoir they should receive penicillin, 300,000 to 600 000 U by intramuscular injection daily, for five to ten days at the start of a cold

We have found that the number and severity of acute infections can be helped to a worth while degree by the daily use of prophylactic chemotherapy during the season of colds We start many patients on a sulfonamide (one 0 5 gm , [7 5 gr] tablet of either sulfamerazine or gantrisin® twice a day) about September 1st and keep them on this daily ration until warm weather is established the following spring The patients on this regimen are required to return in one week, then two weeks and monthly thereafter during the period of administration in order to have white counts and urine examinations Any patient who is put on daily chemotherapy should be told what drug he is taking He should not be given therapeutic doses of sulfonamide for any infection because there is a possibility that it might suppress bone marrow activity and result in dangerous leukopenia

Instead of a sulfonamide patients may be put on prophylactic antibiotics penicillin, aureomycin, achromycin,® etc These preparations are more expensive, they may in some instances induce gastrointestinal upsets and, most important they may lay the groundwork for serious and dangerous monilial infections

3 *Dyspnea* This is a troublesome symptom in many patients It is usually a manifestation of the associated pulmonary fibrosis or emphysema Spain[2] has produced impressive evidence to suggest that the primary lesion in emphysema is in the terminal bronchiole He has demonstrated thickening, narrowing, stiffening and inflammation of the bronchiolar walls According to his ideas this chronic infection, to which recurrent acute infections are added, sets up bronchospasm which causes secondary distention of the alveoli He notes that emphysema usually occurs in patients with long standing cough

Bronchodilator drugs should be used in patients with bronchiectasis who have dyspnea Aminophyllin by mouth may be tried and is sometimes beneficial The most useful drugs are vaponefrin, isuprel® and neo-synephrine® These are administered by nebulizer (Vaponefrin or DeVilbiss No 40 are good) It is important that the patient be taught how to use the nebulizer, it should be inserted in the mouth just beyond the teeth and the spray inhaled slowly

Oxygen must be used with great caution in the patient with chronic pulmonary disease who is dyspneic and may be cyanotic at rest These patients probably have both carbon dioxide retention and anoxia If oxygen is given in an attempt to relieve dyspnea and cyanosis, the increase in arterial saturation which will occur may reduce the anoxic stimulus to breathing The consequent hypoventilation allows more carbon dioxide retention, and carbon dioxide narcosis may appear Thus the cyanotic patient who is given continuous oxygen during an ambulance trip to the hospital may arrive in coma

If oxygen is to be given to these patients, it must be used sparingly and intermittently for short periods several times a day

4 *Bleeding* This may constitute an indication for surgery If hemorrhage is severe, it may be justifiable to make a direct approach on the source of bleeding even in a poor risk patient We have recently had such a situation

PNEUMONECTOMY FOR MASSIVE HEMORRHAGE

CASE 1 (M G H unit No 102604) A fifty year old crane operator came to the Emergency Ward of the Massachusetts General Hospital on June 24, 1954, because of hemoptysis for four days

This man had had a chronic cough since he had influenza in 1918 at the age of fourteen He was first seen at the hospital in 1926 with

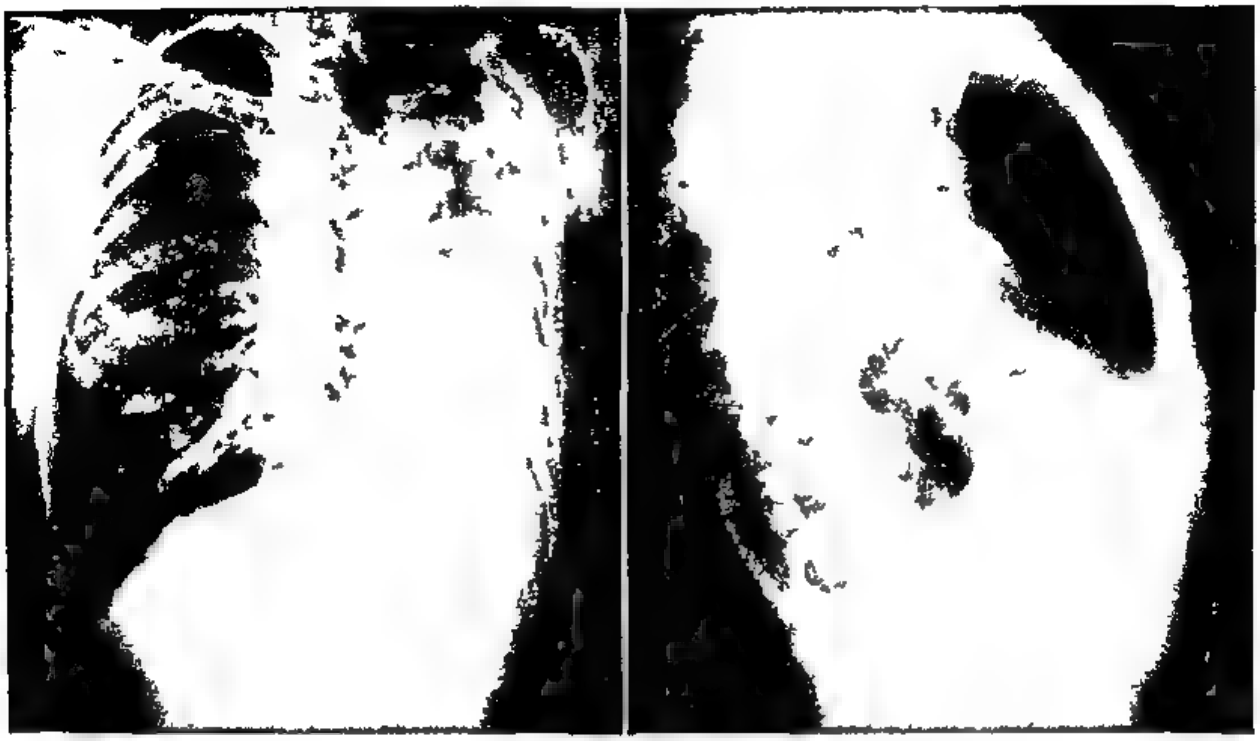

1A 1B

FIG 1 Case 1 A and B postero-anterior and lateral x rays taken three years before left pneumonectomy for uncontrolled hemoptysis Note that although the left lung is the site of major disease there are also extensive changes in the right lung with emphysema at apex and base and probable collapse of the middle lobe

hemoptysis and a consequent suspicion of tuberculosis A diagnosis of bilateral bronchiectasis was made at that time He had foul breath, cough sputum and on one past occasion, had had hemoptysis of one pint He had lost 35 pounds Intensive search of sputum failed to demonstrate tubercle bacilli and the tuberculin skin test was negative Since then he has been seen irregularly during the past twenty eight years

In 1938 a lipiodol examination demonstrated bronchiectasis in left lower right lower and right middle lobes

In 1938 he was presented to Dr Edward D Churchill for question of operation Dr Churchill believed that because of the bilateral involvement surgery was not advisable and advised a series of therapeutic bronchoscopies Prognosis was considered very doubtful Bronchoscopy was performed repeatedly with aspiration of large amounts of thick tenacious foul secretion from both main bronchi (This patient is one of those included in the follow up

X rays at that time were essentially the same as those which were taken on April 23 1951 (Fig 1) and interpreted as follows ' There are extensive changes throughout the left lung which is considerably reduced in size The upper lobe shows numerous areas of rarefaction probably representing bronchiectatic cavities The area usually occupied by the lower lobe is nearly homogeneously dense Superimposed on the left lung area is the herniation of the right lung into the left chest The right middle lobe is probably collapsed The right lung shows rather diffuse increase in the markings with areas of emphysema in the costophrenic angle and at the apex In comparison with previous reports it is rather questionable as to whether there is any real change

From 1951 to 1954 he continued work and did not report to the clinic The present hemoptysis was the most severe he had ever experienced and it continued after admission with falling hemoglobin despite blood transfusions It was believed that there was now no alternative to operation and on the fifth hospital day left extrapleural pneumonectomy was performed under endobronchial gas oxygen ether anesthesia The patient received

Lung Abscess—Medical Aspects

S Aubrey Gittens M D and John P Mihaly M D *New York New York*

From the Medical Service of the Harlem Hospital New York New York

Lung abscess is a localized area of suppuration in lung tissue with or without cavitation and accompanied more or less by necrosis Pulmonary gangrene is a massive fulminating abscess differing from the latter in degree but not in kind While time is the most convenient factor in distinguishing acute from chronic abscess the dividing line is somewhat hazy Usually a duration of less than six weeks earmarks the abscess as acute A subacute abscess is one which has been present seven to twelve weeks and a duration of greater than twelve weeks is accepted as evidence of chronicity[1] One must not however be blinded by chronology in assessing the stage of disease in any given case Judgment must be based on the total clinical and radiologic picture and should be very critical since an abscess with chronic features cannot be cured medically

BACTERIOLOGY

By common concept lung abscess is a lesion caused by one or several species of pyogenic bacteria Extraordinary fungous acid fast and secondary invasion and a large variety of organisms can often be recovered from the sputum by proper bacteriologic technics Besides the ubiquitous streptococcal and staphylococcal floras the most notorious secondary invaders are the normal inhabitants of the oropharyngeal flora such as pneumococci Bacillus welchii fusiform bacilli oral spirochetes and other miscellaneous anaerobes Hemophilus influenzae Escherichia coli Bacillus tularensis and even Bacillus mallei (glanders bacillus)[2] have been recovered

When the infection is caused predominately by anaerobic organisms putrefactive necrosis acute lung abscess since it will not be encountered in aerobic infections of the lung with abscess formation

Lung abscess is definitely decreasing in incidence perhaps because of a more liberal administration of the various antibiotics early in the course of any infectious disease Thus potential suppuration in the lungs as elsewhere is usually aborted Higher nutritional standards and better oral hygiene are also contributing factors in reducing the number of cases

SITE

The right lung is more frequently involved than the left perhaps because of the more vertical course of the right main bronchus In our studies at the Harlem Hospital the right lung was involved in 70 per cent of the cases[3] In spite of previously accepted belief the lower lobes are not the most common sites Although over 50 per cent of the aspirational abscesses are located in the apices of the lower lobes[4] we have found acute abscess from all causes to be equally distributed between upper and lower lobes Some authors moreover have found the upper lobes to be far more common sites of abscess formation[5] These findings may be explained by the greater accessibility of the upper lobe bronchi to aspirated material when the body is in the supine or lateral recumbent position as in sleep or unconscious states

PATHOGENESIS

A study of the pathogenesis is not merely academic but will inevitably shed a revealing light on the best possible treatment A mere suppression of pyogenic activity by antibiotics is self delusory where underlying causes have not been detected and removed so as to prevent their recurrence The following modes of

pathogenic evolution are recognized and presented in approximate order of frequency

Aspirational Inhalational : Because of the nature of this type of abscess it always communicates with a bronchus although such communication may be temporarily obliterated by bronchial occlusion Aspirational abscesses

dental and oropharyngeal surgery is particularly prone to complication by acute lung abscess any type of surgery far removed from the upper respiratory passages may be responsible as a result of the accompanying deep anesthesia Regurgitation of gastric contents is likely to cause very destructive necrosis because of the digestive enzymes and acid content of the gastric juice Cardiospasm and esophageal overflow are occasional factors [6,7] Frequently concealed by the patient are such predisposing causes as unconsciousness following an altercation or electroshock therapy [8] Foreign body inhalation especially in children and water aspiration particularly sea water may be responsible

Neoplastic Secondary infection in pulmonary tumors particularly carcinomas is not an infrequent finding Necrosis and suppuration may involve the primary growth *per se* More common is suppuration in atelectatic lung distal to the neoplasm The bronchial obstruction caused by neoplasms interferes with adequate drainage and with other defensive pulmonary dynamics allowing a nidus of organisms to flourish in the secretions which have collected distal to the obstruction Other patterns of spillage are possible as described by Brock [9] Carcinoma should always be considered as a ranking possibility as a cause of lung abscess in an individual over forty years of age An intensive and persistent diagnostic search must be made in every case to rule out carcinoma as the primary cause in spite of preliminary negative data

Postpneumonic Some types of pneumonia

in its early stages to make the distinction between this type of boggy pneumonitis and pulmonary suppuration extremely difficult With inadequate therapy it may fail to resolve and proceed to frank abscess formation Small abscesses are encountered early in the course of staphylococcic pneumonia Streptococcal pneumonias are usually suppurative from the onset Lung abscess secondary to pneumococcic pneumonia is rare except in infancy and senility

Traumatic Penetrating wounds of the thorax open an obvious route for pyogenic infection of lung tissue However closed injuries due to direct or contra coup blows may result in secondary infection of intrathoracic hematomas which act as excellent culture media for organisms which may have been aspirated concomitantly or subsequently or which may have been circulating in the blood stream One should not overlook the possibility of abscess merely because an open chest wound has not been demonstrated

Direct Extension from Adjacent Organs The most frequent primary foci of such invasion are pyogenic infections of the esophagus spine and subphrenic abscesses While empyema is not an infrequent complication of acute lung abscess it must not be overlooked that the reverse can also occur

Septic Embolism Since blood from all parts of the body must be necessarily funneled through the pulmonary circuit septic emboli arising from any focus in the body will be filtered through the vascular bed of the lungs Abscesses of embolic origin tend to be multiple [4] and are often associated with infarct formation Septic thrombophlebitis of the lower extremities is a very common primary focus

Miscellaneous Multiple small abscesses are not infrequent late in the course of chronic bronchiectasis and may coalesce to form a large acute abscess Various types of localized pulmonary disease such as atelectasis fibrosis secondary to granulomatous disease and chronic non specific pneumonitis may occasionally flare up in acute abscess formation Secondary suppuration may arise in bland pulmonary infarcts occurring on a cardiac or some other non infectious basis [10] Lung abscess secondary to skin trauma has also been described [1]

COMPLICATIONS

Complications may be divided into those caused by the rampage of the abscess and those

rise to daughter abscesses in ipsilateral or contralateral lung, (2) rupture of abscess into the interlobar fissure or pleural cavity, causing localized or generalized empyema, (3) rupture both into bronchial tree and pleural space, causing bronchopleural fistula and pyopneumothorax, (4) erosion of blood vessels, especially bronchial arteries, causing hemorrhage,[16] and (5) metastatic implantation of infectious material into other organs, particularly the brain In the second category are (1) lapse of an acute abscess into chronicity, (2) residual bronchiectasis remaining as a focus for future suppuration, and (3) extensive fibrosis, resulting in the clinical syndrome of pulmonary fibrosis and emphysema and causing an embarrassed pulmonary circulation and ventilatory crippling

Medical management in most of the foregoing complicating features of lung abscess can rightfully be confined only to optimal preparation for adequate surgery

TREATMENT

Before the advent of the antibiotics and more precise methods of physiologic evaluation, medical management was largely of a palliative character In a large number of cases, as high as 40 to 60 per cent in some series, the process lapsed into chronicity, became complicated and ended as a surgical problem [3] Volatile oil inhalations, vaccines, intravenous alcohol and x ray therapy were tried, but proved of little value Arsenicals were given where spirochetes were recovered, and potassium iodide when fungi were demonstrated, but both these classes of organisms were usually only secondary invaders Recovery was obtained with such measures alone in a substantial number of cases, yet as high as 35 per cent of these patients terminated fatally while apparently recovering Lung abscess was therefore considered a "surgical disease" from the onset, external drainage being the treatment of choice, since resectional surgery had not yet come of age The antibiotics, however, brought changing concepts of treatment. It is true that uniformity of results and unanimity of opinion [illegible] the pendulum [illegible] lief that acute [illegible] s primarily a [illegible]

Successful medical management depends on (1) prompt and adequate antibiotic therapy, (2) postural drainage and other ancillary supportive measures, (3) recognition and amelioration of coexisting medical and psychologic diseases, (4) marginal minor surgical procedures, and (5) early recognition of cases in which major surgery is indicated at the outset.

ANTIBIOTIC THERAPY

Sulfonamides The sulfonamides, particularly sulfadiazine, altered the therapeutic approach somewhat, but because of their relatively narrow antimicrobial spectrum they produced no astonishing results [12 13]

Penicillin From the first studies with penicillin it was soon apparent that this was *an invaluable drug in the treatment of pulmonary suppuration* [14] It still remains as the *mainstay of antibiotic therapy in acute lung abscess* Its particular efficacy no doubt relates *to the predominantly gram-positive microorganisms* and oral spirochetes of the oropharyngeal flora which are the chief primary pathogens responsible for the average case of acute lung abscess We believe that, preferably but not obligatorily, with complementary sulfadiazine it will produce as satisfactory a result in acute lung abscess as any other single antibiotic The following principles must be heeded in treating acute lung abscess with penicillin (1) the pathogens must be identified and known to be sensitive, (2) early and vigorous treatment is indicated, with doses significantly exceeding those commonly used for the majority of other infectious diseases, (3) treatment must be sufficiently prolonged since the cure time of lung abscess is longer than that encountered with other pyogenic infections, and (4) better results are obtained with *aerobic than with anaerobic abscesses* The dosage schedule we employ at the Harlem Hospital is 600,000 units of procaine-penicillin G intramuscularly every six hours until the patient is clinically well, then twice daily until there is complete radiologic resolution of the lesion with only residual minor irreversible fibrotic changes When sulfadiazine is used in combination with penicillin, we use a dose of 1 gm every four hours.

Penicillin G diethylaminoethyl ester hydriodide (neo-penil®) has been recommended in the treatment of pulmonary infections sus-

ceptible to penicillin, since greater lung tissue and sputum levels are reached with this compound than with penicillin salts, including procaine penicillin We have not used this preparation at the Harlem Hospital and are not aware of any controlled studies in acute lung abscess which have demonstrated the unequivocal superiority of this ester over procaine-penicillin By the same token a definite role in the treatment of acute lung abscess has not been shown for dibenzyl ethylenediamine dipenicillin G (bicillin®), which produces a two- to four-week therapeutic blood level

We have not encountered any hypersensitivity reactions to parenteral penicillin in any of our cases In view of the known increased frequency of such reaction, however, we are aware that therapeutic concepts may change in the near future, at least to the extent of obligatory sensitivity tests before initiating long-term penicillin therapy

Streptomycin and Dihydrostreptomycin These drugs, single and in combination, have done much to solve the problem of gram-negative organisms immune to all forms of penicillin. Many clinicians have substituted a penicillin-streptomycin regimen for penicillin and sulfadiazine Harter considers 100,000 units of penicillin every three hours and 1/2 gm of streptomycin every twelve hours a satisfactory regimen for the treatment of acute lung abscess[4] We have not used this combination at the Harlem Hospital because of the danger of masking a coexisting tuberculous infection Eighth cranial nerve involvement following prolonged streptomycin or dihydrostreptomycin therapy is always a real possibility and should be preceded by audiometric tests

Chloramphenicol (Chloromycetin®) Although this drug possesses a wide antimicrobial range, its potential danger of inducing blood dyscrasia interdicts its prolonged use without careful laboratory control It has been used successfully in chronic pulmonary suppuration[2] We have not used it in our cases

Tetracycline Derivatives *Chlortetracycline (aureomycin) and oxytetracycline (terramycin)* While these drugs have certain marked advantages, chiefly their incredibly broad range of antimicrobial activity and the ease of administration inherent in the oral route of medication, we have failed to note any dramatic response to either of them In a number of our cases we were successful in effecting a cure of an acute abscess with the cycline drugs in cases in which penicillin had apparently failed, but we believe it is not beyond the range of possibility that penicillin had made the job easier for the results later obtained with the tetracycline derivatives The obvious disadvantages of these drugs are their greater cost, the danger of emergence of pathogenic yeasts due to excessively thorough respiratory bacterial elimination, and the occurrence of tocopherol (vitamin K) deficiencies secondary to intestinal flora destruction The latter is particularly significant, as abscess cavities, particularly the putrid variety, are prone to bleed easily even in the absence of lowered blood vitamin K levels

We have used both aureomycin and terramycin in dosages of 250 mg every six hours until clinical cure is attained, then three times daily until complete radiologic clearing is seen. In two patients admitted in an advanced state of sepsis, we administered initial doses of 500 mg of terramycin in 5 per cent glucose intravenously concurrently with oral medication We believe this procedure to have been life-saving in these two cases

All things considered, it is believed best to reserve the tetracycline series for unusually stubborn cases in which penicillin has failed after an adequate trial period, or in those cases in which the causative organisms are demonstrated to be generically or individually immune to penicillin and for those cases which are extremely toxic An alternate approach in treatment would be the development of a basic penicillin regimen interrupted by brief periods of tetracycline derivative therapy, as suggested by Barach[5] This method ingeniously harnesses the natural antagonism of the bacterial groups, first allowing the gram-negative organisms to aid in the elimination of their gram-positive antagonists already belabored by penicillin, and then conquering the conquerors by the tetracyclines

Tetracycline (Tetracyn,® Achromycin®) and Erythromycin® These drugs are relative newcomers on the antibiotic scene and have not yet been properly evaluated for their specific activity in acute lung abscess Theoretically, at least, they should be of considerable usefulness in gram-positive coccal infections, particularly when hypersensitivity to other antibiotics exists Erythromycin is said to alter the intes-

tinal flora to a lesser extent than the other wide-spectrum antibiotics

POSTURAL DRAINAGE AND OTHER ANCILLARY MEASURES

Zeal over pharmacotherapy often obscures the need for the rigid enforcement of postural drainage, supportive therapy, good nursing care and such other special procedures as common sense will dictate There is little excuse for not instituting prompt postural drainage The optimal position can easily be determined from precise knowledge of bronchopulmonary segmental anatomy and the specialized radiologic technics, as tomography, which we are now able to employ in determining the exact location of a pulmonary lesion The duration and frequency of drainage must be decided on an individual basis and will depend on such factors as type of patient, coexisting diseases, facilities and convenience of the drainage position Massages or the use of vibratory apparatus over the abscess site will often serve to loosen thick mucus plugs Inhalation of tryptar® (Armour brand of trypsin) aerosol by nebulizer or aerosol mask, may liquefy tenacious sputum Gentle coughing exercises should also be taught to the patient Parenteral and oral vitamin therapy, liver, iron and other hemopoietics, high-protein high-calorie diets, careful attention to a well functioning alimentary tract, and prompt alleviation of distressing symptoms by palliative medication are all measures to be observed in a medical regimen Unfortunately, however, these measures are often left in the hands of a harassed nursing staff, taken for granted or inadequately stressed Repeated small transfusions of 250 to 300 cc of whole blood are often helpful in regaining lost ground, especially when a severe anemia has supervened In acute stages oxygen should be given by catheter, mask or tent to relieve respiratory embarrassment

The Chronic Chest Disease Service of the Harlem Hospital has every patient with acute lung abscess placed on a "supportive regimen" consisting of multivitamins, feosol and protein supplements daily In severe cases liver and iron is administered intramuscularly and 1,000 cc of amigen solution intravenously daily If the erythrocyte count is less than 3 million, transfusions are added in the early stages of the disease to correct promptly the acute anemia which is a common finding in cases with overwhelming toxicity

COEXISTING MEDICAL AND PSYCHOLOGIC DISEASES

A substantial number of patients with acute lung abscess admitted to hospitals unfortunately come from beyond the pale of accepted social standards In this category are met the underprivileged, undernourished, drug and alcohol addicted, and mentally subaverage Such people are frequently desperate, have poor insight and show impaired judgment The rate at which such patients leave the hospital against advice is high Of 105 cases of lung abscess admitted to the Harlem Hospital from April 1, 1949, to April, 1954, twenty left the hospital against advice as soon as there was some degree of clinical improvement Many of those who did remain to completion of therapy were periodic behavior problems In dealing with these patients, therefore, the greatest amount of tact, patience and understanding is required If facilities for psychiatric guidance are available, they should be promptly applied Since the average case of acute lung abscess will be hospitalized for approximately two months, some form of recreation or occupational therapy must be provided to maintain morale and optimal patient cooperation

Coexisting medical diseases, both predisposing and unrelated to the abscess, are extremely common Malnutrition, cardiac disease, neurologic disorders, chiefly epilepsy, thrombophlebitis and alcoholic syndromes including frank delirium tremens are the most common Of the twenty four deaths we have had in our series, twenty occurred in the presence of such diseases and four were due to overwhelming septicemia It is clear that a thorough medical evaluation in every case of acute lung abscess is mandatory and immediate therapy should be instituted for any recognized predisposing intercurrent or complicating disease which may exist

SUMMARY OF 105 CASES WITH SUPPURATIVE LUNG DISEASE

In twenty cases the pulmonary disease was secondary to some other fatal systemic disease In eight cases the lung disease was chronic and presented complications necessitating surgical management on admission Four cases of primary lung abscess were complicated by

overwhelming septicemia beyond help by medical treatment Seventy three cases of acute uncomplicated lung abscess were treated with antibiotics Of these twenty left the hospital against medical advice after being clinically improved but not cured Fifty three patients completed treatment and were cured medically Treatment in these cases was as follows terramycin fourteen cases aureomycin thirteen penicillin and sulfadiazine ten penicillin three penicillin then aureomycin four penicillin then terramycin seven streptomycin and terramycin combined one and penicillin then aureomycin and terramycin one

Before discharge from the hospital those patients who have been successfully treated should be instructed to avoid situations which were shown to have caused or precipitated the abscess A well organized social service can be of inestimable value here Periodic clinic follow up care is also essential after discharge from the hospital

MARGINAL MINOR SURGICAL PROCEDURES

In the field of chest diseases as in every other comparable field there is an overlapping area between pure medicine and definite surgery The dividing line will differ with individuals and institutions Some of the procedures in this twilight zone are chest taps pneumothorax enzymatic debridement and topical treatment The necessity of these measures will arise only when a relatively minor complication has occurred or a major one is threatening

Hemoptysis Minimal hemoptysis may be controlled by sedation and intravenous tocopherol calcium procaine or pituitrin or any rational combination of these Artificial pneumothorax and other forms of collapse and immobilization therapy are occasionally advocated for the closure of cavities responsible for massive hemorrhage but in general these measures have fallen into deserved disrepute because of the interference with free drainage which they produce

Empyema In loculated types of empyema complicating peripherally situated abscesses in which simple aspiration has proved to be of limited value enzymatic debridement by the intrapleural instillation of trypsin streptokinase streptodornase or vardase® (streptokinase streptodornase Lederle) may circumvent the necessity of external drainage In cases of pleural effusion whether suppurative or not aspiration should be followed by the intrapleural instillation of the antibiotics In the Harlem Hospital we routinely use 1 million units of aqueous penicillin and 5 gm of streptomycin in 100 cc of physiologic saline We have not encountered a hyperergic reaction but since this is possible especially when the enzymes are used we routinely antihistaminize patients before instilling antibiotics or enzymes into the pleural cavity

Pyopneumothorax Where pyopneumothorax is associated with a marked mediastinal shift and acute respiratory distress underwater drainage may be a life-saving measure In more severe cases, or when a ball valve mechanism is present the involved hemithorax may have to be kept under continuous negative pressure

Aerosol Therapy Aerosol therapy with the antibiotics particularly penicillin alone or in supplementation of oral or intramuscular modalities has met with much praise Lastlake believes that extirpation of even chronic abscesses may be avoided in many cases by aerosolized solutions of penicillin for at least one month after maximum benefit has been obtained from surgical drainage

Topical Treatment Topical treatment of lung abscess has been described by Burnett et al [19] whereby aspiration is performed under fluoroscopic guidance followed by the instillation of 100 000 units of penicillin and 1 gm of streptomycin in 1 to 5 cc of a wetting agent This treatment is supplemented by aerosol inhalations four times daily These authors stress however that this procedure should be attempted only by a qualified thoracic surgeon

SELECTION OF CASES FOR MAJOR SURGERY

It is not within the scope of this paper to evaluate the various surgical procedures used formerly or currently in the treatment of acute lung abscess Reference to this information may be found elsewhere in the literature [20] Nevertheless a statement of a few principles which have guided us in the selection of our cases is in order

Bronchoscopy Bronchoscopy should always be employed wherever the etiology of an acute abscess is obscure where the response to conservative therapy is slow or where a foreign body or malignant growth is suspected The value of a bronchoscopy is both diagnostic and therapeutic Bronchial washings obtained

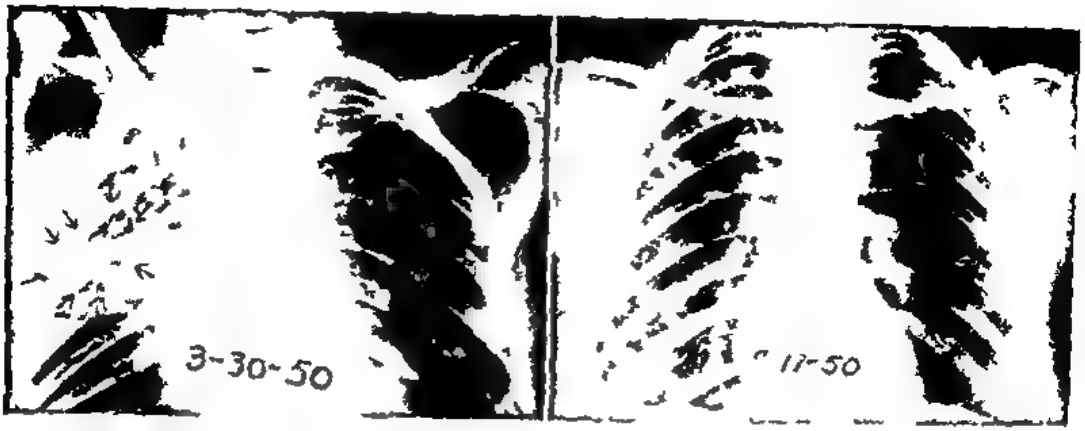

1 2

FIG 1 Shows a cavitary lesion with fluid level in a toxic extremely ill patient The abscess involved the entire right upper lobe

FIG 2 About six months later shows complete healing with minimal fibrotic scarring in the right infraclavicular zone

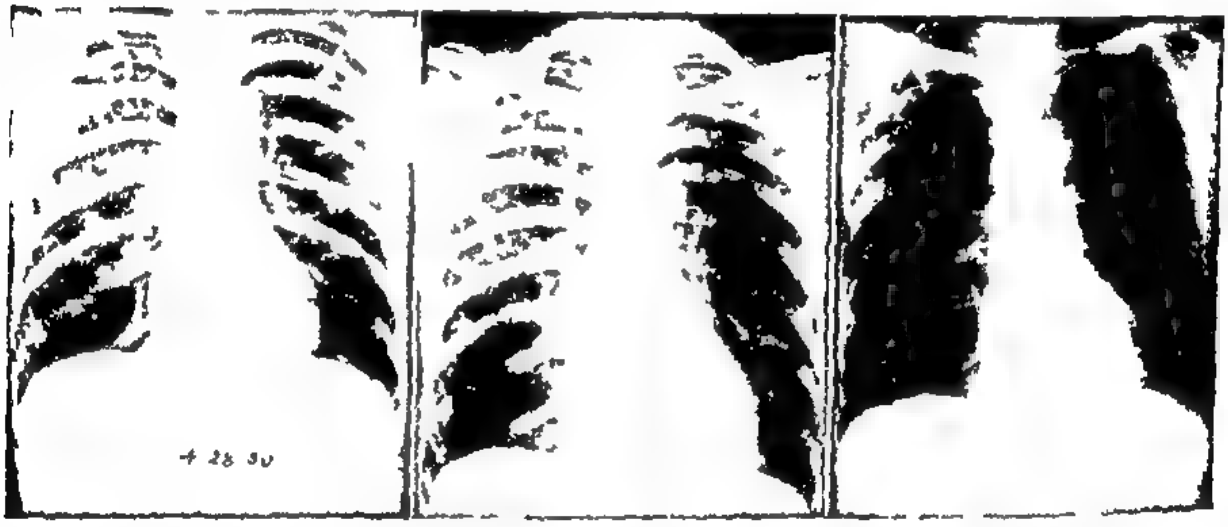

3 4 5

FIG 3 Shows an abscess in the dorsal segment of the right upper lobe There is a cavity with a fluid level

FIG 4 Six weeks later shows a marked reduction in the size of the lesion and of the cavity which still contains a fluid level

FIG 5 Taken several months after discharge shows the healed right upper lobe lesion with fibrotic changes in the right infraclavicular zone

by this procedure may be studied bacteriologically and cytologically, tissue biopsies may be obtained from suspicious areas and foreign bodies removed if present . Bronchial [illegible]

Surmonte, and Long[illegible] Rubin Goldstein and Rubin believe that bronchoscopy should never be omitted and that every patient should have at least one bronchoscopy in the course of treatment[8] We do not have our cases bronchoscoped routinely but insist on same whenever any of the foregoing indications exist

External Drainage In our view this should never be the surgical treatment of choice We reserve recommendation of this procedure only where a definite contraindication to excisional surgery exists In those cases however, in which external drainage is done it should never be performed through normal pulmonary tissue by way of artificially produced adhesions because of the danger of spread to normal collateral areas of lung unprotected by a defen

sive inflammatory reaction Moreover metastatic brain abscesses may follow since the venous channels are not closed by protective inflammatory thrombosis The pointing of the abscess must therefore be precisely localized and the drainage established through this site [21] If on entering the thorax it is seen that this site has been missed it is best to close the wound and re-enter the thorax at the proper site [4]

Resectional Surgery It is imperative that resection should remove the diseased area completely with a minimum sacrifice of healthy lung tissue [22] This is vital not only for immediate functional results but also because of the possibility of a later indication for resection for an unallied condition It is incumbent both on the surgeon and internist to determine exactly what the extent of the disease is Resection should be limited to lobectomy or preferably segmental resection

Pneumonectomy This radical step is rarely indicated for lung abscess It should be reserved only for those cases in which fairly good evidence exists that the underlying process is neoplastic in which extensive fibrosis has caused such mediastinal shifting that there is marked interference with cardiovascular dynamics or in which the diseased lung has undergone advanced damage while the pulmonary circulation has remained intact resulting in negligible oxygen intake in the diseased lung The latter condition produces a functional arteriovenous fistula and is demonstrable by proper pulmonary function tests

Even when a case has been earmarked for surgery whether from the very onset or at any time in its course sound medical management as indicated elsewhere in this paper must apply in order to render the patient an optimal risk for surgery

In our last published paper on acute lung abscess [3] we reported a series of thirty seven successfully treated patients Of these ten were treated with penicillin three with penicillin and sulfadiazine twelve with aureomycin six with terramycin four started on penicillin and completed with aureomycin and two started on penicillin and completed with terramycin We were unable to conclude that any single antibiotic or combination of antibiotics was distinctly superior to the others

Since that published series we have successfully treated sixteen more patients eight with terramycin one with aureomycin one with combined streptomycin and terramycin one started on penicillin and completed with aureomycin and terramycin and five started on penicillin and completed with terramycin We have deliberately varied the therapy in a persistent search for an optimal combination of antibiotics but are still unable to deviate from our previously held conclusions that none of these drugs holds a clear superiority over the others but that successful results depend on prompt and adequate treatment The clinical cure time still remains about twenty days and total cure time (clinical plus radiologic) about two months Our only adverse criticism with regard to penicillin is the necessity for its intramuscular administration This however is greatly outweighed by its negligible cost

The accompanying reproductions of chest [illegible] our results [illegible] 1 to 5 rep [illegible] results in the fifty three cases of uncomplicated acute lung abscess which we treated and cured medically between the period April 1949 and April 1954

CONCLUSIONS

[illegible]

role of surgery in chronic cases and those early cases with complications must be clearly recognized In this type of case the joint efforts of the internist and the surgeon as a team provides the best results Further that the number of patients requiring surgery will become increasingly smaller if prompt and adequate antibiotic and ancillary medical measures are instituted early in the course of acute suppurative disease of a primary nature

REFERENCES

1 NEUHOF H TOUROFF A S W and AUFSES A H Surgical treatment by drainage of subacute and chronic abscess of the lung *Ann Surg* 113 209 1941

2 HOWE C and MILLER W R Human glanders report of six cases *Ann Int Med* 26 93 1947

3 GITTENS S A and MIGALY J P Medical management of acute lung abscess *Am Rev Tuberc* 69 5 1954

4 H [illegible]

5 C [illegible]

6 VINSON, P [illegible] Cardiospasm complicated by pulmonary abscess, case report *Am J Surg*, 2 359 1927
7 HAWES, L E and SOULE, A [illegible] Pulmonary changes in cardiospasm *Am J Roentgenol*, 53 124, 1945
8 RUBIN E. H, GOLDSTINE, S A and RUBIN, M. Management of non tuberculous bronchopulmonary suppurations *M Clin North America*, 33 391, 1949
9 BROCK, R C Studies in lung abscess lung abscess and bronchial carcinoma *Guy's Hosp Rep*, 97 75, 1948
10 LEVIN, L KERNOHAN, J W and MOERSCH, H J Pulmonary abscess secondary to bland pulmonary infarction *Dis of Chest* 14 218 1948
11 SCHWARTZ J Staphylococcus abscess due to trauma of skin *J Mt Sinai Hosp*, 12 637, 1945
12 STIVELMAN, B P and KAVEE, J Penicillin in the treatment of putrid lung abscess *Arch Int Med*, 25 66 1946
13 SNOOK, R R Aspiration pneumonia with beginning lung abscess treated with penicillin *J Kansas M Soc*, 46 40 1945
14 ROBERTS, J E H, TREBBS, O S and BATES, M Pleural and pulmonary suppuration treated with penicillin *Lancet*, 1 39 1945
15 BARACH A A Remissions in bronchial asthma and hypertrophic pulmonary emphysema *J A M A*, 147 8, 1951
16 [illegible]
17 [illegible]
abscess *Am J Med*, 8 263 1950
18 EASTLAKE, C., JR Aerosol therapy in sinusitis bronchiectasis, and lung abscess *Bull New York Acad Med*, 26 423 1950
19 BURNETT, W E, ROSEMOND G P CASWELL, H T, HALL, J J and BUCHER R M The topical treatment of lung abscess *Pennsylvania M J*, 52 719, 1949
20 NEUHOF, H and TOUROFF, S S W Acute putrid abscess of lung surgical treatments and results in eighty six consecutive cases *J Thoracic Surg* 9 439 1949
21 CHAMBERLAIN J M and FINNERTY, J J Modern technics in thoracic surgery *S Clin North America*, 29 557, 1949
22 NACLERIO, E A and HOCHBERG, L A Segmental resection in pulmonary surgery *Am J Surg*, 79 488, 1950
23 HARRIS, M S, CORNELL, L, SHORE, C and LOVITZ, H Chloramphenicol in the control of bronchopulmonary suppuration *Dis of Chest*, 21 4 1952
24 MILLER J, SURMONTE, J and LONG, P The intrabronchial use of streptokinase and streptodornase in the treatment of slowly resolving pneumonia *Dis of Chest*, 23 2, 1953

Lung Abscess—A Medicosurgical Problem

David H Waterman, M D, Sheldon E Domm, M D and William K Rogers, M D,
Knoxville, Tennessee

From the Thoracic Surgical Services of Fort Sanders Presbyterian Hospital and Knoxville General Hospital, Knoxville Tenn

Three fallacies concerning lung abscess would seem to be currently present in the minds of many physicians The first of these is that lung abscess has become so rare a disease that it is no longer of importance The second is that medical treatment alone suffices in practically all of the few cases that are encountered The third is that resection is the only surgical procedure to be considered in the remaining cases Actually there is some basis of fact for each of these concepts, they are erroneous simply because they are carried too far

Regarding the first of these, it must be remembered that the etiologic factors producing lung abscess, such as dental sepsis, aspiration of vomitus or other infective material, and various types of bronchial block have not been eliminated by antibiotics Earlier treatment of the resulting pulmonary infections with the antibiotics however, and the wider acceptance of prompt bronchoscopy certainly should result in fewer abscesses Nevertheless a review of our own figures shows we are still encountering as many cases of lung abscess and suppurative pneumonia as we did in the early forties For example, in the past two years we have treated over fifty cases In a recent article Gittens and Mihaly[1] have reported thirty-seven abscesses in the acute uncomplicated category alone at the Harlem Hospital from April, 1949 to April, 1953 Figures from other thoracic clinics give further evidence that the problem has by no means been eliminated

That the wide-spectrum antibiotics have mitigated the severity of lung abscess and suppurative pneumonia is undeniably true The highly toxic, desperately ill lung abscess patient is now rarely rather than commonly seen The entire therapy picture is materially brighter than the complicated one of a relatively few years ago when the frequently quoted figures of Allen and Blackman,[2] and Smith[3] showed over 34 per cent mortality in a combined collective series of 4 280 cases

In 1952 the authors[4] analyzed 218 cases of lung abscess and suppurative pneumonia personally treated Of these, 134 cases were treated by conservative measures consisting of bronchoscopy and antibiotics Good results were obtained in 77 per cent of the seventy-four seen in the postantibiotic era, in contrast to 63 3 per cent of the sixty seen in the preantibiotic period Significantly there was a marked drop in mortality from 23 3 per cent in the preantibiotic era to 4 per cent in the postantibiotic It should be pointed out that these are completely unselected figures and represent all cases which were treated, whether acute, subacute or chronic

[illegible]

plicated abscesses seen early in the course of the disease were included, the results were uniformly excellent without surgery Stivelman and Kavee[5] presented a similarly optimistic picture in 1949 While our own experience in the majority of such cases closely parallels this, it must be borne in mind that in actual practice not all abscesses are seen early in the acute stage, nor are these responsive to medical treatment alone in all cases We have had occasion to observe several acute abscesses in the past few years that were rapidly fulminating in spite of massive combined antibiotic therapy We are also encountering abscesses presenting a bacterial flora resistant to almost all antibiotics

While our over all mortality since antibiotics have been used has been gratifyingly low, we have actually seen no decrease but rather an increase in the number of cases coming to surgery Probably this is due to the effect of antibiotics in relieving symptoms and obscuring diagnosis so that more abscesses progress to the chronic stage Once an abscess

is chronic or complicated, with permanent parenchymal and bronchial damage resulting, the golden opportunity for medical therapy is already passed

As to the third fallacy, the published figures on resection of chronic abscess, such as those

TABLE 1

Lesion	No of Cases	Per cent
1 Lung abscess and suppurative pneumonia	268	57 8
2 Carcinoma with secondary suppuration	187	40 3
3 Adenoma with secondary suppuration	3	0 6
4 Embolic abscess with pyemia	6	1 3
Totals	464	100 0

of Shaw and Paulson[6] with only 3 8 per cent mortality in fifty-two cases have been so favorable that many physicians have assumed that no place remains for other types of surgical therapy Admittedly the indications for open drainage are markedly narrowed by the efficacy of conservative therapy on the one hand, and the improved mortality of resection on the other Most recent surgical contributors, however, such as Byron[7] and Cowley,[8] utilize surgical drainage not infrequently Bad risk patients, for example, constitute a rather sizable group and frequently can be salvaged by this procedure Physicians should not have to be reminded that surgical drainage of suppuration is still a valid principle

MEDICOSURGICAL MANAGEMENT

Numerous surgical writers, such as Glover and Clagett,[9] and Klepser and Davis[10] have expressed the viewpoint that lung abscess is a surgical problem from the outset While we entirely subscribe to such a dictum in the strict sense, it is perhaps more politic to state that lung abscess is a medicosurgical problem

From 1941 to the present time 464 cases of abscess or suppurative pneumonia have come under our cognizance This number does not include cases of mycotic infection, bronchiectasis or tuberculosis, but does include those cases associated with malignant disease in order to show the increasing role carcinoma plays as an etiologic agent Table 1 is the breakdown of these cases and shows that carcinoma with secondary suppuration contributes 40 3 per cent to the total

With bronchogenic carcinoma on the increase it can be predicted that an even greater incidence will be encountered Thus it would seem mandatory that every case of lung abscess, whether acute or chronic, be carefully investigated for malignant background, a viewpoint shared by Brock[11] and Strang and Simpson[12]

It has been our good fortune to be able to apply either conservative or surgical therapy as we saw fit in most of the cases in our series In a high percentage of these it has not been necessary to resort to surgical measures other than bronchoscopy Therefore we do not believe that our figures are weighted in favor of either medical or surgical treatment

It is the purpose of this report to outline the regimen that has proved the most efficacious in our hands in treating the remaining 268 cases listed in the first line of Table 1 Roughly 70 per cent of these were putrid and 30 per cent non putrid For the purposes of discussion the steps in management are listed under the following headings

1 *Preliminary Work up* The prompt evaluation of each patient after he is admitted to the hospital will, in the majority of instances permit application of rational therapy from the outset The importance of a careful history bearing in mind the possibility of bronchogenic carcinoma as an etiologic agent need not be emphasized Physical examination must be thorough Six-foot erect postero-anterior and lateral x rays will give the exact size and segmental location of the lesion Almost one-third of these cases will not show the characteristic fluid level due to bronchial block In addition to the routine laboratory work a packed cell volume determination may be of advantage The sputum is examined on admission for acid fast bacilli, but cultures and smears for other organisms are not done at this time in view of the well known contamination by mouth organisms and the consequent superiority of a bronchoscopic specimen The appearance and odor of the sputum are noted—the use of a glass container permits ready inspection—and the volume is recorded daily Day and night temperatures are kept of course

Routine administration of antibiotics is not begun on admission except in the rare instance when extreme toxicity makes this imperative

2 *Bronchoscopy* In our opinion every case of lung abscess or suppurative pneumonia demands bronchoscopy within the first twenty four hours The procedure is so simple and so fruitful that it is difficult to see why any physician should hesitate to apply it promptly or why some writers would seem to show a lack of enthusiasm for the procedure We have never seen a patient with lung abscess or suppurative pneumonia who was too ill to be bronchoscoped, although we have seen many too ill to permit any delay in performing the procedure

by lung abscess are sufficiently advanced to permit diagnosis via the bronchoscope In addition to ruling out other pathologic disorder, valuable information is gained regarding the suppurative process, in that the inflammatory reaction can be localized and correlated with the x ray findings and the bronchial reaction and block factors evaluated Fox, Hughes, and Sutliff[13] also emphasize that diagnostic bronchoscopy is essential

A second important function of bronchoscopy, related to the first, is the collection of bronchial secretions uncontaminated by mouth organisms for laboratory study In addition to the routine smears, aerobic and anaerobic cultures tuberculosis smears and cultures and fungus cultures it has been our practice in all of our abscesses to order sensitivity studies for antibiotics because of the disturbing frequency with which we are encountering cases presenting a bacterial flora resistant to almost all the available chemotherapeutic agents This resistance may not necessarily correlate with previous antibiotic administration in the individual In recent months we have found a surprising number of infections sensitive only to chloromycetin,[9] and have postulated that this may be due to the more restricted use of this agent by the average physician following the reports of complications after prolonged administration As Hewitt[14] has pointed out the bacteriostatic and bacteriocidal specificity of the antibiotics has made clear the necessity for more, rather than less specific bacteriologic diagnosis if proper treatment is to be applied

From a therapeutic standpoint bronchoscopy has long been advocated as an essential prerequisite to effective conservative management An infection in the lung is like any other infection in that it must drain adequately if it is to clear A competently performed bronchoscopy with thorough systematic aspiration of all branch bronchi, particularly in the affected segments, will promote bronchial drainage as will no other measure Anyone who has repeatedly observed via the bronchoscope the typical angry, swollen bronchial mucous membrane can well understand how this bronchial drainage cannot be achieved without mechanical help An efficient bronchoscopy evacuates accumulated and obstructing bronchial secretions (even to the extent of actually mechanically opening the lung abscess in some cases), permits shrinking of the mucous membrane by topical application, thus relieving further

usually manifested within the first few days or even the first few hours, and may be very dramatic As a rule the patient begins to raise secretions effectively in large amounts often when little was produced before The odor of the sputum may even disappear overnight, as the anaerobes diminish with effective drainage of the abscess Cough is increased the first day or two following the bronchoscopy, if it is well performed, but diminishes as the sputum volume begins to decrease The temperature usually falls, sometimes precipitously, and the patient exhibits evidence of reduced toxicity and increased well-being Bronchoscopy need not be repeated in the average case more often than every week or ten days, as the beneficial effect should last about this period of time In our opinion more frequent bronchoscopy is rarely necessary and frequently is harmful Often only a single bronchoscopy is necessary, but if the salutary effects are not observed fairly promptly the patient is rebronchoscoped several days later If improvement does not

thoracic surgeon to contribute an important phase of therapy in lung abscess Bronchoscopy is not a definitive treatment in itself

Various authors have advocated the instilla

tion of antibiotic agents directly through the bronchoscope, but our results with aerosol antibiotics have been so satisfactory that we have resorted to direct instillation only infrequently

3 *Postural Drainage* Immediately following the bronchoscopy the patient is placed on a postural drainage regimen four times a day, or more often if there are profuse secretions It is our practice to use an expectorant such

then takes his postural drainage and coughs vigorously in the position for two or three minutes It must be emphasized that postural drainage should be individualized, as incorrect postural drainage may do more harm than good Postural drainage by definition is that position which most effectively aids drainage In a middle lobe for example, the patient should lie flat on his back In lower lobes the position is well down over the bed as near vertically as possible In upper lobes the patient may either lie on his face or his back or sit upright, depending upon the segment involved After the individualized position has brought the secretion to the main bronchus, the head down position may be used briefly to advantage Experimentation will find the most effective position or combination of positions This routine should then be carefully demonstrated and supervised so that it may be utilized effectively Postural drainage should be continued as long as the abscess persists even if the patient's sputum drops to an almost negligible amount The dryer the patient's lung can be kept, the quicker will be his recovery

4 *Antibiotics* Once bronchoscopy making possible bronchial drainage, has been done and the bronchial secretions obtained for laboratory study, the vigorous administration of antibiotics is begun Until the laboratory studies provide accurate direction to antibiotic therapy, the most satisfactory agent for immediate use is penicillin This has been the most effective antibiotic in our hands, and we agree with Hewitt that the aqueous preparations of penicillin, such as penicillin G potassium, are superior to the repository ones during the initial phase of therapy Lung abscess is potentially highly dangerous, and penicillin in bacteriocidal doses is warranted We administer 100,000 to 300,000 units every three hours, using the hypoallergic preparations if indicated Frequently we use procaine penicillin at bedtime, however, so that the patient may have uninterrupted rest

Penicillin is also administered by the aerosol route in doses of 25,000 to 50,000 units every three hours during the day for three or four days following the bronchoscopy A broncho-relaxing drug, such as neo-synephrine,® vaponefrin,® isuprel,® or prothricin,® providing a shrinking agent plus tyrothricin, is added to each inhalation This usually results in rapid improvement in the severe inflammatory bronchial reaction so typical of lung abscess We have now had a wide experience in the use of such aerosol antibiotics after bronchoscopy in some 4,000 cases of bronchial and pulmonary infection and have been particularly enthusiastic about the results in our lung abscess group We have found the penicillin aerosol much superior to penicillin dust Terramycin® is the only other antibiotic we have found advantageous by the aerosol route Trypsin inhalations, however, may aid greatly in liquefying secretions

As soon as the sensitivity studies are reported, usually within the first few days of treatment, the antibiotic therapy is modified as indicated Actually the use of sensitivity studies has simplified rather than complicated the treatment of infection, as the antibiotic of maximum effectiveness can thus be chosen without experimentation

The physician should be constantly aware that the antibiotic initially used may so change the bacterial flora as to become ineffective This is usually manifested by a reversal in response to therapy or by an actual increase of the suppurative process on x ray When such change occurs we usually rebronchoscope the patient and obtain additional bacteriologic cultures and sensitivity studies Fortunately a large number of antibiotics are now available for alternative therapy

Should the patient develop sudden dyspnea and chest pain, the physician must be alert to the possibility of rupture of the abscess into the pleural cavity and should drain the resulting empyema as an emergency procedure Not infrequently the abscess may go on to healing once the pleural cavity drainage is provided

5 *X-rays* Weekly x-rays in the erect postero-anterior and lateral positions are the best guide to the real progress of the case

Unless there is definite x-ray improvement at weekly intervals, surgical intervention should [illegible] one in lung abscess, and procrastination may cost the life of the patient [illegible] of the resection Frequently minor bron- [illegible] bronchography have been noted in our series

6 *Open Drainage* Three indications still are present for open drainage The first of these is the occasional fulminating acute abscess that fails to respond to conservative treatment with bronchoscopy and antibiotics and which must be drained as a life saving measure These are rare cases, but are just as much a problem in therapy as they were in the preantibiotic era

The second indication is in the patient either too old or too ill to be safely resected Attendant heart disease, for example, or another serious lesion elsewhere may make the patient too severe a risk to undergo extirpation surgery Occasionally the relatively easy procedure of open drainage may be more practical in civilian or military situations in which the experience of the surgeon, the available hospital or anesthesia facilities render resection a hazardous undertaking

The third indication is the solitary uncomplicated acute abscess peripherally located in which a good result from drainage can be anticipated, even though resection surgery would be entirely feasible from a risk standpoint Open drainage is a simple procedure and is less risky than major thoracotomy Neuhof, Touroff and their associates[16, 19] demonstrated before our present antibiotics were available that open drainage carried only a 2 43 per cent mortality in a large series of acute lung abscesses With antibiotics this should be even less

It should also be pointed out that resection implies loss of lung tissue, whereas open drainage may conserve it Since the majority of acute cases will respond to conservative therapy, however, there will be few cases encountered, even at best, in which open drainage is desirable It has long been recognized that chronic abscess is rarely suitable for drainage, except as a palliative procedure, and is always an indication for resection in the reasonable risk patient Generally speaking, good results in open drainage will be in direct proportion to the age of the abscess It might also be mentioned that open drainage does not preclude later resection

As to technic, a single stage drainage procedure under local anesthesia can almost always be applied If pleural symphysis is not present, the visceral pleura may be sutured to the parietal before the latter is open We have done this for a number of years without encountering the complication of empyema In the majority of cases, however, the cone of adhesions present is adequate If the abscess has been accurately localized on 6 foot postero-anterior and lateral films, it is possible to resect a small piece of rib directly over the abscess and enter it with little difficulty We believe that abscesses heal concentrically, and hence place the tube in the center rather than at the bottom of the abscess The abscess is packed with washed iodoform gauze brought out through the large rubber drainage tube, and repacked daily until all slough is removed and the abscess cavity reduces in size satisfactorily The tube is not removed until the abscess is completely obliterated Cultures taken directly from the abscess guide therapy if an antibiotic is indicated Routine biopsy of the abscess wall may reveal unsuspected carcinoma or tuberculosis With the protection afforded by antibiotics at the present time, it is frequently possible to discharge the patient from the hospital soon after operation and continue dressings at the surgeon's office This may effect considerable financial savings for the patient

7 *Resection Therapy* Once an abscess has become complicated or has persisted over a period of several weeks beyond the acute stage, permanent pulmonary damage results and resection therapy is indicated The most signal advance in recent years has been the reduction in surgical mortality in resection from the previous appallingly high figure of the preantibiotic era to a respectable one of below 5 per cent in most series In our own experience of fifty-one cases resected since the advent of antibiotics the mortality has been 1 9 per cent This is in sharp contrast to our 28 6 per cent mortality before antibiotics were used The safety with which resection therapy

can now be performed under antibiotic cover age has made it possible to salvage a high per centage of patients who once remained either chronic or who succumbed to their disease

Cowley[8] has mentioned brisk hemorrhage as an indication for surgical intervention In our own experience we have not had occasion to resort to *resection* in such an instance but would not hesitate to do so if the need should arise

It has been our custom to prepare these patients for resection with intensive intra muscular penicillin for two or three days before operation and with aerosol penicillin pre-scribed concurrently to temporarily sterilize the bronchial tree If the sensitivity studies have indicated that another antibiotic is more effective it is of course substituted As men tioned previously most of these patients who come to surgery have already had bronchog raphy so definitive surgery can be well planned

Individual ligation technic is superior to wedge resection in most cases of lung abscess In order to preserve all lung tissue possible segmental resection is applied whenever pos sible In spite of the fact that air leaks are more common with segmental technic we have found it possible to obliterate the residual space rapidly with vigorous active suction and thus avoid the complication of empyema Empyema is also relatively rare when the entire lobe is removed inasmuch as the remaining lobe or lobes can be left with few air leaks and speedily expand to fill the space

Empyema remains a grave problem particu larly in pneumonectomy We have had an incidence of almost 50 per cent, as have Glover and Clagett[9] Because of this high figure we strongly believe that a relaxing type of thoraco plasty should be performed rather promptly following the pneumonectomy To prevent scoliosis the first rib is usually left in place Once bronchopleural fistulas and empyema have developed however the situation is enormously complicated as multiple stage thoracoplasties may fail to obliterate the space and close the fistulas

In 1950 Holman[20] reported a technic whereby chronic lung abscesses could be peeled out of the parenchyma without sacrificing the entire lobe or segment As in a previous report we continue to be interested in this method of resection and consider it a meritorious con tribution Those surgeons who have had the experience of enucleating tuberculous nodules from the lung will find the technic equally applicable in abscess

8 *Final Evaluation* A lung abscess case should be followed carefully, whether his treatment be conservative or surgical until it is certain no residual damage remains and the original lung abscess cavity has been com pletely obliterated We believe that it is mandatory that a bronchogram be taken in all cases of conservative or drainage therapy Touroff Nabatoff and Neuhof[21] by carefully evaluating their large drainage series found 13 4 per cent had some residual change Our experience has been comparable When appre ciable parenchymal or bronchial damage has been demonstrated by the bronchogram elec tive resection is considered

SUMMARY AND CONCLUSIONS

1 Three fallacies currently persist regard ng lung abscess (a) that it is now so rare as to be unimportant (b) that antibiotics alone suff ce as therapy and (c) that resection is the only surgical measure of value

2 Bronchogenic carcinoma is an increas ingly common cause of lung abscess and should be considered as the etiologic agent in every case Forty per cent of a total of 464 cases were malignant

3 Based on the authors experience with 268 cases of lung abscess and suppurative pneumonia of non malignant etiology a reg men of medicosurgical management is outl ned

4 A careful preliminary work up serves as a guide for rational therapy

5 Bronchoscopy is indispensable in lung abscess and should be applied early both for diagnosis and therapy Bronchial secretions obtained at bronchoscopy provide accurate and essential bacteriologic data The limitations of bronchoscopy must be recognized inasmuch as it is not a definitive treatment

6 Postural drainage correctly applied is an essential supplement to bronchoscopy in con servative therapy

7 Antibiotics have changed the entire picture for the better They should be appl ed logic

both parenterally and by the aerosol route

8 Weekly x rays are the most accurate

indication of progress A stationary or retrogressive course demands re evaluation of therapy and consideration of surgery

9 Open drainage may still be applied in the fulminating abscess the poor risk patient and in the simple uncomplicated acute abscess in which a good result can be anticipated

10 Resection with antibiotic coverage has reduced the mortality in chronic abscess to a respectably low figure of 1 9 per cent in the reported series of fifty one cases Conservation of lung tissue is important and lobectomy and segmental resection are greatly superior to pneumonectomy The incidence of empyema in pneumonectomy remains far too high

11 Careful follow up of all cases of lung abscess and suppurative pneumonia is imperative Bronchography is usually indicated Resection should be considered if appreciable damage persists

REFERENCES

1 GITTENS S A and MIHALY J P Medical management of acute lung abscess *Am Rev Tuberc* 69 673 1954

2 ALLEN C I and BLACKMAN J F Treatment of lung abscess with report of 100 consecutive cases *J Thoracic Surg* 6 156 1936

3 SMITH D T Medical treatment of acute and chronic pulmonary abscesses *J Thoracic Surg* 17 72 1949

4 WATERMAN D H and DOWN S E Changing trends in the treatment of lung abscess *Dis of Chest* 25 40 1954

5 STIVELMAN B P and KAVEE J Treatment of acute putrid lung abscess with penicillin and sulfadiazine *Ann Int Med* 38 343 1949

6 SHAW R R and PALLSON D L Pulmonary resection for chronic abscess of the lung *J Thoracic Surg* 17 514 1948

7 BYRON F X The management of abscess of the lung *California Med* 76 325 1952

8 COWLEY R A The treatment of pulmonary abscess *Maryland State M J* 2 593 1953

9 GLOVER R P and CLAGETT O T Pulmonary resection for abscess of the lung *Surg , Gynec & Obst* 86 385 1948

10 KLEPSER R G and DAVIS E W The surgical management of lung abscess *Dis of Chest* 17 172 1950

11 BROCK R C Studies in lung abscess *Guy s Hosp Rep* 97 75 1948

12 STRANG C and SIMPSON J A Carcinomatous abscess of the lung *Thorax* 8 11 1953

13 FOX J K JR. HUGHES F A JR and SUTLIFF W D Nonspecific lung abscess experience with fifty five consecutive cases *J Thoracic Surg* 27 255 1954

14 HEWITT W L Antibiotic therapy of abscess of the lung and bronchiectasis *California Med* 76 319 1952

15 NEUHOF H and TOUROFF A S W Acute putrid abscess of the lung *Surg Gynec & Obst* 63 353 1936

16 NEUHOF H and TOUROFF A S W Acute putrid abscess of the lung *Surg Gynec & Obst* 66 836 1938

17 NEUHOF H and TOUROFF A S W Acute putrid abscess of the lung *J Thoracic Surg* 9 439 1939

18 NEUHOF H TOUROFF A S W and AUFSES A H The surgical treatment by drainage of subacute and chronic putrid abscess of the lung *Ann Surg* 113 209 1941

19 NELHOF H Acute putrid abscess of the lung *Surg Gynec & Obst* 80 351 1945

20 HOLMAN C W Simple excision of lung abscess *Surgery* 27 546 1950

21 TOUROFF A S W NABATOFF R A and NEUHOF H Acute putrid abscess of the lung VI The late results of surgical treatment *J Thoracic Surg* 20 266 1950

77

Air Space Abnormalities

ISRAEL RAPPAPORT, M D AND EDGAR MAYER, M D, *New York, New York*

Loss of lung structure confined to certain parts of the lungs or involving both lungs diffusely is perhaps best designated by the collective term of air space abnormality The literature relating to this condition has greatly increased in the past two decades, and from it a number of facts have become apparent (1) Air space abnormality is a common pulmonary finding and is often seen in patients of all ages from earliest infancy to late senility (2) It occurs most often as an apparent primary pulmonary disease, i e, an independent entity (3) It often develops as a complication of a variety of recognized bronchopulmonary diseases (4) There is no apparent difference in air space abnormalities occurring with or without associated bronchopulmonary disease, (5) *Great confusion prevails in their interpretation* as indicated by the increasing terminology which now includes the following cysts, bullae, cystic emphysema, bullous emphysema, honeycomb lung, vanishing lung, cotton candy lung, pneumoceles, cystic bronchiectases and bronchiolectatic emphysema (6) In spite of this varied nomenclature there is still obviously a strong tendency to reduce all air space abnormalities to the common denominator of emphysema, and the majority of workers tend to look upon them as manifestations of obstructive emphysema

In recent publications we discussed some of the problems involved in their interpretation and pointed out the difficulties inherent in their identification with emphysema We emphasized that current concepts about emphysema are so problematic that to explain air space abnormalities as manifestations of it is just begging the question Confirming the need to reduce all pulmonary changes observed in them to a common denominator, we have proposed the concept of "air space disorder"

"Air space disorder" is not just another designation, but is instead an explanation of air space abnormalities on the basis of a new concept which arose from our analysis and interpretation of the clinical and pathologic features of a large number of cases, including all forms of the condition in patients of all ages In this chapter it is our purpose to show how the great complexity of air space abnormalities can be simplified and logically fitted into the natural history of "air space disorder"

THE COMPLEX NATURE OF AIR SPACE ABNORMALITIES

Clinical observations have long established the fact that air space abnormalities comprise the following four types of lung changes

1 *Overdistention* by stretching of air spaces lacking power of elastic recoil This occurs by *a mechanism which requires little explanation* Thoracic traction expands these air spaces in inspiration Their failure to retract completely in expiration results ultimately in overdistention However, it is also reasonable to assume that this overdistention must result in proportionate narrowing of the air passages (bronchi) and that this will eventually lead to a point when obstructive mechanisms begin to operate While the mechanical factors operating in overdistention are quite obvious, their overemphasis has diverted attention from the real problem, i e, the primary cause of loss of elastic recoil which to begin with makes overdistention possible This will be discussed later

2 *Overinflation* of air spaces due to bronchial obstruction Here we are dealing mostly with a ball valve mechanism which prevents deflation with expiration In final analysis too incomplete recoil during expiration occurs here because of air trapping behind the obstructed air passage Overinflation appears to be a completely mechanical process and under clinical conditions its usual cause is some inflammatory process in the bronchi However, it may be pointed out here that it is frequently assumed that in overinflation behind

bronchial obstruction lung structures may become so overstretched as to lose their power of elastic recoil Overdistention may then replace overinflation even after the bronchial obstruction has ceased to operate The validity of this assumption will be discussed later

3 *Atelectasis*, i e , compression of air spaces by encroachment of adjacent overdistended or overinflated air spaces Both overdistention and overinflation necessarily lead to atelectasis of adjacent normal air spaces by compression of surrounding lung tissue or by compression or distortion of their air passages It is particularly true that in overinflation behind obstruction pressure often exceeds that in surrounding normal air spaces and proceeds at the cost of the latter It then results in the combination of atelectasis and hyperinflation associated with such lung changes as cysts, bullae, pneumoceles and the like

4 *Compensatory overexpansion* of non affected lung areas has been almost completely overlooked, although it is obviously a very important part of the lung changes comprised in air space abnormalities, all the more so since it contributes to the hyperinflation of the lungs as a whole

Overdistention, overinflation and atelectasis imply loss of function in the affected lung areas When this becomes significant in extent, it must be compensated for by hyperfunction of non affected lung areas involving their overexpansion.

It is a long recognized fact that in the need for increased function the lungs can overexpand for compensatory hyperfunction This develops temporarily in the "effort" lung and permanently at high altitudes It has also been amply demonstrated that one lung can compensate for the other, and in the same lung one part likewise can compensate for the other by overexpansion The latter is a common feature of all pulmonary affections involving sufficiently large parts of one or both lungs to require compensatory hyperfunction of the non affected parts Rightly or wrongly this has been designated as compensatory (vicarious) emphysema because of the overexpansion of the hyperfunctioning lung areas We previously explained this[1,2] by postulating that only a fraction of the air spaces available in any part of the lung are ordinarily expanded for simultaneous function at rest and all available air spaces will be expanded in compensatory hyperfunction Compensatory emphysema differs from genuine emphysema in that the latter consists of an increase in the size of the air spaces in the area affected, while the former implies an increase in the number of air spaces of normal size In the former normal alveolar function is even improved

Air space abnormalities of limited extent can be compensated for by non affected lung areas without significant overexpansion of the lungs as a whole and may then be present without clinical symptoms or signs This explains the clinical latency of air space abnormalities discovered only by chance x ray or by

Often to begin with the clinical manifestations are due to the extent of the compensatory function of non-affected parts and the significant overexpansion of the lungs as a whole leading to ventilatory disturbance With continued progress of air space abnormalities, clinical manifestations often arise when the non affected lung areas are encroached upon so that they are no longer capable of compensatory function even while the lungs as a whole are not overexpanded

Compensatory emphysema involving large parts of the lungs must be maintained by increased thoracic traction which for obvious reasons aggravates also the mechanical changes in the affected parts of the lungs This is particularly true in the presence of diffuse air space abnormalities when the advantages gained by compensatory overexpansion are more limited Therefore it is indeed true that "emphysema begets emphysema" The presence of compensatory emphysema may be difficult to discern in air space abnormalities with overdistention and overinflation of significant extent

REVERSIBILITY OF AIR SPACE ABNORMALITIES

Among the chief characteristics of air space abnormalities is their variable reversibility The most complete reversibility is demonstrable in cases of hyperinflation and atelectasis which often occur spontaneously Caffey[3] has shown that spontaneous reversibility of overinflated lung areas with re expansion of adjacent atelectatic areas is practically the rule in children In later life too it often occurs

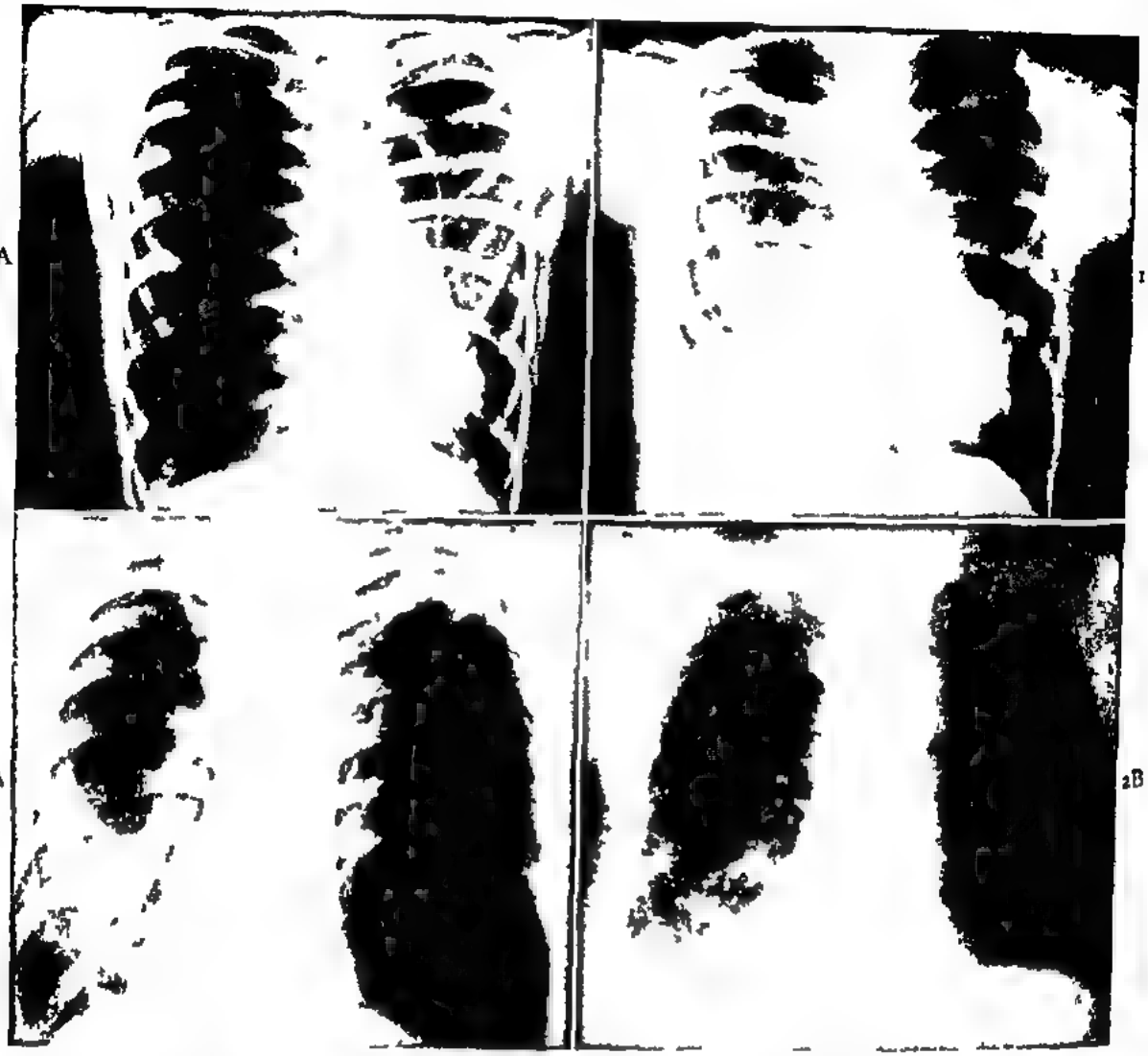

FIG 1 A eleven year old girl X ray reveals a pneumocele of enormous size occupying the right hemithorax and even herniating into the left side It appears as if the right lung had been turned into one vast air sac B x ray taken after operation which involved deflating and resecting a hyperinflated air sac formed in a part of the right lower lobe The whole right lung was atelectatic due to compression following operation this re-expanded lung proved to have fairly normal function even after a decade of atelectasis

FIG 2 A fifty five year old man known to have bullous emphysema for fifteen years X ray reveals an acute pneumocele in the left hemithorax Required emergency decompression by trocar and continuous suction B x ray shows re-expansion of the left lung which was even better than the status before the onset of the acute pneumocele At that time the left lung contained extensive air space abnormality which appeared irreversible

spontaneously We have observed this especially in cases in which fluid (probably secretions) accumulated in the abnormal air spaces As this fluid is eventually absorbed, the air is also absorbed Reversal can be brought about by surgical deflation, perhaps in a majority of cases The extent of reversibility of air space abnormalities is quite unpredictable from the clinical and x ray features In general it can be said that the more extreme the extent of hyperinflation, the more likely is there extensive mechanical obstructive hyperinflation of a high degree of reversibility However the extent of reversibility is often not realized until demonstrated by surgical intervention (Figs 1 and 2)

Reversibility of compensatory emphysema is of course obvious, but its extent will naturally depend on the extent of actual reversal of the changes in the affected lung areas Clinically the situation is often such that compensatory emphysema must be maintained permanently

and becomes reversible only as the lungs cease to be expanded at death During life reversibility of compensatory emphysema is responsible for much confusion in the correlation of the clinical and morphologic features in air

even discounting the expected loss of air from the lung under the circumstances

The previous brief review of lung changes involved in air space abnormalities should suffice to indicate that their nature is far more complex than would appear from current literature Not only have the structural changes associated with deflation of adjacent air spaces

overlooked The features of air space abnormalities have been misinterpreted chiefly by overemphasizing the role of mechanical factors Attention has been focused almost exclusively on the structural features associated with mechanical hyperinflation, and these have become identified with emphysema The result is the current completely mechanical concept of the nature and origin of emphysema

The error in this interpretation becomes apparent if we consider that, as previously mentioned, the mechanical changes in air space abnormalities are reversible while so-called genuine emphysema is not reversible As pointed out the mechanical factor involved in overstretching abnormal air spaces operates on structures which have lost their power of elastic recoil The characteristic feature of genuine emphysema is the primary loss of elastic recoil, and the latter is the crux of the problem of the origin and nature of emphysema

THE PROBLEM OF THE PRIMARY DEFECT IN AIR SPACE ABNORMALITIES

That current concepts cannot account for the origin of air space abnormalities has been increasingly realized by discerning observers As was pointed out recently by Head,[4] "The prevailing concept that ball-valve obstruction of a bronchus with consequent air entrapment is the only mechanism which can account for ballooning of intrapulmonary cavities and cysts is incorrect" He contends that "another mechanism has much broader implications in pulmonary physiology Any intrapulmonary cavity whose walls are stretchable but

gradually in size to the limits of its stretchability and at the expense of the expansion of the normal elastic lung This principle is less easy to explain or to understand It is, however, extremely important It accounts, I believe, for the tremendous increase in the size of congenital pulmonary cysts, in part for the progressive enlargement of blebs and bullae and also for the enlargement of any lobe or segment of a lobe which, as the result of emphysema, has lost its elasticity but not its stretchability"

In most recent publications Churchill,[5] realizing the inadequacy of prevailing concepts, also discussed the problem of "paradoxic development of cystic and bronchiectatic changes following bronchial obstructions" His answer to this is what he describes as the "space-occupying function of air" based on

segments are found filled with air that enters through adjacent normal segments or remaining normal bronchi within the diseased segment' His explanation of this remarkable phenomenon is particularly significant "The architectural design of the lung is such that its spatial integrity tends to be preserved even after a morbid insult has destroyed the function of segmental structural units This mechanism involves what is referred to as the 'space-occupying function' of air within an organism, a physiologic principle illustrated by other examples"

Head too speculates on the important role of collateral ventilation and explains the primary defect as follows "The air which enters the parenchyma through collateral channels behind obstructed segmental or lobular bronchi does not readily flow in and out but tends to

relative entrapment of the air which has entered obstructed lobules and segments,

accounts for the development of emphysema rather than entrapment by ball valve obstruction of the bronchi, as was predicated by Laennec.

Analyzing these recently proposed views it seems to us that they are merely adding some new hypothetic features to the mechanistic ideas and support essentially the old concept of obstructive emphysema as the sole basis of air space abnormalities. Ingenious as these speculations are, they have not solved the problem, namely, the ultimate cause of emphysema and its role in air space abnormalities. However, these ideas do point up the difficulties in the current crudely mechanistic concepts and confirm the need to assume the existence of a primary lung defect on the basis of which abnormal air spaces as well as emphysema develop.

OUR CONCEPT OF THE PRIMARY LUNG DEFECT

Morphologically abnormal air spaces are characterized chiefly by the loss of alveolar parenchymal structures. The air spaces become enlarged by coalescence, they are not distended. In the final analysis air spaces so enlarged represent loss of the normal partitions. If we conceive that the air space partitions are not merely structural fixtures but are in the nature of a functional activity of these structures then loss of air space partitioning becomes the manifestation of a disturbance in the function of the lungs so conceived. Such a truly biologic concept of "visceral" lung function was presented recently by one of us.[6] Our interpretation of air space disorder as a manifestation of a structural as well as functional lung defect is based on that concept.

This defect may involve certain restricted parts of the lungs or involve both lungs diffusely. Lung areas so affected are not distended, in fact their volume may even be diminished, yet their air spaces are too large in proportion to their fine air passages. Their bronchi are patent and may even be somewhat distended. However, lung areas which have lost their parenchyma and its partitioning function tend eventually to become overstretched by thoracic traction because of loss of power of elastic recoil. Also the bronchus here tends toward oversecretion because of increased arterial blood supply from augmented bronchial circulation. Bronchorrhea invites infection with its sequelae of obstruction. This leads to hyperinflation as a local secondary manifestation of mechanical origin as previously discussed.

THE NATURAL HISTORY OF AIR SPACE DISORDER

As to the origin of the primary pulmonary defect so conceived, the answer we believe lies in the natural history of air space disorder as gleaned from clinical observations interpreted in the light of the concepts previously mentioned. We have tabulated what we conceive to be the natural history of air space abnormalities in Figure 3.

As indicated in Figure 3 we postulate that the primary pulmonary defect may be of developmental or acquired origin. The alveolar damage may arise at any time from the very beginning to almost the very end of life. Particularly critical periods are the intranatal establishment of lung function, the postnatal continued growth of the lungs and the decline of functioning capacity with advanced age. In the latter, acquired, and in the two former developmental defects may be assumed to play the predominant role. In previous publications[7,8] we have discussed reasons which lead us to believe that developmental defects carried into later life play the important role of a predisposing factor even in acquired defect. In turn, acquired pulmonary changes play an important role in promoting the evolution of developmental defects, even in early life causing these to go on to air space disorder. Thus the pathogenesis of the latter in any phase of life is often best explained on the basis of acquired pulmonary changes the origin of which can be traced back to persistent developmental defects brought along from very early life.

We have advocated this concept of the long range natural history of chronic pulmonary disease with, or related to, emphysema in several publications in past years.[7,8] The very significant role of developmental defects arising during the postnatal growth of the lungs may now be considered as fairly well demonstrated.[9] Since then much confirmatory evidence has appeared in recent literature.[10]

Recently much evidence has come forward of perhaps even greater significance of the intranatal phase of establishment of lung function at birth. There is now evidence especially incriminating violent resuscitation efforts now practiced with high pressure machines on new

borns with tardy establishment of lung function [11]

Lung defects acquired throughout adult life are also quite characteristic of the subsequent phases of life as indicated in Figure 3

From the foregoing analysis it should be apparent that the great confusion in the interpretation of air space abnormalities resulted from failure of recognizing the roles played by the primary lung defect in the origin and the role of compensatory emphysema in the evolution of their morphologic and clinical features Identification of the primary lung defect of developmental or acquired origin with secondary changes of mechanical origin and our inability to separate compensatory emphysema when the latter complicates the combination of the former two prevents better understanding of air space abnormalities

On the basis of the previous concepts it appears logical to bring all air space abnormalities under one common denominator and we proposed that they be designated by the name of air space disorder for the reasons just [illegible]

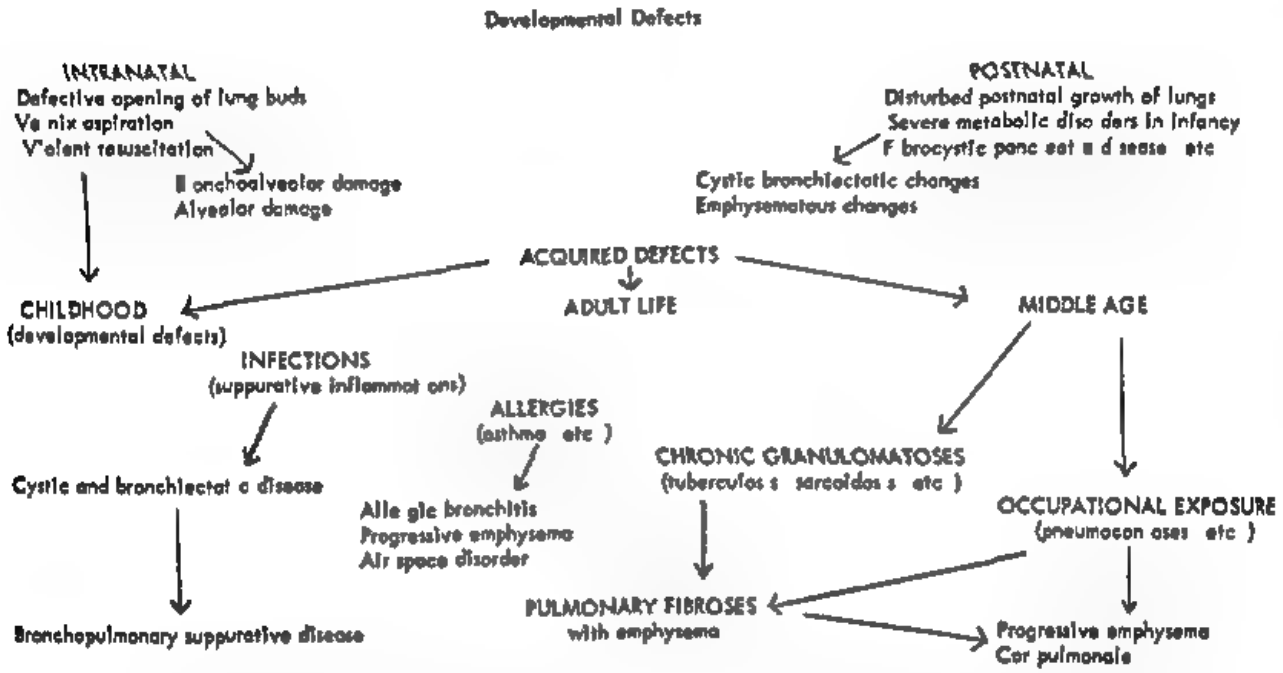

FIG 3

disorder of the air spaces of the lungs comprising a complex combination of distended as well as compressed lung areas From the standpoint of its functional implications it represents a disturbance in the activity of the structures of the air spaces of the lungs

PRACTICAL ASPECTS

Understanding of the nature and origin of air space disorder should lead to more frequent recognition and to more correct interpretation of its clinical manifestations It will account for the occurrence of identical or very similar clinical pictures in a great variety of chronic pulmonary diseases of different etiology It will explain the phenomena of so called emphysema arising in any phase of life from earliest infancy to late senility in association with clinical conditions characteristic for these age periods (Fig 3)

Knowledge of the circumstances which lead to development of air space disorder should lead to its earlier recognition by closer observation of progress of postnatal lung development in infants and children. It should lead to deliberate search for lung defects when those should be suspected on clinical grounds or from x ray features in adolescents and young adults It should result in correct interpretation of clinical pictures based on air space disorder such as pseudo asthma and others discussed in previous publications [7 8] Finally it should

result in earlier recognition of these pulmonary conditions before they end up in vanishing lungs or so-called progressive bullous emphysema of hopeless extent

Progress in treatment is bound to follow advances in the recognition of air space disorder and in the understanding of its nature This should begin with progress in prevention of its mechanical complications by such methods as improved technics of resuscitating asphyctic newborns, improved methods of keeping air ways open in children afflicted with pulmonary infections, mucoviscoidosis and the like, and resection of localized progressive lung defects when they begin to encroach on adjacent lung areas and interfere with the normal growth and expansion of the latter

Knowledge of the frequently insidious nature of air space disorder should stimulate progress in assessing the proportion of normal and abnormal lung areas by such methods as angiography, planigraphy bronchography and bronchospirometry Correlation of these with ventilatory and gas exchange studies should yield true estimates of the functioning capacity of the lungs upon which indications and feasibility of surgical therapy and clinical management in general must be based

CONCLUSIONS

Interpretation of air space abnormalities has remained confused chiefly for two reasons (1) Failure to recognize that loss of power of elastic recoil in genuine emphysema must be traced back to a primary lung defect (2) failure to consider the role of compensatory emphysema so difficult to discern in presence of genuine emphysema and of mechanical hyperinflation or overdistention These have led to identification of air space abnormalities with emphysema and to a concept of the latter in which the structural features and the mechanical factors are overemphasized

Clinical experience indicates that air space abnormalities are complex conditions, the true nature of which is best described as "air space disorder" with functional as well as morphologic implications

On the basis of a new concept of "visceral lung function and its implications regarding the role of developmental postnatal and acquired lung defects, the natural history of all these pulmonary conditions can be readily reduced to the common denominator of "air space disorder"

The practical aspects of this concept in relation to clinical problems are presented

REFERENCES

1 MAYER, E and RAPPAPORT L. Pulmonary emphysema *J Mount Sinai Hosp* 12 505 1945
2 MAYER E and RAPPAPORT I Pulmonary emphysema *Rocky Mountain M J*, 42 257 1945
3 CAFFEY J Natural regression of pulmonary cysts during early infancy *Pediatrics* 11 48 1953
4 HEAD J R Observations of mechanism of emphysema *Quart Bull Northwestern Univ M School* 25 210 1951
5 CHURCHILL, E Architectural basis of pulmonary ventilation *Am Surgeon* 137 1 1953
6 RAPPAPORT I The problem of the visceral function of the lungs *Dis of Chest* 25 1 1954
7 MAYER E and RAPPAPORT I Clinical observations of abnormal air spaces *J A M A* 153 700–703 1953
8 MAYER, E and RAPPAPORT I Developmental origin of cystic and emphysematous changes in lungs *Dis of Chest* 2 146 1952
9 MEDLAR, E Personal communication
10 BAXTER, S G and MEAKINS J F Developmental bronchial cysts *Ann Int Med* 38 967, 1953
11 EHRENHAFT J L and TABER R E Progressive infantile emphysema *Surgery*, 34 412 425 1953

Pulmonary Tension Disorders in Infants and Children

JOHN A. CAMPBELL, M.D., *Indianapolis, Indiana*

From the Department of Radiology, Indiana University Medical Center, Indianapolis, Indiana

THE pulmonary tension disorders of infants and children are those characterized by an excessive inflation of the bronchial structure, the lung parenchyma or the pleural space by encysted or trapped air under pressure. The majority of these conditions, particularly the most serious variety, are encountered in the neonatal period or first few months of life. Those occurring later in infancy or early childhood are apt to be less disabling and demand less urgent treatment. The expansile changes frequently, but not invariably, result from some kind of check-valve mechanism between the distended area and its air supply.

All of these tension states are manifest roentgenologically by uniform, distinct areas of intrathoracic radiolucency associated with displacement and compression of adjacent soft tissue structures. Roentgen examination undoubtedly offers the best means for clinical detection and evaluation of the extent of these lesions, yet this method has serious limitations in the differential diagnosis of them. The roentgen findings will not always establish that the tension rarefaction involves the lung parenchyma rather than the pleural space, and frequently will not demonstrate with certainty whether the lesion is a solitary loculated air cyst or has a diffuse lobar emphysematous distribution. Furthermore, it is virtually impossible on roentgenographic grounds alone to distinguish certain naturally reversible acquired cysts from congenital irreversible cysts which need surgical treatment. Nevertheless serial chest roentgenograms provide a most important study of the progress of the hyperinflated areas which aids in deciding the proper course of management.

Since the natural history of many of these lesions allows them to regress spontaneously while others progressively jeopardize the life of the individual, the need for critical roentgen analysis in every case cannot be overemphasized.

CLINICAL FINDINGS

Clinically, these conditions are usually accompanied by varying degrees of dyspnea and cyanosis. Occasionally, profound respiratory distress due to acute obstructive changes or severe compressive atelectasis of the adjacent normal lung develops rapidly making surgical excision urgent and life-saving. Since such violent and alarming symptoms can be more transient and benign in younger infants than in older patients, the decision concerning the degree of hazard to the infant's life is probably better evaluated by the pediatrician than the surgeon in these instances. Acute respiratory infection may or may not be present as a complicating or secondary factor. More often, however, the infection may constitute the primary cause of the tension phenomenon which may show spontaneous regression after the infection subsides. This is a strong argument for conservative treatment in all infected cases. Spontaneous pneumothorax due to rupture of the hyperventilated area into the pleural space may cause a sudden increase in respiratory embarrassment requiring immediate thoracentesis with an underwater seal.

PATHOLOGIC CLASSIFICATION

Attempts to classify these disorders are largely unsatisfactory in that the basic mechanisms of their production are so poorly understood pathologically. This is partly due to the minute nature of the anatomic structures involved and to the fact that pathologic specimens do not actually reveal functional derangements which may operate in the living organ. The obvious check-valve mechanism which is apparent clinically in many hyperventilated lungs or cystic lesions is very fre-

quently impossible to demonstrate in gross or even microscopic examination of the resected specimens yet the similarity of appearance and behavior of these conditions to seemingly identical lesions due to an aspirated foreign body in the bronchial tree or a traumatic tension pneumothorax makes the assumption of an underlying check valve mechanism valid in all cases

Any classification based on pathologic findings must deal with the controversial problem of whether certain pulmonary cystic lesions are of congenital or acquired origin Unfortunately we have not reached a point in our thinking on these entities to say with certainty what constitutes a truly congenital cystic malformation in many instances Even at surgery there is no consistent way of differentiating the congenital from the acquired cyst because of the gross similarities and wide variations in the findings Both types show thick or thin walls air fluid content and epithelial lining Even the presence of bronchial epithelium cartilage mucous glands elastic and muscle tissue does not conclusively point to congenital origin because it may only represent the wall of a severely dilated bronchial structure distal to an obstruction

On the other hand there is little question that such potential causes of tension cystic disease as adenomatoid hyperplasia of lung (cystic hamartomas) cartilaginous hypoplasia of bronchial structures and intralobar sequestration of the lung are of congenital origin

The real controversy in this matter stems not so much from the disagreement over the pathologic findings as from the fact that the distinction as to whether a lesion is of congenital or acquired origin may be vital to prognosis and treatment There is a natural tendency to submit to surgical correction disorders attributed to congenital anomaly on the basis that they are irreversible

On the other hand surgical excision is more frequently postponed in suspected acquired cystic lesions on the assumption they are more apt to regress spontaneously

Caffey[1] points out that spontaneous regression without surgical removal is the rule for most pulmonary cysts if their course is followed sufficiently long Even if the cyst persists after months or years of observation the patient usually continues to thrive He believes nonoperable management should be the rule in all pulmonary cysts of infancy except in rather rare instances in which acute respiratory distress due to marked overexpansion of the cyst makes surgical decompression or excision a life-saving necessity

To avoid needless radical surgery on a tension disorder which may regress spontaneously operative intervention should be based only upon unsatisfactory clinical progress and never on the roentgen findings alone

Suffice it to say that from the standpoint of pathologic classification tension disorders of the lung develop through a variety of check valve mechanisms derived from (1) developmental bronchopulmonary malformations (2) bronchogenic pulmonary suppuration (3) intrabronchial and extrabronchial occlusions and (4) pleural fistulas

ROENTGENOLOGIC FINDINGS

Accurate roentgenologic differentiation of these various pathologic groupings is frequently impossible because of the similarity in findings Nevertheless identification is considerably enhanced by carefully correlating the roentgen appearances of the lesion and its anatomic distribution with the factors of age mode of onset infection and collateral disease processes. Anatomically the involvement may be unilateral or bilateral in distribution The expanded area may be intralobar lobar or pneumonic in extent with those showing a lobar emphysematous character tending to be more serious and irreversible The age and history of onset helps to evaluate the origin of the process i e occurrence at birth trauma foreign body aspiration The association of current or previous inflammatory disease makes some roentgen evidence highly specific A knowledge of coincidental cardiovascular mediastinal systemic or other organ disease process may give the roentgen findings greater specificity Roentgen diagnosis should not be difficult in a great many instances if one is aware of the entity and its attendant manifestations

1 *Developmental Bronchopulmonary Malformations* Probably the most frequent lesions in this group are the lobular bronchial cysts They seem to result from embryonic blockage in the lumina of the bronchial buds, and develop as single or multiple cystic cavities lined with bronchial structures and filled with secretions Norris and Tyson[2] have shown by an ingenious study of serial sections that the

FIG 1 Solitary bronchial cyst A spherical trabeculated tension cavity expands the left lower lobe Its thin wall is barely discernible Note compressed lung segments in the angles of the thorax This proved to be a loculated bronchiectatic malformation

original defect is a small irregular dilatation in the smaller bronchioles When arrested in this stage, such focal dilatation results in fetal or cystic bronchiectasis characterized by rather uniform sized, thin-walled cysts in the terminal arborization of the bronchial tree

If the process continues, these bronchiolar dilatations become pinched off to form larger cysts, up to several centimeters in diameter When diffuse, this process gives rise to the so called honeycomb lung and may involve one or several lobes This type of honeycombed lung is actually a form of bronchiectasis and is clearly demonstrable by bronchography in contradistinction to the acquired fibrocystic form of honeycombed lung in which the check valve alveolar and interstitial cysts do not fill on bronchography

Most frequently, the focal segmentation process is isolated and a single bronchial cyst forms The postnatal behavior of such a cyst depends on mechanical factors When a check valve mechanism develops in the narrow tortuous bronchial lumen, the fluid is evacuated and the cyst may expand rapidly to form a huge tension cavity which greatly distorts the lobe in which it arises Roentgenographically, such a solitary bronchiectatic tension cyst shows a clear or trabeculated large area of rarefaction, with discernible lung tissue at the apex and angles of the thorax, and absence of collapsed lung at the hilum Mediastinal herniation when present, is much less striking than with tension pneumothorax The cyst will usually not visualize on bronchography The margin of the cyst wall is generally not clearly distinguished unless it is secondarily infected or contains fluid Anatomically, such lesions are intralobar in extent (Fig 1)

A less frequent type of bronchopulmonary malformation is cystic hamartoma or adenomatid hyperplasia of the lung[3] observed almost exclusively in premature infants It is characterized by a marked proliferation of embryonic lung tissue resembling normal adult lung tissue except that it is composed of an organoid overgrowth of terminal bronchioles surrounded by many tiny alveolar lobules The malformed portion passes directly into normal appearing lung tissue at the periphery without any demarcation or encapsulation The essential feature is an excessive overgrowth of bronchioles, which causes lobar enlargement, while the development of the alveoli is completely suppressed except at the periphery

This mass may become hyperventilated under tension, or remain completely distended with secretions, depending on the potency of



2A 2B

FIG 2 Cystic hamartomas A communicating type of adenomatoid hyperplasia of right lung in which a check valve hyperventilation of the involved right upper lobe has occurred B non-communicating type of adenomatous hyperplasia of lung showing a dense cystic mass expanding the left upper lobe and filled with fluid secretions instead of air because no bronchial communication has been established

its bronchial communication A check valve mechanism in the faulty and undersized bronchial supply causes a roentgen picture that is often indistinguishable from obstructive lobar emphysema caused by bronchial occlusions Its occurrence in the premature newborn without evidence of infection or aspirational episode together with the presence of hamartomatous mass at the hilum should suggest the diagnosis Usually this type of lesion is not capable of producing the extreme degree of expansile distortion of the hemithorax that is seen with the locular cysts There is also no formation of large air cysts because the check valve mechanism occurs in the larger bronchi (Fig 2)

Another type of bronchial malformation which may show tension manifestations is sequestration of the lung[4] The pulmonary abnormality consists of lung tissue which is sequestrated or dislocated from the normal bronchial and blood supply of the surrounding lung This occurs as either an intralobar or extralobar sequestration depending upon whether the anomalous segment lies within the lower lobe or adjacent to it forming an accessory lobe or lung The bronchial supply of the abnormal lung does not communicate with that of the involved lobe, and its blood supply is derived from an aberrant pulmonary artery arising directly from the thoracic or abdominal aorta This artery may pass through the diaphragm or mediastinum to reach the lung creating an important hazard if lobectomy is contemplated In intralobar sequestration the venous drainage is to the normal pulmonary veins and in extralobar sequestration to the systemic veins

The sequestrated lung may consist of one or more large bronchogenic cysts or a polycystic mass showing expansile characteristics incident to infection or bronchial occlusion Radiographically, this lesion may remain obscure until complicated by infection when pneumonic density surrounding air and fluid distended cysts develops in the posterior, medial inferior portion usually in the lower lobes Sometimes a finger like extension of the density passes medially toward the diaphragm and aorta Although the tension characteristics of the cystic disease show spontaneous regression as infection subsides the tendency for progressive expansion with repeated inflammatory episodes may make surgical removal desirable Bronchography and barium swallow aid to differentiate this condition from suppurative bronchiectasis and diaphragmatic hernia Aortography shows the associated vascular anomaly

FIG 3 Pneumatocele in suppurat ve pneumon a A small a r bubble appears v th n consol dated lobe B def n te cavernous area appears one week later su rounded by w de band of density C two weeks later the tens on cyst has expanded markedly follow ng resolut on of the pneumon c nfiltrate D at four weeks the pneumatocele is further d stended and produces med st n l d splacement The lungs show compensatory emphysema

2 *Bronchogenic Pulmonary Suppuration* Suppurative bronchopulmonary disease is the chief cause of acquired intralobar tension cystic disease During the course of the bronchogenic spread of certain forms of interstitial pneumonia one or more round hyperventilated cavities or pneumatoceles may appear roentgenographically within the infected portions of the lung parenchyma These may rapidly enlarge and remain as thin walled air containing cysts for many months after the pneumonic density has disappeared Doub[6] Caffey[8] and others believe that these radiolucent areas constitute a special form of regional obstructive emphysema resulting from a check valve mechan sm produced by thick exudate edema and expiratory constriction in a small bronchus supplying an area of interstit al pulmonary sepsis and necros s As the necrotic tissue is liquefied and evacuated through the bronchus the resultant cavity is increasingly expanded with air These cavit es may contain fluid levels and be mistaken for necrotic abscesses They are lined with a thin layer of granulation tissue

Tension pneumatoceles occur most frequently in staphylococcic and other suppurative pneumonias[7] but they are also seen in tuberculosis (caseating bronchopneumonia) and similar granulomatous infections In fact when ever a pneumatocele of this type is encountered, staphylococcic pneumonia should be strongly suspected as the cause They tend to d sappear spontaneously as the infection subsides although they frequently persist for several months after disappearance of the

FIG 4 Tuberculous tension pneumatocele This huge high tension air filled cavity containing fluid proved to be a regional obstructive emphysematous cyst in the left upper lobe lined with tuberculous granulation tissue Such lesions occur in caseating bronchopulmonary tuberculosis and may undergo spontaneous regression during the course of disease

inflammatory densities Only at this stage is a problem in differentiation created, since there are usually no roentgen clues of previous inflammatory disease Following collapse or gradual reduction in the size of the cyst, the walls ultimately become impossible to find [illegible] on for one [illegible] or more [illegible] This indicates the different stages of pneumonic involvement incident to bronchogenic spread of these infections [8]

Roentgenologically, the pneumatocele may be distinguished by the rather characteristic changes in its appearance on a sequence of films In the initial consolidative phase of the pneumonia, such a lesion resembles air bubbles deeply seated in the parenchyma During the phase of consolidation a small poorly outlined spherical cavity is seen As the consolidation resolves, a vivid thin-walled pneumatocele is formed that is at first surrounded by a wide margin of lung tissue, but which may rapidly inflate under tension to fill the entire lobe or hemithorax With this, there may be extreme compression of the adjacent lung and mediastinum The pneumatocele may vary greatly in size from day to day, occasionally ballooning up to alarming proportions Suddenly it may disappear entirely because of loss of the valve [illegible] such proportions that it persistently and seriously embarrasses cardiorespiratory function, or ruptures to form tension pneumothorax surgical intervention indicated Here closed catheter drainage will usually suffice, and recourse to lobectomy is rarely necessary (Fig 4)

Intrabronchial and Extrabronchial Occlusions The classic form of obstructive emphysema of infancy is derived from a check-valve impaction of an aspirated non radiopaque foreign body, frequently a peanut, into a secondary bronchus The hyperventilation may be lobar or multilobar in extent and causes displacement of the mediastinum to the side opposite the lesion on radiographs made in the expiratory phase of respiration The tension state lasts for forty eight to ninety-six hours and is followed by atelectasis of the involved area History is important but not always accurate Age is a factor in that such aspiration generally occurs in a child who has incisor teeth, but no opposing molars, usually about the second and third years of life This point aids in differentiating the foreign body type from those lobar obstructive emphysemas occurring in the first few months of life The latter types show a progres-

FIG 5 Lobar obstructive emphysemas A lobar emphysema of left upper lobe due to intrabronchial occlusion incident to hypoplasia of bronchial cartilage B lobar emphysema of right middle and lower lobes due to extra bronchial occlusion produced by vascular compression in Eisenmenger's complex There is atelectasis of the right upper lobe

sive pneumatic distention of one lobe to extreme proportions causing marked respiratory distress and cyanosis without subsequent atelectasis of the involved lobe This is probably because the intrabronchial edema at the point of obstruction is less severe than with foreign body There is also a tendency for involvement of the upper lobes in contradistinction to the lower lobe involvement with foreign body aspiration

Severe lobar emphysema of this type[9] probably results most frequently from hypoplastic development of the bronchial cartilaginous rings It is not unusual as reported by Van Epps and Davies [10] for the surgeon and pathologist to find no definite obstructive mechanism to explain the marked inflation of the lobe The overdistended lung shows fragmentation of the interstitial elastic tissue and ruptured alveolar walls from the increased intra alveolar tension but nothing to suggest adenomatoid hyperplasia It has been postulated that an infolding of bronchial mucosa or kinking of an underdeveloped bronchial ring might serve to produce functional check valving in these instances Compression atelectasis of the adjacent lobes may be seen in the changing roentgen picture Spontaneous regression of the tension state if it does occur is transient, and fulminating recurrences are the rule Conservative decompressive measures by needle or trocar have been unsuccessful

Extrabronchial compressive occlusions cause severe degrees of obstructive emphysema in a single lobe or the entire lung depending upon whether they affect a primary or secondary bronchus The common causes in infancy are intrathoracic vascular anomalies and mediastinal mass lesions lying close to the bronchus Duplication and bronchogenic cysts attached or incorporated into the bronchial wall may give rise to a ball valve action which prevents normal expiratory function and builds up a high tension form of emphysema (Fig 5)

In infants with congenital cardiovascular disease a persistent ductus arteriosus may overlay the left main bronchus and produce the check-valve effect Striking examples of extrabronchial interference with the ventilation of the lung have also been seen in cases of aberrant pulmonary veins truncus arteriosus vascular ring anomalies Eisenmenger's complex transposition of great vessels, and enlarged bronchial arteries

In these cases one must be careful not to mistake profound avascularity of the lung for

(suppurative) pneumonia in infancy and in childhood and its surgical aspects *Am J Dis Child* 72 691 1946

9 FISHER H W POTTS W J and HOLINGER R H Lobar emphysema in infants and children *J Pediat* 41 403 410 1952

10 VAN EPPS E F and DAVIES D H Lobar emphysema in children *Am J Roentgenol* To be published

11 FORBES G H Diagnosis and management of severe infections in infants and children review

12

472 1954

13 SUSMAN M P Hydatid cyst of lung two unusual cases *Australian & New Zealand J Surg* 21 297 299 1952

Cystic Disease, with Emphasis on Emphysematous Blebs and Bullae

JEROME R HEAD, M D, *Chicago, Illinois*

PULMONARY cysts, emphysematous blebs, emphysematous bullae and extreme emphysema localized to a lobe or a segment of a [illegible] tend to increase in size, either rapidly or gradually, and all may become so large that they crowd and compress the adjacent normal lung and in this manner produce dyspnea All are amenable to surgical treatment The pathogenesis of all except the cysts is poorly understood, and why all of them, even the cysts, grow steadily larger is not generally recognized

DEFINITIONS AND GENERAL CONSIDERATIONS

Pulmonary cysts are congenital epithelium-lined cavities There are three varieties, i e, simple cysts, batrachian cysts and bronchiectatic cysts or congenital cystic lung Simple cysts are solitary epithelium-lined cavities which have no well organized communications with the air passages They are often filled with fluid or, if a communication with the air passages has developed, with air or fluid and air They do not tend to increase in size They are relatively innocuous, becoming clinically important only when they produce hemoptysis or when they become infected

Batrachian cysts are segments of lobes whose development has become arrested in the batrachian stage A patent segmental bronchus enters them and then branches to spread, medusa like, over their lining surface Along each such bronchial radicle are numerous openings for the ingress and egress of air These cysts tend to increase rapidly in size, probably soon after birth One that is small at birth may in a few weeks come to fill an entire hemithorax, compressing the adjacent normal lung and forcing the mediastinum far to the opposite side

Congenital cystic lung closely resembles bronchiectasis It is the result of arrest of development in a late stage The larger bronchi branch normally but instead of decreasing steadily in size at some point along their course open up into smaller or larger bronchiectatic cysts From a clinical point of view the disease is scarcely distinguishable from bronchiectasis The symptoms and treatment of the two conditions are the same They will not be considered in this section

Emphysematous blebs are air-filled blisters covered by the visceral pleura They are not usually associated with vesicular emphysema They are produced by the rupture of alveoli into the subpleural plane Small ones, such as cause most cases of spontaneous pneumothorax, are common Some of them increase progressively in size Giant blebs (either single or multiple, either apical or basal) which cause important dyspnea are relatively common When one observes the interior of these blebs through a thoracoscope, the mechanism which causes them to grow progressively larger is obvious On inspiration multiple small stomas in the lung open to permit the entrance of air On expiration they close to prevent its exit. It is obvious that this ball valve mechanism entraps air in them under pressures which on exertion or coughing must be extremely high

Emphysematous blebs rarely become infected The author has seen one case of empyema of bilateral blebs Treatment by rib resec- [illegible] is absorbed It is probable that the inflammatory exudate closes the communications with the air passages More will be said about this in the discussion of the treatment

Recently Korol has presented statistics which indicate that blebs predispose to bronchiogenic carcinoma The author has seen several cases

Extreme lobar emphysema in infants and small children is an obscure and dramatic condition in which a single lobe which is grossly normal becomes so tremendously dilated that it occupies an entire hemithorax, compressing the adjacent lobes and pushing the mediastinum far to the opposite side In recent years an increasing number of such cases has been reported A number of these patients have been operated upon and a relatively normal respiratory status restored by resection of the emphysematous lobe The etiology and mechanism of the condition is obscure It is generally believed that the dilation of the lobe is caused by a ball valve obstruction of the lobar bronchus The confusing thing is that in only one of the cases has an obstruction been found, either by bronchoscopic examination or by examination of the lobes removed at operation or autopsy In one case Holinger found strands of tissue partially obstructing the bronchus Removal of these through the bronchoscope corrected the condition In no other case has any obstruction been demonstrated Folds of mucosa and abnormalities of the cartilages have been suggested as accounting for obstruction but these explanations are hypothetic and probably incorrect It is possible that bronchial obstruction is not the cause In the ordinary case of locked emphysema such great dilation of a lobe or lung does not and cannot occur Usually the greatly narrowed bronchus widens on inspiration to permit the entrance of air and closes on expiration to prevent its egress For this reason the lobe or lung enlarges only to its inspiratory maximum and it is because it does so that the roentgenogram taken on deep inspiration fails to disclose the condition Any difference in the aeration of the lungs becomes apparent only on a film taken on expiration Such great dilation of a lobe as is found in this condition presupposes an obstruction which permits air to enter only when the intrabronchial pressure is greatly elevated as in coughing or straining but which is complete during normal inspiration and expiration One can conceive of such an obstruction and can conceive that it might produce a locked emphysema of high pressure If such an obstruction does ever exist one would expect to encounter it in other conditions and in adults Therefore inasmuch as the very existence of this type of ball valve is problematic and no obstruction of any kind is found in these cases one is justified in suspecting that some other mechanism accounts for these greatly dilated lobes. The theory that a congenital or acquired loss of elasticity permits them to stretch to this size will be developed in a separate section of this paper

Emphysematous bullae are air sacs within the lung parenchyma which are produced by the breaking down of the interalveolar septa They are an end result of severe vesicular emphysema They are often confused with blebs and the terms "bleb" and "bulla" are often used loosely and interchangeably The conditions are distinct, both in their etiology and pathogenesis, and their treatment is entirely different

Vesicular emphysema is a dilation of the alveoli It is either caused by or always results in a loss of pulmonary elasticity Its etiology and pathogenesis are obscure It is discussed here as a disease amenable to surgical treatment because it is often localized to lobes or segments of lobes These, because of the entrapment of air and because their loss of elasticity permits them to stretch to such size that they crowd and compress the adjacent normal or more nearly normal lung frequently act to produce dyspnea in the same manner as do giant cysts and blebs Not only are such emphysematous lung portions functionless in the exchange of gases but also by occupying space and taking their share of the pulmonary circulation they limit the maximum function of the more normal lung portions Resection of such lobes or segments is occasionally indicated and in carefully selected cases may result in an important increase in functional vital capacity

CONSIDERATIONS OF THE ETIOLOGY OF EMPHYSEMA AND THE CAUSES FOR PROGRESSIVE ENLARGEMENT OF CYSTS BLEBS, BULLAE AND EMPHYSEMATOUS LOBES

I have already stated that the etiology and pathogenesis of vesicular emphysema are obscure Pathologically, as first noted by Laennec, the lungs are dilated, they are inelastic and do not collapse when removed from the thorax The alveoli are enlarged and inter [illegible] down [illegible] ennec [illegible] ed by [illegible] les by viscid secretions He noted, however, that occasionally cough and secretions were absent

The modern conception of the etiology and pathogenesis of vesicular and bullous emphysema is similar to that advanced by Laennec It is spoken of as obstructive emphysema, and obstruction of the finer air passages either by secretions, edema or spasm is predicated There is considerable evidence to support this theory, but that the process is as simple as this seems improbable It is true that most patients afflicted with this condition have had a chronic cough for many years prior to the development of the emphysema Without having definite asthma, most of them have a prolonged expiratory phase, some wheezing and a reduction in maximum breathing capacity which is out of proportion to the reduction in vital capacity These all speak for expiratory obstruction of the finer air passages, as does the fact that antispasmodic drugs increase the vital capacity On the other hand, some patients have no cough or expectoration, and in bronchial asthma, the condition which would seem most likely to produce it, severe emphysema is rare Most patients do not have and have never had bronchial asthma It is also difficult to understand how a ball valve obstruction which permits air to enter the alveoli more easily than it can leave them would result in such extreme dilation In locked emphysema of this type the alveoli can be dilated only to the inspiratory maximum It seems probable that dilation beyond this point necessitates a mechanism whereby air is forced into them during forced expiratory efforts There is reason to suspect that the collateral channels between segments and lobules are routes by which air can thus be forced into obstructed lobules and segments It is generally believed that when a segmental or lobular bronchus is obstructed, the lung distal to the obstruction becomes atelectatic This is not true What is usually interpreted as segmental or lobular atelectasis is merely infection secondary to the interference with the normal drainage of secretions If the obstruction becomes complete before infection develops, the segment continues to receive air from adjacent segments and probably becomes emphysematous rather than atelectatic It seems probable that air can flow through these intersegmental communications on cough and other strong expiratory efforts, and that it is in this manner that obstructed segments and lobules become dilated beyond the maximum inspiratory limit We have observed through the thoracoscope inserted into blebs that the small air passages at the periphery of the lung do open during expiration and close during inspiration This suggests that the same paradoxic mechanism may operate between lobules In this connection it seems worth while to report two instances in which complete obstruction of a segmental bronchus resulted in severe emphysema of the lung distal to the obstruction In one instance we operated upon a young man for what appeared to be a large bleb or cyst at the base of the right lung This had forced the diaphragm down and had crowded the uninvolved normal lung upward At operation it was found that there was a tremendously emphysematous accessory lobe which hung from the lower medial margin of the lower lobe by a pedicle of normal lung tissue The bronchus which should have led into the normal bronchial tree of the accessory lobe ended blindly in the pedicle and the bronchi of the accessory lobe were filled with a pinkish, gelatinous material The accessory lobe was, however, greatly dilated, and since the only air communications between it and the lower lobe were in the parenchyma of the pedicle, one must suppose that air entered through these on strong expiratory efforts more readily than it could leave through them on normal expiration

In the second case the bronchogram revealed complete stenosis of the lower lobe and lingular bronchi At operation the lower lobe was, as would be expected, completely atelectatic The lingula, however, was markedly emphysematous That this was more than a mere compensatory enlargement of the lingula secondary to atelectasis of the lower lobe was evidenced by the fact that the dilated lingula had actively crowded the remainder of the upper lobe into the dome of the pleural cavity

These two cases seem to demonstrate that when in the absence of infection a segmental or lobular bronchus is obstructed and the only air passages into the obstructed lung are through the collateral channels from adjacent segments, the obstructed lung becomes emphysematous and actively emphysematous in that the dilation is greater than that of maximum inspiratory filling

There is another mechanism which works to produce progressive enlargement of lung cysts, emphysematous blebs and emphysema-

Extreme lobar emphysema in infants and small children is an obscure and dramatic condition in which a single lobe which is grossly normal becomes so tremendously dilated that it occupies an entire hemithorax, compressing the adjacent lobes and pushing the mediastinum far to the opposite side. In recent years an increasing number of such cases has been reported. A number of these patients have been operated upon and a relatively normal respiratory status restored by resection of the emphysematous lobe. The etiology and mechanism of the condition is obscure. It is generally believed that the dilation of the lobe is caused by a ball valve obstruction of the lobar bronchus. The confusing thing is that in only one of the cases has an obstruction been found, either by bronchoscopic examination or by examination of the lobes removed at operation or autopsy. In one case Holinger found strands of tissue partially obstructing the bronchus. Removal of these through the bronchoscope corrected the condition. In no other case has any obstruction been demonstrated. Folds of mucosa and abnormalities of the cartilages have been suggested as accounting for obstruction, but these explanations are hypothetic and probably incorrect. It is possible that bronchial obstruction is not the cause. In the ordinary case of locked emphysema such great dilation of a lobe or lung does not and cannot occur. Usually the greatly narrowed bronchus widens on inspiration to permit the entrance of air and closes on expiration to prevent its egress. For this reason the lobe or lung enlarges only to its inspiratory maximum and it is because it does so that the roentgenogram taken on deep inspiration fails to disclose the condition. Any difference in the aeration of the lungs becomes apparent only on a film taken on expiration. Such great dilation of a lobe as is found in this condition presupposes an obstruction which permits air to enter only when the intrabronchial pressure is greatly elevated as in coughing or straining, but which is complete during normal inspiration and expiration. One can conceive of such an obstruction and can conceive that it might produce a locked emphysema of high pressure. If such an obstruction does ever exist, one would expect to encounter it in other conditions and in adults. Therefore, inasmuch as the very existence of this type of ball valve is problematic and no obstruction of any kind is found in these cases, one is justified in suspecting that some other [illegible]

[illegible]

will be developed in a separate section of this paper.

Emphysematous bullae are air sacs within the lung parenchyma which are produced by the breaking down of the interalveolar septa. They are an end result of severe vesicular emphysema. They are often confused with blebs and the terms "bleb" and "bulla" are often used loosely and interchangeably. The conditions are distinct, both in their etiology and patho[illegible]

[illegible]

in a loss of pulmonary elasticity. Its etiology [illegible]

of lobes. These, because of the entrapment of air and because their loss of elasticity permits them to stretch to such size that they crowd and compress the adjacent normal or more nearly normal lung, frequently act to produce dyspnea in the same manner as do giant cysts and blebs. Not only are such emphysematous lung portions functionless in the exchange of gases, but also by occupying space and taking their share of the pulmonary circulation they limit the maximum function of the more normal lung portions. Resection of such lobes or segments is occasionally indicated and in carefully selected cases may result in an important increase in functional vital capacity.

CONSIDERATIONS OF THE ETIOLOGY OF EMPHYSEMA AND THE CAUSES FOR PROGRESSIVE ENLARGEMENT OF CYSTS, BLEBS, BULLAE AND EMPHYSEMATOUS LOBES

I have already stated that the etiology and pathogenesis of vesicular emphysema are obscure. Pathologically, as first noted by Laennec, the lungs are dilated, they are inelastic and do not collapse when removed from the thorax. The alveoli are enlarged and interalveolar septa are here and there broken down to form smaller or larger bullae. Laennec suggested that the condition was produced by ball valve obstruction of the bronchioles by viscid secretions. He noted, however, that occasionally cough and secretions were absent.

Extreme lobar emphysema in infants and small children is an obscure and dramatic condition in which a single lobe which is grossly normal becomes so tremendously dilated that it occupies an entire hemithorax compressing the adjacent lobes and pushing the mediastinum far to the opposite side. In recent years an increasing number of such cases has been reported. A number of these patients have been operated upon and a relatively normal respiratory status restored by resection of the emphysematous lobe. The etiology and mechanism of the condition is obscure. It is generally believed that the dilation of the lobe is caused by a ball valve obstruction of the lobar bronchus. The confusing thing is that in only one of the cases has an obstruction been found either by bronchoscopic examination or by examination of the lobes removed at operation or autopsy. In one case Holinger found strands of tissue partially obstructing the bronchus. Removal of these through the bronchoscope corrected the condition. In no other case has any obstruction been demonstrated. Folds of mucosa and abnormalities of the cartilages have been suggested as accounting for obstruction but these explanations are hypothetic and probably incorrect. It is possible that bronchial obstruction is not the cause. In the ordinary case of locked emphysema such great dilation of a lobe or lung does not and cannot occur. Usually the greatly narrowed bronchus widens on inspiration to permit the entrance of air and closes on expiration to prevent its egress. For this reason the lobe or lung enlarges only to its inspiratory maximum and it is because it does so that the roentgenogram taken on deep inspiration fails to disclose the condition. Any difference in the aeration of the lungs becomes apparent only on a film taken on expiration. Such great dilation of a lobe as is found in this condition presupposes an obstruction which permits air to enter only when the intrabronchial pressure is greatly elevated as in coughing or straining but which is complete during normal inspiration and expiration. One can conceive of such an obstruction and can conceive that it might produce a locked emphysema of high pressure. If such an obstruction does ever exist one would expect to encounter it in other conditions and in adults. Therefore inasmuch as the very existence of this type of ball valve is problematic and no obstruction of any kind is found in these cases one is justified in suspecting that some other mechanism accounts for these greatly dilated lobes. The theory that a congenital or acquired loss of elasticity permits them to stretch to this size will be developed in a separate section of this paper.

Emphysematous bullae are air sacs within the lung parenchyma which are produced by the breaking down of the interalveolar septa. They are an end result of severe vesicular emphysema. They are often confused with blebs, and the terms bleb and bulla are often used loosely and interchangeably. The conditions are distinct both in their etiology and pathogenesis, and their treatment is entirely different.

Vesicular emphysema is a dilation of the alveoli. It is either caused by or always results in a loss of pulmonary elasticity. Its etiology [illegible]

of lobes. These because of the entrapment of air and because their loss of elasticity permits them to stretch to such size that they crowd and compress the adjacent normal or more nearly normal lung, frequently act to produce dyspnea in the same manner as do giant cysts and blebs. Not only are such emphysematous lung portions functionless in the exchange of gases but also by occupying space and taking their share of the pulmonary circulation they limit the maximum function of the more normal lung portions. Resection of such lobes or segments is occasionally indicated and in carefully selected cases may result in an important increase in functional vital capacity.

CONSIDERATIONS OF THE ETIOLOGY OF EMPHYSEMA AND THE CAUSES FOR PROGRESSIVE ENLARGEMENT OF CYSTS, BLEBS, BULLAE AND EMPHYSEMATOUS LOBES

I have already stated that the etiology and pathogenesis of vesicular emphysema are obscure. Pathologically as first noted by Laennec the lungs are dilated, they are inelastic and do not collapse when removed from the thorax. The alveoli are enlarged and interalveolar septa are here and there broken down to form smaller or larger bullae. Laennec suggested that the condition was produced by ball valve obstruction of the bronchioles by viscid secretions. He noted however that occasionally cough and secretions were absent

The modern conception of the etiology and pathogenesis of vesicular and bullous emphysema is similar to that advanced by Laennec It is spoken of as obstructive emphysema, and obstruction of the finer air passages either by secretions, edema or spasm is predicated There is considerable evidence to support this theory, but that the process is as simple as this seems improbable It is true that most patients afflicted with this condition have had a chronic cough for many years prior to the development of the emphysema Without having definite asthma, most of them have a prolonged expiratory phase, some wheezing and a reduction in maximum breathing capacity which is out of proportion to the reduction in vital capacity These all speak for expiratory obstruction of the finer air passages, as does the fact that antispasmodic drugs increase the vital capacity On the other hand, some patients have no cough or expectoration, and in bronchial asthma, the condition which would seem most likely to produce it, severe emphysema is rare Most patients do not have and have never had bronchial asthma It is also difficult to understand how a ball valve obstruction which permits air to enter the alveoli more easily than it can leave them would result in such extreme dilation In locked emphysema of this type the alveoli can be dilated only to the inspiratory maximum It seems probable that dilation beyond this point necessitates a mechanism whereby air is forced into them during forced expiratory efforts There is reason to suspect that the collateral channels between segments and lobules are routes by which air can thus be forced into obstructed lobules and segments It is generally believed that when a segmental or lobular bronchus is obstructed, the lung distal to the obstruction becomes atelectatic This is not true What is usually interpreted as segmental or lobular atelectasis is merely infection secondary to the interference with the normal drainage of secretions If the obstruction becomes complete before infection develops, the segment continues to receive air from adjacent segments and probably becomes emphysematous rather than atelectatic It seems probable that air can flow through these intersegmental communications on cough and other strong expiratory efforts, and that it is in this manner that obstructed segments and lobules become dilated beyond the maximum inspiratory limit We have observed through the thoracoscope inserted into blebs that the small air passages at the periphery of the lung do open during expiration and close during inspiration This suggests that the same paradoxic mechanism may operate between lobules In this connection it seems worth while to report two instances in which complete obstruction of a segmental bronchus resulted in severe emphysema of the lung distal to the obstruction In one instance we operated upon a young man for what appeared to be a large bleb or cyst at the base of the right lung This had forced the diaphragm down and had crowded the uninvolved normal lung upward At operation it was found that there was a tremendously emphysematous accessory lobe which hung from the lower medial margin of the lower lobe by a pedicle of normal lung tissue The bronchus which should have led into the normal bronchial tree of the accessory lobe ended blindly in the pedicle and the bronchi of the accessory lobe were filled with a pinkish, gelatinous material The accessory lobe was, however, greatly dilated, and since the only air communications between it and the lower lobe were in the parenchyma of the pedicle, one must suppose that air entered through these on strong expiratory efforts more readily than it could leave through them on normal expiration

In the second case the bronchogram revealed complete stenosis of the lower lobe and lingular bronchi At operation the lower lobe was, as would be expected, completely atelectatic The lingula, however, was markedly emphysematous That this was more than a mere compensatory enlargement of the lingula secondary to atelectasis of the lower lobe was evidenced by the fact that the dilated lingula had actively crowded the remainder of the upper lobe into the dome of the pleural cavity

These two cases seem to demonstrate that when in the absence of infection a segmental or lobular bronchus is obstructed and the only air passages into the obstructed lung are through the collateral channels from adjacent segments, the obstructed lung becomes emphysematous and actively emphysematous in that the dilation is greater than that of maximum inspiratory filling

There is another mechanism which works to produce progressive enlargement of lung cysts, emphysematous blebs and emphysema-

tous lung This may be stated as follows Whenever an air filled cavity within the lung or a portion of lung is stretchable but inelastic it will stretch progressively under the forces of respiration and in so doing will compress and crowd the lung which is normally elastic It has been generally assumed that giant balloon cysts and giant emphysematous lobes have increased in size because of pressure developed within them by a ball valve occlusion of the bronchus In the case of the giant emphysematous lobes encountered in infants no such obstruction has been found and measurement of pressure within giant lung cysts reveals that it is plus and minus zero This means that there is a free ingress and a free egress of air These cysts which comprise no more than a single segment of a lobe are small at birth They expand to their maximum size in the first few weeks We have seen serial x rays of one such case in which a small cyst in the middle lobe enlarged to occupy the entire hemithorax in the course of three weeks The actuality of this dilation by stretching can be demonstrated by employing a variation of the classical vacuum bottle representation of the mechanics of respiration If three glass tubes are inserted through the stopper and to two of these are attached finger cots of different degrees of [illegible] and empties less completely than that which is more elastic until in a short time it has enlarged to fill the bottle

It seems possible even probable, that this mechanism accounts for the giant cysts and for the giant emphysematous lobes of infants In vesicular emphysema once the lung portion has lost its elasticity this mechanism undoubtedly accounts for a further increase in size of this stretchable but inelastic lung

TREATMENT

Giant lung cysts usually represent a single segment of a single lobe In their treatment lobectomy is the most that is usually required and in many instances these cysts can be peeled away from the adjacent segments and removed without sacrificing even a lobe

Emphysematous blebs can be treated either by intracavitary suction or by open operation The former method is indicated for large solitary blebs and in cases in which dyspnea is so extreme as to contraindicate major surgery Open operation with amputation of the blebs and suturing of the pleural edges is indicated when the blebs are multiple and the patient s condition is such as to warrant major surgery

Vesicular emphysema is rarely generalized in the sense that all of both lungs are equally involved It is usually symmetric in any given case either both apices or both bases being the seat of the severest disease In some cases the remainder of the lungs are relatively normal and are functional and elastic In such cases the dilated inelastic emphysematous portions are a hindrance rather than a help to respiration They compress the good lung they limit the movement of the chest wall they force down the diaphragm and they utilize a portion of the air exchange and the pulmonary blood flow without adding to the exchange of gases They also cause cough In all ways they are a hindrance rather than a help Removal of such lobes or portions of lobes can result in an appreciable and important increase in functional vital capacity The selection of cases is difficult and extremely important One must be sure that he is going to increase the vital capacity rather than decrease it

Lobectomy is rarely necessary The extremely affected lung portions rarely comprise more than a few segments Segmental resection as usually performed without suturing of the lung surfaces is not feasible in an emphysematous lung It is our practice to place an intestinal clamp at the line at which the lung is to be resected and to run a continuous Roux suture just proximal to it This overlapping suture is both hemo- and aerostatic It eliminates the dangers of blood leakage into the lung and air leakage into the pleura

SUMMARY AND CONCLUSIONS

1 Giant lung cysts giant emphysematous blebs and vesicular and bullous emphysema localized to lobes or segments frequently produce severe dyspnea

2 All of these conditions are amenable to surgical treatment

3 Original theories are advanced for the progressive enlargement of these air filled sacs and also for the pathogenesis of vesicular and bullous emphysema

Pulmonary Air Cysts—A Therapeutic Concept

DAVID J DUGAN M D AND KENNETH L HARDY, M D, *Oakland, California*

THE subject of air cysts of the lung has been ably covered in the literature It is the purpose of this chapter, however, to review collectively the voluminous array of data on the topic and to relegate the mass of information to an orderly and reasonable understanding For practical therapeutic purposes we shall attempt to classify the subject into its simplest terms The trinity of classification diagnosis and treatment will then form a unity of logical thought

Because we believe that there is no acceptable surgical procedure for the treatment of diffuse pulmonary emphysema our remarks on this topic will be concise and pertinent We will limit our main thoughts to the cases of localized (single or multiple) pulmonary air containing spaces in which initially at least the remaining lung tissue is functionally, grossly and microscopically normal

We have chosen the all inclusive term air cyst because of its generic ability to represent all of the conditions under discussion recognizing that its causation may be emphysema tous congenital bronchiectatic or traumatic We believe that this eliminates the etiologically implicating terms of bleb bulla congenital cyst pneumatocele tension cyst etc which have hitherto been used with free and often confusing interchange in the literature

These air cysts may originate in any of the following four ways (1) by extensive coalescing fragmentation of interalveolar septa resulting in an intrapulmonary emphysematous bulla in which the wall is formed by ragged adjacent lung (2) by subpleural dissection into the visceral pleura forming an emphysematous bleb with a mesothelial wall (3) by further development of a bronchiectatic sac which dilates from ball valve bronchial communication or (4) by a congenital developmental arrest resulting in an air cyst with a true fibrous epithelium lined capsule Whether or not the etiology of an individual air cyst is due to one of the foregoing mechanisms is a moot question from the therapeutic point of view

The presence of pulmonary air containing spaces or air cysts carries with it the potential of four very real hazards[1] regardless of their mode of formation namely, (1) disturbance in pulmonary function (2) infection, (3) rupture and (4) hemorrhage, Although these dangers are modified by the nature of the air cyst in varying degree, we can on clinical grounds alone only conjecture as to their etiology when the remaining lung tissue is otherwise normal and therefore must consider these threats equally in our therapeutic thinking

A Bleb Bulla Pneumatocele Tension cyst Giant cyst Localized hyperlucent emphysema Balloon cysts Adenogenous cyst					Air cyst
B Etiology		Disturbance in Pulmonary Function	Infection	Rupture	Hemorrhage
Air Cyst	Emphysematous bleb or bulla	May be great	Rare	Frequent	Occasional
	Congenital cyst or group of cysts	Varied	Frequent	Occasional	Common if infected
	Bronchiectatic	May be great	Frequent	Rare	Frequent
	Traumatic foreign body or direct chest wall trauma	Frequent	Frequent	Rare	Rare

With the foregoing classification in mind, purposely simplified in order to emphasize certain therapeutic implications let us examine the possible future of these localized (single or multiple) air containing spaces

DISTURBANCE IN PULMONARY FUNCTION

Disturbance in pulmonary ventilation resulting from these air cysts is dependent primarily upon the nature of the bronchial communication and the state of the remaining lungs This is succinctly brought out by Bald

win and co-workers[4] in a careful physiologic study of sixteen cases, which they divided from the functional standpoint into three groups

Their group I cases, in which the bronchial communication is free and patent and the remaining lungs are normal, represent a functional aberration due to dead space aeration which is roughly proportional to the size of the cyst As can be demonstrated manometrically, these cases do not develop increased tension, but they may undergo progressive enlargement at the expense of the adjacent previously normal lung Head and Avery's hypothesis,[19] based on direct pressures and thoracoscopic visualization, in which the cyst is seen to enlarge during expiration, further corroborates this observation Their explanation is substantiated anatomically by the careful histologic studies of Liebow and associates,[22] who demonstrated increase in musculature of the cyst walls in emphysema at the expense of elastic tissue and vascular supply

In Baldwin's group II cases, in which the bronchial communication is imperfect or intermittent but the remaining lungs are normal, the factor of tension may become extreme due to a one way bronchial valve-like mechanism Air trapping, paradoxic respiration compression of previously normal adjacent lung, mediastinal shift and increased pulmonary vascular resistance with resultant right heart strain may then occur

Their group III is composed of cases associated with diffuse emphysematous involvement of both lungs in which air cysts (blebs or bullae in this instance) are merely scattered exaggerations of a generalized disease They further divide this group into (1) those with primary ventilatory insufficiency and (2) those with combined ventilatory and alveolar insufficiency It is in the former subgroup that judicious surgical removal of a localized cyst or cysts which have undergone enlargement or tension may be extremely helpful In the second subgroup, however, we heartily agree with Baldwin that no logical surgical therapy is available at the present time

Disturbance in pulmonary function is of prime concern at any age, but its severity is often magnified in the infant [2 30] Of particular interest is the follow up on a three month old infant reported by one of us (D J D) in 1947 This child (Case 1) had acute respiratory embarrassment which became more severe over a two- to three-week period Chest roentgenogram (Fig 1) revealed a complete absence of lung markings in the left hemithorax with mediastinal shift and compression of the right lung Needle aspiration as well as tube drainage on the left were unsuccessful Thoracotomy was performed and a large air containing cyst was revealed This occupied the basilar segments of the left lower lobe and the remaining segments were normal except for compression atelectasis The cystic area was removed by segmental resection and Figure 2 shows the x-ray appearance of the chest six years later The child is asymptomatic and the film is considered within normal limits without evidence of residual emphysema

INFECTION

From the standpoint of infection, certain of these air-containing spaces represent a definite threat As has been pointed out by several workers, the tendency of air cysts due to emphysema to develop suppuration is rare [28] although we have personally seen it occur in two cases These patients were markedly distressed by the superimposition of pulmonary sepsis on an already impaired ventilatory situation Both were functionally improved and also cured of their infection by conservative pulmonary resection There is a great tendency of epithelium lined cysts however, to undergo suppuration This is particularly true when their bronchial communication is poor Many of these patients are diagnosed as having chronic lung abscess Certainly this etiologic train of events should be considered when thinking of lung abscess, especially in young individuals who give no antecedent history of aspiration or pneumonitis

Certainly, also, the reported cases[10 27 31] in which bronchiectatic sacs have undergone tremendous overexpansion from tension due to the nature of the bronchial communication, are associated with chronic infection

Pierce and Dirkse[23] reported four cases of pulmonary pneumatocele following pneumonitis Although this is a theoretic possibility, one wonders if the actual nature of the situation was not one of suppuration in a pre-existing cyst Perhaps the cyst, temporarily filled with exudate, was surrounded by pneumonitis and only later discharged its contents through a bronchus, the cyst then becoming apparent

1 2

FIG 1 Case I Chest roentgenogram showing g ant tens on cyst occupy ng entire left hem thorax in a three month old infant

FIG 2 Same case Chest film taken six years following roentgenogram shown in Figure 1 Note absence of residual pulmonary emphysema

for the first time This sequence probably occurs more frequently than we suspect

A situation which well demonstrates the development of infection in a localized air cyst is illustrated in Case II This forty six year old woman had knowledge that she was harboring an air cyst in her left chest for approximately seven years She had been under competent medical observation during this time and refused any definitive treatment in spite of progressive shortness of breath During the seventh year of her observation she began experiencing intermittent episodes of chills fever and cough productive of purulent sputum Fluoroscopic exam nations revealed small collections of fluid within the cyst at intermittent intervals although the fluid did not collect in any great amount It was thought that evacuation of the cystic area was being accomplished intermittently by means of a fairly large bronchial communication This impression was substantiated by the chest roentgenogram taken during an ep sode of fever and productive cough (Fig 3) She then consented to surgery At thoracotomy a huge air cyst was found originating from the apico posterior segment of the left upper lobe markedly compressing an otherwise normal lung Segmental resection was performed thereby removing the infected cyst in *toto* The large communicating apicoposterior bronchus was closed in routine fashion and she had excellent re expansion of the remaining lung The surgical specimen showed inflammatory necrosis of the wall which was a pseudocapsule of compressed pulmonary parenchyma The patient is now asymptomatic and the postoperative film is shown in Figure 4

RUPTURE

Danger of rupture is always present in those lesions with poor bronchial communication which develop tension Pleural symphysis is rare over these cysts [19] and rupture is frequently and dramatically followed by tension pneumothorax and its train of disastrous events [17 31 35] Occasionally re expansion of the

3 4

FIG 3 Case ■ Large cystic area in left chest present for seven years Heavy infiltration at left card e bord r ind cative of secondary infection

FIG 4 Same case Postoperative film follo v ng left ap cal poster or segmental resect on for suppurat ve g int cyst

lung may occur due to bronchial distortion or local tissue-flap circumstances following rup ture and normal intrapleural relationships will be restored without medical aid It is apparent that such a fortuitous outcome can not be predicted with certainty and the rarity of its occurrence would make its prediction therapeutically treacherous

HEMORRHAGE

In general the pulmonary les ons under dis cussion are seldom complicated by hemor rhage [1] In the emphysematous cases perhaps the avascularity of the cyst wall[21] itself accounts for the infrequency of this complica tion The occurrence of hemorrhage is most probable after secondary infection has caused tissue necrosis and vascular erosion in the wall of the lesion Spontaneous bleeding how ever will rarely be the cause of massive hemoptysis Such a process may radiographi cally simulate lung abscess with fluid level Spontaneous hemopneumothorax following rup- ture of an emphysematous bleb with persistent bleeding from a torn intercostal branch artery caused by stretching of chest wall adhes ons may be extremely dramatic Persistent bleed ng from the high pressure systemic vessel in sp te of conservative therapy may require early exploration [29]

The complicating factors of rupture and hemorrhage are best demonstrated in a single case previously reported (Case III) Th s twenty seven year old man experienced sudden left chest pain with dyspnea and prostration Initial chest x rays revealed hydropneumo- thorax on the left with some mediastinal com pression (Figure 5) Thoracentesis was ini tially productive of 1 000 cc of blood and repeated aspirations over a three day period failed to improve the situation Because of the continuing blood loss thoracotomy was per formed and a small cyst of the superior segm ent of the left lower lobe was found Within taut adhesions over the cyst a small arterial blood vessel was revealed which was responsible for the massive persistent hemor rhage Segmental resection of the cystic area and control of the responsible vessel was followed by complete expansion of the left lung and recovery (Fig 6)

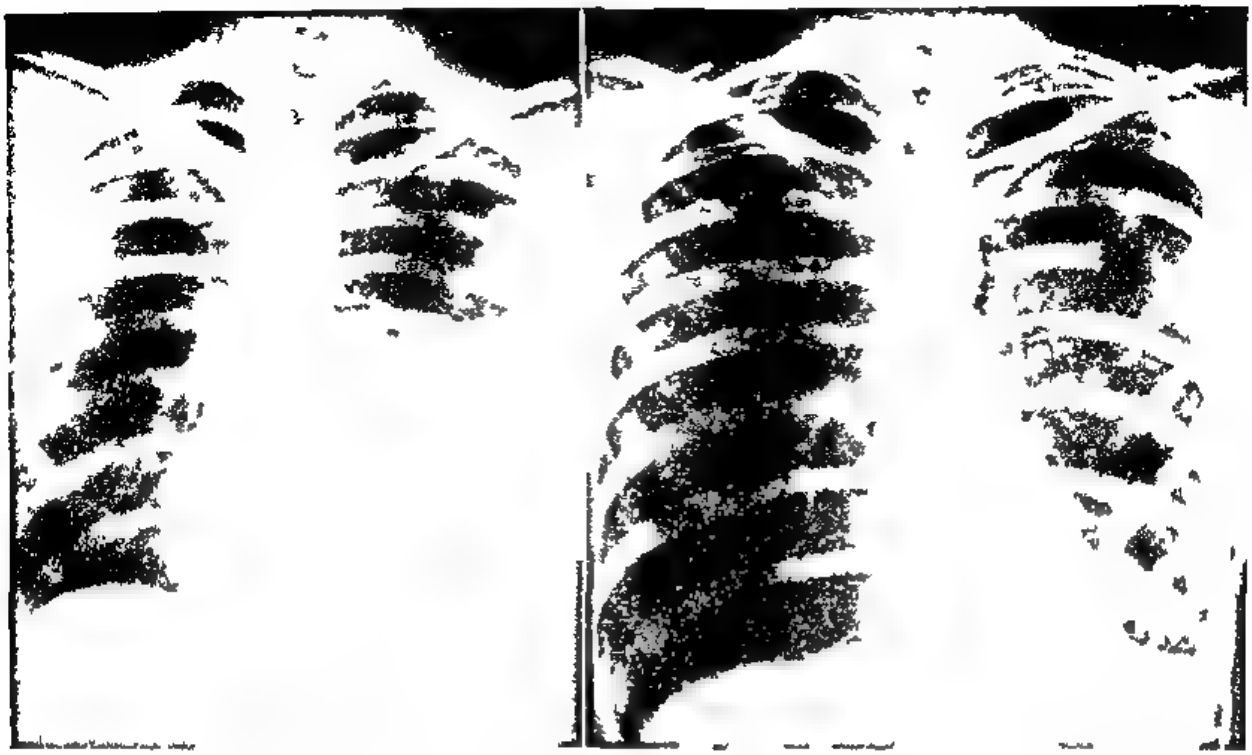

5 6

FIG 5 Case 1 1 Chest roentgenogram showing hydropneumothorax due to rupture of a r cyst and hemorrhage

F G 6 Same case Postoperat ve appearance of chest following thoracotomy for resect on of ruptured and bleed ing cyst

DIAGNOSIS

The vast majority of patients with air cysts present no particular diagnostic problem Conventional chest roentgenograms will in most instances clearly demonstrate the bound aries and extent of these air containing spaces It is of importance hov ever to point out certain pitfalls and offer a few suggestions that might aid in more accurate evaluation of these les ons Single small localized cystic areas disclosed during routine x ray exam na tions warrant careful cons deration These asymptomatic lesions may be harmless and usually present no immediate therapeut c problem In such cases a program of serial x ray examinations should be pursued having in m nd surgical intervention only if progres sive f lms demonstrate cons stent or sudden enlargement Failure to follo v such cases may result in the needless sacrifice of pulmonary tissue if a progressively enlarging air space is allowed to rob adjacent pulmonary paren chyma A demonstrat on of such a course of events was illustrated in one of our cases in which a program of watchful expectancy car ried out elsewhere followed a relatively small air space in the right apex to the state of com plete vanish ng of the right lung over a period of twenty four months Early surgery when progression was radiolog cally obvious might well have saved the eventual pneumonectomy

In contradistinction to this sequence indi vidual cysts may remain quiescent over many years and deserve attention in the consistently asymptomatic patient only by roentgen ob servation This recommendation for conserva tism in an unchanging situation presupposes that d agnost cally confus ng les ons [6] such as thin walled coccidioidal echinococcal tuber culous or non specific (possibly carcinomatous) burned out abscess cavities have been excluded by studies not pertinent to this discuss on Where etiology is still in doubt local zed excision for exact diagnosis is the conservative approach

Special x ray technics are often helpful in [illegible] localized cysts may be helpful Occasionally lateral decubitus films after the institution of

diagnostic pneumothorax may serve to differentiate pericardial and bronchogenic cysts from the group of pulmonary air containing spaces pertinent to this discussion The simple employment of the underexposed film as recommended by Head is frequently very helpful

Diagnostic needling of air cysts is seldom indicated and in some instances may result in disaster [26] The danger lies in the sudden rupture of the cyst wall with bronchopleural fistula, *tension pneumothorax and sudden* death from mediastinal compression [20] Maier and associates have brought out the diagnostic advantage of needling fluid filled cystic cavities when the question of empyema exists [15] Such a maneuver is helpful but sudden interference with the intrapleural or intrapulmonary pressure should never be attempted without adequate facilities available for immediate tube drainage or thoracotomy as the situation warrants

Bronchoscopy has been condemned in the past on the theoretic grounds of possible rupture of a cyst due to increased intrabronchial pressure and strain Although rupture is possible by such a means we have not seen it occur during or following bronchoscopic procedures The possibility of a foreign body or other remedial bronchial pathologic condition contributing to the development of the air cyst is of sufficient prominence to commend the routine use of bronchoscopy in all cases in *which secondary bronchial obstruction is in* question [8]

Mention should also be made of the rare instance in which an air cyst with tension in the left lower lobe in the neonatal period may be confused with congenital diaphragmatic hernia Multiple fluid levels and concentric air spaces in the left pleural cavity occurring in an infant should arouse suspicion as to the likelihood of diaphragmatic herniation with the presence of bowel in the thorax Needle aspiration in such a case is definitely contraindicated and barium studies are usually diagnostic

Fluoroscopic examination of the patient in the upright position is one of the most valuable aids in the study of these air cysts The normal *respiratory excursions may be carefully* observed and the relative function of both lungs and diaphragms estimated Air trapping, representative of ball valve bronchial communication, *can be demonstrated by paradoxic* mediastinal movement on the inspiratory effort Such an observation would indicate the likelihood of continued growth of such a cyst while the absence of paradox and the diminution in the size of the radiolucent area would tend to assure its static character, for the moment at least The Valsalva maneuver in this situation is also valuable in the fluoroscopic evaluation of these lesions

Bronchography is of disputable worth in the *preoperative investigation of an individual* with an air cyst We have found that these air containing spaces seldom have a bronchographically demonstrable communication and its presence or absence is rarely of immediate surgical importance When the procedure is employed however, post tussive and twenty four hour films will often show intracavitary oil when the initial films fail to demonstrate bronchial communication It has been our experience that in general the cases which are *representative of this discussion do not* present associated chronic pulmonary disease, and we therefore have not used bronchography routinely in their diagnosis If, however, in an individual case we believe that more accurate x ray visualization of the adjoining or contralateral lung is of importance because of the possibility of bronchiectasis we do not hesitate to do bronchography, provided the decision for surgical intervention has been made This then may be helpful in influencing the extent of surgical resection Although the ventilatory interference of lipiodol and similar oily media is an objection to their use, especially in individuals with borderline pulmonary function we have not hesitated to use these compounds if the indications as outlined heretofore were present The objection to these agents together with the flocculent alveolar oil retention which so often persists may be overcome by the use

these cases we have employed angiocardiography as described by Miscall [25] By such studies an estimate can be made of the integrity of the compressed adjacent lung by assaying the pulmonary vascular pattern In certain rare instances such a study is of particular advantage, however, we believe that in most cases the careful use of fluoroscopy and routine roentgen films can give us information that is

diagnostically satisfactory and therefore are hesitant to use the not entirely harmless intravenous radiopaque dye routinely

THERAPY

Conservative means of attacking these lesions have been successful in the past[14 24 25] in which needle aspiration was followed by apparent rupture and lung re-expansion Although such results have been reported the dangers of tension pneumothorax and its sequelae far outweigh the hazards of exploratory thoracotomy We now believe that exploration and surgical excision is the treatment of choice[11 20 26] As was first pointed out by Dugan and Samson in 1947[5] those patients whose air cysts have developed tension immediately improve upon opening of the chest[10]

approach In the instance of multiple localized cysts b segmentectomy or lobectomy, at most may be in order Occasionally when multiple cysts not confined to a single lobe are found or where contrary to preoperative evaluation the remaining ipsilateral lung is emphysematous the local excision and plication imbrication techniques is probably the most beneficial and function sparing method Except in rare instances Monaldi drainage[9] or endocutaneous flap procedures[7] are obsolete in our opinion One could conceive of a large infected cyst in a debilitated individual in which Monaldi drainage might be used as a temporary expedient These procedures require meticulous and prolonged attention extended morbidity and are always complicated by infection and chronic pleural reactions not seen with modern resection technics They were logically proposed at a time when intrathoracic procedures carried a somewhat higher risk than at the present time The emergency use of an intracavitary catheter may be life saving in certain instances[3] where tension in a single cyst is

[illegible] a [illegible] Avery of a two-stage Monaldi type drainage procedure is indicated today

A few words regarding the surgical treatment of generalized hypertrophic pulmonary emphysema[18] are germane to a discussion of this nature We believe that in certain cases of this disease single or localized cysts which have further compromised already damaged emphysematous lung by undergoing tension warrant surgical consideration[4 11] Their removal may be beneficial by reducing to a degree dead space aeration This presupposes that the patient has enough pulmonary reserve to survive the early postoperative period and functionally does not fall into Baldwin s group IIIB It also implies that the removal of the offending cysts will be performed by the most lung conserving technics possible that is by local excision imbrication segmental resection or at the most lobectomy It must be emphasized that surgery in these cases is palliative not curative but in well chosen instances may afford the patient a higher level of exercise and pulmonary tolerance

We do not believe however that any surgical procedure has yet been devised which will regenerate the emphysematous lung We agree with Carter[3] that the problem in these patients is ventilatory and not vascular and is most probably based on a yet unexplained loss of pulmonary elastic tissue as emphasized by Liebow[16] Certainly bronchiolar obstruction fits somewhere into the picture

vascular anastomoses in this disease Liebow has demonstrated these anatomically showing a tremendous increase on the venous side (bronchial vein pulmonary vein) and a definite although lesser increase on the arterial side (bronchial artery pulmonary artery) This allows for chronic by pass desaturation from the right to left auricles in the case of the venous anastomoses On the other hand the arterial anastomoses represent a conglomerate fistula which only adds to the effort of the heart already laboring under the threat of cor pulmonale It would seem unwise to augment surgically such a mechanism

We therefore on theoretic grounds alone cannot understand the proposal of advocating pleurectomy and poudrage in the treatment of emphysema In the few instances in which

such a procedure resulted in significant systemic pulmonary anastomoses, as disclosed by postmortem examination it is logical to assume that the cardiac burden in those patients was thereby increased The output and work load of the left heart was further raised to a degree proportional to the magnitude of the existing shunt plus the created shunt There is absolutely no evidence to indicate that actual regeneration of functioning lung tissue takes place following poudrage nor can the procedure be shown to prevent the continuing breakdown of intra alveolar septa in the relentless emphysematous process There is likewise no indication that systemic blood oxygenation is increased by another mechanical circuit through a lung already effete as far as alveolocapillary transfer is concerned

nothing to offer in the surgery of pulmonary emphysema

SUMMARY

Assignment of the generic term air cyst to the group of intrapulmonary space occupying air containing lesions is done in an attempt to classify the subject into its simplest terms for sound therapeutic comprehension We recognize that air cysts may be emphysematous bronchiectatic congenital or traumatic but since we cannot predict their etiology with certainty until viewed histologically their clinical and therapeutic understanding must have in mind their fate if left unattended In the light of present day thinking we believe that their tendency to cause disturbance in pulmonary function to undergo suppuration rupture or hemorrhage makes their surgical excision mandatory We have indicated the applicable resection techniques and have likewise stressed the futility of surgical attack in diffuse pulmonary emphysema except in certain definite situations

REFERENCES

1 ALLBRITTEN F F JR. and TEMPLETON J Y Treatment of giant cysts of the lung *J Thoracic Surg* 20 749 1950

2 ALLISON S T The vanishing lung report of a case of advanced bullous emphysema *Ann Int Med* 17 139–148 1942

3 ANSPACH W E and WOLMAN I J Large pulmonary air cysts of infancy with special reference to pathogenesis and diagnosis *Surg Gynec & Obst* 56 635–645 1933

4 BALDWIN E DEF HARDIN A., GREENE, D G COURNAND A and RICHARDS D W JR Pulmonary insufficiency IV A study of 16 cases of large pulmonary air cysts or bullae *Medicine* 29 169 1950

5 BARTHOLINUS T Malpighi *Opera Omnia* pp.

6

7 ment of large pulmonary air cysts (balloon cysts) by an end cutaneous flap *J Thoracic Surg* 11 617 1942

8 BURKE R M Vanishing lungs a case report of

9

10

11

12 management of pulmonary emphysema *J Thorac & Surg* 24 398 1952

13 CRENSHAW G L Degenerative lung disease *Dis J Chest* 25 443 1954

14 CROSWELL and KING Congenital air cyst of the lung *J A M A* 101 832 1933

15 DUGAN D J and SAMSON P C The surgical treatment of giant emphysematous blebs and pulmonary tension cysts *J Thoracic Surg* 20 729 1950

16 FREEDMAN E Emphysematous blebs and bullae *Am J Roentgenol* 35 324 1936

17 GOUGH J Fatal pneumothorax due to rupture of a solitary bulla of the lung *Lancet* 2 314 315 1937

18 HARRIS H J Extensive destruction of lungs emphysema with giant bullae autopsy *Radiology* 36 492 494 1941

19 HEAD J R and AVERY L F Intercavitary suction (Monaldi) in the treatment of emphysematous bullae and blebs *J Thorac Surg* 18 706 1949

20 KOROL E and EASON C F Bullous emphysema or bilateral pneumothorax *Radiology* 23 223 227 1934

21 LIEBOW A A The bronchopulmonary venous collateral circulation with special reference to emphysema *Am J Path* 29 251 1953

22 LIEBOW A A LORINO W E and FELTON W L II The musculature of the lungs in chronic pulmonary disease *Am J Path* 29 889 953

23 LLOYD M S Bullous emphysema case report *J Thoracic Surg* 18 532 1949

24 MILLER H T JR. Congenital cyst of lung *Ann Surg* 12 392 1926

25 MISCALL L and DUFFY R W Surgical treatment

26

Emphysematous blebs and bullae *Surgery* 1947

27 PARMELEE, A H and APPELBACH, C W Congenital air cyst of the lung *Am J Dis Child*, 41 1380 1931
28 PIERCE and DIRKSE Pulmonary pneumatocele (localized alveolar or lobular ectasia) *Radiology* 28 651, 1937
29 ROSS J, DUGAN D J and FARBER, J E Spontaneous hemopneumothorax with early thoracotomy case report *Dis of Chest* 23 577 1953
30 SHAW R R Localized hypertrophic emphysema *Pediatrics* 9 220 1952
31 SWANSON L E PLATAU F S and SADLER, W Congenital cyst of the lungs *Am J Dis Child*, 35 1024, 1928
32 TYSON, M D The surgical management of solitary cysts or cyst like structures of pulmonary origin *Ann Surg*, 118 50–75, 1943
33 VOLLMER H Zytische Lungengebilde im Kindesalter *Ztschr f Kinderh* 46 810, 1928
34 WARRING F C JR. and LINDSKOG G E Surgical management of giant air cysts of the lungs *Am Rev Tuberc*, 63 579, 1951
35 WILCOX, A and FOSTER CARTER A F Spontaneous pneumothorax associated with bullous emphysema *Lancet* 2 315 317 1937

Infected Cystic Disease

RICHARD H MEADE, M D, *Grand Rapids, Michigan*

SINCE the adoption, in a widespread way, of routine chest x-rays, pulmonary cysts have become commonplace For years the literature has been full of articles on pulmonary cysts, in their various forms and with their varied complications The related subject of infected cystic disease of the lung has received little attention In an article published in 1953[1] the subject was discussed on the basis of nine cases in which resection had been used It was our impression then that the condition was a common one Since then however, only eight more patients have been treated These have been similar to the earlier ones, and together with them supply the material for this article

By "cystic disease of the lung" is meant a condition in which there is replacement of normal lung tissue by multiple cysts of various sizes Such a disease does not give rise to symptoms unless a large amount of the lung is involved Even when there is extensive bilateral involvement there may be no definite symptoms This is also true of simple pulmonary cysts However, when infection of this cystic tissue occurs, the result is pneumonitis which does give symptoms, and once this area becomes infected, it rarely if ever returns to normal An area of cystic disease is functionless The normal mechanism for the removal of secretions is lacking Although the cysts are usually lined with ciliated columnar epithelium, there is no apparent connection between the cystic area and the bronchial tree The bronchioles in the area are either absent or undeveloped Such tissue, therefore, cannot withstand the insults of infection even though antibiotics may temporarily sterilize it The result of this infection is chronic pneumonitis, and in practically every one of our cases this

recurrent attacks of pneumonia, whereas the others had an onset suggesting pneumonia followed by a chronic cough productive of purulent sputum, or else merely began coughing and continued to do so with production of sputum In many cases the symptoms were insignificant and the only thing that brought the patient to us was the finding of an abnormal shadow in the x-ray of the chest Medical treatment is of value in controlling the infection but curative therapy is limited to resection of the involved part of the lung Of the seventeen cases in which operation was carried out all excep

their

from

use of intravenous fluid following the operation

Whether or not the cysts are of congenital origin is of no clinical importance but of real academic interest Certain solitary cysts, which are lined with ciliated columnar epithelium and have in their walls islands of tissue resembling fetal lung, are generally accepted as being congenital in origin However, when the argument for congenital origin depends purely on the finding of columnar epithelium lining the cysts, there is reason for a difference of opinion It is true that cystic areas may develop as the result of infection, and cystic bronchiectasis may at times present a picture resembling infected cystic disease It is our impression that the patients upon whom we

into this controversial subject

COURSE OF THE DISEASE

There has been a fairly definite pattern to the disease in the seventeen patients whom we have treated The onset has usually been

rather

virus

been

short, and symptoms have quickly subsided after the use of various antibiotics Complete recovery has not always occurred, the patient continuing to be tired and having a cough When

the first illness

ing

ted

wn

for

study In those instances in which there has

been complete recovery from the initial illness no x-rays have been taken It has only been when there has been a recurrence of trouble that x rays have been taken If there were x rays in the first illness, it is seen that the shadow which was present then is still present The other patients who had an insidious onset of their symptoms have usually been considered to have chronic bronchitis and no x-rays have been taken until the symptoms have persisted for a long time Here again it is the x ray appearance which sends the patient in for special study There are no characteristic symptoms, but it is rather striking that eight of fourteen adults had expectoration of varied amounts of blood at some time during their illness None of the three children had any blood in their sputum, but as young children rarely expectorate sputum, this is not significant

FIG 1 X ray of chest of patient showing shadow in left lower lobe

DIAGNOSIS

The diagnosis of infected cystic disease is rarely made primarily Usually the diagnosis is reached after the exclusion of other more common ailments The diagnosis is strongly suggested when there is a history of an attack of pneumonitis, thought to be of the virus

recurrent attacks of pneumonitis with x ray changes persisting in the same area Certain other diseases must first be considered and the patient studied accordingly Tuberculosis is the first to be considered Tuberculin skin tests and sputum and gastric washing studies must be done If the skin test is positive guinea pig inoculation of sputum or of gastric washings is necessary Bronchiectasis is the disease with which infected cystic disease is most apt to be confused Bronchoscopy for the presence of obstruction from tumor, or granulation tissue, is essential Bronchography will demonstrate the changes due to bronchiectasis It also will be of value at times in suggesting the presence of infected cystic disease When bronchoscopy has failed to demonstrate any evidence of bronchial obstruction and the bronchogram reveals failure of filling of the part of the lung in which there is the unknown shadow, the diagnosis of infected cystic disease is strongly suggested The failure of filling in such cases is due to the fact that there is no connection between the infected area and the bronchial tree However one cannot be absolutely sure that this is the true explanation, as obstruction of the terminal bronchi from mucus or from other material may occur Thus it is necessary to add this bit of information to the other data In my experience the use of iodized oil in such instances has never caused trouble but it is quite likely that the use of too much oil might be bad The use of sectional radiography may be helpful If the cysts are sufficiently large, they can be demonstrated by this technic We have found this true in cases of solitary cysts but not in cases of cystic disease

HISTORY OF TYPICAL CASE

As an example of a rather typical case of infected cystic disease it is well to review briefly the history of such a case This patient was a child of four At the ages of one and a half, and two and a half, he had had attacks of "bronchitis" Except for a chronic cough he had been perfectly well His mother developed pulmonary tuberculosis and he was accordingly studied for this disease An x ray of the chest revealed a shadow in his left lower lobe which was thought to be due to tuberculosis (Fig 1) The tuberculin skin test was negative, and studies of gastric washings were negative on smear and on guinea pig innoculation Bronchoscopy revealed nothing abnormal It was decided that he had infected cystic disease and operation was performed When the chest was opened, it was seen that there

FIG 2 Photograph of portion of lower lobe removed at operation showing the various sized cysts

was a mass in the anterior part of the lower lobe which felt firm The rest of the lung was normal This part of the lobe was removed with preservation of the large apical segment He made an uneventful recovery and has had no further evidence of chest trouble Examination of the specimen (Fig 2) revealed that most of the resected tissue showed consolidation and on section one could see multiple cysts or abscesses containing much greenish gray purulent material After evacuation of this material it was seen that the area was full of small cysts Some were lined with smooth mucous membrane while others were lined with granular tissue On microscopic examination the impression gained from the gross appearance was substantiated The larger cysts were lined with columnar mucoid epithelium which showed extensive ulceration and replacement by a considerable amount of exudate Other areas of the specimen showed many foci in which alveoli were completely or partly filled with masses of polymorphonuclear leukocytes lymphocytes and erythrocytes as well as with groups of lipid containing macrophages In these areas there was an increase in fibrous tissue as well as an accumulation of erythrocytes Bronchi and bronchioles contained considerable purulent material and there was ulceration of the epithelium

TREATMENT

It is obvious that the only successful treatment of such a condition is excision Ordinarily the extent of the disease is such that only partial lobectomy is necessary but it is most important to remove all abnormal tissue At times the remaining part of the lung may feel normal but it is without pigment whereas the rest of the lung shows the usual evidence of anthracosis Such tissue is almost certainly the site of cystic disease and must be removed to avoid later trouble Even though the diagnosis of infected cystic disease cannot be made and no other definite diagnosis established it is certainly necessary to operate upon such patients and investigate the site of the abnormal x ray shadow Occasionally when all tests have been negative the lesion proves to be carcinoma this possibility must always be remembered *No lesion producing a persistent* shadow in the x ray of the lungs not proved to be due to tuberculosis should be allowed to remain in place

SUMMARY AND CONCLUSIONS

The subject of infected cystic disease of the lung has been reviewed on the basis of findings in seventeen cases in which resection was performed It is thought that the process is the result of infection of congenitally cystic lung tissue which once having become infected is unable to return to a normal state The symptoms are not characteristic but the persistence associated uber mors iated olved first Cure follows resection of part of the lung

REFERENCE

1 MEADE, R H and RASMUSSEN R H The clinical problem of infected cystic disease of the lung *Dis of Chest 24 205 1953*

Intralobar Bronchopulmonary Sequestration

ANDRE J BRUWER, M D, *Rochester, Minnesota*

From the Section of Roentgenology, Mayo Clinic and Mayo Foundation, Rochester, Minnesota The Mayo Foundation is a part of the Graduate School of the University of Minnesota

THE association of a congenital cystic condition of a portion of the lower lobe of a lung, with an anomalous artery of supply which arises from the aorta just above or just below the diaphragm, has been termed "intralobar bronchopulmonary sequestration"[7]

This condition is of interest to the surgeon because it represents a definite hazard to those not familiar with it In about 3 per cent of patients operated upon death has resulted from fatal bleeding resulting from damage to the anomalous artery In several patients the presence of the vessel was not suspected and injury to it resulted in massive hemorrhage which, fortunately, could be controlled In jury to the anomalous artery is especially hazardous because the artery is usually quite short when it originates above the diaphragm When it originates below the diaphragm, injury to it may cause even more difficulty owing to the danger of retraction below the diaphragm

Embryologically, intralobar sequestration is of interest The anomalous artery is due to persistent connections between the pulmonary plexus and the dorsal aortas, via the splanchnic plexus, which normally atrophy When they persist, however, anomalous arteries such as those described result Such arteries occasionally enter one or both lower lobes of normal lungs[17] To my knowledge, the true incidence of such anomalous arteries, unassociated with other abnormalities, has not been determined at the time of this study Of interest, however, are the cases in which a congenital abnormality of the bronchial system of a lower lobe is associated with the anomalous arteries Some say that the anomalous artery is merely the embryonic artery of supply to the portion of lung that has been sequestered "Except for the fact that the artery is a nutrient vessel to the sequestrated mass, their relationship is purely passive"[7] On the other hand, Pryce has suggested that the anomalous artery may be the cause of the bronchopulmonary sequestration, creating traction on and separation of a portion of the lower lobe during early embryologic development

It is probable that extralobar bronchopulmonary sequestration (inferior accessory lung), various degrees of pulmonary agenesis, certain types of diaphragmatic hernia[6,8] and some types of pulmonary vascular anomalies[19] have, broadly speaking, a similar embryologic basis Such a proposal was implied by Cole and coworkers based on the work of Needham, they suggested that "The most likely explanation is that some interference with the embryologic organization takes place in the lower chest behind the heart and that all structures under development in that area, at the time may be affected" Although diffuse and intangible, this hypothesis is basically no doubt the most accurate,

INCIDENCE

Although the literature contains reports of necropsy in fewer than ten cases of intralobar bronchopulmonary sequestration, it contains descriptions of surgical procedures in almost 100 cases[1,4,9,15–17] The surgical significance is indicated by the fact that there have been three deaths at operation owing to injury to an unexpected anomalous artery The majority of lesions have been on the left side

SYMPTOMS AND DIAGNOSIS

Although the condition is discovered sometimes from routine roentgenograms of the thorax made during surveys or annual checkups, the majority of patients come to operation because of repeated acute pulmonary episodes similar in most cases If the sequestered seg-

ment has no communication with the bronchial tree the cysts are filled with mucoid material On a roentgenogram of the thorax made from the postero-anterior view such a cyst if large enough shows as a rather well defined solid mass whereas the lateral view shows a less well defined misty outline Wyman and Eyler have pointed to the fact that the long axis of the lesion sometimes appears to be directed posteriorly and toward the midline as if indicating the possibility of a connection with the aorta in the region of the diaphragm If a communication with the bronchial tree exists the lesion may contain one or more air fluid levels Fry and his colleagues[7] have made the interesting suggestion that even when a communication with the normal bronchial tree does not exist the lesion may contain a pneumatic area overlying the fluid and that this is due to metabolic gas

Although the roentgenographic appearance of the lesion in itself is not diagnostic the finding of a lesion in the characteristic location usually in a young person who is either symptomless or who gives a history of repeated attacks of pneumonia makes bronchopulmonary sequestration an outstanding diagnostic possibility Familiarity with the clinical picture and roentgenographic features of intralobar bronchopulmonary sequestration has enabled some physicians to diagnose the condition before operation

PATHOLOGIC ASPECTS

The gross abnormality usually falls into one of the three groups of Pryce (1) a large cyst anomalous artery In any of these gross types the bronchial or cystic elements may be completely dissociated from the bronchial tree or there may be a small communication with the bronchial tree perhaps as a result of infection Kergin for example thought that in four of his five cases the connection of the cystic region with the bronchial tree was secondary One also may find that in a specimen with many cystic regions some may have small communications with the bronchial tree while others will be totally isolated and filled only with a jelly like substance probably inspissated mucus The cysts are lined with respiratory epithelium Alveoli in the tissues surrounding the cysts and pigment in the involved pulmonary tissue are not evident both would have been expected if any functioning pulmonary tissue had been present It would appear that the conducting component of the involved region (that is the bronchial component) is abnormally developed and expanded into cystic structures whereas the functioning (alveolar) component is undeveloped The tissue between the expanded bronchi is largely fibrotic and contains a variable number of inflammatory cells depending on the amount of infection that has occurred Infection of the sequestered lung tissue presumably may take place by contiguity from an adjacent temporary infection of the lung or by hematogenous spread as probably occurred in one case reported by Pryce.

In most instances the anomalous arteries are confined to the sequestered region As a rule veins are not found to accompany the anomalous arteries and it is presumed that the venous drainage from the sequestered region is via the normal pulmonary veins Kergin has pointed out that in some cases this may result in a significant arteriovenous shunt The anomalous artery usually enters the lung in the region of the lower limit of the pulmonary ligament It is not unusual for large lymph nodes which may be devoid of pigment to occur in the region of this accessory hilus Although these anomalous arteries have been referred to as bronchial type arteries Pryce has pointed out that they have the histologic appearance of true pulmonary arteries Not infrequently considerable intimal sclerosis is present a feature which some authors consider to result from the high pressures in these vessels but which also may be owing to the fact that they are essentially functionless and that their natural tendency is therefore to deteriorate

CASE REPORTS

Case 1 is of special interest because of the patient's long clinical history, age and the early roentgenograms which were still available (Fig 1)

CASE 1 A man sixty years of age presented himself at the Mayo Clinic in 1951 with the chief complaint of a long history of cough productive of about one half cupful of yellow sputum per day Recently he had lost weight and appetite and had severe malaise as well

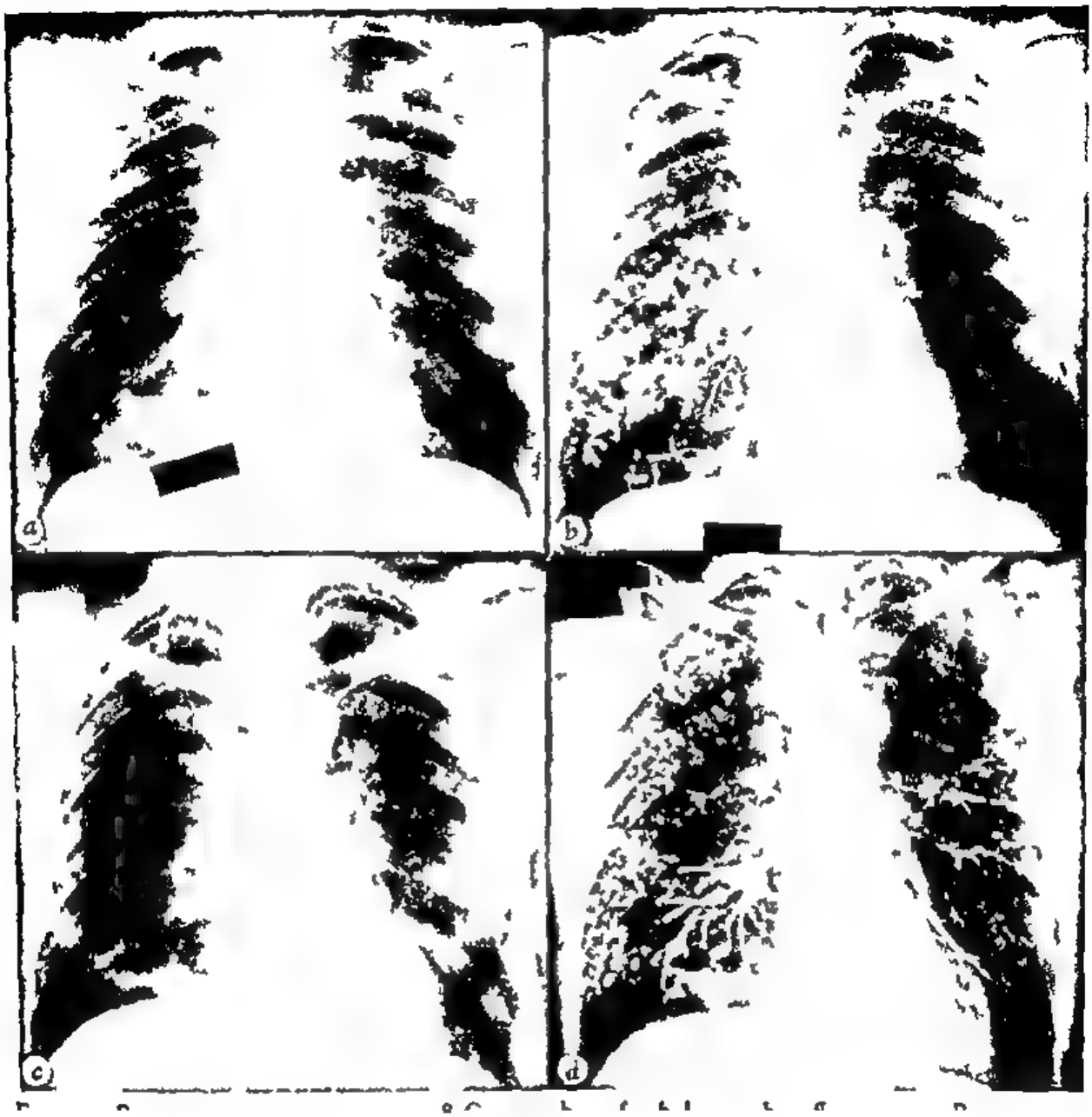

as dyspepsia He had not had night sweats fever or hemoptysis Twenty three years previously the patient had come to the Clinic because for six years he had had spells of coughing productive of large amounts of pus At that time in 1928 a roentgenogram of the thorax revealed evidence of a cavity with fluid level in the right lower lobe in the posterobasal segment and bronchograms revealed evidence of associated bronchiectasis in this region (Fig 1a and b) A great deal of pus was aspirated through the bronchoscope Phrenicotomy was performed and the patient was relieved considerably for a number of years Roentgenograms and bronchograms (Fig 1c and d) of the lung in 1951 appeared remarkably similar to those made twenty three years previously Examinations of the sputum for tuberculosis actinomycosis and other fungi gave negative results At operation a long band of indurated tissue extended toward the midline from the medial basilar portion of the right

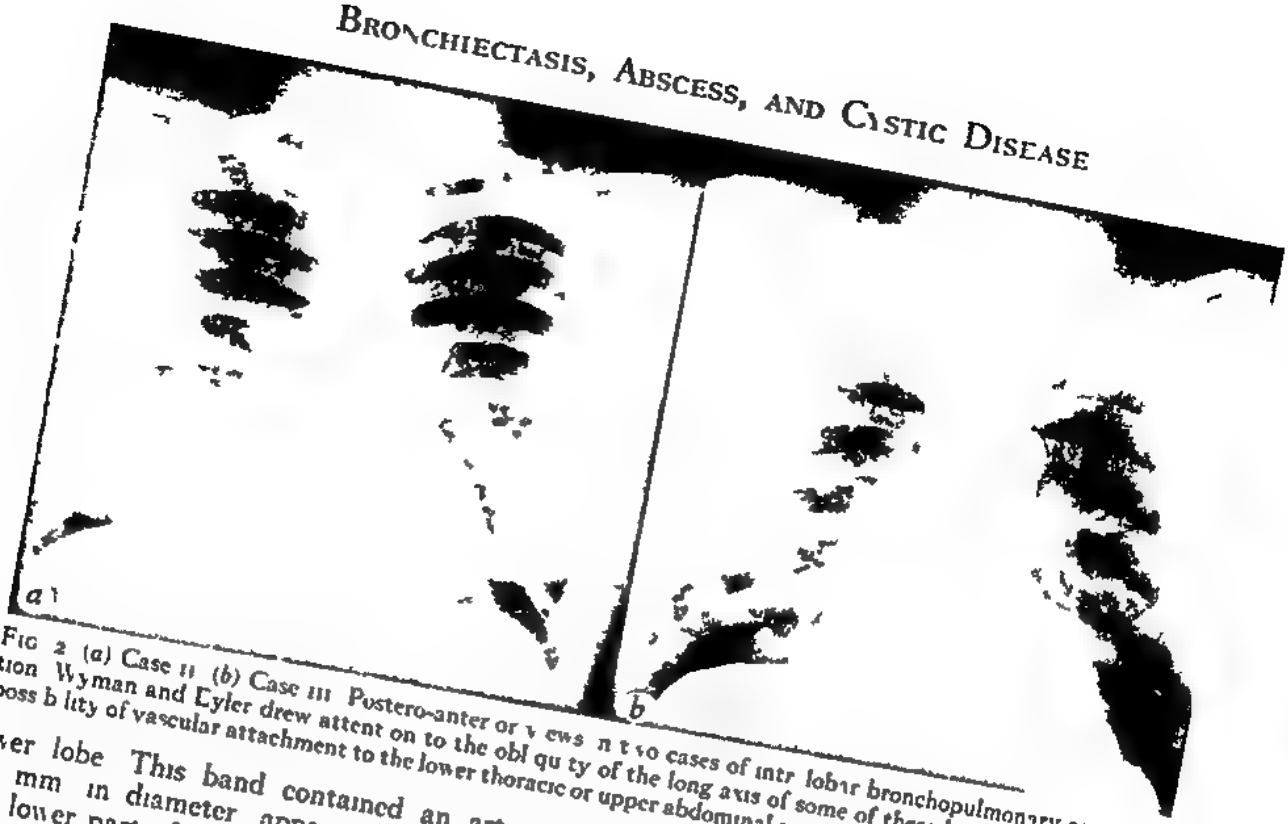

FIG 2 (a) Case II (b) Case III Postero-anterior views in two cases of intralobar bronchopulmonary sequestration Wyman and Eyler drew attention to the obliquity of the long axis of some of these lesions suggesting the possibility of vascular attachment to the lower thoracic or upper abdominal aorta

lower lobe This band contained an artery 0 8 mm in diameter apparently coming off the lower part of the thoracic aorta A cystic structure was felt in the lower lobe and this part of the lung was very adherent to the diaphragm and lateral thoracic wall The right lower lobe of the lung was removed A cyst 6 cm in diameter lined with columnar ciliated epithelium was present in the posterobasal portion of the lobe The anomalous artery which was very sclerotic, ramified around the periphery of the cyst Some of the surrounding lung tissue was bronchiectatic

CASE II A woman thirty six years of age who had been in excellent health came to the Clinic because a mass had been found in the thorax on routine roentgenographic examination A roentgenogram made at the Clinic showed evidence of a well circumscribed mass in the posteromedial part of the base of the right lung (Fig 2a) Exploratory operation revealed a cyst in the posterior part of the lower lobe associated with a few adhesions An anomalous artery from the lower part of the thoracic aorta entered the pulmonary ligament of the right lung The lower lobe of the right lung was removed and the patient made an uneventful recovery The artery was found to ramify in the region of the cyst

CASE III A fifty seven year old man presented himself at the Clinic for evaluation of backache On routine roentgenogram of the thorax evidence was shown of an oval mass of homogeneous density in the posterobasal region of the right lower lobe (Fig 2b) The long axis of this oval density appeared to be directed toward the midline a feature described by Wyman and Eyler[15] Bronchoscopy gave negative results as did studies for tuberculosis fungi and brucella

At operation dense adhesions were found in the posterior costophrenic sulcus in the posterobasal region of the lung A large anomalous artery was found in these adhesions Considerable difficulty was encountered in ligating it owing to its tendency to retract toward its origin from the lower thoracic aorta after it had been divided

The right lower lobe was found to contain a trabeculated bronchogenic cyst containing chocolate-colored material Surrounding it and in the sequestered region were many small bronchial structures but no evidence of alveoli A communication between the cyst and the normal bronchial tree was not apparent The anomalous artery was very sclerotic

CASE IV Although in excellent health a twenty two year old nurse had had several roentgenograms of the thorax in the last five years which had shown evidence of a lesion in the base of the right lung A roentgenogram made at the Clinic in December 1953 revealed evidence of multiple rounded densities each about 3 cm in diameter in the posterior basal

F G 3 (*a b*) Polycyst c les on n the base of the r gl t lung

segment of the right lower lobe (Fig 3*a* and *b*) Roentgenograms made in the patient s home town in 1949 were obtained and showed the same lesions but the densities were slightly larger in those made in 1953 Suggestions as to the nature of the les on included multiple granulomas arteriovenous anomaly hamar tomas metastatic process and bronchiectatic abscesses The surgical consultant suggested multiple bronchogenic cysts and warned about the possibility of an anomalous vessel Results of all other preoperative studies were negative

At operation the right upper and middle lobes were found to be normal The posterior basilar segment of the right lower lobe con tained numerous doughy feeling cysts An artery about 1 cm in diameter arose from the aorta immediately above the diaphragm and entered the right lower lobe through the inferior end of the pulmonary ligament The right inferior pulmonary vein drained nor mally No other vascular or bronchial abnor malities were present Lobectomy was per formed on the right lower lobe The patient made an uneventful recovery

The pathologic specimen contained multiple cysts from wh ch a thick reddish brown material was aspirated The anomalous vessel entered the region of sequestration Patholog c sections were not made because it was decided to do injection stud es with the use of liquid plastics This aspect of the case will be re-ported in the near future [11]

COMMENT

Intralobar bronchopulmonary sequestration is of interest in that the rather typical clinical f ndings in a young person and the presence of a solid lesion or a cystic lesion with an air flu d level in the region of the posterior basal segment make the diagnosis a good likelihood It is thus possible for the roentgenolog st to draw the attention of the surgeon to the possi bility of encountering an anomalous artery in the posterior basal region

In Cases I and III the patients were much older than the usual patient having intralobar sequestration Case IV is unusual in that multiple large cysts were present

Ind cator dilution studies might provide evi dence of early recirculation through the lung as in the case of peripheral arteriovenous fistulas [2]

In view of the similar origin of anomalously draining pulmonary veins[3] and of anomalous arteries we have been interested in finding abnormalities in the bronchial tree among pat ents having anomalous venous drainage of a lung [3] In one case in which the right lung drained into the inferior vena cava the bronchus of the right upper lobe apparently had failed to develop (Fig 4*a* *b* and *c*) The venous anomaly was proved by cardiac catheterization In another case (Fig 5*a* *b* and *c*) with similar roentgenologic findings of anomalous venous drainage of the right lung a major bronchus probably that to the lower

FIG 4 (a) Shadow of anomalous vein projected behind cardiac outline The vein courses downward toward the

ferior vena cava



FIG 5 (a) Small right hemithorax as compared to left Abnormalities in this case included dextropos tion of heart cystic hypogenesis of the bronchus to the right lower lobe and the presence of an anomalous vessel (b) Tomogram in same case showing anomalous vessel and bronchial abnormal ty (c) Bronchogram showing cyst c hypogenesis of right lower lobe bronchus

lobe, ended blindly in a cyst like structure Such findings as these lend further support to the previously quoted statement of Cole and co-workers *regarding the pathogenesis of the* condition

SUMMARY

Intralobar bronchopulmonary sequestration is the association of a cystic lesion in the lung *practically always in the posterior basal seg* ment of a lower lobe with an artery of supply arising from the lower thoracic or upper abdominal aorta This artery is of surgical significance, as it may offer a definite hazard during lobectomy

The anomalous artery is the result of per sistence of connections between the dorsal aorta and pulmonary plexus via the splanchnic *plexus Such an artery may exist alone or in* association with a number of developmental abnormalities such as pulmonary cysts dia *phragmatic hernia arteriovenous pulmonary*

a history of repeated attacks of upper respira tory infection and roentgenograms of the thorax show evidence of a cystic lesion in the posterobasal segment of one of the lungs

Attention is drawn to the similarity of em

bryologic development of anomalous pulmonary veins, and to the occasional association of abnormalities of the bronchial tree with anomalous venous drainage of the lung

Indicator dilution studies would be interesting in the diagnosis of intralobar sequestration

REFERENCES

1 BOYD, D Intralobar pulmonary sequestration *Dis of Chest* 24 162–172, 1953
2 BROADBENT, J C. and WOOD E H Indicator-dilution curves in acyanotic congenital heart disease *Circulation* 9 890–902, 1954
3 BRUWER, A J Roentgenologic findings in anomalous pulmonary venous connection *Proc Staff Meet, Mayo Clin* 28 480–485, 1953
4 BRUWER, A J, CLAGETT, D T and McDONALD, J R. Intralobar bronchopulmonary sequestration *Am J Roentgenol*, 71 751–761, 1954
5 CLAY, R C and HANLON, C R. Pneumoperitoneum in the differential diagnosis of diaphragmatic hernia *J Thoracic Surg*, 21 57–70 1951
6. COLE, F H, ALLEY, F H and JONES, R S Aberrant systemic arteries to the lower lung *Surg Gynec & Obst*, 93 589–596, 1951
7 FRY, W, ARNOLD H S and MILLER, E W Bronchial cyst associated with anomalous artery *Ann Surg*, 138 892–898, 1953
8 HEALEY, J E An anatomic survey of anomalous pulmonary veins their clinical significance *J Thoracic Surg* 23 433–443, 1952
9 HERTZOG, P, TOTY, L, PERSONNE, C and GILBERT, J. Deux nouvelles observations de séquestration pulmonaire kystique avec artère anormale d'origine aortique *Poumon*, 9 77–88, 1953
10 KERGIN, F G Congenital cystic disease of lung associated with anomalous arteries *J Thoracic Surg*, 23 55–65 1952
11 LEMMON, M L, KIRKLIN, J W and DOCKERTY, M B Unpublished data
12 NATUCCI, G Sopra un caso raro di anomalia delle arterie bronchiali *Patbologica*, 31 514–520, 1939
13 NEEDHAM, J Quoted by Cole et al [6]
14 PRYCE, D M Lower accessory pulmonary artery with intralobar sequestration of lung a report of seven cases *J Path & Bact*, 58 457–467, 1946
15 RAZEMON, J P Une variété de malformation congenitale du système bronchique, "la sequestration broncho-pulmonaire" *Echo méd du nord*, 24 204–216, 1953
16 RAZEMON, P, HOUCKE, E and RAZEMON, J P. Deux cas de "sequestration pulmonaire" *Lille chir*, 8 177–183 1953
17 REBORA, F, GEREZ M L GOMEZ, M A and PENA, R Circulación pulmonar anómala y secuestro pulmonar *Rev mex de tuberc*, 13 49–58, 1952
18 WATSON, W L. Pulmonary arteriovenous aneurysm a new surgical disease *Surgery*, 22 919–929, 1947
19 WYMAN, S M and EYLER, W R Anomalous pulmonary artery from the aorta associated with intrapulmonary cysts (intralobar sequestration of lung), its roentgenologic recognition and clinical significance *Radiology*, 59 658–667, 1952

XXVI. TUMORS—BENIGN, MALIGNANT, AND METASTATIC

83

Benign Tumors

LEW A HOCHBERG, M D AND BERNARD SCHACTER, M D, *Brooklyn, New York*

From the Department of Thoracic Surgery, Jewish and Beth El Hospitals, Brooklyn, New York

ALTHOUGH the occasional benign tumor of the bronchus and lung was recognized in former years, chiefly at necropsy, it was not until comparatively recent years that these tumors were treated surgically Sutton in his book on "Tumors—Innocent and Malignant" published in 1894, fails to mention benign tumors of the lower respiratory tract In Kaufmann's monumental work on pathology there are several references to these tumors, but only one antedating the work of Sutton In 1930 Patterson published a paper on benign bronchial neoplasms, reviewing twenty six cases gleaned from various sources Sixteen of these tumors were diagnosed via bronchoscopy and ten at necropsy Two years later Wessler and Rabin reported on seventeen benign bronchial tumors seen at Mount Sinai Hospital in New York City In the combined series of forty three cases reported in the latter two papers there were fifteen adenomas, nine fibromas, seven polypi three chondromas, three lipomas, two fibrolipomas, and one each of papilloma,

removal was accomplished via the bronchoscope either by snipping it out of the bronchial wall or by cauterization of the tumor However, it was not until about twenty years ago that such a tumor was removed via the transthoracic

were 155 case reports but not a single one was for benign tumor of the bronchus or lung The relatively large number of such cases reported in recent years may be ascribed to our advances in radiology, endoscopy, pathology, anesthesia and thoracic surgery The advent of mass chest x ray surveys in recent years has greatly increased our awareness of asymptomatic pulmonary tumors, a goodly percentage of which have been shown to be malignant and a lesser percentage benign Although such roentgenographic studies give the first clue of the presence of a tumor, it is not until the tumor tissue is examined by the pathologist that one can venture an opinion as to whether the tumor is malignant or benign

The object of this chapter is to review the subject of benign bronchopulmonary tumors to present a classification of such tumors based upon the one proposed by Liebow, and to present cases illustrative of some of these tumors

The present classification of benign bronchopulmonary tumors is based upon the genesis of the lung and bronchial tissues It does not propose anything new, but it does attempt to organize the available material on the subject To this end it was found expedient to subdivide these tumors according to their origin Thus they are either epithelial mesodermal or developmental in origin

Epithelial Tumors
- 1 Papilloma of the bronchus
- 2 Adenoma of the bronchus

Mesodermal Tumors
- 1 Vascular tumors
  - (a) Cavernous vascular tumors
  - (b) Capillary hemangiomas
  - (c) Vascular endotheliomas
- 2 Intrabronchial tumors
  - (a) Fibroma
  - (b) Chondroma
  - (c) Lipoma
  - (d) Leiomyoma
  - (e) Myoblastoma
  - (f) Plasmacytoma
  - (g) Lymphoma

Benign Tumors

3 Peripheral tumors of the lung
In addition to those listed above as intrabronchial tumors the peripheral lung tumors include
(a) Neurogenic tumors
(b) Xanthomas

Developmental Tumors
1 Hamartoma
2 Teratoma

PATHOLOGY

Epithelial Tumors 1 The *papilloma* of the bronchial tree is often an inflammatory lesion and therefore not infrequently of multicentric origin True non inflammatory papillomas of the bronchus are very rare The papilloma most often occurs in the region of the stem bronchus Grossly it is a firm coarse sess le polypo d or cauliflower like mass which projects into the lumen of the bronchus Microscopi cally it is comprised of small stratif ed cuboidal or squamous epithelial cells about a stalk of connective tissue Keratinization is quite common in these tumors The surrounding tis sues of the bronchial wall are not invaded by the tumor

2 The *adenoma* is the most prevalent of the benign tumors of the bronchus and lung It is said to constitute about 8 per cent of all primary tumors of the lower respiratory tract and about 80 per cent of all the benign tumors in this part of the body It is a slowly growing local tumor at first circumscribed but later invasive or sluggishly metastasizing Because of this potentiality Hood Good Clagett and McDonald (1953) consider this tumor to be malignant Most frequently the adenoma in volves the subepithelial tissues of the larger bronchi However it may also arise from the smaller bronchi within the substance of the lung There are several theories as to the origin of these tumors Some subscribe to the view that they arise from the bronchial mucosal glands others believe that they arise from a special group of cells known as the oncocytes frequently seen in the bronchial glands Womack and Graham contend that these tumors arise from persistent embryonal bron chial buds Church ll endorses the view that they arise from vestigial pulmonary lobes growing within the bronchus and others be lieve that they arise from the bronch al lymph oid tissues The most widely accepted view is that they arise from the bronchial glands and their ducts

There are two well differentiated histologic patterns seen in these tumors (1) the carcinoid form and (2) the cylindroid form The carcinoid form of bronchial adenoma is the more com mon constituting about 85 per cent of the adenomas Grossly these tumors project into the lumen of the bronchus as a smooth pinkish grey globoid or lobulated mass the surface of which is often covered by many fine vessels Very commonly these tumors grow partly extrabronchially too Jackson and Jackson (1950) point out that in the early case the tumor is sessile but later it may become pedunculated The consistency of these tumors is variable The softer tumors are pale pink while the firmer tumors are pale brown or tan (Fig 1) Microscopically these tumors consist of an outer thin sheet of bronchial epithelium in which metaplasia has taken place Beneath this layer there is a thickened reticular base- ment membrane and dense connective tissue Deep to this is the true neoplastic tissue which characteristically consists of uniform small cells with finely granular acidophilic cytoplasm and nuclei that are finely stippled with chroma tin These cells are arranged in sheets or collec tions resembling acinar groupings In the in vasive stages the cells are less uniformly distributed but the basic pattern of localization remains unaltered Mitosis is very rare in these tumors Bone formation is occasionally seen in the adenoma and is believed to be due to metaplastic changes in the cartilage or osseous transformation of the septa of the capsule about the tumor

In general the truly peripheral adenoma is structurally the same as the endobronchial type (Fig 2) However in these tumors the component cells are more granular and more variable in size and shape

A variant of the carcinoid form of bronchial adenoma is the oncocytoid adenoma Grossly they have most of the features of the other tumors but are firmer in consistency and pale tan in color Microscopically the predomi nating cell is quite large the cells are packed closely together the stroma is not abundant and vascular channels are incon spicuous The cell characteristic of this tumor has a granular or striated cytoplasm and a small centrally placed nucleus which resembles the bronchial mucous glands of older patients

FIG 1 Right lung removed surgically for adenoma (carcinoid) of the intermediate bronchus Same case as Figure 15

FIG 2 Enucleated adenoma (carcinoid) of the left lung Same case as Figure 9

Adenomas comprised entirely of oncocytoid cells are rare However Stout (1943) reported such a case Most often these cells occur in groups within a carcinoid and are separated from the remainder of the tumor by connective tissue At times these cells comingle with the carcinoid cells in which instances transitional cells may also be seen

The cylindroid form of bronchial adenoma comprises about 15 per cent of all bronchial adenomas It arises from the same cell as does the carcinoid Grossly this tumor is pale yellow fairly firm and more translucent than the carcinoid The cut surface of the cylindroid is usually moist having the appearance of thin mucus The tumor is often lobulated and extends diffusely along the bronchial wall (Fig 3) If a capsule is present it is usually indistinct Microscopically, the cells comprising this tumor are pleomorphic and of the epithelial variety The cells are usually smaller than those seen in the carcinoid and are more basophilic The nuclei are variable in size and often fusiform in shape The cells are usually arranged in the form of branching cylinders or tubes lined by a double layer of cells in a plexiform honeycombed mass Mitoses in these cells are fairly common The stroma in these tumors is a loosely arranged connective tissue which is much less vascular than that seen in the carcinoid The cylindroid form of adenoma exhibits a tendency toward invasion of the tissues and may even extend into the bronchial cartilages A variant of this form of adenoma is known as the mucoepidermoid adenoma a mucus producing tumor in which there is an intimate admixture of well differ ' heets of

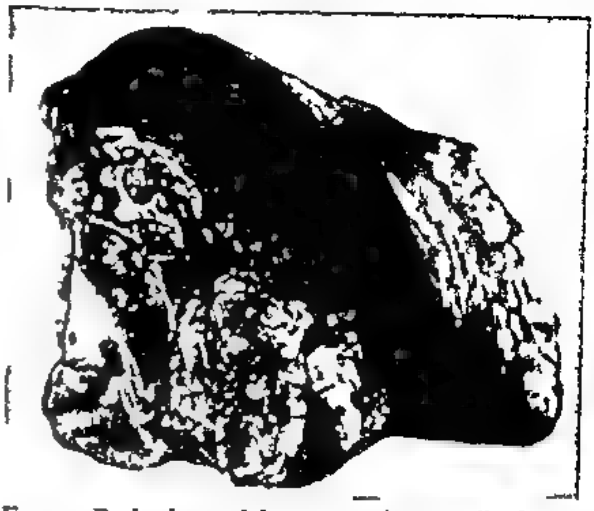

FIG 3 Right lower lobe removed surgically for an adenoma (cylindroid) of the lower lobe Same case as Figure 16

tumors

(2) The *cavernous vascular* tumors are comprised of communicating tortuous dilated vascular channels with both venous and arterial components which have been variously described as arteriovenous fistulas arteriovenous varices cavernous hemangiomas angiomas telangiectasis and intrapulmonic aneurysms Makler and Zion define a pulmonary hemangioma as a ' knot of blood vessels connected by feeder vessels with both the pulmonary arterial and venous circulations Thus it acts as a shunt whereby blood can pass from the arterial to the venous circulation without passing through the lungs and being oxygenated In a review of fifty cases Giampalmo

FIG 4 Enucleated endothelioma (mesothelioma) of the right lung Same case as Figure 10

found that 66 per cent of the cases involved the lower lobes, 18 per cent involved the upper lobes and 16 per cent were in the right middle lobe Grossly, these tumors are well defined within the lung either as single or multiple lesions They may be found in any part of the lung, superficially or deeply within the parenchyma of the lung They consist of a distended, thin-walled, afferent artery, distended efferent veins, and intervening between them are loculated vascular sacs of distended vessels Microscopically, large spaces are noted lined by thin-walled endothelial cells, supported by a fine connective tissue The arterial structures are indistinguishable from the venous component Muscle is occasionally seen in the wall surrounding the dilated channel

(b) *Capillary hemangiomas* are rarely encountered in the bronchi or lungs However, when present they resemble those found in other parts of the body

(c) *Vascular endotheliomas* of the lower respiratory tract are very uncommon Edwards and Taylor (1937) reported four such tumors When present it is a well defined, discrete, more or less encapsulated lesion (Fig 4) On microscopic examination of the tumor one notes cells which are mainly polyhedral in shape, surrounded by a well defined membrane The cytoplasm of the cell is clear, the nucleus small, pale and vesicular, and contains several small nucleoli Also present in these tumors are circulatory channels (vascular and or lymphatic), the walls of which are often formed by masses of tumor cells The cells may be arranged in whorl like fashion and/or in groups which form columns or channels two or three cells in thickness Giant cells are not uncommon in these tumors

2 *Intrabronchial tumors* most often are seen



FIG 5 Enucleated fibroma of the right lung Same case as Figure 11

in the more proximal bronchi but are also known to arise from segmental and subsegmental bronchi They may be pedunculated or have a broad base in the wall of the bronchus In the occasional instance they also penetrate the outer coats of the bronchial wall so [redacted] to form a localized tumor, part of which projects into the lumen of the bronchus and part of which extends into the parenchyma of the lung as an extrabronchial tumor

(a) *Fibroma* These tumors are of variable size, but most often they are small Crimm and Kiechle report removal of a fibroma with the right lower lobe, the weight of both being 740 gm The present writers removed a parenchymal fibroma of the lung which measured, 3 by 3 by 5 cm Grossly, these tumors are firm, pale and either smooth or nodular on the surface, and when within the lung they are distinctly outlined against the pulmonary tissue The cut surface of these tumors is quite similar to its outside surface Cystic changes are occasionally seen when the tumor is transected (Fig 5) Microscopically, they are composed of closely packed spindle-shaped cells In some instances the cellular elements are less prominent and the collagen tissue more in evidence Myxomatous changes and fatty infiltrations are also seen occasionally in these tumors

(b) *Chondroma* The pure chondroma [redacted] not a common tumor In 1950 Hochberg and Pernikoff reported that seventy eight tumors had been recorded in the literature up to that time There are two theories as to the origin of these tumors The first [redacted] based upon the

assumption of hyperplasia of the bronchial cartilages and the second more widely accepted theory of delayed development of cartilaginous elements in embryonic rests which suddenly begin to grow The chondroma varies in size and location The smaller ones being intrabronchial while the larger ones are within the parenchyma of the lung Linser describes a chondroma of the lung which was 20 by 16 by 9 cm These tumors are masses round or ovoid in shape have a lobulated surface and are covered by a semi translucent fibrous capsule They are distinct tumors and do not invade the surrounding tissues The color of the cut surface of the tumor varies with its composition When composed of hyaline cartilage the tumor is very firm grey white in color and has a bluish translucency (Fig 6) When these tumors contain abundant fibrous or elastic tissue they are more opaque and have a yellow white color Microscopic examination of the tumor reveals nests of hyalin and fibrocartilaginous tissue separated from each other by fibrous connective tissue stroma Histologically these tumors simulate normal cartilage The fibrous tissue capsule and trabeculae often contain small vessels Within the substance of the tumor calcific deposits and rudimentary bone formation may be noted In other instances there may be bleeding into the tumor and myxomatous degeneration

(c) *Lipoma* While fat is seen frequently in many lung tumors true bronchopulmonary lipomas are very uncommon Langston (1950) reported that up to that time there were but ten such tumors reported in the medical literature There are numerous theories which attempt to explain the genesis of these tumors The most acceptable one is an overgrowth of a normal constituent of the bronchus Grossly these tumors are rounded or lobulated yellowish pink semi firm often pedunculated and covered by intact mucous membrane Microscopically these tumors are comprised of uniform mature fat cells with moderate amounts of fairly dense fibrous tissue septa separating groups of cells into islands In some areas lymphocytes and small clusters of tubular glands lined by a single layer of cuboidal or low columnar cells may be noted

(d) *Leiomyoma* This tumor, too is rather uncommon in the lower respiratory tract A review of the published cases shows that only

FIG 6 Enucleated chondroma of the right lung Same case as Figure 12 (Previously published in March 1950 issue of *Diseases of the Chest*)

seven such cases were reported in the medical literature before 1954 Franco reported a leiomyoma of the lung 13 by 11 by 9 cm covered at necropsy Grossly these tumors are grey tan in color spherical and firm to palpation They are usually encapsulated and shell out readily The cut surface is opaque with grey interlacing whorls Areas of necrobiosis are seen frequently in these tumors Microscopically these tumors consist of whorls of mature muscle cells with varying amounts of fibrous tissue distributed throughout their substance

(e) *Rhabdomyoblastoma* The presence of striated muscle tumor in this region is believed to be the result of mesenchymal tissue activity These tumors are small well circumscribed and fixed within the wall of the bronchus Microscopically they have three characteristics The first is that they contain large cells resembling undifferentiated muscle fibers arranged in long bands with an occasional syncytial mass The cells have a foamy vacuolated granular basophilic cytoplasm and small round to oval dark staining nucleus The granular structure of the cytoplasm is arranged in parallel rows The second type of cell is represented by clumps of elongated cells resembling smooth muscle cells whose elongated nuclei have a fine chromatin network rounded ends and nuclei The cytoplasm is made up of longitudinal myofibrils These cells either form prominent clumps or intermingle with the first type The third characteristic cell is one which is elongated and has abundant cytoplasm containing eosinophilic granules and an oval dark staining nucleus

(f) *Plasmacytoma* There have been

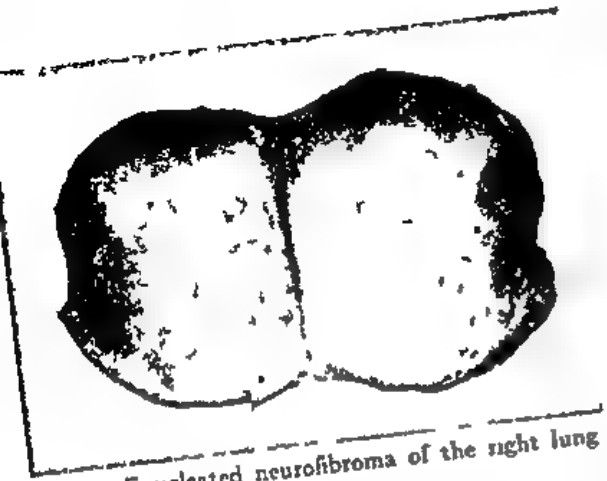

FIG 7 Enucleated neurofibroma of the right lung Same case as Figure 13

such tumors reported (Hill and White 1953) The true plasmacytoma is made up entirely of plasma cells while another form is composed chiefly of plasma cells leukocytes, fibroblasts and some other cells The latter form is a pseudoplasmacytoma and is not considered to be a true form The theories of the origin of this tumor are (1) from the lymphocytes, (2) from the fixed tissue lymphocytes, (3) from the hematogenous lymphocytes, and (4) from connective tissue elements These tumors are usually single but may also be multiple They are usually round or ovoid in shape and are polypoid or lobulated masses which vary widely in size Microscopically, the predominat ing cell is round oval or polygonal with abundant cytoplasm, and contains an ec centrically placed nucleus Within the nucleus there are five to ten deeply staining blocks of chromatin arranged in a circular manner inside of the nuclear membrane Adjacent to the nucleus there is a paranuclear poorly staining region

(g) *Lymphoma* These tumors are also very uncommon They arise from the lymphoid tis- sue in the bronchial wall and grow into an ovoid, firm, encapsulated mass On cut section they are whitish and contain areas resembling lymphoid nodules Microscopically the tumor is composed of cells of the lymphoid tissue variety in which there are large follicles with prominent germinal centers

3 *Peripheral tumors* Such tumors usually arise in the distal parts of the lower respiratory tract It is often difficult to state definitely whether peripheral tumors of connective tissue origin not obviously associated with a bronchus have originated in the parenchyma of the lung, the pleura or from a minute bronchiolar sub- division Although some believe that the leiomyoma is the most frequent tumor at this site, the relatively small number of tumors seen here does not justify any such conclusion

(a) *Neurogenic tumors* This is an uncommon primary tumor of the lung, only five being reported to date Grossly, this tumor is a smooth, firm, well encapsulated whitish glisten- ing mass which is most often single but may also be multiple Microscopically, it is noted that these tumors have a connective tissue capsule with septa extending from it into the tumor proper (Fig 7) Two kinds of tissues are usually seen in these tumors There is the dense, compact tissue of medium sized spindle- shaped cells with uniform elongated oval nuclei, arranged in parallel rows These tumors contain abundant collagen and reticulum fibers arranged in straight bundles, polarized in the same parallel axis The other tissue is of looser texture with spindle cells in a disarranged pattern and moderately large vascular spaces surrounded by thick hyalinized walls

(b) *Xanthoma* Intrapulmonary xanthomas are also very rare, only two such cases having been reported to date Grossly, it is a loosely encapsulated golden yellow tumor which can be separated readily from the surrounding tissues Microscopically, it is composed of characteristic foam cells and contains an abundance of fat globules

Tumors of Developmental Origin 1 *Hamar toma* Albrecht (1904) originally defined this lesion as a "tumor like formation in which there is an abnormal arrangement of the normal components of that organ The abnormality may take the form of a change in quantity, arrangement or degree of differentiation or may comprise all three phases" Two major types of hamartomas are found in the lung (1) the adult form which is relatively a small circum- scribed lesion and (2) the infant or newborn form which is a massive, diffuse process often occupying a lobe or even an entire lung

The adult form These tumors are most often located in the subpleural or peripheral part of the lung and on occasions in the larger bronchi Chardack and Waite (1953) found that only fifteen such tumors were reported as having arisen in the larger bronchi, while Young and his co-workers (1954) reported that of the approximately 200 hamartomas reported only twenty-four were endobronchial in origin The

hamartomas vary in size from about 3/4 to 12 cm in diameter Most of the tumors are about 1 or 2 cm in diameter In most instances these growths are covered by a thin fibrous capsule Externally, they are multicolored nodular or lobular while the cut surface is pale bluish white and often contains yellowish zones of fat deposits and calcification (Fig 8) Irregular areas of cystic changes are not infrequent in these tumors Microscopically, the tumor has communicating and interlacing masses of stroma In proximity to these there are sheets of epithelium resembling that of the bronchial lining The stroma consists mainly of masses of cartilage (hyaline chiefly, but also fibrous and/or elastic) which merges peripherally with the fibrous connective tissue Within the stroma are embedded groups of fat cells bundles of smooth muscle and areas of ossification

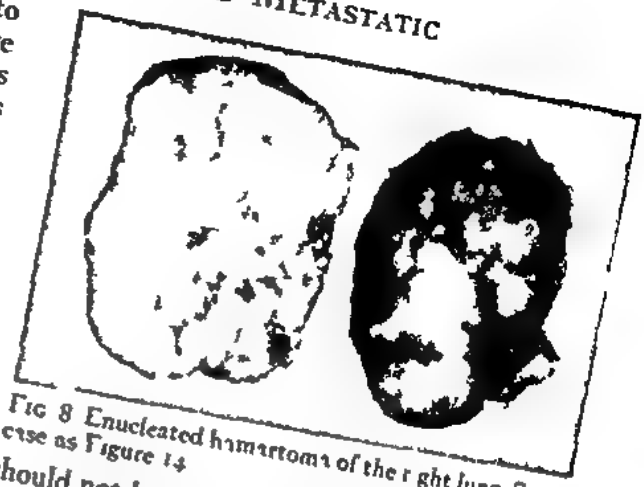

FIG 8 Enucleated hamartoma of the right lung Same case as Figure 14

The diffuse hamartoma of the newborn This tumor is an intrauterine malformation involving a large part of a lung Grossly this tumor may replace the greater part of a lobe or an entire lung Although the tumor is a circumscribed lesion it is not encapsulated Jones reported the case of a one day old child with such a tumor occupying the greater part of the right upper lobe Microscopically the tumor consists of a supporting stroma simulating bronchioles It also contains islands of cartilage fatty tissue fibrous tissue and blood vessels

2 *Teratoma* When located within the lung it has all the characteristics of a teratoma in other parts of the body It is an uncoordinated growth of multiple tissues many of which are foreign to the site of origin It is the result of a developmental aberration in which the germinal layers form various tissues into a tumor There may be domination of one particular germ layer but the others must also be present if one is to classify the tumor as a teratoma

LOCATION

The site of origin of these tumors determines its location Most commonly they arise within the region of the proximal half of the bronchial tree i e from the beginnings of the main bronchi down to and including the segmental bronchi Less frequently they arise distal to the segmental bronchi and in the periphery of the lung Our choice in relating these tumors anatomically to the bronchi should not be interpreted as subscribing to the view that these tumors are necessarily always bronchogenic in origin Any one of these tumors may arise from any region in or in proximity to the bronchopulmonary system The papilloma and the adenoma most often arise from the medial part of the bronchial tree Except for the small telangiectatic tumors most of the vascular tumors arise in the outer half of the pulmonary vascular field Most of the other tumors usually arise in the region of the middle lung field and periphery of the lung Although most commonly the tumors in the larger bronchi grow as endobronchial tumors a goodly percentage of them have extrabronchial extensions The tumors in the peripheral parts of the lung may to all intents and purposes be considered as extrabronchial in their manner of growth The location and manner of growth play an important role in the clinical manifestations of their presence

SYMPTOMS AND SIGNS

The symptoms and signs are variable and dependent upon (1) location and size of the tumor (2) manner of extension (3) histopathologic nature of the tumor (4) duration of condition (5) vascularity of the tumor and (6) effects upon the surrounding tissues and associated complications Many of these tumors are completely asymptomatic and are discovered on routine roentgenographic studies of the chest or at necropsy Those tumors which are endobronchial manifest their presence rather early by a cough and wheezing This is particularly true of the tumor in the proximal part of the bronchial tree As the tumor in this location increases in size and obstructs the bronchial lumen it leads to impaired respiratory function and is manifest by

dyspnea, palpitation, elevation in pulse rate and possibly a reduction in the cough However, if the obstruction to the bronchus is incomplete or intermittent, all of these manifestations are present coupled with variable degrees of expectoration and elevation in temperature The latter condition is due to pulmonary infection distal to the obstruction On the other hand, tumors in the same location which grow extrabronchially and even of larger size than the one within the lumen of the bronchus may remain relatively asymptomatic because they do not encroach upon the respiratory passage and do not interfere with pulmonary ventilation By the same token, if such an extrabronchial tumor should encroach upon a large pulmonary artery or vein, it will impair pulmonary circulation and have a similar clinical effect as an endobronchial tumor insofar as the oxygen supply to the tissues is concerned

Tumors which arise within the pulmonary parenchyma, at a distance from the larger bronchi and periphery of the lung, are notoriously free of symptoms This is due to the fact that they do not encroach upon a large bronchus and that they grow slowly, giving the patient time to accommodate to any loss of function which may take place Tumors arising in the peripheral parts of the lung do not encroach upon pulmonary tissue until they are very large However, they do cause local swelling and congestion of the tissues As a result the visceral pleura rubs against the parietal pleura and gives rise to local pain

In all cases, regardless of the site of origin but more commonly in that group of cases which arise in the proximal bronchi, there is a tendency for the sputum to be blood streaked or stained This is due to superficial erosion and necrosis of the tumor In other instances, as in the adenoma and vascular tumor, hemoptysis may be the first manifestation of the presence of the tumor In some instances the bleeding is sudden in onset brisk and profuse

Because of their peculiar effects on physiology, hemangiomas of the lung present distinctive features which aid in their diagnosis The passage of unoxygenated blood from the venous radicles directly into the arterial circulation, as occurs in these cases reduces the oxygen saturation of the circulating blood As a consequence, cyanosis and dyspnea will develop These symptoms and signs are in direct relation to the degree of arterial blood-oxygen unsaturation In the early stages dyspnea and cyanosis are usually absent or very mild, but as the condition progresses, they may become very distressing Clubbing of the fingertips and toes, epistaxis and hemoptysis are not uncommon in these patients The other signs of chronic hypoxia may also evolve The diagnostic thoracic physical signs are a continuous blowing murmur which becomes intensified with inspiration and fades out to a soft souffle toward the end of expiration Since this disease may involve several areas in the

ROENTGENOGRAPHIC MANIFESTATIONS

By far the most frequently encountered roentgenographic finding in benign tumors of the lower respiratory tract is the circumscribed, well delineated opacity, especially when in the parenchyma or periphery of the lung (Figs [illegible] to 14) However, such a shadow does not exclude the possibilities of the tumor being malignant In those cases in which the tumor is small and/or completely within the wall of the bronchus, conventional roentgenographic studies may fail to reveal the presence of the tumor However, when such a tumor grows into the lumen of the bronchus, it may obstruct the bronchus and cause intermittent or complete obstructive emphysema and/or atelectasis distal to the obstruction (Fig 15) Similar accompanying changes may occur in cases of pedunculated intrabronchial tumors Where obstructive changes occur, one may expect recurrent and chronic inflammatory changes in the lung If these changes are protracted, opalescence of the lung distal to the tumor will also be noted Such roentgenographic findings are to be expected regardless of the nature of the [illegible] opacity or cast its own opacity, as in Figure 16 These roentgenographic changes in the lung are based upon the position of the tumor and not upon its histopathologic structure

Hamartomas of the lung may be recognized occasionally on roentgenograms by the presence of calcific and cystic changes within the tumor However, the presence of such changes is not diagnostic of a hamartoma The caver-

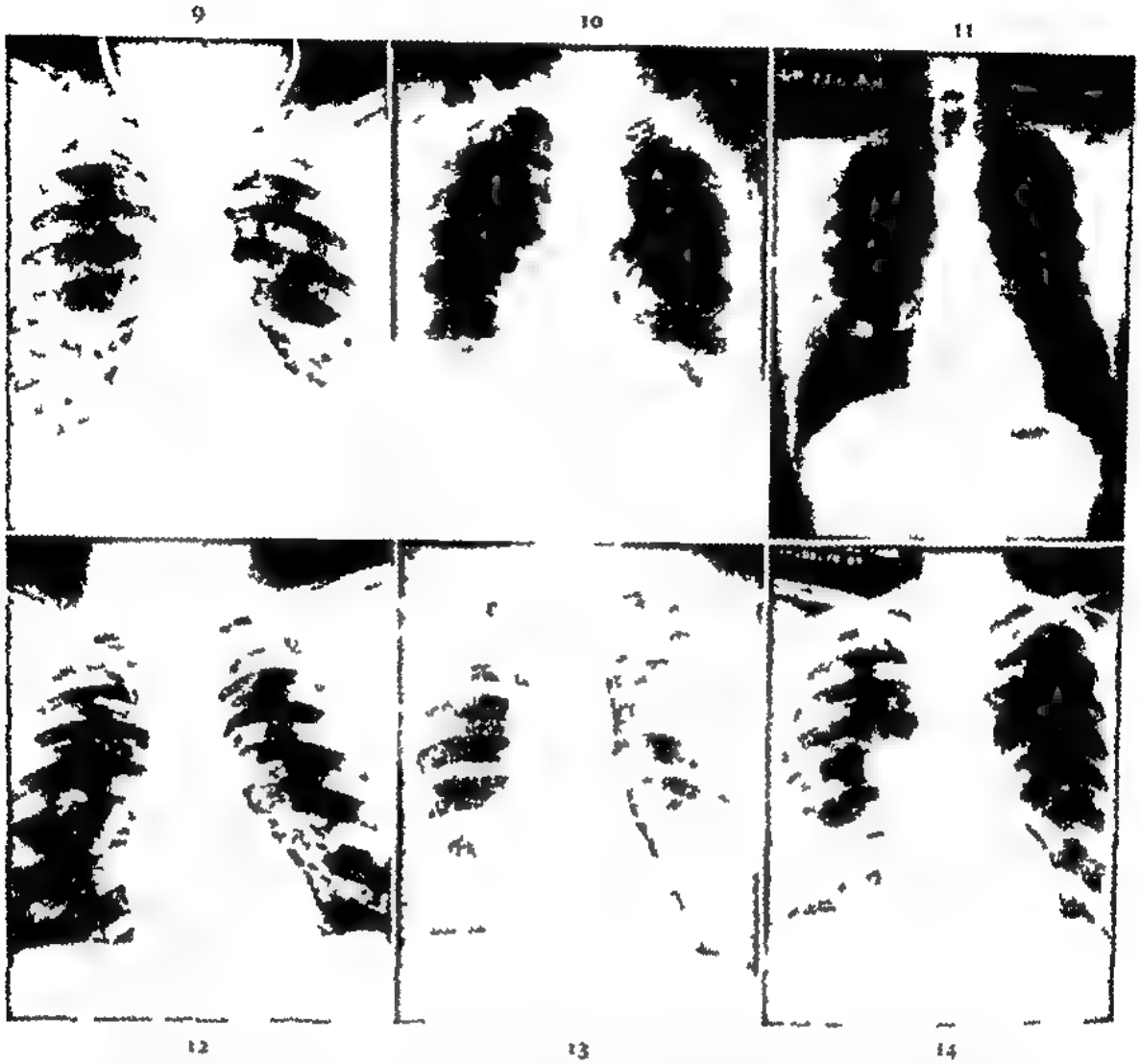

FIG 9 Circumscribed tumor (adenoma) within the parenchyma of the left lung Same case as Figure 2

FIG 10 Postero anterior roentgenogram showing a circumscribed tumor (endothelioma) in the right infrahilar area At the time of operation this tumor was found to be in the superior segment of the right lower lobe Same case as Figure 4

FIG 11 Circumscribed tumor (fibroma) within the parenchyma of the right lung Same case as Figure 5

FIG 12 Circumscribed tumor (chondroma) within the parenchyma of the right lung Same case as Figure 6 (Previously published in March 1951 issue of *Diseases of the Chest*)

FIG 13 Circumscribed tumor (neurofibroma) in the right suprahilar area Same case as Figure 7

FIG 14 Well delineated irregularly opaque mass in the right parahilar area This tumor (hamartoma) was found to be in the superior segment of the lower lobe Same case as Figure 8

nous hemangioma may be suspected in the patient who on fluoroscopy shows the characteristic changes with the Valsalva maneuver within the area of the tumor on laminagraphic study of the tumor area one notes worm like configurations within the opacity and a tongue-like opacity extending from the tumor toward the hilum Angiography is often diagnostic of this lesion

ENDOSCOPY

While endoscopy is a valuable adjunct in the diagnosis of endobronchial tumors the differentiation between benignity and malignancy by this modality is unreliable In approximately half of the cases of benign tumors of the lower respiratory tract one may visualize the growth via the endoscope



15 16

FIG. 15 Delineated opacity of the right lower lobe due to tumor (adenoma) and atelectasis. Same case as Figure 1

FIG. 16 Opacity in the paracardiac portion of the right lower lobe due chiefly to tumor (adenoma). Same case as Figure 3

The adenoma of the bronchus and or lung constitutes approximately 60 per cent of all benign tumors occurring in this area. Since about 80 to 90 per cent of the adenomas arise from the larger bronchi this tumor will be seen via the bronchoscope much more frequently than the other tumors. As seen through the bronchoscope the adenoma is a smooth mass projecting into the lumen of the bronchus often round or lobulated pinkish and containing many small vessels. The surface of the tumor bleeds easily on manipulation. These tumors usually have a broad base in the wall of the bronchus but they may be pedunculated. The other tumors as seen via the bronchoscope are similarly rounded projections into the lumen of the bronchus. They vary in size color vascularity and firmness depending upon their composition. Biopsy of representative tissue is necessary before one can make a definitive histopathologic diagnosis.

THERAPY

The therapy for benign bronchopulmonary tumors is surgical and should conform to the specific needs of the case. Obviously the patient whose condition does not permit removal of the tumor without inordinate risk should not be subjected to unwarranted surgery. Where surgery is performed it is injudicious to sacrifice more lung tissue than is necessary to fulfill the specific requirements of the condition. At the same time it is well to remember that the failure to eradicate completely the disease and its attendant irreversible complications may be equally inadequate. Treatment must be tempered with reason. The basic surgical modalities in the treatment of benign bronchopulmonary tumors are as follows:

Bronchoscopic Removal. In general this method is inadequate in the treatment of such tumors especially in cases of adenoma of the bronchus since many extend through the bronchial wall and since many are potentially malignant. In spite of this bronchoscopic removal has a definite place in the treatment of these tumors. The indications are (1) palliative therapy and (2) to permit evacuation of the contents of the lung distal to the obstructing tumor.

Bronchotomy. Local removal of the tumor by this means via transthoracic bronchotomy is indicated in those cases in which the tumor is confined to a local area in the bronchial wall. After the tumor is removed the defect in the bronchial wall can be repaired by the method advocated by Gebauer.

Enucleation In many instances the tumor is well encapsulated movable within the substance of the lung and close to the periphery of the lung, permitting complete removal with minimal sacrifice of pulmonary tissue In such cases enucleation of the tumor is an ideal method of treatment

Wedge Resection A tumor which is reasonably movable within the lung tissue fairly well circumscribed and somewhat deeper in the lung is best removed with the local pulmonary tissue The method most suitable for such lesions is the wedge pulmonary resection which includes the tumor

Segmental Resection This procedure lends itself to the removal of local tumors within the depth of the lung and which are confined to one segment of the lung It is also indicated in those cases in which the tumor arises within the segmental bronchus or comprises the segmental bronchus leading to irreversible changes in the tissue distal to the obstruction

Lobectomy This method is indicated in those cases in which the tumor occupies a greater part of a lobe or there is considerable involvement of the lobar bronchus and/or there is irreversible damage to the pulmonary tissue distal to the tumor

Pneumonectomy The indications are similar to those of the lobectomy except that the tumor is more proximally situated (in a main bronchus area) and or the irreversible pulmonary tissue changes involve the greater part of the entire lung

In all cases the least radical procedure should be utilized which accomplishes its purpose While conservation of pulmonary tissue is desirable it must not be at the expense of curative therapy Regardless of which of the above said methods is used it must satisfy the dictata of sound surgical judgment in the case of tumor is removed completely as shown in the frozen section studies made at the time of the operation (2) the tumor is non malignant (3) the pulmonary tissue distal to the tumor which is irreversibly infected has also been removed and (4) there has been no unnecessary sacrifice of pulmonary tissue Although the frozen section may show the presence of a benign adenoma it is well to scrutinize the neighboring tissues and especially the lymph nodes for secondary involvement before the wound is closed since these tumors are potentially malignant

SUMMARY

1 A review of the subject of benign bronchopulmonary tumors and cases illustrative of some of these tumors have been presented

2 The pitfalls in the clinical diagnosis of such tumors have been indicated and the surgical modalities in the management of such cases have been discussed

REFERENCES

ABELES H and EHRLICH D Single circumscribed intrathoracic c dense es New England J Med 244 83–88 1951

ALBRECHT E Ueber hamartome Verhandl d deutsch path Gesellsch 7 153 157 1904

ALEXANDER J Fifty years of thoracic surgery Am J Surg 51 217 224 1941

ALEXANDER J Observations on intrathoracic neoplasms Ann Surg 114 734–752 1941

AUSTANI B and SANDRI O Neurofibroma sol tario primitivo del pulmone Chirurgia 7 46 1952

ANDERSON W M Bronchial adenoma with metastasis to the liver J Thoracic Surg 4 236–250 1935

ANDRUS W D Report of the chest tumor registry J Thoracic Surg 12 351 360 1943

ABEY L B Developmental Anatomy Ph Ladelph a 1946 W B Saunders Co

ASHHURE P G Papilloma of the bronchus J Thorac c Surg 27 293 294 1954

BARRETT N R and BARNARD W G Some unusual thoracic tumors Brit J Surg 32 440 450 1944

BEATON A H and HEATLY C A Fat in the tracheobronchial tree with report of a case of true lipoma of the bronchus Ann Otol Rhin & Laryng 61 1206–1218 1953

BELSEY R H R and VALENTINE J C Cylindromatous mucous gland tumors of the trachea and bronchus J Lath & Barr 63 377 387 1951

BERGER S H and BORGADIS A C and AREMENS V Bronchial adenoma J Pediat 43 417 420 1953

BISCARD J D Pulmonary cavernous hemangioma with arteriovenous fistula surgical management Ann Surg 136 965–972 1947

BOREMAN I and BAILMAN R P Cavernous angioma of the right lung J Thoracic Surg 17 205 208 1948

BRAGG E A and LEVENE G Hamartoma of the lung Radiology 54 227–235 1950

BRANDT L L Lymphoma of the lung early course of tuberculosis Am Rev Tuberc 43 429–434 1941

BROWN A L Bronchial tumors thoracobronchotomy Surgery 28 579–582 1950

BRUNN H and GOLDMAN A The differentiation of benign from malignant polypoid bronchial tumors Surg Gynec & Obst 71 703 722 1940

CARLISLE J C LEARY W V and MCDONALD J R Endobronchial lipoma Proc Staff Meet Mayo Clin 26 103 106 1951

CARLSEN C J and KAISER W Chondromatous hamartoma of the lung Thorax 5 293 322 1950

CARR D SKINNER E T ROBBINS S G and KESSLER C R Primary neoplasms of the lung Dis of Chest 17 618–643 1950

CARSWELL, J Arteriovenous fistula of the lung *J Thoracic Surg* 19 789–793 1950
CHAMBERLAIN J M and GORDON J Bronchial adenoma treated by pulmonary resection *J Thoracic Surg* 14 144 159 1945
CHAMPEAU D and COLESPEL, A Leiomyome Bron chique *Ann d'oto-laryng* 70 183 190 1953
CHARDACK W M and WAITE G L Chondromatous hamartoma of a ma n bronchus *Surgery* 34 92–97 1953
CHILDRESS W G and ADIE G C Plasma cell tumors of the med astinum and lung *J Thoracic Surg* 19 794–799 1950
CLAGETT O T and PAYNE J H Complicat ons and treatment of bronchial adenomas *S Clin North America* 26 920–933 1946
CLERF L H Adenoma of the bronchus *Ann O ol Rhin & Laryng* 57 869–874 1948
CORAJOD and BERARD J Hamartochondrome evolvant depuis 15 ans *J franç méd et chir thorac* 6 427–428 1953
COTTON H H and PENIDO J R F Plasma cell tumors of the lung report of a case *D s of Chest* 21 218 221 1952
CRIMM P D and KIECHLE F L Fibroma of the lung *J Thoracic Surg* 23 205 209 1952
DAVIS E W and KLEPSER R G Sympos um on diagnos s and treatment of premal gnant condi tions the s gnif cance of solitary intrapulmonary tumors *S Clin North America* 30 1707 1715 1950
DELARUE N C Bronchial adenoma *J Thoracic Surg* 21 535 542 1951
DIVELEY W and DANIEL H A Primary sol tary neurogenic tumors of the lung *J Thoracic Surg* 21 194 201 1951
DOTY R D Bronchial adenoma *J Thoracic Surg* 21 349–361 1951
EDWARDS, A T and TAYLOR, A B Vascular endothe l oma of the lung *Brit J Surg* 24 481 495 1937
EFFLER, D B BLADES B and MARKS, E The prob lem of the sol tary lung tumors *Surgery* 24 917 928 1948
EPSTEIN I Bronchial adenoma in a supernumerary tracheal lobe *J Thoracic Surg* 21 362 369 1951
FLINT J M Development of lungs *Am J Anat* 6 1 137 1906
FORD W H THOMPSON C W and BLADES B Xanthoma of the lung *Postgrad Med* 8 48–50 1950
FORSEE J H MANON H W and JAMES L A Cavernous hemangioma of the lung *Ann Surg* 131 418–423 1950
FRANCO E Cited by Randall and Blades
FREEDLANDER, S O WOLFAN S and MENDELSOHN H J Surg cal exper ence with asymptomat c intra thorac c growths *Rad ology* 55 700–711 1950
FREIREICH H BLOOMBERG A and LANGS E W Primary bronchogen c le omyoma *Dis of Chest* 19 354 358 1951
GEBAUER, P W Reconstructive surgery of the trachea and bronchi late results with dermal grafts *J Thoracic Surg* 22 568–582 1951
GEEVER F F WILLIAMS W S and MCWILLIAMS J E Bronchial aden ma with cancerous trans formation *Am J Cl n Path* 19 836–839 1949
GIAMPALMO A The arteriovenous ang omatosis of the lung with hypoxaemia *Acta med Scandinav* (suppl 248) 139 1–67 1950
GOLDMAN A The surgical treatment of bronchial adenoma *D s of Chest* 13 321 337 1947
GOLDMAN A The malignant nature of bronchial adenoma *J Thoracic Surg* 18 137–148 1949
GOLDMAN, A and CONNER C L. Benign tumors of the lung with special reference to adenomatous bron ch al tumors *Dis of Chest* 17 644–680 1950
GORDON J and WALKER, G Plasmacytoma of the lung *Arch Path* 37 222 224 1944
GRAHAM E A and WOMACK, N A The problem of the so-called bronchial adenoma *J Thoracic Surg* 14 106–119 1945
HALL, W C The roentgenologic signif cance of hamar toma of the lung *Am J Roentgenol* 60 605–611 1948
HARRINGTON S W Sympos um on certain tumors of the bronchi (adenomas and cyl ndromas) and on tumors of the trachea *Proc Staff Meet Mayo Clin* 21 409–410 1946
HARRIS W H Histolog c analogy of bronch al adenoma to late prenatal and early postnatal structure *Arch Path* 35 85–92, 1943
HARRIS W H and SCHATTENBERG H J Anlagen and rest tumors of the lung their protean histologic patterns in bronchiogenic neoplasia *New Orleans M & S J* 94 333 338 1942
HELLER H and KOSS F H Die gutartigen tumoren der lunge *Chirurg* 23 509–514 1952
HICKEY P M and SIMPSON W M Primary chon droma of the lung *Acta Radiol* 5 475 500 1926
HILL, L D and WHITE, M L. Plasmacytoma of the lung *J Thoracic Surg* 25 187 193 1953
HOCHBERG L A The Thoracic Surgical Patient New York 1952 Grune & Stratton
HOCHBERG L A and PERNIKOFF M Primary chon droma of the lung *D s of Chest* 17 337–346 1950
HOOD H T GOOD C A CLAGETT O T and MC DONALD J R Sol tary circumscribed lesions of the lung *J A M A* 152 1185 1191 1953
HOWES, W E Bronchial adenoma *Dis of Chest* 14 427 436 1948
JACKSON A V Five cases of adenochondroma of the lung *Australian & New Zealand J Surg* 21 173 178 1952
JACKSON C L KONZELMAN F W and NORRIS C W Bronchial adenoma *J Thoracic Surg* 14 98–105

[illegible]

KAUFMANN [illegible] tioners Translated by Reimann [illegible] del phia 1929 P Blakiston & Son Co
KONWALER, B F Bronchial adenomas *Mil Surgeon* 105 448–451 1949
KRAMER R Myoblastoma of the bronchus *Ann Otol Rhin & Laryng* 48 1083 1086 1939
KRAUS A R MELNICK P J and WEINBERG J A Myoblastoma of the bronchus *J Thoracic Surg* 17 382 389 1948

KULEY, M and KUNTMAN, O A case of plasmacytoma of the lung *Dis of Chest*, 19 227-233, 1951
LAFF, H I and NELBELGER, K T Bronchial adenoma with metastasis *Arch Otolaryng*, 40 487-493, 1940
LANE, N, MURRAY, M R and FRASER, G C Neurilemoma of the lung confirmed by tissue culture *Cancer*, 6 780-785, 1953
LANGSTON, H T Benign endobronchial tumors *Internat Abstr Surg*, 91 521-535, 1950
LANGSTON H T and FOX R T The indication for posterior transpleural bronchotomy in the management of intrabronchial tumors *Surg, Gynec & Obst*, 86 192-196, 1948
LELL, W A Report of a case of fibroliposma of right main bronchus, bronchoscopic removal *Ann Otol, Rhin & Laryng*, 58 1124-1134, 1948
LEMON, W E and GOOD, C A Hamartoma of the lung improbability of preoperative diagnosis *Radiology*, 55 692-699 1950
LIEBOW, A A Tumors of the lower respiratory tract In Atlas of Tumor Pathology Washington, D C., 1952 Armed Forces Institute of Pathology
LINDSKOG, G E, LIEBOW, A, KANSEL H and JANZEN, A Pulmonary arteriovenous aneurysm *Ann Surg*, 132 591-606, 1950
LINSER Cited by Verga
MARKLER, P T and ZION, D Multiple pulmonary hemangiomata *Am J M Sc*, 211 261-266, 1946
MAIER, H C Tumors of the lung *Bull New York Acad Med*, 23 136-144 1947
MAIER, H C and FISCHER, W W Adenomas arising from small bronchi not visible bronchoscopically *J Thoracic Surg*, 16 392-398, 1947
MAIER, H C, HIMMELSTEIN A, RILEY, R L and BUNIM, J A Arteriovenous fistula of the lung *J Thoracic Surg*, 17 13-26, 1948
MASON, D G and COBERTH T Adenoma of the bronchus with successful pneumonectomy *Arch. Surg*, 45 542-550, 1942
Massachusetts Gen Hospital Case Reports basal cell papilloma of bronchus, Case No 33151 *New England J Med*, 236 644-645, 1947
MCBURNEY, R P, CLAGGETT, O T and MCDONALD, J R Primary intrapulmonary leiomyosarcoma (thymoma?) associated with myasthenia gravis *Proc Staff Meet, Mayo Clin* 26 345 353, 1951
MCBURNEY, R P, KIRKLIN, J W, and WOOLNER, L B Metastasizing bronchial adenoma *Surg, Gynec & Obst*, 96 482 492, 1953
MCCORKLE, R G KOERTH, C J and DONALDSON J M Thoracic lipomas *J Thoracic Surg*, 9 568-582, 1940
MCDONALD J R, HARRINGTON S W and CLAGETT, O T Study of hamartoma (often called chondroma) of the lung *J Thoracic Surg*, 14 128 143, 1945
MCDONALD, J R MOERSCH, H J and TINNEY, W S Cylindroma of the bronchus *J Thoracic Surg*, 14 445-453, 1945
MCREYNOLDS, G S and PARRISH, R L Adenoma of the bronchus *Ann Otol, Rhin & Laryng*, 50 766-768, 1947
MEISSNER, W A Lung tumors as the pathologist sees them *Nebraska State M J*, 36 347-349, 1951
MOERSCH, H J and MCDONALD, J R Bronchial adenoma *J A M A*, 142 299-304 1950
MOERSCH, H J, TINNEY, W S and MCDONALD, J R Adenoma of the bronchus *Surg, Gynec & Obst*, 81 551-558, 1945
MYERSON, M C Benign neoplasms of the bronchus *Arch Otolaryng*, 9 376-385, 1929
NACLERIO, E A and LANGER, L Adenoma of the bronchus *Am J Surg*, 75 532-537, 1948
NIXON, J W and PERRY, J F Arteriovenous fistula of the lung and an associated hemangioma of the vertebra *Dis of Chest*, 21 108-116, 1952
NOWELL, S Value of tomography in lesions of the main bronchus and their larger sub-divisions *Proc Roy Soc Med*, 40 399-405, 1947
O'BRIEN E J, TUTTLE, W M and FERRANEY, J E The management of the pulmonary 'coin' lesion *S Clin North America* 28 1313-1322 1948
PATTERSON, E J Benign bronchial neoplasms *Arch Otolaryng*, 12 739-746, 1930
PAUL, F Bronchostenose durch ein polypöses Myochondrom des Bronchus *Monatschr f Ohrenh*, 64 660, 1930
PLAUT, A Hemangioendothelioma of the lung *Arch Path*, 29 517-520, 1940
RABIN C B and NEUHOF, H Adenoma of the bronchus *J Thoracic Surg*, 18 149 154 1949
RAMSAY, B H Pulmonary segmental resection solitary lesions of doubtful character *Californ Med*, 74 14-16, 1951
RANDALL, W S and BLADES B Primary bronchogenic leiomyosarcoma *Arch Path*, 42 543-548 1946
RUBIN, M and BERMAN, J Chondromatous hamartoma of the lung *J Thoracic Surg*, 23 303 308, 1952
SCHEIDE, F W Ein grosse fibrom der linken lunge *Zentralbl f allg Path u path Anat*, 89 93-94, 1952
SCHWARTZ, L Adenoma of the trachea and the bronchus *Arch Otolaryng*, 39 231-232, 1944
SCOTT, W H, MORROW, A G and PAYNE, T P B Solitary xanthoma of the lung *J Thoracic Surg*, 17 821-825, 1948
SHERMAN, R S and MALONE, B T A roentgen study of muscle tumors primary in the lung *Radiology*, 54 507-515, 1950
SIMON, M A Hamartomas of the lung and so-called "pulmonary adenomatosis' *Am J M Sc*, 216 333 342 1948
SMOLLER, S and MAYNARD A Del Adenoma of the bronchus in a nine year old child *Am J Dis Child*, 82 587 592, 1951
SOM, M L Adenoma of the bronchus Endoscopic treatment in selected cases *J Thoracic Surg*, 18 462-472 1949
SOM, M L and FEUERSTEIN, S S Endoscopic removal of lipoma of the bronchus *Arch Otolaryng* 54 341-346 1951
SOLDERS C R and KINGSLEY, J W Bronchial adenoma *New England J Med*, 239 459-466, 1948
STOUT, A P Cellular origin of bronchial adenoma *Arch Path*, 35 803-807, 1943
SUTTON, J B Tumors—Innocent and Malignant London 1894 Cassell & Co

THOMAS M R A cystic hamartoma of the lung in a newborn infant *J Path & Bact* 61 599–606 1949

THORNTON T F ADAMS W E and BLOCK R G Solitary circumscribed tumors of the lung *Surg Gynec & Obst* 78 364 370 1944

TOUROFF A S W and SELEY G P Lipoma of the bronchus and lung *Ann Surg* 134 244 250 1951

ULRICH K Endobronchialis hamartochondrom *Arch Ohr u Hel k* 147 149 478–488 1941

VAN HAZEL W HOLINGER P H and JENSIK R J Adenoma and cylindroma of the bronchus *Dis of Chest* 16 146–166 1949

VERGA P I condromi del polmone *Patbologica* 24 1 22 1932

VINSON P P and BEABLETON W E Lipoma of left main bronchus *Arch Otolaryng* 35 868–870 1942

WATTS C F CLAGETT O T and McDONALD J R Discussion of benign neoplasms and report of a case of endobronchial lipoma *J Thoracic Surg* 15 132 144 1946

WEBER H M Notes on a variety of roentgenologic problems *Am J M Sc* 209 688 692 1945

WESSLER H and RABIN C B Benign tumors of the bronchus *Am J M Sc* 183 164 180 1932

WHALEN E J Lipoma of the bronchus *Ann Otol, Rhin & Laryng* 56 811 818 1947

WHITAKER W Cavernous hemangioma of the lung *Thorax* 2 58–64 1947

WHITESIDE J H Hamartoma of the lung *Canad M A J* 63 383 384 1950

WILLIAMS R B and DANIEL, R A Leiomyoma of the lung *J Thoracic Surg* 19 806–810 1950

WOODHOUSE G E Hemangioma of the lung *J Thoracic Surg* 17 408 415 1948

WOLPAW S E The diagnosis and management of asymptomatic isolated intrathoracic nodules *Ann Int Med* 37 489–505 1952

WOMACK N A and GRAHAM E A Mixed tumors of the lung so-called bronchial or pulmonary adenoma *Arch Path* 26 165 206 1938

YATER W M FINNEGAN J and GRIFFIN H M Pulmonary arteriovenous fistula (varix) review of the literature and report of 2 cases *J A M A* 141 581 589 1949

YOUNG J M et al Endobronchial hamartoma *J Thoracic Surg* 27 300–305 1954

Hamartoma

JOSEPH STEIN, M D AND MAXWELL H POPPEL, M D, New York, New York

From the Department of Radiology Veterans Administration Hospital Bronx New York

IN 1904 Albrecht[1] described instances of biliary hamartomas He defined "hamartoma" as 'tumor like malformations in which occur only abnormal mixing of the normal components of the organ The abnormality may take the form of change in quantity, arrangement, or degree of differentiation, or may comprise all three The deduction to be drawn from the histologic examination of these formations is that they have originated in abnormal mixing of their development'

The lesions have been variously reported as papillomas fibroadenomas, chondromas, mixed tumors hamartoma chondromatosum, adenochondromas and lipochondromas Many of these tumors embrace all of the bronchial anlagen, both mesodermal and endodermal tissues Albrecht designated all of these mixed tumors as hamartomas So-called chondromas of the lung are in reality hamartomas and, according to Jones[2] they constitute 0 25 per cent of all routine autopsy cases McDonald, Harrington and Clagett[3] report twenty hamartomas in a series of 7,972 necropsies an incidence of 0 25 per cent These chondromas of the lung contain bronchial epithelium in clefts between cartilaginous masses and may also include the mucoid fibrous, lymphoid and muscular tissues The term hamartoma should be reserved for this type of lesion

Hickey and Simpson[4] reviewed forty cases of primary chondroma of the lung and added two cases of their own Microscopic examinations of their own cases indicated a composition of islands of cartilage myxomatous connective tissue adipose tissue mature fibrous connective tissue and papilliferous gland like structures covered by a single layer of non-ciliated cuboid or columnar epithelial cells In some areas the tumors were covered by stratified ciliated epithelium and contained lime salt deposits Generally the tumors contained the structures previously enumerated although in a few instances osseous tissues were present

Postlethwait et al[5] report a hamartochondroma presenting itself endobronchially, thus causing bronchial occlusion They reported thirteen such similar cases from their review of the literature

Because pulmonary hemangiomas represent an alteration in quantity and arrangement of normally occurring structures of that particular organ, Simon[6] considers pulmonary hemangiomas to be hamartomas They may produce polycythemia, clubbing of the fingers cyanosis and variable degrees of dyspnea Although these tumors conform to Albrecht's definition of hamartoma, hemangioma appears to be a more descriptive term Hall[7] believed that many of the hemangiomatous lesions of the tongue, liver and spleen, as well as some fibromas of the kidney and rhabdomyomas of the heart, were hamartomas Adenoma sebaceum, tuberous sclerosis, Lindau's disease, phacoma of the eye and neurofibromatosis have been considered by some investigators to be examples of hamartomas although this may be farfetched

Verga[7] reported a tendency to invasion in one of his cases and listed several examples in which metastases had apparently occurred However we share the opinion that pulmonary hamartoma is generally a benign lesion

The usual pulmonary hamartoma measures several centimeters in diameter It may, however, vary in size from less than 1 cm in diameter to a very large proportion Jones[2] described a case in which the hamartoma was so large that it occupied all of the right upper lobe of the lung This is a very uncommon finding

Sex Age and Location The incidence is generally considered higher in men in the proportion of 2 or 3 to 1 There is no significant age distribution These tumors may be discovered at necropsy in older individuals but with the advent of routine roentgenographic chest surveys it is anticipated that these lesions will be found more often in younger individuals

Pulmonary hamartomas are said to be usually peripheral and generally just below the visceral pleural surface However, they may occur anywhere in relation to the bronchial tree and pleural surface

Signs and Symptoms Secondary polycythemia, clubbing of the fingers, cyanosis and dyspnea may be expected if one would include pulmonary hemangiomas as hamartomas However, hamartomas not producing bronchial obstruction frequently produce no abnormal symptoms or signs Bronchial obstruction is rather a rare phenomenon in this condition Usually the occurrence of the pulmonary hamartoma is first suspected on an incidental chest roentgenographic examination

Roentgen Diagnosis Pulmonary hamartoma is usually sharply circumscribed and well demarcated with no surrounding infiltrate It is generally spheroid and may be lobulated Calcification and sometimes ossification may be noted within the contour of the lesion Hall[7] reported four cases of pulmonary hamartoma all of which contained demonstrable calcium in the roentgenograms Lemon and Good[8] showed evidence of calcification or ossification in eleven of seventeen cases Calcification was noted in one of our three cases by roentgenography and ossification was seen in another case microscopically Characteristically a hamartoma is indolent It generally does not change in size or shape over a period of years One of Hall's cases[9] was followed for five years and another for twenty-one years by repeated roentgenographic examinations with no demonstrable increase in size The latter case showed an apparent increase in the amount of calcification while under observation One of our own cases was followed for twelve years and showed probably a very slight increase in size (apparent growth of 0 5 cm in one diameter) which we cannot completely account for on technical factors In those instances in which a hamartoma (hamartochondroma) arises from the inner wall of the bronchus, there may be obstructive emphysema present initially to be followed by atelectasis and areas of obstructive pneumonitis

Hall[9] Hickey and Simpson,[4] and others have maintained that the roentgen appearance of a pulmonary hamartoma is sufficiently characteristic for an accurate diagnosis This opinion is not shared by Lemon and Good[8] on the basis of their own experience, and we believe quite strongly that an accurate diagnosis without thoracotomy is impossible in most instances

Most of the hamartomas are peripherally located and thus a bronchoscopic examination is usually of no value Bronchography will simply indicate a tumor adjacent to one of the bronchial radicles Laminographic roentgen studies may be of benefit in demonstrating the exact contour of the lesion and determining the presence of calcification or ossification Thoracotomy with microscopy is the only definitive measure for establishing a diagnosis

DIFFERENTIAL DIAGNOSIS

The differential diagnosis is that of any of the solitary, spheroid, circumscribed pulmonary densities which may present themselves on the chest roentgenogram

Peripheral Bronchogenic Carcinoma This lesion at inception may very well simulate a hamartoma but only exceptionally contains demonstrable calcification and generally grows rapidly in contradistinction to the known indolence of hamartoma However, on rare occasions in a series of about 1,000 pulmonary malignant neoplasms we have observed a small shadow that remained unchanged for two or three years and then suddenly acquired rapid growth Occasionally there may be zones of breakdown within a carcinomatous mass which we have not observed or heard of in hamartoma Metastases from peripheral bronchogenic carcinoma to the brain, bones, regional lymph nodes and other segments of the lung are very common early in the disease It has been our experience that a lung lesion associated with cerebral symptoms is almost always a malignant neoplasm Pulmonary hamartomas metastasize only very rarely, if at all Hamartoma appears "built in" Malignant neoplasm resembles an "*intruder*," often causing changes in pulmonary dynamics such as atelectasis, raising of the diaphragmatic leaflet, mediastinal nodes, etc

Tuberculoma Tuberculoma may exactly simulate a hamartoma in appearance Calcifications within the contour of tuberculoma are quite common (probably a good deal more so than in a hamartoma) Small, adjacent linear infiltrates or fibrotic strands may sometime be seen, while in a hamartoma the surrounding pulmonary tissues are normal There may be other areas of involvement by tuberculous infiltrates both in the lungs and elsewhere in

the body Areas of breakdown within the contour of tuberculoma may occur occasionally Tuberculomas are less apt to grow perceptibly than bronchogenic carcinomas but a demonstrable increase in size is not as rare as in hamartomas It should be noted that on the basis of frequency of occurrence when there is a differential diagnosis considered between tuberculoma and hamartoma the former is the more likely diagnosis In a tuberculoma some calcified regional lymph nodes may be present

Chronic Lung Abscess Occasionally a chronic lung abscess may assume a spheroid configuration with no demonstrable breakdown and thus simulate a hamartoma in appearance Graham and Singer [9] have reported three cases of chronic lung abscess containing calcification Usually however the cause of lung abscess is such that obvious roentgenographic evidence of breakdown occurs and the nature of the lesion becomes apparent There may be spill over into the dependent portion of the lungs

Cyst Pulmonary bronchogenous or enterogenous cysts may be filled with fluid and simulate hamartoma in that they appear circumscribed and spheroid Here again progress films will indicate the true nature of the lesion particularly when a bronchogenous communication is established or re established and the fluid content of the cyst is drained There may also be a change in the size and shape of a cystic lesion on roentgenograms taken in inspiration and expiration and during the physiologic maneuvers of Müller and Valsalva while solid lesions such as hamartoma remain unchanged

Infarct Pulmonary infarcts are usually triangular in appearance shortly after their inception although they may simulate ordinary zones of pneumonitis About 40 to 50 per cent of infarctions are accompanied by pleural fluid Hampton and Castleman [11] have demonstrated that occasionally multiple infarcts which are contiguous may present the appearance of a single solitary density simulating a hamartoma However the clinical history frequently suggests an infarct and the course in progress films is such that the diagnosis is generally not too difficult The triangular or even the spheroid density which is caused by the infarct becomes smaller as weeks or months go by and residual linear densities simulating lobular areas of atelectasis are noted

Arteriovenous Angiomatosis There may be one or more lobulated irregular densities These are usually connected by cord like vascular densities They may be frequently observed to pulsate roentgenoscopically Angiocardiography is decisive

Metastatic Pulmonary Carcinoma A single solitary metastatic focus in the lungs may be confused with a hamartoma but the course of the disease is such that these solitary densities grow rapidly in size and other opacities quickly appear Frequently the presence of a known primary focus establishes a diagnosis immediately and there is no likelihood of confusion with a hamartoma

However one of Hickey s and Simpson s [4] patients had associated carcinoma of the stomach and another carcinoma of the prostate In their forty reviewed cases of hamartoma three had associated carcinomas elsewhere namely two in the prostate and one in a bronchus Therefore when a pulmonary lesion is identified in the presence of a known malignancy elsewhere careful consideration should be given in evaluating operability One of our patients had an abdominoperineal resection with colostomy for carcinoma of the rectum in 1931 and is alive and well as of 1954 an interval of twenty three years He had associated pulmonary hamartoma which might have jeopardized the performance of a needed and life saving surgical procedure On August 19 1954 he was discharged from this hospital in good condition following cholecystectomy for biliary lithiasis

The differential diagnosis may be difficult but with the advent of laminagraphy and other methods one is better able to evaluate the differential diagnosis Biopsy however is the only basic dependable and definitive diagnostic measure As Miscall [10] expressed himself in a conference fortunately there is a relatively safe and simple method to establish a diagnosis Therefore a single solitary lesion of the chest in the presence of operable malignancy elsewhere should not deter the clinician from giving consideration to the possibility that it may not be metastatic and unrelated to primary disease Benign conditions such as hamartoma neurofibroma cyst tuberculoma etc may coexist in the presence of surgically curable primary malignant neoplastic disease Not every nodulation is metastatic

FIG 1A and B Case 1 A chest roentgenogram January 17 1949 demonstrates a mass in right mid lung Surrounding lung structures normal B chest roentgenogram November 2 1949 identifying same mass with no increase in size

FIG 1C Case 1 Photomicrograph showing bizarre arrangement of bronchi hematoxylin and eosin × 100

CASE REPORTS

CASE 1 This sixty year old white man was admitted to the hospital November 28 1949 because of a right inguinal hernia of fifteen years duration A routine chest x ray was diagnosed elsewhere as a nodule or lobulated neoplastic disease There was no significant respiratory history or any other symptoms Physical findings outside of the hernia were essentially normal The hernia became incarcerated and emergency herniorrhaphy was performed with an uneventful recovery

The problem of the chest condition remained to be solved Roentgenograms of the chest (Figs 1A and B) showed a spheroidal well circumscribed density in the right mid lung which measured 2 by 2 cm The lungs were otherwise clear Laminagraphic studies showed no evidence of calcification in the lesion The patient was transferred to the chest service and on December 30 1949 a right sided thoracotomy was performed A solitary discrete tumor of the right lower lobe lying immediately adjacent to the interlobar fissure was found The tumor was shelled out completely and a frozen section was reported as a benign tumor The postoperative course was uneventful

Pathologic report revealed the following A gross specimen consisting of a circular mass measuring 2 by 2 cm was sectioned The external surface appeared to be fibrous capsule which was hemorrhagic and on section showed

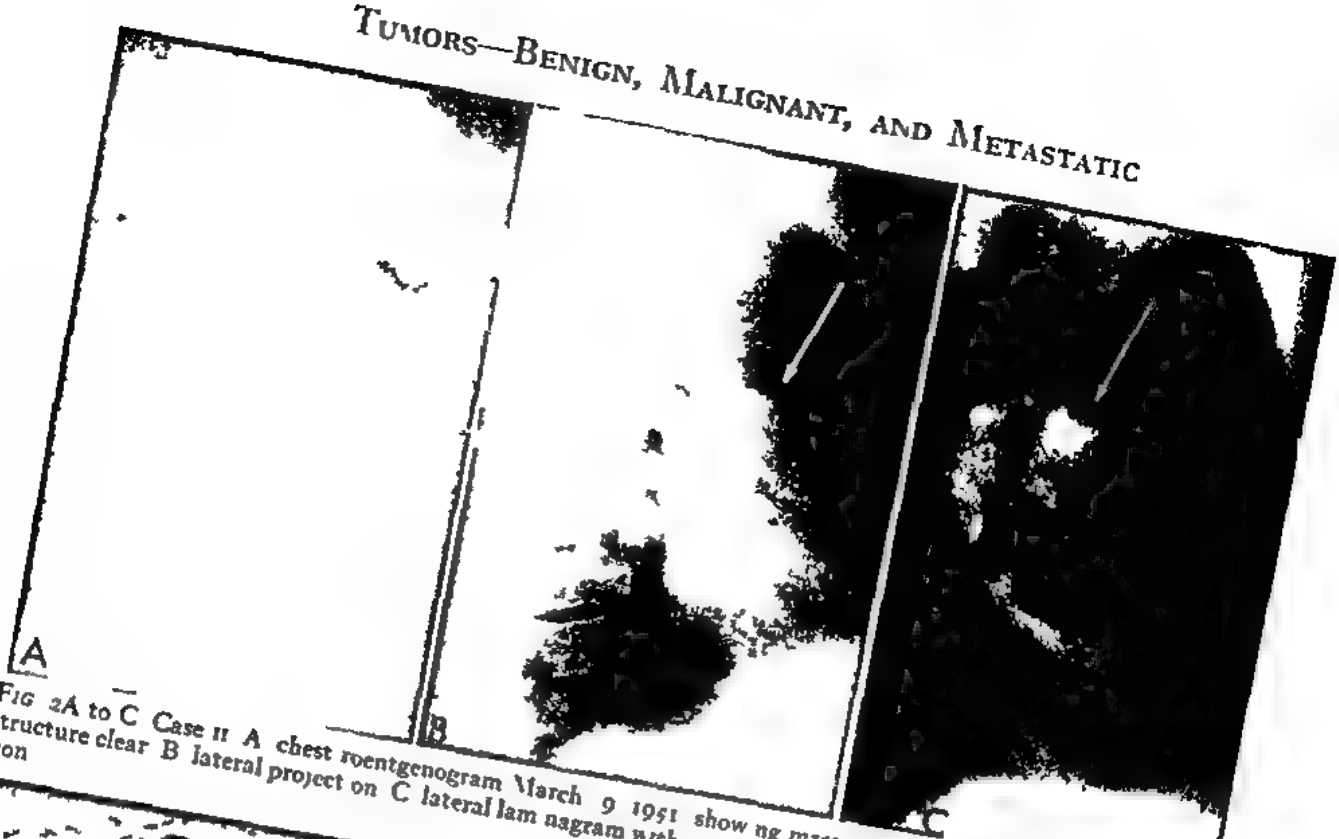

FIG 2A to C Case II A chest roentgenogram March 9 1951 show ng mass in the r ght lung Surrounding lung structure clear B lateral project on C lateral lam nagram with arro v po nt ng to mass show ng punctate calc fica tion

F G 2D and E Case II D photom crograph show ng bronch al hamartoma hematoxyl n and eos n X 20 E photom crograph and h gher magn f cat on sho ing ben gn ep thel um and atyp cal cart lage n hamartoma hematoxyl n and eos n X 100

mucoid firm cartilaginous tissue and a few whitish areas Microscopic examination showed nodules of cartilage with intervening connective tissue and fat enclosing narrow spaces lined by single-layered cuboid non-ciliated epithelium (Fig 1C) The microscopic diagnosis was pulmonary hamartoma (benign)

CASE II This fifty three year old Negro man was admitted March 16 1951 with a story of a mass in the right lung d scovered in a routine chest examination upon coming to the hospital The patient complained of a cough of about ten years durat on w h ch was productive of about 2 tablespoons of dark

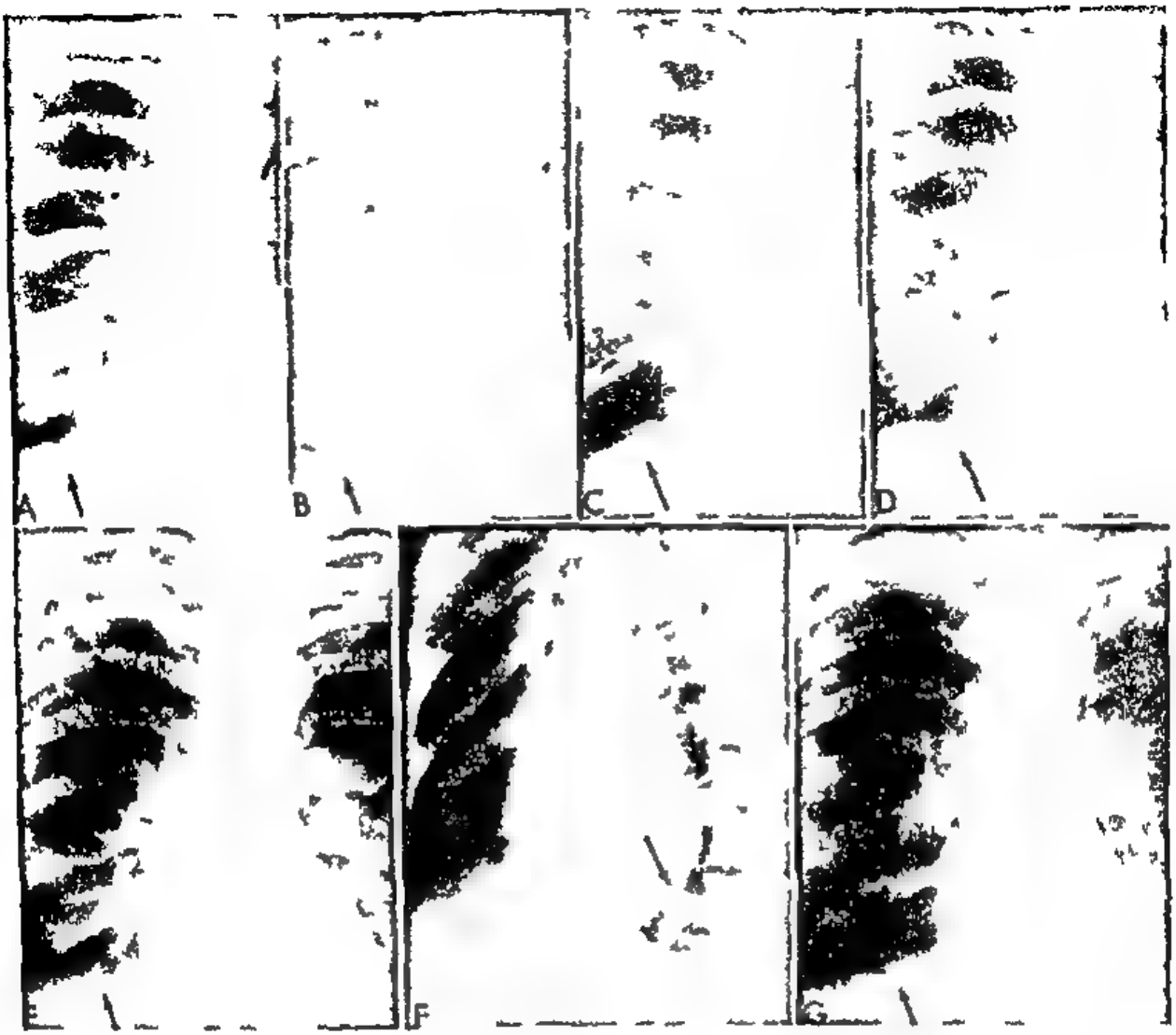

FIG 3 Case II Radiographically recorded surgically and microscopically authenticated case of hamartoma of

of the mass above the diaphragmatic level (arrow) It measures 2 by 2 cm and no increase in growth over exposure made in 1940 C)

mucoid non foul sputum daily with no history of hemoptysis There were no other significant symptoms

Pertinent abnormal physical findings were mild hypertension central opacities in the eyes slight left heart enlargement and a Grade II systolic murmur at the base of the heart There was also atrophy of the left testicle and questionable enlargement of the prostate

Chest roentgenographic studies (Fig 2A and B) showed a spheroid density in the right mid lung measuring 2 5 by 3 0 cm Laminagraphic studies (Fig 2C) showed punctate calcifications within the contour of the mass Further studies including barium enema gastrointestinal series intravenous urography hemogram urine analysis sedimentation rate and blood chemical studies were all within

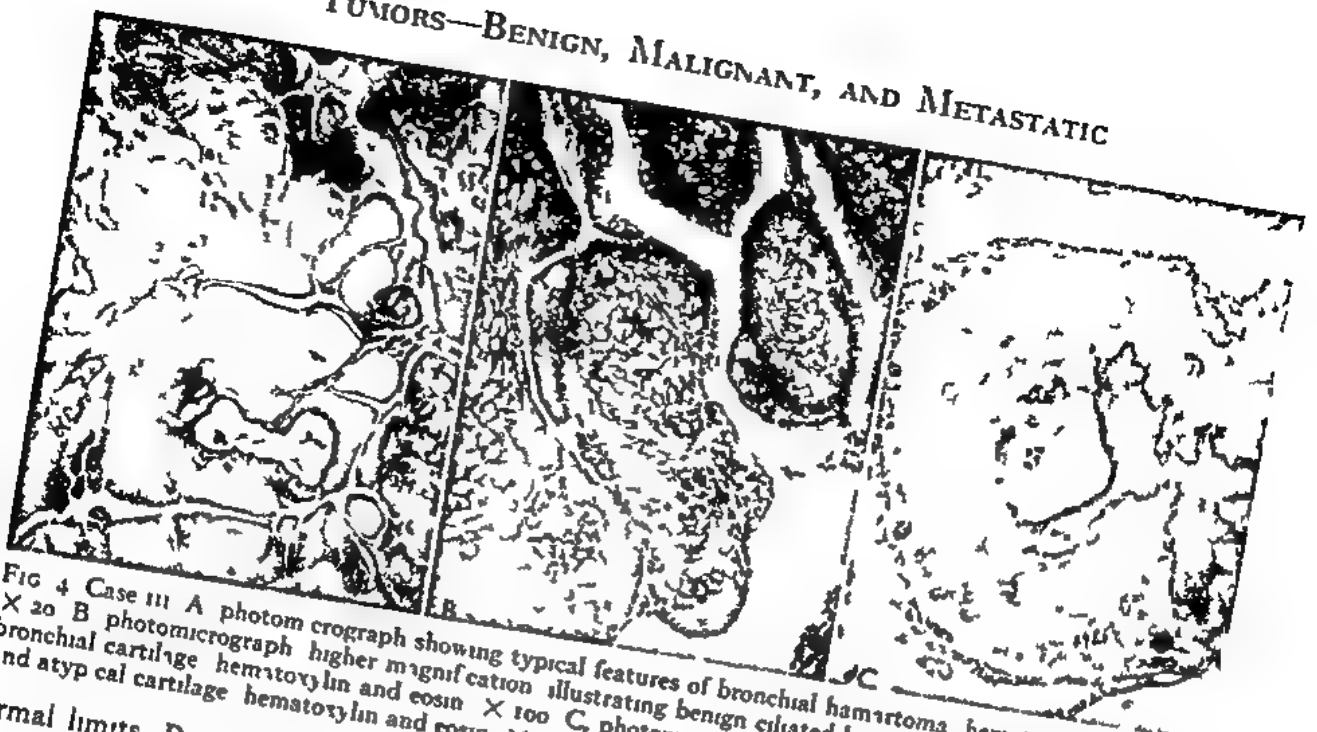

FIG 4 Case III A photomicrograph showing typical features of bronchial hamartoma hematoxylin and eosin × 20 B photomicrograph higher magnification illustrating benign ciliated bronchial epithelium and atypical bronchial cartilage hematoxylin and eosin × 100 C photomicrograph demonstrating metaplastic ossification and atypical cartilage hematoxylin and eosin × 100

normal limits Papanicolaou prepared sputum from bronchoscopy showed no neoplastic cells The P P D tuberculin test in the first strength was positive with a 2 plus reaction to forty eight hours

Thoracotomy was performed May 11, 1951, and a mass described in the roentgenogram was found attached to a very small bronchus It measured 3 cm in diameter and was located in the area of the fissure between the upper and middle lobes The fissure itself was rudimentary and whether this mass was in the upper or middle lobe could not be clearly determined The mass was firm oval and shelled out easily The postoperative course was uneventful

On gross examination the specimen consisted of a firm nodule measuring 2 5 by 2 cm On section the mass was seen to be composed of a central dense homogeneous, grayish white tissue from which many large nodules radiated toward the circumference Microscopically, there was a multilobed sheet of atypical cartilage with connective tissue, fat and clefts between the lobes lined by epithelium of bronchial type (Fig 3D and E) The microscopic diagnosis was epitheliochondromatous hamartoma

CASE III This forty eight year old white man was admitted to the hospital February 18 1949 for evaluation of a previously demonstrated chest lesion seen on roentgenographic study in 1948 The patient had had an abdominoperineal resection with colostomy for carcinoma of the rectum in 1931 During the usual follow-up studies in 1948 a chest roentgenogram showed a small rounded nodule in the right lower lung posteriorly Review of a chest roentgenogram made in 1937 (Fig 3A) showed the nodule to be present at that time measuring 2 by 1 5 cm It measured 2 by 2 cm on the chest roentgenogram taken in 1949 (Fig 3G) suggestive of a 0 5 cm increase in size in one of the diameters in twelve years

During the month previous to admission the patient had had a dull pain in the right side of the chest which was rather constant and radiated to shoulder, head and neck The patient complained of a chronic cough with expectoration of a small amount of whitish mucoid sputum daily without blood or foul odor The remaining history was not relevant

Examination revealed a middle aged patient not seriously ill The pertinent abnormal physical findings consisted of a functioning left sided colostomy, a few moist rales in the right base, bilateral inguinal hernias and a moderate prostatic enlargement

Laboratory data revealed the following Hemogram urinalysis and spinal fluid examinations were normal There were no acid fast bacilli in the sputum Glucose test showed a mild diabetic curve Roentgenographic studies of the gastrointestinal urinary and skeletal systems disclosed no abnormalities except for the functioning colostomy and the chest

roentgenograms showed a spheroidal circumscribed nodular density in the base of the right lung measuring 2 by 2 cm

On March 28 1949 right sided thoracotomy was performed A small circumscribed tumor was found in the right lower lobe and lobectomy was performed The patient made an uneventful recovery

Pathologic report revealed that the specimen consisted of the right lower lobe of the lung Three centimeters from the edge of the lobe there was a rounded calcified tumor measuring 2 5 by 2 5 cm On section this mass showed a calcific surface underlying which was a firm white grumous material Microscopically (Fig 4A B and C) the mass consisted of a bronchial type Some of the cartilage was atypical In [illegible] he of o-

This patient had carcinoma of the rectum associated with a benign hamartoma Through surgery the patient was apparently cured of carcinoma of the rectum and had the nodule been identified prior to the time of surgery the patient might have been considered inoperable Identification after surgery might lead one to believe that metastatic disease occurs postoperatively This patient is alive in 1954 twenty three years following surgical resection of carcinoma of the rectum

SUMMARY AND CONCLUSIONS

Three cases of pulmonary hamartoma observed at this hospital are presented In one patient there was associated carcinoma of the rectum and it is indicated that not all nodular densities in the lung associated with neoplastic disease represent metastases

1 The incidence definition and gross and microscopic anatomy of pulmonary hamartoma are presented

2 The common locations of hamartoma in the lung are described

3 The clinical signs and symptoms of pulmonary hamartoma are listed

4 There are no pathognomonic roentgen signs of pulmonary hamartoma It may be suspected in a single solitary spheroidal opacity in the lung of long duration without appreciable growth

5 Three personally observed cases of pulmonary hamartoma are presented including a summary of the history, physical findings roentgen appearance and pathologic reports

6 Hickey and Simpson s two personally observed cases had associated malignant neoplasms Three of their forty reviewed cases in literature and one of our own three cases had associated primary neoplastic malignant disease giving an incidence of six of forty five cases

7 Not all nodular lesions in the chest with diagnosed primary carcinoma elsewhere represent metastatic disease

Acknowledgments We are indebted to the Medical Illustration Service for preparing the photographs and to Charles C Thomas for permission to use illustrations from the manuscript by Stein et al from *American Journal of Roentgenology Radium Therapy and Nuclear Medicine* December 1 1953

REFERENCES

1 ALBRECHT E Ueber Hamartome *Verhandl d deutsch path Gesellsch* 7 153 157 1904

2 JONES C J Unusual hamartoma of lung in newborn infant *Arch Path* 48 150–154 1949

3 McDONALD J R HARRINGTON S W and CLAGETT O T Hamartoma (often called chondroma) of lung *J Thoracic Surg* 14 128–143 1945

4 HICKEY P M and SIMPSON W M Primary chondroma of lung *Acta radiol* 5 475 500 1926

5 [illegible]

6 [illegible] 216 333 342 1948

7 VERGA P I condromi del polmone *Patologica* 24 1 22 1932

8 LEMON W E and GOOD C A Hamartoma of lung *Radiology* 55 692–699 1950

9 HALL, W C Roentgenologic significance of hamartoma of lung *Am J Roentgenol* 60 605–611 1948

10 GRAHAM E A and SINGER J J Three cases of resection of calcified pulmonary abscess (or tuberculosis) simulating tumor *J Thoracic Surg* 11 173 183 1936–37

11 HAMPTON A O and CASTLEMAN B Correlation of postmortem chest teleroentgenograms with autopsy findings *Am J Roentgenol* 43 305 325 1940

12 SHERWOOD K K and SHERWOOD H H Enchondromata of lung with report of fatal case *Journal Lancet* 52 395 398 1932

13 MISCALL, L Personal communication

85

Preclinical Bronchogenic Carcinoma

KATHARINE R BOUCOT M D *Philadelphia Pennsylvania*

Less than 10 per cent of lung cancer patients seen by thoracic surgeons survive five years The same grim situation is true for cases found by current survey methods [1] Is the poor prognosis due to delay in detection or is it inherent in the tumors themselves? The answer is not yet available and will not be until concerted efforts result in a better detection program

While the characteristics of early lung cancer have not yet been clearly delineated let

With this definition in mind preclinical lung cancer may be classified as follows

I Asymptomatic
  A Without recognizable roentgenographic abnormalities
  B With recognizable roentgenographic abnormalities
    1 roentgenographic changes missed
    2 roentgenographic changes noted
II Symptomatic
  A *Clinician not consulted*
  B Clinician consulted
    1 Physician failure to recognize possibility of malignancy
    2 Physician alert to possibility of malignancy
      a patient refusal of adequate study
      b patient acceptance of adequate study

There must be in the natural history of every lung cancer a period of indeterminate length during which the patient has no symptoms attributable to the new growth and because of minuteness of size the malignancy cannot be seen radiologically For the patients at this stage of tumor growth there is no possibility of diagnosis since even though such tests as the Penn Dowdy serum flocculation test may screen them out as suspect there is no current possibility of determining the site of such very early cancers

However there is a group of asymptomatic

TABLE 1
PREVALENCE PER 100 000 OF PROVED CASES OF BRONCHOGENIC CARCINOMA* BY SEX AND AGE

Sex and Age	No	Proved Bronchogenic Carcinoma	Rate per 100 000
Under 45 years			
Females	58 645	1	2
Males	56 116	3	5
Total	114 721	4	3
Over 45 years			
Females	1 858	1	9
Males	16 577	47	284
Total	27 435	48	175
Over all total	142 156	52	37

* Based on 142 156 individuals x rayed at two official Philadelphia Units Unit 1 total 1947 foodhandlers only 1949 through 1952 Unit 3 total 1949 through 1952

lung cancer patients who have abnormal roentgenograms In our experience about 10 per cent of survey detected carcinoma occurs in persons without symptoms This is the most important segment of proved cases since a high proportion of asymptomatic patients are resectable and may survive five years Since the highest prevalence of primary bronchogenic carcinoma is among men over forty five (Table 1) it is feasible to urge asymptomatic men in this age group to report for survey films every six months

With dual readings of films[2,3] we believe semiannual chest roentgenograms or photofluorograms to be the most effective method for

detecting those tumors so peripherally situated as to be surrounded by ventilated pulmonary tissue This group has the best prognosis Such patients usually have negative bronchoscopic and cytologic studies and a high resectability rate If the tuberculin test is positive and calcium is present in nummular lesions, it seems safe to assume a tuberculous etiology Otherwise, exploration is mandatory if the patient seems able to withstand the procedure The difficulties here are those involved in persuading the patient to accept hospitalization in the absence of symptoms

Despite the best efforts a few small tumors will be missed in this group because of overlying structures or the difficulty of distinguishing them from adjacent pleura or other shadows of similar homogeneous density In the study of 100 survey lung cancer cases referred to previously [1] there were twenty nine patients on whom previous "negative" films were available for review Of these sixteen had erroneously been classified as negative Five of these were still without symptoms at the time new photofluorograms were recognized as abnormal Despite delays in recognition two of the five asymptomatic men were resected and are alive more than five years after the first truly abnormal film

What percentage of lung cancer cases have symptoms? One of our studies was made on all proved cases out of a large basic group x rayed with follow up centered on those with photofluorographic abnormalities Of a series of 100 cases 90 per cent had symptoms [1] However such information was elicited on interview *after* the film abnormalities had been noted

In an effort to study more adequately the time relationships between symptoms and roentgenographic abnormalities the Philadelphia Pulmonary Neoplasm Research Project[4] began operating in December 1951 The men over forty five who join this Project are not a random sample but they are interviewed in regard to symptoms before their films are developed so that we are able to correlate symptoms with x ray changes in the whole group not just for those with carcinoma Among the first 3 006 men over forty five years of age who entered this Project during the first two years of operation twenty eight proved bronchogenic carcinomas were diagnosed over a follow up period of six to thirty months Not one of these men was without any symptom The prevalence of cancer according to five major symptoms is presented in Table II It should be noted however, that, among the twenty eight cases in this preliminary presentation of the Philadelphia

TABLE II
PRIMARY BRONCHOGENIC CARCINOMA ACCORDING TO THE PRESENCE OF FIVE MAJOR SYMPTOMS*

Symptoms†	No	Per cent of 3 006	Proved Carcinoma	
			No	Per cent
None of five major symptoms present	1 977	65 8	7	0 4
Cough for months or years	787	26 2	17	2 2
Worsening cough	108	3 6	5	4 6
Hemoptysis	151	5 0	6	4 0
Unilateral wheeze	113	3 8	1	0 9
Weight loss of more than 10 pounds	227	7 6	7	3 1

Note Follow up to June 3 1954
* Among the first 3 006 men entering the study between December 4 1951 and December 3 1953 Philadelphia Pulmonary Neoplasm Research Project
† Categories not mutually exclusive

Pulmonary Neoplasm Research Project findings differed from routine surveys only in the availability of data from a questionnaire Therefore we may anticipate that the fate of these patients will not be better than that of other survey detected cases As the study progresses there will be cancer cases among those whose original films were negative To date there has been only one such case In this instance unilateral wheeze preceded the photofluorographic abnormality by nineteen months

There is no characteristic syndrome of lung cancer the symptomatology depending on the site of origin relationship to nerves or vital structures rapidity of growth etc Therefore it is difficult to devise the needed educational program for lay persons It does seem that men over forty five could well be advised to seek medical consultation periodically, and certainly when respiratory symptoms persist or worsen In our series of survey-detected cases almost half failed to report to a physician despite the presence of symptoms Only when patient delay is markedly reduced can we hope

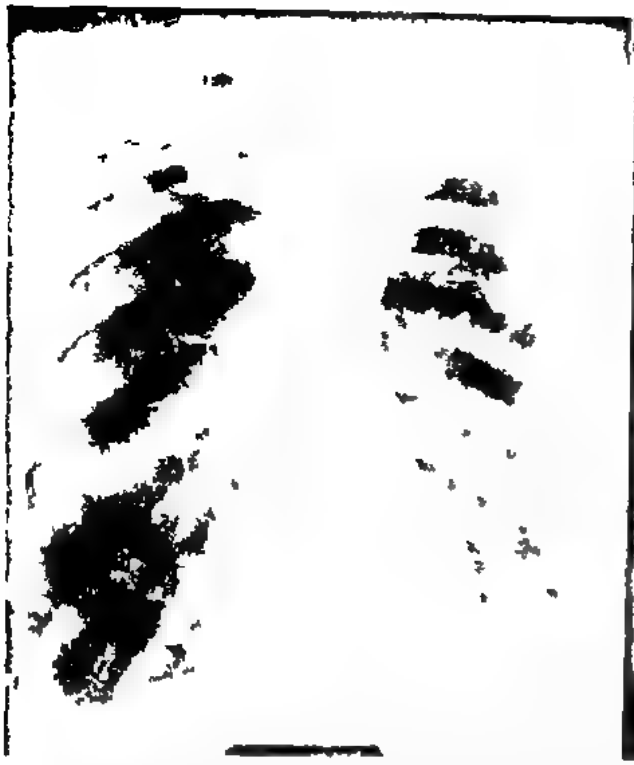

FIG 1 F B a fifty six year old Negro man had a 70 mm photofluorogram on July 26 1948 interpreted as minimal tuberculosis of indeterminate activity because of infiltrations in the right mid lung and left apex No note was made of the localized emphysema in the upper half of the right lung

FIG 2 Same patient A 14 by 17 roentgenogram taken at time of admission to a teaching hospital (January 18 1950) Atelectasis due to bronchogenic carcinoma Patient explored found inoperable He had both anaplastic bronchogenic carcinoma and active pulmonary tuberculosis Ten consecutive sputums were positive for acid fast bacilli.

to so expedite the diagnosis and treatment of this disease as to assess its curability

What of the 40 per cent of proved cases who do seek medical advice? It is unfortunate that many physicians fail to consider the possibility of malignancy Perhaps one should not be impatient because, from the viewpoint of the family physician, lung cancers, though increasing are not as frequent an explanation of respiratory symptoms as the pneumonias bronchiectasis and, at lower socio economic levels tuberculosis There is a problem as to whether or not patients will accept recommendations for extensive study Here is another fertile field for lay education Careful radiologic study is certainly practicable for all men over forty five with respiratory symptoms and represents the minimal indicated investigation If films are negative, and symptoms persist, cytologic study of sputum or bronchial secretions is as important a procedure for cancer detection as is examination of sputum for tubercle bacilli in tuberculosis

It is our impression that tumors originating in the larger bronchi give rise to symptoms of cough relatively early Certainly, by the time pneumonitis occurs the disease has progressed to the point where the size of the tumor is sufficient to permit suppuration distal to partial obstruction Many patients with advanced malignancies have histories of one or more episodes of "viral pneumonia" It is a sound plan to re-ray every pneumonia patient until a completely negative x ray is obtained Even then, the patient should be advised to return at once if symptoms recur and in the absence of symptoms, to report for semiannual roentgenograms

As Overholt pointed out years ago, lung cancer is a masquerading disease Presenting complaints are often shoulder or arm pain arthritis hoarseness or other symptoms not immediately pointing to the chest A great achievement would be made if *all* patients consulting physicians had annual chest x rays and male patients over forty five had semiannual radiograms

It is important to realize that it is not possi

FIG 3 S W a sixty five year old white man had a 70 mm photofluorogram on March 8 1948 because of cough and hemoptysis Film interpreted as suspect neoplasm Emergency hospitalization arranged

FIG 4 Same patient A 14 by 17 roentgenogram taken [redacted] time of cerebral accident (August 24 1951) revealed increase in size of right hilar mass and volume shrinkage of right upper lobe Patient died on October 21 1952

[illegible]

[illegible] Berlain and Rigler* in a carefully controlled study failed to find a reliable classification of the roentgenographic appearance or quality of a tuberculous pulmonary lesion Although we know of no similar study of proved cancer cases it has been our experience that only a little more than one-third such cases detected by survey methods were suspected of malignancy on the basis of their photofluorograms Almost as high a percentage were thought to have tuberculosis alone A quarter of the cancer patients had lesions that had been missed on earlier photofluorograms Thus as in all aspects of medicine there is no substitute for judgment The radiologic report should be viewed in the light of the over all picture Even if tuberculosis is suspected alone and confirmed [illegible]

at diagnosis are in order Ten per cent of our survey patients had active tuberculosis as well as proved bronchogenic carcinoma We have a case in which because of concentration on the presence of obvious densities suggesting tuberculosis obstructive emphysema was missed (Fig 1) and the patient allowed to progress to lobar atelectasis (Fig 2) before exploration was attempted only to reveal inoperable cancer and active tuberculosis

In another case, a man admitted as an emergency case to a teaching hospital because of a mass at the right hilum (Fig 3) was discharged on the basis of one specimen of bronchial secretions positive on smear for tubercle [illegible]

vealed an increase in size of the right hilar mass and volume shrinkage of the right upper lobe (Fig 4) Retrospective investigation of the records revealed that the culture from the specimen collected bronchoscopically had not been positive but this report had gone to the Record Room and had been appended to the chart without any physician's having seen it No other positive sputum had ever been

obtained Certainly, one unconfirmed smear positive for acid-fast bacilli does not constitute an adequate diagnosis of tuberculosis

In summary, while the present five-year survival rate from bronchogenic carcinoma is less than 10 per cent, we need not be pessimistic abo t the [illegible]

cancer cases at the time of clinical recognition suggests that a better prognosis may be possible with routine semiannual chest x-rays on asymptomatic men over forty five, a program of lay education to encourage asymptomatic men in this age group to seek prompt medical advice, and a heightened level of physician suspicion in regard to male patients over forty-five

REFERENCES

1 BOUCOT, K R and SOKOLOFF, M J Is survey cancer of the lung curable? Presented before American College of Chest Physicians in San Francisco, June, 1954 (not published)

2 YERUSHALMY J, HARKNESS J T, COLE J A and KENNEDY, B R The role of dual reading in mass radiography *Am Rev Tuberc*, 61 443 1950

3 YERUSHALMY, J The reliability of chest roentgenography and its clinical implications *Dis of Chest*, 2 133 1953

4 BOUCOT, K R, COOLER D A, NEALON T JR OTTENBERG, D J and THEODOS P A The Philadelphia pulmonary neoplasm research project a preliminary report In press

5 NEWELL, R R, CHAMBERLAIN, W E and RIGLER, L G Descriptive classification of pulmonary shadows A revelation of unreliability in the roentgenographic diagnosis of tuberculosis *Am Rev Tuberc* 69 4 566 1954

86

Cytology

JOHN R McDONALD M D *Rochester Minnesota*

From the Section of Surgical Pathology Mayo Clinic and Mayo Foundation Rochester Minn

A CYTOLOGIC laboratory for the examination of pulmonary secretions is a useful and almost necessary adjunct in a diagnostic center which deals with diseases of the thorax My colleagues and I have found it of inestimable aid in the diagnosis of obscure carcinoma of the

detection of unsuspected pulmonary carcinoma inasmuch as sputum can be raised from the vast majority of lungs

However attempts to mechanize the procedure have not proved too successful As it now because of the personnel time factor involved it a costly affair Most laboratories have utilized technicians to scan the smears of sputum and bronchial secretions and to spot any abnormal cells This is of inestimable aid in decreasing the time expended by the physician cytologist in examination of the smears of sputum or secretion It means of course that the negative reports are essentially the responsibility of the technician However the positive reports become the responsibility of the cytologist A year s training is necessary in order to make a technician capable of recognizing suspicious appearing cells in bronchial material A longer period of training is preferable and certainly leads to increased competency on the part of the technician scanner

The laboratory of pulmonary cytology at the Mayo Clinic has been organized so that sputum and pulmonary secretions or washings are examined The sputum is collected in bottles which contain 95 per cent ethyl alcohol This bottle is given to the patient with instructions to produce sputum from the lungs and not to put saliva into the bottle A twenty four hour specimen is not necessary Five smears are made at random from the sputum Selection of the grossly bloody portions of sputum apparently does not increase the incidence of positivity of the smears for cancers nor does the finding of whitish pieces aid In our laboratory the smear method rather than paraffin sections has been utilized because of the ease of preparation and also because more material can be examined by this particular method Our staining technic is that of hematoxylin and eosin rather than any of the trichrome technics that have been employed by others The diagnosis of anaplastic cells does not appear to be aided by the use of special stains inasmuch as the nucleus is the structure essential to the diagnosis anyway

RESULTS

During the six years of operation of our laboratory for pulmonary cytology we have reported positive findings in 1 600 cases In

from bronchial secretions Obviously study of both sputum and bronchial secretions gave positive results in some cases In 1 7 per cent of this entire group the diagnoses have been considered to be false positive

The results of cytologic examinations in our laboratory have been reported either as positive or negative on a purely objective basis The history has not been available during the examination of the suspected material This seems exceedingly wise to us In certain cases in which the diagnosis was considered at first to be falsely positive the patient has later been proved to have cancer of the lung Other patients are still awaiting an answer Temporarily these results have been called false positives The following case illustrates this

The patient a sixty three year old man stated on admission to the clinic that he had been coughing and wheezing for six months Wheezes were expiratory and inspiratory and bilateral A roentgenogram of the chest showed

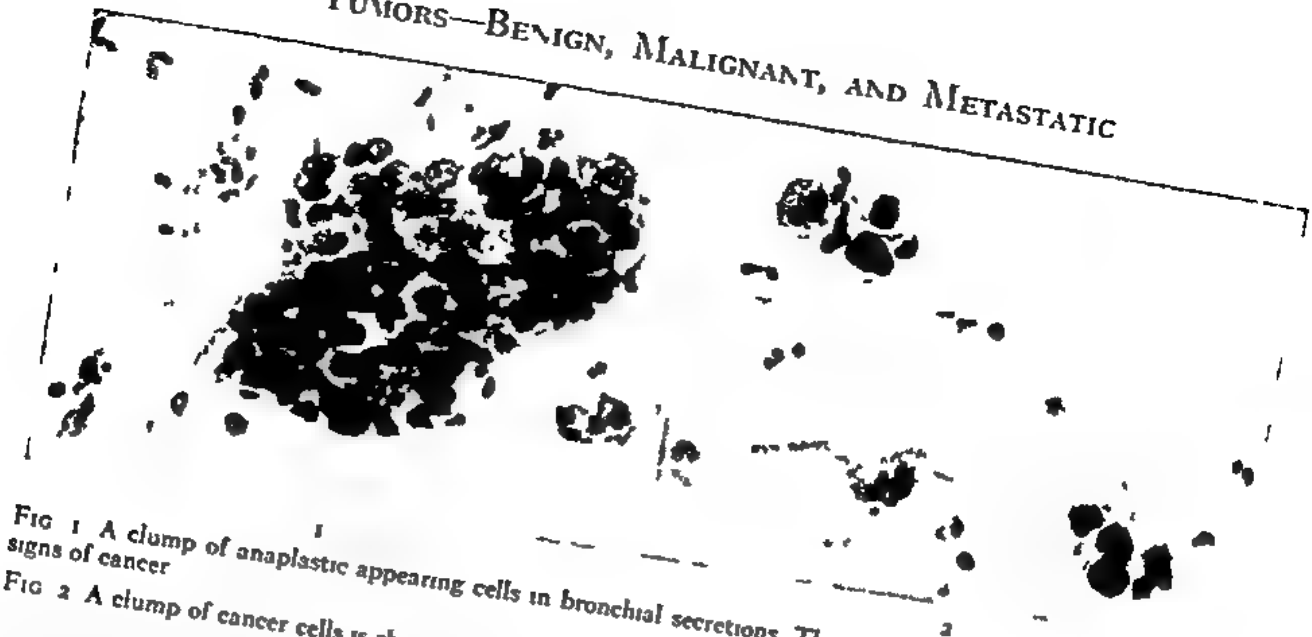

FIG 1 A clump of anaplastic appearing cells in bronchial secretions This patient has not shown any clinical signs of cancer

FIG 2 A clump of cancer cells is shown in sputum

fibrous and calcified lesions in apices of both lungs which were thought to be due to ancient tuberculosis Two bronchoscopic examinations were negative but malignant cells were found in bronchial secretions from both the right and left bronchi on two occasions (Fig 1) Sputum was consistently negative for malignant cells Re-examination one and a half years later showed no change in the status and no development of symptoms suggesting bronchogenic carcinoma In this case the result must be considered false positive although the cells are very suggestive of malignant cells

It is very difficult to determine what the false-negative error is in such a series of cases The false negative error probably is between 30 and 35 per cent in our cases If this percentage is lowered much, the false positive error increases In spite of this high degree of false negativity for bronchogenic carcinoma, the procedure is exceedingly valuable

USES

Examination of sputum and bronchial secretions is most useful in several situations

1 It is useful in the diagnosis of bronchogenic carcinoma of an upper lobe of the lung because lesions in this location are very difficult and often impossible to visualize bronchoscopically Frequently a positive cytologic diagnosis gives the only definite evidence of carcinoma in this location before operation

2 It is useful, too, in the diagnosis of bronchogenic carcinoma which is peripherally situated in the lung These lesions, however, do not give a high incidence of positive cytologic findings It is necessary, of course, to have a bronchus communicating with the carcinoma in order to have cytologically positive sputum, and if no such communication is present, the sputum will not be positive

3 Examination of sputum in the presence of a metastatic lesion is definitely valuable in the diagnosis of malignant disease and it frequently may give the first positive evidence that a metastatic lesion exists

4 In cases of alveolar cell tumor cytologic examinations usually give positive findings The more anaplastic the cell type in this disease, the more readily the tumor cells are recognized in sputum and bronchial secretions Frequently the cells are found in clumps which have broken off

The main usefulness of cytologic examination of pulmonary secretions lies in the diagnosis of bronchogenic carcinoma The following case illustrates this

The patient, a sixty year old man had been a heavy cigarette smoker for many years but his cough had become worse in the last six weeks before admission There had been no hemoptysis Physical examination gave negative results A routine roentgenogram of the chest and results of other examinations were essentially negative Examination of sputum revealed malignant cells (Fig 2) On bronchoscopic examination no tumor was seen Bronchial washings from the right side showed carcinoma cells and those from the left side showed none A stereoscopic roentgenogram

revealed a rounded mass in the right lower part of the lung field which in a tomogram appeared to be 2 cm in diameter At exploration of the right side of the chest a small tumor was found in the middle lobe of the lung with extensive involvement of the hilar lymph nodes A lymph node was removed from the superior mediastinum which proved to be an undifferentiated large cell type of carcinoma The condition was regarded as inoperable and the thorax was closed The patient died eight days later

We have found that results of cytologic examination are most likely to be positive in cases of small cell or "oat" cell carcinoma of the lung and next most likely to be positive in cases of squamous cell carcinoma of the lung This is true because these carcinomas involve the larger bronchi and produce ulceration of the mucosa in most instances We have not found results of cytologic examination to be positive in cases of adenoma of the lung in which bronchial mucosa over the adenoma is intact This observation has been of help in distinguishing between adenoma of the bronchus and small cell undifferentiated carcinoma

SUMMARY

The cytologic examination of sputum and bronchial secretions and washings is a valuable procedure in the diagnosis of bronchogenic carcinoma It also may give evidence of metastatic carcinoma of the lungs and alveolar cell carcinoma

87

Bronchogenic Carcinoma

Foster Murray M D, *Brooklyn New York*

It is generally agreed among pathologists the world over that practically all primary cancers of the lung originate and spring from the basal cell layer of the bronchial mucosa, hence the designation bronchogenic carcinoma They may arise anywhere along the course of the bronchial tree from the major stem bronchus to the extreme peripheral or terminal bronchioles Even one of the rarer forms of bron

et al [2] Herbut[3] and Watson[4] to originate in the basal cell layer of the terminal bronchial mucosa Until recently this type of tumor had always been considered of multicentric origin but the studies of Storey[2] convince him of its unicentric origin He believes the usual wide

duced by canalicular extension

Bronchogenic carcinoma possesses characteristics common to all malignant tumors It is invasive obstructive and destructive It tends to ulcerate and to erode to undergo

and also protrudes into the lumen of the bronchus Both of these events profoundly alter the orderly functioning of these structures especially the relatively small portion intruding into the bronchial lumen It is the latter which interferes with the normal elastic expansion and contraction of the bronchial wall during the respiratory act It is the latter which also effects a gradual increasing atresia of the bronchus resulting in a damaging interference with the normal ventilatory properties of the lung and with the drainage of the bronchial airways distal to the growth Retention of infection follows such increasing obstruction with the consequent development of patchy areas of resolving or organizing lobular pneumonitis While the obstruction is only partial the resulting pneumonitis is more likely to be resolving in character and intermittent and repetitive in type If the protruding part is pedunculated in form a ball valve (check valve) mechanism may be set up for a limited period permitting the ingress of air to distal areas on inhalation but preventing its expulsion on exhalation with consequent establishment of emphysema in those areas When the obstruction becomes complete, the further admittance of air ceases the air previously trapped becomes absorbed and the emphysematous areas are converted into atelectatic ones This transition may occur with amazing rapidity Atelectasis is invariably followed by the development of organizing pneumonitis If the protruding part of the growth is more sessile in form and slower in growth organizing pneumonitis is more likely to result at times even before the obstruction is completed From these ever mutating pathophysiologic dynamics arise the marked variations observed in the

PATHOLOGY

The more anaplastic among these tumors are characterized histologically by an increase in chromatin content of nucleus marked evidence of mitosis loss of cellular polarity and more intensive and accelerated invasive properties Their behavior is conditioned by their basal cell type In general there are three basic cell types the squamous (epidermoid epithelioma) cell the small (oat transitional) cell and the [illegible] nald[5] feel which they [illegible] ing un differentiated types not conforming to the pattern of the first three Often it is difficult to label a given tumor for the several types

may be identified in different portions of the same mass in which case the dominant cell type usually determines its role While having some features in common the several types differ with each other in varying degree in malignancy in location in duration or tempo of evolution and in modes of metastasizing These are the factors that determine in so large a measure the prognosis and possible operability of a given case Accuracy in diagnosis of the type of the neoplasm is therefore most important for the decision to operate is weighted heavily in favor of the less anaplastic ones

The squamous cell type comprises about 42 per cent of all bronchogenic carcinoma It may arise from any portion of the bronchial tree but usually does arise from one of the larger branches of the stem bronchus It is somewhat slower in its evolution than the other types slower in narrowing the lumen of the bronchus and thus more likely to produce disturbed ventilatory function Particularly in this type retention of infection occurs with the development of areas of pneumonitis or emphysema or atelectasis The pneumonic areas may temporarily resolve or become an organizing process or undergo suppurative changes and terminate in abscess formation The prevailing microflora present largely determines this outcome especially the presence of anaerobes and spirochetes The growth itself may undergo necrosis and develop within it a suppurative antrum Death in this squamous cell type often enough results from these complications or sequelae This type of carcinoma tends to metastasize relatively late and does so more frequently by way of the lymph stream Superficial adenopathy appears more often in this type The Pancoast tumor or superior sulcus tumor occurring not too infrequently is of this squamous cell group It is always located in the extreme vault of the thorax and because of its confined quarters tends to bore directly through the bony cage which invests it In its growth it may exert pressure on the cervical sympathetic nerve giving rise to the typical Horner's syndrome It is also apt to invade the brachial plexus with the production of considerable pain about the shoulder and down the arm even at times extending to the fingertips Atrophy of the muscles of the forearm and hand often co-exists It is the squamous cell type of bronchogenic carcinoma which furnishes the vast majority of cases suitable for excisional surgery This is due in part to its relatively slower evolution and in part to its generally later period of metastasizing

The small cell type (including the undifferentiated cell type the so-called oat cell and the transitional cell tumors) comprises about 33 per cent of all lung cancers This is the most anaplastic of all such tumors the most rapid in growth and hence the most lethal from a prognostic viewpoint It is invariably located close to the hilum arising frequently from a major stem bronchus or from one of its immediate branches It is vigorously invasive rapidly involving the adjacent tracheobronchial and paratracheal lymph nodes either by direct extension or by way of the lymph channels This tumor with its tracheobronchial node involvement is very apt to produce a large mass in the mediastinum which exerts much pressure on neighboring structures such as the superior vena cava the phrenic nerve the esophagus or the inferior laryngeal nerve From such pressure arise symptoms so characteristic of this type (1) dilation of the superficial veins of the chest neck and face and at times edema of these areas (2) elevation and fixation of the diaphragm (3) dysphagia and regurgitation and (4) hoarseness or aphonia Rarely does this type undergo necrotic or suppurative degeneration or produce organizing pneumonic or atelectic changes distal to its location Death usually occurs before these complications have time to intervene This is the least resectable of all the types Death usually comes within three to six months of the presenting symptoms or sign Remote metastasis occur much less frequently than in other types

The adenocarcinoma type comprises about 25 per cent of these malignant tumors It is the one most frequently found in the female It may appear in any part of the lung but is more often peripherally located It is frequently identified with pleural irritation and effusion hemoptysis and remote metastases by lymph and blood stream Metastases to the brain and other structures may occur on symptoms in advance of those arising from the parent growth Because of the more frequent occurrence of metastasis this too is a type less often found suited for operation There is a growing belief among pathologists that the adenocarcinoma cell type is definitely of congenital origin

The sites of metastases of all types of bronchogenic carcinoma in the order of frequency

are regional lymph nodes (tracheobronchial, paratracheal, supraclavicular, cervical, anterior scalene and axillary), liver, lungs, bones, kidneys, adrenals, pleura and brain In an excellent summary Shefts and his associates[7] extol the value of scalene node biopsy as a diagnostic aid It is believed that the right anterior scalene nodes drain not only the three lobes of the right lung but also the greater part of the left lower lobe and are therefore apt to furnish revealing biopsy material

SYMPTOMS

In considering the presenting symptoms of this disease, it is important to note that in many cases there is a history of one or several attacks of acute upper respiratory infections often called "flu," "virus pneumonia" or "acute bronchitis" These bouts may be mild or severe, simple catarrhal or suppurative, depending upon the microflora prevailing at the time Usually fleeting in character, they were formerly considered to be prodromal episodes Actually they are manifestations of interrupted bronchial drainage and of retained infection culminating in the production of patchy areas of lobular pneumonitis In the majority of cases the onset is insidious, characterized by symptoms so protean and dissembling in nature as to simulate practically any respiratory affection closely Overholt has aptly termed cancer of the lung "the great masquerader of pulmonary diseases"

In the course of time definitive symptoms do arise and persist, and they are in order of frequency as follows

Cough and Expectoration These occur in about 70 per cent of all cases The cough at the beginning is often dry and spasmodic, the growth at this time acting as would a foreign body in the wall of the bronchus The resulting irritation stimulates the mechanism of expulsion, hence the spastic quality of the cough with little or no sputum Later, as secondary pneumonitis develops or the growth undergoes necrosis and suppuration, the cough becomes a productive one The sputum, scanty at first, may become profuse and may become purulent

Pain The majority of patients experience this symptom some time during the course of the disease When it does occur, it is usually early and constant and boring in quality, and may interfere with sleep at night If pleurisy co exists, the pain is sharp and stabbing in character and much accentuated by deep breathing

Dyspnea, occurring in slightly less than half of all cases, is occasioned by varying degrees of bronchial obstruction Areas of emphysema produced by the check-valve mechanism described by Jackson,[8] if sufficiently extensive, may cause dyspnea The sudden imposition of moderately extensive atelectasis will also give rise to dyspnea, as will massive accumulations of pleural fluid Rarely is dyspnea toxic in origin

Wheeze, often accompanying dyspnea, is brought about by varying degrees of bronchial obstruction Whenever this symptom, dyspnea or both develop for the *first* time in patients after forty-five years of age and *persist*, they should immediately alert one to the possible presence of a bronchial tumor, provided no known cardiovascular or allergic factors are present

Anorexia This is a fairly consistent finding at any time during the course of the disease

Loss of strength and weight is a strikingly variable occurrence, more often late in appearance

Fever may be present at any time, early or late, intermittent or continuous It is a product of ulceration, necrosis and secondary infection of the mass itself or of the concomitant pneumonitis

Hemoptysis, rarely massive, is invariably the result of ulceration and erosion and occurs more often in the adenocarcinomatous or more peripherally located tumors

Pressure symptoms may develop such as dilation of the veins of the chest, neck or face or even edema of these parts, dysphagia, hoarseness or aphonia, and x-ray evidence of marked elevation of a diaphragm These are all the result of encroachment of either the mass itself or its metastatic nodular products on immediately adjacent structures in the mediastinum namely, the superior vena cava, the esophagus, the inferior laryngeal nerve or the phrenic nerve Evidence of any one of these invasive manifestations is generally considered a contraindication to resectional surgery They are more likely to occur with the small cell type of neoplasm because of its invariable close proximity to these mediastinal structures

Anemia and cachexia are usually late complications

Pulmonary osteoarthropathy ("clubbed fingers") is occasionally observed in the course of the relatively slower growing masses as in some squamous cell types Here time permits low grade suppurative processes such as abscess formation and bronchiectasis to develop before other more lethal factors terminate the case hence it is seldom if ever seen in the small cell or adenocarcinoma types

PLEURAL EFFUSIONS

Statistical reports as to the frequency of occurrence of pleural effusions vary considerably, ranging from 15 to 45 per cent They are more apt to occur with the adenocarcinoma cell types and other peripherally located tumors and they reveal the presence of blood in about one third of the cases When aspirated the fluid reforms rapidly, affording only transient relief from the pain or dyspnea which usually

occasionally be demonstrated in the centrifuged sediment, either by cell block or by employing Papanicolaou technic[9] The absence of acid fast bacilli in the sediment, determined by repeated smear culture and guinea pig inoculations, serves as a differential factor

LABORATORY FINDINGS

There is nothing characteristic about the gross appearance of the sputum It may run

stained, especially if the Papanicolaou technic[9] is employed The finding of acid fast bacilli in the sputum does not, of course rule out the possible co-existence of a neoplasm, for a tuberculous lesion and bronchogenic carcinoma may occur concomitantly in the same lung or even in the same lobe

The sedimentation rate is generally increased, usually averaging between 20 and 30 mm in one hour (Cutler method)

PHYSICAL FINDINGS IN THE CHEST

The findings on physical examination of the chest are naturally conditioned by the stage of evolution of the growth, by its location and by the occurrence of sequelae consequent to the mechanical and biologic alterations which follow in its wake These latter may range from emphysema to atelectasis, from pneumonitis to abscess with correlative changes in the physical signs Invariably there is limitation of motion on the affected side Superficial adenopathy when present may be noted by inspection and palpation, especially in the cervical, supraclavicular or axillary regions Dilation of the superficial veins or edema may be observed in the region of the upper chest and neck The percussion note is uniformly dull to flat over the growth or over areas of concomitant pneumonitis or atelectasis The note may be tympanitic if emphysema is at all extensive Tactile fremitus is diminished or absent over the same areas On auscultation the most frequent finding is that of markedly diminished or absent breath sounds over the areas just described Rales may or may not be present and do not serve as a differential point

CAUSES OF DEATH

The causes of death in cancer of the lung are many and varied They are determined largely by the type and grade of malignancy of the tumor In the relatively slower growing tumors such as the squamous cell type secondary infection and metastases play a major role, with pneumonia, lung abscess and bron-

adenocarcinoma group, as do metastases to the brain liver, contralateral lung, kidneys and the long bones

PROGNOSIS AND TREATMENT

The prognosis is always grave, especially in the more anaplastic types, the small cell and adenocarcinoma types Rarely indeed is there

Where evidence of metastases exists or when bloody pleural effusion is present or where

clear-cut symptoms and signs of intramediastinal pressure occur the prognosis is more grim

At the present time excisional surgery offers the only possible chance of a lasting cure Success or failure is directly proportionate to the promptness with which diagnosis is established It must be stressed that the success of surgical attack is conditioned by the type and grade of malignancy of the growth its size and location and of course the age and general physical condition of the patient The operations employed are lobectomy or more often pneumonectomy The choice of operation is decided largely by the location of the growth its extent and in some measure by the philosophy of the surgeon The immediate operative mortality is encouragingly low (10 to 15 per cent) due chiefly to the amazing advancement in operating and anesthesia techniques the judicious use of blood plasma or whole blood and the generous utilization of antibiotics pre and postoperatively

REFERENCES

1 EWING J Neoplastic Diseases 4th ed p 8 8 Philadelphia 1940 W B Saunders Co
2 STOREY C F KNUDTSON K P and LAURENCE B J Bronchiolar (alveolar cell) carcinoma of the lung *J Thorac Surg* 26 331 406 1953
3 HERBUT P A Bronchiolar origin of alveolar cell tumor of the lung *Am J Path* 20 9 1–923 1944
4 [illegible]
5 M [illegible] *Dis of Chest* 25 6 1953
6 GRAHAM E A Primary cancer of the lung with special consideration of its etiology *Bull New York Acad Med* 27 261 276 1951
7 SIEFTS L M TERRILL A A and SEVINDELL H Scalene node biopsy *Am Rev Tuberc* 68 505 522 1953
8 JACKSON C The mechanism of physical signs in neoplastic and other diseases of the lung *J A M A* 9 630 1940
9 PAPANICOLAOU G N and CROMWELL H A Diagnosis of cancer of the lung by the cytologic method *Dis of Chest* 15 412 1949

88

Roentgen Manifestations of Carcinoma

Max Ritvo M.D. *Boston Massachusetts*

ROENTGEN MANIFESTATIONS

THE roentgen examination affords the most dependable and accurate method of establishing the diagnosis of carcinoma of the lung It must be stressed that the shadows produced on the roentgenogram indicate merely the gross pathologic condition The roentgen study enables the observer to determine the size den

and there may be great difficulty in arriving at a definite and conclusive diagnosis on the basis of the roentgen study alone The x ray affords the only means of visualizing the lesion and making an early diagnosis in tumors which are beyond the reach of the bronchoscope and outside the scope of other laboratory methods of examination Roentgen methods of study demonstrate bronchiogenic carcinoma in about 98 per cent of the cases and establish the diagnosis in over 80 per cent of these patients

The roentgen picture varies according to whether the tumor is located in (1) the hilum (2) the central or parenchymal portion of the lung and (3) the peripheral or subpleural region

SITE OF TUMORS

Hilar Tumor This type arises in the proximal portion of the bronchial tree usually in the region of the root of the lung Since the bronchus is quite wide at this point the early stages of the disease may produce little or no change on the roentgenogram As the tumor enlarges definite manifestations develop Lesions which grow outside the lumen of the bronchus produce a localized sharply defined area of increased density in the region of the root of the lung The margins of the mass tend to be lobulated Those which extend within or along the wall of the bronchus tend to have an irregular poorly defined margin The density in the roentgenogram is usually unilateral and sharply defined The tumor is apt to occlude the bronchus and cause atelectasis with collapse of the lung distal to the point of obstruction If the main bronchus is involved the entire lung collapses Occlusion of a segmental bronchus results in collapse limited to the segment of the lung supplied by the affected bronchus The degree of atelectasis and the size of the atelectatic area are not an index of the size of the tumor Atelectasis is manifested by increased density over the involved portion of the lung marked narrowing of the interspaces displacement of the heart and trachea to the affected side and elevation of the diaphragm frequently marked in degree The unaffected portion of the lung or the opposite lung in cases of complete collapse show emphysema The emphysema is present in the portion of the lung adjacent and immediately distal to the site of the neoplasm and may be due to compensatory changes or a valve like narrowing of the lumen of the bronchus which permits

density or is too small to produce a definite shadow in the roentgenogram may produce areas of localized emphysema and careful

of the lung and are usually completely surrounded by lung tissue The growth may extend along the bronchial wall outside of the lumen of the bronchus or grow into the bronchial lumen The lesion is manifested by a rounded or ovoid area of increased density The margins of the growth are smooth and sharply defined in some cases in others there is irregular extension into the adjacent lung tissue These tumors frequently remain asymptomatic for considerable periods of time and

FIG 1 Bronchiogen c carcinoma There is a sharply defined area of increased density in the left parahilar region There is emphysema man fested by increased rad ance in the lung adjacent to the neoplasm

FIG 2 Bronchiogenic carcinoma Advanced carcinoma involving the upper half of the right lung The upper right interspaces are narrowed and the trachea is deviated to the right indicative of atelectas s The small irregular area of increased dens ty in the left mid lung field adjacent to the left hilum represents a metastatic nodule

may become quite large before producing symptoms These are the type which are dis covered on routine chest roentgenograms or during mass surveys, the patient being unaware of the existence of anything of an abnormal nature in the chest Abscess formations fre quently develop The lesion differs from the usual inflammatory abscess of the lung in that it has a denser and thicker wall and its margins are more irregular A fluid level in many in stances is present within the abscess The parenchymal type of carcinoma may also occur as a diffuse nodular reticulation throughout the lung fields closely simulating the meta static lymphangitic type which spreads through the lymphatics and is very highly malignant The roentgen picture closely simulates pneu monitis bronchitis and bronchiectasis and errors in diagnosis are very common

Tumors Arising in Peripheral Portions of Lung Primary carcinomas of the lung orig inating in the extreme peripheral portion of the lung have their point of origin in the smaller bronchioles adjacent to the visceral lung The tumor may be sharply demarcated with clearly defined margins or present hazy irregular borders which extend in infiltrative fashion into the adjacent lung tissue The growth may originate in any portion of the lung and those situated in the region adjacent to the interlobar septa or the mediastinal surfaces of the lung often appear to be hilar or central in origin By use of oblique and lateral roentgenograms and roentgenoscopy the peripheral location of the mass can usually be

the lung is particularly apt to produce localized destruction of the ribs and is associated with the presence of Horner's syndrome in many instances There is a homogeneous density in volving the apex and the upper third of the lung field with destruction of a portion of one or more ribs In contrast to the other types of bronchiogenic carcinoma the apical lesions frequently produce very striking and severe

clinical manifestations which are in marked contrast to the relatively small size of the neoplasm Because of involvement of the pleura pleural effusion frequently develops The fluid is apt to be bloody (Fig 3)

The size of the tumor in primary carcinoma of the lung may vary from miliary to extremely large The mass may be rounded irregular or wedge-shaped With the passage of time the tumors enlarge both centrally and peripherally In some instances there is a narrow band of density extending from the mass in the lung to the hilum The hilus nodes are usually not involved until late in the parenchymal types of primary carcinoma the same is true of the peripheral type The neoplasm may in some cases be manifested as a nodular dissemination or a diffuse reticulation in the lung rather than as a localized mass Abscess formation is usually due to perforation of the bronchial walls with subsequent necrosis Lobar consolidation may precede or accompany the abscess formation Atelectasis and fluid are frequent occurrences in tumors of the lungs and in many cases obscure both the primary growth and areas of destruction in the bony thorax Marked thickening of the pleura is also common and may simulate pleural effusion clinically and roentgenographically The displacement of the mediastinal structures and the changes in the bony thorax which occur in fluid or atelectasis may be modified or absent in the presence of marked infiltrations or thickening of the pleura Bronchiectasis is frequently concomitant with primary carcinoma of the lung Pneumonitis unresolved pneumonia and chronic tuberculosis may occur and may mask or obscure the clinical and roentgen picture for long periods of time Elevation of the diaphragm with paradoxic excursion is indicative of paralysis of the phrenic nerve by invasion of the neoplasm Metastases may occur to the same or opposite lung hence the fact that there are multiple tumors in the lungs does not exclude the possibility of bronchiogenic carcinoma

Bronchography is of great value in the diagnosis of bronchial occlusions abscess formations and bronchiectatic changes Body section roentgenography and overexposed films with the Bucky diaphragm are of aid in the demonstration of narrowing or obliteration of the bronchus cavitations and changes in the ribs scapulae clavicles or vertebrae as well as le-

the upper interspaces being narrowed and the heart and trachea being deviated to the right

sions which may be obscured by the overlying heart or mediastinal shadows Therapeutic pneumothorax particularly after withdrawal of pleural fluid may outline masses which are obscured and also show other important changes otherwise not demonstrable Laminagraphic studies are especially indicated to show changes in the bronchus and to demonstrate masses or cavitations which otherwise would be overlooked or obscured Serial roentgenograms at intervals of a few days or weeks to demonstrate the progression constitute a most important aid in diagnosis However it is not advisable to wait more than two or at most three weeks between the examinations as longer intervals may permit marked extension of the tumor and the development of metastases (Fig 4)

DIFFERENTIAL DIAGNOSIS

The differential diagnosis must include a host of lesions Tuberculosis bronchiectasis pneumonia lymphoma, metastatic neoplasm postradiation fibrosis and many other conditions must be considered Lipoid pneumonia the virus types of pneumonia and the nonspecific granulomas may produce changes which closely simulate primary carcinoma of the lung Lung abscess associated with homo-

4A 4B

lateral displacement of the heart and mediastinal contents or localized emphysema distal to the abscess should always raise the question of bronchiogenic carcinoma Syphilis and tuberculosis may closely simulate carcinoma of the lung The tuberculoma, which produces a solitary mass in the lung quite similar in appearance to carcinoma of the lung is usually considered a benign lesion However, all tuberculomas are potentially dangerous because *of the great probability of subsequent breakdown with the dissemination of tubercle* bacilli This results in rapid and widespread dissemination of the disease The principal benign tumors which may cause confusion in diagnosis are the lipomas, neurofibromas, chondromas, adenomas, hamartomas and cysts These lesions do not show rapid progression on subsequent roentgen studies The laboratory examinations are also negative Several vascular types of lesions are occasionally confused with carcinoma An infarct may produce an area of density in the lung which simulates carcinoma The history is usually important and establishes the differential diagnosis Studies after an interval of one or two weeks show resolution and diminution in the size of the infarct A broncholith due to a foreign body may produce bronchostenosis with atelectasis Substernal thyroid may be differentiated by the displacement and narrowing of the trachea which usually occurs in this condition Metastatic lesions may in rare instances be solitary and sharply defined and produce pictures which very closely simulate primary carcinoma of the lung The determination of *the primary site of the growth is usually the important factor in establishing the diagnosis.* Other diseases, particularly tuberculosis and [illegible] of tumor

The possibility of carcinoma of the lung must be borne in mind in every obscure pulmonary lesion Only by constant care and alertness will early diagnosis be possible Routine periodic roentgen study of the chest, preferably at intervals of six months to a year, and prompt attention to pulmonary symptoms are of the utmost significance in reducing the mortality from this malady

Detection, Selection and Resection in Pulmonary Carcinoma

RICHARD H OVERHOLT, M D AND JAMES A BOLGAS, M D *Boston, Massachusetts*

From the Overholt Thoracic Clinic Boston Massachusetts

I)

is within bounds and often before tissue diagnosis has been made Resection has cured approximately one half of the patients whose carcinoma was localized to the lung at the time of exploration Cure may be possible in even a greater proportion of asymptomatic patients whose roentgen survey lesion is resected within a few weeks of detection Responsibility for early apprehension of both silent and asymptomatic neoplasms must be shared by physician and surgeon alike Success depends upon the prompt appraisal of cancer potential in an abnormal shadow regardless of the circumstances which lead to its discovery

Evaluation of the patient requires one or more of five steps (1) Adequate radiology in order to check the presence of the discovery shadow and establish the existence of a cancer potential, and for localization (2) search for irreversible poor general physical state or incurable associated disease (3) search for distant metastases (4) bronchoscopic assurance that trachea and bronchus to the uninvolved side are sound (5) exploratory thoracotomy

In twenty years more than 1 100 patients with primary pulmonary carcinoma referred to the Overholt Thoracic Clinic have had their diagnosis verified histologically An analysis of various groups from this experience will serve as a basis for comment Patients are seeking advice sooner now than a few years ago Chest films are obtained with less delay More abnormal shadows are being discovered in asymptomatic individuals Efforts at palliation are beginning to yield benefits Five-year cures are constantly being added to the list of survivors

ROENTGENOLOGY

The x ray is the most valuable and dependable instrument with which to demonstrate abnormal densities situated within lung tissue It is the only practical way to screen for silent cancer Fortunately the mechanics of screening the lung are far simpler than of screening any other region including skin breast, buccal cavity or female genital tract All negative cases can be eliminated without the doctor's even seeing the patient Technicians can collect the evidence, and only the small percentage of patients showing abnormal findings require a time consuming examination

Many cancer suspects are being found in mass surveys for tuberculosis However most of these surveys are single-purpose programs To give adequate protection the screening should be an annual affair in all persons past forty years of age The interval should be shortened to four months in the most susceptible group—men of cancer age who smoke

Such a screening program can be implemented by individual patient-doctor arrangement All existing facilities for taking standard or miniature films should be made available for screening purposes Single films, taken and developed by technicians on a mass production basis can keep the cost as low as that of a urinalysis or blood count Every doctor should make it his responsibility to see that his patients have this protection

An abnormal shadow detected, however, is not a lesion diagnosed X-ray, unassisted, cannot make the diagnosis The protean x ray manifestations of pulmonary carcinoma are determined by several factors such as (1) location (2) extent (3) degree of bronchial occlusion, (4) associated infection and (5) vascular or lymphatic involvement

The shadows of cancer simulate those of

many other conditions The most common are tuberculosis, pneumonia and pneumonitis of all types, lung abscess and bronchiectasis

Complete x-ray study must establish that *the abnormal intrathoracic x-ray shadow* is bona fide and not a phantom shadow or misinterpretation of a normal anatomic variation Usually posterior-anterior and oblique or lateral exposures combined with fluoroscopy are sufficient for this purpose Occasionally, stereoscopic exposure, tomography, Bucky grid or over-exposed films give assistance *Very rarely, if ever, is there need to detail* x-ray diagnosis with bronchogram, pneumothorax or pneumoperitoneum

X-ray shadows containing calcium in old, healed lesions are common findings Calcium distributed evenly throughout an abnormal shadow weighs heavily against malignancy If a calcific deposit has a second component or satellite shadows which are entirely free of calcium, malignancy cannot be ruled out with certainty

The exact malignant potential of lesions producing abnormal shadows cannot be determined Hood et al [1] stated that bronchogenic carcinoma was found in 16 per cent of 156 resected solitary circumscribed x-ray lesions of the lung Grow, Bradford and Mahon[2] found malignant 19 per cent of eighty-six circumscribed lesions undiagnosed prior to exploration Abeles and Ehrlich[3] found one-third of twenty-one lesions explored to be malignant Harrington[4] explored fifty-two patients with asymptomatic intrathoracic lesions and found 31 per cent malignant O'Brien, Tuttle, and Ferkaney[5] reported a series of pulmonary "coin" lesions containing 43 per cent malignancies Sharp and Kinsella[6] reported 22 per cent malignancy in their experience with the "isolated pulmonary nodule" Fink[7] found 33 per cent malignant At the Overholt Thoracic Clinic 18 per cent of 268 abnormal intrathoracic x-ray shadows discovered on chest roentgenographic screening were found to be malignant lesions at exploration Although these series are not comparable, an absolute figure for the cancer potential of unexplained densities in the lung is not necessary It is important to remember that some [illegible] and that more than 1 per cent, it is safer to explore than to wait and see, since the risk of exploration is less than 1 per cent

ADJUNCTS TO DIAGNOSIS

Cytologic examination of sputum or bronchial secretions by experienced personnel is a valuable adjunct to the diagnosis of pulmonary carcinoma, provided negative reports are not permitted to delay exploration At the New England Deaconess Hospital negative cytology has been reported preoperatively in nearly one-fourth of all histologically verified pulmonary cancers Furthermore, benign lesions have yielded 2 per cent positive reports, and an additional [illegible] per cent have been reported suspicious of malignancy

Aspiration biopsy through the chest wall is rarely used and is unwise and unnecessary in most instances It has value when a peripheral tumor exists and when (1) peripheral metastases are not accessible for biopsy, (2) tumor cells cannot be demonstrated in sputum or in secretions obtained by bronchial aspiration (3) the tumor is inaccessible or too vascular for bronchoscopic biopsy, (4) the general condition is too precarious to permit exploration It must be remembered that the specimen obtained through a needle is not always adequate for complete histologic diagnosis and there is always the real risk of tumor implantation along the track of the puncture

GENERAL ASSESSMENT

The primary purpose of the history and physical examination should be a painstaking evaluation of the general physical state and a meticulous search for distant metastases Over 90 per cent of all our symptomatic cases reported either cough, chest discomfort hemoptysis, arthritis, weight loss, fatigue change in character of breathing, or combinations of these disturbances Such symptoms may be present with either localized or advanced disease and do not furnish a reliable guide as to curability Abnormal physical findings such as fever, marginal pulmonary reserve, consolidation, emphysema, or even fluid free of tumor cells do not necessarily spell out hopelessness

Irreversible precarious general health prompted rejection of thoracotomy for only twenty-eight cases (3 per cent) of 884 studied by us between 1941 and 1953 Surgery was refused for persistent decompensated cardiac

[illegible]

[illegible]ated incurable proved lymphosarcoma, suggestive evidence for distant metastases—recent psychosis and jaundice

Proved distant metastases contraindicated thoracotomy in 226 (26 per cent) of the 884 cases Supraclavicular lymph node biopsy was always performed if there was a suggestion of lymph node enlargement in that area Accessible metastatic lesions were histologically verified Exceptions were made when there were multiple neurologic or bone lesions or gross superior mediastinal venous obstruction Solitary bone lesions may represent benign disease and should be biopsied The more common sites of distant metastases were supraclavicular lymph nodes, brain, liver, axial and peripheral skeleton, and axillary lymph nodes Pleural fluid is not an absolute contraindication to surgery unless it contains tumor cells Vocal cord paralysis on the side of tumor is a grave sign and usually contraindicates exploration, especially if associated with pleural fluid widened mediastinal x-ray shadow or superior mediastinal obstruction

Since paralysis of the diaphragm can occur as the result of inflammatory disease of the lung or without any discernible intrathoracic pathologic disorder, it does not preclude resectability On occasion, patients with extensive disease and only presumptive evidence of distant spread have had a lobe or a lung removed with worth while palliation This has been especially helpful in patients with violent coughing spells, chest discomfort, arthritic pain or other manifestations of toxicity

BRONCHOSCOPY

Bronchoscopy has its greatest value in determining technical resectability, not in obtaining biopsy When careful physical examination and investigation of suspicious peripheral lesions have failed to contraindicate exploration, bronchoscopy becomes the next logical step in the patient's preoperative evaluation It is the most precise gauge of the tumor's extent within the major air passages Contralateral bronchial or tracheal involvement are findings which make resection either impossible or hazardous

Fixation of the mediastinum suggests neoplastic invasion of the mediastinal lymphatic system and is the prognostic analogue of "frozen pelvis" in carcinoma of the cervix uteri Mobility of the tracheobronchial tree can be determined with gentle pressure transmitted through the tip of the bronchoscope

TABLE I
HISTOLOGIC VERIFICATION (CONSECUTIVE CASES OF PRIMARY CARCINOMA OF LUNG)

Method	1932–1940 99 Cases (%)	January 1947–September 1953 462 Cases (%)
Bronchoscopy biopsy	66	22
Exploration and biopsy	18	37
Biopsy metastasis	7	11
Necropsy	5	2
Pleural fluid cytology	3	2
Sputum cytology without exploration	0	6

Hard fixation usually means carcinomatous invasion of the paratracheal lymph nodes, but, as in the pelvis, inflammation can produce immobility To deny exploration because of this finding alone is unfair to the patient

Enlargement of mediastinal nodes may indent the trachea or major bronchi and cause rounding of the normally sharp carinal spur These findings most often are associated with lymphatic spread but quite often represent only non specific inflammation Although direct invasion of most types of tumor into trachea or contralateral bronchus is an absolute contraindication to successful resection, mediastinal fixation and enlargement of the hilar and mediastinal lymph nodes is but a presumptive contraindication

Unnecessary diagnostic bronchoscopy, with its delay of weeks or months, may rob the patient of an opportunity for cure In addition to [illegible]

[illegible]

tuberculosis investigation with time-consuming laboratory studies such as guinea pig inoculation or cultures

With emphasis on a more direct and positive

many other conditions. The most common are tuberculosis, pneumonia and pneumonitis of all types, lung abscess and bronchiectasis.

Complete x-ray study must establish that the abnormal intrathoracic x-ray shadow is *bona fide* and not a phantom shadow or misinterpretation of a normal anatomic variation. Usual posterior anterior and oblique or lateral exposures need with fluoroscopy [illegible] Occasionally [illegible] tomography, Bucky [illegible] give assistance. Very [illegible] need to detail [illegible] pneumothorax [illegible]

[illegible] calcium in old [illegible] Calcium distribution [illegible] an abnormal shadow [illegible] malignancy. If a calcific deposit [illegible] and component or satellite shadow [illegible] *are entirely* free of calcium malignancy [illegible] be ruled out with certainty.

The exact *malignant* potential of lesions producing abnormal *shadows* cannot be determined. Hood et al. stated that bronchogenic carcinoma was found in 16 per cent of 156 resected solitary circumscribed x-ray lesions of the lung. Grow, Bradford and Mahon[2] found malignant 19 per cent of eighty six circumscribed lesions *undiagnosed* prior to exploration. Abeles and Ehrlich[3] *found* one-third of twenty-one lesions explored to be malignant. Harrington[4] explored fifty two patients with asymptomatic *intrathoracic* lesions and found 31 per cent malignant. O'Brien, Tuttle, and Ferkaney[5] reported a *series* of pulmonary coin lesions containing 43 per cent malignancies. Sharp *and* Kinsella[6] reported 22 per cent malignancy *in their* experience with the isolated pulmonary *nodule*. Fink found 33 per cent malignant. At the Overholt Thoracic Clinic 18 per cent of 268 abnormal intrathoracic x-ray *shadows* discovered on chest roentgenographic screening were found to be malignant lesions at exploration. Although these series are not comparable, an absolute figure for the cancer potential of unexplained densities *in the lung* is not necessary. It is important to remember that some change in density caused the shadow, and that a significant number are cancerous densities. If the cancer potential is *ever* considered to be more than 1 per cent, it is safer to explore than to wait and see, since the risk of exploration is less than 1 per cent.

ADJUNCTS TO DIAGNOSIS

Cytologic examination of sputum or bronchial secretions by experienced persons is a valuable adjunct to the diagnosis of pulmonary carcinoma, provided negative reports are not permitted to delay exploration. A New England Deaconess Hospital report[illegible] has been reported preoperative [illegible] one-fourth of all histologically [illegible] monary cancers. Furthermore [illegible] have yielded 2 per cent positive results, an additional 8 per cent have been [illegible] suspicious of malignancy.

Aspiration biopsy through the chest wall is rarely used and is unwise and unnecessary in most instances. It has value when a peripheral tumor exists and when (1) peripheral metastases are not accessible for biopsy, (2) [illegible] cells cannot be demonstrated in sputum or secretions obtained by bronchial aspiration, (3) the tumor is inaccessible or too risky for bronchoscopic biopsy, (4) the general condition is too precarious to permit exploration. [illegible] remembered that the [illegible] tion along the track of the puncture [illegible]

GENERAL ASSESSMENT

The primary purpose of the history and physical examination should be a preliminary evaluation of the general physical status and a meticulous search for distant metastases. Over 90 per cent of all our symptomatic cases reported either cough, chest discomfort, hemoptysis, arthritis, weight loss, fatigue, change in character of breathing or combinations of these disturbances. Such symptoms may be present with either localized or advanced disease and do not furnish a reliable guide to curability. Abnormal physical findings such as fever, marginal pulmonary reserve, consolidation, emphysema or even [illegible] of tumor cells do not necessarily [illegible] hopelessness.

Irreversible precarious general health prompted rejection of thoracotomy for [illegible] twenty-eight cases (3 per cent) of [illegible] by us between 1941 and 1953. Surgery was refused for persistent decompensated cardiac [illegible]

lar disease—especially aortic, persistently
npensated myocardium, terminal cachexia,
■ widespread pulmonary tuberculosis,
re pulmonary fibrosis and emphysema, asso-
ed incurable proved lymphosarcoma, sug-
ive evidence for distant metastases—recent
chosis and jaundice

Proved distant metastases contraindicated
oracotomy in 226 (26 per cent) of the
4 cases Supraclavicular lymph node biopsy
as always performed if there was a sugges-
on of lymph node enlargement in that area
ccessible metastatic lesions were histologically
erified Exceptions were made when there were
multiple neurologic or bone lesions or gross
uperior mediastinal venous obstruction Soli-
ary bone lesions may represent benign disease
l should be biopsied The more common
s of distant metastases were supraclavicular
mph nodes, brain, liver, axial and peripheral
eleton and axillary lymph nodes Pleural
id is not an absolute contraindication to
urgery unless it contains tumor cells Vocal
ord paralysis on the side of tumor is a grave
ign and usually contraindicates exploration
especially if associated with pleural fluid
widened mediastinal x ray shadow or superior
mediastinal obstruction

Since paralysis of the diaphragm can occur
as the result of inflammatory disease of the
lung or without any discernible intrathoracic
■ pathologic disorder, it does not preclude re
ectability On occasion, patients with exten
ive disease and only presumptive evidence ■f
distant spread have had a lobe or a lung re-
moved with worth while palliation This has
been especially helpful in patients with violent
coughing spells chest discomfort arthritic
pain or other manifestations of toxicity

BRONCHOSCOPY

Bronchoscopy has its greatest value in
determining technical resectability, not in
obtaining biopsy When careful physical ex
amination and investigation of suspicious
peripheral lesions have failed to contraindicate
exploration, bronchoscopy becomes the next
logical step in the patient's preoperative
evaluation It is the most precise gauge of the
tumor s extent within the major air passages
Contralateral bronchial or tracheal involve
ment are findings which make resection either
impossible or hazardous

Fixation of the mediastinum suggests neo-
plastic invasion of the mediastinal lymphatic
system and is the prognostic analogue of
"frozen pelvis" in carcinoma of the cervix
uteri Mobility of the tracheobronchial tree
can be determined with gentle pressure trans-
mitted through the tip of the bronchoscope

TABLE I
HISTOLOGIC VERIFICATION (CONSECUTIVE CASES OF PRIMARY CARCINOMA OF LUNG)

Method	1932 1940 99 Cases (%)	January 1949–September 1953 462 Cases (%)
Bronchoscopy biopsy	66	22
Exploration and biopsy	18	57
Biopsy metastasis	7	11
Necropsy	5	2
Pleural fluid cytology	3	2
Sputum cytology without exploration	0	6

Hard fixation usually means carcinomatous
invasion of the paratracheal lymph nodes, but,
as in the pelvis, inflammation can produce
immobility To deny exploration because ■f
this finding alone is unfair to the patient

Enlargement of mediastinal nodes may in
dent the trachea or major bronchi and cause
rounding of the normally sharp carinal spur
These findings most often are associated with
lymphatic spread but quite often represent
only non-specific inflammation Although direct
invasion of most types of tumor into trachea or
contralateral bronchus is an absolute contra-
indication to successful resection, mediastinal
fixation and enlargement of the hilar and
mediastinal lymph nodes is but a presumptive
contraindication

Unnecessary diagnostic bronchoscopy, with
its delay ■f weeks or months, may rob the
patient of an opportunity for cure In addition to
avoidance of bronchoscopic delay, there should
also be an elimination of extended serial x ray
studies, protracted ■ntibacterial therapy and
tuberculosis investigation with time-consuming
laboratory studies such as guinea pig inocula-
tion or cultures

With emphasis on a more direct and positive

ıany other conditions The most common are ıberculosis, pneumonia and pneumonitis of all ypes, lung abscess and bronchiectasis

Complete x-ray study must establish that ıe abnormal intrathoracic x-ray shadow is *ona fide and not* a phantom shadow or mis ıterpretation of a normal anatomic variation 'sually posterior-anterior and oblique or teral exposures combined with fluoroscopy 'e *sufficient for this* purpose *Occasionally*, ereoscopic exposure, tomography, Bucky 'id or over exposed films give assistance ery rarely, if ever, is there need to detail *ray diagnosis with bronchogram*, pneumo- ıorax or pneumoperitoneum

X-ray shadows containing calcium in old, ıafed' lesions are common findings Calcium stributed evenly throughout an abnormal adow weighs heavily against malignancy If calcific deposit has a second component or tellite shadows which are entirely free of lcium, malignancy cannot be ruled out with rtainty

The exact malignant potential of lesions pro- ıcing *abnormal shadows cannot be deter-* ıned Hood et al [1] stated that bronchogenic rcinoma was found in 16 per cent of 156 re- ıted solitary circumscribed x-ray lesions of e lung Grow, Bradford and Mahon[2] found alignant 19 per cent of eighty-six circum- ıibed lesions undiagnosed prior to explora- ın Abeles and Ehrlich[3] found one-third of enty-one lesions explored to be malignant ırrington[4] explored fifty-two patients with ımptomatic intrathoracic lesions and found per cent malignant O Brien, Tuttle, and rkaney[5] reported a series of pulmonary oin" lesions containing 43 per cent malig ncies *Sharp and Kinsella*[6] *reported 22 per* cent malignancy in their experience with the "isolated pulmonary nodule" Fink[7] found 33 per cent malignant At the Overholt Thoracic Clinic 18 per cent of 268 abnormal intrathoracic x-ray shadows discovered on chest roentgenographic screening were found to be malignant lesions at exploration Although these series are not comparable, an absolute figure for the cancer potential of unexplained densities in the lung is not necessary It is important to remember that some change in density caused the shadow, and that a significant number are cancerous densities If the *cancer* potential is ever considered to be more than 1 per cent, it is safer to explore than to wait and see, since the risk of exploration is less than 1 per cent

ADJUNCTS TO DIAGNOSIS

Cytologic examination of sputum or bron chial secretions by experienced personnel is a valuable adjunct to the diagnosis of pulmonary carcinoma, provided negative reports are not permitted to delay exploration At the New England Deaconess Hospital negative cytology has been reported *preoperatively in nearly* one-fourth of all histologically verified pul monary cancers Furthermore, benign lesions *have yielded* 2 per cent positive reports, and an additional 8 per cent have been reported suspicious of malignancy

Aspiration biopsy through the chest wall is rarely used and is unwise and unnecessary in most instances It has value when a peripheral tumor exists and when (1) peripheral metas tases are not accessible for biopsy, (2) tumor cells cannot be demonstrated in sputum or in secretions obtained by bronchial aspiration, (3) the tumor is inaccessible or too vascular *for bronchoscopic biopsy, (4) the general* con dition is too precarious to permit exploration It must be remembered that the specimen obtained through a needle is not *always ade-* quate for complete histologic diagnosis and there is always the real risk of tumor implanta tion along the track of the puncture

GENERAL ASSESSMENT

The primary purpose of the history and physical examination should be a painstaking evaluation of the general physical state and a meticulous search for distant metastases Over 90 per cent of all our symptomatic cases *reported either cough, chest discomfort, he-* moptysis, arthritis, weight loss, fatigue, change in character of breathing, or combinations of *these disturbances Such symptoms* may be present with either localized or advanced disease and do not furnish a reliable guide as to curability *Abnormal physical findings* such as fever, marginal pulmonary reserve, con solidation, emphysema, or even fluid free of tumor cells do not necessarily *spell* out hopelessness

Irreversible precarious general health prompted rejection of thoracotomy *for only* twenty-eight cases (3 per cent) of 884 studied by us between 1941 and 1953 Surgery was refused for persistent decompensated *cardiac*

valvular disease—especially aortic, persistently decompensated myocardium, terminal cachexia, active widespread pulmonary tuberculosis, severe pulmonary fibrosis and emphysema, associated incurable proved lymphosarcoma, suggestive evidence for distant metastases—recent psychosis and jaundice

Proved distant metastases contraindicated thoracotomy in 226 (26 per cent) of the 884 cases Supraclavicular lymph node biopsy was always performed if there was a suggestion of lymph node enlargement in that area Accessible metastatic lesions were histologically verified Exceptions were made when there were multiple neurologic or bone lesions or gross superior mediastinal venous obstruction Solitary bone lesions may represent benign disease and should be biopsied The more common sites of distant metastases were supraclavicular lymph nodes, brain, liver, axial and peripheral skeleton, and axillary lymph nodes Pleural fluid is not an absolute contraindication to surgery unless it contains tumor cells Vocal cord paralysis on the side of tumor is a grave sign and usually contraindicates exploration, especially if associated with pleural fluid, widened mediastinal x-ray shadow or superior mediastinal obstruction

Since paralysis of the diaphragm can occur as the result of inflammatory disease of the lung or without any discernible intrathoracic pathologic disorder, it does not preclude resectability. On occasion, patients with extensive disease and only presumptive evidence of distant spread have had a lobe or a lung removed with worth while palliation This has been especially helpful in patients with violent coughing spells, chest discomfort arthritic pain or other manifestations of toxicity

BRONCHOSCOPY

Bronchoscopy has its greatest value in determining technical resectability, not in obtaining biopsy When careful physical examination and investigation of suspicious peripheral lesions have failed to contraindicate exploration, bronchoscopy becomes the next logical step in the patient's preoperative evaluation It is the most precise gauge of the tumor's extent within the major air passages Contralateral bronchial or tracheal involvement are findings which make resection either impossible or hazardous

Fixation of the mediastinum suggests neoplastic invasion of the mediastinal lymphatic system and is the prognostic analogue of "frozen pelvis" in carcinoma of the cervix uteri Mobility of the tracheobronchial tree can be determined with gentle pressure transmitted through the tip of the bronchoscope

TABLE I
HISTOLOGIC VERIFICATION (CONSECUTIVE CASES OF PRIMARY CARCINOMA OF LUNG)

Method	1932–1940 99 Cases (%)	January, 1949–September, 1953 462 Cases (%)
Bronchoscopy biopsy	66	22
Exploration and biopsy	18	57
Biopsy metastasis	7	11
Necropsy	5	2
Pleural fluid cytology	3	2
Sputum cytology without exploration	0	6

Hard fixation usually means carcinomatous invasion of the paratracheal lymph nodes, but, as in the pelvis, inflammation can produce immobility To deny exploration because of this finding alone is unfair to the patient

Enlargement of mediastinal nodes may indent the trachea or major bronchi and cause rounding of the normally sharp carinal spur These findings most often are associated with lymphatic spread but quite often represent only non-specific inflammation Although direct invasion of most types of tumor into trachea or contralateral bronchus is an absolute contraindication to successful resection, mediastinal fixation and enlargement of the hilar and mediastinal lymph nodes is but a presumptive contraindication

Unnecessary diagnostic bronchoscopy, with its delay of weeks or months, may rob the patient of an opportunity for cure In addition to avoidance of bronchoscopic delay, there should also be an elimination of extended serial x-ray studies, protracted antibacterial therapy and tuberculosis investigation with time-consuming laboratory studies such as guinea pig inoculation or cultures

With emphasis on a more direct and positive

FIG. 1. Mrs. S. R., age fifty-four. The decision to explore was made on the basis of x-ray evidence. The patient was asymptomatic. The discovery film five months previously revealed an abnormal density of similar size and character. In this instance, as suspected, bronchoscopy was negative. The insert depicts the space relationship between the lesion and the range of bronchoscope vision. Within the circle the fine straight line represents a normally sharp carina. In order to save discomfort, time and expense, bronchoscopy was performed in the two minutes preceding the insertion of an intratracheal tube for anesthesia. Right pneumonectomy for circumscribed, poorly differentiated adenocarcinoma was performed on December 20, 1949. The convalescence was uneventful. Total hospital stay was twenty days. She is well now, four and a half years later.

diagnostic and treatment program our clinic has seen a fall in its bronchoscopy histologic verification from 66 per cent prior to 1941 to 22 per cent since 1949 (Table 1). A concomitant rise in verification at exploratory thoracotomy from 18 per cent to 57 per cent mirrors the philosophy that suspicious roentgen shadows must be explored before prolonged and expensive diagnostic or quasidiagnostic procedures have spent the patient's last hope for cure.

In a group of 462 cases of verified primary pulmonary carcinoma, 348 bronchoscopies were performed and 104 bronchoscopies with pathologic diagnosis were achieved. Thus although 76 per cent of all patients were bronchoscoped and 30 per cent of the bronchoscopies gave a biopsy positive for malignancy, only 22 per cent of all the patients had their diagnosis verified preoperatively by this means. Since 74 per cent of the lesions in this group of patients were centrally placed near the hilum, the statistics suggest a failure of bronchoscopy to discover cancer accessible in the proximal bronchi. Clarification of these statistics rests chiefly with three facts:

1. Many of the lesions centrally placed had obvious distant metastases and histologic

FIG 2 Mr A C age forty seven The decision to explore was made on the basis of the x ray evidence The only significant symptom was hemoptysis of ten days duration Discovery film (survey) two months previously when patient was asymptomatic revealed a slightly smaller shadow Lateral projection (see insert right) placed the lesion in the superior segment of the lower lobe It was posterior and out of bronchoscopic range Since resection was indicated the exploration was planned to follow the bronchoscopy immediately The essential bronchoscopic findings are indicated in the insert (left) The appearance of the blunted and widened carina is shown in the circle Slightly above the carina and in the membranous portion of the trachea there was a bulge suggestive of an enlarged mediastinal node As suspected all bronchial airways within bronchoscopic view were open Upon exploration February 3 1949 grade III epidermoid carcinoma was found Twenty four lymph nodes some tremendously enlarged, were removed All were negative for tumor Right pneumonectomy was followed by a satisfactory convalescence The total hospital stay was ten days Now five and a half years later the patient is living well and working as a plumber

verification came from those sources rather than from bronchoscopy

2 A recent practice at the clinic has been to omit biopsy in those patients who are to undergo immediate thoracotomy and have uninvolved trachea carina and contralateral bronchus It is not always wise to remove a specimen via the bronchoscope when a lesion is visible Serious intrabronchial hemorrhage is not a rare occurrence Its risk should be weighed against the theoretic advantage of preoperative histologic verification

3 Some carcinomas can be seen in the upper lobe bronchi with right angle telescopic lenses but are not within reach of the biopsy forceps

The best interests of the operable patient are served when there is the least possible delay between bronchoscopy and thoracotomy X ray evidence alone forces the issue of exploration in all early cases Unless the odds

FIG 3 Mr J G age seventy The decision to explore was based upon the x ray evidence A chronic cough was present for eighteen months and hemoptysis for two weeks His general physical condition was satisfactory There was no evidence of distant metastases He was toxic and resection was desirable regardless of mediastinal lymph node involvement S nce bronc oscopy failed to demonstrate n tumor above a safe level for bronchial division exploration followed immed ately The insert ind cates the findings at bronchoscopy The carina was wide A bulge was seen in the posterior wall of the trachea just above the carina A fungating mass projected into the lower lobe bronc us and purulent secretions welled up around it On October 19 1948 right pneumonectomy was performed for a grade III epidermoid carcinoma The medial half of the lower lobe was indurated and airless All visible lymph nodes eleven in number were resected Some were very large and firm All were negative for tumor The convalescence was uneventful and the total hospital stay was twenty four days His physician reports now nearly six years later that the patient is al ve and well

strongly suggest tracheal involvement and a frozen mediastinum the patient might as well be scheduled for preoperative bronchoscopy under topical anesthesia with the plan to proceed immediately (i e , the same hour) with thoracotomy, should no unexpected contraindication be discovered Fore-oblique and right angle telescopic lenses introduced through the bronchoscope assist in the thorough examination of the tracheobronchial system In silent cancer and in most early symptomatic cancer the bronchoscopy will be negative

However, a neoplasm may be seen involving the primary or secondary bronchi and be accessible for safe biopsy (Figs 1 to 3)

Doubtfully resectable cases are scheduled for separate bronchoscopic evaluation so that the patient and operating room personnel will be spared a cancellation It is our practice to explore the cervical area and upper mediastinum whenever there is a question of resectability This often is done as an office procedure In many cases it is a simpler method of settling the issue than bronchoscopy (Fig 4)

deemed unw se because risk of hemorrhage was great Secretions and sputum were both pos tive for tumor cells The pat ent was advised that surgery was not ind cated No therapy was given Total hosp tal stay was two days He succumbed twelve months later

EXPLORATORY THORACOTOMY

Exploratory thoracotomy ■ the final arbiter for many as to resectability It gives a rapid diagnosis when that diagnosis is urgently needed It evaluates more accurately than any other means the extent and histologic type of the growth The thoracic surgeon has an advantage over the abdominal surgeon Vision ■ not hampered at thoracotomy by an obtrusion of multiple mobile organs The sur geon s fingers more easily detect a lesion in the delicate airy substance of the lung than in a solid structure such as the liver or kidney Palpation of lung tissue is more precise than the handling of slithering coils of intestine.

for biopsy by wedge segmental or lobar resection

Although accuracy in diagnosis and e tion demands a wider use of exp able safety of the Fortunately brought

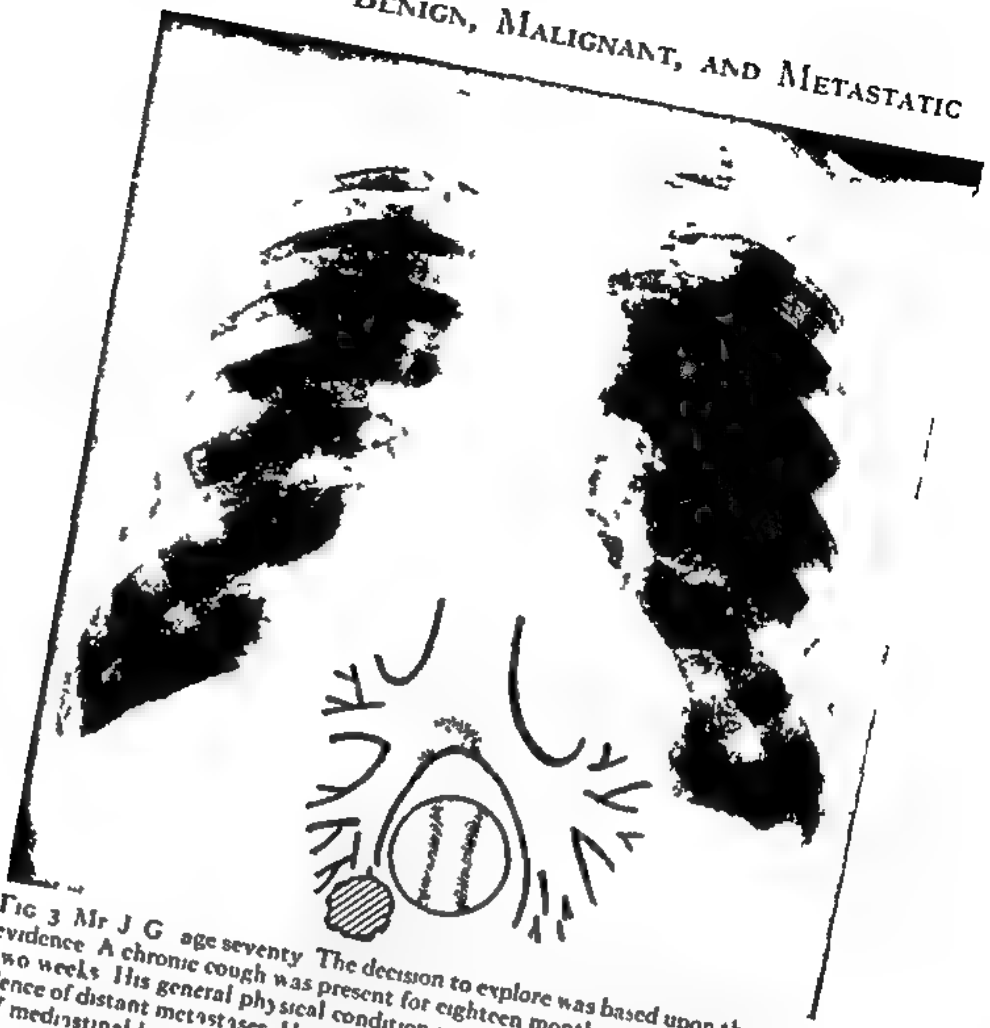

FIG 3 Mr J G age seventy The decision to explore was based upon the x ray evidence A chronic cough was present for eighteen months and hemoptysis for two weeks His general physical condition was satisfactory There was no evidence of distant metastases He was toxic and resection was desirable regardless of mediastinal lymph node involvement Since bronchoscopy failed to demonstrate a tumor above a safe level for bronchial division exploration followed immediately The insert indicates the findings at bronchoscopy The carina was wide A bulge was seen in the posterior wall of the trachea just above the carina A fungating mass projected into the lower lobe bronchus and purulent secretions welled up around it On October 19 1948 right pneumonectomy was performed for a grade III epidermoid carcinoma The medial half of the lower lobe was indurated and airless All visible lymph nodes eleven in number, were resected Some were very large and firm All were negative for tumor The convalescence was uneventful and the total hospital stay was twenty four days His physician reports now, nearly six years later that the patient is alive and well

strongly suggest tracheal involvement and a frozen mediastinum the patient might as well be scheduled for preoperative bronchoscopy under topical anesthesia with the plan to proceed immediately (i e, the same hour) with thoracotomy, should no unexpected contraindication be discovered Fore-oblique and right angle telescopic lenses introduced through the bronchoscope assist in the thorough examination of the tracheobronchial system In silent cancer and in most early symptomatic cancer the bronchoscopy will be negative However, a neoplasm may be seen involving the primary or secondary bronchi, and be accessible for safe biopsy (Figs 1 to 3)

Doubtfully resectable cases are scheduled for separate bronchoscopic evaluation so that the patient and operating room personnel will be spared a cancellation It is our practice to explore the cervical area and upper mediastinum whenever there is a question of resectability This often is done as an office procedure In many cases it is a simpler method of settling the issue than bronchoscopy (Fig 4)

lower trachea and main bronchi were fixed Use of the biopsy forceps was deemed unwise because risk of hemorrhage was great Secretions and sputum were both positive for tumor cells The patient was advised that surgery was not indicated No therapy was given Total hospital stay was two days He succumbed twelve months later

EXPLORATORY THORACOTOMY

Exploratory thoracotomy is the final arbiter for many as to resectability It gives a rapid diagnosis when that diagnosis is urgently needed It evaluates more accurately than any other means the extent and histologic type of the growth The thoracic surgeon has an advantage over the abdominal surgeon Vision is not hampered at thoracotomy by an obtrusion of multiple mobile organs The surgeon's fingers more easily detect a lesion in the delicate airy substance of the lung than in a solid structure such as the liver or kidney Palpation of lung tissue is more precise than the handling of slithering coils of intestine. Tests of inflation and deflation of the lung may yield additional evidence of abnormality. Nodes in the direct lymphway of the disease-bearing segment can be directly approached Parenchymal lesions can be totally removed for biopsy by wedge segmental or lobar resection

Although accuracy in diagnosis and evaluation demands a wider use of exploration, reasonable safety of the procedure must be assured Fortunately, advances in surgical technics have brought operative mortality in cases of pul-

monary carcinoma explored biopsied and closed without resection because of massive mediastinal invasion to slightly more than 1 per cent Exploratory thoracotomy for benign disease is well below one half of 1 per cent (Table II)

TABLE II
OPERATIVE MORTALITY IN CARCINOMA

Years	Exploration only (%)	Resection of Localized Lesions (%)
1933 1940	28	33
1941 1945	12	7 7
1946–1950	8 5	13
1951 1953	1 3	2 7

With the safety accuracy and necessity of exploratory thoracotomy well established its use has become more frequent in our clinic In the past four years 71 per cent of all cases seen have been explored This high rate results partially from the fact that some preselection has been made by referring physicians Also

TABLE III
HISTOLOGICALLY VERIFIED PRIMARY PULMONARY CARCINOMA

Year	Thoracotomy (%)	Resection (%)
1933 1940	43	18
1941 1945	63	30
1946–1950	67	42
1951 1953	71	49

extension of surgical palliation to more patients has raised the exploration rate It is significant moreover, that the resectability rate has risen three times as rapidly as has the exploration rate (Table III)

RESECTION

Early exploration has had a large part in making safe resection possible in an increasing number of cases Resection has been performed on nearly two-thirds of all patients explored for lung malignancy since 1945 Operative mortality including all deaths occurring within a month after operation has fallen steadily In the last three years the over all mortality rate was 7 per cent, for localized lesions the rate was 2 7 per cent

Two-thirds of the pulmonary resections fr 1941 to 1949 were for lesions which had ev dence for extension outside the lung to th mediastinum or chest wall Some of the resec

TABLE IV
POSTOPERATIVE RESULTS THIRTY SIX LUNG CANCERS DISCOVERED BY X RAY SURVEY

Localized to Lung (22)	Extended beyond Lung (14)
16 Survivors 8—One to three years 8—Three years or more	3 Survivors 2—One to three years 1—Three years or more
6 Dead 3—Of disease 2—At operation 1—No follow up	11 Dead All presumably of disease

tions were performed with the hope of palliation in others histology revealed unsuspected metastases in mediastinal lymph nodes Of all these patients undergoing resections for lesions already outside the lung 9 per cent lived more than five years

One third of the resections were in cases without evidence of extension beyond the lung From this group one of every four lived five years or more

Thirty six resections were performed for cancers discovered during radiologic screening Of those resected nineteen (53 per cent) are alive more than one year, nine (25 per cent) are alive more than three years Twenty two of the thirty six resections (61 per cent) were in lesions localized to the lung From this favorable group sixteen (73 per cent) are alive more than one year eight (36 per cent) are alive more than three years One half of all patients in the survey groups presented themselves for therapy more than seven months after the original x ray had been found suspicious for tumor This delay was caused in part by the reluctance of patients and in part by physicians in quest of definite diagnosis prior to suggesting thoracotomy Of all the patients coming to resection within two months of the first x ray, two of three are alive more than one year Of all patients still asymptomatic at the time of surgery three of four are alive more than one year Of asymptomatic patients resected within two months of survey

nine of ten have survived one year or longer (Table IV)

Safer resection has given dividends in prolonged life, relief of symptoms and cure The earlier, silent cases have had the least risk from operation and they have benefited most in cure

SUMMARY AND CONCLUSIONS

1 The abnormal shadow by x ray is evidence enough to demand exploration in many instances

2 The cancer potential of such shadows has been discussed

3 Each cancer patient deserves proper evaluation as to resectability A differentiation must be made between absolute and presumptive evidence of extension of the primary growth beyond surgical limits

4 Discomfort time and expense can be saved for those patients who probably should be explored regardless of negative or positive bronchoscopic findings by carrying out bronchoscopy as a preliminary to intratracheal intubation and exploration

5 Millions upon millions of chests are being examined by x ray each year More shadows that carry a cancer potential are being recorded A growing proportion of patients with pulmonary cancer are resectable More people are being cured

REFERENCES

1 HOOD R T JR GOOD C A CLAGETT O T and McDONALD J R Solitary circumscribed lesions of the lung J A M A 152 1185 1953

2 GROW J H BRADFORD M L and MAHON H W Exploratory thoracotomy in the management of intrathoracic disease J Thoracic Surg 17 480 1948

3 ABELES H and EHRLICH D Single circumscribed intrathoracic densities New England J Med 244 85 1951

4 HARRINGTON S W The surgical treatment of circumscribed intrathoracic lesions lesions found on routine thoracic roentgenologic examinations with absence of subjective symptoms Dis of Chest 19 255 1951

5 O'BRIEN E J TUTTLE W M and FERRANEY J E The management of the pulmonary coin lesion S Clin North America 30 1707 1950

6 SHARP D V and KISSELLA T J The significance of the isolated pulmonary nodule Minnesota Med 33 886 1950

7 FINK D L Coin lesions of the lung Minnesota Med 34 554 1951

Radical Surgery for Carcinoma

JOHN H GIBBON, JR, M D, T LANE STOKES, M D AND JOHN J McKEOWN, JR, M D,
Philadelphia, Pennsylvania

From the Jefferson Medical College Hospital of Philadelphia Pennsylvania

IN any discussion on pulmonary diseases the subject of cancer of the lung will be of prime importance This is true because of the extraordinary increase in the incidence of cancer of the lung in the past two decades It has become the most common cancer in white males, exceeding even cancer of the stomach The increased death rate from this disease among the male population in this country is illustrated in Figure 1 The same rising death rate did not occur in women (Fig 1) This remarkable increase in the deaths from cancer of a particular organ in men has aroused much speculation Prominent among the theories which have been advanced to explain the increase is the theory that prolonged and heavy cigarette smoking has been a significant contributing etiologic factor in the most common form of this cancer, namely, the squamous cell type The most recent extensive statistical study of this relationship was published by Hammond and Horn [1]

The following remarks concerning the surgical treatment of cancer of the lung are based upon a consecutive series of 617 patients seen by the senior author, his associates Drs Allbritten and Templeton, and the resident surgical staff at the Jefferson Medical Center These cases were studied between April 1, 1946, and January 1, 1954, and 441 of the patients were operated upon The remaining patients were not explored because of obvious evidence of metastasis outside the involved hemithorax

The symptoms of carcinoma of the lung have been adequately described in numerous articles in recent years and will not be considered here In 98 per cent of the patients in our series there was a detectable abnormality in the x-ray film of the chest and in 85 per cent a presumptive diagnosis of cancer of the lung was made by x-ray By means of bronchoscopy, a positive histologic diagnosis was established in 65 per cent of our cases, in 23 per cent by biopsy, and in an additional 42 per cent by cytologic examination of bronchial secretions This means that in 23 per cent of patients, the lesion was in one of the main bronchi or in the upper portion of a lower lobe bronchus, or projecting into a main bronchus from the orifices of the upper lobe or middle lobe bronchi However, in 42 per cent of the group when a biopsy was unobtainable, a positive histologic diagnosis was established by examination of a frozen section of tissue

Needle biopsy through the chest wall, in any patient in whom the lesion might be operable, is mentioned only to be condemned It is, of course, justifiable to establish a histologic diagnosis in this fashion if it is obvious that the lesion is inoperable In one of our patients a needle biopsy had been performed at another institution The lesion proved to be operable and pneumonectomy was performed Some months postoperatively a nodule of cancer appeared in the needle tract

The treatment of cancer of the lung where there is no evidence of distant metastasis is the complete surgical extirpation of the cancer with en bloc removal of all mediastinal lymph nodes In our experience such surgical treatment has resulted in a five-year survival rate of 26 per cent of all the patients in whom it was possible to remove the cancer of the lung In sharp contrast to this is the fact that 99 per cent of all the patients in our series in whom it was

not possible to remove the cancer were dead [illegible]

in whom the cancer was not removed only three are alive more than eighteen months after establishment of the diagnosis In these three patients the diagnosis was made on cytologic examination of the bronchial secretions Despite the absence of histologic section of the tumor we believe that the diagnosis of cancer of the lung in these patients is correct

adrenals at autopsy[8] Metastasis to bone, pancreas and kidney are somewhat less frequent Even less frequent, but constituting a significant proportion is metastasis to the brain to the opposite lung and to skin or subcutaneous tissues[28] Fortunately the most common earliest site of metastasis is to the cervical lymph nodes which are frequently palpable Any enlarged cervical lymph node should therefore be removed and examined histologically

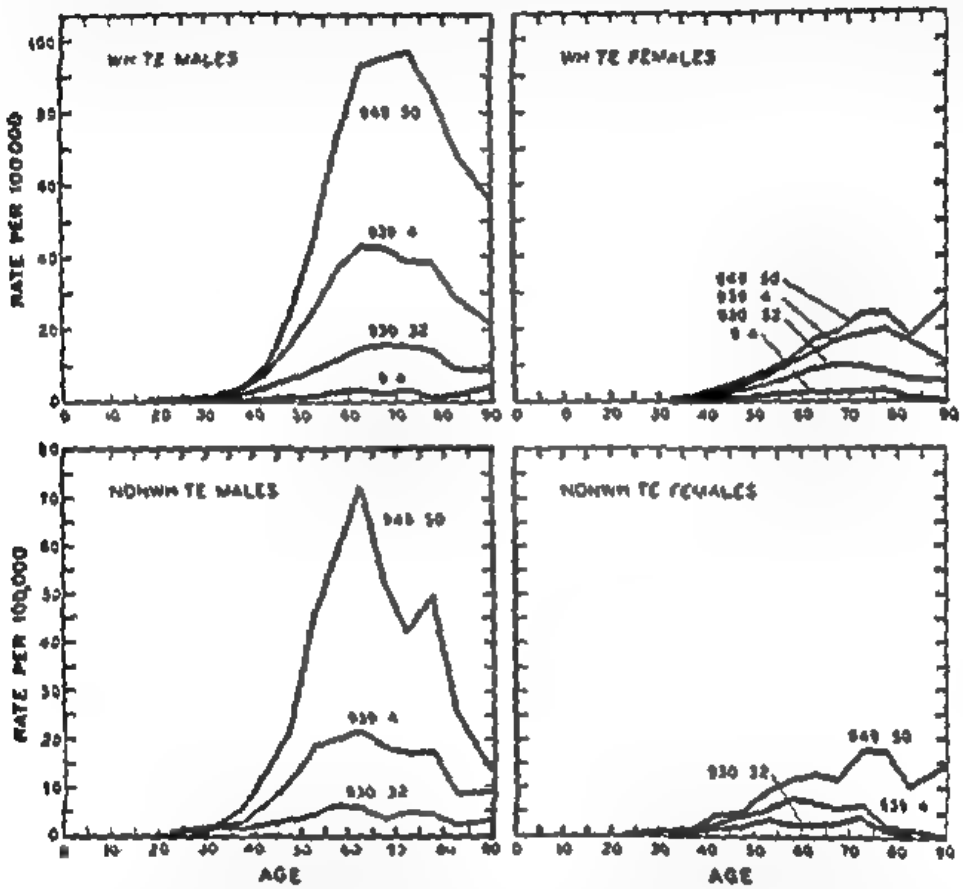

FIG 1 Number of deaths per 100 000 population from cancer of the lung and pleura The striking increase in death rate of males between the 1930–1932 period and 1949–1950 period is apparent (Reproduced from *Industrial Med & Surg* 23 253 257 1954 with permission of the author and publisher)

OPERABILITY

If there is any evidence of cancer outside the involved hemithorax the patient should not be operated upon The most common site of metastasis outside the involved hemithorax is to the cervical lymph nodes on the ipsilateral side The axillary lymph nodes on the same side are much less commonly involved In patients dying of cancer of the lung about 40 per cent show metastasis to the liver and to the

Invasion of the ribs and intercostal muscles by a peripherally located pulmonary cancer is a bad prognostic sign Even though it is possible to remove the involved portion of these structures en bloc with the lung such patients in our experience have not survived more than eighteen months Peripheral lesions in the lung with pain radiating around the chest or localized to the region of the tumor, have frequently invaded the chest wall Paralysis of the phrenic nerve is not regarded as a contraindication to operation This nerve is

usually infiltrated by a hilar growth which extends into the pericardium It is of course quite easy to remove the involved nerve and pericardium if the lesion is otherwise operable On the other hand paralysis of the left recurrent laryngeal nerve has invariably in our experience indicated an unresectable growth In these patients the carcinoma generally originates in the left main bronchus or in the left upper lobe We have explored twenty two such patients and in all it was impossible to remove the growth because of extension into the wall of the aorta or massive invasion of the mediastinum The right recurrent laryngeal nerve of course is only rarely involved because of its high position in the right side of the thorax Growths originating in the apex of the lungs producing Pancoast s syndrome have also proved to be unresectable

A pleural effusion especially when bloody is also a bad prognostic sign If the centrifuged sediment of such fluid contains cancer cells the patient is not explored because pleural metastasis will be widespread We have as yet been unable to perform a total pleurectomy together with a radical pneumonectomy If no tumor cells are found in the centrifuged sediment the patient should be explored particularly if the histologic diagnosis has not been established We operated upon one patient who had a massive bloody pleural effusion who was thought to have an inoperable cancer but in whom no histologic diagnosis had been established The patient was found to have a massive hemothorax of undetermined etiology with a completely atelectatic lung The hemothorax was evacuated the thickened visceral pleura was peeled off the surface of the lung allowing complete re-expansion The patient is symptom free two years after operation with no signs of carcinoma

EXTENT OF THE OPERATION

No extensive study of the pattern of metastasis to pulmonary and mediastinal lymph nodes has been made in cancer of the lung comparable to those made by Gilchrist and David[8] in cancer of the colon and by Coller Kay and McIntyre[9] in cancer of the stomach Such a study was begun in our laboratory several years ago but was never carried to completion The lungs were cleared by Gilchrist s technic and all lymph nodes were removed labeled and examined histologically

The results of this study together with observations at operation on more than 400 patients with cancer of the lung have enabled us to reach some tentative conclusions concerning pathways of lymphatic spread In general cancers of the upper lobe are prone to metastasize to the tracheal lymph nodes whereas those of the lower lobes tend to metastasize to the carinal group of lymph nodes The intercommunications between lymph nodes The intra the lobar bronchi and the main bronchi around such that we are convinced that it is impossible to perform an ideal cancer operation by doing a lobectomy In small peripheral tumors wide excision of the tumor will prove as 'curative as either lobectomy or pneumonectomy provided that metastasis has not occurred However it is obviously impossible for the surgeon to be sure that lymph nodes are not already involved Therefore radical pneumonectomy should be performed on all patients with cancer of the lung no matter what the size of the initial growth or its location and regardless of whether or not there appears to be metastasis to nodes Our only exception to this rule of performing a radical pneumonectomy has been in those patients who require extensive excision of the chest wall because of involvement by the cancer In these patients we usually perform lobectomy or bilobectomy rather than pneumonectomy because of the forbidding mortality when pneumonectomy is performed in conjunction with extensive resection of the chest wall Furthermore the prognosis in such cases is at best extremely poor

PREOPERATIVE PREPARATION

Anemia if present should be corrected by blood transfusion prior to operation If there is a weight loss of 15 pounds or more the patient is also given at least 500 ml of blood preoperatively even though the hematocrit and hemoglobin are within normal limits In our experience such patients with considerable weight loss invariably have a diminished circulating blood volume Only incipient or actual heart failure or such extensive pulmonary emphysema that the patient is dyspneic at rest are regarded as contraindications to pneumonectomy If there is an infection of the lung distal to a bronchus obstructed by the tumor antibiotics are employed preoperatively In most patients this will control the infection In an occasional patient the fever will not

subside until the infected lung is removed We have had a number of patients in whom pulmonary tuberculosis was coexistent with cancer of the lung If there is active tuberculosis in the lung contralateral to the cancer, operation is of course contraindicated

ANESTHESIA

An intratracheal tube with an inflatable cuff should always be used It ensures an airway and permits the easy aspiration of secretions during the operation The inflated cuff allows adequate ventilation of the lungs and avoids gastric distention with the anesthetic gases In several thousand intrathoracic operations we have seen no ill effects from using such balloons

The intubation is performed after local anesthetization of the pharynx and larynx with 0 5 per cent pontocaine or, in patients who are nervous and apprehensive, after the induction of anesthesia with intravenous sodium pentothal® and nitrous oxide and oxygen Once the intratracheal tube is in place and the cuff inflated anesthesia is continued and maintained

uppermost We realize that this position increases the difficulty of providing adequate pulmonary ventilation during the operation However, it gives the best exposure, through a posterolateral incision, for a difficult pneumonectomy Neither the prone nor supine positions provide the same excellent access to all parts of the opened hemithorax With the aid of a mechanical ventilator, which provides negative pressure during the phase of expiration, we have been able to maintain an adequate pulmonary ventilation during prolonged and difficult pneumonectomies, even when there was severe emphysema of the contralateral lung Furthermore it has not been necessary to use a curare like drug in order to have a completely quiet diaphragm The carbon dioxide tension falls and the pH rises, sufficiently so that no diaphragmatic activity occurs even with a very light plane of anesthesia

The tracheobronchial tree must be kept at all times free of secretions mucus and pus [illegible] tion of the trachea is repeated as o[illegible] sary throughout the course of the [illegible] It is routinely done when the p[illegible] on his side before the chest is o[illegible] repeated as soon as the pleural cav[illegible]

The necessity for such aspiration must also be borne in mind when the diseased lung is being handled or compressed If there are abundant secretions from the diseased lung entering the trachea and the opposite bronchus, the bronchus of the diseased side should be rapidly closed with a clamp or by tying a heavy tape around it at the start of the operation The last aspiration is performed as the intratracheal tube is being withdrawn, after deflation of the cuff, at the conclusion of the operation when the patient is placed in the supine position on the bed or stretcher to leave the operating room The final consideration of importance with regard to anesthesia is that the plane should be light throughout the operation There is no necessity for the muscular relaxation which is required in so many abdominal operations We make it a practice to have the patient so light that when the skin stitches are being inserted, the patient moves because of the stimulus from the needleprick in the skin Usually the patient is able to arouse sufficiently to respond to questioning before he leaves the operating room

TECHNIC OF RADICAL PNEUMONECTOMY

Many authors have made contributions to the development of the technic of radical pneumonectomy in recent years [1 6 10 1*] Brock,[2] Cahan[3] and Higginson[11] have especially stressed block dissection of lymph nodes Later we will describe the technic we have been using for the past five or six years Four or five scratches are made in the skin at right angles to the line of the proposed incision Such scratches are of aid in the accurate closure of the long, curved wound The skin incision is begun at the level of the spine of the scapula starting at a point one-third of the distance from the dorsal border of the scapula to the spines of the vertebra [illegible]

[illegible] muscle [illegible] ded [illegible] line
[illegible] of the mus[illegible] [illegible] of tl [illegible] rius
[illegible] muscle a [illegible] ut
[illegible] [illegible] de

in the direction of their fibers over the rib to be removed as far as the costal cartilage

Removal of either the fifth or sixth rib gives adequate exposure for a radical pneumonectomy Frequently the fifth rib is removed when the cancer is in the upper lobe and the sixth rib if there is a bulky tumor in the lower lobe The rib is removed subperiosteally from the angle posteriorly to the costal cartilage in front The posterior layer of the periosteum is then incised and the pleural cavity opened Adhesions between the parietal and visceral pleura if present are sufficiently separated so that the lung may be depressed with a broad malleable retractor covered with a gauze sponge This retraction of the posterior portion of the lung enables the remaining posterior segment of the rib to be excised from within the chest from the point of previous division to the transverse process of the vertebra The pleura and posterior layer of periosteum overlying this rib segment is incised with a scalpel and the periosteum is completely stripped from the rib down to the transverse process The rib is again divided here with large rongeur forceps During the resection of this posterior segment of the rib no retraction of the erector spinae mass is made nor are any of the fibers of the muscle divided This method of removing the posterior segment of the rib without disturbing the overlying erector spinae muscle aids greatly in obtaining an air tight closure of the posterior portion of the wound after completion of the pneumonectomy A self retaining rib spreader is then put in position protecting the wound edges with gauze sponges Opening the rib spreader to its fullest extent should be done slowly so as to allow tissues to stretch With this precaution fractures of the ribs above and below the wound can be avoided

With the thorax widely opened the first step in the operation is adequate exploration in order to determine whether the lesion can be extirpated If the tumor is peripheral and has invaded one or more ribs and intercostal muscle bundles the feasibility of excising these structures together with the involved lobe of the lung should be determined As stated previously lobectomy rather than pneumonectomy is advisable in these patients In the usual case all adhesions between the lung the wall of the chest the diaphragm and mediastinum should be separated Until this is done it is often impossible to determine the feasibility of a radical pneumonectomy If a positive histologic diagnosis has not been made preoperatively it is imperative to establish such a diagnosis before performing radical pneumonectomy It is usually possible to remove a lymph node suspected of being the site of metastasis without contaminating the operative field with cancer cells

When a histologic diagnosis has been established the only findings in our experience which prevent radical pneumonectomy from being performed consist of either massive matted invasion of the mediastinal lymph nodes direct invasion of the aorta on the left or extensive invasion of the superior vena cava on the right It is infrequent to find invasion of the pulmonary veins of such extent as to contraindicate the performance of a pneumonectomy A short pulmonary artery stump can always be closed with a continuous suture Involvement of the pulmonary veins as far as the wall of the left atrium can be taken care of by applying a non-crushing clamp to the wall of the left atrium removing all of the pulmonary veins and some of the atrial wall The wound in the atrium is then repaired with a running suture Similarly invasion of the main bronchus up to the trachea does not prevent the performance of pneumonectomy Even in the usual case it is our practice to divide the trachea obliquely just beyond the bronchus so as to leave no bronchial stump (Fig 3)

The radical pneumonectomy is begun on either the right or left side by incising the mediastinal pleura from the apex of the chest down to the main bronchus This incision is then extended anteriorly to expose the pulmonary artery and posteriorly to expose the bronchus and the carinal nodes On the right side (Fig 2) the azygos vein is doubly ligated and divided Making traction on the divided stumps of the veins the parietal pleura is elevated from the underlying structures from the main bronchus to the apex of the chest This exposes the fat and lymph nodes overlying the upper esophagus trachea and superior vena cava Care is taken not to injure the phrenic nerve in this process The vagus nerve is ligated and divided just below the point where the recurrent laryngeal nerve passes around the right subclavian artery Making traction on the divided distal stump of the

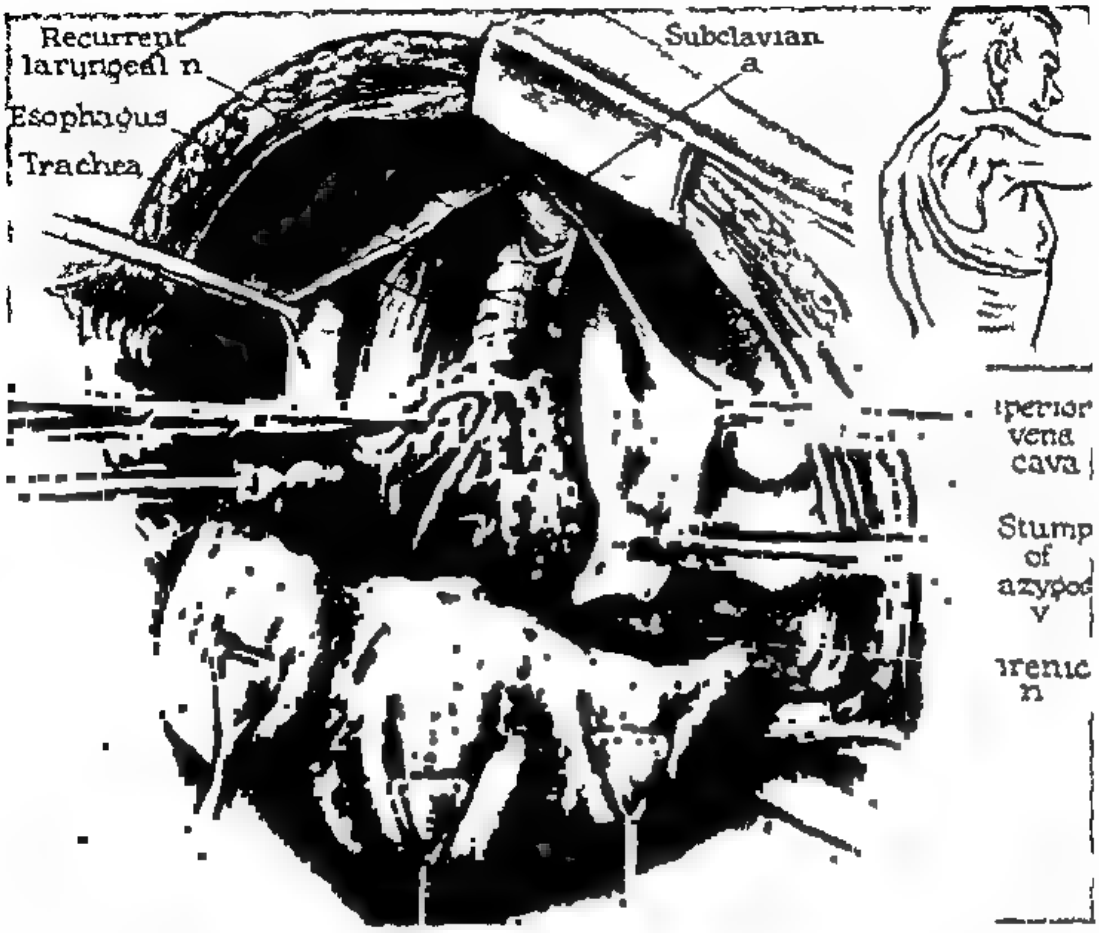

FIG 2 Drawing illustrating the removal of the superior mediastinal lymph nodes in a right radical pneumonectomy

vagus nerve the mass of fat and lymph nodes overlying the anterior and lateral walls of the trachea are swept downward by sharp and blunt dissection Included in this mass of fat and lymph nodes will be the occasional nodes which overlie the esophagus and those lying between the superior vena cava and the anterior flap of pleura When this dissection is completed the entire intrathoracic portion of the trachea upper esophagus and superior vena cava will lie bare of all fat and lymph nodes (Fig 2) During this dissection the upper lobe of the lung is drawn caudad by broad triangular clamps applied to the lung taking care not to crush infected tissue or tumor

The dissection is then carried anteriorly to expose the pulmonary artery and the superior pulmonary vein Excellent exposure of the entire pulmonary artery up to its origin from the main pulmonary artery can easily be attained by retracting the superior vena cava anteriorly The vena cava need not be occluded by this traction Only in rare instances will it prove advisable to approach the most proximal portion of the right pulmonary artery by separating the parietal pleura from the superior and lateral surface of the vena cava and retracting the cava posteriorly This is however, a useful maneuver to remember if there is a bulky hilar tumor which makes access to the pulmonary artery difficult We have not as yet found it necessary to divide the superior pulmonary vein before ligating and dividing the pulmonary artery on the right as has been suggested by Sweet [14] Such a maneuver merely exposes the more distal portion of the pulmonary artery, whereas the long main stem of the pulmonary artery lying posterior to the superior vena cava is the portion of the vessel which must be widely exposed

The pulmonary artery is then divided between ligatures Any rather thick non absorbable suture material may be used, such as heavy silk cotton or linen Fine strong suture material may cut through the vessel wall when it is drawn up and tied The distal

FIG 3
in a rig

portion of the artery is ligated first If the tumor is at a safe distance, we are apt to employ two distal ligatures—one around the branch to the upper lobe and the other around the branch to the lower and middle lobes The proximal ligature is then passed around the vessel and tied close to the main pulmonary artery It is our practice to place a second proximal ligature of the same material This ligature is carried on a curved needle which transfixes the artery 2 or 3 mm distal to the proximal ligature This transfixing ligature is tied with a square knot on one side of the vessel One of the free ends is then passed again around the vessel and the free ends tied a second time on the other side of it

[illegible] from the proximal ligature which may have a tendency to slip off and in any event, the cuff of artery distal to the transfixing ligature will be shortened There should always be a wide, flared stump of the artery distal to this ligature

The superior pulmonary vein is isolated ne The ligatures are then applied as for the p monary artery. It is always advisable, possible, to apply the distal ligatures branches of the superior pulmonary vein order to provide a longer stump distal to th proximal ligatures If the cancer is in the hila area, it is our invariable practice to open the pericardium in order to expose a greater length of the superior vein for safe ligation A second transfixing proximal ligature is employed in the same manner as for the pulmonary artery As mentioned previously, if the tumor is close to, or is invading, the superior vein, a light non-crushing clamp is applied to the auricular wall, the entire vein is removed and the wound in the atrium repaired with a running suture of No 0000 deknatel silk

The dissection is continued by reapplying the lung clamps so as to draw the lung anteriorly. The pulmonary ligament is divided up to the inferior pulmonary vein All the lymph nodes overlying the esophagus are swept upward during this process and the main trunk of the

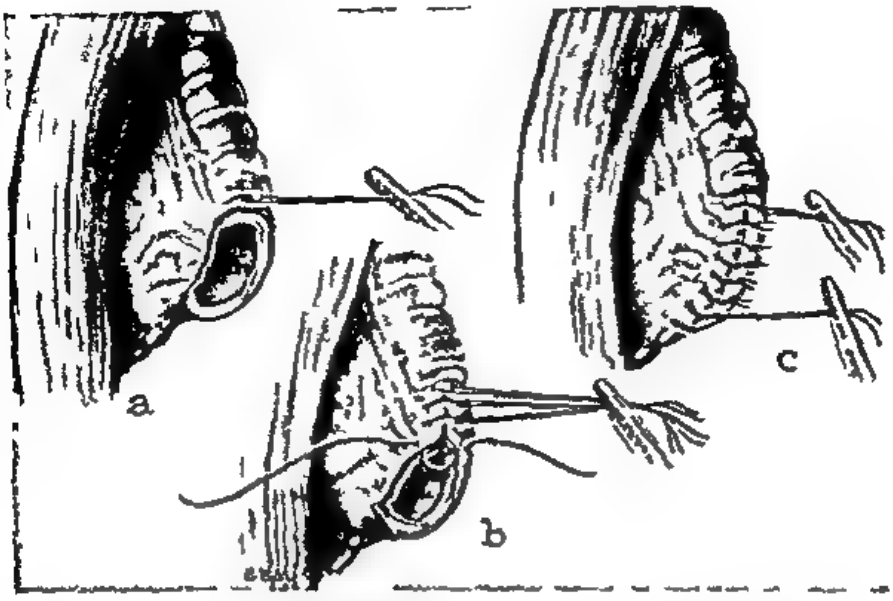

FIG 4 Drawing illustrating the techn e of closure of the tracheal wound after amputat on of the right bronchus in a pneumonectomy (a) Traction on a suture placed prior to amputation of the bronchus keeps the f eld exposed (b) technic of placing interrupted sutures to close the trachea so that the mucous membrane is not traversed by the non absorbable suture material (c) the closure completed The suture l ne is always reinforced by buttressing it against viable adjacent tissue

vagus nerve ■ again divided low in the thorax These lymph nodes and the isolated segment of the vagus nerve are held upward on the posterior surface of the lung by clamps (Fig 3) The inferior pulmonary vein is then ligated and divided in the same manner as described for the superior pulmonary vein Removal of the subcarinal lymph nodes is then begun This dissection is started along the caudad margin of the opposite main bronchus at a distance of at least 3 cm from the carina These lymph nodes are then separated from the opposite main bronchus (Fig 3) and are also drawn up to the lung leaving the carina and main bronchus bare

The dissection has now been completed and the main bronchus ■ ready for division and closure The lung with the attached lymph nodes and fat is retracted in the direction which will provide the best exposure of the bronchus and lower trachea A clamp ■ placed across the main bronchus distal to the proposed line for division of the bronchus to prevent mucus or pus escaping into the operative field No proximal clamp ■ used A traction suture of No 30 cotton on a fine French needle is passed through the lateral tracheal wall just above the line of the proposed incision (Fig 4a) The lower trachea is then divided along an oblique line as indicated in Figure 3 It should be emphasized that in all cases the incision ■ made through the trachea and not the bronchus This is done in order to avoid leaving any bronchial stump in which secretions can collect In some instances when the tumor is [illegible] too bulky, the incision is not completed immediately but is only carried through half its length Traction on the lung as well as [illegible] suture in the tracheal wall then aids [illegible] exposure of the tracheal wound for [illegible] closure Generally, however, the incision [illegible] completed at once and the lung remo[illegible] the operative field as this affords [illegible] posure for suture of the tracheal w[illegible] soon as the trachea is opened, the [illegible] main bronchus and the trachea are [illegible] of any blood or secretions present

The wound in the trachea is cl[illegible] interrupted stitches of No 30 cott[illegible] french eye needle Care is taken to [illegible] needle and the suture do not pass [illegible] mucus membrane of the trachea [illegible] cases it is surprisingly easy to do t[illegible] This suturing technic approximate[illegible] mucosa, yet leaves no suture [illegible] the lumen of the trachea This [illegible] technic we believe avoids ulcerat[illegible] granulation tissue and bleeding [illegible] of closure of the tracheal wo[illegible] rupted stitches are placed app[illegible]

FIG 5 Drawing illustrating the completed removal of mediastinal lymph nodes superior to the aortic arch prior to the removal of the lymph nodes inferior to the arch in a left radical pneumonectomy

3 mm apart The suture line is reinforced with additional stitches if it is considered necessary An attempt is always made to have the closed tracheal wound lie in immediate contact with some neighboring tissue We formerly were in the habit of suturing a pedicled flap of parietal pleura over the suture line More recently we have been using any available tissue in the immediate vicinity to buttress the suture line

A left radical pneumonectomy is performed in a manner almost identical with the above described procedure on the right side The presence of the aortic arch however crossing the field of the cephalad node dissection makes it impossible to perform the theoretically ideal block removal of fat and lymph nodes (Fig 5) The mediastinal pleura is opened from the apex of the chest to the hilum of the lung All fat and lymph nodes overlying the left common carotid and left subclavian arteries are swept downward over the aortic arch leaving these vessels and the vagus nerve clearly exposed Care must be exercised during this procedure to avoid injuring the left recurrent nerve as it passes upward between the trachea and the esophagus The recurrent nerve is then identified as it passes around and beneath the aortic arch It should be kept clearly in view during the subsequent lymph node dissection as it can be easily injured inadvertently The vagus nerve is ligated and divided just beyond the left recurrent branch The ligamentum arteriosum is then divided Traction on the divided stumps of this ligament helps to provide exposure of the lymph nodes around the main bronchus and lower portion of the trachea The aortic arch is elevated as much as possible from the trachea and the esophagus Beginning high up beneath the aortic arch all the fat and lymph nodes lying anterior and lateral to the trachea and lateral to the esophagus are swept downward by blunt and sharp dissection to the distal portion of the left main bronchus The dissection from here on differs in no essential way from that described previously for the right side except that the pericardium is almost invariably opened on the left to expose the most proximal portion of the left pulmonary artery

Before closing the wound in the chest the

pleural cavity is washed with salt solution which is then aspirated With the salt solution lying in the mediastinum the anesthetist increases the intratracheal pressure to test the bronchial stump for leakage of air If any leak is present, the stump must be exposed and the air leak closed The pleural flaps overlying the upper mediastinum are loosely approximated, as this may aid in the more rapid sealing off of the mediastinum Patients who have had a radical pneumonectomy, however, will always show some subcutaneous emphysema in the neck because coughing in the postoperative period will inevitably force air into the mediastinum and up into the neck The ribs above and below the one resected are then drawn toward one another by any suitable rib approximator The periosteum of the resected rib is closed with a continuous suture of No o chromic catgut which is interrupted once In our ex-

interrupted stitches of non absorbable suture material spaced at a distance of from 2 to 3 cm The serratus magnus the latissimus dorsi and the trapezius muscle, if it has been divided, are closed with interrupted stitches Drawing the arm down to the side and sliding the scapula posteriorly and caudad on the chest wall relieves tension on these muscles and facilitates closure The deep layer of the superficial fascia is approximated with fine interrupted cotton with buried knots taking care to align the skin accurately guided by the previously made scratch marks The skin is closed with interrupted cotton sutures

A small gauze dressing is applied to the wound This in turn is covered with strips of wide elastoplast® adhesive The skin is painted with compound tincture of benzoin which is allowed to dry before applying the elastoplast The elastic adhesive should be only gently stretched when it is applied since overstretching will blister the skin beneath it The adhesive should extend well beyond the midline both anteriorly and posteriorly This elastic adhesive dressing gives an excellent support to the wound during the act of coughing during the postoperative period This original dressing may be removed and replaced with a light gauze dressing by the fourth or fifth day if desired Skin sutures are removed on the seventh day Before the patient leaves the operating room, intrapleural pressure on the operated side should be adjusted to normal values This is best done after the patient has been returned to the supine position A needle is inserted in the pleural cavity of the operated side anteriorly in the second interspace at a sufficient distance from the sternum to avoid injury to the internal mammary vessels Sufficient air is then withdrawn to leave the intrapleural pressures, with quiet respiration, in the neighborhood of minus 2 to minus 10 cm of water

SUMMARY

A brief analysis of a series of 617 patients with cancer of the lung is presented The results of surgical treatment are reported and the technic of radical pneumonectomy described

REFERENCES

1 ALLISON P R Intrapericardial approach to the lung root in the treatment of bronchial carcinoma by dissection pneumonectomy *J Thoracic Surg* 15 90 1946

2 BROCK R C Bronchial carcinoma *Brit M J* 2 737 1948

3 CAHAN G C WATSON W L and POOL J L Radical pneumonectomy *J Thoracic Surg* 22 449 1951

4 COLLER, F A KAY, E B and MCINTYRE H S Regional lymphatic metastases of carcinoma of the stomach *Arch Surg* 43 748 1941

5 ENGLEMAN R M and MCNAMARA W L Bronchogenic carcinoma A statistical review of two hundred and thirty four autopsies *J Thoracic Surg* 27 227, 1954

6 GIBBON J H JR HERBUT P A and DE TLERK J J The diagnosis and operability of bronchogenic carcinoma *J Thoracic Surg* 17 419 1948

7 GILCHRIST R K and DAVID V C. Lymphatic spread of carcinoma of the rectum *Ann Surg* 108 621 1938

8 HALPERT B FIELDS W D and DEBAKEY M E Intracranial metastasis from carcinoma of the lung *Surgery* 35 346 1954

9 HAMMOND E C and HORN D The relationship between human smoking habits and death rates *J A M A* 155 1316, 1954

10 HEALEY J E and GIBBON J H JR Intrapericardial anatomy in relation to pneumonectomy for pulmonary carcinoma *J Thoracic Surg* 19 864 1950

11 HIGGINSON J F Block dissection in pneumonectomy for carcinoma *J Thoracic Surg*, 25 582 1953

12 KIRKLIN J W and JAMPOLIS, R W Intrapericardial dissection in left pneumonectomy for bronchiogenic carcinoma *J Thoracic Surg* 25 280 1953

13 SWEET R H Thoracic Surgery 2nd ed Philadelphia and London 1950 W B Saunders Co

Lung Cancer Associated with Cancer Primary in Other Sites

WILLIAM G CAHAN, M D New York, New York

From the Thoracic Surgical Service, Memorial Center for Cancer and Allied Diseases, New York, N Y Made possible in part by the grant of Leonard Wolfson and the Albert Schweitzer Fund

MULTIPLE cancers originating in different anatomic sites of the same individual have frequently been observed Up to 1932 this phenomenon had been noted both in life and at autopsy in 1 259 instances [9] For the most part they have grouped themselves in organs that are part of the same anatomic and physiologic system but they are also found in sites that seem to have no particular interrelationship

Warren and Gates[10] performed 2 829 autopsies on patients with cancer and found 194 instances of multiple primary malignant growths —an incidence of 6 8 per cent On the basis of these data they concluded that an individual with one cancer is eleven times more apt to have a second develop than is a patient in whom the first cancer has not yet developed The authors also stated that an average interval of 3 2 years elapsed between the appearance of the individual neoplasms when this could be measured

If this predisposition to develop multiple malignant tumors exists in certain individuals it is reasonable to suppose that as survival rates are extended by a combination of earlier diagnosis and improved methods of treatment new cancers can be expected to arise in new sites Therefore in follow up examinations patients who have had cancer should be scrutinized for evidence of a separate primary growth as well as for metastases from a lesion already known to exist

The management of multiple primary cancers may seem at first to be exceedingly complex Indeed in those occurring synchronously it is often difficult to decide what form of therapy to employ and which tumor deserves first consideration therapeutically or if both should be treated at once In metachronous lesions there is less confusion for the time interval between the appearance of the separate tumors usually permits an estimation of the degree of control of the first lesion and a more deliberate selection of the treatment for the second

It has been assumed that the possibility of survival diminishes with the advent of each new cancer capable of metastasizing Yet it is more and more suggestive as experience accumulates that the maintenance of aggression in treatment rather than the yielding to defeatism has produced surprisingly favorable results In the series to be reported herein eight of eighty two patients survived five or more years after treatment of their multiple cancers one of which occurred in the lung Consequently, we believe that the appearance of two or more primary cancers of different organ systems should not contraindicate radical therapy for each If for example adenocarcinoma of the rectum has been controlled by abdominoperineal resection and later carcinoma of the breast develops it should be treated by radical mastectomy Similarly the apparently complete eradication of a malignant testicular tumor several years prior to the appearance of gastric cancer would not contraindicate gastrectomy

The probability of survival in each separate case of cancer varies considerably with the particular clinical setting If the carcinoma of the rectum just mentioned occurred by itself and were in the pathologic classification of Dukes A or Dukes B the patient would have an estimated 65 to 85 per cent chance of living five years If the breast cancer that was removed subsequently were the only tumor present and was found not to have metastases in the regional lymph nodes the chance of five-year survival would be approximately 75 per cent One can only conjecture whether the combination of these two primary lesions in one individual would alter the prognosis Actually, the prognosis may be even better than that reported for

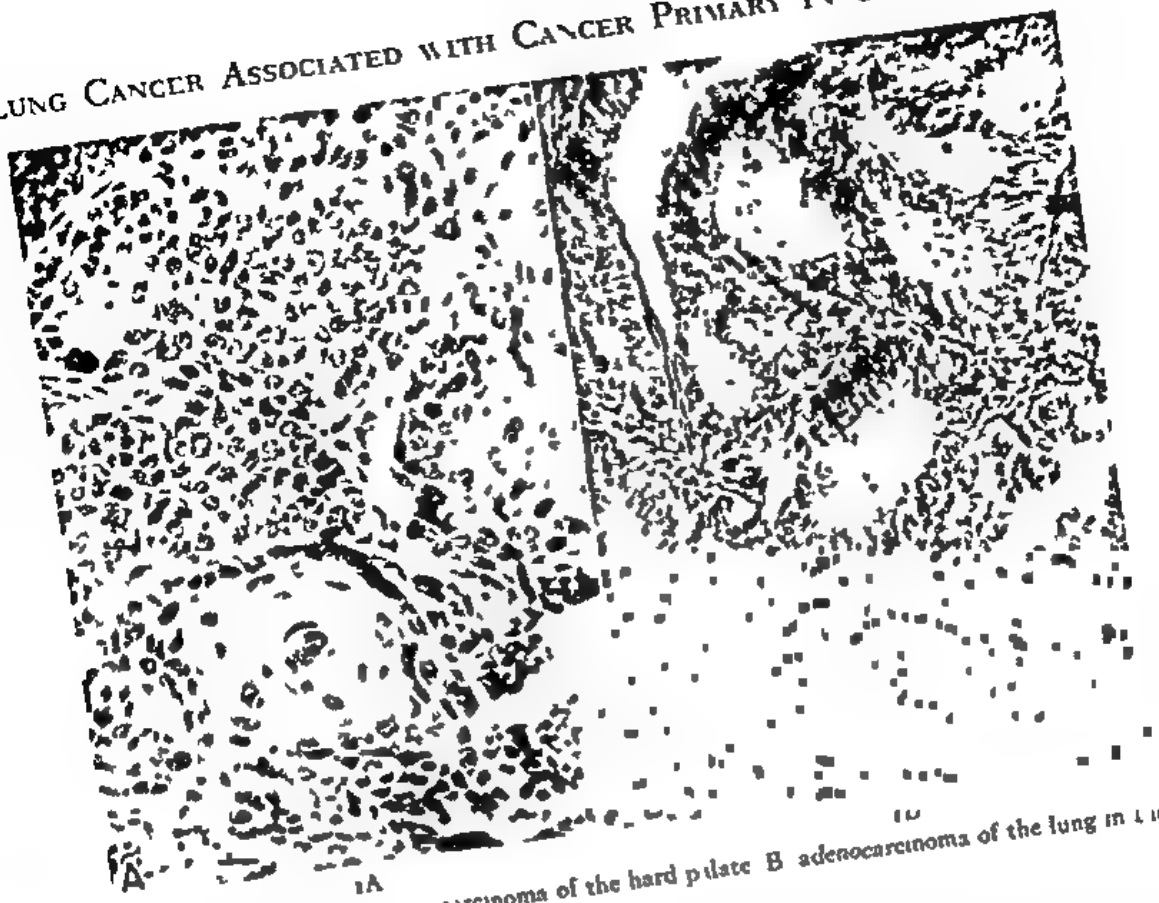

FIG 1 Case 11 A squamous carcinoma of the hard palate B adenocarcinoma of the lung in the same patient

such notorious cancers as those of the stomach or esophagus occurring alone

In facing repeated major surgical procedures patients and their families need psychologic help but respond well when a reasonable chance of 'cure' is offered Thus a forty nine year old mother of four children did not protest when she was faced with the necessity of radical mastectomy, anterior resection of the sigmoid colon and right upper and middle lobe lobectomy

CRITERIA FOR MULTIPLICITY

Criteria for diagnosis of multiple cancers must be clearly defined In the first two examples cited previously (carcinoma of the rectum followed by breast cancer and a malignant testicular tumor followed by gastric cancer) the combinations of lesions were such that the second primary, because of its location was not likely to be confused with metastases from the first However, when lung tumors are considered, a careful distinction must be made as to whether this organ is acting as the site of a new growth or as a filter and repository of metastases This distinction can be made unequivocally only when the two tumors have entirely different histologic characteristics as seen in our Case 11* in which squamous carcinoma of the hard palate coexisted with adenocarcinoma of the lung (Fig 1) There are twenty-six cases in this series meeting this criterion (excluding seventeen cases with basal cell carcinomas of the skin) The former are classified as having positive evidence of multiple primary cancers

On the other hand, if the two lesions in question have the same histologic pattern it is almost impossible to distinguish microscopically between a new, primary focus and metastasis in the lung By no means however does this necessarily exclude the possibility that the pulmonary lesion may be a separate and distinct primary one Reliance in these instances must be placed upon the clinicopathologic picture, and in this series thirty eight cases are classified as having probable evidence of multiple primary cancers In Case 19 (Figs 8 and 9) squamous carcinoma existed synchronously in the extrinsic larynx and the left main stem bronchus The latter is an unusual site for metastasis from the former, and in the gross specimen removed by radical pneumonectomy, cancer was found arising from the bronchial

*Case numbers refer to those in this series of eighty two patients

wall There were no metastases noted in the remainder of the resected lung nor have any appeared subsequently in the regional lymph nodes of the neck or in the opposite lung in the five years and five months since operation In Case 32 squamous carcinoma confined to the

TABLE I

M [illegible] *

[illegible] 3 2 c

* From the files of Memorial Center

edge of one vocal cord and non infiltrative in character, occurred synchronously with epidermoid carcinoma of the right upper lobe bronchus The pathologist believed that the probability that the two lesions represented primary cancer and its metastasis was remote despite the presence of the same basic histologic pattern

In addition to these gross observations the pathologist will sometimes find in the bronchus *in situ* carcinoma confluent with bronchogenic carcinoma suggesting the bronchial origin of the cancer

In a separate group are seventeen cases of lung cancer associated with basal cell carcinomas of the skin Although these skin lesions

viduals to evolve cancer

COMPILATION OF CASES

In 2 502 cases of cancer of the lung observed in Memorial Center over a period of twenty

There were two triple primaries

Warren and Gates[10] found 120 cases of lung cancer in their autopsy series in nine of which there was another primary lesion—an incidence of 7 5 per cent They constituted 4 6 per cent of all the cases found to have multiple primary cancers at autopsy

The sites of the separate malignant growths in our series are listed in Table II and include eighteen of the oral cavity nineteen of the larynx (both extrinsic and intrinsic), five of the colon and rectum and three each of the bladder, kidney and squamous carcinoma of the skin one of the breast and two each of the testicle Hodgkin's disease and lymphatic leukemia. There was one each of the prostate breast, cervix common bile duct branchiogenic cyst cancer, and one soft part sarcoma The triple primary cases included one patient who had cancer of the breast and sigmoid and another

TABLE II

MULTIPLE PRIMARIES ASSOCIATED WITH LUNG CANCER

Double Primary	
Head and Neck	
Lip	2
Alveolar ridge	2
Buccal mucosa	1
Tongue	6
Floor of mouth	3
Hard palate	2
Tonsil	1
Extrinsic larynx	11
Intrinsic larynx	8
Branchiogenic cyst	1
Breast	1
Colon	
Sigmoid	3
Rectum	2
Genitourinary	
Testicle	2
Prostate	1
Bladder	3
Kidney	3
Lymphoma	
Hodgkin s d sease	2
Lymphatic leukemia	2
Cervix	1
Common bile duct	1
Soft part sarcoma	1
Skin	3
Basal cell carcinoma of skin	17
Triple Primary	
Breast and s gmoid	1
Tongue and extrins c larynx	1
Total cases	81

who had cancer of the tongue and extrinsic larynx

In the literature[8-11] there are at least thirty seven cases in which cancer of the lung has been found to be one of two malignant tumors at autopsy Of these the kidney colon and stomach were the sites of the other tumor five times the skin four times the prostate and breast three times each the esophagus gallbladder and tongue, twice each and the lip bladder larynx liver sarcoma of the leg and lymphosarcoma once each In addition there was a triple primary arising synchronously as squamous carcinoma of the bronchus adenocarcinoma of the pancreas and carcinoma of the prostate

Synchronous and Metachronous Cancers In a discussion of multiple primary malignant

growths the time relationships between the appearances of the tumors is of interest In this communication the cancers are considered synchronous if the interval between the establishment of the diagnosis of the first primary tumor and the detection of the second was less than six months metachronous if more than six months

In the sixty four cases in this series excluding the cases associated with basal cell carcinomas lung cancer was synchronous with another malignant tumor in twenty four instances and in forty instances it was metachronous

In four of the forty metachronous cancers lung cancer antedated the appearance of the second primary malignant tumor two of these were in the extrinsic larynx one was in the descending colon and Hodgkin s disease developed in one patient The interval in these four cases ranged from six months to four and a half years This finding may be considered as additional evidence that prolonged survival after the removal of one cancer may well permit the formation of a second at another site In this connection in the original paper from this institution[2] which listed twenty five multiple primary cancers of the type under discussion not one case was reported in which a lung lesion antedated the appearance of the second growth This is also true for the majority of the cases reported in the literature

DIAGNOSIS

When a patient who has cancer known to metastasize develops pulmonary symptoms or a asymptomatic roentgenographic shadow whose significance is not clear considerable clinical and laboratory data may be required to establish the true nature of the process[3]

History and Physical Examination Although primary cancer of the lung may be expected to show earlier evidences of bronchial irritation and stenosis than metastasis little reliance can be placed on signs and symptoms as aids in differentiating between the two

Sex and Age There were seventy two men and nine women in this series Their ages varied from thirty five to eighty four years with an average of 59 3 years

Roentgenographic Findings The fact that seventeen cases were asymptomatic and were detected by routine roentgenograms of the chest emphasizes the value of these films as part of a follow up system Once the diagnosis of cancer capable of metastasizing is made, it has been customary to order x rays of the lungs at intervals varying with the virulence of the known malignant tumor, but not less frequently than every six months

It is impossible to establish with certainty the nature of a solitary shadow of the lung by roentgenographic means alone Nevertheless the correct diagnosis of primary lung cancer as distinguished from metastasis, was suggested in sixty eight instances largely by the fact that certain cancers are known to metastasize infrequently to the lung In addition the pulmonary shadow s configuration with its associated segmental atelectasis and the inability to demonstrate other suggestive opacities radiologically gave further emphasis to this possibility It is fundamentally important that the radiologist be aware that such a differential diagnosis exists and bring this possibility to the attention of the clinician

Additional aid in evaluating pulmonary shadows in this category may be derived from comparison with previous chest roentgenograms and every effort should be made to obtain them At Memorial Hospital it is believed that an orderly progression of radiologic technics should be maintained Whereas these technics may increase the possibility of revealing lesions not shown by ordinary roentgenograms they should be used for a specific purpose and not ordered routinely For the most part in addition to the ordinary sagittal and lateral views of the chest stereoscopic postero-anterior views are taken Occasionally these stereoscopic views are taken in the lateral projection If doubt persists the relatively expensive procedure of tomography can be used to define doubtful shadows seen on the previous films and to help reveal bronchial changes in the absence of atelectasis

It is tempting to assume that a single shadow in the lung in the presence of cancer is metastasis and that it may represent the forerunner of many to come However undue delay in aggressive therapeutic action while attempting to gain a panoramic view by a series of x rays over a period of time increases the probability that primary cancer or a solitary metastatic deposit may elaborate itself and become incurable

Bronchoscopy and Exfoliative Cytology Papanicolaou[8] states that in sputum or bronchial

aspiration containing clusters of cells the pathologic varieties of primary lung cancer can often be distinguished In twelve cases it was possible to make a definite preoperative diagnosis of pulmonary cancer by obtaining histologic material which proved different from that of the

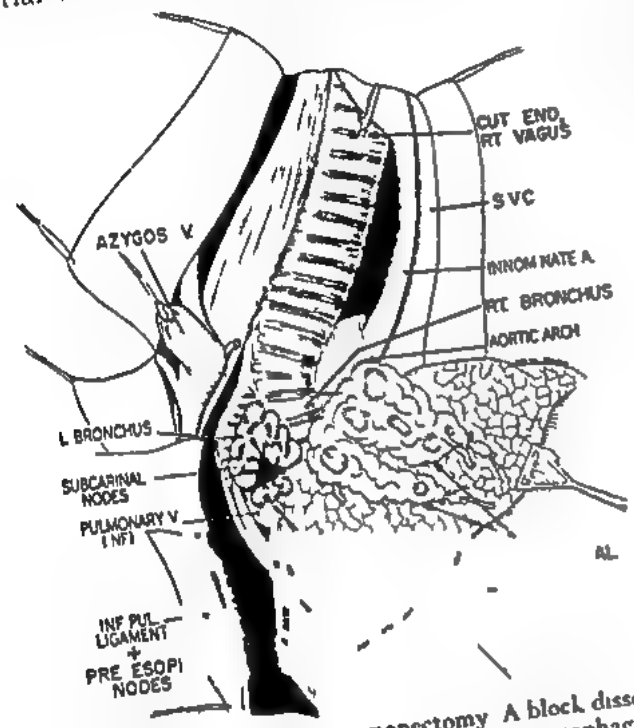

FIG 2 Right radical pneumonectomy A block dissection of the paratracheal subcarinal and pre-esophageal lymph nodes with the lung is shown The right bronchus is not divided Note recurrent laryngeal nerve with divided stump of right vagus which has been excised Azygos vein is retracted (S V C = superior vena cava) See Figure 3

other primary cancer For example, in Case 45 a correct diagnosis was made when the first cancer was adenocarcinoma of the rectum and the cytologic picture of the bronchial washings was squamous carcinoma Radical pneumonectomy was performed which confirmed the nature of the lung lesion

In these eighty one cases there were thirty-four instances in which the cytology of the bronchial secretions was positive In six of these cases exfoliative cytology alone was able to make a diagnosis of cancer of the lung In two other cases the cytology as well as the biopsy was positive and in four cases the cytology failed to yield a positive diagnosis Bronchoscopic biopsy helped clarify the differential diagnosis in two cases by distinguishing squamous carcinoma of the bronchus from Hodgkin's disease, and oat cell carcinoma from squamous carcinoma of the extrinsic larynx Two cases were established preoperatively by aspiration biopsy through the chest wall

When the cells obtained by exfoliative cytology reveal the same histologic structure as the known primary cancer elsewhere, it is impossible to distinguish whether metastasis is present However, the fact that carcinoma is revealed by this method is often a help in establishing the true nature of equivocal shadows This was demonstrated in five of eighteen cases in which solitary metastatic foci rather than primary carcinoma of the lung were found However, for the most part, metastases in the lung tend to yield scantier exfoliations than a primary malignant tumor

Biopsy at Operation In a number of instances it was impossible to make a preoperative histologic diagnosis by any clinical means, therefore exploratory thoracotomy was used This procedure is a relatively simple one, has a mortality of less than 1 per cent and very little morbidity However, before surgery is undertaken every effort is made to evaluate the patient's cardiac and pulmonary function so that at operation it can be judged how much functional respiratory epithelium can be removed if it is necessary

Tumors located near the hilum and seeming to arise in, or immediately adjacent to, the main stem bronchus (as in Case 21) can be handled in two ways (1) an aspiration biopsy of the main tumor mass can be made with the chest open, and (2) a wedge of tissue can be removed from a representative area However, when the clinical setting strongly suggests that a primary tumor of the lung exists, it has been customary to perform radical pneumonectomy without an adequate biopsy * (Fig 2) This provides the only means of securing a complete specimen for histologic study without incising the lesion itself, thereby reducing the risk of intrapleural dissemination of infection and/or neoplastic tissue The inclusion of the mediastinal lymph nodes as part of a block dissection with the lung takes little more time, does not increase morbidity and improves the probabilities of removing all the gross evidences of cancer

The problem of the management of solitary peripheral lesions at exploratory thoracotomy is more difficult, for if this were a primary carcinoma and the patient's reserve were adequate, radical pneumonectomy affords the best chance

for wide removal of cancer If it is a solitary metastasis, one might tend to be more conservative in the amount of respiratory epithelium to be removed and thus perform radical lobectomy (Fig 3)

In an attempt to distinguish the histologic nature of these peripheral tumors, wedge or segmental resection and even aspiration biopsy of these lesions has been used These methods provide a quick pathologic diagnosis and have added significance if slides of the primary lesion elsewhere in the body are available for comparison However, if the patient's condition permits, the aforementioned measures are usually omitted when it seems most probable that cancer is present and a radical lobectomy is performed

Reasoning in a similar vein, as for the tumors of the hilum for which radical pneumonectomy was performed, it is believed that these peripheral lesions should be excised *in toto* with the affected lymphatics This provides a wider and more complete excision of the tumor, and a better opportunity to distinguish the character of the lung growth by preserving its relationship to the bronchial tree The inclusion of the lymph nodes implicit in radical lobectomy, although not as thorough a dissection as that of radical pneumonectomy, increases the probability of removing metastatic foci The reason for this is that not only primary cancers of the lung but also metastatic deposits therein can give rise to daughter or second generation metastases in the local lymph nodes On occasion, after radical lobectomy has been completed, if there is doubt whether or not there has been adequate excision achieved by this compromise procedure, and if the condition of the patient permits, a modified radical pneumonectomy can be completed

On several occasions a roentgenographic finding of a single shadow was inaccurate in that multiple parenchymal nodules were found at exploratory thoracotomy One of these is usually selected for frozen section, and if this is positive for the presence of cancer, nothing further need be done

HISTOLOGIC TYPES

The histologic type of pulmonary neoplasm in this series was epidermoid carcinoma in sixty-three instances Five patients had adenocarcinoma of the lung, four had anaplastic carcinoma, two had oat cell carcinoma, two had

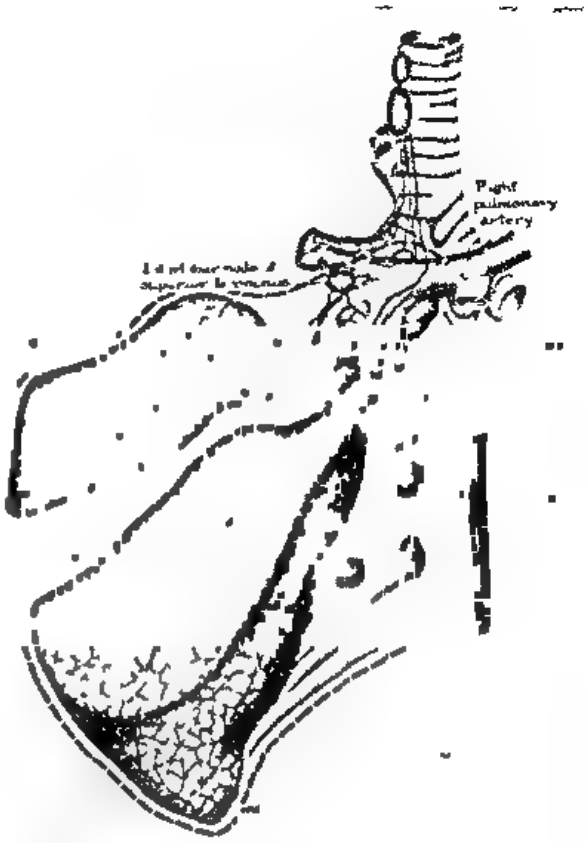

FIG 3 Right radical middle and lower lobe lobectomy is indicated by the dotted line Note how the nodes of the right paratracheal region are not included (See Figure 2) Stump of right upper lobe shown, lobe omitted for clarity

mucous gland carcinoma, and two had spindle cell carcinomas One patient had terminal bronchiolar carcinoma, one had extramedullary plasmacytoma and one had malignant bronchial adenoma

TREATMENT

Of the eighty one cases in this series, forty-two were surgically explored, twenty-three had simple or radical pneumonectomy and nine [illegible] This is [illegible] high [illegible] rable [illegible] this reflects the relatively early stage in which most of these lesions were discovered

There was one postoperative death after radical pneumonectomy and one after exploratory thoracotomy

In the thirty-nine patients who were nonresectable, gold filtered radon seeds were inserted in and about the cancer at the time of exploratory thoracotomy, and this was usually

aspiration containing clusters of cells the pathologic varieties of primary lung cancer can often be distinguished In twelve cases it was possible to make a definite preoperative diagnosis of pulmonary cancer by obtaining histologic material which proved different from that of the

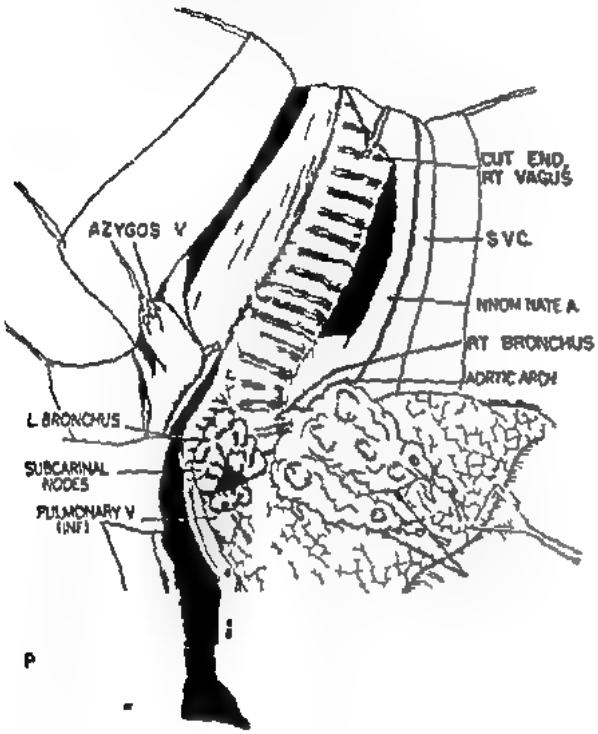

excised Azygos vein is retracted (S V C = superior vena cava) See Figure 3

other primary cancer For example in Case 45 a correct diagnosis was made when the first cancer was adenocarcinoma of the rectum and the cytologic picture of the bronchial washings was squamous carcinoma Radical pneumonectomy was performed which confirmed the nature of the lung lesion

In these eighty one cases there were thirty four instances in which the cytology of the bronchial secretions was positive In six of these cases exfoliative cytology alone was able to make a diagnosis of cancer of the lung In two other cases the cytology as well as the biopsy was positive and in four cases the cytology failed to yield a positive diagnosis Bronchoscopic biopsy helped clarify the differential diagnosis in two cases by distinguishing squamous carcinoma of the bronchus from Hodgkin s disease and oat cell carcinoma from squamous carcinoma of the extrinsic larynx Two cases were established preoperatively by aspiration biopsy through the chest wall

When the cells obtained by exfoliative cytology reveal the same histologic structure as the known primary cancer elsewhere it is impossible to distinguish whether metastasis is present However the fact that carcinoma is revealed by this method is often a help in establishing the true nature of equivocal shadows This was demonstrated in five of eighteen cases in which solitary metastatic foci rather than primary carcinoma of the lung were found However for the most part metastases in the lung tend to yield scantier exfoliations than a primary malignant tumor

Biopsy at Operation In a number of instances it was impossible to make a preoperative histologic diagnosis by any clinical means therefore exploratory thoracotomy was advised This procedure is a relatively simple one has a mortality of less than 1 per cent and very little morbidity However before surgery is undertaken every effort is made to evaluate the patient s cardiac and pulmonary function so that at operation it can be judged how much functional respiratory epithelium can be removed if it is necessary

Tumors located near the hilum and seeming to arise in or immediately adjacent to the main stem bronchus (as in Case 21) can be handled in two ways (1) an aspiration biopsy of the main tumor mass can be made with the chest open and (2) a wedge of tissue can be removed from a representative area However when the clinical setting strongly suggests that [illegible] has been

provides the only means of securing a complete specimen for histologic study without incising the lesion itself thereby reducing the risk of intrapleural dissemination of infection and or neoplastic tissue The inclusion of the mediastinal lymph nodes as part of a block dissection with the lung takes little more time does not increase morbidity and improves the probabilities of removing all the gross evidences of cancer

The problem of the management of solitary peripheral lesions at exploratory thoracotomy is more difficult for if this were a primary carcinoma and the patient s reserve were adequate, radical pneumonectomy affords the best chance

for wide removal of cancer If it is a solitary metastasis one might tend to be more conservative in the amount of respiratory epithelium to be removed and thus perform radical lobectomy (Fig 3)

In an attempt to distinguish the histologic nature of these peripheral tumors wedge or segmental resection and even aspiration biopsy of these lesions has been used These methods provide a quick pathologic diagnosis and have added significance if slides of the primary lesion elsewhere in the body are available for comparison However if the patient s condition permits the aforementioned measures are usually omitted when it seems most probable that cancer is present and a radical lobectomy is performed

Reasoning in a similar vein as for the tumors of the hilum for which radical pneumonectomy was performed it is believed that these peripheral lesions should be excised *in toto* with the affected lymphatics This provides a wider and more complete excision of the tumor and a better opportunity to distinguish the character of the lung growth by preserving its relationship to the bronchial tree The inclusion of the lymph nodes implicit in radical lobectomy although not as thorough a dissection as that of radical pneumonectomy increases the probability of removing metastatic foci The reason for this is that not only primary cancers of the lung but also metastatic deposits therein can give rise to daughter or second generation metastases in the local lymph nodes On occasion after radical lobectomy has been completed if there is doubt whether or not there has been adequate excision achieved by this compromise procedure and if the condition of the patient permits a modified radical pneumonectomy can be completed

On several occasions a roentgenographic finding of a single shadow was inaccurate in that multiple parenchymal nodules were found at exploratory thoracotomy One of these is usually selected for frozen section and if this is positive for the presence of cancer nothing further need be done

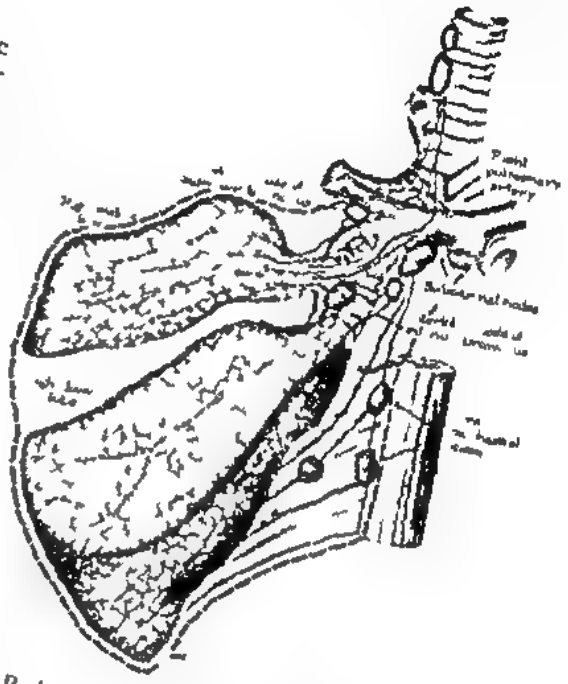

FIG 3 Right radical middle and lower lobe lobectomy is indicated by the dotted line Note how the nodes of the right paratracheal region are not included (See Figure 2 Stump of right upper lobe shown lobe omitted for clarity

HISTOLOGIC TYPES

The histologic type of pulmonary neoplasm in this series was epidermoid carcinoma in sixty three instances Five patients had adenocarcinoma of the lung four had anaplastic carcinoma two had oat cell carcinoma two had mucous gland carcinoma and two had spindle cell carcinomas One patient had terminal bronchiolar carcinoma one had extramedullary plasmacytoma and one had malignant bronchial adenoma

TREATMENT

Of the eighty one cases in this series forty two were surgically explored twenty three had simple or radical pneumonectomy and nine had either simple or radical lobectomy This is a resectability rate of about 75 per cent which is much higher than the average for operable primary lung cancer alone Undoubtedly this reflects the relatively early stage in which most of these lesions were discovered

There was one postoperative death after radical pneumonectomy and one after exploratory thoracotomy

In the thirty nine patients who were not resectable gold filtered radon seeds were inserted in and about the cancer at the time of exploratory thoracotomy and this was usually

supplemented by super voltage x ray therapy in the postoperative period

There were seven individuals who had no treatment directed to their primary lung cancer either because it was too far advanced, they were too sick or had refused specific therapy Most of these patients were dead within a three to four month period after the diagnosis was made

RESULTS

In this series of eighty one patients there were eight who survived five or more years after their lung operation Of these eight a primary cancer other than in the lung had its origin in one case each in the hard palate the extrinsic larynx and in the rectum One five-year survivor had three primary cancers of the breast colon and lung The remaining four patients had basal cell carcinomas

In this group seven had epidermoid carcinoma of the lung and one had extramedullary plasmacytoma It is interesting to note that one of these survivors had both pulmonary vein invasion and parietal pleural involvement by cancer and had had a simple upper lobe lobectomy He died of a heart attack five years later and no evidence of cancer was found at autopsy There were two other patients (Cases 38 and 45) in whom the pulmonary vein was found on the excised specimen to be invaded by the lung cancer Both of these patients have survived two years without evidence of disease so far after radical pneumonectomy in each case

Thirteen patients lived from one to four years after the pulmonary surgery six of whom are without evidence of disease at the present time

There were nine autopsies in this series each one of which confirmed the presence of separate primary cancers In two of these there was a chance finding of a second primary cancer occurring in the bladder and in the gallbladder

The interval between the development of the first and the second primary growth ranged from 0 to 18 years and there were fifteen instances in which this interval was five or more years

Oral Cavity Cancers One of the most interesting findings in this series is the occurrence of cancer in the head and neck region of thirty six patients, which is by far the largest single anatomic group Eighteen of these occurred within the oral cavity and nineteen in both the extrinsic and intrinsic larynx (eleven extrinsic eight intrinsic) One can only conjecture that this relatively high proportion of cancer in an anatomic system related to the lungs suggests a possible common etiologic agent or group of agents

Several facts have become apparent and are worth emphasizing Whenever cancers of the oral cavity or larynx occurred synchronously with lung cancer the pulmonary lesion was the first to be treated when the patient s condition permitted it This follows the principle that the more lethal disease deserves first consideration

When one of the primary cancers involved the larynx before the exploratory thoracotomy was performed elective tracheostomy was performed and anesthesia administered through it This obviated the necessity of introducing an [illegible] addition if an endotracheal tube were used without a tracheostomy the threat of occlusion of the airway by laryngeal edema in the postoperative phase is a real one Also the maintenance of good toilet of the tracheobronchial tree under these circumstances is facilitated by the use of a tracheostomy

When a patient has had a total laryngectomy and in the course of time a cough develops with or without the production of sputum it is usually interpreted as tracheobronchitis In at least three instances in this series this misinterpretation was made and it was only with increasing cough and eventually hemoptysis that a roentgenogram of the lungs was advised and the pulmonary shadow that proved to be lung cancer was observed Therefore at this institution it has become a routine for all patients who have had cancer of the oral cavity or larynx even though asymptomatic to have a roentgenogram of their lungs every six months. Should they develop respiratory symptoms at any time before this interval postero-anterior and lateral x ray chest films are taken and expectorated matter plus bronchial washings are studied for exfoliative cytology

This principle of routine x ray of the lungs as previously outlined should not be confined to those patients with oral or laryngeal cancer but should be applied to cancer arising in other anatomic sites as well The interval of six months is an arbitrary one and might be re-

duced in patients whose original cancer appears to be highly aggressive

Solitary Metastases Of the eighteen cases mentioned in which a solitary metastasis rather than primary carcinoma of the lung was found, the sites of origin included four cases with adenocarcinoma of the rectum, two with osteogenic sarcoma of the femur, one teratocarcinoma of the ovary, one leiomyoma of the uterus, one liposarcoma of the buttock, one malignant melanoma each of the gingiva, the skin of the back and the left ear lobe, one fibrosarcoma of the mandible, one papillary cystadenocarcinoma of the kidney, two rhabdomyosarcomas of the extremities, one mixed tumor of the left parotid, and one breast carcinoma

In this group there are five alive and well five years after resection, there are five dead of disease, and eight who are living without evidence of disease ranging from one month to four years

There are at least 150 reported cases of metastases surgically excised from the lung in the literature, and many of these have surprisingly long survival rates with no other metastases becoming evident

DISCUSSION

There are several points that can be made from the aforementioned data

1 Multiple primary cancers in unrelated systems can and probably will occur with increasing frequency as survival rates improve Therefore, in all patients who have had a known malignant tumor constant vigilance should be maintained, not only for evidence of the spread of metastases but also for the initiation of a new primary cancer

2 In a patient with cancer primary at an other site capable of metastasizing, the appearance of a shadow in a roentgenogram of a lung with or without pulmonary symptoms, may indicate the presence of a new primary cancer of the lung In fact, in a similar period of time at this institution there were only eighteen solitary metastases occurring in the lungs, whereas there were sixty-four separate primary cancers of the lung This would indicate that there is approximately a 3½ to 1 chance that a solitary pulmonary shadow is a separate primary lung cancer rather than a single metastatic deposit

3 The appearance in a roentgenogram of a solitary pulmonary shadow synchronous with cancer from another site known to metastasize, should not depress aggressive action in the treatment of either lesion, if each tumor is potentially controllable by established therapeutic measures In these synchronous tumors the more malignant or lethal should be treated first, if possible In most instances this will be the lesion in the lung

4 If the shadow in the lung appears metachronously with cancer at another site known to metastasize, some radiologic procedures, bronchoscopic biopsy or exfoliative cytology might aid in establishing not only the presence of cancer but also the possibility of a new primary lesion in the lung Should all these measures remain equivocal, exploratory thoracotomy should be performed for diagnostic purposes.

5 If a pulmonary lesion arises in, or is immediately adjacent to, a main stem bronchus, radical pneumonectomy is the treatment to be preferred If the lesion is more peripherally placed radical lobectomy can be performed The excision of the lymph nodes in a block dissection with the lung or lobe containing either a new primary or a metastatic focus, requires little additional surgical skill or time, adds no morbidity or mortality and improves the probability of removing all the cancer Theoretically, at present this affords a better opportunity for cure

6 At exploratory thoracotomy when the lesion is found to be non-resectable, gold filtered radon seeds may be inserted within the tumor and about its periphery, and supplemented by external radiation therapy in the postoperative period This method of treatment has produced a measure of palliation and perhaps even prolongation of life in a sufficient number of patients to encourage its further use

7 The preponderantly large association in this series between carcinomas arising in the head and neck and separate primary cancers of the lung should stimulate alertness for this possibility The same vigilance about pulmonary shadows should be maintained for cancer in other sites

8 The resectability rate of 75 per cent in this series of patients and the survival of eight for five years or more should encourage aggressive action in the treatment of multiple primary cancers.

4A 4B

FIG 4 Case 63 A and B triple primary postero-anterior and lateral views Chest roentgenograms showing opacity in right upper and middle lobes

Four cases will be described in some detail As evidence of the value of aggressive therapy the following case report of a woman who had separate carcinoma of the breast, colon and lung is of interest

CASE 63 A thirty-nine year old woman had a right radical mastectomy in May, 1941, with a pathologic report of infiltrating duct carcinoma with metastases to axillary lymph nodes at all levels Eight years and four months later adenocarcinoma, Grade II, Duke's B of the transverse colon was removed by anterior resection Two months later a shadow in her

presence of cancer without definition as to histologic type Stereoscopic views of the lungs and x rays of her skeletal system as well as other detailed laboratory studies failed to reveal any evidence of spread from the breast and colon cancers In November, 1949 exploratory thoracotomy was performed, and in the absence of other nodules, this peripherally placed

(Fig 6C) All peribronchial and mediastinal lymph nodes were negative This patient is alive without evidence of disease five years after her last procedure

CASE 19 This sixty-four year old man was first seen on February 17, 1949, with a three-month history of hoarseness, for which he received eighteen penicillin injections On laryngoscopic examination there was a large, fungating, pedunculated lesion which was 3 cm wide and 5 5 cm in length, rising on the right side of the extrinsic larynx, invading the epiglottis and right vocal cord A routine chest film showed a shadow in the left lung field, and it was suggested by the radiologist that this was compatible with primary carcinoma of the lung

two, and on March 29 1949 left radical pneumonectomy was performed (Fig 8) The pathologic diagnosis was squamous carcinoma grade II, mediastinal lymph nodes clear A gross description of the lesion showed that the cancer had its origin from the major bronchus to the lower lobe, and the mass meas

FIG 5 Case 63 Triple primary Right upper and middle lobes containing lesion (arrow)

6A 6B 6C

FIG 6 Case 63 Photomicrographs of the triple primary malignant tumors A infiltrating duct carcinoma breast B adenocarcinoma grade II of rectum C bronchogenic carcinoma terminal bronchiolar type

ured [illegible] by 4 cm At the conclusion of the pneumonectomy prophylactic tracheostomy was performed On May 11, 1949 six weeks later, total laryngectomy was performed and the pathologic specimen was squamous carcinoma grade II (Fig 9) The patient recovered from this procedure without difficulty and was discharged from the hospital two weeks later Since that time he has returned to work and was last seen on A [illegible] 1954 over five years after his two [illegible] without any evidence of [illegible]

Comment This patient is the first in whom synchronous cancer of the extrinsic larynx and the lung existed The choice of treating the more malignant tumor first resulted in radical pneumonectomy, at the conclusion of which procedure tracheostomy was performed His uneventful recovery permitted the second operation with [illegible] six week period and he has [illegible] lence of disease for five years [illegible] If it had been assumed that [illegible] lung were metastasis, x ray [illegible] been [illegible] stered to both

7A 7B

FIG 7 Case 19 A and B postero anter or and lateral cl est roentgenograms show ng shadow n left m d lung f eld posteriorly placed

FIG 8 Case 19 Spec men of left lung show ng carc noma n left lower lobe

sites, and one doubts that survival for this length of time would have been possible

CASE 41 The patient was a 65 year old white woman who was first seen on September 29 1948 presenting a history of lymphatic leukemia of five years' duration She had been treated elsewhere for the disease by roentgen irradiation radioactive phosphorus and urethane On examination there were generalized adenopathy and hepatosplenomegaly White blood count was over 200 000 with 92 per cent lymphocytes She had no pulmonary complaints but a submitted chest roentgenogram taken four months previously showed a 6 cm opacity in the right lower lung field This was reported by the radiologist as consistent with bronchiogenic carcinoma Bronchoscopy did not visualize the tumor A sputum specimen was reported as Class v Shows large masses of lymphocytes and also clusters of neoplastic cells suggestive of a malignant lung tumor adenocarcinoma in type Roentgen ray therapy to the lung lesion was begun on May 6 1949 and the patient was given 3 000 r to each of two chest portals, anterior and posterior using the 1 000 kv machine She remained asymptomatic until February 9 1950 when she complained of marked weakness nasal hemorrhages and axillary and inguinal lymph node enlargement developed ACTH was administered without avail She died on March 20 1950 At autopsy the diagnosis of terminal alveolar adenocarcinoma of the right lower lobe of the lung metastatic to liver was revealed together with diffuse evidences of lymphatic leukemia

Comment In this instance radiation therapy was selected as the method of choice for the lung lesion because the hemorrhagic propensity of patients with leukemia precluded surgical intervention

CASE 45 This patient was a fifty four year old white man who first came to Memorial Hospital on July 19 1940 with a complaint of rectal bleeding of eight months duration Biopsy of a rectosigmoid lesion 12 5 cm from the anal margin was reported to be adenocarcinoma grade II On October 24 1940 a one stage combined abdominoperineal resection was performed On subsequent follow up visits the patient was reported to be well until May 2 1949 when he complained of slight cough and bloody sputum Roentgenogram of the chest indicated the possibility of early bronchiogenic

FIG 9 Case 19 Total laryngectomy specimen (posterior view opened) showing carcinoma of extrinsic larynx in patient who had radical pneumonectomy six weeks previously (Fig 8) He is alive and well without evidence of disease over five years later

carcinoma Bronchoscopy had revealed no apparent abnormality Papanicolaou studies of bronchial washings were reported as class v Conclusive evidence of a squamous carcinoma of the lung On July 15 1949 at exploratory thoracotomy a tumor mass was found in the apex of the left lower lobe measuring about 4 cm in diameter and extending across the interlobar fissure to the left upper lobe Left radical pneumonectomy was performed and the specimen was reported as bronchiogenic squamous carcinoma—mediastinal lymph nodes clear The patient had an uneventful recovery and was without evidence of disease five years and six months later

Comment The development of metachronous lesions in this case of the rectum and lung was separated by nine years and a preoperative diagnosis of a new primary pulmonary cancer was derived from roentgenograms and bronchial cytologic studies

REFERENCES

1 ALEXANDER, J and HAIGH C Pulmonary resection for solitary metastatic sarcomas and carcinomas Surg Gynec & Obst 85 127-146, 1947
2 CAHAN W G BUTLER, F S and WATSON R B Multiple cancers primary in the lung and other sites J Thoracic Surg 21 335 348 1950

3 CAHAN, W G, WATSON, W L and POOL, J L Radical pneumonectomy *J Thoracic Surg*, 22 449–471, 1951
4 CAHAN, W G Radical lobectomy To be published
5 EFFLER, D B, BLADES, B and MARKS, E The problem of the solitary lung tumors *Surgery*, 24 917–928, 1948
6 PAPANICOLAOU, G Personal communication
7 POOL, J L, WATSON, W L and DIAMOND H D Asymptomatic intrathoracic tumors To be published
8 SPAIN, D M The incidence of multiple primary malignant tumors and a report of a case with three primary carcinomata. *New York State J Med* [illegible]
9 [illegible]
10 WALTER, S and GATES, O Multiple primary malignant tumors A survey of the literature and a statistical study *Am J Cancer*, 16 1358 1414 1932
11 WARREN, S and EHRENREICH, T. Multiple primary malignant tumors and susceptibility to cancer *Cancer Research* 4 554–570, 1944

Bronchiolar Carcinoma

CAPT CLIFFORD F STOREY M C Portsmouth Virginia

From the U S Naval Hosp tal Portsmouth Va The opin ons or assert ons contained herein are those of the author and are not to be construed as official or reflecting the v eus of the Navy Department or of the naval service at large

BRONCHIOLAR carcinoma is a rather uncom mon but highly important type of pul monary malignancy This tumor also has been referred to as alveolar cell carcinoma alveolar cell tumor pulmonary adenomatosis and by an almost endless variety of other descriptive titles Some have questioned whether all of the lesions reported under the numerous synonymous or related terms represent variants of a single entity or whether they include two or more distinct though similar tumors The best evidence appears to indicate that all of the lesions in this group represent the same neoplasm which may vary considerably in its histologic picture and clinical behavior It was formerly believed that this tumor was in variably bilateral in distribution that the lesions were always widespread in extent and that patients with this disease were faced with a hopeless outlook Fortunately, modern ad vances in diagnostic and therapeutic technics have rather clearly established the fact that this dismal prospect does not necessarily prevail On the contrary recent experience indicates that this tumor is frequently if not always localized in its early stage and that resection at this time may offer a better prog nosis than with any other lung cancer Three brief case reports* serve to illustrate certain features of this disease

CASE REPORTS

CASE 1 J J M (Reg No 109054) a thirty seven year old white man was ad mitted to the U S Naval Hospital St Albans New York in November 1949 because a routine chest x ray had shown a discrete solitary lesion in the left upper lung field He complained of a mild non productive cough of six or seven months duration which he attributed to smoking He also mentioned a slight ache in the left anterior chest which had been present for an indefinite period of time but at least for many months His present and past medical history was otherwise nega tive The family history was non-contributory Complete physical examination revealed no abnormal findings The patient did not appear to be ill Routine laboratory studies gave results within the normal range The tuberculin skin test was positive in the second strength Postero anterior and left lateral chest roent genograms revealed a round homogeneous sharply circumscribed lesion measuring 2 cm in diameter situated in the anterior segment of the left upper lobe (Fig 1) Postero anterior and lateral tomograms confirmed these findings In addition some observers thought that a fleck of calcific density could be seen in the center of the lesion on the tomograms Bronchoscopy showed no ab normalities of the tracheobronchial tree The bronchial aspirate was negative on smear for acid fast bacilli Cultures of the aspirate planted at this time were subsequently re ported as negative for tubercle bacilli Cytologic studies of the sputum and bronchial aspirate were not done Ten days after admission left thoracotomy was performed and a moderately firm spherical lesion was removed by excisional biopsy from the anterior segment of the left upper lobe On sectioning this mass did not present the gross appearance of a chronic pulmonary granuloma but suggested a tumor Immediate frozen sections were made which showed bronchiolar carcinoma (Fig 2) Careful inspection and palpation of the left lung revealed no other lesion There were no en larged or firm mediastinal lymph nodes Left upper lobectomy was performed The patient s postoperative course was uneventful His chest x rays approximately three years postopera

* These cases have all been reported in abstract form

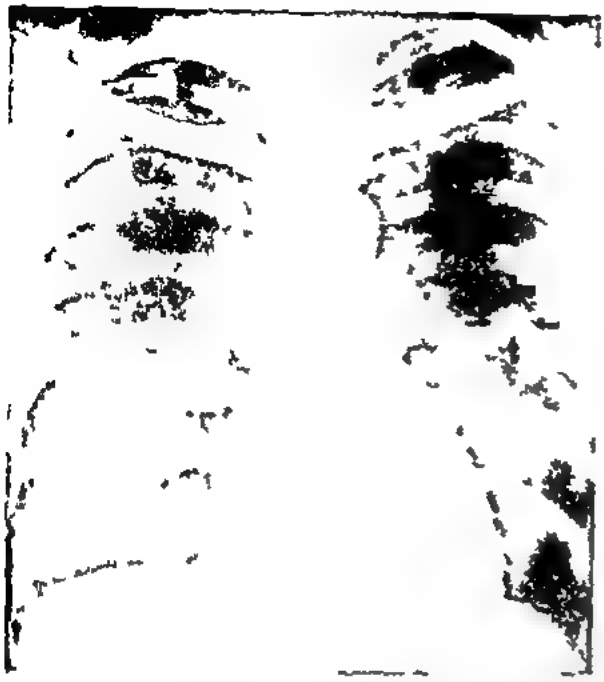

FIG 1 Case 1 Admission chest roentgenogram showing sharply circumscribed ovoid lesion 2 cm in diameter at the level of the third left anterior interspace (From Storey et al *J Thoracic Surg* 26 331 1953)

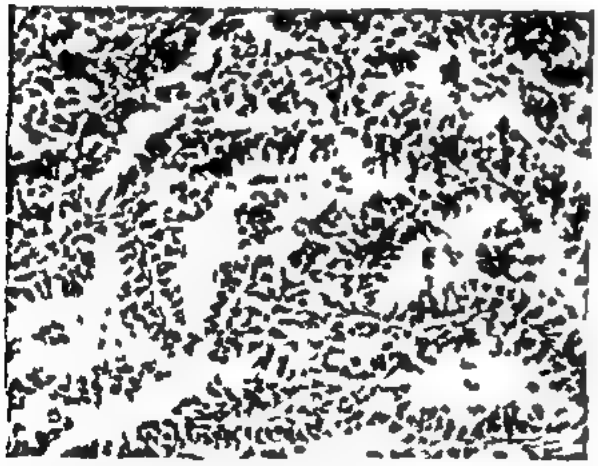

FIG 2 Case 1 Histologic section of the resected tumor showing the typical picture of bronchiolar carcinoma × 280 (Armed Forces Institute of Pathology Washington D C)

tively (Fig 3) revealed no pathologic condition At the present time, almost five years after resection, he remains clinically well His chest x rays are essentially negative and he is on active duty in the Navy

Comment Prompt resection of this patient's lesion appears to have paid dividends Time was not wasted in intensive diagnostic measures that would probably have proved unrewarding Results of sputum cultures were not awaited The cultures are usually negative

FIG 3 Case 1 Chest roentgenogram made three years after left upper lobe lobectomy There is no evidence of residual or recurrent disease

in lesions of this type even when they are of tuberculous origin Much can be said in favor of an aggressive policy with early excisional surgery in patients presenting a solitary peripheral pulmonary nodule

CASE II J N H (Reg No 116208) was admitted to the U S Naval Hospital St Albans in October, 1950 because a routine chest x ray taken at the time of induction into the service had shown a rounded lesion 2 cm in diameter in the right upper lung field (Fig 4) The patient had had a pre-employment chest x ray twenty months previously which was interpreted as negative although on review a round lesion 2 cm in diameter (Fig 5) could be clearly identified at the same site as the lesion shown on his induction film On admission the patient complained of a burning sensation beneath the right scapula of four months duration, low back pain radiating to the right leg for about four months and a dry cough for two or three months He did not appear to be ill His past medical history and family history revealed nothing noteworthy Physical examination was negative and routine laboratory studies gave results within normal limits Nothing abnormal was seen on bronchoscopy The bronchial aspirate and numerous smears and cultures of the sputum and

gastric contents were negative for tubercle bacilli Papanicolaou preparations of the sputum were suspicious of malignancy (class III) on several occasions The tuberculin skin test was positive in the weakest dilution Chest roentgenograms one month after admission showed a spread in the vicinity of the original lesion a halo of fine nodular lesions measuring 1 or 2 mm in diameter having made their appearance By December 1950 a month after this these lesions were more pronounced and similar miliary nodules could be seen in the opposite lung as well as in all lobes of the right lung The clinical diagnosis of miliary tuberculosis was made and the patient was started on therapeutic doses of streptomycin and PAS but these drugs failed to alter the course of his disease In January 1951 he was found to have a pericardial effusion (Fig 6) Pericardiocentesis was performed on two occasions 800 and 500 cc of hemorrhagic fluid being removed on the two taps Cytologic study of this fluid revealed malignant cells of an unidentified type Late in January a lung biopsy was performed through a small right anterior intercostal incision Histologic examination of the surgical specimen showed bronchiolar carcinoma The patient s pulmonary lesions showed steady progression (Fig 7) He became increasingly short of breath and died of respiratory insufficiency early in March 1951 Postmortem examination showed that widespread bronchiolar carcinoma involved all lobes of both lungs with metastases to the heart liver kidneys and spine

Comment This patient s lesion was unfortunately missed at the time of his first chest x ray examination When the peripheral nodule was noted on his chest roentgenograms twenty months later the lesion remained stable and prompt excision at that time may have afforded the chance of a cure The belief that the lesion was tuberculous in nature resulted in procrastination while an intensive effort was made to establish the diagnosis of pulmonary tuberculosis By the time the correct diagnosis was established widespread dissemination of the neoplasm had occurred making the prognosis hopeless

CASE III N L F (Reg No 248326) was admitted to the U S Naval Hospital Portsmouth Virginia on March 24 1952 in the fifth month of her first pregnancy complaining of pain in the left chest This was described as a ' pulling sensation which was aggravated by deep breathing coughing or exertion These symptoms began two months previously and had gradually increased in severity Her past medical history systemic review and family history were non contributory Physical examination showed the findings consistent with an intrauterine pregnancy of five months' duration but was otherwise unremarkable Routine laboratory studies showed no abnormalities A chest x ray taken just before admission showed multiple miliary soft tissue densities throughout both lung fields which the radiologist considered to be due to vascular shadows viewed axially Repeat chest roentgenograms in April 1952 showed that these lesions had increased in number and size and it was apparent that they represented parenchymal involvement and not blood vessels (Fig 8) The sputum and gastric washings were repeatedly negative on culture for acid fast bacilli Subsequent chest x rays taken at intervals of every few weeks showed a progressive increase in the pulmonary lesions which involved all lobes of both lungs (Fig 9) Meanwhile her pregnancy progressed normally and a healthy male infant was delivered spontaneously in August 1952 Following delivery the patient suffered increasing chest pain and shortness of breath Her vital capacity progressively diminished until November 1952 when it was 1 5 L A left thoracotomy with lung biopsy was performed in November 1952 and course continued she became markedly dyspneic and cachectic and died on July 4 1953 of pulmonary insufficiency Complete postmortem examination showed extremely extensive tumor involvement of all lobes of both lungs There were no metastases to the mediastinal nodes or other thoracic structures and no distant metastases were found at that time Because the histologic characteristics of the pulmonary lesions lacked many of the features commonly associated with malignancy and no local or distant metastases were discovered the diagnosis of pulmonary adenomatosis was established

Comment This case illustrates the vagaries of this disease The patient was a Navy nurse and had had chest x rays yearly In spite of this her lesions were bilateral and extensive at

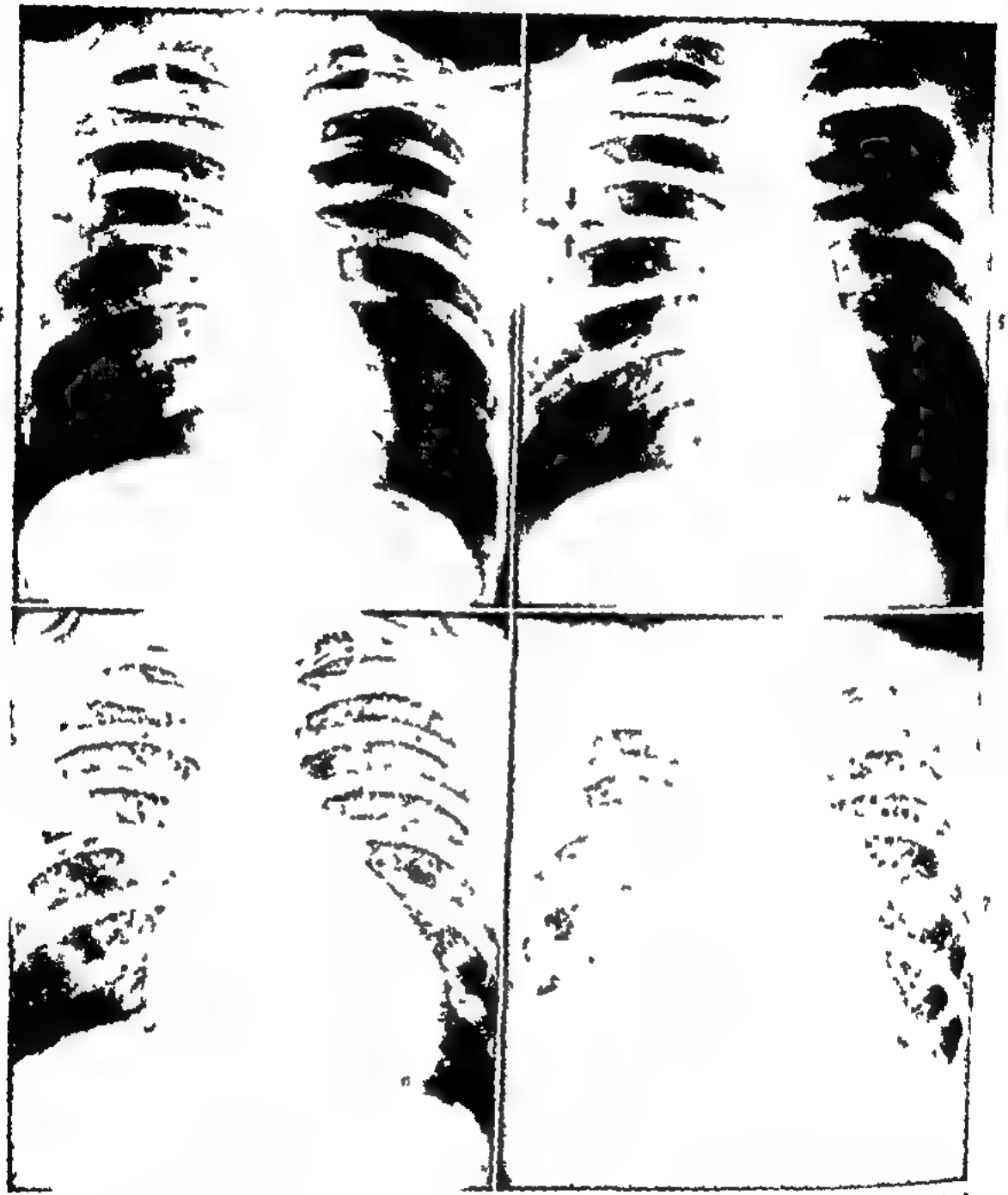

FIG. 4. Case 11. Admission chest roentgenogram showing spherical lesion situated peripherally at the level of the third right anterior interspace.

FIG. 5. Same case. Chest roentgenogram made sixteen months prior to admission. The lesion seen on the admission film was clearly visible in this x-ray and has not changed appreciably in size in the interim. (From Storey et al.: *J. Thoracic Surg.*, 26: 331, 1953.[9])

FIG. 6. Same case. All lobes of both lungs are now involved by discrete nodular lesions and a large pericardial effusion has developed.

FIG. 7. Same case. The patient's lesions have increased in size and number, and there is a fluid consolidation adjacent to the right border of the heart. (From Storey et al.: *J. Thoracic Surg.*, 26: 331, 1953.[9])

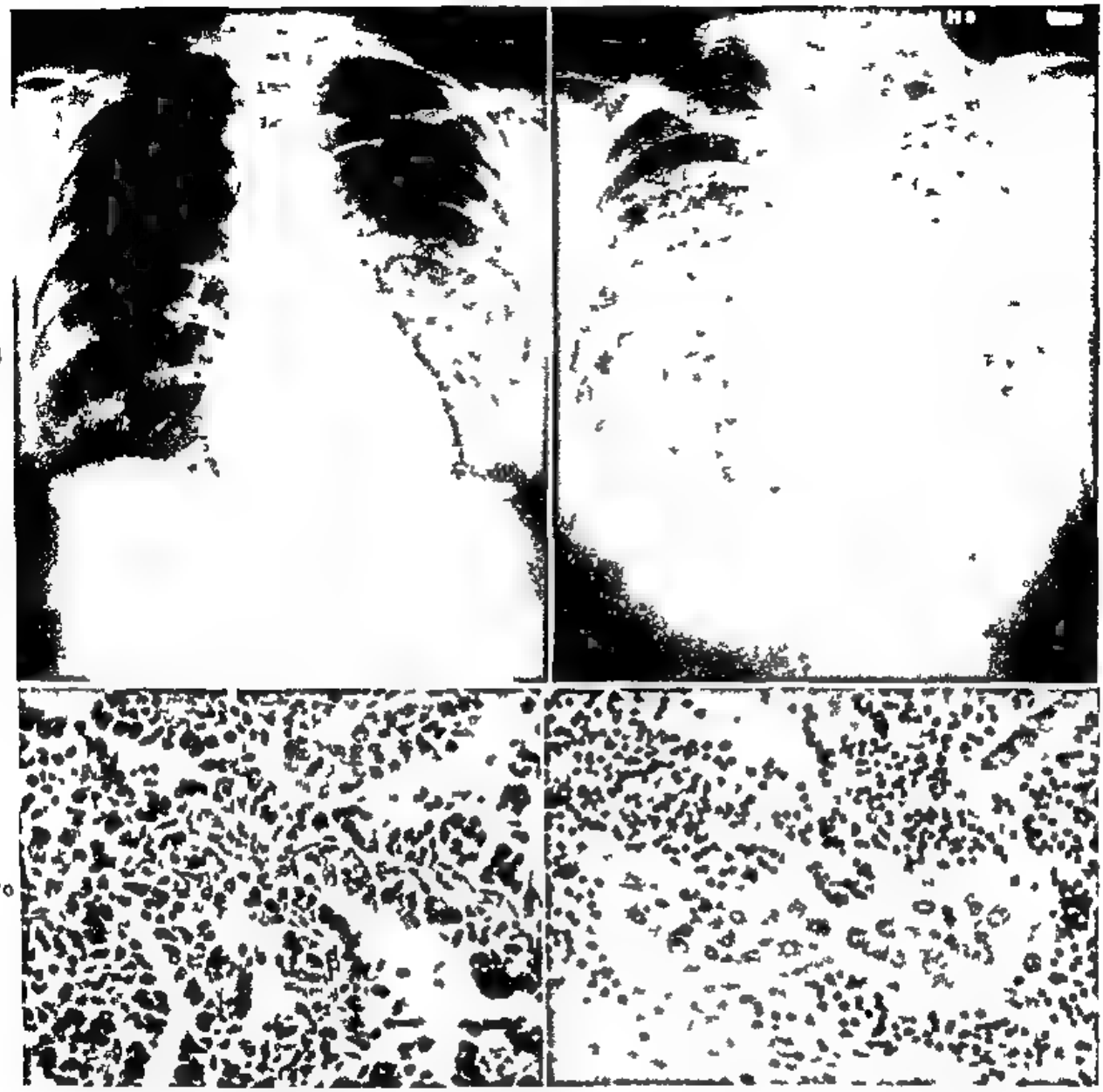

FIG 8 Case III Chest roentgenograms made about one month after admission showing many fine discrete nodular lesions involving all lobes of both lungs more prominent in the lower one-half of the lung fields

FIG 9 Same case Chest x ray made about nine months after admission showing a striking increase in the lesions

FIG 10 Same case Histologic section of lung biopsy specimen showing the typical picture of bronchiolar carcinoma X 280 (Armed Forces Institute of Pathology Washington D C)

FIG 11 Same case Histologic section which shows a metastatic tumor focus in the cerebellum X 300

the time of their discovery This case also illustrates an important point pertinent to the argument concerning benign pulmonary adenomatosis versus malignant bronchiolar carcinoma At the time of lung biopsy the diagnosis of pulmonary adenomatosis was established The diagnosis was confirmed at postmortem examination when no metastatic lesions were found in the mediastinal nodes or elsewhere However, in preparation for a Clinical-Pathological Conference over a year later new sections were made from all of the vital organs and small nests of neoplastic cells were seen along the stalk and in the capsule of the anterior lobe of the pituitary, in the cerebellum (Fig 11) in the pia arachnoid, and in one section through the lenticular nucleus The cellular arrangement was similar to that

present in the primary pulmonary lesions Some of the foci showed papillary formations Some of the tumor cells appeared to be ciliated

REMARKS

Definition We have suggested that the diagnosis of bronchiolar carcinoma" be limited to those tumors which meet the following criteria (1) a tumor characterized by alveoli lined by epithelial cells of columnar or cuboidal type with eosinophilic cytoplasm and basally placed nuclei, (2) a new growth which does not destroy the pulmonary architecture, (3) one in which there is no intrinsic tumor of a bronchus, and (4) in which there is no evidence of primary adenocarcinoma elsewhere in the body

Histogenesis The multiplicity of nomenclature applied to this tumor appears to be but a reflection of the lack of precise knowledge as to its histogenesis In this connection there are two definite schools of thought One holds that the alveoli possess an epithelial lining and that the tumor takes origin from the lining cells at this site the other contends that the alveoli are not lined by epithelium and that the lesion arises from the basal cells of the bronchioles The preponderance of evidence suggests the bronchioles as the most likely site of origin and this writer holds to that belief for the following reasons (1) There is considerable histologic evidence which indicates that the alveoli are lined by mesenchymal rather than epithelial cells (2) Carcinomas, by definition are invariably of epithelial origin (3) Bronchioles are clearly lined by epithelium and therefore could give rise to these cancers (4) Histologically, the tumor cells resemble the lining cells of the normal bronchiole (5) Microscopically, these lesions can be seen extending from bronchioles to alveoli Two recent studies emphasize strongly the relative unimportance of the arguments as to the origin of this tumor First Bracket[5] has questioned the doctrine of absolute specificity of the germ layers stating that they actually possess pluripotentiality Their actual potentiality represents what they normally become, their total potentiality what they are capable of forming under diverse natural or experimental influences Second, Waddell's[6] recent observations suggest that the bronchiolar epithelium itself may be of mesodermal origin Clinically, the important fact is that these tumors arise peripherally and whether they begin primarily in the bronchioles or the alveoli is chiefly a matter of academic interest

Etiology The cause of bronchiolar carcinoma is unknown The striking morphologic resemblance of this cancer in man to jaagsiekte an infectious disease in sheep, has frequently been pointed out It is believed that jaagsiekte is due to a virus since the disease is easily transmitted by housing infected sheep together with healthy sheep Sheep affected with this disorder have severe pulmonary symptoms with marked watery nasal discharges Histologically, the lesions seen in jaagsiekte are composed of alveoli lined by a regular layer of non ciliated high cuboidal epithelium, often papillary in nature, with prominent interstitial fibrosis Despite its clinical and histologic similarity to jaagsiekte, there is no evidence to indicate that bronchiolar carcinoma in man is an infectious disease Efforts to transmit the disease from man to laboratory animals have been unsuccessful It is true however, that a few reported cases of human bronchiolar carcinoma have been exposed to sheep ill with a pulmonary disorder, but this is a marked exception rather than the rule Certain chemical carcinogenic agents such as urethane and dibenzanthracene have produced lung cancers in mice, and the histologic structure of these induced tumors is similar to bronchiolar carcinoma as seen in man It has not been possible, however to establish a close etiologic relationship between any of the common irritants and bronchiolar carcinoma

Pathology Gross bronchiolar carcinoma consistently arises in the periphery of the lung It may present as a solitary tumor or as discrete multiple nodules varying in size from 1 or 2 millimeters to several centimeters in diameter These nodules may coalesce, giving rise to a solid tumor of considerable size which bears a striking resemblance to a stage of gray hepatization of lobar pneumonia The cut surface of the tumor varies from grey tan to yellow brown and is moderately firm Mucus often exudes from the cut surface Cavities are seen rarely Atelectasis of a major degree is distinctly uncommon but focal atelectasis is seen frequently Thorough search of the entire bronchial tree will fail to reveal a primary lesion in the bronchi When the tumor nodules are subpleural in location, they present as slightly raised umbilicated masses A pleural effusion

is not uncommon, and when present it is often serosanguineous in character

Microscopic Histologically the tumor is composed of alveoli which are lined by cells which are usually of the tall columnar type but they may be low columnar or high cuboidal The cytoplasm is eosinophilic The nuclei are round or oval and are located basally Although the tumor cells are almost invariably nonciliated, in a few cases ciliated neoplastic cells have been seen The pulmonary architecture is almost never destroyed, the tumor cells appearing to line the lumens of the alveoli and terminal bronchioles While they are usually well differentiated without anaplastic features, more malignant tumor cells are encountered occasionally and the histologic picture has been found to vary from case to case and even in different portions of the same tumor The tumor cells frequently form papillary projections within the alveoli and these papillary projections tend to desquamate into the alveoli The cells of this new growth usually produce mucin although this is by no means an invariable feature Invasion of the pulmonary lymphatics can be demonstrated in sections from over 50 per cent of the cases Small nests of tumor cells are conspicuous in the perivascular lymphatics Clusters of tumor cells are [illegible]

the slides from many cases originally diagnosed as pulmonary adenomatosis as well as a large number of histologic sections from tumors which were diagnosed primarily as bronchiolar or alveolar cell carcinoma, and no essential differences in the histologic picture have been found that would distinguish one from the other Furthermore, those diagnosed as pulmonary adenomatosis frequently were shown to metastasize within the lung, to lymph nodes and to other organs For this reason it seems clear that the term "adenomatosis," denoting a benign lesion, is no longer tenable and that all of these neoplasms should be classified as bronchiolar carcinoma

CLINICAL FEATURES

Incidence It has been estimated that this tumor constitutes between 1½ and 5 per cent of all lung cancers, and it appears that the latter figure is more nearly correct There is strong reason to believe that these tumors are frequently reported as peripheral adenocarcinoma This tumor exhibits no racial predilection It occurs with about equal frequency in men and in women The age incidence coincides with the so-called "cancer age" The average age of 218 patients recently reviewed[2] was fifty four years, and 85 per cent of patients fell in the age group between thirty and seventy years Thus the age incidence in this neoplasm does not differ materially from that of bronchial cancer

Symptoms The most common symptoms are cough, sputum production, dyspnea, chest pain, weight loss, hemoptysis, weakness, fever, anorexia and pain other than chest pain, in that order It is noteworthy that 7 per cent of the reported cases had no symptoms and represented accidental x-ray discoveries The character and degree of the cough in patients with this disorder is highly variable It is usually not of the harassing type and is commonly proportionate to the amount of sputum production These patients commonly produce clear frothy, watery sputum which becomes purulent in character only when there is a complicating secondary infection It has often been stated that this disease is characterized by the production of huge amounts of sputum, but this is not necessarily the case In a series of 218 patients it was found that 17 per cent produced no sputum and an additional 56 per cent raised less than 3 ounces daily Hence only 27 per cent of the patients raise really large amounts of sputum Hemoptysis, frequently small in amount, is fairly common in patients with this tumor Approximately one-third of them will show hemoptysis and it is not rare for this to be the initial symptom

Duration of Symptoms Bronchiolar carcinoma is most often a slowly progressive chronic pulmonary disease which is not debilitating until late in its course, it gives rise to a remarkably few systemic symptoms and usually kills by the sheer extent of the pulmonary involvement Review of a large series of cases indicates that symptoms had been present for more than six months at the time of diagnosis in over 70 per cent of the patients In 41 per cent symptoms had been present for more than a year and in 23 per cent the symptoms exceeded two years in duration Furthermore, those patients whose symptoms were of less than six months' duration included those who never had symptoms at all as well as

those who received the benefit of early excisional surgery The known duration of the disease has been extremely long in a number of cases. Instances have been reported where the known duration was at least seven or eight years, and in other cases the probable duration was as great as eleven to fifteen [illegible] is [illegible] on occurs in some cases, an indolent and protracted course is seen more often

Physical Signs The findings on physical examination are not helpful in the diagnosis of this disease In early cases examination of the [illegible] When [illegible] disease and the presence or absence of secondary infection In the presence of complications, such as pneumonia or suppurative pul- [illegible] nature of the symptomatology and physical findings in patients with this tumor is emphasized by noting the original clinical impression in patients subsequently proved to have bronchiolar carcinoma They have been diagnosed most frequently as pulmonary tuberculosis, but the working diagnosis has often been [illegible] size from a millet seed to a cherry, rounded in contour but with indistinct margins fading imperceptibly into the surrounding lung and involving all lobes of both lungs, are characteristic of this variety of lung cancer Fortunately, this is the *late* rather than the [illegible] While this picture [illegible] series of patients at the time of the first chest x-ray which demonstrated their lesion As a matter of fact, the most frequently encountered radiographic picture at the time of the patient's first chest x-ray was that of a solitary peripheral nodule, usually of small size This was the initial x-ray finding in 26 per cent of the reported cases In reality there is no roentgenographic picture that is characteristic of bronchiolar carcinoma and it may mimic any type of pulmonary disorder It has been customary in the past to divide these lesions into two types the diffuse[3] and the nodular[4] This is a purely artificial distinction, for these merely represent different stages of the same process With continued growth, the discrete nodules tend to coalesce to form solid masses Furthermore, the growth characteristics and manner of extension of this tumor vary in different [illegible] lobe or the opposite lung It is more common to find lesions of both types in a single patient than to encounter a patient in whom the lesions are exclusively nodular or one with diffuse consolidation alone More than two-thirds of the patients show unilateral lesions in their first chest roentgenograms, and in about one-half of the cases the tumor is confined to a single lobe at the time of the original demonstration of the disease Postmortem examination in the fatal cases, however, shows extensive bilateral lesions much more frequently [illegible] des [illegible] sis when Skorpil[10] performed a left upper lobectomy for a lesion which proved to be a bronchiolar carcinoma It is not surprising then to find that postmortem examination has been the most frequent method of diagnosis of this neoplasm Wood and Pierson[11] performed a lobectomy in February, 1943, for a pulmonary lesion of uncertain etiology which proved to be a bronchiolar carcinoma, and since that time seventy-five patients of record have been correctly diagnosed during life[2] Two developments account for the fact that in recent years it has been possible to diagnose this lesion at a time when it may still be amenable to treatment First among these is the aggressive use of early excisional surgery in the management of patients with solitary peripheral nodules or persistent pulmonary infiltrates of uncertain etiology A second and most promising diagnostic method is the use of the Papanicolaou exfoliative cytologic technic in the examination of the sputum of patients suspected of having bronchiolar carcinoma Papanicolaou has noted that this tumor exfoliates profusely and yields abundant material characteristic of this type

of neoplasm [12] Good and associates [13] and McDonald and Woolner[14] also believe that in certain instances cells in the sputum possess characteristics that will permit the examiner to suggest the diagnosis of bronchiolar carcinoma The typical findings consist of clumps of columnar cells with a free border of cytoplasm and fairly regular nuclei It is probable that these clumps represent groups of cells which formed papillar projections within the alveoli which have broken off and been expectorated The value of the Papanicolaou technic is strongly suggested by the report of Watson and Smith[15] from the Memorial Hospital in New York City Among a group of fifteen patients proved to have bronchiolar carcinoma the sputum was either positive or strongly suspicious of cancer in 80 per cent Other diagnostic methods include needle biopsy, lung biopsy at open thoracotomy and peripheral lymph node biopsy in patients with metastatic disease These latter methods are usually of value only in the patients with extensive and widespread disease when the diagnosis is of considerable interest but little practical importance

Metastases Metastatic lesions are present

strong support for the opinion of Watson and Smith [6] that metastases are most frequent to the same lung the opposite lung or the hilar nodes Distant spread occurs most commonly to the liver abdominal nodes, bones adrenals brain kidneys cervical nodes spleen and heart in that order of frequency Among the patients with metastases, approximately one third of them will show local spread only Another one-third of this group will show both local and distant spread while the remaining third will show distant spread only Thus roughly two-thirds of the patients with metastatic disease will show involvement of the intrathoracic lymph nodes The fact that almost one-third of the patients with metastatic disease show distant spread only demonstrates the frequency of blood borne metastases There is convincing evidence to indicate that metastases may take place by either of the following four routes (1) local invasion (2) lymphatic spread (3) blood borne metastases and (4) bronchogenic dissemination Proof that these tumors spread by local extension by the lymphatics and by the blood stream is conclusive and unmistakable The concept of aerial metastases or bronchogenic dissemination is one having important therapeutic implications There are many competent observers who believe that this tumor is of multicentric origin but this theory has never

air passages as well as by more conventional routes [2 17] The concept of bronchogenic spread of this tumor is strongly supported by the established ease with which the tumor cells and papillary tumor projections desquamate, by the findings of these cells in distant bronchi and by the relative frequency with which exfoliative cytologic studies yield positive findings Metastases to other lobes of the same lung and to the opposite lung by way of the blood stream the lymphatics and the bronchial tree strongly support the unicentric as opposed to the multicentric origin of this tumor Numerous cases may be cited to prove that it is frequently of long duration and that it often behaves in an indolent manner [2 15 20] The late appearance of apparently new lesions following resection may therefore reasonably be considered as metastases which were present but not evident at the time of surgery rather than as an example of multicentric origin

Treatment Excisional surgery is the only hopeful form of treatment for this neoplasm It does not respond to irradiation nor is it favorably affected by cytotoxic agents The peculiar growth characteristics and manner of spread of bronchiolar carcinoma suggest that conservative pulmonary resection is the treatment of choice in the majority of patients When the distribution of the disease makes such a procedure feasible the involved lobe or lobes should be removed unless there is proved or strongly suspected involvement of the mediastinal lymph nodes In that situation a total pneumonectomy and radical mediastinal lymph node dissection should be performed Otherwise pneumonectomy should be reserved for those patients in whom the distribution of the disease makes that operation mandatory The justification for conservative pulmonary resection in the treatment of this tumor lies in the fact that approximately 50 per cent of the patients will show no metastases at the time of their death Of the total group approxi

mately 20 per cent demonstrate both local and distant spread, while about 15 per cent will show distant spread only [2] Therefore, about 85 per cent of all patients with this tumor could not be permanently benefited by radical pneumonectomy as customarily employed in the treatment of bronchogenic carcinoma The remaining 15 per cent who will show only *mediastinal lymph node involvement, may or* may not be cured by such an operation One must balance this potential benefit against the likelihood of an undetected spread to the opposite lung requiring excisional surgery on that side at some future time if previous contralateral pneumonectomy has not made such an operation unfeasible

Prognosis Excisional surgery has been employed in the treatment of this neoplasm for too short a time to permit definite conclusions to be drawn as to results Among a group of fifty seven reported patients treated by resection whose reports we have reviewed,[2] thirty seven were alive from six months to more than five years postoperatively Twenty six of the thirty seven survivors were free of disease at the time of their last follow up examination Five of these patients had been operated upon more than five years previously Among five personal patients with this tumor one had extensive bilateral disease and died without definitive surgery A second patient had a recurrence five months after his original operation and a second resection was performed, however, he again has recurrent disease which will almost surely prove fatal The remaining three patients are alive and well one more than five years postoperatively, the second more than three years postoperatively and the third approximately one year after operation

SUMMARY AND CONCLUSIONS

1 The pulmonary neoplasm which has been referred to as bronchiolar carcinoma alveolar cell carcinoma alveolar cell tumor, pulmonary adenomatosis and by numerous other similar or related titles represents a single entity which varies only in its degree of malignancy in different patients or in different portions of the same lesion

2 The site of origin of this tumor has not been clearly established but the preponderance of present day opinion inclines to the belief that it arises in the terminal bronchioles and histologic studies appear to bear this out The important clinical fact that it arises peripherally has been shown conclusively

3 Although there are many who believe this lesion to be of multicentric origin convincing proof of this theory has never been offered On the contrary there is much evidence to suggest *that it arises unicentrically and spreads to* other parts of the lungs and to distant sites by direct invasion, the lymphatics the blood stream or by bronchogenic dissemination Slightly over 50 per cent of patients show metastatic lesions at autopsy It has been shown repeatedly that this tumor may behave in an indolent manner The late appearance of new lesions in the same or the opposite lung after resection of the primary growth can be more logically explained on the *basis of an* undisclosed preoperative spread than by the unproved theory of multicentric origin

4 Unfortunately there are no clinical features or roentgenographic characteristics whereby these tumors can be definitely recognized The symptoms are those of any chronic pulmonary disease and the physical findings depend upon the location character extent and distribution of the disease The radiographic picture may mimic that of virtually any type of pulmonary disorder

5 It has been stated frequently that bronchiolar carcinoma or pulmonary adenomatosis is characterized by diffuse nodular lesions involving all lobes of both lungs and by the expectoration of huge quantities of glairy mucoid sputum While this is a fair description of certain patients with this disease it is not typical of the average patient nor is it presented by those patients in whom an accurate diagnosis is therapeutically important

6 Two diagnostic methods have proved helpful in the study of patients with this tumor The most important of these is histologic examination of the resected specimen from patients who present with solitary peripheral pulmonary nodules or persistent pulmonary infiltrates of uncertain etiology A second valuable aid in these patients is cytologic examination of the sputum or bronchial aspirate by the Papanicolaou method Exfoliative cytologic studies have shown a high degree of accuracy in the diagnosis of this tumor

7 The treatment of choice of bronchiolar

carcinoma ■ conservative excisional surgery This implies lobectomy when such an operation is feasible If there is multiple unilateral lobar involvement or demonstrable mediastinal lymph node metastases total pneumonectomy and radical mediastinal node dissection become mandatory

8 Surgical treatment of this condition was begun too recently to permit conclusive statements to be made concerning prognosis Evidence is accumulating however to suggest that with early excisional surgery the prognosis in patients with this tumor may be appreciably better than in those with bronchogenic carcinoma

REFERENCES

1 LIEBOW A A Tumors of the lower respiratory tract Atlas of Tumor Pathology section V fascicle 17 p 53 Washington D C 1952 Washington Armed Forces Institute of Pathology

2 STOREY C F KNUDTSON K P and LAWRENCE B J Bronchiolar (alveolar cell) carcinoma of the lung *J Thoracic Surg* 26 331 1953

3 DELARUE N C and GRAHAM E A Alveolar-cell carcinoma of the lung (pulmonary adenomatosis Jaagsiekte?) a multicentric tumor of epithelial origin *J Thoracic Surg* 18 237 1949

4 HERBUT P A Bronchiolar origin of alveolar cell tumor of the lung *Am J Path* 20 911 1944 Alveolar cell tumor of the lung *Arch Path* 41 175 1946

5 BRACHET A Treatise on Embryology of Vertebrates 2nd ed Revised by Dalcq and Gerard Paris 1935 Masson & Cie (Quoted by OPPENHEIMER J M Non specificity of germ layers *Quart Rev Biol* 15 1 1940)

6 WADDELL, W R Organoid differentiation of the fetal lung A histological study of the differentiation of mammalian fetal lung in utero and in transplants *Arch Path* 47 227 1949

7 DUNGAL, N GISLASON G and TAYLOR F L. Epizootic adenomatosis in the lungs of sheep—comparisons with jaagsiekte verminous pneumonia and progressive pneumonia *J Comp Path & Therap* 51 46 1948

8 MUSSER J H Primary cancer of the lung *Univ of Pennsylvania M Bull* 16 289 1903 1904

9 MALASSEZ L Histological examination of a case of encephaloid cancer of the lung (epithelioma) *Arch de physiol norm et path* 3 323 1876

10 SKORPIL, F Pathology and histology of alveolar epithelial carcinoma case with atypical metastases into lymph nodes *Frankfurt Ztschr f Path* 55 347 1941 Pathology and histology of alveolar epithelial carcinoma *Zentralbl f allg Path u path Anat* 80 91 1942 1943

11 WOOD D A and PIERSON P H Pulmonary alveolar adenomatosis in man Is this the same disease as jaagsiekte in sheep? *Am Rev Tuberc* 51 205 1945

12 PAPANICOLAOU G N Personal communication to Watson and Smith [15]

13 GOOD C A MACDONALD J R CLAGETT O T and GRIFFITH E R Alveolar cell tumors of the lung *Am J Roentgenol* 64 1 1950

14 MCDONALD J R and WOOLNER L B Cytologic examination of sputum and bronchial secretion in diagnosis of bronchogenic carcinoma *Surg Gynec & Obst* 88 676 1949

15 WATSON W L and SMITH R R Terminal bronchiolar or alveolar cell cancer of the lung report of 33 cases *J A M A* 147 7 1951

16 NEUBERGER K T and GEEVER E S Alveolar cell tumor of the human lung *Arch Path* 33 551 1942

17 HUTCHISON H E Pulmonary adenomatosis and alveolar cell carcinoma *Cancer* 5 884 1952

18 WHITE J N MADDING G F and HERSHBERGER L R Alveolar cell tumor of the lung *Dis of Chest* 21 655 1952

19 SHIPMAN S J STEPHENS H J and BINKLEY F M Pulmonary alveolar adenomatosis *Am Rev Tuberc* 60 788 1949

20 BASS H F and SINGER, F Co-existing lobar adenocarcinoma and cystic disease of the lung *Ann Int Med* 34 498 1951

mately 20 per cent demonstrate both local and distant spread while about 15 per cent will show distant spread only[2] Therefore about 85 per cent of all patients with this tumor could not be permanently benefited by radical pneumonectomy as customarily employed in the treatment of bronchogenic carcinoma The remaining 15 per cent who will show only mediastinal lymph node involvement may or may not be cured by such an operation One must balance this potential benefit against the likelihood of an undetected spread to the opposite lung requiring excisional surgery on that side at some future time if previous contralateral pneumonectomy has not made such an operation unfeasible

Prognosis Excisional surgery has been employed in the treatment of this neoplasm for too short a time to permit definite conclusions to be drawn as to results Among a group of fifty seven reported patients treated by resection whose reports we have reviewed[2] thirty seven were alive from six months to more than five years postoperatively Twenty six of the thirty seven survivors were free of disease at the time of their last follow up examination Five of these patients had been operated upon more than five years previously Among five personal patients with this tumor one had extensive bilateral disease and died without definitive surgery A second patient had a recurrence five months after his original operation and a second resection was performed however he again has recurrent disease which will almost surely prove fatal The remaining three patients are alive and well one more than five years postoperatively, the second more than three years postoperatively and the third approximately one year after operation

SUMMARY AND CONCLUSIONS

1 The pulmonary neoplasm which has been referred to as bronchiolar carcinoma alveolar cell carcinoma alveolar cell tumor pulmonary adenomatosis and by numerous other similar [1]

the same lesion

2 The site of origin of this tumor has not been clearly established but the preponderance of present day opinion inclines to the belief that it arises in the terminal bronchioles and histologic studies appear to bear this out The important clinical fact that it arises peripherally has been shown conclusively

3 Although there are many who believe this lesion to be of multicentric origin convincing proof of this theory has never been offered On the contrary there is much evidence to suggest that it arises unicentrically and spreads to other parts of the lungs and to distant sites by direct invasion the lymphatics the blood stream or by bronchogenic dissemination Slightly over 50 per cent of patients show metastatic lesions at autopsy It has been shown repeatedly that this tumor may behave in an indolent manner The late appearance of new lesions in the same or the opposite lung after resection of the primary growth can be more logically explained on the basis of an undisclosed preoperative spread than by the unproved theory of multicentric origin

4 Unfortunately there are no clinical features or roentgenographic characteristics whereby these tumors can be definitely recognized The symptoms are those of any chronic pulmonary disease and the physical findings depend upon the location character extent and distribution of the disease The radiographic picture may mimic that of virtually any type of pulmonary disorder

5 It has been stated frequently that bronchiolar carcinoma or pulmonary adenomatosis is characterized by diffuse nodular lesions involving all lobes of both lungs and by the expectoration of huge quantities of glary mucoid sputum While this is a fair description of certain patients with this disease it is not typical of the average patient nor is it presented by those patients in whom an accurate diagnosis is therapeutically important

6 Two diagnostic methods have proved helpful in the study of patients with this tumor The most important of these is histologic examination of the resected specimen from patients who present with solitary peripheral pulmonary nodules or persistent pulmonary infiltrates of uncertain etiology A second valuable aid in these patients is cytologic examination of the sputum or bronchial aspirate by the Papanicolaou method Exfoliative cytologic studies have shown a high degree of accuracy in the diagnosis of this tumor

7 The treatment of choice of bronchiolar

carcinoma is conservative excisional surgery This implies lobectomy when such an operation is feasible If there is multiple unilateral lobar involvement or demonstrable mediastinal lymph node metastases total pneumonectomy and radical mediastinal node dissection become mandatory

8 Surgical treatment of this condition was begun too recently to permit conclusive statements to be made concerning prognosis Evidence is accumulating however, to suggest that with early excisional surgery the prognosis in patients with this tumor may be appreciably better than in those with bronchogenic carcinoma

REFERENCES

1 LIEBOW A A Tumors of the lower respiratory tract Atlas of Tumor Pathology section v fascicle 17 p 53 Washington D C 1952 Washington Armed Forces Institute of Pathology

2 STOREY C F KNUDTSON K P and LAWRENCE B J Bronchiolar (alveolar cell) carcinoma of the lung *J Thoracic Surg* 26 331 1953

3 DELARUE N C and GRAHAM E A Alveolar-cell carcinoma of the lung (pulmonary adenomatosis, Jaags ekte?) a multicentric tumor of epithelial origin *J Thoracic Surg* 18 237 1949

4 HERBUT P A Bronchiolar origin of alveolar cell tumor of the lung *Am J Path* 20 911 1944 *Alveolar cell tumor of the lung Arch Path* 41 175 1946

5 BRACHET A Treatise on Embryology of Vertebrates 2nd ed Revised by Dalcq and Gerard Paris 1935 Masson & Cie (Quoted by OPPENHEIMER J M Non specificity of germ layers *Quart Rev Biol* 15 1 1940)

6 WADDELL, W R Organoid differentiation of the fetal lung A histologic study of the differentiation of mammalian fetal lung in utero and in transplants *Arch Path* 47 227 1949

7 DUNGAL, N GISLASON G and TAYLOR, E L Epizootic adenomatosis in the lungs of sheep—comparisons with jaags ekte verminous pneumonia and progressive pneumonia *J Comp Path & Therap* 51 46, 1948

[illegible]

[illegible]

u path Anat 80 91 1942 1943

11 WOOD D A and PIERSON P H Pulmonary alveolar adenomatosis in man Is this the same disease as jaags ekte in sheep? *Am Rev Tuberc* 51 205 1945

12 PAPANICOLAOU G N Personal communication to Watson and Smith [18]

13 GOOD C A MACDONALD J R CLAGETT O T and GRIFFITH E R Alveolar cell tumors of the [illegible]

chiolar or alveolar cell cancer of the lung report of 33 cases *J A M A* 147 7 1951

16 NEUBERGER, K T and GEEVER, [illegible] Alveolar cell tumor of the human lung *Arch Path* [illegible] 551 1942

17 HUTCHISON H E Pulmonary adenomatosis and alveolar cell carcinoma *Cancer* 5 884 1952

18 WHITE J N MADDING G F and HERSHBERGER, L R Alveolar cell tumor of the lung *Dis of Chest* 21 655 1952

19 SHIPMAN S J STEPHENS H J and BINKLEY F M Pulmonary alveolar adenomatosis *Am Rev Tuberc* 60 788 1949

20 BASS H E and SINGER, E Coexisting lobar adenocarcinoma and cystic disease of the lung *Ann Int Med* 34 498 1951

93

Metastatic Tumors

EMIL A. NACLERIO, M.D., *New York, New York*

THE lung is a common site for metastasis from primary malignant tumors originating elsewhere in the body. The incidence of metastasis to the lung is significantly greater than primary bronchogenic carcinoma. This is not surprising when it is realized that (1) the pulmonary capillary bed acts as a filter for tumor emboli and (2) a rich supply of lymphatic channels exists which connect the lung with the mediastinum and adjacent structures.

Until recently it was considered that the outlook for these patients was hopeless and any efforts at treatment were futile. Today palliation can be achieved in selected patients by the use of radiation therapy, radioisotopes and chemotherapeutic drugs. Alleviation of pain and cough, retardation of the metastatic growths and subsidance of malignant effusions are a few of the desired goals. In isolated cases in which the primary lesion has been controlled the surgical removal of a solitary metastasis to the lung proves beneficial and can prolong life.

Inasmuch as early metastases to the lungs are usually clinically silent and because approximately 30 per cent of all metastases are found in the lungs, it becomes apparent that x-ray examination of the chest often reveals the presence of the disease. For these reasons it can be categorically stated that no patient harboring cancer should be subjected to a major surgical procedure without careful radiologic examination of the chest.

FREQUENCY OF METASTATIC TUMORS IN THE LUNGS

It is necessary to mention that involvement of the lungs by contiguity either from a primary or secondary growth is not metastasis. Only tumor emboli which have arisen from the primary growth as detached, transported fragments of that tumor are entitled to be called metastasis.

An approximate incidence of the most frequent of primary malignancies metastasizing to the lung can be best obtained from figures of necropsies. Lee,[1] in a review of 465 cases, found lung metastases in nearly 22 per cent of all autopsies in cases of cancer. Willis[2] in a personal series of 500 necropsies, found pulmonary metastases in 29 per cent of the cases. In an extensive review of over 1,303 cases Turner and Jaffe[3] found pulmonary metastases in 26.6 per cent of the cases. In a more recent study of 1,000 autopsies of cancer patients Abrams and his associates[4] found an incidence of lung invasion in 46.5 per cent of the cases. These studies indicate that if a patient has a malignancy, there is at least one chance of four of the presence of a metastatic lesion in the lung. Table 1 shows the relative frequency of metastases to the lung from malignancies of the various organs as cited by the foregoing authors.

TABLE 1
INCIDENCE OF METASTASES TO THE LUNG FROM MALIGNANCIES OF VARIOUS ORGANS

Primary Growth	Metastases to the Lung (%)		
Renal carcinoma	5	40	61
Osteosarcoma	73		
Fibrosarcoma and liposarcoma		34.5	
Choriocarcinoma	75		
Carcinoma of thyroid	65	60	
Malignant melanoma	60	62.5	
Carcinoma of breast	55	62	[illegible]
Oropharyngeal carcinoma	30	22 (approx.)	
Esophageal carcinoma	20	25	
Carcinoma of stomach	20	16.8	31.8
Carcinoma of liver	20	35 (approx.)	
Carcinoma of pancreas	20	25	34
Carcinoma of colon		21.2	3[illegible].3
Uterine malignancy	15	43.[illegible]	
Ovarian carcinoma	10	13	11
Author	Willis[2]	Turner and Jaffe[3]	Abrams et al.[4]
No. of necropsies	500	1,303	1,000

PATHOGENESIS

Tumor cells which originate from different parts of the body may gain access to the lungs

by (1) invasion via the blood stream (2) lymphatic spread, (3) direct extension (4) aspiration and (5) coelomic spread The organs or tissues in which these emboli originate may be more easily suspected if the possible routes of metastases through the blood and lymph are kept in mind

Invasion of Blood Stream Metastases via the blood stream are predicated upon malignant invasion of a contiguous major venous channel with embolic transport of the tumor cells These cells enter the caval system pass the right heart the pulmonary arteries and finally lodge in the capillaries The capillaries act as the filter for almost all of the systemic venous tumor emboli These entrapped cells may then multiply to set up subsidiary growths in the lung

It is possible that metastases to the lung may travel by way of the bronchial arteries Willis[2] suggests this explanation for the scattered discrete metastases in both lungs occasionally found accompanying a primary growth in one lung The emboli in this case enter the bronchial arteries via the pulmonary veins and left heart

Metastases occurring in the liver may serve as a relay station for further embolization to the lungs either by way of direct invasion of the vena cava or by involvement of the efferent hepatic veins Cancer emboli destined for deposit in the liver reach this organ chiefly by way of the portal vein Primary cancers of the viscera or tissues in the portal region of venous drainage (i e the lower esophagus stomach gallbladder pancreas small intestine colon and rectum) are the common sources of such emboli Cancers metastatic to these viscera may drain secondarily into the liver and then migrate to the lung

Cancer cells also reach the lungs through the thoracic duct and large lymph trunks which enter the caval system

Of interest is the phenomenon of systemic venous metastases without metastases to the lung This is exemplified in the occurrence of limited vertebral involvement secondary to cancer of the prostate breast or thyroid This phenomenon has been adequately explained by Batson[4] He has demonstrated that a collateral circulation exists between the veins of the chest, abdominal wall and vertebral column The vertebral veins lie outside the thoracoabdominal cavity and communicate with the intercostal veins the veins of the abdomen and the azygos system of veins The latter communicates freely with the posterior bronchial veins and the veins draining the parietal pleura With cough or strain the pressure in this valveless low pressure system is raised sufficiently to shunt the blood flow from the azygos channels into the vertebral system The pressure of this paravertebral collateral circulation may serve to explain the high incidence of intracranial metastases without pulmonary involvement

Lymphatic Spread Cancer cells not infrequently metastasize to the lungs by means of lymphatic permeation or extension While spreading successive chains of lymph nodes become involved With the invasion of the mediastinal or hilar lymph nodes the lungs may become involved by direct extension as well as through the medium of retrograde lymphatic spread Whether the lungs are involved by retrograde extension from the hilar lymph nodes (along peribronchial and subpleural lymphatics) or whether the tumor cell invade the lungs initially by way of the pulmonary arteries (going across to the lymphatics and then spreading to the hilar lymph nodes) is still not entirely clear[4]

There are numerous large lymphatic path ways connecting the lungs and the structures around the diaphragmatic crura Cancers from these structures (namely liver adrenals and the celiac and lumbar groups of lymph nodes) can easily invade the lungs

Direct Extension Invasion of the lungs by contiguity usually occurs from primary lesions in the adjacent structures Tumors of the chest wall especially carcinoma of the breast and lesions of the musculoskeletal structures may extend directly into the lungs In addition, neoplastic pleural implants and malignant infiltrations of the diaphragm regardless of origin invariably invade the lung

Aspiration Aspiratory spread is a possible method of metastasis of tumors on the surface of the oropharynx and trachea to the lungs[2]

Coelomic Spread Local spread through the pleural cavity is frequently observed in both primary and secondary tumors of the lung

DIAGNOSIS

In most instances pulmonary metastatic carcinoma is easy to diagnose Often pulmonary metastases are merely a part of late generalized

spread and have little clinical importance Less frequently they occur as metastases and may be mistaken for primary growths of the lung or some other lesion of the lung On occasion even with the knowledge that an extra pul monary carcinoma has been previously re

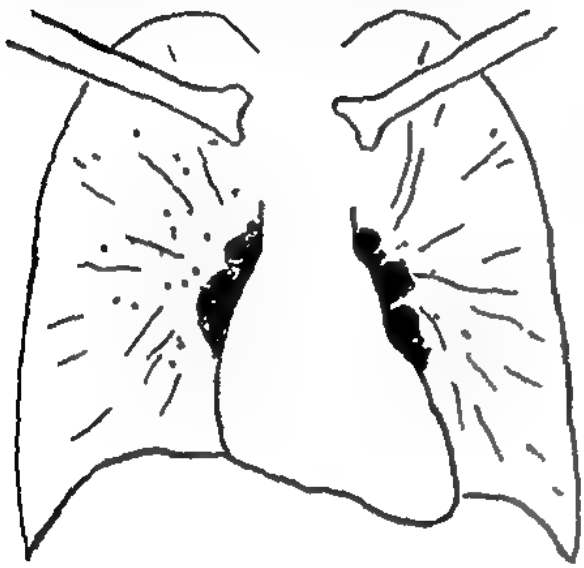

FIG 1 Miliary pattern

moved the presence years later of an isolated metastasis of the lung may be most difficult to diagnose Sometimes the existence of a shadow in the lung field and a known primary carcinoma elsewhere creates a most serious problem in diagnosis and an attitude of de featism on the part of the physician It has been shown in these situations that there is a 3 to 1 chance that a solitary pulmonary shadow is a separate primary cancer of the lung rather than a single metastatic deposit This problem of multiple primary cancers originating in different organs is discussed in detail in the chapter entitled Lung Cancer Associated with Cancer Primary in Other Sites

There is no clinical pattern characteristic of pulmonary metastasis The early lesions are almost invariably silent and are often revealed unexpectedly by x ray examination As the lesions progress the patient presents one or more of the following symptoms weakness loss of weight cough shortness of breath and pain in the chest

Small hemorrhages may occur in the later phases Profuse hemoptysis is encountered in patients with metastatic chorio-epithelioma[7]

Expectoration of mucopurulent material may be indicative of abscess formation the result of central necrosis of the parenchymal mass

Dyspnea is usually associated with paren chymal lesions which extend to the pleura to produce an effusion Shortness of breath also may be caused by extensive neoplastic invas on of the lung pressure on the trachea and bronchi and secondary infection of the already

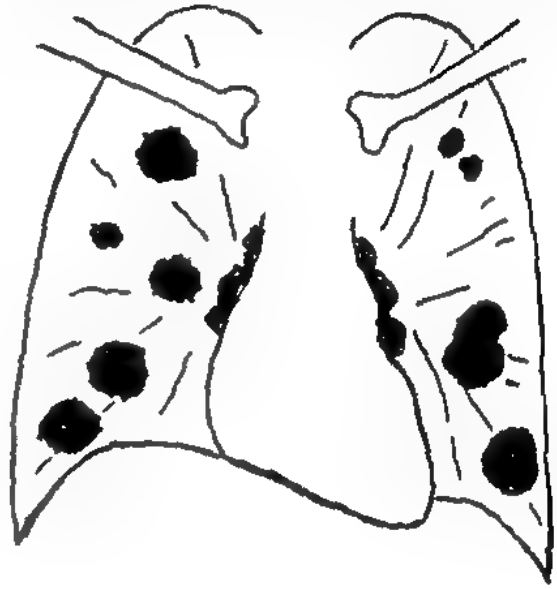

FIG 2 Nodular pattern

involved areas of lung by neoplastic tissue Severe respiratory distress associated with cerebral manifestations usually occur as part of the syndrome which develops when the superior vena cava is compressed by tumor tissue The clinical syndrome has been seen in patients with carcinoma of the thyroid breast ovary and testicle and in the malignant lymphomas[8]

Fever is common in the presence of com plicated pulmonary infection In the advanced stages as a result of intoxication malaise anorexia considerable loss of weight and even dehydration become evident

Clinically and roentgenologically metastatic tumors of the lung may mimic almost any con dition that involves the bronchopulmonary system Not infrequently lesions of the med astinum and abnormalities of the chest wall an diaphragm and even disturbances of the heart are to be included in the differential diagnos of pulmonary metastases

Numerous attempts have been made to classify the x ray appearances of metastatic lesions to the lung into various patterns The le sions can be conveniently classified in the follow ing categories miliary nodular lymphangitic and pneumonic with or without cavitation

The miliary form (Fig 1), a rare pattern commonly referred to as miliary carcinosis, is characterized by numerous and widely distributed densities The densities range in size from those just visible to those a few millimeters in diameter Variation in size of the solitary and multiple round densities These lesions are listed in a table on page 108

The lymphangitic form (Fig 3), an uncommon pattern is characterized by diffuse stringlike strands which radiate from the hilum The fine strands gradually extend on both sides and

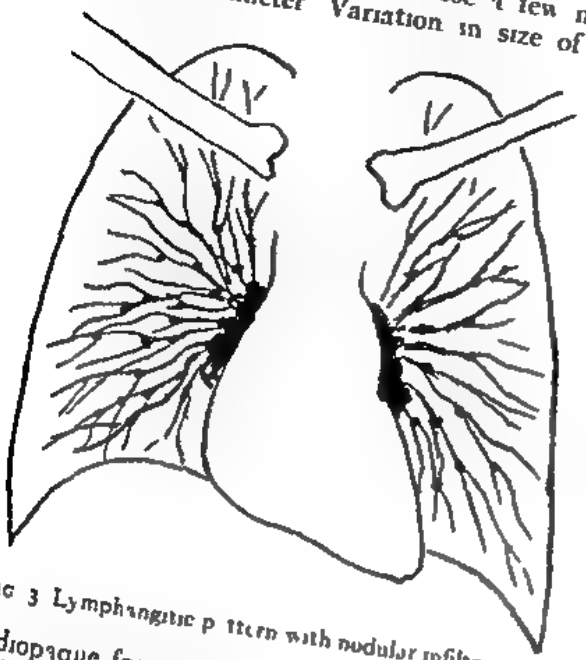

FIG 3 Lymphangitic pattern with nodular infiltration

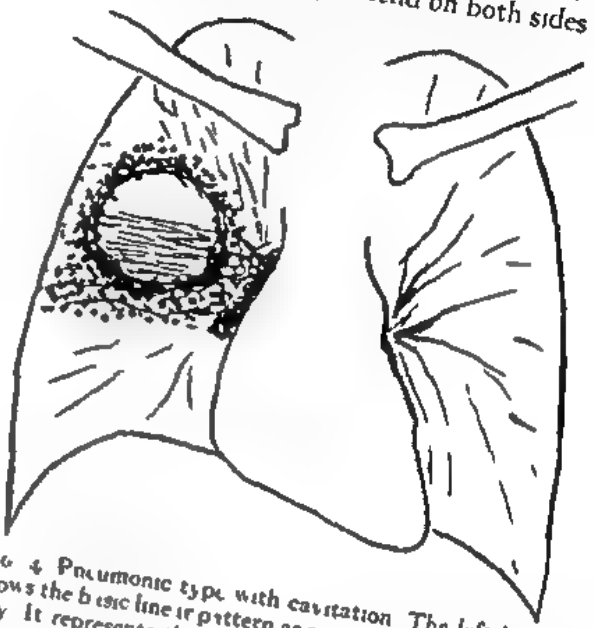

FIG 4 Pneumonic type with cavitation The left lung shows the basic line or pattern as seen roentgenographic ally It represents the normal lung structure for which the anatomic term *bronchovascular markings* is used

radiopaque foci may be an indication of multiple metastatic episodes Miliary carcinosis roentgenologically indistinguishable from miliary tuberculosis Other conditions which are to be considered in the differential diagnosis of miliary lesions are listed on page 107

The nodular form (Fig 2) consists more or less of rounded densities which are fairly well circumscribed The size ranges from less than 1 cm to several centimeters in diameter The densities may be single or multiple and of unequal size The pattern most frequently encountered is the multiple nodular type in which the nodules are most numerous as a rule in the lower lobes but may occur in any portion of the lung Lesions of the thyroid, stomach, colon and ovary, and chorio-epithelioma and malignant melanoma predispose to nodular formation Carcinomatous infiltrations are small more irregular in outline and less uniform in density than those produced by sarcoma, whereas sarcomatous metastases usually are larger and sharply outlined Hypernephroma, seminoma and sarcoma usually take the form of huge rounded densities hence the designation "cannon ball" or "golf ball" metastasis This form must be differentiated from the numerous lesions which give rise to the lung fields become opaque The lymphatics are found to be thickened due to the solid strands of carcinoma In addition, small nodules are prone to develop along these strands, in the film there will be fine densitions strung along the network of pulmonary markings This form may be the result of metastases from a distant organ or from the lung itself Approximately 70 per cent of the cases are secondary to gastric carcinoma This condition must be differentiated from the numerous lesions which give rise to linear radiopacities These lesions are listed on page 106

The pneumonic pattern (Fig 4) may be the result of neoplastic invasion or compression of the bronchi, or the involvement of lung parenchyma by tumor tissue Consequently, secondary changes may develop, e g, atelectasis, pneumonitis, abscess formation and bronchiectasis Differentiation from primary bronchogenic carcinoma by x ray may be virtually impossible. This pattern must be differentiated from the numerous lesions which give rise to radiopacities, conforming to segmental or lobar configuration (See page 110) Despite adequate roentgenograms of the

chest a significant number of metastases are missed In performing 100 autopsies on patients with pulmonary metastases, all of whom had had chest x-rays within three weeks before death Lee[1] found forty cases in which the pulmonary *metastases were not radiographically* apparent, even in retrospective review of the x rays Rigler[11] emphasizes that when metastatic nodules are less than 2 mm in diameter or when miliary nodules are not numerous, they may not be seen in the x ray film

Differential diagnosis of pulmonary metastases can be made by taking a complete and correlated history as well as complete physical examination, x-ray studies, skin sensitivity tests, cytologic examination of the sputum, bronchial washings, gastric lavage and biopsy studies Bronchoscopic examination proves valuable when bronchial symptoms are present As early as 1932[12] and in 1936[13] Vinson and co-wor[illegible] sis of [illegible] man[14] [illegible] f bronchial involvement in 109 autopsy specimens of pulmonary metastatic malignancy

Higginson,[15] in a series of thirty-five cases, proved involvement of a bronchus of major or segmental caliber in nine instances In eight of these cases (22 8 per cent) bronchoscopic biopsy was positive

In certain cases radioisotope tracer technics can be of service in detecting metastases to the thyroid In selected patients exploratory thoracotomy is justified if all other examinations are non diagnostic

If metastatic pulmonary malignancy is strongly suspected, every attempt should be made to rule out carcinoma or sarcoma elsewhere in the body Certain primary malignancies with a tendency to metastasize to the lung prevail in specific age groups The common offenders in children up to the age of eight are Wilms' tumor and neuroblastoma In older children malignant tumors of the bones and malignant lymphomas predominate In patients between thirty and forty years of age a tumor of the testis or malignant melanoma should be suspected In patients over forty years of age one may discover cancer of the breast and cancer of the stomach

TREATMENT

Patients with pulmonary metastases too often are treated rather haphazardly A signifi- [illegible] nf useful life and occasionally prolongs life

An active and a more positive approach *is needed in the management of these patients*, particularly when definite symptoms are present Therapy should include the utilization of (1) specific measures and (2) supportive measures

Specific therapy refers to the use of agents and specialized procedures which have the ability of destroying the cancer or inhibiting its growth These measures include radiotherapy, utilization of radioisotopes, nitrogen *mustard, triethylene melamine and related* compounds, and hormonal control procedures of value in metastatic breast and prostatic carcinoma

Supportive therapy refers to the management of the many problems which may arise The more common ones are pain in the chest, cough, dyspnea, anoxemia, cor pulmonale, recurrent collection of pleural fluid and findings of superior vena caval obstruction In a significant number of patients a miscellaneous group of complications occur They are nerve paralyses, esophageal invasion, myocardial invasion, etc As a result nf the extension of the disease, in many cases the clinical *picture* changes constantly, and unless the patient is closely observed and the specific causes are uncovered, we can expect little effect from the medications we employ Infinite patience and a desire to offer these patients adequate psychotherapy will prove of utmost value.

The specific and supportive measures used in the treatment of patients with metastatic tumors of the lung are discussed in the chapters entitled "Treatment of Inoperable Pulmonary Cancer, Primary and Metastatic" and "*Radioisotope Therapy*" *These measures* are mainly palliative

Evidence is accumulating in support of surgical removal of solitary metastatic tumors of the lung Isolated efforts to treat these lesions were made as early as 1926 when Davis[16] *performed a "pulmonary resection"* for metastatic sarcoma, primary in the breast

An outstanding case report of extirpation nf both a primary malignant tumor and the associated solitary metastasis to the lung was recorded in 1939 by Barney and Churchill[17] Churchill performed a subtotal lobectomy for

a metastatic nodule from carcinoma of the kidney removed fifteen months previously Five months before nephrectomy the lung nodule was the first evidence of illness in this patient Twelve years after lobectomy the patient was still alive without evidence of disease

In 1950 Seiler and associates[18] reported sixty-two cases of pulmonary resection for metastasis, fifty two gathered from the world literature and ten performed at the Mayo Clinic In this series the primary tumor was sarcoma in 32 per cent and carcinoma in 68 per cent The most commonly removed metastatic lesions were carcinoma of the large bowel (eleven), hypernephroma (seven), fibrosarcoma (seven) and carcinoma of the ovary (five) In a significant number of cases the metastatic lesion was found to be invading a major bronchus Twenty three of sixty-two patients (37 per cent) were living and apparently well at the time of the report, two patients had survived ten years or longer, and seven more had survived periods ranging from three to ten years

Kergin,[19] in 1954 and Higginson in 1955[15] reported a series of pulmonary resections for metastatic tumors It can be concluded, on the basis of a thorough review of the literature, that surgical excision of a solitary metastatic lesion of the lung is indicated in certain cases in which the primary tumor apparently has been completely removed and in which there is no evidence of further metastatic spread In these cases resection of lung by local excision, segmental repair or lobectomy is justifiable In some instances pneumonectomy may be the treatment of choice

Before plans are made to perform thoracotomy for a presumptive solitary metastasis in the lung, it is mandatory that the lung fields are critically studied by tomography, postero anterior and lateral views This procedure on numerous occasions has revealed smaller discrete foci in the same or contralateral lung which were not encountered in the conventional chest film The use of tomographic studies will avoid the performance of unnecessary surgery in a significant number of patients

SUMMARY

1. The incidence of pulmonary metastases as obtained from figures of necropsies is presented

2 The avenues by which tumor cells gain access to the lungs are briefly discussed

3 Diagnostic criteria with emphasis on roentgen patterns are stressed, and differential diagnosis of pulmonary metastases is considered

4 The management of these patients includes the utilization of specific and supportive measures

REFERENCES

1 LEE I N Pulmonary metastases *Dis of Chest*, 30 85 1956.

2 WILLIS, R A The Spread of Tumors in the Human Body St Louis, 1952 C V Mosby Co

3 TURNER J W and JAFFE, H L A clinical and roentgenological study of involvement of skeleton and lungs *Am J Roentgenol*, 43 479, 1940

4 ABRAMS, H L, SPIRO, R and GOLDSTEIN, N Metastases in carcinoma, analysis of 1,000 autopsied cases *Cancer*, 3 74, 1950

5 BATSON, O V The functions of the vertebral veins and their role in the spread of metastasis *Ann Surg*, 112 138, 1940

6 RUBIN E. The Lung As a Mirror of Systemic Disease Springfield, Ill, 1956 Charles C Thomas

7 BANYAI A L Non Tuberculous Diseases of the Chest Springfield, Ill, 1954 Charles C Thomas

8 MAYER, E and MAIER, H C Pulmonary Carcinoma-Pathogenesis, Diagnosis and Treatment New York, 1956 New York University Press

9 SANTE, L R The Chest, vol 31 New York, 1931. Paul B Hoeber, Inc

12 VINSON, P B and MARTIN, W J, JR Pulmonary metastasis from hypernephroma diagnosed by bronchoscopy *Arch Otolaryng*, 15 368, 1932

13 MAYTUM, C. K. and VINSON P B Pulmonary metastasis from hypernephroma with ulceration into a bronchus simulating primary bronchial carcinoma *Arch Otolaryng*, 23 101, 1936

14 KING, D S and CASTLEMAN, B Bronchial involvement in metastatic pulmonary malignancy *J Thoracic Surg* 12 305 315, 1943

15 HIGGINSON, J F A study of excised pulmonary metastatic malignancies *Am J Surg*, 90 241–252 1955

16 DAVIS, G Ein Beitrag zur operativen Behandlung der Lungengeschwulste *Acta chir Scandinav*, 62 329-341, 1927

1950

19 KERGIN, F G The treatment of secondary tumors of lung *Surg, Gynec & Obst*, 99 115–117, 1954

94

Sarcoma

THEODORE H NOEHREN, M D, *Buffalo, New York*

INCREASED interest and knowledge of pulmonary tumors in recent decades have altered many of the traditional concepts of these entities At the turn of the century, for example, sarcoma of the lung was considered the most common primary pulmonary malignancy, but that was when lung tumors of any type were considered rare Today, however, the picture is almost reversed While bronchogenic carcinoma is recognized for its frequency, primary sarcoma of the lung is considered by some to be almost non existent It is a rare entity, occurring in a ratio of one in 7,272 autopsies from the University of Kansas Hospitals, an incidence of 0 014 per cent [1] In 1936 Mallory[2] listed it among the rarest of tumors, reporting the first one in over 8,000 autopsies at the Massachusetts General Hospital Since then, however, three more cases have been published from that institution Reports of cases of sarcoma of the lung continue to appear in the literature[3,4] and it is probable that even *more cases are seen which are not published* Whether this indicates an increasing incidence of this tumor cannot be determined at this time

In a recent study of thirty-five cases of primary sarcoma of the lung[5] an attempt was made to define the *clinical characteristics* of this entity The group included the following primary types spindle cell sarcoma fifteen, fibrosarcoma six, lymphosarcoma five, osteoid chondrosarcoma one, mixed cell sarcoma one, reticulum cell sarcoma one, "round" cell sarcoma one, leiomyosarcoma one, chondrosarcoma one, plexiform sarcoma one, myosarcoma one and "sarcoma" one No attempt was made to analyze the clinical picture for each *of the various types of sarcoma* It was thought that while this may eventually be helpful and although reports by some authors[6] strongly support individual characteristics for some types, a larger number of cases will be necessary to evaluate this

Probably the most significant consideration is to determine whether or not any distinguishing *diagnostic characteristics can be found* for sarcoma of the lung To assay this, the clinical findings in patients with this type of tumor will be presented in comparison with the clinical findings in a representative collection of

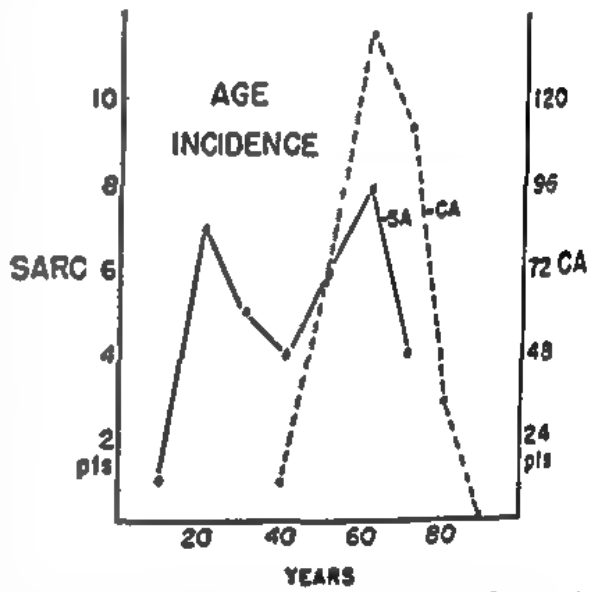

FIG 1 The comparative age incidence of primary sarcoma and carcinoma of the lung

pulmonary carcinomas reported by Moore.[7] His cases represent the experience with bronchogenic carcinoma at the Presbyterian Hospital in New York City for the years 1940 through 1949

Age It has frequently been assumed that primary sarcoma of the *lung occurs in* the earlier decades It is apparent that there is a difference in the age incidence of the two types of tumors, but considerable overlap occurs (Fig 1)

Sex Ratio. It is suggested from Figure 2 that both types of pulmonary tumor are more common in males, although the preponderance is not so great in the sarcoma patients Furthermore, in the sarcoma patients this apparent sex difference is not statistically significant in a series of only thirty-five cases

Symptoms In two of the patients with sarcoma of the lung there were no symptoms, the lesion having been found on routine roentgenographic study One of these, a lymphosarcoma, replaced the entire left upper lobe This was the only case in the series which

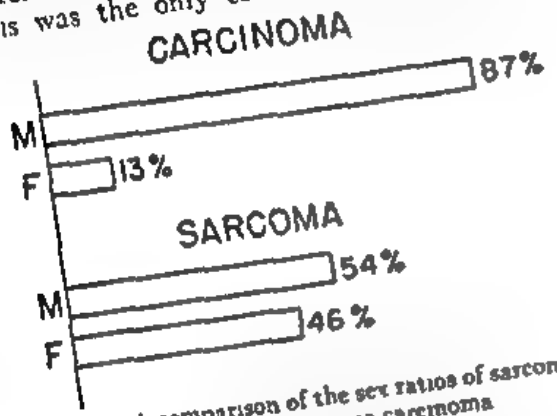

FIG 2 A comparison of the sex ratios of sarcoma of the lung and bronchogenic carcinoma

corresponded to what previous authors have described as the classic picture of sarcoma a large slowly growing silent tumor The other silent mass, also a lymphosarcoma was an isolated lesion in the right lower lobe and measured 8 cm in diameter (Table 1)

TABLE 1
COMPARISON OF SYMPTOMS IN SARCOMA AND BRONCHOGENIC CARCINOMA

Symptoms	Carcinoma Per cent)	Sarcoma (Per cent)
Cough	78	74
Hemoptysis	51	43
Weight loss	49	49
Chest pain	49	43
Fever	30	43
Pneumonitis	20	26
Weakness	17	26
Dyspnea	16	7
Wheeze		

Roentgen Appearance Chest roentgenograms of patients with sarcoma of the lung range from a perfectly normal roentgenogram through the many varieties of pulmonary tumor manifestations In some cases the roentgenogram demonstrated no evidence of a tumor In others solitary nodules, either regular or irregular in outline, large space-filling masses atelectasis, cavitation, pleural effusion pneumonitis multiple densities, hilar enlargement and in one case a mass containing calcium were found Tumor growth rate as determined by serial roentgenograms was of little or no value in differentiating this type tumor from bronchogenic carcinomas The roentgen appearance, then, is not diagnostic and there is no consistent characteristic appearance of sarcoma in the lung

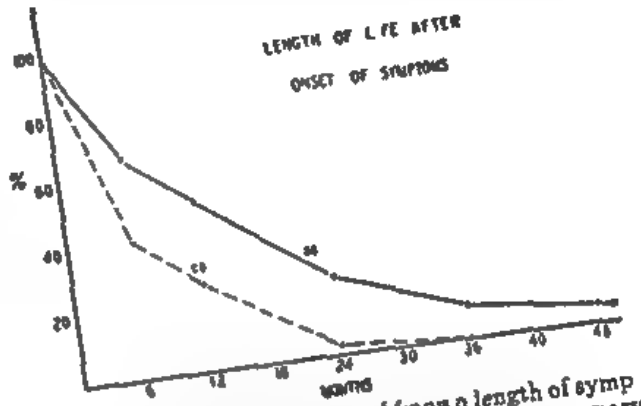

FIG 3 A comparison of the total known length of symptoms in twenty two patients who died of primary sarcoma of the lung with thirty three cases of "untreated bronchogenic carcinoma

Longevity Patients with primary sarcoma of the lung demonstrated a relatively greater longevity than did those with bronchogenic carcinoma The one case of sarcoma graphed as still living at forty eight months died fifty nine months after the onset of symptoms (Fig 3)

Treatment Of the total thirty five cases of sarcoma of the lung eighteen or 48 5 per cent, were amenable to surgical procedures This compares with 24 per cent resectability in Moore s series of bronchogenic carcinoma It is to be noted that in four cases the tumor could be removed at thoracotomy without sacrificing lung tissue It is also of interest that in two instances fulguration at bronchoscopy was at least temporarily adequate and in a third the patient herself coughed up the tumor with no further evidence of the sarcoma four years later Follow up for various periods showed that 59 per cent of the postoperative patients were still alive

Pathology Of eighteen cases in which post mortem examinations were performed, metastases were found in ten and no metastases were found in eight The distribution of these metastases included eight (one questionable) to the lungs, two each in the local nodes, kidney, spleen and liver one each in the brain, diaphragm and heart and one (questionable) to the spine

COMMENTS

The findings in thirty-five cases of sarcoma of the lung indicate that it is a rare tumor found only questionably more frequently in males than in females It occurs equally in persons under and over forty years of age The

TABLE II
SURGICAL TREATMENT

Procedure	No	Living	Follow up without Evidence of Recurrence
Lobectomy (one or more lobes)	5	2 1	14 mo 6 mo 2 yr (with recurrence)
Pneumonectomy	6	4	7½ mo 12 mo 18 mo and 36 mo
Thoracotomy (with tumor removal)	4	4	19 mo 15 mo 7 mo and 7 mo
Thoracotomy (without tumor removal)	1	0	
Craniotomy	1	0	
Coughed tumor	1	1	4 yr
Died at surgery	2	0	
Bronchoscopy with fulguration	2	2	12 mo and 7 in 1 who also had roentgen therapy

clinical picture and roentgen manifestations of this type of tumor can be quite similar to bronchogenic carcinoma Surgical resectability of pulmonary sarcomas may be higher than for carcinomas of the lung No distinguishing clinical characteristics to aid in the differential diagnosis have been found Biopsy remains the only sure method of diagnosis

A serious consideration with this type of tumor is the frequency with which sarcomas elsewhere in the body will metastasize early to the lung and mistakenly be interpreted as a primary tumor Microscopically, the difference between the primary and the metastatic sarcoma may be extremely difficult The slow-growing nature of sarcomas from several type tissues notably bone, may make the primary source of such metastases frequently very obscure for long periods of time The diagnosis of primary sarcoma of the lung then is best made when either a complete autopsy examination discloses no other source for the tumor tissue, or a sufficient period of time has elapsed to rule out biologically a primary source elsewhere in the body

Mention should also be made of a particular type of sarcoma which is not included in these considerations It is the so-called carcinosarcoma True carcinosarcomas are single lesions with both carcinomatous and sarcomatous components found in the esophagus, uterus, larynx, bronchus and lung Their metastases may show a microscopic picture of carcinoma only, sarcoma only or both Bergmann, Ackermann and Kemler[9] have reported in detail two carcinosarcomas of the lung which they found in 258 surgically treated bronchopulmonary tumors at Barnes Hospital They have also found four so-called "collision" tumors which were the result of chance intermingling of a carcinoma and sarcoma arising fortuitously close to one another and presenting a microscopic picture similar to carcinosarcoma

SUMMARY

1 Primary sarcoma of the lung is a rare tumor, found only questionably more frequently in males than in females It occurs in persons under forty as often as it does in those over forty

2 A comparison of the clinical picture and roentgen manifestations of this type of tumor with those of bronchogenic carcinoma reveals no distinguishing characteristics

3 The duration of the patient's life and the surgical resectability of pulmonary sarcoma may be greater than for carcinoma of the lung

4 The frequency of slowly growing sarcomas elsewhere in the body which metastasize to the lung make it necessary to be cautious in diagnosis of a sarcoma as primary in the lung

REFERENCES

1 ELLIS R C Primary sarcoma of the lung with brain metastases *J Kansas M Soc* 40 243 1939
2 MALLORY, T B Cabot case No 22441 *New England J Med* 215 837 1936
3 STOREY C F Fibrosarcoma of the bronchus *J Thoracic Surg* 24 16 1952
4 JOHNSON E K., MANGIARDI, J L and JACOBS, J B Primary leiomyosarcoma of the lung treated by pneumonectomy *Surgery* 32 1010 1952
5 NOEHREN T H and MCKEE F W Sarcoma of the lung *Dis of Chest* 25 663 1954
6 STOUT, A P and HIMADI G M Solitary (localized) mesothelioma of the pleura *Ann Surg* 133 50 1951
7 MOORE H L. Primary carcinoma of the lung *Cancer* 4 663 1951
8 TANNER, G R and GORDON H Untreated bronchogenic carcinoma a report of thirty five cases *Am J Path* 28 953 1952
9 BERGMANN M., ACKERMANN L V and KEMLER, R L. Carcinosarcoma of the lung *Cancer* 4 919 1951

95

Lymphomatoid Lesions

A Rottino, M D and G Hoffman, M D, *New York, New York*

From the Dorothy H and Lewis Rosenstiel Foundation St Vincent s Hospital Hodgkin's Disease Research Project The work was also supported in part by grants from the Damon Runyon Memorial Fund

It is the purpose of this chapter to describe the pathologic changes produced in the lung by malignant lymphoma It has been our custom to classify the following entities under this general group (1) leukemia acute and chronic, (2) lymphosarcoma lymphocytic and reticulum cell, and (3) Hodgkin s disease

Analysis of 5,200 autopsies performed at St Vincent s Hospital over the past twenty years disclosed the following fourteen cases of acute leukemia with no instance of lung involvement, thirteen cases of chronic myeloid leukemia with no instance of lung involvement, ten cases of lymphatic leukemia with one instance in which there were gross nodules in the lung, forty cases of lymphosarcoma with three instances of lung involvement, and eighty-three cases of Hodgkin s disease with forty instances of lung involvement Thus of the various diseases classified as lymphoma, specific lung involvement was observed over whelmingly in Hodgkin's disease

The gross appearances of lung lesions observed in the one instance of lymphatic leukemia and the three instances of lymphosarcoma [illegible]
served
Hence,
the latter disease

The clinical and pathologic data were obtained from forty patients followed up by us in the Hodgkin's Clinic of St Vincent's Hospital These patients subsequently died and were autopsied at the hospital The control group was composed of forty-three other patients from the same Clinic dying from or with the same disease, and upon all of whom necropsy was performed

Pertinent clinical data pertaining to these patients are found in Table 1

monic involvement resembling lobar pneumonia (Fig 2), (3) lobular, confluent lobular

Table 1

	Pulmonary Group	Non pulmonary Group
Sex		
Males	21	29
Females	19	14
Age distribution (yr)		
10–20	10	1
21–30	4	9
31–40	14	13
41–50	8	8
51–60	4	6
61–70	[illegible]	6
Duration of life after Hodgkin s disease was discovered		
Under 1 yr	1	10
1 yr	6	[illegible]
2 yr	13	9
3 yr	7	4
4 yr	2	3
5 yr	3	3
6 yr	2	2
7 yr	4	1
8 yr	1	[illegible]
10 yr	[illegible]	1
12 yr	0	1
15 yr	1	0

and bronchopneumonia types of Hodgkin's disease of the lung (Fig 3), (4) a bronchitic [illegible]

The lesions varied from case to case as to number, size and distribution, and as a rule occurred mixed Most common of these is the nodular form present as multiple, discrete,

FIG 1 Nodular type Note size number and distribution of individual lesions. Lesions are firm solid and grey

FIG 2 Lobar form of Hodgkin s disease

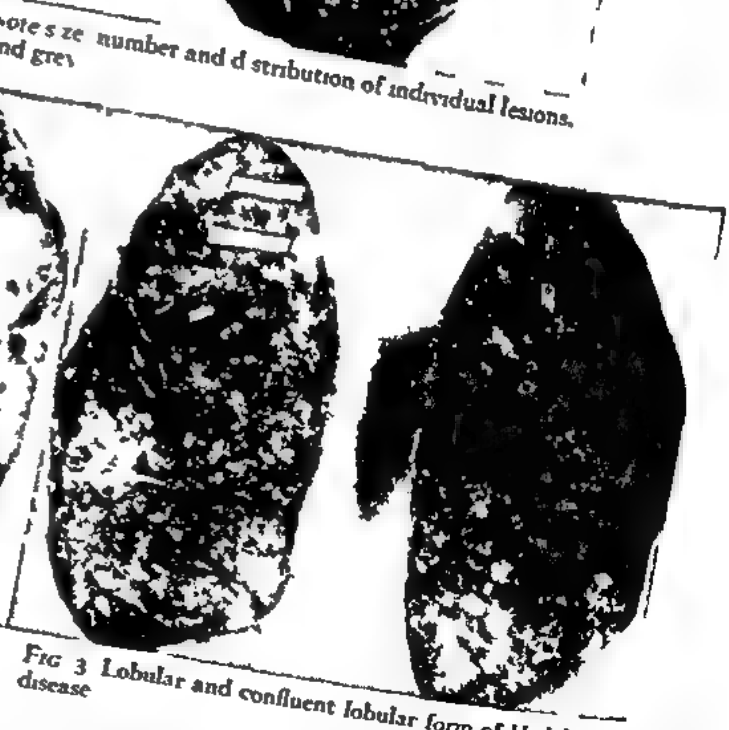

FIG 3 Lobular and confluent lobular form of Hodgkin s disease

firm grey areas Diffuse involvement of an entire lobe or portion of it is the second most common type occurring seven times in our series Although distal bronchioles and secondary bronchi are frequent sites of involvement by the disease under discussion the main bronchi were affected less often—only 3 times In one instance the lesion involved not only the bronchial tree but extended throughout the entire length of the trachea as well The miliary form of pulmonary Hodgkin s disease is rare since only one example was found in our entire series of eighty three autopsies

The pulmonary lesions were subject to a variety of degenerative changes such as cavitation fistula formation and ulceration of bronchial lesions The first was observed three times, the second once and the third three times In one lung an entire lobe was reduced to a single cavity whose wall was composed of typical

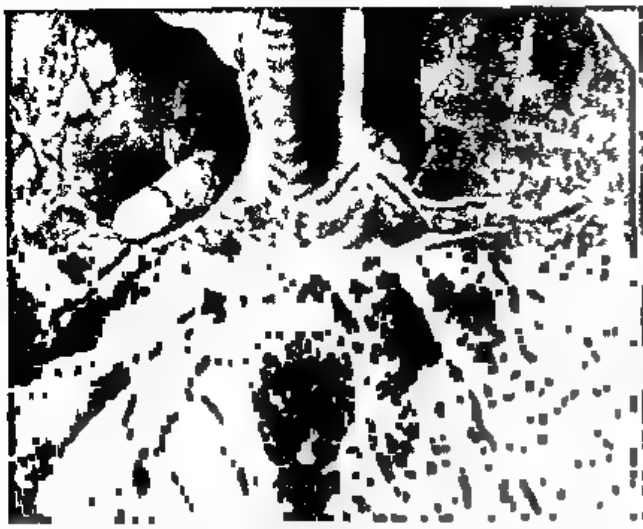

FIG 4 Bronchitic type of Hodgkin's disease Note the mucosa in the left main bronchus it is raised and nodular

FIG 5 Miliary type of Hodgkin's disease Note the uniformity of size and distribution of the nodules resembling miliary tuberculosis

Hodgkin's tissue A fistula occurred between this cavity, the trachea and esophagus In two cases it was our distinct impression that excessive x-ray therapy may have been the cause of the cavitation

In two lungs, in addition to Hodgkin's disease there was coexisting extensive tuberculosis Cor pulmonale caused by extensive pulmonary Hodgkin's disease occurred once

The pleura was affected twenty-two times by Hodgkin's disease, and in nine of these the lesions were limited to the diaphragm

Pleural effusions were found in thirty-four of the eighty-three autopsies Although pleural effusion frequently occurred when both lungs and pleura were affected by Hodgkin's, it was also seen when neither site was involved by it Thus effusions were found concurrent with pulmonary and pleural involvement by Hodgkin's twenty times and occurred alone fourteen times In nine instances Hodgkin's disease of the lung was uncomplicated by pleural effusion The fluids were as a rule straw-colored and rich in fibrin Only one of them was chylous The quantities varied from 250 to 3,000 cc The latter quantities produced complete atelectasis of the lung

When the lungs are involved by the illness in question, mediastinal and hilar nodes are usually affected, too Only in eight instances was this not so There were many cases of mediastinal involvement with the lungs free of the disease

In no instance was Hodgkin's disease limited solely to the lung Always the latter was associated with involvement of many sites, i e, liver, spleen, nodes, heart, etc

While pulmonary lesions in comparison to extent of disease elsewhere were often small, they were at times sufficiently large to dominate the clinical picture

Histologic Findings In general the histology of Hodgkin's disease of the lung at autopsy, although complex, proved fairly uniform and was similar to that observed in the lymph nodes and other organs concomitantly involved by the disease In all but one patient, who died from heart failure resulting from a rheumatic heart, the dominant cell was an irregular hyperchromatic reticulum cell mixed with fewer numbers of the Sternberg-Reed cell In some cases the degree of cellularity was such that the picture could be called sarcomatous Usually there was, however, a variable amount of fibrosis associated with the cellular proliferation The Hodgkin lesion was to a large extent in and about the bronchioles producing typical bronchopneumonia The process extended from here, into and about blood vessels, within interlobular septa, along alveolar walls and within acini Thus complex pictures of lobular, bronchitic, bronchopneumonic and interstitial Hodgkin's pneumonia were produced (Fig 6)

Of particular significance were the findings in the patient dying from heart disease, cited previously Here the lesion was predominantly a lobular pneumonia (Fig 7) The exudate present was chiefly lymphocytic with moderate numbers of reticulum and Sternberg-Reed cells

FIG 1 Nodular type Note size number and distribution of individual lesions. Lesions are firm solid and grey

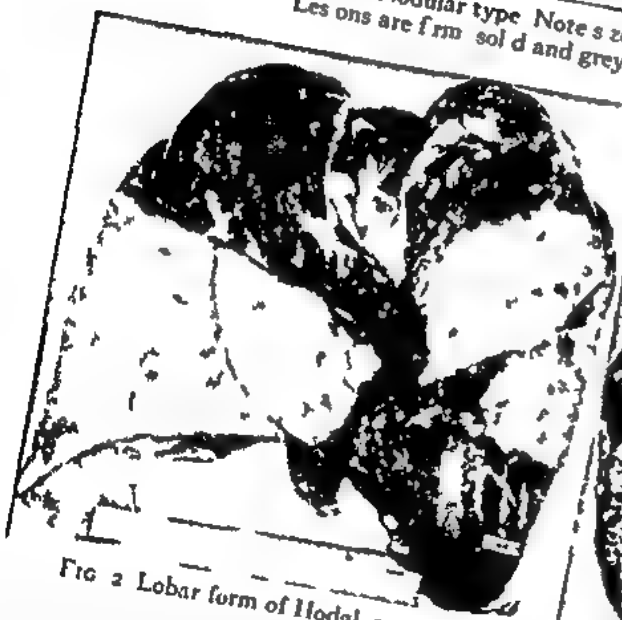

FIG 2 Lobar form of Hodgkin's disease

FIG 3 Lobular and confluent lobular form of Hodgkin's disease

firm grey areas Diffuse involvement of an entire lobe or portion of it is the second most common type occurring seven times in our series Although distal bronchioles and secondary bronchi are frequent sites of involvement by the disease under discussion the main bronchi were affected less often—only 3 times In one instance the lesion involved not only the bronchial tree but extended throughout the entire length of the trachea as well The miliary form of pulmonary Hodgkin's disease is rare since only one example was found in our entire series of eighty three autopsies

The pulmonary lesions were subject to a variety of degenerative changes such as cavitation fistula formation and ulceration of bronchial lesions The first was observed three times the second once and the third three times In one lung an entire lobe was reduced to a single cavity whose wall was composed of typical

FIG 4 Bronchitic type of Hodgkin s d sease Note the mucosa in the left main bronchus it is raised and nodular

FIG 5 Miliary type of Hodgkin s d sease Note the uniformity of s ze and d stribution of the nodules re sembl ng miliary tuberculosis

Hodgkin s tissue A fistula occurred between this cavity the trachea and esophagus In two cases it was our distinct impression that excessive x ray therapy may have been the cause of the cavitation

In two lungs in addition to Hodgkin s disease there was coexisting extensive tuberculosis Cor pulmonale caused by extensive pulmonary Hodgkin s disease occurred once

The pleura was affected twenty two times by Hodgkin s disease and in nine of these the lesions were limited to the diaphragm

Pleural effusions were found in thirty four of the eighty three autopsies Although pleural effusion frequently occurred when both lungs and pleura were affected by Hodgkin s it was also seen when neither site was involved by it Thus effusions were found concurrent with pulmonary and pleural involvement by Hodgkin s twenty times and occurred alone fourteen times In nine instances Hodgkin s disease of the lung was uncomplicated by pleural effusion The fluids were as a rule straw-colored and rich in fibrin Only one of them was chylous The quantities varied from 250 to 3 000 cc The latter quantities produced complete atelectasis of the lung

When the lungs are involved by the illness in question mediastinal and hilar nodes are usually affected too Only in eight instances was this not so There were many cases of mediastinal involvement with the lungs free of the disease

In no instance was Hodgkin s disease limited solely to the lung Always the latter was associated with involvement of many sites i e liver spleen nodes heart etc

While pulmonary lesions in comparison to extent of disease elsewhere were often small they were at times sufficiently large to dominate the clinical picture

Histologic Findings In general the histology of Hodgkin s disease of the lung at autopsy although complex proved fairly uniform and was similar to that observed in the lymph nodes and other organs concomitantly involved by the disease In all but one patient who died from heart failure resulting from a rheumatic heart the dominant cell was an irregular hyperchromatic reticulum cell mixed with fewer numbers of the Sternberg Reed cell In some cases the degree of cellularity was such that the picture could be called sarcomatous Usually there was however a variable amount of fibrosis associated with the cellular proliferation The Hodgkin lesion was to a large extent in and about the bronchioles producing typical bronchopneumonia The process extended from here into and about blood vessels within interlobular septa along alveolar walls and within acini Thus complex pictures of lobular bronchitic bronchopneumonic and interstitial Hodgkin s pneumonia were produced (Fig 6)

Of particular significance were the findings in the patient dying from heart disease cited previously Here the lesion was predominantly a lobular pneumonia (Fig 7) The exudate present was chiefly lymphocytic with moderate numbers of reticulum and Sternberg Reed cells



FIG 6 A projection of a large section of lung Note the discrete Hodgkin's lesion involving an area about a bronchus pulmonary vessels and surrounding acini



ow power Picture m
o is sts of lymphocytes and reticulum
s are conspicuous

The same cellular pattern was observed in lymph nodes and other organs affected by Hodgkin's disease in this patient

In addition to the typical Hodgkin's type of reaction, lobules were found filled with a fibrinous exudate, either pure or in a state of organization. Lobules distended with lipid engorged macrophages were common. The relationship and significance of both these lesions to the Hodgkin process is not yet known by us

Clinical Aspects of Pulmonary Hodgkin's Disease Although at times pulmonary symptoms dominate the clinical picture, the pulmonary lesion is often silent or obscured by symptoms arising from other organs more severely involved by Hodgkin's disease

In a few instances the disease is ushered in by [illegible] symptoms of onset were pulmonary the work up indicated lung tumor or suppurative disease, and a diagnosis of pulmonary Hodgkin s disease was subsequently established from study of a lobe removed at operation

By far the most frequent experience is to discover pulmonary involvement by Hodgkin's during the course of the disease with the aid of the x ray picture which it is our practice to take at three to six month intervals

The common symptoms when they do occur are cough, chest pain, and in advanced cases, dyspnea and orthopnea The cough is usually dry and hacking It can be severe, and when it persists into the night, interferes with sleep The pain may be sharp or may be experienced as a soreness or a heavy feeling

Patients have survived for periods as long as four years after the lung lesions were discovered During this interval with the aid of x ray pictures, the lesions have been seen to diminish in size, increase in size and change in shape In no instance can we claim observing a lesion disappear completely

Etiology In the past ten years research into the etiology of Hodgkin's disease has been focused on a hypothetic microbiologic agent In 1944 Grand[1] interpreted as indicative of the presence of a virus certain phenomena occurring in tissue cultures of Hodgkin's diseased nodes This conclusion has not been concurred in by other investigators[2, 4] who repeated the work Both Hoster and Karnofsky attempted isolation of a Hodgkin's virus by inoculation of Hodgkin's diseased tissue extracts[5] or implantation of Hodgkin's material[6] on chorioallantoic membrane without success Bostick[7] reports [illegible] that this same material inoculated intracranially in suckling mice in due course is rendered sufficiently virulent to induce paralysis in mice

In [illegible] nificar [illegible] micro [illegible] contributions of earlier years by Bunting and Yates[10] who apparently were the first to have isolated a diphtheroid in Hodgkin's disease, and later, Cunningham[11] who concluded that the diphtheroid was an air-borne contaminant Our own experience with diphtheroids led us to the same conclusion [12]

Attempts to date to reproduce the disease with microbiologic agents isolated from patients with Hodgkin s disease have proved fruitless

Pathogenesis The micropathology of Hodgkin's disease presents a definite pattern of slow development in some patients, more rapid in others In general the pattern seen at any one time has been, in our experience, fairly uniform so that the study of a node from one area [illegible] of the lymphocyte obscuring very often an occasional enlarged reticulum cell with a prominent nucleolus [13] Progress in the pathology is characterized by hyperplasia of this type of reticulum cell and the appearance of more bizarre forms with pleomorphic nuclei, the [illegible] node becomes completely fibrous In other instances, instead of atrophy of cells and fibrosis the abnormal forms of reticulum cells proliferate quite markedly so that the pathologic picture resembles a reticulum cell sarcoma In most terminal cases of Hodgkin's disease one finds in a node or organ a mixed pattern, fibrosis and sarcomatous change—the extent of each varying from node to node and from case to case

It is our opinion that a similar train of histologic events occurs in the lung and that an appreciation of this fact is pertinent to proper management of therapy

Therapy Since the lung constitutes but one of many foci affected by this disease, treatment must be directed toward the individual as a whole X-ray remains as it has in the past, a very useful tool for the treatment of localized Hodgkin's disease One word of caution must be raised concerning its repeated use

because a shadow observed in the roentgen film does not disappear or is not altered Failure to do so may be due to the fact that the lesion is predominantly fibrous or else of a sarcomatous pattern therapeutically refractory to the x ray Persistence in this method of treatment can only damage overlying or adjacent normal tissue

In addition to the x-ray, nitrogen mustard[14] and triethylene melamine[15] have proved to be most useful drugs in the management of Hodgkin's disease

When the foregoing three modalities have proved ineffectual, we have found butazolidin®[16] most helpful in controlling symptoms such as pain, fever and malaise In selected cases adenosine-5-monophosphate[17] has a highly specific effect on pruritus Cortisone and ACTH sometimes help In an occasional case aureomycin, terramycin,® penicillin and other antibiotics aid in controlling unsuspected intercurrent infections

Nature of Hodgkin's Disease The nature of Hodgkin's disease remains difficult to comprehend Judged by the increasing conspicuousness of the morphologically altered reticulum cell as the disease advances, it would appear to be a proliferative disease, yet in the early phases it is the lymphocyte which dominates the microscopic picture Why this should be so is not known The cause and significance of the transition of one cell type from dominant role to another remains to be discovered One fact does stand out, i e, that increasing refractoriness to therapy seems to coincide with diminution in numbers of lymphocytes The reason for this and what is indicated thereby is a fascinating but unanswered question Nor do we yet have an inkling into the function of the eosinophil which is so conspicuous at times in Hodgkin's disease

Thus much work remains to be done before the etiology of Hodgkin's disease is discovered and its nature elucidated Until these aims are achieved, much of the subtle pathology of Hodgkin's disease will remain difficult to explain and the search for therapy will continue to be empiric

REFERENCES

1 GRAND C. G Tissue culture studies of cytoplasmic inclusion bodies in lymph nodes of Hodgkin's disease *Proc Soc Exper Biol & Med* 56 229–230 1944

2 ROTTINO, A In vitro studies of lymph nodes involved in Hodgkin's disease I Liquefaction of culture medium *Arch Path*, 47 317 327 1949

3 ROTTINO, A In vitro studies of lymph nodes involved in Hodgkin's disease II Tissue culture studies formation, behavior and significance of the multinucleated giant cell *Arch Path*, 47 328 334 1949

4 JACQUEZ J A and PORTER, K R Electron microscopy observations on Hodgkin's material *Cancer*, 2 853–856 1949

5 HOSTER, H A Personal communication unpublished data

6 KARNOFSKY D A, PARISETTE, L M, PATTERSON P A and JACQUEZ, J A The behavior and growth of homologous and heterologous normal and neoplastic tissues on the chick embryo and the influence of various agents on tumor growth *Acta Unio Internat Contra Cancrum* 6 641–651 1949

7 BOSTICK, W L The serial passage of Hodgkin's disease tissue extracts in chicken eggs *J Immunol* 59 189–193 1948

8 BOSTICK W L. Serial intracranial passage of Hodgkin's disease material in suckling mice *Federation Proc* 13 424 1954

9 FLEISHER, M S Significance of diphtheroid microorganisms in blood culture *Am J M Sc* 224 548 553 1952

10 BUNTING C. H and YATES J L An etiologic study of Hodgkin's disease *J A M A*, 62 516 1914

11 CUNNINGHAM, W F The status of diphtheroids with special reference to Hodgkin's disease *Am J M Sc*, 153 406 412 1917

12 ROTTINO A Re-evaluation of significance of diphtheroids in malignancy by means of germ free techniques Hodgkin's disease, etc *Arch Int Med*, in press

13 ROTTINO A Progress in the study of Hodgkin's disease *Ohio State M J* 49 888–890 1953

14 KARNOFSKY, D A Nitrogen mustards in the treatment of neoplastic disease Advances in Internal Medicine, vol iv pp 1–59 Chicago 1950 Year Book Publishers Inc

15 ROTTINO A Triethylene melamine in the treatment of Hodgkin's disease and other lymphomas. *New York State J Med* 52 346–348 1952

16 ROTTINO, A, JOFFE, A and HOFFMANN G Phenylbutazone a useful chemotherapeutic agent for Hodgkin's disease *Arch Int Med.*, 93 561–570 1954

17 ROTTINO, A Effect of adenylic acid therapy upon pruritus due to Hodgkin's and other diseases *Cancer* 3 272 278, 1950

Treatment of Inoperable Cancer, Primary and Metastatic*

DAVID A KARNOFSKY, M D, W P LAIRD MYERS, M D AND RALPH PHILLIPS, M D,
New York, New York

From the Chemotherapy and Radiation Therapy Services, Memorial Center for Cancer and Allied Diseases New York N Y

THERE are an estimated 20 000 new cases of primary bronchogenic carcinoma diagnosed each year in the United States, and the number seems to be increasing Probably less than 5 per cent of these cases are satisfactorily controlled by surgery In addition, the lung is a common site for metastatic cancer, and the mediastinum for lymphomatous diseases The estimated frequency with which pulmonary metastases occur in various types of cancer is shown in Table 1 About 25 per cent of all patients dying of cancer have pulmonary metastases but data on the proportion with respiratory symptoms are lacking It is apparent that some patients with pulmonary metastases have no symptoms In others the disease is so generalized that the pulmonary disturbances are only a minor part of the total picture, while in a third group respiratory symptoms constitute the major problem This last group comprises approximately one-third of the patients with lung metastases, or about 20,000 new patients each year in the United States

The most effective method of treatment is to interfere with the growth and extension of the neoplastic cells This can be accomplished to a limited degree with ionizing radiation or specific drugs The presentation of the methods of application of these agents and the indications for their use is the primary purpose of this report A number of non specific measures which may alleviate some of the manifestations and secondary complications of the growing tumor will also be mentioned The objectives of treatment are the relief of discomfort, improvement in function and restoration of the patient to a tolerable and possibly useful activity for as long as possible

PRINCIPLES OF GENERAL MANAGEMENT

The following remarks are based on the assumption that the lesion has been first carefully evaluated from a surgical point of view

TABLE 1
APPROXIMATION OF THE INCIDENCE OF PULMONARY METASTASES AT AUTOPSY

Primary Site of Cancer	Estimated No of Deaths in U S per Year	Pulmonary Metatases (%)
Breast	25 000	
Kidney	4 000	
Bone	2 500	50–70
Thyroid	1 000	
Testes	1 000	
Pancreas	8 000	
Ovary	6 000	25
Adrenal	600	
Intestine	35 000	
Uterus, including cervix	18 000	
Prostate	12 000	20
Liver	8 000	
Esophagus	4 000	
Stomach	25 000	
Bladder	7 000	15
Head and neck	6 000	
Lymphomas and leukemia	15 000	50–90

Accurate Diagnosis The presence of cancer, its type and extent must be clearly established The presence of primary cancer elsewhere in

* The chemotherapy program is supported in large part by grants from the American Cancer Society The Damon Runyon Memorial Fund and by Grant C1889 from the National Cancer Institute of the National Institutes of Health, U.S P H S, and The Lasker Foundation

logic disturbance encountered was alveolo respiratory insufficiency with anoxemia

It is admittedly difficult to analyze thor oughly the anatomic and physiologic aspects behind the symptomatology which each patient presents However the approach previously suggested will often help to clarify the situa tion Treatment both [illegible]

TREATMENT

In general active therapy is indicated in the management of inoperable cancer par ticularly when definite symptoms are present[7] Specific and supportive measures are discussed separately

Specific Therapy This refers to agents given for the purpose of destroying the cancer or inhibiting its growth The application of specific therapy will be discussed for the different forms of cancer

Primary bronchogenic carcinoma The natural progression of inoperable or recurrent bronchogenic carcinoma is usually rapid and approximately 70 per cent of the patients die within one year after the clinical onset of the disease

If at thoracotomy the primary tumor or metastatic lymph nodes are not resectable they should be implanted systematically with radon seeds Radon seed implants deliver a high tumor dose of 8 000 to 12 000 r with minimum risk of radiation damage to sur rounding structures It is also a useful method for marking the anatomic limits of the tumor and involved lymph nodes for a subsequent course of x ray therapy In inoperable cases without evidence of distant metastases radia tion therapy is advisable even in the absence of disabling symptoms because as the disease spreads such symptoms are likely to appear within a short time In the presence of symp toms whether distant metastases are already evident or not x ray therapy produces relief of bronchial obstruction cough dyspnea and hemoptysis or of mediastinal pressure symp toms in about 70 per cent of the patients

Bronchogenic cancer is best irradiated with supervoltage x rays (1 000 to 2 000 kv) or with hard gamma rays (telecobalt) For epidermoid and differentiated adenocarcinoma a tumor dose of 6 000 r in five to six weeks is given when there is a chance for prolonged control of the disease A smaller dose is indi cated if the intrathoracic metastases are more extensive In anaplastic (oat cell) carcinoma the high probability of hepatic and cranial metastases reduces the possible survival time to a few months Therefore we prefer for the convenience of the patient to shorten the period of treatment to the primary lesion and a 3 000 r tumor dose is given in nine days

Palliation has been most successful when the disease was largely confined to the mediastinum or a single portion of the lung It is less effective in widespread disease with involvement of the parenchyma of both lungs such as occurs in terminal bronchiolar carcinoma Nevertheless x ray therapy may be of benefit The more heavily involved lung is irradiated first with a tumor dose of 2 000 r in eight days if there is a satisfactory response the other lung is similarly treated

Large tissue doses in excess of 2 500 r will cause some degree of pneumonitis beginning two to eight weeks after irradiation Radiation pneumonitis sometimes resolves completely or partially sometimes progresses to pulmo nary fibrosis and sometimes cannot be differ entiated from lymphatic spread of carcinoma Radiation pneumonitis may be alleviated in some cases by cortisone 200 to 300 mg /day and antibiotics should always be used to prevent secondary infections

In some instances of far advanced disease nitrogen mustard (HN2)* is used in conjunc tion with x rays[8] Provided the hematolog c status of the patient is within normal limits a single dose of 0 4 mg /kg (20 to 30 mg) in the average adult is given intravenously usually into the tubing of an infusion This dose will induce several hours of nausea and vomiting beginning within one-half to two hours Seda tion with sodium amytal or chlorpromazine may diminish the vomiting On the basis of observations in the laboratory we have give a course of HN2 immediately preceding th onset of x ray therapy in order to produc additional injury to the tumor cells Whil the value of this combination has not bee established clinically it seems reasonable t continue its use in patients with large tumors There is a more definite reason for using HN2 in patients presenting with symptoms due to compression of the superior vena cava These patients are uncomfortable with edema and

* Mustargen® (Merck & Co Inc Rahway New Jersey)

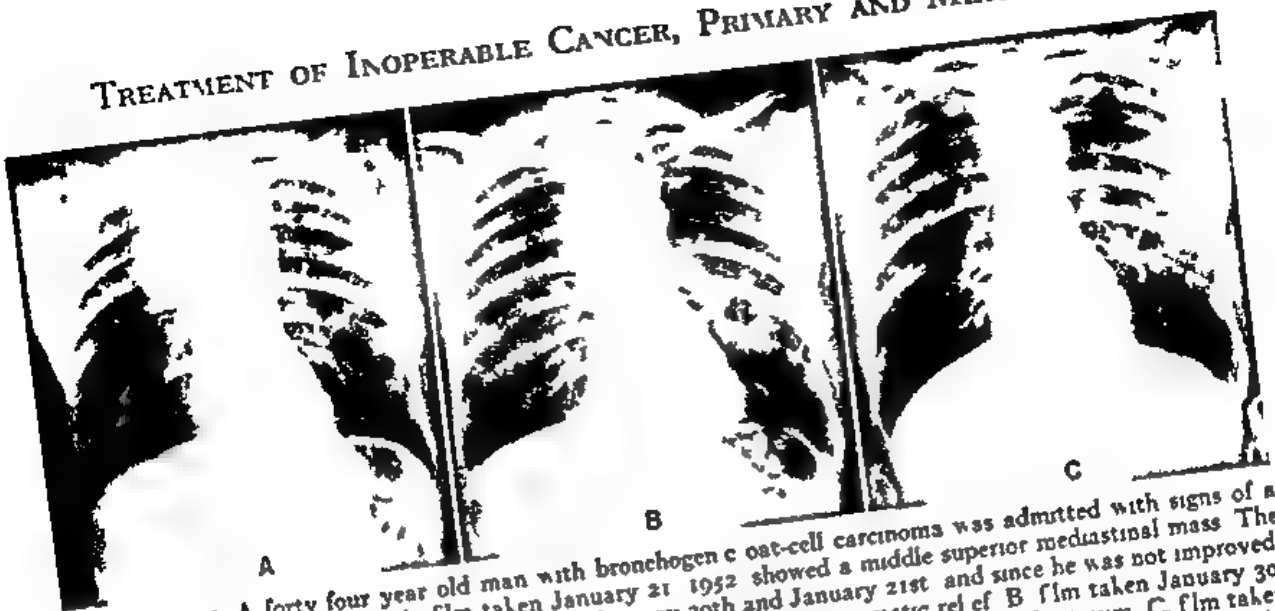

FIG 4 Case 11 A forty four year old man with bronchogenic oat-cell carcinoma was admitted with signs of a superior vena caval syndrome A film taken January 21 1952 showed a middle superior mediastinal mass The patient received 6 mg of TEM intravenously on January 20th and January 21st and since he was not improved on January 23rd he received 0 3 mg /kg HN2 There was prompt symptomatic relief B film taken January 30 1952 showed regression of mediastinal mass A tumor dose of 3 000 r was given to the mediastinum C film taken February 13 1952 showed further improvement The patient had a ten month remission on Manifestations of the disease due to generalized metastases occurred in November 1952 and the patient died April 2 1953 with evidence of severe liver insufficiency due to metastatic disease

venous engorgement of the face neck and arms increased venous pressure and dyspnea and orthopnea HN2 usually given as 0 4 mg kg in a single dose will produce prompt relief of this syndrome in 80 to 90 per cent of the patients with objective evidence of tumor regression Improvement is due in part to a reduction of the inflammatory reaction and edema in the mediastinal and cervical nodes but histologic changes have been observed in the tumor cells similar to those following x ray therapy[8] The treatment is given in a single injection so that if effective it will result promptly in improvement Usually patients with anaplastic or oat cell carcinoma show the most striking response If the response is incomplete and the patient s blood count is not unduly depressed in three weeks another dose of 0 2 or 0 4 mg /kg of HN2 may be given The serious reaction of edema in the tumor bed and lymph nodes such as sometimes occurs after the initiation of x ray therapy has not followed the use of HN2 The remissions induced by HN2 are brief lasting three to eight weeks and second courses of treatment are usually not as effective[8] Therefore it is desirable in most cases to start x ray therapy within one week Figure 4 Case 11 describes a patient treated in this manner

Recurrent pleural effusion in lung cancer may be due to mediastinal parenchymal or pleural disease When evidence of pleural involvement exists x ray therapy the intrapleural instillation of radioactive gold (Au^{198})[8] or HN2 may control the effusion[8] The usual procedure is to remove most of the pleural fluid and instill Au^{198} or HN2 into an almost dry pleura The usual dose of Au^{198} is 75 to 100 mc and of HN2 20 to 30 mg One of these treatments will be effective in most instances in relieving the need for frequent thoracenteses Occasionally triethylene melamine (TEM) an oral drug with nitrogen mustard like activity has been used in widespread lung cancer The usual dose is 5 to 10 mg the first week taken one hour before breakfast with plain water and further dosage is determined at weekly intervals on the basis of the peripheral blood picture[4] Although the effects of TEM are similar to those of HN2 the latter is preferred for promptness and consistency of action While treatment may control the pulmonary disease lung cancer disseminates widely and the disturbances produced by distant metastases often overshadow the local problems

Metastatic cancer to the lungs With the exception of carcinomas of the breast prostate and thyroid and the lymphomas and leukemias which may be treated by special methods, carcinomas and sarcomas metastatic to the lungs are managed according to the principles outlined for lung cancer It is recognized even more conspicuously in these tumors that some

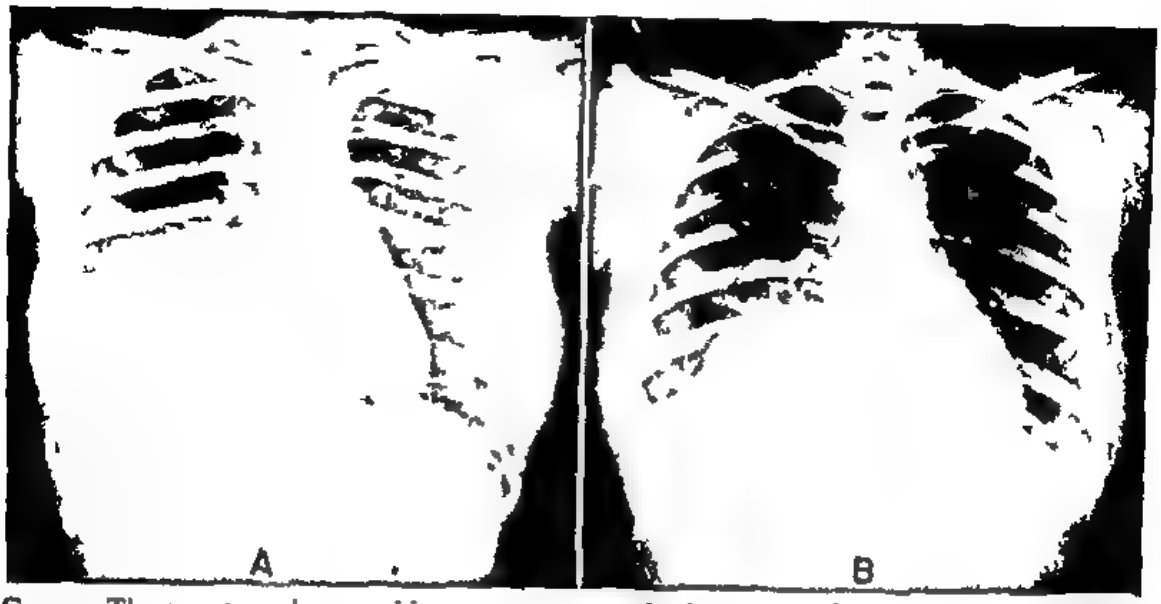

may increase in size slowly and produce virtually no symptoms

Pulmonary metastases are, in general, no less responsive to irradiation than metastases elsewhere, but radiation pneumonitis and

of disease elsewhere

Multiple pulmonary metastases of seminoma, chorioepithelioma, lymphosarcoma, neuroblastoma and other radiosensitive cancers may be irradiated even in the absence of symptoms, since a tumor dose of 2,000 to 2,500 r to the whole chest can cause their *disappearance without producing more than* temporary pneumonitis Five-year radiation survivals are recorded in patients with pulmonary metastases from seminoma, chorioepithelioma, Ewing's and Wilms' tumors, and reticulum cell sarcomas Apart from the preceding, irradiation of multiple pulmonary metastases is not usually advisable except for the relief of symptoms Hemoptysis is sometimes a problem and can usually be stopped by a tumor dose of 2,000 r, if the site of hemoptysis cannot be determined, it is our practice to irradiate the largest metastasis first. Chronic

first (tumor dose 2,000 to 2,500 r), and to avoid irradiating the remaining lung for as long as possible Dyspnea may also be improved, but less frequently than cough or sputum

X-ray therapy is sometimes preceded by a course of HN2 or TEM, also these drugs used alone may cause a favorable response (Fig 5, Case III)

Breast cancer Pulmonary metastases occasionally respond to hormonal control measures, a number of techniques are available for altering the hormonal balance and the indications for each method are being more clearly defined by experience[8,9]

In premenopausal patients with inoperable or recurrent disease the usual sequence of therapy is as follows

Surgical castration is preferred (radiation castration may be effective) After evaluating the response, if no improvement occurs or if improvement is followed by relapse, androgen therapy is started, usually 100 mg of testoste-

rone propionate injected intramuscularly three times weekly If there is a favorable response, when the patient relapses on therapy, further improvement may follow its discontinuation

Adrenalectomy has caused further improvement, particularly in situations when the patient has been benefited by castration and testosterone In some clinics adrenalectomy is the first procedure used in patients who have relapsed following a response to castration

Hypophysectomy has not been adequately evaluated in patients refractory to other hormonal control measures, but regression of pulmonary metastases has been seen following hypophysectomy

Cortisone, 200 to 300 mg /day, may produce temporary improvement in patients resistant to castration and testosterone

These methods should be applied in an orderly sequence so that the effect of one procedure is evaluated before initiating another

In postmenopausal women hormonal control measures have consisted, usually in a sequence which varies in different clinics, of trials of estrogens, androgens, castration (radiation or surgical), combined adrenalectomy and castration, and of cortisone in far advanced cases Some degree of objective response occurs in about 50 per cent of the cases with widespread breast cancer

Besides the established value of these methods, x-ray therapy has been effective in temporarily relieving pulmonary symptoms Treatment is directed to the local manifestations of disease in the mediastinum and pulmonary parenchyma Also, recurrent pleural effusions have been effectively controlled by x ray therapy Recently intrapleural Au^{198} has been used for the same purpose

In some instances the polyfunctional alkylating agents, such as nitrogen mustard, TEM, triethylene phosphoramide (TEPA) and triethylene thiophosphoramide (ThioTEPA), may have a favorable influence on pulmonary metastases HN2 is usually given in a single dose of 0 4 mg /kg intravenously, and TEM is given orally under careful dosage control as maintenance therapy [4] Recurrent pleural effusions due to breast cancer may respond to the intrapleural injection of HN2 given in the manner described for lung cancer Two patients illustrating favorable responses to HN2 and TEM, respectively, are shown in Figures 6 and 7, Cases IV and V

Prostatic cancer Pulmonary or osseous metastases from carcinoma of the prostate respond as remarkably to treatment as those elsewhere in the body Either estrogen or surgical castration is effective in the majority of cases, and frequently a combination of estrogen and castration is used Figure 8, Case VI, shows pulmonary metastases which responded to estrogen therapy

Thyroid cancer The natural course of thyroid cancer is varied, unpredictable and often protracted, even in patients with pulmonary metastases The pulmonary lesions respond to x ray therapy, and if they are capable of concentrating iodine, to radioactive iodine (I^{131}) [10] I^{131} in suitable patients is preferable The potential response to I^{131} is well correlated with the histologic type, the alveolar and follicular tumors are more likely to pick up I^{131} The patient is first given a tracer dose of I^{131} to determine how efficiently it is concentrated in the tumor If selective uptake is demonstrated, the avidity of tumor cells for iodine may be further enhanced by removing the normal thyroid gland by surgery or destroying it by I^{131} A further procedure is to administer thiouracil for six to eight weeks in order to block the uptake of iodine by the tumor The tumor cells will show their maximum uptake of I^{131} two to three days after stopping thiouracil The therapeutic dose of I^{131} is determined for each case on the basis of uptake of the tracer dose and estimated mass of tumor The chief limiting factor in dosage is damage to the hematopoietic system, and the usual dose is in the range of 100 to 200 mc by mouth Figure 9, Case VII, illustrates a satisfactory response

Lymphomas and leukemias Early and apparently localized Hodgkin's disease of the mediastinum is usually treated vigorously by radiation therapy with a tumor dose in the range of 2,400 to 3 000 r in three to five weeks If the disease is chiefly in the mediastinum but there is evidence of disease elsewhere, a smaller tumor dose in the range of 1,500 to 2,000 r is given These doses are sufficient to produce prolonged and sometimes permanent disappearance of the local disease even though it recurs elsewhere. In an experimental series of patients with mediastinal and cervical or axillary disease we have given a course of HN2, 0 4 mg /kg, followed by 3 000 r tumor dose (1,000 kv) to the tumor bearing area. This

FIG 6 Case IV This fifty-three year old woman had bilateral carcinoma of the breast diagnosed in July, 1952 Initial treatment was bilateral radical mastectomy Pulmonary metastases were first noted in March, 1953 A, pre- on of right of 45 mg March 2

FIG 7 Case [illegible] treated by right ing na t 3 led the

patient died on March 2, 1954

treatment is well tolerated and it is given with the purpose of obliterating the disease While it will take a number of years to demonstrate that this is a superior form of treatment, of five patients who were treated more than three years ago, thus far one has shown evidence of recurrent disease. A course of HN2 is also useful in treating bulky mediastinal and [illegible] compression [illegible] to the patient.

FIG 8 Case VI This seventy-one year old man had carcinoma of the prostate and pulmonary metastases diagnosed in August 1949 A pretreatment chest film The patient was orchiectomized and placed on 0 5 mg diethylstilbestrol daily B marked regression in the pulmonary metastasis in a film taken April 4 1951 almost two years later

FIG 9 Case VII This nineteen year old man had multiple pulmonary metastases from carcinoma of the thyroid

and x ray examination of the lungs reveals no evidence of disease

For recurrent mediastinal involvement or parenchymal disease x rays are the initial method of treatment Radiation therapy should be given in doses adequate to cause tumor regression In far advanced cases the pulmonary lesions may be the predominant problem and they often show considerable resistance to x rays The dosage in these situations may be increased because the possibility of producing clinical improvement often overshadows the hazard of pulmonary fibrosis In some of these instances however, HN2 or TEM may be effective in relieving cough and dyspnea and produce objective evidence of tumor regression While the response to a course of HN2 usually lasts for only one to three months TEM may be used as maintenance therapy This type of response is shown in Figure 10 Case VIII When pulmonary symptoms recur after x ray the response to a

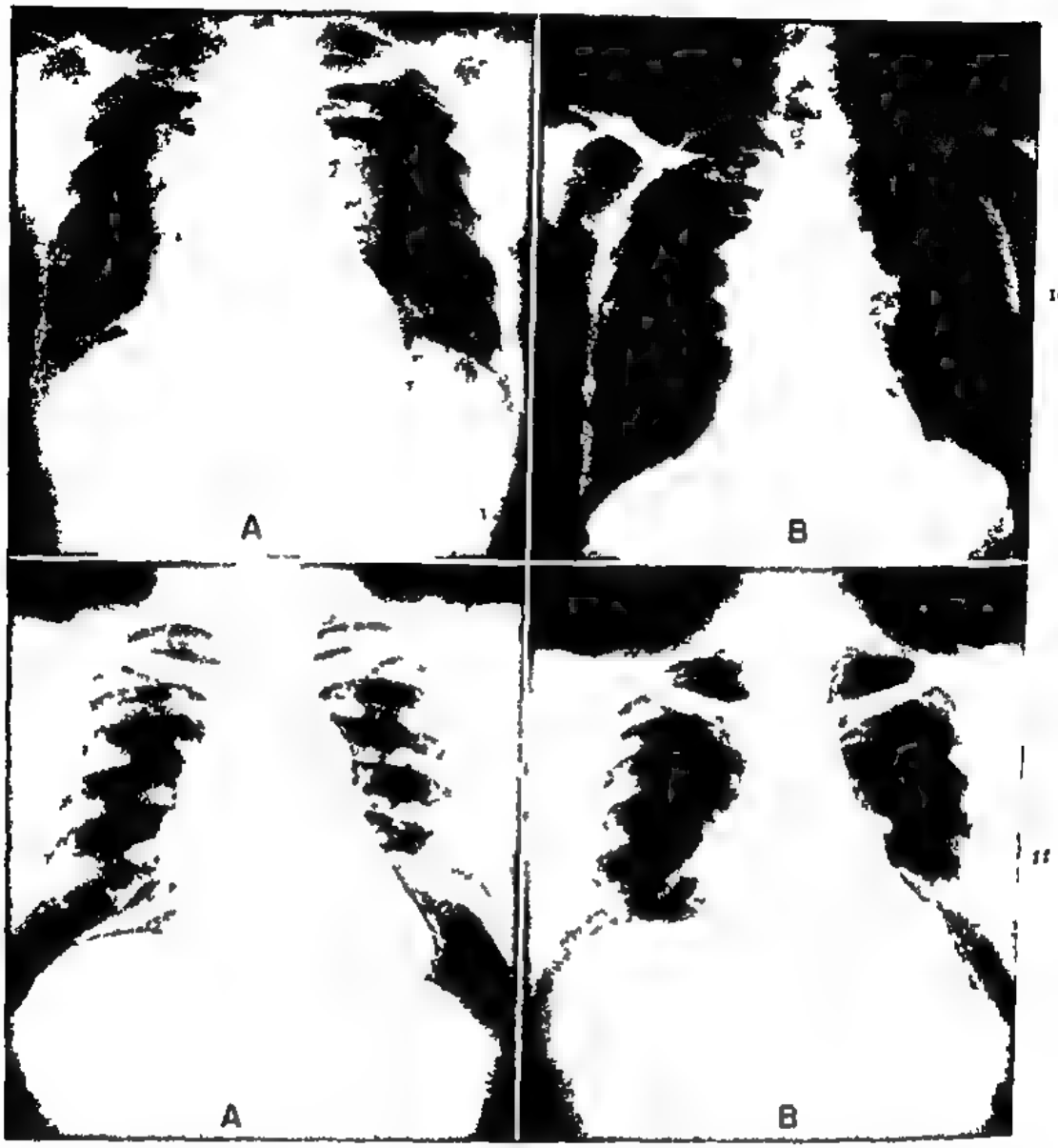

10

11

FIG 10 Case VIII This fifty-one year old woman had Hodgkin's disease diagnosed in August, 1946 The patient was treated with several courses of x rays to enlarged cervical, axillary and mediastinal nodes A chest film taken in February, 1950, showed progression in mediastinal enlargement with pulmonary symptoms The patient was placed on a maintenance dose of TEM and showed marked symptomatic improvement with regression of the mediastinal widening B, film taken September 5, 1951 Disease recurred elsewhere and the patient died October 23 1951

FIG 11 Case IX This thirty three year old man had acute myeloblastic leukemia diagnosed in October, 1953 A, film taken October 23 1953 showed mediastinal adenopathy The patient received 6-mercaptopurine and obtained a complete hematologic remission B film taken February 23 1954 showed regression of the mediastinal adenopathy The patient had relapse in May, with increase in the mediastinal widening and a second remission was induced with cortisone

course of HN2 may be useful in deciding whether the symptoms are due to active disease or pulmonary fibrosis. Some patients with Hodgkin's disease finally go on to almost complete replacement of the lung by fibrotic tumor, which is refractory to therapeutic doses of x-ray or nitrogen mustard

The varieties of lymphosarcoma are usually managed in the same manner as Hodgkin's disease, although they do not respond as consistently to treatment Some forms of the disease may be extremely sensitive to therapy, and small doses of x-rays, 200 to 400 r, HN2 or TEM will cause regression of enlarged mediastinal and cervical nodes These patients may also respond to cortisone The response of

these sensitive tumors is similar in many respects to that of chronic lymphatic leukemia and specific therapy should therefore be given cautiously The resistant forms of lymphosarcoma, particularly the reticulum cell sarcomas, require much higher doses of x-rays to produce regression, the response may be prolonged, but often following a marked regression the disease recurs rapidly and becomes resistant to therapeutic doses of x-rays These tumors also show a similar and very transient reaction to TEM or HN_2, and these drugs are usually of little practical value in rapidly growing and resistant reticulum cell sarcomas

Acute leukemia may respond to the adrenal cortical steroids, the folic acid antagonists (aminopterin and amethopterin) and 6-mercaptopurine (purinethol)[2] The most consistent and favorable results have been obtained in children Mediastinal enlargement occurs in some patients, and these enlarged nodes usually regress during a hematologic remission of the disease (Fig 11, Case IX)

Pulmonary problems are not prominent in chronic myelocytic and lymphatic leukemia When pulmonary infiltration or mediastinal enlargement occurs, if the process is not controlled by appropriate specific systemic therapy, such as the use of HN_2 TEM, myleran, P^{32}, urethane or 6-mercaptopurine, small doses of x rays to the lung or mediastinum (200 r) may produce tumor regression Lymphosarcomas in children are treated with x-rays and HN_2 during the localized stage, but they may also respond to the same systemic agents effective in acute leukemia

Children's Tumors Many cancers of childhood produce pulmonary metastases These include embryonal rhabdomyosarcoma, Wilms's tumor, Ewing's tumor, embryonal carcinomas and neuroblastoma The histologic appearance of the tumor is not a reliable guide to radiosensitivity, and the temporary response to x-ray therapy may sometimes be remarkably good These tumors in children, regardless of their extensive distribution in the lungs, are worth treating Occasionally x-ray therapy is combined with a preliminary course of HN_2

Supportive Measures While specific therapy offers the only chance of relieving the underlying disease, many major problems can be managed only by supportive measures

Chest pain and cough are treated with opiates Dyspnea is usually relieved only by successful specific therapy However, pleural effusions, associated cardiac failure or associated pneumonitis may be aggravating factors which are amenable to supportive measures including thoracenteses, digitalization or antibiotics

If the principal problem is one of endobronchial obstruction, antibiotics, expectorants, bronchodilators, hydration and postural drainage will help to eliminate the infection and mucous plug formation and the resultant atelectasis

If anoxemia is present, oxygen should be administered either by nasal tube or in a tent The possibility of respiratory acidosis should be kept in mind inasmuch as oxygen administration may be harmful in such situations Respiratory alkalosis likewise can occur with the hyperventilation sometimes seen with extensive pulmonary infiltration Treatment with a 5 per cent CO_2—95 per cent O_2 mixture may be helpful in respiratory alkalosis These respiratory disturbances will be discovered only if thought of and if a CO_2 content of the blood is obtained Occasionally the clinical picture and a CO_2 content are sufficient to make a diagnosis, but in some instances a blood pH may be necessary

If the patient presents a picture consistent with cor pulmonale and right heart failure, the usual measures including digitalization and diuretics should be undertaken

Pleural manifestations most commonly are those of fluid collection Recurrent effusions present a very difficult problem in management At present repeated thoracenteses combined with specific therapy constitute the best treatment Bronchopleural fistulas and pneumothorax are likewise difficult to treat Measures (talc insufflation) to induce an adhesive pleuritis around the lesion may be tried but are usually unsuccessful

When the patient demonstrates the findings of superior vena caval obstruction, general measures should include salt restriction, diuretics and semi recumbent position

The miscellaneous group of complications (nerve paralyses, esophageal invasion, myocardial invasion, etc) are treated best with specific measures Occasionally pericardial paracentesis becomes necessary if tamponade due to effusion becomes a problem Tamponade, however, may reflect extensive replace-

ment of the pericardium by tumor and paracentesis would be useless Digitalis and quinidine or both may be of use in controlling arrhythmias

SUMMARY AND CONCLUSIONS

Involvement of the respiratory tract by inoperable or recurrent bronchogenic carcinoma or by metastatic neoplasms is a common problem which almost always results directly in death or is associated with a fatal extension of the neoplasm elsewhere in the body By a careful analysis of the pathogenesis of the pulmonary disturbance and the use of specific measures which may restrain the growth of the neoplasm, and by appropriate supportive measures it is possible to relieve symptoms, sustain morale, increase the period of useful life and occasionally prolong life Favorable responses to treatment are to some degree unpredictable in the individual patient, and the physician is justified in pursuing an optimistic and aggressive therapeutic approach The specific measures available include (1) the application of local x ray therapy, (2) radioactive gold in recurrent pleural effusions, (3) nitrogen mustard, triethylene melamine and related compounds in lung cancer, in selected cases of metastatic carcinoma and in the lymphomatous diseases, (4) hormonal control procedures in metastatic breast and prostatic cancer, (5) radioactive iodine in selected cases of metastatic thyroid cancer, and (6) the adrenocortical hormones, the folic acid antagonists and 6-mercaptopurine in acute leukemia

Acknowledgment We wish to express our appreciation to the Medical and Surgical Services of Memorial Center for the use of some of their case records

REFERENCES

1 BALDWIN, E. DEF, COURNAND, A, and RICHARDS, D W, JR Pulmonary insufficiency II A study of 39 cases of pulmonary fibrosis. *Medicine* 28 1–35, 1949

2 BURCHENAL, J H The treatment of leukemia. *Bull New York Acad Sci*, 30 429–447 1954

3 GAENSLER, E. A, MCKAY, D G, WARE, P F and LYNCH, J P Cytological changes in bronchogenic carcinoma following treatment with nitrogen mustard (methyl bis (B-chloroethyl) amine) *Arch Path*, 46 503–518 1948

4 KARNOFSKY, D A Triethylene melamine in treatment of lymphomas and leukemias. *Clin North America*, 38 541–554 1954

5 KARNOFSKY, D A, ABELMANN, W, CRAVER, L and BURCHENAL, J H The use of nitrogen mustards in the palliative treatment of carcinoma with special reference to bronchogenic carcinoma *Cancer*, 1 634 656 1948

6 KENT, E M and MOSES C Radioactive isotopes in the palliative management of carcinoma of the pleura *J Thoracic Surg*, 22 503 516 1951

7 MAYER, E and ROSWIT, D Newer palliative measures in the management of inoperable bronchogenic carcinoma *Dis of Chest* 21 491–512, 1952

8 PEARSON, O H, WEST, C D, HOLLANDER, V P and TREVES, N E Evaluation of endocrine therapy for advanced breast cancer *J A M A*, 154 234–239, 1954

9 PEARSON, O H, WEST, C D, LI, M C, MACLEAN, J P and TREVES, N Endocrine therapy of metastatic breast cancer *Arch Int Med*, in press

10 RAWSON, R W, RALL, J E and ROBBINS, J Uses and misuses of radioactive iodine in treatment of cancer of thyroid *Arch Int Med*, 92 299–307, 1953

11 STORSTEIN, O Circulatory failure in metastatic carcinoma of the lung A physiologic and pathologic study of its pathogenesis *Circulation* 4 913–919, 1951

97

Radioisotope Therapy

B. Roswit, M.D., New York, New York

From the Radiotherapy Service and Radioisotope Service, Veterans Administration Hospital, Bronx, New York

Artificial radioactive isotopes have been widely utilized in clinical investigations for nearly two decades. Yet of the more than eighty artificially produced radioisotopes presently available, only twelve have been found useful in the treatment of human illness. Of these only four (I-131, P-32, Au-198 and Co-60) are now being clinically utilized in the treatment of diseases of the chest, principally pulmonary cancer. Nevertheless, many palliative benefits have thus been gained. They may be measured in terms of relief from distress and disability, and occasional prolongation of useful and comfortable life.

Particularly in bronchogenic carcinoma is there an urgency for an exhaustive investigative study of every possible radiotherapeutic agent, because the vast majority of such patients, when first diagnosed, are already beyond hope for cure by surgical means. Radiation therapy is today shouldering the burden of treatment in the inoperable case to an increasing degree and is doing useful work in relieving suffering in a way which is not possible at present by any other means.

In this discussion we shall review the current role of radioisotopes in the treatment of pulmonary cancer, describing the guiding principles of treatment, the clinical benefits to be expected as well as the hazards entailed. For this review we shall draw largely upon published reports from other radioisotope laboratories both here and abroad, as well as upon our own experience in this field.

The criteria for an "ideal" radioisotope suitable for use in the treatment of pulmonary disease, principally neoplastic, include: (1) prompt and selective localization in the diseased tissues (which must be radioresponsive), (2) optimum half life, 14 hours to 14 days, (3) well understood biologic behavior—distribution, excretion and localization, (4) suitable radiation spectrum, (5) low toxicity, and (6) availability. It appears that I-131, P-32 and the colloidal suspensions of Au-198 and P-32, as presently employed, barely qualify as "ideal" therapeutic agents for internal administration in intrathoracic cancer.

The therapeutic applications may be considered in the following categories: (1) selective absorption (e.g., radioiodine in intrathoracic metastases from cancer of the thyroid), (2) macrophage phagocytosis (e.g., colloidal suspension of Au-198 and P-32 in treatment of malignant effusion), (3) physical placement (e.g., interstitial, transbronchial and intravenous applications of colloidal suspensions of radioelements in accessible neoplasms), (4) external radiation source (e.g., cobalt-60 gamma ray therapy for deep-seated bronchogenic carcinoma).

THYROID CANCER—INTRATHORACIC METASTASES

Radioiodine Therapy (I-131). Although more than eight years have elapsed since radioiodine was first employed in the treatment of advanced thyroid cancer, a strictly investigative approach is still mandatory in each new case. Only primary tumors and their metastatic lesions which concentrate iodine are suitable for treatment, and these are encountered in less than 15 per cent of the cases. In our laboratory, for example, only three of forty-three individuals with inoperable thyroid neoplasms were found acceptable for aggressive treatment by virtue of their initial or induced concentration of I-131. Large mediastinal tumors regressed under treatment in two of our patients for two and three years, respectively. In one case a striking degree of rehabilitation was accomplished for a period of three years (Sorrentino, Roswit and Yalow[7]).

The failure of I-131 to concentrate in pulmonary, mediastinal or hilar metastases from an unknown source does not necessarily exclude the possibility of their being of thyroid origin.

Only a small percentage of patients will show an uptake of a tracer dose in a metastatic lesion before the remaining normal thyroid tissue is thoroughly destroyed by a heavy dose of I 131 or surgically removed The thyroid stimulating hormone of the anterior pituitary may then encourage the metastatic deposits to take up and retain significant amounts of radioiodine The uptake may be further increased in some cases by administration of propyl thiouracil or thyroid stimulating hormone

Because of the many limitations of I 131 therapy no patient with pulmonary or mediastinal metastases from cancer of the thyroid should be denied roentgen therapy if isotope treatment appears unfeasible or ineffective One of our patients has survived nearly ten years without disease after roentgen therapy for far advanced adenocarcinoma of the thyroid This patient when first seen had massive cervical mediastinal and hilar metastases associated with a large right lower lobe parenchymal lesion The clinical picture was further complicated by a fulminating superior vena cava compression syndrome The patient has remained in good health for the past ten years working regularly as a train conductor (Mayer and Roswit [illegible])

CHRONIC LEUKEMIA—PULMONARY MANIFESTATIONS

Radiophosphorus Therapy (P 32) It has long been known that rapidly proliferating tissue shows a more rapid rate of uptake of phosphorus than normal tissue This is particularly true in leukemia and forms the basis for an effective treatment modality (P 32) in chronic myeloid leukemias Involvement of the intrathoracic nodes or infiltration of the lung is not uncommon in this disease entity The pulmonary manifestations may share in the systemic and hematologic improvement which follow radiophosphorus therapy in the myeloid form of the disease The intrathoracic lesions of chronic lymphatic leukemia lymphosarcoma and Hodgkin's disease on the other hand are best treated by means of roentgen therapy It will be of interest to follow further developments in the Au 198 precipitate therapy proposed by Muller and Rossier[illegible] for lymphomas Huge radiogold particles are delivered to the lung via the intravenous route by these investigators creating a form of radioactive microembolic therapy

MALIGNANT PLEURAL EFFUSIONS

Radiogold Therapy (Colloidal Suspension—Au 198) Recurrent pleural effusion intensifies the suffering of a large group of patients with inoperable carcinoma of the lung or pleura both primary and metastatic Repeated thoracentesis soon becomes complicated by pneumothorax or infection further burdening the patient's already slender survival period The cause of the malignant effusion is still poorly understood it may be the result of multiple cancer seedings or implants on the pleural membrane tumor compression of drainage tracts interference with the dynamics of fluid transfer across the pleural membrane or any combination of these various factors

Roentgen therapy has occasionally been helpful but the results of conventional therapy have been generally disappointing A radioisotope in colloidal suspension emitting energetic beta particles can be easily introduced into the pleural space delivering superficial radiation to the pleural membrane without traumatizing the underlying lung or harming other critical tissues such as the bone marrow The insoluble colloidal particles are soon found on the serous membrane largely phagocytosed by macrophages Muller[illegible] first used zinc-63 to attain these objectives but the half life of this agent is extremely short (38 3 minutes) Hahn found that a radiogold (Au 198) colloid satisfied the therapeutic criteria very well This agent is now in use in hundreds of clinics both here and abroad Reports of favorable clinical results have come from Andrews and his colleagues[illegible] Clark and LeRoy[illegible] Kent and Moses[illegible] King et al[illegible] Seaman Sherman and Bonebrake[illegible] Storaasli et al[illegible] and Walter[illegible]

Physics Au 198 is easily created in the pile by neutron gamma reaction from an abundant parent Au 197 It is economically produced in high activity and is readily converted to a metallic colloid of extremely stable form quite amenable to autoclaving The half life of Au 198 is 2 7 days and the radiation spectrum contains a beta particle of 0 98 mev energy and a gamma ray of 0 41 mev In the pleural membrane fully 95 per cent of the radiation effect is produced by the beta particles The maximum range of the beta particle in tissue or water is 3 8 mm but 90 per cent of the energy is dissipated in the first millimeter The gold is supplied commercially in a suspension of colloid particles approximately 003 microns in size

Biology Metallic gold is insoluble in body fluids and practically all of the injected material remains in the pleural space After injection it is flocculated in large aggregates upon the pleural membrane resting principally in the macrophages Its mode of action in the control of effusions is not yet clearly understood but it is presumed that the effect of radiation on the superficial surface of the neoplastic tissue which may line the pleural cavity is of some importance Other assumptions include (1) impact of radiation on normal serous membrane with alteration of the dynamic process of diffusion (2) radiation effect on the small blood vessels in the serosa, and (3) destruction of floating cancer cells Kniseley and Andrews[34] found uneven distribution on cavity surfaces Most particles were phagocytosed only a fraction remaining in the colloidal suspension usually enmeshed in fibrin Deposition in the regional lymph nodes was slight and inconsistent Tracer studies in our laboratory reveal that this radiocolloid sometimes may remain in the pleural fluid for several days without deposition on the pleural surface In such instances little or no clinical benefit may be expected

Pathology A diffuse radiation pleuritis is produced with inhibition of fluid accumulation There is a fibrous thickening of the pleura varying widely in degree with extensive adhesions and pocketing of the fluid after multiple injections Radiation changes in the tumor are not prominent, being limited only to superficial areas (Kniseley and Andrews[34])

Method The material is received in a cherry red colloidal suspension containing 10 to 25 mc of Au 198 per ml A thoracentesis is performed and most of the pleural fluid is removed If a fibrinous or bloody sediment is found some investigators lavage the pleural space because gold may be concentrated in this sediment instead of flocculating directly upon the pleural surface (Rubenfeld[44]) After the injection the patient is required to change position frequently to assure thorough distribution In several cases we have utilized an automatic rocking bed for this purpose The dose level varies in different clinics ranging from 50 to 150 mc Despite the growing tendency to give single massive doses (about 150 mc) Andrews and his group[2] prefer to give 75 mc as the initial dose to be followed by larger doses after several weeks

Equipment A variety of systems for intrapleural administration of radiogold has been reported (Andrews et al,[2] Rose Osborne and Stevens[40] Taplits[60] and Ter Pergossian and Sherman[61]) In our own laboratory an apparatus has been devised which is simpler to handle than those previously described and offers additional safety features for medical and laboratory personnel as well as for the patient (Yalow and Cohen[64]) The operating principle is the transfer, without direct handling of suitably diluted radiogold into the patient by the hydrostatic pressure of a siphon system Since syringe pressure is not used to force fluids through the system danger of blowouts is avoided (Fig 1A) Ter Pogossian and Sherman[6] outlined in detail the necessary laboratory facilities and equipment required in receiving diluting administering and monitoring Au 198 according to the specifications of the Atomic Energy Commission Several important handbooks on radioisotope handling are now available on request from the National Bureau of Standards Washington D C

Radiation Hazards The entire administration procedure usually requires about three minutes with the bulk of the radioactivity passing into the patient in about half a minute The radiation received at 3 feet from the shielded bottle is less than 1 milliroentgen per hour per 100 mc The radiation during the transfer itself is not readily measurable since the time of transfer is so short The physician who may wish to steady the tapping needle with a clamp would receive less than 10 mr per 100 mc to his hands while his body receives 7 mr Others entering the room receive less In fact with this procedure radiation from patient after treatment represents the only potential hazard At intervals after the administration of the agent the patient is monitored with a portable rate meter When 100 mc are given there is usually an activity of 50 mr hr at the edge of the patient s bed and 5 mr hr at 5 feet from the patient (It is well to recall that the maximum daily permissible dose is 50 mr) The patient must be at least 6 feet from other patients A nurse is permitted to be within 2 feet of such a patient for a maximum of twenty minutes a day The time can be doubled after three days due to physical decay of the radioisotope

Selection of Patients The measure of success in this therapeutic procedure appears to be directly related to the maintenance of strict

FIG. 1. A. Technique and apparatus for intrapleural therapy with radioactive colloidal gold utilizing the hydrostatic pressure of a siphon system. Massive lead chamber shields container holding Au ¹⁹⁸. Personnel remain at a distance from patient during treatment for safety from penetrating gamma radiation.

B. Method for intrapleural administration of radioactive colloidal chromic phosphate ($CrP^{32}O_4$). A conventional 1 cc. glass syringe is used, shielded by a 10 mm. plastic cylinder which provides complete protection against the beta rays. The absence of a gamma ray in P³² makes for relative ease and safety in delivering the treatment and in subsequent patient management.

criteria in the selection of patients. Suitable patients for radiogold therapy are those in relatively good condition likely to survive long enough to enjoy the benefits of treatment. Patients who appear to be getting rapidly worse or already in a preterminal state are not often helped. A simple tracer study over a period of several days may help in selecting those patients in whom the colloid is promptly flocculated on the serous membrane. Kent and Moses[31] have found that patients whose primary lesion is an adenocarcinoma are most difficult to palliate. The site of origin appears to have no material effect on the outcome. When bulky tumors are present, roentgen therapy should be more useful. Patients with serous fluid are more likely to be benefited than those with sanguineous effusions and much fibrin sediment (Rubenfeld[34]). In some clinics radiogold is instilled in the immediate postoperative period after pulmonary resection for cancer, in an attempt to destroy floating tumor cells on tiny pleural implants (Kent and Moses,[31] and Rose, Osborne and Stevens[49]).

Results of Treatment. In favorable cases the fluid becomes clear, contains less blood and fails to reaccumulate. Even in favorable cases there may sometimes be considerable lag between the administration of the isotope and the cessation of fluid formation. Andrews and his colleagues[2] mention the disappearance of malignant cells from the fluid aspirated from these cavities. When fluid is well controlled patients experience a distinct improvement in general well being. In forty cases reported by Seaman, Sherman and Bonebrake palliation was achieved in approximately one-half the number of patients. Favorable results have been documented by most clinics.[2,3,11,30,31,33,34,41]

Of forty-one patients treated by Kent and Moses[31] pleural effusion was completely arrested in twenty-five cases (60.9 per cent). In nine other patients (21.9 per cent) the effusion was unquestionably checked, as demonstrated by the need for aspiration at much less frequent intervals. In this group the distribution of pulmonary lesions was as follows: bronchogenic carcinoma, twenty-eight cases; carcinoma of

the breast, ten cases, pelvic cancer, two cases sarcoma of abdominal wall, one case

In our own preliminary experience with this agent most of the patients died of far advanced disease too soon for evaluation of treatment The dose employed, 35 mc, is now generally regarded as inadequate However, this group served well in the development of effective technics and in tracer studies

Reactions and Complications Severe impairment of blood elements has been rarely observed,[8] and such effects are usually transitory, followed by complete recovery Systemic radiation reactions are unusual even when doses of 150 mc have been employed There may, however, be evidence of distinct pleuritis, with friction rub, accompanied by pleural and diaphragmatic pain

Limitations of Au-198 (1) Although the penetrating gamma radiation contributes about one twentieth of the radiation effect in the pleura and provides an effective label, this component of Au-198 creates problems in personnel protection during the period of preparation, administration and in the post-injection period (2) The patient himself emits gamma radiation and must be hospitalized and restricted as long as more than 30 mc are retained in his body (United States Atomic Energy Commission regulations) (3) Large shipments over long distances from the commercial source become relatively expensive (4) The half life is too short (5) Tissue penetration of the beta particle is too shallow (6) Transfer of particles to pleural membrane is not consistent These limitations and hazards of Au-198 therapy stimulated our interest in the use of a pure beta emitter with a longer half life and more energetic beta particles Radiophosphorus appeared to satisfy these criteria and a colloidal suspension of $Cr\ P^{32}\ O_4$ was prepared by the Abbott Laboratories under the direction of Dr D Tabern

Radiophosphorus Therapy (Colloidal Suspension—$Cr\ P^{32}\ O_4$)—Advantages of Colloidal $Cr\ P^{32}\ O_4$ This agent has several theoretic advantages over radiogold, including (1) longer half life (14 3 days), most of the radiation being expended over a period of six to eight weeks, an optimum time interval in radiotherapy of most neoplasms, (2) more energetic beta particle penetrating more deeply into tissue (maximum of 8 mm compared to 3 8 mm for Au-198) (3) absent gamma component therefore greater safety, economy and convenience in shipping handling, administration and management of the patient after treatment, (4) greater ionization and destruction action per disintegration, (5) hospitalization is not required, (6) the P-32 beta particle

will affect a volume of tissue 50 times greater than that of the average Au-198 beta particle Flocculation on the pleural surface is prompt, and consistent, and fairly homogeneous In the first eight patients studied there was prompt and almost complete disappearance of the material from the pleural fluid within less than twenty-four hours in every case, and in most cases in less than fifteen minutes We have gathered good evidence that after injection most of the radioactivity remains on the walls of the injected cavity [3] Doses of 10 to 20 mc in less than 10 cc of fluid were injected through the aspirating needle after most of the pleural fluid was removed As in radiogold therapy, the patient was made to change position at frequent intervals after treatment (Fig 1B)

Results of treatment in a series of treated cases will be discussed in a later communication [52 53] It is of interest that one of our patients with intrathoracic lymphosarcoma and massive recurrent pleural effusion, unresponsive to conventional therapy, has remained fluid-free for $2\frac{1}{2}$ years (Fig 2) after intrapleural therapy with colloidal Cr P^{32} O_4 Jaffe[28] has obtained good results with this agent in approximately twenty of thirty patients with carcinomatous pleural effusion

Colloidal yttrium-90, with a pure beta emission of high energy (2 18 mev) and half-life of 2 54 days, is being studied in several clinics for intrapleural and interstitial therapy No clinical data are yet available

INTERSTITIAL THERAPY

Extension of malignant disease to hilar and mediastinal nodes is frequently encountered at operation for bronchogenic carcinoma and represents the principal reason for failure to salvage the patient by surgical means An effective method for intensive local irradiation of non resectable nodes and other extensions of the neoplasm would be desirable at the time of surgery, to be followed by radical roentgen therapy Radon seeds have occasionally been utilized by thoracic surgeons in this manner in an attempt to retard the malignant growth, but artificial radioactive sources are far more versatile and less hazardous to the operator

Radioactive Gold Seeds (Au-198) Radioactive gold seeds of the required number and strength may be instantly cut to order in the operating room from previously irradiated gold wire Gamma ray therapy is provided by shielding out the beta particles with gold tubing or sheathing [24 45] British investigators have designed and utilized a new instrument in the form of an automatic gun for implanting radioactive gold seeds or grains into tumors with great precision This instrument as well as the platinum-filtered gold grains, is always available to the surgeon at the time of exploratory operation

Radioactive Colloidal Gold (Au 198) Any well encapsulated, discrete neoplasm can be infiltrated with a radiocolloid beta emitter, as a means of delivering intensive ionizing radiation Despite primary difficulties in achieving homogeneous infiltration and in dosage determination, radioactive gold (Au 198) may come to be a valuable adjunct in the management of advanced carcinoma of the prostate[22] and in cancer of the female pelvis [46] It may well be applied to radiotherapy of inoperable bronchogenic carcinoma The awkward heavy, lead shielded syringe generally employed to reduce the exposure to the operator can now be replaced by a pneumatic remote control precision injector for use in the operating room Radioautographic and roentgenographic technics have been developed to evaluate the effectiveness of the radiocolloidal localization in any site [26]

Radioactive Colloidal Cr P^{32} O_4 Allen Hempelmann and Womack[1] were the first to employ insoluble radioactive chromic phosphate in interstitial irradiation of cancer (in experimental animals) We have explored its usefulness over the past three years in twenty four patients with a variety of inoperable tumors including metastatic bronchogenic carcinoma [27] In selected cases it may prove to be a valuable palliative adjunct to roentgen therapy It can be safely handled in a conventional glass syringe shielded by a cylinder of lucite 10 mm thick Although an optimum dose level has not yet been established, tumor regression has been noted in a dose range from 30 to 100 μc per gm of malignant tissue Injections are made in geometric patterns, simulating radium needle implantation Forcible injection is avoided, the material being released as the needle is withdrawn The findings in this study will be reported in a later communication [51] It may be of interest that Jaffe[28] has noted tumor regression in eighteen of twenty-eight patients whose prostatic cancers were injected with radioactive colloidal chromic phosphate A three-year

arrest of a malignant mixed tumor of the tongue was reported by Mumma[44] after injection with this radiocolloid. A well documented experimental study of body distribution and tissue effects has recently been reported by McCormick, Milles, Jaffe and Seed.[40]

TRANSBRONCHIAL THERAPY

Meneely and colleagues[41,42] showed that when a colloidal suspension of Au-198 is given via the bronchus, the fluid vehicle is absorbed and the gold remains for many days in the lung parenchyma, delivering large doses at therapeutic levels. Lungs thus treated show striking gross radiation changes and the bone marrow is not affected. However, the gold colloid drains very slowly via the regional lymphatics, taking from ten to fourteen days to develop concentrations sufficient to permit adequate radiation of the lymph nodes. Since the half-life of Au-198 is only 2.7 days, it would thus appear to be less than ideal for irradiating the regional lymph nodes.

Silver-111 (half-life 7.5 days) was found by Hahn and his group[23] to be rapidly transported to the regional lymphatics after endobronchial administration. Hahn and Carothers[20,21] also prepared a radioactive gold colloid (Au-198) coated with inactive silver which was removed from the lung parenchyma in considerable proportions, appearing promptly in the lymphatic nodes draining the particular lung region. Lymph node dosage was estimated to be of the order of 70,000 equivalent beta roentgens. Only negligible quantities of the material apparently gained access to the circulation. Surprisingly little radioactivity was found in the contralateral lobe. In every instance, however, there was drainage to the contralateral lymph nodes. This is particularly significant in view of the fact that unilateral primary lesions of the lung and breast are frequently associated with spread to lymph nodes on the contralateral side.

Since radiogold colloids remain in the lung parenchyma for long periods, and silver-coated radiogold colloids are transported to regional lymph nodes in high concentration, the possibility of utilizing both these agents in combination remains to be exploited. Hahn and Carothers[19] further propose the utilization of a gold isotope of a very high specific activity—Au-199 (half-life 3.3 days, with beta emission of 1.01 mev and gamma ray of 0.45 mev).

Bryant, Burke and Christophersen[10] were also able to deliver effective radiation to specific segments of the lung and to regional lymph nodes as well by direct instillation of radiogold colloid into a single lobe through the bronchoscope (using a urethral catheter) or by direct injection into the submucosa of an intermediate bronchus by means of a long needle (through the bronchoscope). In the latter instance phagocytic activity carried the colloid through the lymph channels to the nodes. No liver damage was demonstrable in any of the animals. The authors suggest that a combination of these two methods may be a means of supplying radiation for palliation in patients with inoperable cancer of the lung involving hilar and mediastinal nodes.

INTRAVENOUS THERAPY

Selective fixation of a radioisotope in the human lung via the intravascular route was first accomplished by Muller and Rossier.[43] Zinc-63 was injected intravenously in the form of a non-soluble dispersoid sulfide, resulting in diffuse microembolism in the lung capillaries. This treatment was tolerated well, and in one patient a very large squamous cell carcinoma of the bronchus was reduced to a small fibrous rest. Zinc-63, however, has a very short half-life (38.3 minutes), which renders its general use unfeasible. Nor can the colloidal radiogold now widely employed for intrapleural use be utilized for intravenous therapy. The very small particles which make up this material (.003μ) will be passed through the lung capillaries to lodge in the reticuloendothelial system. Muller and Rossier[43] therefore utilized a radiogold precipitate of particle size 1,000 times larger than those of colloidal gold. The radiogold precipitate was thus localized within a single lobe of the lung by directing an intravenously introduced cardiac catheter (under roentgen control) into a predetermined pulmonary artery or a division branch. Calculated doses of 16,000 reps were thus delivered into the lung parenchyma.

TELECURIE THERAPY

Cobalt-60 (half-life 5.3 years) provides a powerful source of radiation equivalent to that produced by a 2 million volt x-ray therapy machine and can thus be employed as a substitute for the x-ray tube and generator. Such high energy radiation has brought tangible

palliative benefits to patients with deep-seated cancer involving the thorax abdomen or pelvis Radiation in the range of 1 to 3 mev, when compared with conventional radiation (0 20 to 0 26 mev) has greater reaching power to the deep tumor and produces less skin reaction less bone damage and little radiation sickness The delivery of a more effective tumor dose now becomes feasible with probable improvement in clinical results The greater risks involved in more radical therapy in the region of the lung may possibly be ameliorated by the use of cortisone and ACTH (Cosgriff and Kligerman [12] and Friedenberg and Rubenfeld[15])

Cobalt 60 teletherapy units are rapidly coming into use in many clinics throughout the country Fried[14] has treated eighty three patients with inoperable lung cancer employing one of the first cobalt 60 gamma ray units in this country He states that the patients tolerated the treatment well and the clinical results have definitely been improved compared with those achieved with conventional equipment

Other useful nuclear sources of high energy radiation include iridium 192 (utilized in England) and cesium 137 now in use at Oak Ridge for telecurie therapy

SUMMARY AND CONCLUSIONS

1 In this discussion we have reviewed the present role of radioisotopes in the treatment of pulmonary diseases notably intrathoracic cancer including the indications and guiding principles for therapy, clinical results to be expected and hazards involved We have drawn largely upon the reported experiences of other radioisotope laboratories both here and abroad including our own experience in this field

2 Of the more than 80 artificially produced radioisotopes now available only four (I 131 P 32 Au 198 and Co-60) are today being clinically utilized in the treatment of pulmonary cancer Nevertheless the effort has been rewarding when appraised in terms of relief of distress and disability and prolongation of useful life

3 A variety of new applications of these versatile agents has been described for better management of patients with inoperable cancer of the lung They include intrapleural transbronchial interstitial telecurie therapy and intravenous technics for more effective delivery of ionizing radiation to the diseased tissues A final evaluation of their therapeutic benefits while not yet possible will be awaited with great interest

REFERENCES

1 ALLEN H HEMPELMANN L H and WOLFACK N A Effect of insoluble radioactive phosphorus (chromium phosphate) when applied interstitially in the treatment of adenocarcinoma of man n s inn ce Cancer Research 5 239 1945

2 ANDREWS A ROOT S W KERMAN H D and BIGELOW R R Intracavitary colloidal radioactive gold in the treatment of effusions caused by malignant neoplasms Ann Surg 137 3[illegible] 1953

3 ANDREWS G A ROOT S W and KAISELEY R M Metabolism and distribution of colloidal Au injected into serous cavities for treatment of effusion associated with malignant neoplasms Cancer 6 294 1953

4 BATLEY F Cobalt[60] teletherapy some principles and observations J Canad A Radiologists 4 66 1953

5 BERCU B A and MANDELL H N Radioactive iodine for chronic lung disease J Clin Investigation 33 917 1954

6 BERG H F CHRISTOPHERSEN W M ISAACS A M and BRYANT J R Localization of radioactivity in regional lymph nodes Arch Surg 6[illegible] 228 1953

7 BLACK M B WOOLNER L B and BLACKBURN C M The uptake of radioactive iodine by carcinoma of the thyroid gland a study of 128 cases J Clin Endocrinol 13 1378 1953

8 BOTSFORD T W WHEELER H BROWNELL A ROBERT A and JAQUES W E Hypoplasia of bone marrow associated with radioactive colloidal gold therapy J A M A 151 [illegible] 1953

9 BRUCER M Radiation hazards and protection in a hospital J A M A 147 1745 1951

10 BRYANT J R BURKE H F and CHRISTOPHERSON W M Localization of radioactivity in the lung and the lymph nodes. J Thorac Surg 26 22 1953

11 CLARK T H and LEROY G B Experience with radioactive gold [illegible] Proc Inst Med Chicago 1[illegible] 64 1950

12 COSGRIFF S W and KLIGERMAN M M Use of ACTH and cortisone in the treatment of post irradiation pulmonary reaction Radiology 5[illegible] 537 1951

13 FREUNDLICH H F and HAYBITTLE J L Improved iridium 192 teletherapy unit Acta radiol 39 231 1953

14 FRIED J R Two years experience with cobalt 60 beam therapy (Personal communication December 1954)

15 FRIEDENBERG R M and RUBENFELD S The role of cortisone in preventing fibrosis following irradiation Am J Roentgenol [illegible] 271 1954

16 GETZOFF P HIDALGO J and MEYER J A Syringe shield used in injecting radioactive gold J A M A 152 1431 1953

17 GOODELL J P B SHEPPARD C W and HAYS P F Colloidal gold containing the radioactive isotope Au[198] in the selective internal radiation

therapy of diseases of the lymphoid system *J Lab & Clin Med* 32 1437 1947

18 HAHN P F A Manual of Artificial Radioisotope Therapy New York 1950 Academic Press Inc

19 HAHN P F and CAROTHERS E L The use of radioactive colloidal gold in the treatment of malignancies *Nucleonics* 6 54 1950

20 HAHN P F and CAROTHERS E L Lymphatic drainage following intrabronchial instillation of silver-coated radioactive gold colloids in therapeutic quantities *J Thoracic Surg* 25 265 1953

21 HAHN P F and CAROTHERS E L Radioactive metallic gold colloid coated with silver and their distribution in the lung and its lymphatics following intrapulmonary administration therapeutic indications in primary lung and bronchogenic tumors *Brit J Cancer* 5 400 1951

22 HAHN P F GOODELL, J P B SHEPPARD C W CANNON R O and FRANCIS H C Direct infiltration of radioactive isotopes as a means of delivering ionizing radiation to discrete tissues *J Lab & Clin Med* 32 1432 1947

23 HAHN P F ROUSER G BRUMMITT H MOORE HEAD J and CAROTHERS E L The drainage of radioactive silver colloids by the lymphatics following intrapulmonary administration in dogs *J Lab & Clin Med* 39 624 1952

24 HENSCHKE U K JAMES A G and MYERS W G Radiogold seeds for cancer therapy *Nucleonics*, 11 46, 1953

25 HERVE A and CLOSAN J Distribution in the organism of radioactive chromic phosphate injected intravenously *Acta radiol* 35 257 1951

26 HIDALGO J A BURNS E and NIESET R T A technique for evaluating the effectiveness of localization of radioactive colloidal gold ^{198} after direct injection into tumors *Am J Roentgenol* 72 658 1954

27 HOLT H J SINCLAIR W K and SMITHERS D W A gun for interstitial implantation of radioactive gold grains *Brit J Radiol* 25 419 1952

28 JAFFE H L The interstitial use of radioactive chromic phosphate in therapy Symposium on Radioisotopes in Medicine Oak Ridge Institute of Nuclear Studies September 1953

29 JONES H B WRODEL C J and LYONS W K Method of distributing beta radiation to the

the pleura *J Thoracic Surg* 22 503 1951

31 KENT E M and MOSES C Radioactive isotopes as an aid in the palliation of intrathoracic carcinoma Proceedings of the Second Annual Cancer Conference Part II p 939 1952

32 KERR H D FLOCKS R H ELKINS H B and CULP D The treatment of moderately advanced carcinoma of the prostate with radioactive gold *Am J Roentgenol* 69 969 1953

33 KING E R SPICER D W DOWDA N F BENDER, M A and NOEL, W F The use of radioactive colloidal gold in pleural effusion and ascites associated with malignancy *Am J Roentgenol* 68 413 1952

34 KNISELEY R M and ANDREWS G A Pathological changes following intracavitary therapy with colloidal Au ^{198} *Cancer* 6 303 1953

35 LEVINE M H Radioiodine therapy of intractable emphysema a report on 14 patients (Personal communication October 1954)

36 MACKSTROTH C U and CURTIS G M Criteria for therapy of malignant thyroid lesions with I^{131} *Arch Surg* 67 187 1953

non resectable pulmonary neoplasms—primary and metastatic *New York State J Med* 53 1637 1953

39 MAYER, E and ROSWIT B Newer palliative measures in the management of inoperable bronchogenic carcinoma *Dis of Chest* 21 491 1952

40 MCCORMICK, J B MILLES G JAFFE H and SEED L Tissue distribution of injected radioactive colloidal chromic phosphate ($CrP^{32}O_4$) *Arch Path* 58 187 1954

41 MENEELY G R AUERBACH S H WOODCOCK C C KORY R C and HAHN P F Transbronchial instillation of radioactive gold colloid in the lung of the dog *Am J M Sci* 225 172 1953

42 MENEELY G R KORY R C AUERBACH S H and HAHN P F Distribution of radioactive colloidal gold following intrapulmonary administration *Federation Proc* 10 365 1951

43 MÜLLER J H and ROSSIER, P H New methods for treatment of cancer of the lung by means of artificial radioactivity (Zn 63 and Au 198) *Acta radiol* 35 449 1951

44 MUMMA C S Treatment of mixed tumors of the tongue with radioactive chromic phosphate solution *Arch Otolaryng* 58 192 1953

45 MYERS W G COLMERY B H WALDRON M and MCLELLON M C Radioactive gold 198 for gamma radiation therapy *Am J Roentgenol* 70 258 1953

46 NIXON J J and ROSWIT B Roentgen therapy and radioisotope therapy In Cancer of the Lung Editors Mayer E La Due J and Nixon J J New York (to be published) New York University Press and American Cancer Society

47 RALL, J E MILLER, W N, FOSTER, C G PEACOCK, W C and RAWSON R W The use of thiouracil in the treatment of metastatic carcinoma of the thyroid with radioiodine *J Clin Endocrinol* 11 1273 1951

48 ROOT S W TYOR M P ANDREWS G A KNISELEY R M Distribution of colloidal radioactive chromic phosphate after intracavitary administration

50 ROSWIT B Chapter XII in Cancer of the Lung Editors Rosenblatt M Bonal and Lea, J R Oxford Press, 1956 Chapter 14 in Pulmonary Carcinoma Editors Meyer E and Maier H C, New York University Press, Lippincott 1956

51 ROSWIT, B and NEWERLY, K Interstitial radiation of inoperable neoplasms with radioactive colloidal chromic phosphate ($CrP^{32}O_4$) (Unpublished data)

52 ROSWIT, B, NEWERLY, K and BERLIN, H Treatment of malignant pleural effusion with radioactive colloidal chromic phosphate ($CrP^{32}O_4$) (Unpublished data)

53 ROSWIT, B and LA DUE J Chapter 17, Second ary malignancies in the lung In Pulmonary Carcinoma Editors Mayer E, and Mater, H C New York University Press, Lippincott, 1956

54 RUBENFELD S Experience with malignant pleural effusion treated by intracavitary colloidal radiogold in 75 patients (Personal communication, December 1954)

55 SEAMAN W B SHERMAN, A I and BONEBRAKE, M Radioactive gold in the treatment of effusions J A M A 53 630, 1953

56 SHERMAN A I BONEBRAKE, M and ALLEN W Application of radioactive colloidal gold in the treatment of pelvic cancer Am J Roentgenol, 66 624 1951

57 SORRENTINO J, ROSWIT B and YALOW, R A Thyroid carcinoma with multiple metastases and pathological fracture successfully treated with radioiodine Radiology, 57 729, 1951

58 STORAASLI, J P, BONE, F J, KING, D P and FRIEDELL, H L The use of radioactive colloidal gold in the treatment of serous effusions neoplastic origin Surg, Gynec & Obst, 96 70 1953

59 STURGEON, C T DAVIS, F E, CATZ, B, PETIT D and STARR, P Treatment of thyroid cancer metastases with TSH and I^{131} during thyroid hormone medication J Clin Endocrinol, 13 1378, 1953

60 TAPLITS, S A pneumatic remote control precision injector for interstitial and intracavitary injection of radioactive colloidal gold Am J Roentgenol, 72 655, 1954

61 TER POGOSSIAN, M and SHERMAN, A I Handling of radioactive gold for therapeutic purposes Nucleonics 10 23 1952

62 WALTER, J Radioactive gold in malignant effusions Proc Roy Soc Med, 46 466, 1953

63 YALOW, A Dosimetry of therapeutic use of internally administered radioisotopes (In press personal communication June, 1954)

64 YALOW, R S and COHEN, B B Apparatus for intracavity administration of colloidal gold Nucleonics, 11 65 1953

65 ZILVERSMIT, D B, BOYD, G A and BRUCER, M The preparation and particle size measurement of mono-disperse radioactive gold colloids J Lab & Clin Med, 40 261, 1952

98

"Coin" Lesions—Medical and Pathologic Aspects

HAROLD GUYON TRIBBLE, M D, *Oakland, California*

A RECENT definition of "coin lesions" proposed by Storey et al [21] gives the following limiting criteria (1) 1 0 to 5 0 cm in size, (2) round or oval in shape, with sharply circumscribed borders, (3) surrounded on all sides by normal appearing lung, (4) no symptoms, (5) homogeneous in density or containing calcium and (6) solitary This would eliminate large masses with adjacent inflammatory reaction associated with atelectasis or those obviously arising in the chest wall or mediastinum It would also eliminate a typical Ghon complex

These lesions are listed in the literature under various names, such as solitary intrapulmonary tumors (Davis and Klepser,[10] Löffler, Blades and Marks[12]) isolated pulmonary nodules (Sharp and Kinsella[21]), single circumscribed intrathoracic densities (Abeles [illegible] since [illegible], of solitary circumscribed lesions (Hodgson and McDonald[22])

The term "coin lesion" is adequately descriptive from its x-ray appearance and is well understood by the profession It is not an ideal term but has achieved acceptance by common usage

Considerable literature has accumulated on this subject since Graham, in 1933 [17] showed that pneumonectomy was a feasible procedure and, in 1936,[18] reported on resection of calcified pulmonary abscess in three cases, all of which proved to be tuberculomas Alexander[4] called attention to such lesions in 1942 and, characteristically, covered the problem at that early date well and completely He pointed out that these approximately similar x ray shadows may represent diverse types of benign and malignant lesions and that any diagnosis from clinical study alone is of interest but of little importance What is of paramount importance is whether a nodule is benign or malignant and, if malignant, whether it is still completely removable Preoperative determination can be made only rarely Therefore, all patients with presumably removable nodules should be operated upon The literature to date provides ample confirmation of Alexander's point of view at that time

When an abnormal shadow of this description appears on the chest roentgenogram, there is a lamentable tendency in some quarters to "watch it" I believe that very few experienced chest physicians will agree with this practice There is a large gamut of tests now available examination of the cells and [illegible] biopsy, blood counts and chemistry, serologic studies various intradermal tests, usually for tuberculosis, coccidioidomycosis, histoplasmosis and echinococcus, various x ray procedures, including stereoscopic and body section radiography, biopsy of retrosternal and deep supraclavicular nodes, etc However, when all of these studies have been accomplished, including whenever it is thought that such a lesion may be metastatic, gastrointestinal x-ray series, urologic studies with pyelograms, gastroscopies, proctoscopies, x ray study of the bones, etc, one still sees the shadow on the x ray film without having achieved a positive and confirmed diagnosis

The problem with a "coin" lesion is not so much an exact clinical diagnosis as an immediate and pressing question of whether or not this x ray shadow represents carcinoma This question can usually be answered definitely only by exploratory thoracotomy If the shadow represents carcinoma, no time can be lost in removing it—no time can be lost in establishing the exact diagnosis and following through with

the necessary surgery which, with most men, would be total pneumonectomy if the condition of the patient permits Many of these lesions will be benign tuberculomas and other granulomas, in which case a few days' or weeks' delay would be of less importance However, there must be a very brief portion of time when a carcinomatous lesion can be entirely resected There is another instant after which any surgical procedure now known would be too late because the original lesion would have already metastasized Time then is of the essence It would, therefore, not seem wise to embark on time-consuming differential diagnostic procedures, most of which are likely to be negative, as emphasized by Wolpaw [36]

Carcinoma of the lung is obviously increasing (Boyce[7]) Adler,[3] in 1912, could collect only 374 cases of carcinoma of the lung from the world literature In 1950, there were 21,219 deaths recorded from carcinoma of the lung in the United States alone [32] Surgery is the only means we have at this time to cure carcinoma of the lung completely Surgical results, at best, are not as favorable as we would like Too many patients come to the surgeon in advanced stages and are already inoperable when first seen As pointed out by Boyce,[7] it is disastrous to assume that because pneumonectomy is not accomplishing very much it is a dangerous and useless operation It is no longer dangerous and the reason it is accomplishing so little is that there are so few opportunities to demonstrate its possibilities How, then, can we afford not to make a positive diagnosis of the lesions visible by x ray in order to rule out carcinoma as the cause of the abnormal shadow?

REVIEW OF THE LITERATURE

Abeles and Ehrlich,[1] in a study of forty-four patients carefully worked up, showed that few diagnoses were definitely established before exploratory thoracotomy In twenty-one patients operated upon, seven had primary pulmonary malignancies Ten refused surgery, six of them on the advice of their family physicians, in five of the ten definite malignancy subsequently developed

Davis and Klepser[10] had a similar experience in some sixty seven cases in which thirty seven (55 per cent) were malignant In forty cases referred in private practice, twenty-eight (70 per cent) were malignant, the average age being 52 9 years In the sixty seven cases, forty seven were males and twenty females the ages varying from twenty five to seventy four years

Sharp and Kinsella,[31] in discussing the significance of the isolated pulmonary nodule reported ninety-six cases over a four year period Their patients ranged in age from twelve to eighty five years Growth of a nodule is not necessarily a sign of cancer for it was noted in fibroma, hamartoma, adenoma and granuloma, while lack of growth for many months may be observed in carcinoma In forty-one of their ninety six cases, surgical exploration was refused and a confirmed diagnosis was not available. In the other fifty five patients the diagnosis was proved fifteen (27 per cent) of these were malignant twenty two (40 per cent) inflammatory, and eighteen (33 per cent) were benign tumors The authors concluded that the only reliable and accurate diagnostic procedure is exploratory thoracotomy, with excision and prompt pathologic examination of the mass Even with the lung exposed in the surgeon's hand it is often impossible to state accurately the nature of the nodule, and they believe that, in general, indirect studies cannot be expected to furnish the answer At the beginning of their study Sharp and Kinsella made exhaustive clinical studies in attempting to reach a correct clinical

An editorial[14] poses the question, Shall these lesions be observed or operated upon for diagnosis and therapeutic considerations? It points out that there is a low operative mortality and that there is no other way to achieve a positive diagnosis In the various series of such patients reviewed and reported, 15 to 30 per cent of the lesions were malignant

Effler, Blades and Marks [12] in a study of twenty four young service personnel, found that even in this young group 15 per cent of the lesions were malignant, with no mortality from surgery itself

Grow, Bradford and Mahon,[19] reporting on 200 young service men hospitalized at Fitzsimons United States Army General Hospital found 25 [illegible] per cent of such pulmonary lesions malignant

Mahon and Forsee,[25] in a study of fifty five lesions thought to be tuberculomas, reported seven tumors, four (7 per cent) were malignant Thirteen other lesions were described and the authors stated that, in spite of employing

every possible diagnostic procedure to arrive at a correct diagnosis, each of these lesions was suspected at some time of being a tuberculoma and only on pathologic examination after removal was the correct diagnosis established They advise wedge resection to establish diagnosis They had no operative deaths It is their belief that in such cases the operative risk is no greater than in appendectomy Their patients ranged from nineteen to fifty-four years, the average age being thirty-two years

Bugden[8] aptly compares the operative procedure in "coin" lesions with that in the study of breast lesions in which biopsy is readily accepted

O'Brien, Tuttle and Ferkaney[27] believe that these lesions will usually fall into one of four groups (1) malignant or benign tumors, (2) tuberculomas, (3) chronic indolent abscesses, or (4) metastatic tumors In reporting on twenty-one patients over two and a half years of age, in almost 50 per cent of the patients operated upon the lesion was a tumor and 90 per cent of these tumors were malignant They point out that a malignant tumor will usually grow but that one cannot wait for this growth for diagnosis, as a small malignant tumor of the lung without growing in situ may metastasize extensively They further point out that the age of the patient in whom the lesion appears is not always helpful in diagnosis It is sometimes stated that under the age of forty, because most of these lesions are either benign or tuberculomas, operation is not necessary, but two patients in their series with carcinoma were under thirty-five years of age and two of the eight patients in their series with tuberculomas were over fifty

Overholt and Schmidt,[28] discussing in 1949 the silent phase of cancer of the lung stated that the problem was magnified by an astounding recent increase in numbers, yet simplified by facilities for early detection They showed that excision was feasible, relatively safe and effective, and emphasized that physicians now have the tools to find, label and successfully treat cancer of the lung In 1951, Overholt[29] pointed out that different pathologic processes in the lungs may produce identical shadows on x ray films, while conversely the same disease may produce different shadows In his series it was impossible to establish an absolute diagnosis preoperatively in more than two-thirds of the patients in whom excisional therapy was indicated He stated that in 61 per cent of the cancers seen during the past year diagnosis could not be established until after exploration In 162 cases explored, fifty eight lesions were tumors of which 67 per cent were malignant

[illegible]

lesions[30] There was almost unanimity of opinion that such lesions should be resected Attention was called to the fact that the presence of calcification in these lesions does not necessarily rule out the possibility of malignancy

Harrington,[30] in his series of 291 various types of extrapulmonary and intrapulmonary lesions reported fifty-two patients with no symptoms In this group of fifty-two cases, twelve lesions were found to be malignant, nine being early primary processes, and surgical removal was achieved at a time when results are most favorable

Boyce[6] in 1953, stated that only when pneumonectomy can be carried out promptly in respect to the pathologic process, not the symptoms are the results of treatment rewarding In this study of the causes of death in patients with carcinoma of the lung in a large public hospital, he concludes that, if this group of fatalities teaches us anything at all, it is that suspicious lesions in the chest must be explored on suspicion alone, without delay for time consuming positive diagnosis If the lesion is found to be a tuberculoma, a lung abscess or a benign lesion surgery is still the procedure of choice

Liebow[21] in discussing tumors of the lower respiratory tract states that since it is necessary to establish an accurate diagnosis when any intrathoracic tumor presents itself, exploration is indicated in view of the small risk of thoracotomy and the danger of allowing a malignant intrathoracic tumor to remain untreated

DeBakey,[11] in his discussion of the problem of carcinoma of the lung states that the demonstration of an abnormal x ray shadow demands aggressive action to establish the diagnosis When other measures fail to reveal the exact nature of the lesion, prompt exploration is indicated The risk of exploration, except in the aged and debilitated, may now be considered less than that involved by the consequences of delay He points out that this is an urgent public health problem and advises routine x ray of the chest every six months in

men over forty, to help control the rising death rate from cancer of the lung

In 1953 Storey, Grant and Rothmann[21] reported on forty patients with coin lesions of the lung, ages nineteen to seventy Most of these were young men in the service All of the lesions were detected by routine x ray, 17 5 per cent were found to be malignant They state that surgical excision without undue delay is the treatment of choice

Hood et al[22] emphasized that complacency is no longer justifiable on the part of an attending physician who discovers a solitary circumscribed lesion of the lung with its recognized malignant potentiality Generally there are no symptoms, so patients are not impressed The peripheral location of the lesion makes important diagnostic aids available for the study of most diseases of the chest ineffective In their study of 156 cases in which resection was performed, 35 per cent of the lesions were malignant Evidence of growth increased the suspicion of malignancy, size alone was not a help They advised that preoperative diagnostic study in those patients in whom calcium is not demonstrable should be (1) adequate examination of sputum for malignant cells, (2) a blood sedimentation rate and (3) a tuberculin test Prolonging the diagnostic study beyond this is in most cases without justification, and the decision regarding operation should not be delayed on this account Their attitude toward calcium will be discussed later

My own attitude toward examination of sputum or tracheal or bronchial washings for malignant cells in the diagnosis of these lesions has crystallized in recent months This procedure is an interesting technical study but of little real practical importance If a positive diagnosis is made through examination of the cells in the sputum, the lesion must be resected if possible If this examination is negative and carcinoma is not completely ruled out, exploratory thoracotomy is still definitely indicated A prolonged search of sputum specimens in attempting to achieve an exact pathologic diagnosis would then seem to be a waste of valuable time and delays the necessary surgery

Vivas and Crabtree,[23] Brooke Army Hospital, bring up an interesting point They state that all lesions of medium and small size of light density should be considered malignant, that lesions of medium and small size of medium density should be studied carefully, and that lesions of heavy density are less likely to be malignant They stress the value of previous chest films They believe that all lesions over 3 cm should be considered malignant Their conclusions are based on a study of fifty cases. This matter of density would seem to be a difficult point to decide because of differences in x ray technic, even under controlled conditions

May, Rose and Dugan[24] reported in 1954 that in 40,000 routine admission chest x rays taken in a Veterans Administration Hospital sixty unsuspected solitary lung lesions were found Twenty-four of these were diagnosed and treated by surgical removal, and twelve were diagnosed by other methods Of these thirty six, eight (22 per cent) were primary bronchogenic carcinomas They recommend that "coin" lesions be excised for diagnosis because usually the nature of such lesions can not be detected save by surgical resection and microscopic study Like DeBakey,[11] these authors also believe that routine roentgenographic examination of the chest at six month intervals is advisable, especially for men over forty years of age, since asymptomatic tumors routinely detected are often confined to the lungs

Whether or not the lesion containing calcium should be resected promptly has caused much discussion

In a study of calcification, using tuberculous lesions both for clinical and experimental study, Bloch[4] showed that the degree of calcification on the x ray is arbitrary and is largely dependent on special x ray technics for its demonstration

The Mayo Clinic Group in a series of papers[15 16 22 23] say that in a group of 156 cases in which resection was performed calcium was detected by body section radiography in 32 per cent of the granulomas, in 28 per cent of the hamartomas, but in no other lesion They believe that the calcium reliably indicates benignancy Good Clagett and Weed[15] state that if the coin lesion contains calcium, watchful waiting is justified Hodgson and McDonald[22] oppose the routine resection of coin lesions They discuss calcium again and warn that one must be sure that what is seen on the x ray is truly calcium and that it does lie within the mass It may occur in a number of pulmonary conditions, which they list They say that the presence of true calcium within

the mass indicates that the lesion is not a carcinoma, except in the rare condition of a malignancy developing around a lung stone or a teratoma Then, they state that some calcific lesions should be removed anyhow, depending upon the nature of the lesion itself

Abeles and Chaves [7] from the study of some thirteen cases, consider the presence of calcium strong evidence against malignancy They state that such lesions should not be excised as exceptions to this are too few and they advise tomographic films Fink[14] and Culver et al[9] also think that if a coin lesion contains calcium watchful waiting is justified

On the other hand, Storey, Grant and Rothmann[13] state that the degree of assurance afforded by the presence of calcium within the mass is debatable The amount of security offered by calcification within the coin lesion is relative rather than absolute and is not sufficient reason to withhold from the patient the potential benefits that may be derived from the histologic examination of the lesion after removal

Tuttle[34] also states that the presence of calcium in a lesion does not assure that it is not carcinoma Sharp and Kinsella[31] say that the old idea that all granulomas and calcifications in the lung are the result of tuberculosis has definitely been disproved Calcium deposits do not establish the benign or malignant nature of the process

May, Rose and Dugan[26] report a case of proved bronchogenic carcinoma which by x ray appeared to contain calcium Hodes[21] states that the presence of calcium in a pulmonary nodule does not exclude the possibility of a malignant pulmonary lesion He has seen four patients with calcified nodules which ultimately proved to be bronchogenic carcinoma

Finally Good et al[16] in a paper based upon the same 156 cases of the Mayo Clinic stated that failure to show calcium does not mean that a lesion is malignant, but demonstration of calcium seems to be the only feature which is sufficiently accurate to allow us to postpone an operation indefinitely The paper was discussed vigorously, and Dr Good replied that tumors which do not show calcium should be excised as soon as found while the calcified ones may be watched for a time, but that they too must be excised if they show evidence of growth or if the patient experiences hemoptysis obstruction of a bronchus, or other symptoms of serious import Dr Hodes discussed these points as noted previously Dr Good closed by saying "After all I have never maintained that the calcified lesion should not be removed I have said only that it could be watched longer"

Calcium, then, may be difficult to detect even when present We see that the consensus is that in view of all the factors pro and con the apparent presence of calcium within the lesion should not bar its excision for the purpose of establishing a definitive pathologic diagnosis and ruling malignancy in or out

The roentgenograms accompanying the fol- and which were not These x rays are truly representative of average "coin" lesions

CASE REPORTS

CASE I (Fig 1) C F, a thirty nine year old white woman was first seen on November 2, 1951, complaining of a heavy tight feeling in the center of her chest with a dry cough and excessive perspiration on exertion She had not felt well for the past year and a half

Past history revealed a few chest colds and frank pneumonia in 1919 and 1944 She had had pleurisy in 1947 The only surgery was a kidney suspension in 1931 The family history was non-contributory

Physical examination was normal, except for fluoroscopy of the chest which revealed a 2 5 cm "coin" lesion close to the pericardium on the right but definitely within the parenchyma of the lung Bronchoscopy, November 21, 1951, was negative except for flecks of mucoid sputum in the right lower lobe and slight redness of the orifice of the posteromedial section Bronchial lavage at the time of bronchoscopy was negative for acid fast bacilli and Papanicolaou stain showed group III, doubtful, a few atypical epithelial cells seen in clumps, many erythrocytes

Exploratory thoracotomy was performed on December 21, 1951, and the lesion removed

Pathologic report revealed the following the submitted specimen consisted of a portion of the lower lobe of the right lung weighing 40 gm and measuring 10 by 5 by 5 cm The

men over forty, to help control the rising death rate from cancer of the lung

In 1953 Storey Grant and Rothmann[22] reported on forty patients with coin lesions of the lung ages nineteen to seventy Most of these were young men in the service All of the lesions were detected by routine x ray 17 5 per cent were found to be malignant They state that surgical excision without undue delay is the treatment of choice

Hood et al[23] emphasized that complacency is no longer justifiable on the part of an attending physician who discovers a solitary circumscribed lesion of the lung with its recognized malignant potentiality Generally there are no symptoms so patients are not impressed The peripheral location of the lesion makes important diagnostic aids available for the study of most diseases of the chest ineffective In their study of 156 cases in which resection was performed 35 per cent of the lesions were malignant Evidence of growth increased the suspicion of malignancy size alone was not a help They advised that preoperative diagnostic study in those patients in whom calcium is not demonstrable should be (1) adequate examination of sputum for malignant cells (2) a blood sedimentation rate and (3) a tuberculin test Prolonging the diagnostic study beyond this is in most cases without justification and the decision regarding operation should not be delayed on this account Their attitude toward calcium will be discussed later

My own attitude toward examination of sputum or tracheal or bronchial washings for malignant cells in the diagnosis of these lesions has crystallized in recent months This procedure is an interesting technical study but of little real practical importance If a positive diagnosis is made through examination of the cells in the sputum the lesion must be resected if possible If this examination is negative and carcinoma is not completely ruled out exploratory thoracotomy is still definitely indicated A prolonged search of sputum specimens in attempting to achieve an exact pathologic diagnosis would then seem to be a waste of valuable time and delays the necessary surgery

Vivas and Crabtree[24] Brooke Army Hospital bring up an interesting point They state that all lesions of medium and small size of light density should be considered malignant that lesions of medium and small size of medium density should be studied carefully and that lesions of heavy density are less likely to be malignant They stress the value of previous chest films They believe that all lesions over 3 cm should be considered malignant Their conclusions are based on a study of fifty cases This matter of density would seem to be a difficult point to decide because of differences in x ray technic even under controlled conditions.

May Rose and Dugan[25] reported in 1954 that in 40 000 routine admission chest x rays taken in a Veterans Administration Hospital sixty unsuspected solitary lung lesions were found Twenty four of these were diagnosed and treated by surgical removal and the other thirty six eight (22 per cent) were primary bronchogenic carcinomas They recommend that coin lesions be excised for diagnosis because usually the nature of such lesions can not be detected save by surgical resection and microscopic study Like DeBakey[11] these authors also believe that routine roentgenographic examination of the chest at six month intervals is advisable especially for men over forty years of age since asymptomatic tumors routinely detected are often confined to the lungs

Whether or not the lesion containing calcium should be resected promptly has caused much discussion

In a study of calcification using tuberculous lesions both for clinical and experimental study Bloch[6] showed that the degree of calcification on the x ray is arbitrary and is largely dependent on special x ray technics for its demonstration

The Mayo Clinic Group in a series of papers[11 16 22 23] say that in a group of 156 cases in which resection was performed calcium was detected by body section radiography in 32 per cent of the granulomas in 28 per cent of the hamartomas but in no other lesion They believe that the calcium reliably indicates benignancy Good Clagett and Weed[6] state that if the coin lesion contains calcium watchful waiting is justified Hodgson and McDonald[22] oppose the routine resection of coin lesions They discuss calcium again and warn that one must be sure that what is seen on the x ray is truly calcium and that it does lie within the mass It may occur in a number of pulmonary conditions which they list They say that the presence of true calcium within

the mass indicates that the lesion is not a carcinoma, except in the rare condition of a malignancy developing around a lung stone or a teratoma Then, they state that some calcific lesions should be removed anyhow, depending upon the nature of the lesion itself

Abeles and Chaves,[2] from the study of some thirteen cases, consider the presence of calcium strong evidence against malignancy They state that such lesions should not be excised as exceptions to this are too few, and they advise tomographic films Fink[14] and Culver et al[9] also think that if a coin lesion contains calcium watchful waiting is justified

On the other hand, Storey, Grant and Rothmann[33] state that the degree of assurance afforded by the presence of calcium within the mass is debatable The amount of security offered by calcification within the coin lesion is relative rather than absolute and is not sufficient reason to withhold from the patient the potential benefits that may be derived from the histologic examination of the lesion after removal

Tuttle[34] also states that the presence of calcium in a lesion does not assure that it is not carcinoma Sharp and Kinsella[31] say that the old idea that all granulomas and calcifications in the lung are the result of tuberculosis has definitely been disproved Calcium deposits do not establish the benign or malignant nature of the process

May, Rose and Dugan[28] report a case of proved bronchogenic carcinoma which by x ray appeared to contain calcium Hodes[21] states that the presence of calcium in a pulmonary nodule does not exclude the possibility of a malignant pulmonary lesion He has seen four patients with calcified nodules which ultimately proved to be bronchogenic carcinoma

Finally, Good et al[16] in a paper based upon the *same 156 cases of the Mayo Clinic, stated* that failure to show calcium does not mean that a lesion is malignant, but demonstration of calcium seems to be the only feature which is sufficiently accurate to allow us to postpone an operation indefinitely The paper was discussed vigorously, and Dr Good replied that tumors which do not show calcium should be excised as soon as found, while the calcified ones may be watched for a time, but that they too must be excised if they show evidence of growth or if the patient experiences hemoptysis, obstruction of a bronchus, or other symptoms of serious import Dr Hodes discussed these points as noted previously Dr Good closed by saying, "After all, I have never maintained that the calcified lesion should not be removed, I have said only that it could be watched longer"

Calcium, then, may be difficult to detect even when present We see that the consensus is that in view of all the factors pro and con the apparent presence of calcium within the lesion should not bar its excision for the purpose of establishing a definitive pathologic diagnosis and ruling malignancy in or out

The roentgenograms accompanying the following and which were not These x-rays are truly representative of average "coin" lesions

CASE REPORTS

CASE I (Fig 1) C F, a thirty-nine year old white woman, was first seen on November 2, 1951, complaining of a heavy tight feeling in the center of her chest with a dry cough and excessive perspiration on exertion She had not felt well for the past year and a half

Past history revealed a few chest colds and frank pneumonia in 1919 and 1944 She had had pleurisy in 1947 The only surgery was a kidney suspension in 1931 The family history was non contributory

Physical examination was normal, except for fluoroscopy of the chest which revealed a 2 5 cm "coin" lesion close to the pericardium on the right but definitely within the parenchyma of the lung Bronchoscopy, November 21, 1951, was negative except for flecks of *mucoid sputum in the right lower lobe and* slight redness of the orifice of the posteromedial section Bronchial lavage at the time of bronchoscopy was negative for acid fast bacilli and Papanicolaou stain showed group III, doubtful, a few atypical epithelial cells seen in clumps, many erythrocytes

Exploratory thoracotomy was performed on December 21, 1951, and the lesion removed

Pathologic report revealed the following the submitted specimen consisted of a portion of the lower lobe of the right lung weighing 40 gm and measuring 10 by 5 by 5 cm The



FIG 1 Case I Coin lesion below hilus close to right cardiac border Pathologic diagnosis oat cell carcinoma
FIG 2 Case II Coin lesion in right lower lung field Pathologic diagnosis fibrocaseous tuberculoma
FIG 3 Case III Coin lesion in left lower lobe Pathologic diagnosis chronic non specific inflammation

pleura was smooth moist and glistening and showed a mottled pinkish and yellowish gray appearance On section the pulmonary parenchyma was congested and partially atelectatic and centrally close to the bronchus, was a lobulated nodular, fibrous lesion 3 by 2 by 2 cm in size The lymph nodes were pigmented Submitted separately was a section of the inferior vein of the lower lobe, this was rather firm and indurated and measured 2 by 0 8 by 0 3 cm Also submitted were the middle and remainder of the lower lobes of the right lung weighing 250 gm The bronchial tree was markedly dilated and contained mucous material The pleura was smooth, moist and glistening The pulmonary parenchyma was atelectatic and congested being similar to that already described

Microscopically the sections showed a growth composed of small basophilic oat cells with a characteristic basal appearance These cells were infiltrating the mucous membrane of the bronchi and also the alveoli Mitotic figures were numerous Two of the six lymph nodes showed tumor The tumor cells were similar to those seen in the primary growth

Pathologic diagnosis was oat cell carcinoma

Two and one-half years postoperatively the patient was doing well with no evidence of recurrence

CASE II (Fig 2) T. K., a twenty seven year old white woman, was first seen on May 28, 1954, complaining of a persistent cough for two weeks and extreme fatigue for the past month Her family physician had taken a chest x ray which revealed a lesion in the lower portion of the right lung

Past history was non-contributory She had had a gallbladder operation in 1951 and had dieted from a maximum weight of 265 pounds down to her present weight of 235 pounds The family history was also non-contributory

Physical examination revealed a twenty seven year old obese white woman, six months pregnant On x ray there was an indeterm lesion of the anterobasal segment of the r lower lobe which had speckles of cent calcification with a surrounding zone of so nature Clinical impression was "coin" lesio right lower lung field

Thoracotomy was performed on June 1 1954 and the lesion removed

Pathologic report was as follows specimen labeled 'right lung tuberculoma' was a globular firm mass that averaged 2 2 cm in diameter On section it consisted of concentric layers all rather firm of fibrous consistency The inner mass measured 1 0 cm in diameter was rather chalky gray white, slightly friable This was surrounded by a zone which was grayish tan in color and rather fibrous Similar alternative fibrous capsules surrounded the entire mass A small fragment of lung tissue was present This measured up to 3 0 cm Representative sections were taken for microscopic study

Microscopically, sections of the specimen labeled "right lung tuberculoma" showed a nodule of eosinophilic necrotic tissue surrounded by a small zone of pulmonary tissue The small amount of surrounding recognizable

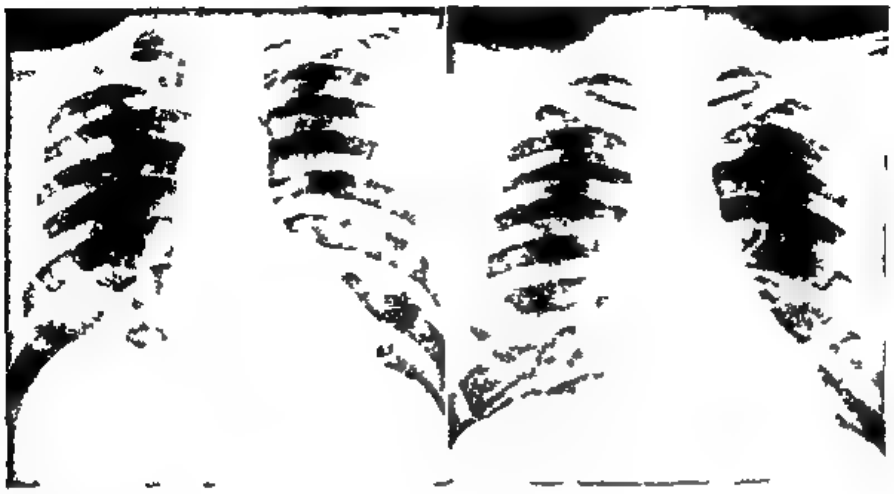

4 5

Fig 4 Case iv Coin les on in right upper lung field Pathologic diagnosis alveolar cell carcinoma

Fig 5 Case v Coin lesion in left upper lung f eld Pathologic diagnos s fibrous and calcareous nodule tuberculosis

lung tissue showed considerable lymphocytic infiltration, diffuse fibrosis slight anthracosis and a thickening of the cells lining the alveoli Sections stained by the Ziehl Neelsen technic showed a small number of acid fast bacilli within the necrotic nodule

ary 4 1952, by her family physician who had been watching a rounded density at the left posterior heart base since August 1951 This density had remained constant Patient had

grams had been normal Family history was also non contributory

Physical examination was negative, except for the "coin" lesion in the left lower lobe revealed by x ray

Exploratory thoracotomy was performed on February 1952, and the lesion removed

Pathologic report revealed the following the submitted specimen consisted of a small mass of tissue from the lung measuring 3 by 1 5 by 1 0 cm The pleura appeared smooth and glistening On section a thin rim of lung parenchyma was present surrounding a central area which was cystic and contained greenish gray purulent material

Microscopically, the sections showed an inflammatory lesion with no evidence of specific type granulation tissue There were diffusely scattered round cells plasma cells and histiocytes with some metaplasia of the bronchial epithelium The alveoli were col lapsed in many areas and in some places they showed hemorrhage and round cell infiltration There was one area in which the alveoli showed an adenomatoid reaction with large, clear, granular cells These were not sufficient, however, to cause any obstruction They may represent a very minute, microscopic beginning adenoma No evidence of actinomycosis, coccidioidomycosis or tuberculosis could be demonstrated

Pathologic diagnosis was chronic non specific inflammation

When last seen two and a half years post operatively the patient was doing well and her lungs remained clear

Case iv (Fig 4) M J T, a fifty-nine year old white man, was first seen on December

tory infection three weeks before He dated his hoarseness from that time

Past history was essentially negative except that the patient had lived around Phoenix, Arizona, for the past eighteen years There had never been any erythema nodosum In 1948 he had a chest x ray in Nogales Mexico

and was told that he had a spot on his lung but that it was not thought to be of any importance Family history was non contributory

Physical examination was negative except for some question of small very deep axillary nodes and fluoroscopy and x ray of the chest revealed a discrete but irregular roundish density at the top of the right lung Intradermal tuberculin and coccidioidin tests were positive Bronchoscopy on December 26 1950, was negative except for a white patch seen on the right vocal cord Bronchial lavage at the time of bronchoscopy was negative for tubercle bacilli for fungi or coccidioides and Papanicolaou stain was considered negative

Exploratory thoracotomy and segmental resection of the lesion were recommended at the time of examination but the patient did nothing about it until March, 1951 when he entered the Veterans Administration Hospital, Los Angeles, California On March 14 1951, right upper lobectomy was performed The patient withstood the procedure well and his postoperative course was smooth

Pathologic report revealed a relatively small circumscribed carcinoma of rather regular cytology and apparently of terminal bronchiolar or alveolar origin no tumor extension was observed in anthracotic hilar lymph nodes examined

Pathologic diagnosis was alveolar cell carcinoma, right upper lobe

On July 7 1952 over a year postoperatively, the patient was examined by the Surgical Tumor Board at which time he was asymptomatic A chest x ray at that time was normal except for the postoperative changes

CASE V (Fig 5) L H a thirty three year old white man was referred to us on September 22, 1953 by his family physician because of a 'coin' lesion in the left upper apex Patient had been feeling under par recently and had noted elevation of temperature in the evening

Past history revealed that on March 30, 1953 patient had a right spontaneous pneumothorax and was treated in the hospital for eleven weeks Chest x ray of July 27 1953 showed complete re expansion of the right lung At that time the shadow in the left upper apex was found The only known exposure to tuberculosis had been twelve years previously when the patient worked on a tuberculosis ward The family history was non-contributory

Physical examination was essentially negative, except for a positive intracutaneous tuberculin test Culture of tracheal wash was reported negative six weeks later Serial x ray films showed the 'coin" lesion to be constant

Exploratory thoracotomy, with wedge resection of the lesion, was performed on January 15 1954

Pathologic report revealed the following the specimen labeled 'nodule from left upper lung consisted of a rounded rather firm mass measuring 1 2 cm in diameter A small amount of fibrotic lung tissue was on the outside A concentrically arranged dense fibrous capsule measuring 2 mm formed the second layer, and the center of the lesion was filled with grayish caseous material There was a small amount of anthracotic pigment in the periphery of the specimen

Microscopically, sections of the mass from the left upper lobe of the lung showed a mass with a fibrous capsule and a central degenerated fibrous substance with marked calcium deposit in it The fibrous capsule was made up partly of new fibrous tissue growth and partly of condensed lung parenchyma Within this there were numerous masses of lymphocytes and masses of pigment filled macrophages

Pathologic diagnosis was fibrous and calcareous nodule of the lung, tuberculosis

When last seen, seven months postoperatively, the patient was doing well and the lung remained clear

SUMMARY

In the so called 'coin' lesion a definitive confirmed diagnosis cannot usually be reached by various laboratory and x ray procedures Surgical exploration for removal of the nodule and pathologic study is urgent These lesions then—many of which look almost exactly the same on the x ray film—will finally be diagnosed as a large variety of pathologic entities

The important fact however, is that in various series from 15 to 30 per cent of such lesions are malignant and in some specially selected older age groups as high as 70 per cent are shown to be malignant The presence of calcium in the lesion does not completely rule out the possibility that the lesion may be malignant and it is not a contraindication to exploratory thoracotomy

Exploratory thoracotomy, in proper hands is a benign procedure It should be thought of in the same way as most physicians and even the general public have been educated to think

about biopsy of a breast nodule The nodule in the lung should be removed so that a definite pathologic diagnosis can be made The lesion

even

orkup

nant

metastases may well be present and the chance for successful surgery has generally been lost

Carcinoma of the lung is becoming more of a public health and clinical problem Agreement on the need for prompt exploratory thoracotomy to achieve a definitive pathologic diagnosis of such 'coin' lesions is becoming almost universal among physicians skilled in treating diseases of the chest However such agreement is not yet so widespread among the general medical profession, and certainly not among the general public We must keep emphasizing the need for a very prompt and direct surgical approach in diagnosing and treating such 'coin" lesions if we are to reduce the present extremely high mortality from carcinoma of the lung

REFERENCES

1 Abeles H and Ehrlich D Single circumscribed intrathoracic densities *New England J Med* 244 85 1951

2 Abeles H and Chaves A Significance of calcification in pulmonary coin lesions *Radiology* 58 199 1952

3 Adler I Primary Malignant Growths of the

and experimental study *Am J Roentgenol* 59 853 1948

6 Boyce F F Causes of death in carcinoma of the lung in a large public hospital *Dis of Chest* 24 626 1953

7 Boyce F F Carcinoma of the lung a problem in diagnosis *Geriatrics* 9 355 1954

8 Bugden W F Asymptomatic and circumscribed lesions of the chest *Am Rev Tuberc* 62 512 1950

9 Culver G J Concannon J P and MacManus J E Pulmonary tuberculomas pathogenesis diagnosis and management *J Thoracic Surg* 20 798 1950

10 Davis E W and Klepser G S Significance of solitary intrapulmonary tumors *S Clin North America* 30 1707 1950

11 DeBakey M E The problem of carcinoma of the lung *Am Surgeon* 19 1 1953

12 Editorial Pulmonary coin lesions *Radiology* 54 116 1950

13 Effler D B Blades B and Marks E Problem of the solitary lung tumors *Surgery* 24 917 1948

14 Fink D L Coin lesions of the lung *Minnesota Med* 34 554 1951

15 Good C A Clagett O T and Weed L A Granuloma of the lung a problem of differential diagnosis *Tr Nat Tuberc A* 47 294 1951

16 Good C A Hood R T Jr and McDonald J R Significance of a solitary mass in the lung *Am J Roentgenol* 70 543 1953

17 [illegible]

18 [illegible]

tuberculosis) simulating tumor *J Thoracic Surg* 6 173 1936

19 Grow J B Bradford M L and Mahon H W Exploratory thoracotomy in the management of intrathoracic disease *J Thoracic Surg* 17 480 1948

20 Harrington S W The surgical treatment of circumscribed intrathoracic lesions *Dis of Chest* 19 855 1951

21 Hodes P J Discussion of paper by Good et al [16]

22 Hodgson C H and McDonald J R The diag

of the lung study of 156 cases in which resection was performed *J A M A* 152 1185 1953

24 Liebow A A Tumors of the Lower Respiratory Tract Atlas of Tumor Pathology section v fascicle 17 p 141 Washington D C 1952 Armed Forces Institute of Pathology

25 Mahon H W and Forsee J H The surgical treatment of round tuberculous pulmonary lesions (tuberculomas) *J Thoracic Surg* 19 724 1950

26 [illegible]

27 [illegible]

28 [illegible] 141 017 949

29 [illegible]

30 [illegible]

31 Sharp D V and Kinsella J J The significance of the isolated pulmonary nodule *Minnesota Med* 33 886 1950

32 Statistical Bulletin Metropolitan Life Insurance Company 34 4 1953

33 Storey C F Grant R A and Rothmann B F Coin lesions of the lung *Surg Gynec & Obst* 97 95 1953

34 Tuttle W Discussion of paper by Culver et al [9]

35 Vivas J R and Crabtree S F The significance of size and radiographic density of solitary lesions in the lungs *Am Pract & Digest Treat* 4 857 1953

36 Wolpaw S E The diagnosis and management of asymptomatic isolated intrathoracic nodules *Ann Int Med* 37 489 1952

Solitary Circumscribed Lesions—Diagnosis and Management

CORRIN H HODGSON M D, Rochester Minnesota

From the Section of Medicine Mayo Clinic and Mayo Foundation Rochester Minnesota

IT is hardly necessary to emphasize the importance of the solitary circumscribed pulmonary lesion because most physicians have learned from the recorded experience of others or from their own practices that this lesion cannot be regarded lightly It is imperative that the nature of every such lesion be determined either by clinical investigation or, if that fails by examination of the tissue after surgical removal The types of lesions which make this subject of vital importance are summarized in Figure 1, these are infectious granuloma capable of dissemination, potentially malignant tumor and carcinoma of the lung The great majority of solitary circumscribed lesions fall into one of these three categories Usually these dangerous lesions are indistinguishable clinically and require removal for diagnosis However, in the enthusiasm for resection one should not forget that judicious individual consideration is always the basis for sound medical practice and may spare many of these patients an unnecessary operation

In reviewing the literature on the subject of the solitary circumscribed lesion, one is confused by the difference in definitions Some limit the study to patients without any symptoms while others do not Some restrict their cases to those in which the lesion is of an arbitrarily specified size Some weight their reports with a large number of younger patients while others weight them with older patients All of these factors necessarily lead to statistical disagreement In spite of this confusion, one thing remains clear—everyone reports that a significant number of solitary circumscribed lesions are malignant Also very important, though somewhat less impressive, is the still larger number of granulomas some of which are potentially dangerous to health and deserve serious consideration From the practical standpoint, a suitable working definition of the solitary circumscribed lesion is as follows It is a lesion seen on roentgenogram as a solitary one, as being completely within the substance of the lung, as being more or less rounded in shape, as having a fairly well defined border, and as being not necessarily asymptomatic but free of complications such as pleural effusion, obstructive pneumonitis or cavitation

OBSTACLES TO CLINICAL DIAGNOSIS

Unfortunately there are many limitations to the clinical diagnosis of solitary circumscribed lesions Most of them are peripherally placed beyond the limits of bronchoscopic visualization Therefore bronchoscopy is only helpful in selected cases In granulomas due to tuberculosis, smears of sputum seldom demonstrate the organism, and cultures of sputum and gastric contents do not often give positive results If there is a question of malignancy, one is not justified in waiting several weeks for the results of cultures for the tubercle bacillus Thus the need for haste in itself limits clinical diagnosis The cytologic examination of sputum and bronchial secretions never gives positive results in adenoma of the bronchus, and in only a small portion of the peripherally placed carcinomas does such examination give positive results whether the tumors be primary or metastatic Skin sensitivity tests also are of limited value as will be seen later The usual laboratory procedures are of little help except in evaluating the patient's general condition Roentgenographically, there are few distinguishing characteristics by which these lesions can be differentiated and about all that one can say is that a lesion is present, that it has a certain location within the lung and that it does or does not appear to contain calcium

These obstacles are sufficient to prevent making a clinical diagnosis in the majority of

FIG. 1 Types of lesions that make the subject of solitary circumscribed pulmonary nodules important (a) infectious granuloma (tuberculosis) capable of dissemination (b) potentially malignant tumor (adenoma) (c) carcinoma of the lung

cases necessitating surgical removal of the lesion for more definitive information

EXTRAPULMONARY SHADOWS SIMULATING INTRAPULMONARY MASSES

In order to avoid embarrassing errors exact localization of these roentgenographic shadows is required Stereoscopic roentgenograms taken in the postero anterior projection plus a single roentgenogram taken in the lateral projection

masses Included in this category are tumors and
of
of
fractures and intercostal neurofibromas and pleural lesions including encapsulated fluid or empyema fibrous mesothelioma and pleural plaques

SIGNIFICANCE OF CALCIFICATION

The presence of calcification in a lesion is about the only definite evidence of benignity available in the clinical investigation of solitary pulmonary nodules When calcium appears to be present the physician must be sure that what he sees is calcium that it lies within the lesion and that it is not just one of a great many such calcified areas in the lung Where many calcific shadows are present just by chance one might be enveloped in a malignant tumor Postero anterior and lateral Bucky roentgenograms or tomograms of the lesion may be very helpful in delineating calcium within the area in question if it is not seen on routine roentgenograms

Calcification may occur in a number of different pulmonary conditions which produce solitary circumscribed nodules in old tuberculous foci in hamartomas in hematomas around foreign bodies within parasites in granulomas notably those of coccidioidomycosis and histoplasmosis in metastatic osteogenic sarcoma and perhaps very rarely in an adenoma of the bronchus It does not occur in solitary circumscribed primary bronchogenic carcinoma except in those rarest of instances when a carcinoma

calcium For the most part calcified lesions do not have to be removed Some of the calcified lesions yield positive cultures for tubercle bacilli and therefore are a potential source of danger Although they have been known to rupture and discharge contents infected with tubercle bacilli it must be unusual for this to happen Laminated lesions perhaps never require removal as they are said to be sterile Laminations of course indicate a granulomatous lesion never a tumor Hamartomas being strictly benign may be treated as are other calcified lesions and allowed to remain

THE SOLITARY CIRCUMSCRIBED LESION

Vascular Abnormalities Very few of the vascular lesions are ever solitary and circumscribed Arterial and venous aneurysms are

nearly always *contiguous* with the hilum and, therefore, are not discrete lesions The author has seen one venous aneurysm however which conformed to the definition of this subject

Pneumonitis, Abscess, Infarction and Hydatid Disease Acute or chronic pneumonitis may occasionally give a circumscribed shadow as seen on the roentgenogram The history should lead one to suspect such a condition and repeat roentgenograms taken after a short interval are likely to show changes in the contour of the shadow identifying it as pneumonitis rather than a tumor Acute and chronic abscess of the lung may also produce a circumscribed shadow Pulmonary infarction is a very common condition which may at times produce a discrete lesion Here the history of previous operation or injury or recent thrombophlebitis would cause one to suspect it and perhaps avoid an unnecessary operation at considerably increased risk Roentgenograms taken after a short interval will reveal changes that remove the lesion from the tumor category Echinococcosis is a rare entity in the United States but when it occurs, it is likely to present in the form of a solitary circumscribed lesion

Granulomas The granulomas are the largest single group under consideration here. Various investigators of the subject of the solitary circumscribed lesion have reported the frequency of granulomatous lesions as follows Grow and co-workers 49 per cent, Abeles and Ehrlich, 20 per cent, Storey and co-workers, 70 per cent, Effler 50 per cent Hood and co-workers, 41 7 per cent, Sharp and Kinsella 40 per cent O'Brien and co-workers 38 per cent, and Davis and Klepser, 25 per cent The frequency of these lesions is thus well established but their relative importance is not so well defined It is known that they may break down and disseminate the infection causing them, but how often this happens is not clear.

The different types of granuloma can be differentiated from each other only by identifying the causative organism or substance. By microscopic examination of the tissue alone one can identify only some of the cases of histoplasmosis, coccidioidomycosis, actinomycosis and oil granuloma Tubercle bacilli may be simulated by other acid fast organisms and debris, hence their identity must be confirmed by culture or guinea pig inoculation in any event It is rather useless, therefore to [illegible] d time in search of acid fast organisms in tissue sections

One cannot emphasize too strongly the importance of complete bacteriologic examination of granulomatous tissue removed at operation This investigation is fully as important as the microscopic examination of tumor [illegible]

(1) microscopic examination of direct smears and fixed sections for fungi and other causative agents (2) culture for tubercle bacilli fungi and other organisms and (3) guinea pig inoculation In spite of adequate bacteriologic examination however, the majority of these granulomatous lesions do not yield any organisms and, therefore their exact cause remains a mystery Histologically they may appear to be "burned out" granulomatous infections but some of the sterile lesions seem to be histologically active It is not reasonable to assume that they are all due to any specific infection, such as tuberculosis, without having adequate proof of such infection and it is therefore a mistake to refer to unproved lesions as "tuberculomas"

What part do the specific skin tests play in the diagnosis of the circumscribed lesion They are certainly a matter of interest to anyone working on this subject, but from the practical standpoint they really contribute little It is dangerous to allow a positive or negative skin reaction to influence one in choosing between observation or exploration of this type of lesion One must remember that the benignity of the lesion must be established beyond question or a confirmed diagnosis made Therefore, one cannot rely on presumption which is all that is contributed by a skin test

Because some non-calcified granulomatous lesions are potentially dangerous (and one cannot tell beforehand which ones are) and because many of them cannot be distinguished from malignant tumors it is necessary to remove most of them surgically Certainly the potential dangers of leaving them in the lung outweigh the risk of present day thoracotomy As discussed previously, calcified granulomas are much less hazardous and not all of them require removal

Benign Tumors Could one be certain of the identity of benign tumors they could of course, be left alone unless they should enlarge or cause symptoms but unfortunately it is

seldom possible to determine that a lesion is a benign one, such as a bronchogenic cyst or [illegible] removed to prove their innocence A hamartoma in which calcium is demonstrable may be managed as are other calcified lesions

Adenoma of the Bronchus Most adenomas of the bronchus are centrally placed and visible bronchoscopically Moersch and McDonald found 91 per cent in that category However, occasionally one is peripheral, solitary, circumscribed and beyond bronchoscopic visualization Although relatively benign, between 5 and 10 per cent of them metastasize, making them a real danger Because they are covered with intact mucosa, they do not shed tissue, so that no cells are found on examination of sputum or bronchial secretions Preoperative diagnosis is, therefore, almost impossible when they are peripheral Bronchial adenomas may remain unchanged for a number of years It is not advisable, therefore, to defer thoracotomy on the basis of the fact that the lesion has remained unchanged for a long time

Hood and co-workers found that 7 7 per cent of the solitary circumscribed lesions they studied were adenomas Sharp and Kinsella reported two adenomas among ninety-six such solitary lesions, and Abeles and Ehrlich reported one among twenty-one It is seen, therefore, that adenomas account for a significant, though not large, number of the circumscribed lesions under discussion Their removal is, of course, indicated

Primary Malignant Tumors The high frequency of occurrence of malignant tumors makes this subject important The proportion of the tumors that are malignant has been given by various authors as follows Grow and co-workers, 23 per cent, Abeles and Ehrlich, 33 per cent, Watson, 40 per cent, Overholt, 24 per cent, Harrington, 23 per cent Hood and co-workers, 35 3 per cent, Davis and Klepser, 55 per cent, O'Brien and co-workers, 42 9 per cent, Fink, 33 per cent, Sharp and Kinsella, 27 3 per cent, Storey and co-workers, 17 5 per cent, Effler and co-workers, 16 6 per cent, and Effler, 37 5 per cent, Age has a dominant relationship, the lowest incidence of malignancy occurring in the series reported by Storey and Effler and their co-workers,[4 14] in which young males predominated

The diagnosis may be made preoperatively in some cases Hood and co-workers were able to identify malignant cells when they were looked for in the sputum of 53 per cent of their patients This is considerably higher than previously believed possible and indicates the value of this procedure However, it is important to remember that the inability to find malignant cells in the sputum or bronchial secretions does not in any way eliminate the possibility that the lesion is malignant Bronchoscopically, few of these lesions are visualized and, therefore, biopsy proof is seldom forthcoming

A number of malignant lesions have been observed to remain the same size over a period of several years For this and other obvious reasons there is no place for a "period of observation" or slow diagnostic methods such as cultures for tubercle bacilli when there is a possibility that the lesion is malignant

There has been much discussion of the size of the lesions and some investigators have limited their study to lesions of specified dimensions Because such restrictions are arbitrary, they serve little purpose Every larger malignant tumor was once less than 2 cm in diameter and that would have been the time to remove it It is well known that metastatic lesions of less than 2 cm in diameter are clearly visible roentgenographically, and therefore one should also see primary tumors of that size The fact is, however, that a primary malignant growth of that small size is not detected Is it because of failure to recognize small malignant tumors or because of failure of the roentgenogram to show them? Until further information is available, it is not safe to assume that a lesion of less than 2 cm is not malignant

The appearance alone does not distinguish between a primary and a metastatic lesion of the lung It is necessary, therefore, that each be explored in the hope that it will prove to be curable

Although age and sex bear a significant relationship to the incidence of the different pulmonary conditions, they do not give a sufficient basis for the management of a solitary pulmonary nodule Primary bronchogenic carcinoma is rarely seen in persons less than thirty years of age but other types of malignancy may occasionally be encountered Nor can the possibility of a malignancy be eliminated be-

cause the patient is a woman although the incidence of primary cancer of the lung is much higher among men

With all the interest in the subject of the solitary pulmonary nodule it is surprising that there is a lack of follow up studies on the patients with malignant lesions for whom resection has been performed It has been assumed that resection for these lesions accomplishes its purpose This assumption is not justified until statistical studies indicate that removal of the malignant tumor brings about a permanent cure in a significant number of patients

Solitary Metastatic Nodules As mentioned previously it is seldom possible to tell clinically whether a circumscribed lesion is primary or metastatic Evidence of malignancy elsewhere in the body or the history of a previously removed cancerous lesion is very strong presumptive evidence of the metastatic nature of the lesion in question Even after examination of the surgical specimen the pathologist is often unable to tell whether a primary or metastatic lesion has been removed

As in any case in which surgical treatment is contemplated a thorough general examination should be conducted and if there are any clues to a possible hidden malignancy they should be investigated It is not worth while however to undergo exhaustive tests in a blind search for primary malignancy without any leads to follow

If a patient has had a previous malignant lesion and then presents a solitary circumscribed nodule in the lung the chances are tumor may have developed Under favorable circumstances and after careful individual consideration one may be justified in recommending thoracic exploration for this situation In some instances even though metastasis appears almost certain one may consider thoracotomy after giving due consideration to the location and type of the original malignant tumor, its growth and invasive characteristics the lack of evidence of metastasis elsewhere in the body, and the age and general condition of the patient Such exploration is justified by the possibility that the lesion is not metastatic and by the fact that some patients remain well for a number of years after removal of a known metastatic growth Cases in which this procedure is justifiable do not occur frequently however

CONCLUSION

In the management of the solitary circumscribed pulmonary nodule one must prove the lesion to be benign or it should be removed The only clinical criterion for benignity is the demonstration of calcium in the lesion Thoracotomy, because of the low risk and short period of incapacity for the patient is now a very useful frequently employed diagnostic measure and in no situation does it serve better than in the management of the solitary circumscribed pulmonary nodule

REFERENCES

1 ABELES H and EHRLICH D Single circumscribed intrathoracic densities *New England J Med* 244 85 88 1951

2 DAVIS F W and KLEPSER R G The significance of solitary intrapulmonary tumors *S Clin North America* 30 1707 1715 1950

3 EFFLER D B Solitary lung tumors *Am Rev Tuberc* 63 252 254 1951

4 EFFLER D B BLADES B and MARKS E The problem of the solitary lung tumors *Surgery* 24 917–928 1948

5 FINK D L Coin lesions of the lung *Minnesota Med* 34 554 555 1951

6 GROW J B BRADFORD M L and MAYON H W Exploratory thoracotomy in the management of intrathoracic disease *J Thoracic Surg* 17 480–493 1948

7 HARRINGTON S W The surgical treatment of circumscribed intrathoracic lesions lesions found on routine thoracic roentgenological examinations, with absence of subjective symptoms *Dis of Chest* 19 255 269 1951

8 HOOD R T JR GOOD C A CLAGETT O T and McDONALD J R Solitary circumscribed lesions of the lung study of 156 cases in which resection was performed *J A M A* 152 1185 1191 1953

9 MAYON H W and FORSEE J H The surgical treatment of round tuberculous pulmonary lesions (tuberculomas) *J Thorac Surg* 19 724 739 1950

[illegible] R Bronch [illegible]

12 OVERHOLT H H Cancer detected in survey *Am Rev Tuberc* 62 491 496 1950

13 SHARP D V and KINSELLA T J The significance of the isolated pulmonary nodule *Minnesota Med* 33 886–888 1950

14 STOREY C F GRANT R A and ROTHMANN B F Coin lesions of the lung *Surg, Gynec & Obst* 97 95 104 1953

15 WATSON W S Quoted by Overholt [12]

100

The Solitary Pulmonary Nodule

Edgar W Davis M D Sol Katz M D and J Winthrop Peabody, Jr M D *Washington D C*

Solitary nodules of the lung represent a [illegible] of a benign process To the casual observer neither the size nor shape is a source of much concern To the smooth border and peripheral location of these lesions add a general lack of symptoms and the deception is complete The disguise is apt to be fleeting however for if [illegible] metastasis The purpose of this chapter is to re-emphasize the hazards inherent in this group of tumors and to renew our earlier plea for their prompt excision

Besides being one of the first to cite this danger[1] the senior author has reported what is acknowledged to be the highest cancer rate yet quoted for these lesions [2] Since this figure has been widely referred to in the literature and its accuracy occasionally questioned the thought occurred that an analysis of a comparable series of patients subsequently operated upon might prove interesting and informative Accordingly this report comprises a comparative study between the original sixty seven patients reported in 1950 and the next sixty seven consecutive patients operated upon for a solitary tumor of the lung As will be shown the two groups are remarkably similar

Patients have been selected on the basis of the [illegible] it may be round ovoid or slightly lobulated in shape (3) its edges are circumscribed and its contour is smooth (4) there is no calcification within the tumor and (5) there is no evidence of cavitation Excluded from this series are all tumors with associated pneumonitis atelectasis or regional lymphadenopathy Hilar, mediastinal diaphragmatic and chest wall masses are ruled out by the presence of aerated lung around the tumor In other words the tumor must be situated in the peripheral portion of the lung Extreme sharpness of outline has not been required Cavitary lesions are not included because the many terms applied to solitary tumors (viz solitary nodule coin lesion etc) all imply that the mass is solid This is just as well inasmuch as cavitation is in itself generally accepted as an indication for resection whereas the solid nodule is not No lesion is included in which calcification can be demonstrated for it is believed that their inclusion would weight the statistics in favor of the benign lesion This is certainly true of nodules which are completely calcified those stippled with calcium or those presenting a concentric ring type of calcification[7] It is only a little less emphatically true of practically all partially calcified nodules although rare exceptions are noted [8] Restrictions as to size of the nodule have been proposed by some authors [4 5] but to us this seems relatively unimportant when considering the possibility of bronchogenic carcinoma since size alone is no guarantee against malignancy True the small nodule is less likely to be carcinoma than the large nodule but the large lesion was once small and it was then that treatment should ideally have been applied Finally unlike several other series we have not required that the patient be asymptomatic By far the majority of these patients are asymptomatic, yet a surprising number develop vague com [illegible]

In comparing these two series of patients one

is immediately struck by their similarity Of the original sixty seven solitary intrapulmonary tumors thirty seven (55 per cent) were malignant (Table I), among the next sixty-seven, thirty-four (51 per cent) were malignant, (Table II) Insofar as the malignant lesions are concerned the only real distinction between the two groups is a considerably higher incidence of metastatic carcinomas among the second series of patients Although the relative number of men and women is not appreciably different in the two series, there is a surprising disproportion in sex distribution between the two groups with malignant tumors Thus in the first group only 12 per cent of the malignant lesions occurred in females whereas in the subsequent series 30 per cent were in women Although we would be quick to admit that this difference is probably unique and not representative it emphasizes nonetheless that the patient's sex has no real bearing on the possibility of any particular case being carcinoma As for age the two groups are quite comparable, the first averaging 52 9 years and the second 49 4 years Worth noting is that six of the original thirty-seven patients with malignant tumors and seven of the last thirty four were less than forty five years of age In other words about one of every five malignant tumors occurred in a patient who had not yet reached the so-called "cancer age" Moreover, just as youth provides no assurance against malignancy, it is no more logical to assume that the older patient necessarily has cancer, for in the second group there were six patients over sixty five years of age, only two of whom had bronchogenic carcinoma, one having a bronchial adenoma and three, a granuloma

TABLE I
ORIGINAL SIXTY SEVEN CONSECUTIVE SOLITARY INTRAPULMONARY TUMORS

Condition	Number
Malignant*	
Bronchogenic carcinoma	32
Metastatic malignant tumor (kidney 1 testis, 1)	2
Bronchial adenoma†	1
Lymphoblastoma	1
Neurogenic sarcoma	1
Non malignant‡	
Granuloma	18
Chronic pneumonitis	4
Hamartoma	2
Cyst	2
Pleural mesothelioma	2
Lipoid granuloma	1
Myofibroma§	1

* Thirty seven cases (55 per cent), thirty three men and four women
† Originally diagnosed as a bronchogenic carcinoma but reclassified after further study
‡ Thirty cases (45 per cent) fourteen men and sixteen women
§ Classified by some as a form of hamartoma [18]

TABLE II
NEXT SIXTY SEVEN CONSECUTIVE SOLITARY INTRAPULMONARY TUMORS

Condition	Number
Malignant*	
Bronchogenic carcinoma	26
Metastatic malignant tumor (kidney 2 bone 1, breast 1 ovary 1 bowel 1)	6
Bronchial adenoma	1
Hodgkin s disease	1
Non malignant†	
Granuloma	27
Hamartoma	2
Cyst	1
Chronic pneumonitis	1
Pleural mesothelioma	1
Fibroma	1

* Thirty four cases (51 per cent) twenty five men and nine women
† Thirty three cases (49 per cent) seventeen men and sixteen women

Bronchogenic Carcinoma Taken individually bronchogenic carcinoma constitutes the largest single contributor to this group of solitary lesions This study confirms the commonly accepted precept that the cellular pattern of peripheral carcinomas shows a reversal of the usual distribution Thus adenocarcinomas constitute over half of the carcinomas in this series, whereas when considering all bronchogenic carcinomas regardless of location only about 13 per cent prove to be adenocarcinomas [8]

Metastatic Carcinoma and Sarcoma Twice in the first series and six times in the second we resected solitary metastatic nodules Frequently there is no suggestion preoperatively

FIG 1 Fifty four year old asymptomatic white woman who had never smoked A left radical mastectomy had been performed two months previously for adeno carcinoma of the breast Intrapulmonary nodule in right lower lobe was resected and proved to be pri mary epidermoid bronchogen c carcinoma

that the lesion is metastatic Even when there is it is extremely difficult, expensive and time consuming to find the primary without some clue to its origin For this reason we prefer to remove these nodules after a reasonable but not overly elaborate study If it proves to be metastatic, then the histology generally sug gests the site of the primary

When a primary extrapulmonary tumor has

in the lung Even so it should be emphasized that once a secondary tumor appears in the lung widespread metastases generally show up rather promptly In one careful study it was concluded that with several exceptions the patients with a long hiatus between the removal of the primary and secondary tumors did no better than the group as a whole[7] This is exemplified by one patient in our second series who, after removal of a clear cell carcinoma of the right kidney, survived twelve years before a metastatic nodule appeared in the left lung, only to have signs of cerebral metastasis develop within a month after excision of the pulmonary metastasis Perhaps the most important aspect to this problem is this the presence of a solitary intrapulmonary nodule in a patient with a primary malignant tumor elsewhere is no proof that the pulmonary nodule represents a metastasis Actually it may be a primary bronchogenic carcinoma as was true of a fifty-four year old woman in our second series who had recently undergone left radical mastectomy for adenocarcinoma The small nodule noted in the right lung (Fig 1) was presumed to be a solitary metastasis, but following resection it was found to be a primary epidermoid carcinoma As a result of our experience with this and several similar cases we have become extremely reluctant to consider a history of previous cancer surgery as a reliable guide to the identity of a solitary intrapulmonary tumor

Bronchial Adenoma Even when unaccom panied by frank evidence of malignancy bronchial adenomas remain potentially malig nant tumors and have been so classified in this study As a rule they are centrally located, hence as one might imagine, they should seldom enter into the differential diagnosis of solitary tumors of the lung While this has proved true in our experience, it should be pointed out that in at least one series of solitary circumscribed lesions bronchial adenomas represented a substantial portion of the total number, namely, 7 7 per cent[8] In our combined series we have encountered only two such cases, both occurring in the middle lobe

Granuloma The most common benign type of nodule occurring in the lung is the granu loma Eighteen such lesions were included in our original series, while twenty seven have been encountered in the second Thus of all the solitary tumors included in this study 36 per cent were granulomas As implied by the non specificity of the term "granuloma" the exact identity of all of these lesions has not yet been ascertained The traditional view is that these are tuberculomas, but the tubercle bacillus appears to have been accused unfairly This is not to say that none are true tuberculomas Assuredly, when acid fast bacilli are demon strated by smear, culture or specially stained tissue sections, the lesion is indeed a tuberculoma More often than not, however, these lesions prove to be bacteriologically negative,

2A 2B

FIG 2 Forty five year old asymptomatic white woman A, solitary tumor in left lower lobe discovered in routine chest roentgenogram B no calcium visible in planigram Lesion resected and found to be packed with histoplasma Diagnosis histoplasmoma

and the diagnosis is then seriously in doubt From a rather broad personal experience with the periodic acid-Schiff (PAS) stain[9,10] we are convinced that many of these granulomas are in reality indolent mycotic foci With few exceptions[9,11] the etiologic fungi, due apparently to the fact that they are either dead or dying can seldom be recovered by cultures[12] and are generally invisible in ordinary hematoxylin and eosin stained tissue sections Utilizing the PAS stain, histoplasma or less commonly some other pathogenic fungus can be demonstrated in a fair number of these granulomas From our studies to date as well as those of others[13-14] we suspect that the histoplasmoma is more common than the tuberculoma In view of our failure to isolate the responsible fungi by culture, we presume these foci to be healed or healing and for that reason we are reasonably certain that they do not on their own merits deserve resection Unless calcification is demonstrable radiographically, however, we do not believe that they can be reliably differentiated from a small, circumscribed carcinoma by any means short of resection (Fig 2)

Chronic Pneumonitis Chronic pneumonitis without any apparent granulomatous component will occasionally take the form of a solitary intrapulmonary nodule Only one such diagnosis was included in the second series of cases suggesting that closer scrutiny will relegate most of these lesions to the category of granulomas

Hamartoma Hamartomas have always been considered extremely rare benign tumors of the lung when in effect they are probably not too uncommon This would seem to be substantiated by the fact that in one series hamartomas comprised 16 per cent of all solitary lesions[8] In our combined series we have seen only four hamartomas and two of these were removed from the same patient, the second appearing five years after excision of the first If it were possible to make a preoperative diagnosis of hamartoma, we believe that surgery would be unnecessary, since these tumors are benign and do not as a rule attain very

FIG 3 Sixty two year old asymptomatic white man Solitary tumor of the right lower lobe discovered in routine chest x ray Pneumonectomy performed for primary epidermoid bronchogenic carcinoma Note similarity [redacted] Figure 2.

large proportions In this regard the tendency of hamartomas to calcify actually strengthens our belief that calcific nodules do not warrant surgical excision unless enlarging In the absence of calcium, however, it is impossible to differentiate a hamartoma from a carcinoma and resection is necessary to establish the diagnosis

Pleural Mesothelioma Pleural mesotheliomas are definitely unusual tumors The localized fibrous type of pleural mesothelioma commonly presents the radiographic appearance of a solitary tumor of the lung although in effect they are not truly intrapulmonary Clubbing of the digits and arthritis, which are frequent accompaniments of this tumor, were noted in none of the three patients in this series with pleural mesotheliomas Even when present such signs help in no way to exclude bronchogenic carcinoma Moreover, the tremendous size that these tumors eventually reach, is reason enough to justify their excision Histologically it [redacted] extremely important to differentiate pleural mesotheliomas from fibromas, fibrosarcomas, neurofibromas and neurofibrosarcomas which are the usual but erroneous pathologic interpretations of these tumors

Other diagnostic possibilities among the solitary intrapulmonary tumors include chronic abscess, pulmonary cyst, hemangioma, lipoid granuloma, fibroma, fibrosarcoma and other comparably uncommon entities

SUMMARY

1 Two large groups of patients, all of whom presented the radiographic picture of [redacted] solitary intrapulmonary tumor, have been analyzed and compared

2 The incidence of malignancy, as we have previously emphasized, is extreme, being over 50 per cent in each group

3 The more common lesions entering into the differential diagnosis have been briefly discussed Particular attention has been paid to the frequency with which histoplasmosis accounts for the so-called "tuberculoma"

4 Because the correlation between clinical impression and the histology of any particular lesion is extremely tenuous, and since the various diagnostic tests are rarely helpful, prompt surgical excision would seem to constitute the only logical approach to the problem of the solitary tumor of the lung

REFERENCES

1 DAVIS E W and KLEPSER, R G Significance of solitary intrapulmonary tumors Read before the Annual Meeting of the American College of Chest Physicians, Atlantic City, N J June 8, 194[illegible]

2 DAVIS, E W and KLEPSER, R G The significance of solitary intrapulmonary tumors *S Clin North America*, 30 1707, 1950

3 LONDON S H and WINTER, W J Calcification within carcinoma of the lung *Arch Int Med*, 94 161, 1954

4 THORNTON T F JR ADAMS, W E and BLOCH, R G Solitary circumscribed tumors of the lung *Surg, Gynec & Obst*, 78 364 1944

5 SHARP D V and KINSELLA, T J The significance of the isolated pulmonary nodule *Minnesota Med*, 33 886, 1950

6 PATTON, M M, McDONALD J R and MOERSCH, H J Bronchogenic adenocarcinoma *J Thoracic Surg*, 22 83 1951

7 SEILER, H H, CLAGETT, O T and McDONALD [illegible]

10 PE[illegible]

11 MATTHIESEN D E The surgical significance of solitary circumscribed lung nodules in histoplasmosis *Am Rev Tuberc*, 69 829 1954

12 PUCKETT T F Pulmonary histoplasmosis a study of twenty two cases with identification of H capsulatum in resected lesions *Am Rev Tuberc*, 67 453 1953

13 ZIMMERMAN L E Etiology of so called pulmonary tuberculoma *M Ann District of Columbia*, 23 423 1954

14 ZIMMERMAN L E Demonstration of histoplasma and coccidioides in so-called tuberculomas of lung, preliminary report on 35 cases *Arch Int Med* In press

15 CRUICKSHANK D B and HARRISON G K Diffuse fibro-leiomyomatous hamartomatosis of the lung *Thorax* 8 316 1953

Importance of Surgery in the Management of Coin Lesions

Wm M Tuttle, M D, Raymond J Barrett, M D and J H Hertzler, M D, *Detroit, Michigan*

From the Department of Surgery, Wayne University College of Medicine Herman Kiefer Hospital and Harper Hospital, Detroit Michigan

A considerable literature and even greater clinical experience has accumulated since attention was first focused on the varied nature of the pulmonary coin lesion The main purpose of this chapter is to discuss the present day management of such lesions

THE INCIDENCE OF VARIOUS PATHOLOGIC STATES

As far as we know, Graham and Singer[1] in 1936 made the first reference to the removal of rounded lesions within the lung These were apparently all of tuberculous origin In 1948, one of us (W M T) reported a series of twenty-one patients,[2] giving the incidence of the various pathologic states (Table I) It is interesting to note the close similarity between this series and Table II which represents 714 isolated round lesions collected from the literature by Jones and Cleve[3]

Table I

Pathologic Diagnosis	No of Patients	Percentage
Bronchogenic carcinoma	8	39 0
Sarcoma	1	4 9
Tuberculoma	8	38 0
Cyst	1	4 9
Abscess	2	9 5
Chondroma	1	4 9
		100 2

Table II

Pathologic Diagnosis	Percentage
Malignant tumors	35 8
Inflammatory	40 0
Benign tumors	12 5
Heterogeneous group of lesions	12 5

DIAGNOSIS

The most difficult problem in the management of any disease is the formulation of a correct diagnosis Especially is this true in the case of the small isolated lesion within the lung parenchyma whose presence can be detected only by x-ray

Since a goodly percentage of small rounded lesions within the lung are granulomas of various types, the appropriate skin test reactions are often employed Probability that a specific granulomatous process is not present, as indicated by negative skin tests, is of value [illegible] may represent the granulomatous form of either tuberculosis or one of the fungus diseases, should not give the physician any special assurance that the disputed mass is not tumor Since in so many cases the skin tests are far from diagnostic we have come to place little value upon them

The x ray, while of considerable worth in revealing the mass within the lung has not proved of great value in determining its true pathologic nature A smooth, well circumscribed border has often been considered a sign that the lesion was benign, while a roughened border which tended to streak into the normal lung tissue has been interpreted as a sign of malignancy Basically these maxims are correct, but undue reliance cannot be placed upon them in the individual case As an example take the widely held view that calcification

within the lesion is a sign of a benign process We have seen three instances of pulmonary carcinoma with x ray evidence of calcium within the mass Fibrosarcoma may also reveal evidence of calcification When the solitary rounded tumor is first seen it is often wise to resort to a survey of other body systems to determine if the lesion may be metastatic

TREATMENT

It becomes obvious that there is no reliable diagnostic pattern by which the true nature of the rounded isolated pulmonary tumor can be determined It has frequently proved disastrous to treat such lesions by periods of observation ranging from several weeks to many months It will be recalled that Graham and Singer, in a day when pulmonary resection was far from a safe procedure attacked such lesions with boldness The wisdom of their early approach has been amply proved in the many subsequent studies showing the high incidence of malignancy in these lesions It has become our custom to remove all such lesions unless (1) it is known to have been present over a period of many years or (2) it can be shown that it represents merely one of multiple metastases In situations other than the foregoing thoracotomy is performed

At operation if gross or frozen section examination reveals the presence of carcinoma lobectomy or pneumonectomy is performed At the present time there is considerable discussion as to the relative merits of lobectomy and pneumonectomy in the treatment of pulmonary malignancy In the absence of evidence of glandular involvement beyond the point of lobar drainage it has been fairly well demonstrated that lobectomy is as efficacious as pneumonectomy The question of the so called radical pneumonectomy might be raised but it is doubtful whether many persons know what a radical pneumonectomy really is It would seem to the authors that a bronchogenic carcinoma in a period of active growth is equally as well treated by lobectomy as pneu

(W M T) that those carcinomas of the lung which are cured are removed during a period of relative cellular inactivity

We have dealt with benign lesions by either removal of the segment in which they are contained or by local enucleation We have not resorted to the so called wedge clamp method. For some peculiar reason the vast majority of benign tumors and granulomatous lesions appear upon the lobar surface Thus they are rather easily removed by an enucleation procedure similar to removal of a thyroid adenoma, in which the individual vascular and bronchial elements are clamped, divided and ligated as encountered No attempt is made to close the defect thus created since, when this is done in the human or in the experimental animal the formation of air containing cysts or fibrosing hematomas occasionally occurs

In all patients the chest is drained for a period of twenty four hours with either one or two intercostal tubes and with or without suction depending upon the individual surgeon s fetish in this matter

COMMENTS

It should be obvious that any rounded object resembling tumor within the parenchyma of any organ is best treated by removal In this era when great propaganda campaigns are being carried on for the early detection and treatment of cancerous and pre-cancerous conditions it does not seem feasible to advocate a policy of watchful waiting on lesions which have a 38 per cent chance of being malignant Undoubtedly many persons have lost their lives because their physician has felt justified in watching a rounded mass to determine whether it will increase in size The growth of the primary tumor has nothing to do with its metastatic potentialities The authors have [illegible] ed ng he lesion was finally convinced that its removal was essential and on microscopic section it proved to be adenocarcinoma Whether this lesion originally was an adenoma is in our opinion beside the point since we believe that adenomas are actually adenocarcinomas It seems probable that the relative malignancy of an adenocarcinoma is quite as difficult to evaluate as whether a cartilaginous tumor is a chondroma or a chondrosarcoma It is likely that much depends upon the section of the tumor that is removed for study

Metastatic lesions in the lung have been removed on numerous occasions The results which have been accomplished in some of these

patients has been most gratifying It would seem that the best results have come in those patients in whom the metastatic lesion appeared at a considerable interval of time after the removal of the primary growth It is the experience of all thoracic surgeons that there is an increasing gradient of good results as the time lapse increases between the removal of the primary and the appearance of its secondary manifestations He who advises against the removal of a solitary, probably metastatic, nodule occurring over one year after the removal of the primary, assumes a heavy responsibility

For many years the feeling has been prevalent that thoracic exploration is a perilous method of arriving at a diagnosis in pulmonary disease Many physicians would advise that their patients be denied thoracic exploration while giving willing assent to an exploration of their peritoneal cavity In a day of competent anesthesia and surgery such reasoning shows a fundamental ignorance of the facts Exploratory thoracotomy today can be performed with a safety at least equal to that of exploratory laparotomy, and therefore flings wide the portals to the problem of the undiagnosed solitary pulmonary lesion

The preceding paragraph is pertinent as we approach the consideration of the 60 to 65 per cent of rounded pulmonary masses whose pathologic nature will prove to be either benign or inflammatory

Benign tumors of the lung, such as chondromas, fibromas or hamartomas seldom become malignant It is often difficult, however, to say whether a chondroma is truly a chondroma or a chondrosarcoma Most of these pathologic states appear the same by x-ray, and there are no diagnostic methods to distinguish between them Therefore, all must be removed

The rounded inflammatory mass within the lung has long been diagnosed by the pathologist as a tuberculoma, because it was caseating at its center and laminated at the periphery Many individuals have believed that the so-called tuberculoma was an innocuous lesion Recently Mitchell[4] has shown that in untreated patients there is about one chance in four of the progression of such a lesion or its evacuation into the tracheobronchial tree with widespread dissemination of the disease A similar observation was made by Mathers[5] who found that, over a period of five to ninety months, twelve of twenty-three tuberculomas either enlarged, cavitated or showed evidence of parenchymal spread Thus it would appear that the so-called harmless tuberculoma can on occasion prove quite noxious

Occasionally caseous lesions are found from which the tubercle bacillus can be grown, but in the great majority of the so-called pulmonary granulomas no tubercle bacilli can be demonstrated on smear or microscopic section, nor can they be grown on culture Recently Puckett[6] has shown, in a study of such lesions from the Fitzsimons General Hospital, that many of these patients actually suffered from a granulomatous form of histoplasmosis Brosius[7] has confirmed this study in a group of our own patients at Harper Hospital It is becoming increasingly evident that histoplasmosis can become a generalized fatal disease It would not, therefore, seem unwarranted to remove such potentially dangerous lesions

CONCLUSION

The problem of the benign appearing, "harmless," round lesion of the lung has been reviewed

REFERENCES

1 GRAHAM, E A and SINGER J J Three cases of resection of calcified pulmonary abscess (or tuberculosis) simulating tumor *J Thoracic Surg*, 6 173–183 1936

2 O BRIEN F J TUTTLE, W M and FERKANEY J Management of pulmonary coin' lesion *S Clin North America* 28 1313 1327 1948

3 JONES R C and CLEVE, E A *Arch Int Med* 93 842 849 1954

4 [illegible]

5

6

7 BROSIUS W L Personal communication

XXVIII. TRAUMATIC, CHEMICAL AND RADIATION INJURY

102

Injury To Lung

AUBRE DE L. MAYNARD, M.D., EMIL A. NACLERIO, M.D. AND JOHN W. V. CORDICE, JR., M.D.
New York, New York

From the Department of Surgery, Harlem Hospital New York N. Y.

A CONSIDERATION of trauma to the lung can not be disassociated from trauma to the thoracic wall and pleura, which almost invariably accompanies it. Normal respiratory function is dependent upon the integrity of the latter structures as upon the integrity of the lung itself. The intimate interrelationship of these three structures in carrying out the mechanical aspects of the vital function of respiration is the main characteristic which distinguishes this class of injuries from trauma elsewhere in the body.

PATHOLOGY AND PATHOLOGIC PHYSIOLOGY OF LUNG TRAUMA

The physiologic alterations in respiratory function accompanying lung trauma are referable basically to (1) Exudative or transudative reactions involving the tracheobronchial tree, respiratory epithelium and pulmonary interstitial tissue, (2) breaks in the anatomic integrity of the lungs, pleura and chest wall and their sequelae, (3) Traumatic and hemorrhagic shock and their sequelae.

When lung tissue is injured it reacts with the same processes of hyperemia, transudation, leucotaxis and exudation, and localized or diffuse necrobiosis which characterize the inflammatory reaction in other soft tissue to a variety of traumas. The type and severity of the reaction will depend upon the character and intensity of the inciting agent. This agent may be trauma of many types. A general classification follows:

(1) Gross physical trauma. Blast, contusion, penetrating missiles, etc., (2) radiation effect. Thermal burns, x ray, gamma radiation, etc., [illegible] smoke, [illegible] ory reaction, as elsewhere, appears to be an irritant sufficient to damage tissue and release certain tissue substances which stimulate a state of hyperemia, capillary dilatation and fluid and leukocyte transfer into the area involved. Even at an early stage in this process in the lung a critical physiologic derangement may develop. This is because any exudative or transudative reaction involving the alveolar or interstitial pulmonary tissue immediately imposes a physical barrier interfering with the transfer of gases from the alveoli across the respiratory epithelium into the capillaries and vice versa. When this derangement is localized, the reserve of pulmonary functioning tissue elsewhere in the lung prevents critical encroachment upon respiratory function. When this process is widespread, however, even at this early stage asphyxia will be precipitated when the respiratory reserve is not sufficient to carry the patient's metabolic needs.

Following the early stage, the progress of the inflammatory reaction will depend upon the presence of severe, prolonged or repeated traumatic insults, the presence of secondary bacterial invaders and the factors of tissue or serologic (immunologic) resistance to the bacterial invaders and toxins. The early reaction may progress to a pneumonitic picture, with the infiltration of leukocytes and other cellular elements and a deposition of fibrin.

When there is sufficient tissue damage, either primary (due to the initiating trauma) or secondary (due to an intense inflammatory or bacterial effect), lung necrosis will develop. This may liquefy, forming an abscess. The abscess may resolve or evacuate itself endobronchially, or erupt into the pleura forming an empyema. The size and location of the process, in addition to the other factors previously cited, will determine the eventual course.

In the process of healing the elaboration of fibrous tissue in injuries sufficient to produce tissue destruction is the rule. The extent and

-ntensity of the fibroplastic process depends upon the character and duration of the inflammatory reaction Evidence that there is regeneration of pulmonary alveoli after destruction is inconclusive and the weight of evidence is strongly against this [illegible]

Within the pleural potential space there is a pressure which is negative in reference to atmosphere This is the result of the elastic recoil of the lungs pulling upon the collapsed airtight space within the relatively unyielding bony thorax This pressure negativity is transmitted throughout the chest and has its effect upon the intrathoracic organs Regular cyclic variations in the amount of negativity produced by the diaphragm and other muscles of respiration result in the inflow and outflow of pulmonary air and assist in the filling of the great veins and the heart During normal quiet respiration inspiration is accomplished by contraction of intercostal and diaphragmatic muscles raising the costal arcs and depressing the diaphragm thereby actively increasing the intrathoracic volume Expiration under this circumstance is passive occurring when these muscles relax When respiration is more active (tachypnea hyperpnea dyspnea) or when there are exaggerated movements such as sneezing or coughing expiration also becomes an active phase with chest neck and abdominal muscles brought into play Derangement of this balanced system may be caused by pneumothorax or hemothorax conditions resulting when the pleural cavities contain air or blood or by an instability of the chest wall

Breaks in the anatomic integrity of the bronchi and other air containing element of the lung with an intact visceral pleura may give rise to pulmonary interstitial emphysema (P I E) [illegible] If this accumulation of air breaks through the visceral pleura pneumothorax results If the trachea bronchi or primary bronchioles are involved in the injury or if there is dissection of the air centrally along the course of the bronchi and pulmonary blood vessels mediastinal emphysema will result (Fig 1)

Mediastinal emphysema regardless of etiology is a grave complication for two principal reasons first because of the production of a mediastinal pressure which prevents adequate filling of the great veins and heart and is rapidly fatal and second because of the frequent accompaniment of mediastinal infection which by pressure and sepsis rapidly produces death The physical findings accompanying the development of mediastinal emphysema are characteristic and it is important to recognize them early so that definitive measures may be taken without delay Frequently there

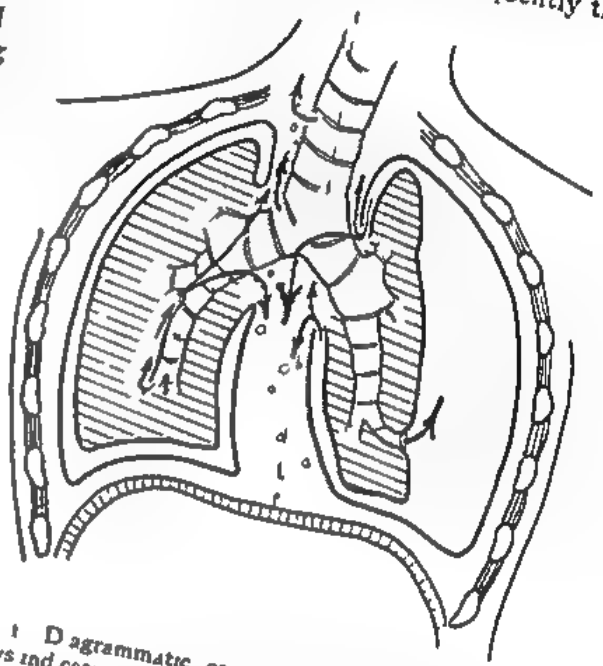

FIG 1 Diagrammatic cross section of chest with arrows indicating routes by which air from the respiratory tract may form mediastinal emphysema on the left from the trachea bronchus and from pulmonary interstitial emphysema travelling centrally along the bronchovascular structures on the right from pneumothorax by leaks in the pleura in the superior and inferior hilar regions

is a feature of the history other than trauma to the chest such as foreign bodies in the esophagus or respiratory tree and recent esophageal or tracheobronchial endoscopy which will lead us to a high index of suspicion of this development

Early the patient will complain of substernal (or subxiphoid) pain which is aggravated by swallowing or breathing At this time auscultation may reveal a precordial crunching sound synchronous with the heart beat (Hamman's sign) There may also be guarding of the movements of the neck There is then noted crepitus on palpation of the cervical presternal or epigastric regions and distention of the neck veins and progressing degrees of circulatory failure as the pressure on the great veins grows extending into frank shock collapse and death This progression may occur very

FIG 2 X ray film showing mediastinal emphysema which developed in a twelve year old girl within minutes following perforation of a foreign body through the left main bronchus Air streaking and widening of the mediastinum and air dissecting up into the fascial planes of the neck are well seen

rapidly within four to eight hours With it may be an accompanying dyspnea and cyanosis which reflect the effect of circulatory failure, more than the pressure on the trachea and bronchi These latter structures are semi rigid and maintain their patency after the mediastinal pressure has obstructed the great veins

A prominent feature is the voice change which occurs due to pressure and tension on the recurrent laryngeal nerves The sound is metallic strained and slightly hoarse a nasal quality is also characteristic In some cases the terminal event may be signs of progressing sepsis Sepsis may occur in spite of surgical decompression of the mediastinum if the mediastinum has been heavily seeded with bacterial organisms from the site of leakage

since retrosternal air will be seen clearly

Rupture of interstitial emphysema through the visceral pleura or the direct or indirect communication of a bronchus bronchiole or alveolus with the pleural cavity, causes what is called *closed* pneumothorax Pneumothorax may also follow rupture of mediastinal emphysema into the pleura[7] If the penetration comes through the parietal pleura with a communication of the pleural space to the outside through the chest wall or indirectly through the diaphragm and abdominal wall (as occasionally seen during abdominal surgery) *open* pneumothorax is said to exist

When a defect in the parietal pleura is present with pneumothorax air frequently escapes into the subcutaneous tissue producing subcutaneous emphysema Alarming swelling of the subcutaneous tissues will occur if there is persistent leakage through the parietal pleural defect or if there is communication with the bronchial passages through a zone of pleural symphysis at the place of penetration However the swelling which may extend from the face down to the legs along the fascial planes is essentially innocuous giving rise to no great danger or discomfort (Fig 3A and B)

The collapse of one lung resulting from pneumothorax ordinarily can be compensated for by the ventilatory capacity of the remaining lung However, a dangerous situation arises when there is a progressive increase of air with a build up of tension within the pneumothorax cavity When the visceral pleura or chest wall defect acts as a valve permitting air to enter the pleural cavity during one phase of respiration and not permitting escape during the other successive increments of air build up the intrapleural tension In closed pneumothorax forced expiration against a closed or partially closed glottis as in coughing pushes air through the visceral defect into the pleural space under great pressure The same events may follow rupture of an emphysematous bulla or bleb In open pneumothorax tension will develop when the chest wall defect allows air to enter during inspiration and does not permit escape during expiration (Fig 4) This repetitious build up of pressure completely collapses the lung on the affected side displaces the mediastinum away from the affected side angulates and tends to collapse the great veins and seriously interferes with cardiac filling With the mediastinal displacement the opposite hemithorax is encroached upon and the ventilatory capacity of the remaining lung is lessened Unless relieved promptly the condition results fatally

In open pneumothoraces with external openings smaller than the glottic opening and with

3A 3B

[illegible] Right

out the valve like phenomenon of the wound, there is collapse of the lung on the affected side, but no development of tension pneumothorax An open wound exists through which air both enters and escapes, and there [illegible] a to and fro motion of the mediastinum to some degree, but the patient may stabilize in spite of these conditions

In open pneumothoraces with external openings larger than the glottic aperture itself, the volume exchange occurs less from the lung through the trachea and glottis with the respiratory effort, but more from the pneumothorax through the chest wall defect This extrapulmonic exchange which is proportional to the relative size of the glottic and chest wall openings obviously cannot effect aeration of blood Meanwhile the intrapulmonic air merely swings from one lung to the other ("Pendelluft Phenomenon"), in association with swinging or fluttering of the mediastinum back and forth In addition to the failure of respiratory effort, the to- and fro-shift of the mediastinum exerts a great interference with the return of venous blood to the heart by angulating the venae [illegible] super-

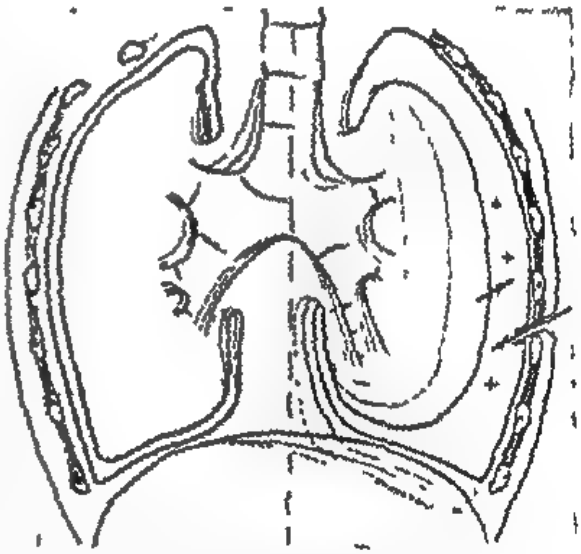

FIG. 4 Diagrammatic cross section of chest representing the stages of development of tension pneumothorax Progressive collapse of lung, shift of the mediastinum and depression of the diaphragm on the affected side are seen This follows the intake of air through a pulmonary or chest wall defect during one phase of respiration and failure to release this air during the other phase Increasing increments of air pressure are added to the pleural space as through a valve resulting in this condition

of the

thorax is destroyed by a crushing injury, respiration [illegible] reflected in flail-like, paradoxic motion of the unstable portion of the chest wall This occurs, for example, when a number [illegible] or more

thorax These segments then passively sink in

with inspiration and move outward with expiration (Fig 5) This diminishes the efficiency of the respiratory effort and wet lung rapidly develops When a large area of the chest wall is unstable or when both chests and the sternum or both have been crushed the

This is the mechanism of fatality following blast injuries to the lung In these injuries there is extensive rupture of bronchioles alveoli and their blood vessels Interally drowning the patient with hemorrhage and transudate

Hemorrhage from the thoracic wall ie

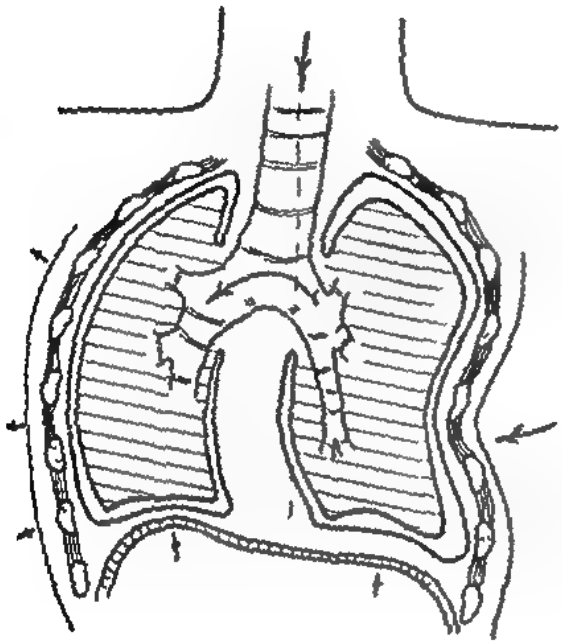

5A

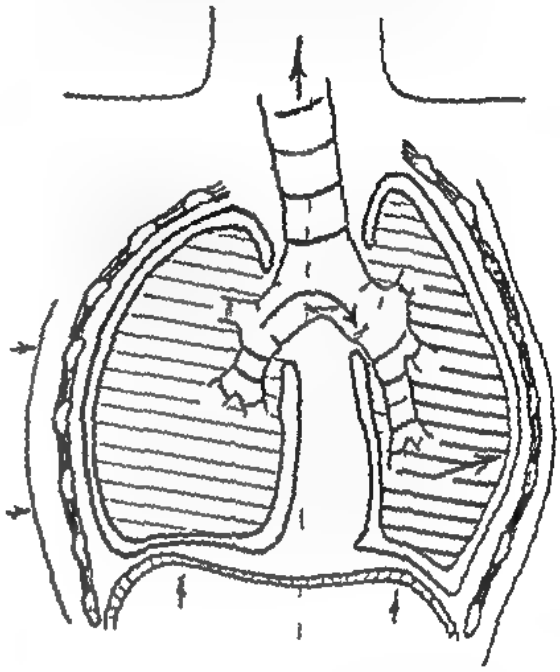

5B

phase show ng s ak ng be ng taken into lung hase show ng push ng into the lung on the mpr se (1) paradoxic

paradox must be stopped promptly or death will ensue

Hemorrhage occurs from pulmonic or chest wall vessels Hemorrhage from the lung itself may be exsanguinating if large pulmonary vessels are opened and occasionally operation with control or lobectomy or pneumonectomy may be necessary Most often however blood loss from the lung is not great enough in itself to cause death from hemorrhage and it usually controls itself Low pressure in the pulmonary vessels and frequent partial collapse of the lung due to pneumothorax or hemothorax assist in hemostasis With traumatic rupture of bronchial or alveolar structures there may be rupture of blood vessels with intrabronchial intra alveolar or interstitial hemorrhage This hemorrhage may seriously interfere with respiratory function by filling air passages and interstitial tissues with blood

intercostal and internal mammary vessels is a frequent problem and exsanguinating hemorrhage may occur from either of these sites In a few cases of injury moderate to severe hemothorax manifests itself after a three- to eight day period of freedom from clinical signs and symptoms (late hemothorax) The intercostal arteries except for the first and second come directly off the aorta are of good size [illegible] An injury

be a treacherous injury because the bleeding like that of the internal mammary may be within the chest and concealed The internal mammary vessels are also of large size come off the subclavian arteries and carry high pressures The bleeding from these vessels is most often concealed within the chest, but their location about 1 cm lateral to the sternal

border on each side, will lead to a high index of suspicion of injury to this vessel in all wounds in this area

In controlling hemorrhage from the intercostal and internal mammary vessels, the collateral arterial channels in each case must be remembered (Fig 6) Because the internal mammary arteries connect with the intercostals (to the fifth anteriorly), musculophrenic and superior epigastrics, these vessels have a potent arterial anastomosis peripherally and unless both sides of any bleeding point are ligated, bleeding will not be controlled

In our experience control of the intercostals is accomplished chiefly by proximal ligation Their distal ends, although anastomosing through connecting branches with the internal mammary in the upper five vessels, are of small cal ber and do not [illegible]

the pleural membrane or the sudden development of pneumo- or hemothorax It appears to be a primary or reflex phenomenon and is seldom severe or prolonged

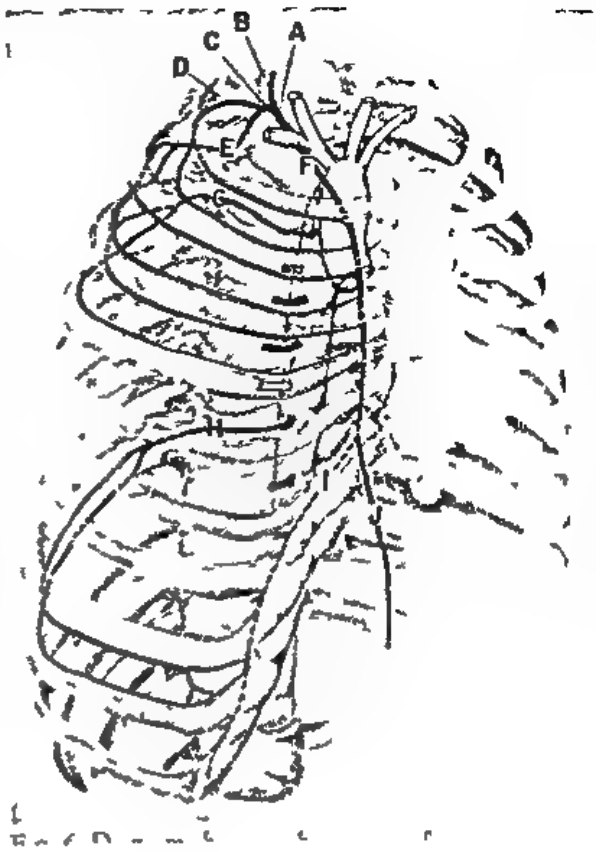

connections A, costocervical trunk, B deep cervical branch C, superior intercostal, D, first intercostal, E second intercostal, F, internal mammary, G third intercostal, H, eighth intercostal I, musculophrenic, J, superior epigastric

SPECIFIC PULMONARY INJURIES AND THEIR TREATMENT

The various pulmonary injuries and their treatment may be analyzed in terms of the development of a number of morbid components associated with these injuries These morbid components are (1) shock, (2) anoxia, (3) hemorrhage, (4) pneumothorax, (5) the unstable chest wall and (6) infection

Emphasis on the aforementioned components will vary according to the type and extent of the injury

An outline of the principal lung injuries follows

I Non penetrating injuries to lung
  A Blast injury
  B Burns
    1 Chest wall burns
    2 Inhalation burns
  C Inhalation trauma
  D Radiation trauma
  E Crushing trauma to chest
II Penetrating injuries to lung
  A Foreign bodies
  B Rib fractures

NON-PENETRATING INJURIES TO THE LUNG

Blast Injury Blast or concussion injury is caused by the transmission of shock or pressure waves through the chest of a victim who is in proximity to the point of detonation of an explosion The severity of the injury is related to the nearness of the victim to the blast, the type of explosive (high explosives cause more damage) and the medium through which the pressure wave is transmitted before reaching the body Shock waves passing through water are much more damaging than waves originating from a similar explosion in air This is because water is heavier and much less compressible than air This allows it to transmit the shock wave faster and with much more sustained intensity from its point of origin The same pressure phenomenon is caused by localized contusions of the chest following falls or

with inspiration and move outward with expiration (Fig 5) This diminishes the efficiency of the respiratory effort and wet lung rapidly develops When a large area of the chest wall is unstable, or when both chests and the sternum or both have been crushed the

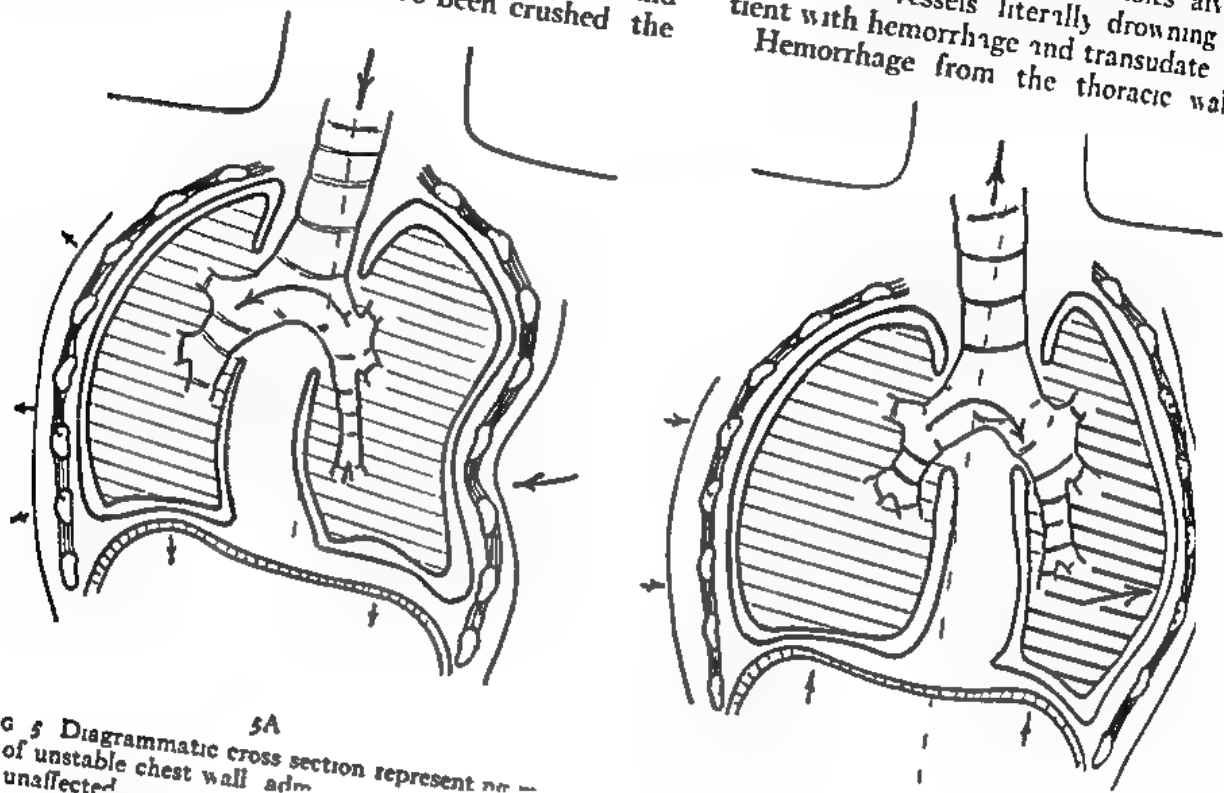

FIG 5 Diagrammatic cross section represent pr — in of unstable chest wall adm on unaffected out of unst damaged sic movement ■

5A

paradox mu will ensue

Hemorrhage occurs from pulmonic or chest wall vessels Hemorrhage from the lung itself may be exsanguinating if large pulmonary vessels are opened and occasionally operation with control or lobectomy or pneumonectomy may be necessary Most often however blood loss from the lung is not great enough in itself to cause death from hemorrhage and it usually controls itself Low pressure in the pulmonary vessels and frequent partial collapse of the lung due to pneumothorax or hemothorax assist in hemostasis With traumatic rupture of bronchial or alveolar structures there may be rupture of blood vessels with intrabronchial intra alveolar or interstitial hemorrhage This hemorrhage may seriously interfere with respiratory function by filling air passages and interstitial tissues with blood

This is the mechanism of fatality following blast injuries to the lung In these injuries there is extensive rupture of bronchioles alveoli and their blood vessels literally drowning the patient with hemorrhage and transudate

Hemorrhage from the thoracic wall ie intercostal and internal mammary vessels is a frequent problem and exsanguinating hemorrhage may occur from either of these sites In a few cases of injury, moderate to severe hemothorax manifests itself after a three- to eight-day period of freedom from clinical signs and symptoms (late hemothorax) The intercostal arteries except for the first and second come directly off the aorta are of good size posteriorly and carry high pressure An injury particularly posteriorly, to an intercostal vessel may have to be controlled directly This may be a treacherous injury because the bleeding like that of the internal mammary may be within the chest and concealed The internal mammary vessels are also of large size come off the subclavian arteries and carry high pressures The bleeding from these vessels is most often concealed within the chest but their location about 1 cm lateral to the sternal

border on each side, will lead to a high index of suspicion of injury to this vessel in all wounds in this area

In controlling hemorrhage from the intercostal and internal mammary vessels, the collateral arterial channels in each case must be remembered (Fig 6) Because the internal mammary arteries connect with the intercostals (to the fifth anteriorly), musculophrenic and superior epigastrics, these vessels have a potent arterial anastomosis peripherally and unless both sides of any bleeding point are ligated, bleeding will not be controlled

In our experience control of the intercostals is accomplished chiefly by proximal ligation Their distal ends, although anastomosing through connecting branches with the internal mammary in the upper five vessels, are of small caliber and do not produce a problem of retrograde bleeding (Fig 6)

Pleural shock is a state of circulatory depression which may be incident to penetration of the pleural membrane or the sudden development of pneumo- or hemothorax It appears to be a primary or reflex phenomenon and is seldom severe or prolonged

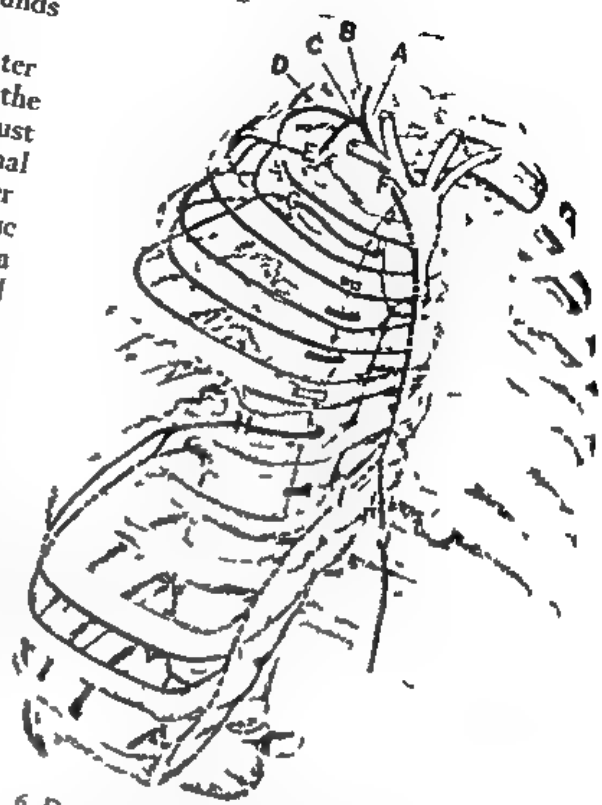

Fig 6 Diagram showing the origins of the intercostal, intercostal collateral and internal mammary arteries on the right side the courses and relationships of these vessels to the thoracic cage and their major anastomotic connections A costocervical trunk B deep cervical branch C, superior intercostal D first intercostal E second intercostal F internal mammary G third intercostal H eighth intercostal I musculophrenic J superior epigastric

SPECIFIC PULMONARY INJURIES AND THEIR TREATMENT

The various pulmonary injuries and their treatment may be analyzed in terms of the development of a number of morbid components associated with these injuries These morbid components are (1) shock, (2) anoxia (3) hemorrhage, (4) pneumothorax, (5) the unstable chest wall and (6) infection

Emphasis on the aforementioned components will vary according to the type and extent of the injury

An outline of the principal lung injuries follows

I Non penetrating injuries to lung
  A Blast injury
  B Burns
    1 Chest wall burns
    2 Inhalation burns
  C. Inhalation trauma
  D Radiation trauma
  E Crushing trauma to chest
II Penetrating injuries to lung
  A Foreign bodies
  B Rib fractures

NON-PENETRATING INJURIES TO THE LUNG

Blast Injury Blast or concussion injury is caused by the transmission of shock or pressure waves through the chest of a victim who is in proximity to the point of detonation of an explosion The severity of the injury is related to the nearness of the victim to the blast the type of explosive (high explosives cause more damage) and the medium through which the pressure wave is transmitted before reaching the body Shock waves passing through water are much more damaging than waves originating from a similar explosion in air This is because water is heavier and much less compressible than air This allows it to transmit the shock wave faster and with much more sustained intensity from its point of origin The same pressure phenomenon is caused by localized contusions of the chest following falls or

direct blows and by the passage of high velocity *missiles through the chest* In all of these the pressure wave, passing rapidly and suddenly through delicate pulmonary tissues, tends to disrupt them *The principal pulmonary effect is* seen in rupture of alveoli and capillaries, although larger bronchial and vascular elements may be similarly damaged As described earlier, there is an ensuing permeation of the damaged area with transudate and blood and a so-called traumatic wet lung develops Grossly, there is a transformation of the normal spongy aerated organ to a dense, airless, hepatized organ The role of reflex factors in the production of traumatic wet lung have not been completely elucidated although they undoubtedly play a part

After a patient sustains a blast injury numerous moist rales and a wet, ineffective cough develops With the increasing intrabronchial fluid, atelectasis and pneumonitis occur and spread to areas of the lung which may not have been primarily damaged by the blast *This is accompanied by increasing* dyspnea and cyanosis When the blast effect is generalized, as in some of the more severe blast injuries, treatment is ineffective and death ensues promptly In the more localized or less severe cases the use of measures to combat anoxia atelectasis and infection may be successful Anoxia in these patients is treated by encouraging and assisting the patient to cough up endobronchial fluid Close supervision with good nursing care, minimal sedation, particularly the avoidance of narcotics that may depress the respiratory center in therapeutic dosage, the administration of oxygen and the use of intratracheal suction, bronchoscopy and occasionally tracheotomy to remove secretions are the methods of approach With effective removal of secretions and transudate, the atelectasis is prevented or relieved

Adequate doses of antibiotics must be given to help prevent and control pneumonitis General supportive care is given but the use of infusions and transfusions must be undertaken with the utmost care Electrolyte solutions especially, aggravate the condition of wet lung In the management of these cases one must appreciate the amount of local lung damage and this must be weighed against the systemic fluid imbalance that exists, remaining fully aware that the injudicious use of electrolyte solutions constitutes a definite hazard When the patient's condition or other associated injuries dictate the use of supportive fluids whole blood, slowly administered under close supervision, has been our preference

Burns *Thermal burns applied to the chest* wall seldom penetrate deeply enough to burn the lung itself, except in cases of advanced *charring and destruction of the chest wall* by flame in which case the patient seldom survives beyond rescue Burns of the chest wall do exert noxious effects upon the lung, however by restricting motion of the chest in two ways Painful first and second degree burns of the chest wall cause marked guarding and splinting of the chest This is a conscious as well as a reflex attempt to avoid motion of the chest which would increase the pain *Also third* degree burns, although not painful may present a dense, inelastic, leathery, coagulation eschar which will mechanically restrict the respiratory motion of the chest *Abdominal* breathing will also be restricted by these same mechanisms operating in the abdominal wall *The total effect on the lung* is the same Restricted motion makes it difficult to rid the tracheobronchial tree of secretions Retained secretions produce blockage and atelectases anoxia and pneumonitis Reflex mechanisms demonstrated experimentally by Detakats[5] in a wide variety of chest wall injuries may also operate here to increase tracheobronchial mucorrhea and hasten the process of atelectasis It is apparent, therefore, that the effect of burns of the chest wall on the *lung are independent* of the direct thermal effect on the lung However, this direct effect may occur to a *relatively minor degree in some cases*

When flame, or hot air or *gases are inhaled* by the patient, burns are produced through the respiratory passages, from the external nares down through the oropharynx glottis larynx and tracheobronchial tree Depending upon the intensity of the heat and the amount of inhalation, the burns may extend to or past any of the structures named and they may be involved in first, second or third degree burns *The events which follow are* swelling of the involved mucous membrane and hypersecretion by glandular elements, infection of the damaged mucous membrane and the addition of suppurative material to the glandular mucorrhea Swelling of the laryngeal and glottic areas prevents effective coughing and also produces respiratory obstruction and *stridor* This

necrotizing tracheobronchitis and respiratory obstruction soon produce bronchopneumonia which kills the patient

Burns of the nasal passages and pharynx carry a very grave prognosis even though they may be accompanied by only a small burned area of the face When first seen the patient may appear to be comfortable and stabilizing well following his injury The presence of hoarseness and a cough is the indication that the burn has extended into the respiratory tract When the inevitable processes of glottic edema and suppuration within the tracheobronchial tree supervene, and they may take from six to seventy-two hours, the mortality in these cases is extremely high

Treatment in cases of burns of the chest, and particularly respiratory tract burns, must be concerned with the early and continued maintenance of a patent airway and clearing this airway of tracheobronchial secretions Oxygen administration, catheter suction of the pharynx and tracheal suction bronchoscopy and tracheotomy as indicated may be used Large quantities of antibiotics are used to combat infection Hygienic care of the oropharynx is maintained by suction and frequent irrigation with hydrogen peroxide and antibiotics must also be avoided in the management of these cases

Inhalation Trauma There are a host of substances which when inhaled may traumatize the tracheobronchial tree and lungs by their chemical properties Ficklen,[9] in his manual, reviews more than ninety vapors, gases and dusts which are important as industrial health hazards In general, these substances act acutely as local irritants on the lung and tracheobronchial tree, or slowly as the pneumoconioses producing pulmonary interstitial fibroplasia There are also the group of war gases, which when inhaled give an intense irritative effect Space will not permit a discussion of these individual substances

By far the most common offender to which most of the population in urban areas is exposed is smoke Smoke originates in domestic and industrial sources and may constitute a public health problem as well as an economic one by its irritative and destructive properties The usual smoke which comes from the burning of coal contains varying concentrations of tars, grit, ash, sulfur dioxide and other chemicals The sulfur dioxide combines with oxygen of the air and moisture to form sulphuric acid which has a destructive effect on clothing, metal, stone and other building materials and vegetation, as well as the respiratory tracts of persons breathing such fumes The grit and ash also contain small amounts of silica which, after a time, will produce fibroplastic changes in the lungs of persons heavily exposed Under certain atmospheric conditions when smoke in a given area is not diluted and dispersed, a condition of concentrated smog or smaze may develop and continue for days at a time Pulmonary irritative phenomena may then constitute a public health problem of major proportions Pharyngitis, laryngitis and tracheobronchitis with mucorrhea and cough develop in persons exposed During these periods the death rates from respiratory diseases and heart diseases rise significantly as a direct result of superimposition of this pulmonary effect

Radiation Trauma Radiation trauma to the lung is a class of injury which until recently has been seen relatively rarely and usually in relation to the use of radiation therapy to the [illegible] in warfare, we may expect to see this injury more frequently [illegible] latent periods following the exposure before the symptoms of injury develop Third, the effects are likely to be more severe and prolonged than a thermal burn, although the last two characteristics are dependent upon the type and duration of the radiation Hematopoietic tissue particularly is severely damaged by penetrating radiation

The details of the tissue changes resulting from ionizing radiations are still very poorly [illegible]

FIG 7 Photograph demonstrating tracheobronchial suction Assistant holds tongue forward and directs light into pharynx Operator introduces a stiff rubber tube through nostril into oropharynx Suction is then started while tube is being introduced into trachea The open mouth proves of value in directing the tube

tion of water and other tissue components This concept f
reducing
or aminic
the tissue effects of radiation

The tissue reaction to radiation in lung begins with hyperemia, edema and round cell infiltration and progresses on to bleb formation and varying degrees of cellular necrosis, fol lowed by infection and suppuration This process in the lung bears an obvious relationship to the development of respiratory com plications There have been few accurate and detailed studies of radiation pneumonitis *although the course of events, as indicated by* the work of Lobsenz,[10] makes it appear that in marginal and sublethal injuries non specific treatment of the *resulting pneumonitis* with antibiotics oxygen administration and the maintenance of an adequate airway may be expected to have good effect The use of cysteinamine or other reducing substances vitamin B_{12}, and hematinic compounds and antibiotics may be of value in ameliorating the systemic effects of exposure to radiation Work is continuing in this field but at the present time there appears to be no substance as yet available which will give significant protection against, or arrest and reverse, the cytologic effects of intense radiation exposure such as would be produced by an atom or hydrogen bomb

Crushing Trauma to the Chest Crushing injuries to the chest occur frequently in falls automobile and airplane accidents and other forms of gross physical trauma to the body Their immediate mortality is high because they are frequently associated with rupture of the heart or great vessels fatal spinal and cerebral injuries extensive fractures and decapitation or other dismemberment of the body Of itself however, a crushing injury to the chest may be rapidly fatal by setting into motion the chain of events which have been described herein previously Any part of the chest may be stove in and a particularly lethal situation arises when both chests are crushed or when both chests are made unstable by *extensive bilateral costochondral fractures* and a flail sternum There may or may not be a penetration into the chest and pneumothorax but the mechanical forces previously described produce anoxia, shock and death

Treatment is primarily directed at stabilizing the chest wall This may be done by sandbags or strapping if the area is unilateral and fairly small in size More extensive instability must be handled by traction to the unstable sternum or chest wall by tenacula, towel clips or wires Direct wiring or bone grafting of the *unstable ribs can be done in some* instances However it is done, the stabilization of the chest wall is mandatory and ingenuity is sometimes required to accomplish this No one method of stabilization is applicable to all cases The maintenance of chest wall stability may be assisted by the use of positive pressure oxygen either by mask or by tracheotomy tube Jansen's method of keeping the pressure of the *air in the tracheobronchial tree always* somewhat above atmospheric pressure even during expiration, has been reported as reducing paradoxic movement of the unstable chest and flutter of the mediastinum [11] At the same time this is effective treatment for the pulmonary edema or wet lung We have not committed ourselves to a use of this method because of danger in impeding expiration with positive pressure and the lack of a well standardized mechanical breathing apparatus

Avery and associates[12] *have successfully* treated the flail thorax of patients with critically crushed chests by using internal pneu
mechani
used
ator
which delivers a fixed volume of gases for

intermittent positive pressure endotracheal ventilation is They emphasize that mechanical ventilation has not been effectively applied in the past because of (a) improperly designed apparatuses, (b) the time-honored fear of the adverse effects of the active hyperventilation and (c) the numerous references in the literature regarding deleterious response of the circulation to intermittent positive pressure insufflation.

An open and clear airway must also be maintained Frequently this can be accomplished by transnasal suction (Fig 7) Tracheotomy, in order to avoid obstruction at the laryngeal or glottic level and to enable tracheobronchial secretions to be removed easily and repeatedly, should be performed without delay if it appears needed Supportive treatment in the form of shock therapy, antibiotics, judicious sedation and the care of associated injuries completes the plan of therapy

Pneumothorax and hemothorax also frequently occur following multiple rib fractures in this type of injury The handling of these complications is discussed in the following section

PENETRATING WOUNDS OF THE LUNG

Penetrating trauma to the lung may be inflicted by foreign bodies such as knives, bullets and other missiles or by the fragment of a broken rib, where displacement so as to impinge upon the lung occurs

Foreign bodies which are of low velocity, such as knives, and the penetration of rib fragments cause localized tissue damage in the site or tract of injury, but in general such wounds are tolerated well by the lung and unless infection supervenes, healing is prompt Furthermore, bleeding is not likely to occur in massive amount from the lung, and the leakage of air into the pleura is only temporary, the defect sealing itself promptly as a rule

With penetration by high velocity missiles, such as bullets and shrapnel, the tissue defect is likely to be larger and this defect is surrounded by a zone of devitalization due to blast or concussive effect Therefore, the complications of pneumothorax, hemothorax, and infection are more frequent and severe Surgery in these cases is usually confined to the debridement and care of the external wounds Further surgical operative management will be required when bleeding from lung, intercostal artery or internal mammary artery are not controlled, or when lung or thoracic wall damage is very extensive Exploration may also be indicated to rule out or repair damage to heart, great vessels, trachea, bronchi or esophagus Exploration will also be indicated in cases of diaphragmatic injury and in this instance abdominal exploration as well may have to be performed The extent of pneumothorax may be followed by watching the physical signs (auscultatory signs, respirations, shock, etc), performing serial pneumothorax readings and taking x rays of the chest A large or sucking wound of the chest must be closed immediately One must be on the alert for progressive pneumothorax or the development of tension A stabilized pneumothorax, even of fairly large degree, may do no harm if the patient tolerates it well and it may have the advantage that the partially collapsed lung tends to control air leaks and hemorrhage quicker Therefore, we believe that if pneumothorax is minimal or moderate and not increasing, and the general condition of the patient is stabilized, no urgent evacuation of the pneumothorax is necessary A persisting pneumothorax may be removed later at a convenient time by aspiration

If the pneumothorax is massive when seen or is increasing in size, or if there are signs of encroachment upon respiratory function, needle aspiration or decompression by underwater drainage must be performed immediately If there is evidence of increase, persistence or recurrence of the pneumothorax so treated, a small rubber tube placed into the chest through a trocar and led to underwater drainage, or a polyethylene tube similarly placed through a large bore needle (15 gauge) provides sure and continuous decompression of the pleural cavity Only relatively rarely will it be necessary to explore a chest to control air leaks from lung or bronchi

With hemothorax it must be remembered that dangerous hemorrhage occurs most often from the thoracic wall rather than from the lung The factors that govern the decision to operate to control hemorrhage are location of the wound (areas of internal mammary and posterior intercostals, especially), size of the hemothorax when first seen and its subsequent progress, and other evidences of continuing or massive hemorrhage such as falling hemoglobin and hematocrit, pallor, air hunger and shock. Chest wall vessels, internal mammary and intercostal, may be approached and ligated extrapleurally However, it must be remembered that massive hemothorax may follow injuries to the heart, aorta, vena cavae, or

major pulmonary vessels and open thoracotomy will be dictated when there is a suspicion of injury to any of these structures We have had four cases in which there were combined injuries of the vessels of the internal mammary and the heart

If the hemothorax is small or moderate close observation of the patient and x ray and auscultatory checks of the extent of the hemothorax must be made If distress occurs due to pressure of the hemothorax or mediastinal shift immediate aspiration is performed to give relief

A hemothorax should be evacuated by repeated needle aspiration to remove as much of the blood as possible The sooner that this is done after cessation of bleeding the greater the likelihood of success in complete evacuation Instillations of streptokinase may aid in this although there have been reactions encountered with the use of the drug and it may predispose to a recurrence of bleeding We favor beginning aspirations within twelve to twenty four hours after cessation of hemorrhage and stabilization of the patient Daily aspirations are performed until no more blood can be obtained

The sequel to an incompletely drained hemothorax is a captive hypofunctioning lung enclosed by organizing blood clot which must be removed surgically by decortication Small degrees of residual clotted hemothorax may be absorbed It is our procedure however to perform early decortication after three to six weeks if there is not continued significant diminution in the pleural clouding on follow up x rays *Decortication at this time is technically easier and the continuing functional capacity of the lung is assured*

Rib Fractures Fractures of ribs where only one or two ribs are involved and there is no threat to the stability of the chest may be best treated by intercostal block with xylocaine or a similar local anesthetic to relieve pain Strapping of the involved area of the chest with adhesive tape or elastoplast bandage also gives relief from pain at the expense however of diminishing the movement of the thorax This may have a distinct disadvantage in an older patient especially when a wide segment of the thorax is involved Direct wiring for fixation of ribs or a combination of multiple intercostal blocks with gentle taping may be recommended in more extensive cases The unstable chest in multiple rib injuries has been discussed

SUMMARY

A brief consideration has been made of the pathology of the principal types of lung trauma with incident or closely allied trauma to chest wall and pleura

It has been emphasized that failure of respiratory function secondary to a number of mechanisms is the lethal factor in most of these injuries

Specific injuries are discussed and outlines of therapy given based largely upon our experience in the management of cases at Harlem Hospital

REFERENCES

1 VALLE A R and MIDER G B The mechanism of healing of lung tissue and its reaction to different suture material *J Thoracic Surg* 19 324 331 1950

2 MONTGOMERY G L. Healing of experimental wounds of lung *Brit J Surg* 31 292–299, 1944

3 OLCH I Y and BALLON H C. The origin of scar tissue in healing of the lung *Arch Surg* 19 1595 1601 1929

4 JOANNIDES M HESSE A L and JOANNIDES, M Jr Surgical wounds mode of healing of pulmonary tissue *J Thoracic Surg* 18 605 606, 1949

5 MACKLIN C. C. and MACKLIN M T Pulmonary Interstitial Emphysema and its Sequellae An Anatomical Interpretation Essays in Biology in Honor of Herbert M Evans pp 331 368 Berkeley and Los Angeles 1943 Univ of California Press

6 MACKLIN M T and MACKLIN C. C Malignant interstitial emphysema of the lungs and mediastinum as an important occult complication in many respiratory diseases and other conditions *Medicine* 23 281 358 1944

7 [illegible] and [illegible]

8 [illegible] L. Reflex pulmonary atelectasis *J A M A* 10 686–690 1942

9 FICKLEN J B Manual of industrial health hazards West Hartford Conn 1940 Service to Industry

10 LOBSENTZ H LEVINE A and SEROPIAN D An experimental study of radiation pneumonitis. *Bull New York Acad Med* 28 547 1952

11 JENSEN N K Recovery of pulmonary function after crushing injuries of the chest *Dis of Chest* 22 319–343 1952

12 AVERY E E Morch L T Benson D W Crit ment 311 1956.

13 MORCH E T SAXTON Jr G A GIGG Artificial Respiration Via the Uncuffed Tracheostomy Tube *J A M A* 160 864 86 1956.

103

Diseases of the Pleura*

LOUIS L. FRIEDMAN, M.D., *Birmingham, Alabama*

From the Friedman Diagnostic Clinic, Birmingham, Alabama

ALTHOUGH the pleura is only a paper-thin serous membrane, its anatomic size fails to reflect its real importance in health and disease. By virtue of its position and disease resistant properties, it may act as a barrier to the further spread of disease in the endothorax. Diseases of the pleura are very rarely primary. With the exception of mesothelioma of the pleura, primary involvement by nontuberculous processes is indeed a rare occurrence. Because of its intimate relationship with the lung and other thoracic and upper abdominal structures, it is only too frequently secondarily involved by diseases of adjacent and neighboring organs. Certain generalized systemic illnesses also show an unusual predisposition for pleural involvement. Indeed, the pleura can fall heir to almost any disease which involves contiguous or distant tissues. In view of these facts the need for a clear and concise classification of pleural diseases is imperative. Unfortunately, the large number of disease entities which involve the pleura, together with our limited knowledge of many, precludes the possibility of satisfactory classification. For simplicity, pleural diseases will be classified as inflammatory, mechanico-circulatory and neoplastic.

ANATOMY AND PHYSIOLOGY

The pleura closely invests the outer surface of the lungs and lines the endothorax. The part which invests the lung is known as the visceral pleura while the part which lines the endothorax [illegible] to its anatomic location. Under normal conditions the pleura is a glistening, moist, transparent membrane. The free surface is lined by a single layer of mesothelial cells which rest on a delicate elastic limiting membrane. Beneath the latter membrane is found the loose connective tissue stroma. This is composed of collagenous and elastic fibers disposed at various angles but, generally, parallel to the free surface. The cellular elements are predominantly fibroblasts and macrophages. A subserous layer of tissue is responsible for the close adherence of the pleura to the related underlying structures. Beneath the visceral pleura it is very thin and continuous with the elastic interlobular tissue. Underneath the parietal pleura, however, this layer is thickened, particularly in the cervical and mediastinal portions. The air tight space, or sac, created by the free surfaces of the visceral and parietal pleura is known as the pleural cavity.

Normally, the visceral and parietal pleurae are everywhere in close apposition with the possible exception of the costomediastinal and the phrenicocostal sinuses. In the absence of disease, it is a potential but non existent space. Mechanical irritation of the visceral and parietal pleurae due to the usual respiratory movements is prevented by the lubricant action of a small amount of lymph which is normally present in the pleural cavity. The presence of this fluid is non-detectable by the usual clinical and roentgenographic methods of investigation. Strenous physical exertion is accompanied by a physiologic increase in the amount of lymph. The intrapleural pressure is subatmospheric and in normal quiet respiration varies from −7 cm. of water during inspiration to −2.5 cm. of water during expiration. Of course, in unusual or forced respiratory efforts there is a wider range of intrapleural pressures. The nerve supply of

* Reprinted with changes from *Nontuberculous Diseases of the Chest*. Sponsored by American College of Chest Physicians. Edited by A. L. Bryan. 1954. Courtesy of Charles C Thomas, Publisher, Springfield, Ill.

the visceral pleura is derived from the autonomic pulmonary plexuses and contains both sympathetic and parasympathetic fibers while the parietal pleura is additionally supplied from the intercostal nerves The blood supply of the pleura is unusually rich The visceral pleura is supplied from the pulmonary arteries while the parietal pleura obtains its blood supply from the aortic superior intercostal internal mammary mediastinal esophageal bronchial and phrenic arteries Venous drainage of the pleura corresponds to the arterial blood supply The lymphatics of the pleura are intimately related to the lymph drainage of the lungs and thoracic cage

INFLAMMATORY DISEASES OF THE PLEURA—PATHOLOGY AND PATHOGENESIS

Inflammation of the pleura is known as pleurisy or pleuritis The pneumococcus and the streptococcus are the most frequent etiologic agents Depending on the stage and nature of the disease the inflammatory reaction in the pleura may be fibrinous serofibrinous or frankly purulent The line of demarcation between these three types of pleural reactions is not always very definite Actually they represent different stages of the same basic pathologic process and frequently defy differentiation even with the assistance of all available clinical and laboratory aids

Fibrinous Pleurisy In fibrinous pleurisy the pleural exudate consists of much fibrin inflammatory cellular elements and only a slight increase in the amount of lymph Since an associated clinically detectable effusion is absent in fibrinous pleuritis it is frequently referred to as dry pleurisy The nature of the pleural exudate in fibrinous pleurisy depends on the response of the tissue to the etiologic agent Usually the pneumococcus is responsible for a very thick exudate whereas the streptococcus is associated with comparatively thin pleural reactions Fibrinous pleurisy occurs in practically all cases of lobar pneumonia The pathology of the underlying disease is responsible for this high incidence of pleural involvement In addition to the pneumococcus and streptococcus all the other pathogenic bacteria are capable of producing a fibrinous pleuritis Fibrinous pleurisy may be seen as part of the picture of such clinical entities as rheumatic fever disseminated lupus erythematosus diabetic coma dehydration and uremic states primary atypical pneumonia of undetermined etiology, emphysema bronchiectasis lung abscess tularemia typhoid fever actinomycosis ornithosis Pick's disease and a host of other conditions Occasionally it may be found as a complication of acute or chronic bronchitis It has recently been observed in two cases of pancreatitis In brief any disease which is capable of pulmonary involvement may produce a fibrinous pleuritis The terminal stages of many chronic and debilitating diseases likewise may have an associated fibrinous pleurisy

Fibrinous exudates contain no known proteolytic enzymes Autolysis of the exudate therefore is not responsible for its removal Instead it is replaced from within outward by a layer of young vascular connective tissue. This process is known as organization and occurs only in fibrinous exudates Recovery from the underlying disease process is usually followed by complete organization of the pleural exudate After replacement has been effected the pleura may appear perfectly normal and evidence of past inflammation can be ascertained only by microscopic examination of the membrane The recuperative properties of the pleura are truly amazing Many cases of pleuritis unquestionably are overlooked clinically and even after pathologic study In a significant number of cases however permanent pleural and diaphragmatic adhesions may persist after replacement of the fibrinous exudate These are more frequent in the lower part of the endothorax in contradistinction to tuberculous adhesions which usually are found in the upper part of the thoracic cavity If the disease is progressive the fibrinous exudate may be replaced by a serofibrinous effusion.

Serofibrinous Pleurisy The etiology of serofibrinous exudates is similar to that of fibrinous pleuritis The amount of the effusion varies greatly and is dependent on the extent and nature of the disease process Usually the fluid is grossly clear and serous in nature Depending upon the fibrinogen content and other suspended material it may be light yellow milky or opalescent Its protein content predominantly fibrinogen is 4 per cent or more and its specific gravity is 1 018 or higher Because of its high fibrinogen content it possesses the ability to clot As a rule clotting does not occur until the fluid is withdrawn from the thoracic cavity Occasionally when the fibrino-

FIG 1 Fibrin ball in right hemithorax following resorption of serofibrinous effusion

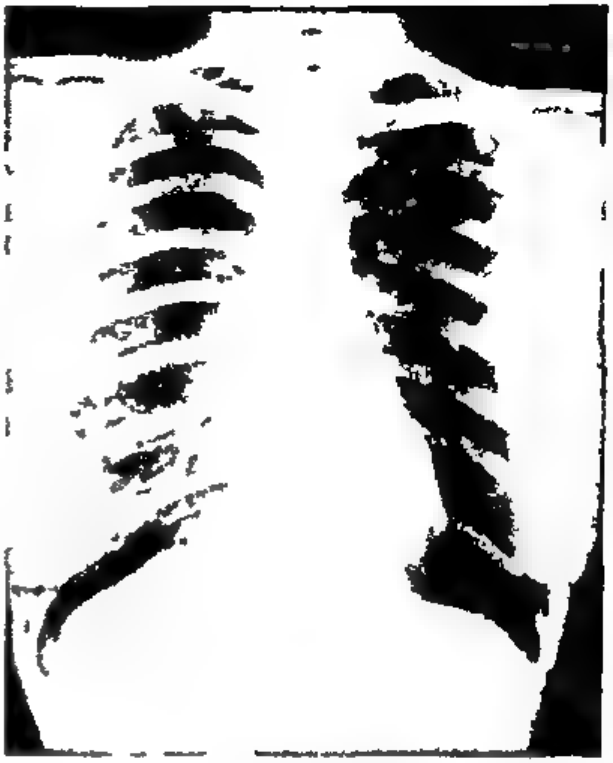

FIG 2 Blunting of right costophrenic angle following undiagnosed serofibrinous effusion

gen content is very high "fibrin balls (Fig 1) may form in the pleural cavity These are smooth, regular, round or oval shaped bodies of varying sizes which persist after the disease has subsided The cellular elements in pyogenic effusions are predominantly polymorphonuclears although other cells such as lymphocytes and eosinophils may be present in varying numbers In non pyogenic exudates the number of lymphocytes are proportionately higher Eosinophil cells are present in unusually large numbers or actually predominate the cellular picture in certain effusions A reasonable explanation for this uncommon characteristic of pleural fluid is not always available Bacteria may be found on direct microscopic examination of an appropriately stained smear of the fluid but more frequently identification depends upon indicated cultural procedures A substantial number of pyogenic effusions may yield sterile cultures consistently If a non pyogenic basis for the effusion is also lacking it is customary to attribute these so-called "idiopathic" effusions to a tuberculous origin Since the fibrinogen content of serofibrinous exudates varies so widely in the same and different diseases it has become the practice to classify the effusion as serous or serofibrinous Clinically however the terms are used interchangeably The differentiation has no real merit and is usually quite arbitrary

In this presentation all exudates which are not frankly purulent are considered serofibrinous The name serofibrinous has pathologic as well as clinical significance Further subdivision tends to confuse the issue and is actually without appreciable benefit Broken down cellular elements and proteins may be so suspended in a serofibrinous effusion as to impart a milky appearance to the exudate From gross inspection this type of exudate may be erroneously labelled as chylous but microscopic examination proper staining and chemical analysis of the fluid will easily establish its true nature Such exudates are chyloid and not true chylous effusions Effusions of long duration may have a brownish discoloration probably due to the presence of cholesterol Very few cases of fibrinous pleurisy whether treated or untreated, progress beyond the stage of serofibrinous exudation After the serofibrinous effusion has subsided the pleura usually returns to a gross normal appearance

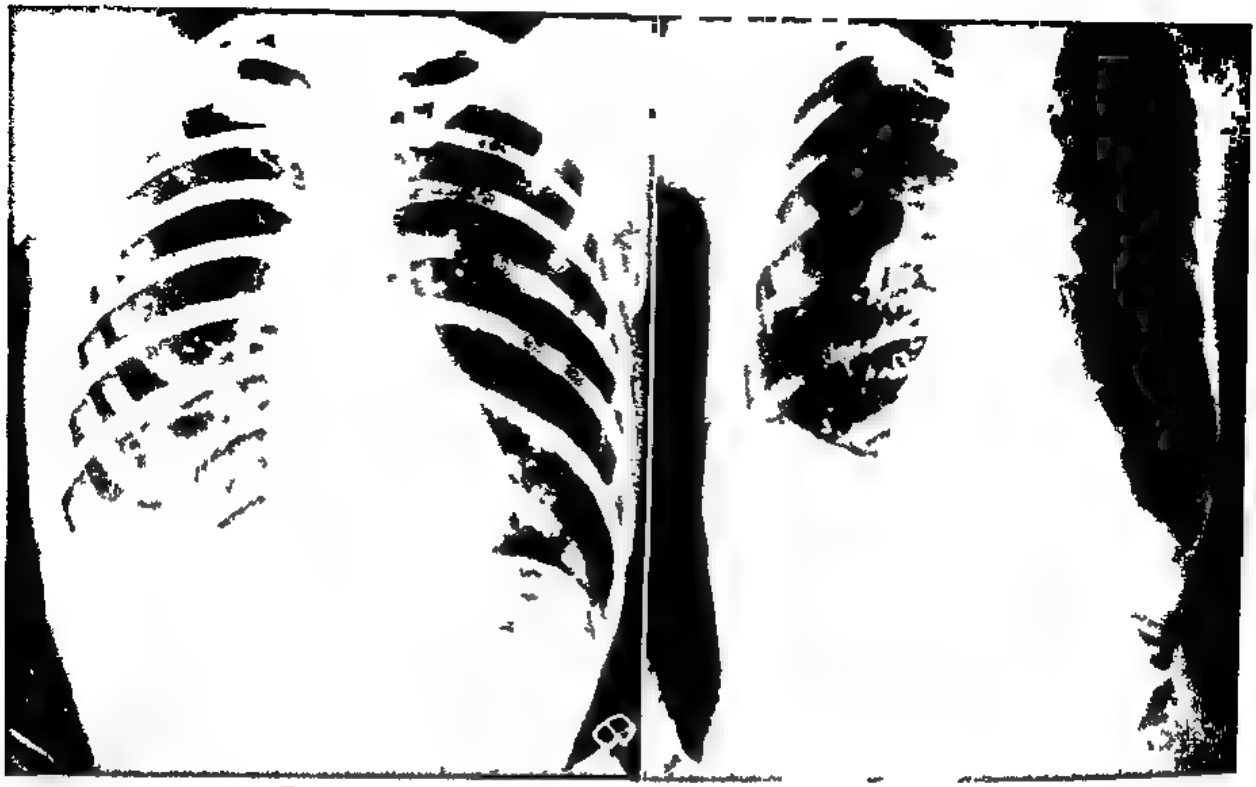

FIG 3 FIG 4

FIG 3 Tenting of right hem diaphragm following pneumonia with effus on

FIG 4 B lateral elevation and flatten ng of diaphragms following pneumonia with effus on

necropsy Obliteration of the costophrenic tten and fre quently observed in x ray films of the chest

rather common occurrence following pyothorax calcification of the pleura due to serofibrinous pleurisy probably never occurs

Empyema A frankly purulent pleural exudate is known as empyema or pyothorax It is only rarely primary and as a rule is generally secondary to a suppurative disease of the lungs or other neighboring thoracic and upper abdominal organs Infections of the pleura without involvement of the underlying pulmonary tissue if they ever occur, must be blood borne from a distant focus Serofibrinous exudates only infrequently become frankly purulent Conversion of a serofibrinous pleurisy to empyema however may follow diagnostic or therapeutic thoracentesis unless rigid sterile technic is observed Another important exception is streptococcal empyema which complicates epidemic influenza or measles The pleural reaction in this instance is at first serofibrinous and is only slowly converted to a thick purulent exudate

The microscopic characteristics of empyema fluid are similar to those of a pyogenic serofibrinous exudate with the exception that the former is more purulent It is much easier however to differentiate the two on paper than in actual practice All the elements of empyema fluid may be found in pyogenic serofibrinous effusions The bacterial content, number of pus cells and the amount of cellular debris are all proportionately higher in empyema than in serofibrinous pleural reactions The difference is one of degree rather than one based on fixed standards Therefore the line of demarcation between the two is necessarily flexible Until better standards for differentiation are developed we must be content with interpretations based on clinical judgment past experience and relatively arbitrary standards In view of the foregoing remarks any attempt to subdivide empyemas into seropurulent and purulent types must be viewed only with academic interest

Although any pathogenic micro-organism is capable of producing empyema the pneumo-

A B

FIG 5 A multilocular empyema complicating pneumonia of the left lower lobe B lateral view same case

occus, streptococcus and staphylococcus are the most frequent offenders Pneumococcal empyemas may follow epidemic influenza and measles but more frequently have their origin in lobar pneumonia The empyema is usually metapneumonic and occurs in the convalescent period A thick creamy, yellow green exudate is characteristic of this complication Streptococcal empyema which complicates strepto coccal p

known as synpneumonic empyema The bacteriology of empyemas produced by septic infarction depends upon the nature of the embolus Commonly pyothorax may be the result of mixed infections This is generally the case in putrid empyemas which frequently complicate bronchiectasis and lung abscess Although anaerobic streptococci predominate in these instances spirochetes anaerobic bacilli fusiform bacilli and other microorganisms are found in myriads Anaerobic bacteria are responsible for the foul and offensive odor of putrid empyemas The presence of gas in the pleural cavity is common in this variety of pyothorax Bronchopleural fistula also gives rise to a rapidly developing mixed empyema The fluid re forms almost as quickly as it can be removed Subdiaphragmatic and hepatic abscess due to the colon bacteria and endamoeba histolytica respectively infrequently are responsible for empyema Colon bacilli cause a thick foul smelling exudate while anchovy sauce color may characterize the amebic infestation

Unlike serofibrinous exudates which have a tendency to be generalized and fill all recesses of the pleural cavity empyemas may be more localized and are frequently limited by thick adhesions This characteristic gives rise to the development of loculated empyema cavities which may or may not communicate with adjoining pockets (Figs 5A and B) When numerous loculations are present the fluid may be frankly purulent in some and serofibrinous in others Empyemas are commonly found in the lower thoracic cavity but interlobar infrapulmonic (Fig 6) apical or mediastinal locations are not unusual Ordinarily the mediastinum is flexible and mobile The continued presence of empyema fluid interferes with its flexibility and mobility Later it may become a rigid and fixed structure This is a

FIG 6

FIG 7

FIG 6 Infrapulmonic pleural effusion

FIG 7 Calcification of pleura result of empyema following pneumonia in childhood Note flattening and elevation of left hemidiaphragm

very valuable asset in the surgical management of empyemas In streptococcal empyemas fixation of the mediastinum is delayed and *surgical drainage of necessity must be deferred* pending the development of this complication The pressure of the empyema fluid causes compression and atelectasis of the underlying lung proportionate to the amount of pleural effusion Naturally *small encapsulated empyemas do not cause the same degree of compression* The compressed lung is surrounded by the purulent exudate and, if the condition remains untreated is soon encased in a thick fibrous capsule This latter development portends serious impairment of pulmonary function *On occasion the fibrous tissue covering the* lung and pleura may reach great thickness and be as tough as shoe leather Necrosis and destruction of pulmonary tissue may result from the pressure of empyema fluid If drainage is not established for the empyema fluid it seeks its own avenue of escape from its pleural confines This may be accomplished by the supervention of a bronchopleural fistula or by empyema necessitatis In the latter instance the fluid burrows through the tissues of the thoracic wall and escapes through a perforation effected by its own pressure and tissue-destroying properties This opening is usually in the vicinity of the costochondral junction of the fifth rib Nature frequently provides a 'cure' in this fashion to compensate for man's ignorance and neglect If the patient survives the empyema some morbid evidence of its effects *may always be detected This mute testimony* may be in the form of a thickened pleura thick pleural adhesions pachypleuritis draining sinus calcification (Fig 7) of the pleura or contraction of the hemithorax on the involved side In the latter event, the trachea and *mediastinal structures are pulled to the affected* side the interspaces are narrowed the diaphragm is elevated and the lung is in a varying degree of collapse It may thereafter be the site of chronic infection such as bronchiectasis Associated pericarditis and myocarditis are

empyemas of

to

ral

nal

npyemas may become sterile and gradually sorb but as a rule they rarely terminate pontaneously Generalized amyloidosis is a ossible complication

SYMPTOMS AND SIGNS OF PLEURISY

Since pleurisy may complicate an endless umber of clinical entities we must be alert to ecognize its development without delay A igh index of suspicion and familiarity with its inical manifestations will result in more rompt and correct diagnoses The symptoms nd signs of pleurisy fall into two general ategories those associated with fibrinous leuritis and those found in association with leural effusions Fibrinous pleurisy is much the nore painful of the two At times the pain of brinous pleurisy reaches excruciating proportions and may actually be beyond the ndurance of even those patients with high pain thresholds Fortunately this symptom is elf limited Pleuritic pain originates in the parietal pleura since the visceral pleura and ung are devoid of pain fibers The exact nechanism of pleural pain is still a matter for peculation In some quarters it is believed that pleural pain results only from tension on the parietal pleura As an example they cite the pleural pain associated with pneumothorax Another school of thought attributes pleural pain to the movement of the two inflamed pleural surfaces on each other There is abundant evidence in support of this contention and it is by far the more logical explanation of pleural pain For example the pleuritic pain of lobar pneumonia may be allayed completely by the induction of a small pneumothorax Likewise the development of pleural effusion heralds prompt relief in painful pleurisy

The intensity of a friction rub does not necessarily parallel the severity of the pain In the absence of a demonstrable friction rub however pleural pain is observed only rarely Pleural pain is ordinarily well localized The nerve supply of the lower thorax and diaphragm is such however, that pleuritic pain may commonly be referred to distant sites In central diaphragmatic pleurisy, the pain is transmitted regularly to the neck and shoulders Since the last six intercostal nerves supply the lateral portions of the diaphragm and the lower thorax, painful stimuli from these areas may be referred to the abdomen and back A quick and reliable diagnostic aid is the dramatic relief of pain which can be accomplished with manual pressure on the thoracic wall overlying the inflamed pleura Unless one is keenly aware of these possibilities attention may be focused erroneously on the wrong part of the anatomy Ignorance of these facts unfortunately has resulted in unwarranted abdominal surgery Although all abdominal viscera may be suspected unjustly in undiagnosed pleurisy the appendix and gallbladder most frequently are the erroneous objectives of therapeutic surgery

Both dry and wet pleurisy may be associated with varying degrees of dyspnea In fibrinous pleurisy dyspnea is the direct result of voluntary restriction in the range of normal respiratory excursions This compensatory measure is designed to allay the severity of the pleural pain which accompanies ordinary respiratory efforts Shallow, rapid abdominal breathing is the result Movement coughing sneezing or even talking aggravates the pain The dyspnea associated with pleural effusions has a mechanical basis It is simply the result of pulmonary compression with a consequent decrease in vital capacity The amount of fluid required to produce the symptoms of dyspnea varies in the individual patient and with the rapidity of the fluid formation Some patients tolerate of compensatory physiologic reactions so that patients can eventually tolerate large pleural accumulations Additional dyspnea may result from pressure on the contralateral lung and displacement of the mediastinum Cyanosis may be associated with severe dyspnea The detection of a pulsus paradoxus supplies further evidence of cardiorespiratory embarrassment

Useless shallow cough may be part of the picture of both dry and wet pleurisy Severe paroxysmal cough associated with postural changes and productive of large quantities of frankly purulent sputum when detected clinically is strongly suggestive of bronchial communication with a pyothorax The febrile reaction varies greatly depending on the etiology and severity of the pleuritis It may be normal or may reach as high as 103° to 104°F In pyogenic effusions it may be continuous remittent or intermittent More frequently it is intermittent Chills high fever and marked toxicity may dominate the clinical picture of

pyothorax Close observation of the temperature curve in the convalescent stage of lobar pneumonia will frequently suggest the development of empyema There is a gradually increasing degree of daily fever after the temperature has become normal by crisis lysis or therapy Patients suffering from fibrinous pleurisy or serofibrinous pleurisy may not appear ill Many patients with pleurisy may be very sick Patients with empyema usually are very ill In chronic cases they are weak and debilitated The toxicity of the infection may

widely depending on the primary disease process responsible for its development For example the over all signs and symptoms of pleuritis associated with rheumatic fever may differ greatly from those due to tularemia or bronchiectasis

PHYSICAL SIGNS

the thorax
rious types
influenced

profoundly by the underlying disease process Inflammatory exudates may be bilateral but are generally unilateral

Fibrinous Pleurisy (Dry Pleurisy) On inspection the patient may be dyspneic and is frequently found lying on the affected side Respiratory movement of the involved half of the thorax is usually restricted while the normal side is fuller and more active Breathing may be largely abdominal Cough if present is weak and non productive On palpation the findings of inspection may be verified and additionally a friction rub may be detected The percussion note is usually unchanged on the involved side but a compensatory increase in resonance may be elicited over the contralateral lung If the fibrinous exudate is pronounced the percussion note may be dulled The diaphragm may be found resting at a higher level Auscultation reveals a friction rub Since friction rubs are inconstant and often transient frequent auscultation is indicated If the pleuritis affects the mediastinal pleura and is also in relation to the pericardium the friction rub may be synchronous with the heart beat but is modified by respiration This is known as a pleuropericardial friction rub The breath sounds on the affected side are usually diminished while on the contralateral uninvolved side they may be intensified

Pleural Effusions Serofibrinous Empyema The patient may or may not be dyspneic In the author's experience dyspnea has been a more consistent finding of fibrinous pleuritis In the event that dyspnea is present the patient usually rests on the side of the effusion and prefers to have the head elevated The interspaces on the side of the effusion usually bulge and little if any respiratory movement can be detected On the contralateral side the interspaces are widened and the respiratory activity is intensified On palpation the observed movements of the thorax can be verified Tactile fremitus is decreased over the fluid but increases in intensity as its superior border is approached Immediately above the fluid level fremitus is increased Rarely a friction rub may be felt In left sided effusions the apex beat of the heart cannot be palpated The trachea may be deviated to the contralateral side The percussion note is dulled over the fluid but the outlined area of dullness varies with changing positions Greater degrees of *shifting may be detected with less viscid effusions* than with thicker exudates An additional area of dullness may be detected at the base of the normal lung on the back This is known as Grocco's triangle Immediately above the fluid one elicits Skodaic resonance

For academic purposes only one may outline Ellis's line If the effusion is on the left Traube's semilunar space may be obscured On the right effusions interfere with demarcation of the liver dullness by percussion When effusions involve the left hemithorax the left border of the heart cannot be percussed and the right border may be found considerably to the right of the sternum On auscultation the breath sounds and vocal fremitus are diminished or absent over the fluid Rarely a consolidated or atelectatic lung beneath the effusion transmits tubular breath sounds and vocal fremitus Immediately above the fluid level the breath sounds are harsh and tubular and vocal fremitus is characterized by egophony In left sided effusions the heart may not be heard Occasionally one may hear a friction rub near the border of the fluid superiorly The breath and voice sounds are increased over the contralateral lung

FIG 8

FIG 9

FIG 8 Massive serofibrinous effusion Note shifting of heart shadow to contralateral side

FIG 9 Moderate sized serofibrinous effusion

It is impossible to ascertain the nature of pleural fluid except by thoracentesis The physical findings of pleural effusion as detailed above apply to rather massive accumulations (Fig 8) Naturally the physical findings will vary as does the amount of pleural fluid The findings of encapsulated and interlobar effusions depend on the [illegible]

[illegible]

note and decreased vocal fremitus and breath sounds The physical signs of a thickened pleura are very similar to those of pleural effusion

DIAGNOSIS

The clinical detection of dry or wet pleurisy does not ordinarily offer any serious diagnostic difficulty After a satisfactory history is obtained and a careful complete physical examination is performed the diagnosis is usually obvious Small pleural effusions however are generally evasive on physical examination and as a result they are overlooked frequently by the most astute clinicians Occasionally small collections of pleural fluid may yield positive physical findings long before roentgen ray evidence is available Even with the use of special technics and positions at least 300 to 400 cc of fluid in the pleural cavity is necessary to produce the changes on which a positive roentgen ray diagnosis can be based The diagnosis of pleurisy nevertheless is not really as difficult as the determination of its etiology

It is estimated conservatively that in excess of 80 per cent of all pleurisies are tuberculous in origin This observation acquires added significance when one considers the fact that the majority of idiopathic pleurisies also have a tuberculous etiology In view of this fact the correct etiologic diagnosis of non tuberculous pyogenic and sterile pleurisies should be the rule rather than the exception Success along this line may be achieved regularly by the intelligent utilization of available and indicated diagnostic laboratory aids As previously stated, the primary origin of non tuberculous pleurisies may be discounted Therefore accurate specific knowledge of the underlying thoracic abdominal or other distant and systemic disease processes is essential If this information is

available the etiologic diagnosis of complicating pleurisies presents no special problem

Fibrinous pleurisy may be confused with such clinical entities as incipient herpes zoster of the thoracic wall or intercostal neuralgia The development of typical physical findings however soon dispels the confusion Here again knowledge of the underlying disease process facilitates early accurate diagnosis Roentgen ray examination of the chest in fibrinous pleurisy is generally of little or no assistance unless blunting of the costophrenic angle is detected

As regards pleurisy with effusion roentgen ray examination fluoroscopy and diagnostic thoracentesis afford the most useful and dependable diagnostic aids Typically in the usual erect postero anterior film of the chest pleural fluid casts a shadow which is similar in density to that of the heart diaphragm and subdiaphragmatic organs Generalized inflammatory pleural effusions tend to be unilateral and occupy the most dependent portions of the pleural cavity They cast a dense shadow which as a rule reaches its greatest height in the lateral part of the thorax (Fig 9) Loculated or encapsulated effusions may occupy any part of the pleural cavity or may be confined to the interlobar fissures Pleural effusions however may assume bizarre contours and cast very unusual roentgen ray shadows To derive the maximum benefits of available roentgen ographic aid the patient should if indicated be examined not only in the erect posteroanterior position but films should also be obtained in the erect anteroposterior lateral oblique supine lordotic and lateral decubitus positions The latter position is almost indispensable in the detection of small pleural effusions Examination of the chest in these various positions will reveal the inconsistent and mobile nature of the dense shadow cast by fluid The differentiation of pleural effusion from other endothoracic as well as upper abdominal diseases may be based on these characteristics The roentgen ray is indispensable in the diagnosis of pleural fluid Relatively large accumulations of pleural fluid frequently yield essentially normal physical findings and may be suspected and diagnosed only by proper roentgen ray examination

Fluoroscopic examination of the chest is an indispensable adjunct to roentgen ray studies This procedure provides a means for direct visualization of the altered endothoracic mechanics Limitation of diaphragmatic and other respiratory movements can be observed on the affected side Observation of the compensatory respiratory effort of the contralateral side is also invaluable Additionally after the introduction of a contrast medium such as iodized oil appropriate fluoroscopic and roentgenographic studies will reveal accurately the boundaries of the pleural fluid When a bronchopleural fistula is suspected the introduction of iodized oil into the bronchial tree or pleural cavity prior to roentgen ray examination and fluoroscopy will establish the diagnosis In suspected empyema necessitatis the introduction of iodized oil into a draining sinus may confirm pleural communication Draining sinuses of pleuropulmonary actinomycosis can be outlined accurately with this relatively harmless technic

The accidental or intentional presence of air in the pleural cavity will provide a straight linear demarcation of the upper limit of the effusion Diagnostic pneumothorax is an effective means of differentiating between pleural, pulmonary and other endothoracic diseases In order to avoid future complications for the patient and interference with therapy however it is advisable to produce only a very minimal degree of pneumothorax Diagnostic pneumoperitoneum is likewise valuable in differentiating between pleural fluid and subdiaphragmatic disease Herniation of the stomach or other portions of the gastrointestinal tract may be very confusing at times The use of diagnostic pneumothorax and pneumoperitoneum may help the solution to this problem A barium meal or enema will yield the final answer Aerograms of the stomach or colon are likewise very valuable diagnostic aids

Unequivocal proof of the existence of a pleural effusion depends on aspiration of fluid by thoracentesis Unless specifically indicated, air should not be introduced into the pleural cavity during or following diagnostic aspiration Microscopic examination of the fluid may point to the etiologic diagnosis It is important to note the color, viscosity and odor A thin serosanguineous fluid for example may suggest a pulmonary infarct while creamy yellow green fluid is typical of pneumococcal pyothorax Foul smelling exudates suggest the presence of anaerobic bacteria In medate

determination of the specific gravity will differentiate quickly between a transudate and an exudate In doubtful instances the protein content of the fluid may be determined The protein level of transudates is generally less than 2 5 per cent Bacteriologic examinations must include a satisfactory stain of a direct smear of the fluid Cultures and other procedures may be indicated Fluid which has developed synpneumonically or metapneumonically should be typed for specific pneumococci If one suspects malignancy part of the specimen should be examined histopathologically for the possible presence of neoplastic cells With proper study the determination of the specific etiologic diagnosis in pyogenic effusions is ordinarily accomplished by the well trained physician with relative ease Before withdrawing the aspirating needle 10 cc of 1 per cent methylene blue or some other suitable dye may be injected if a bronchopleural fistula is suspected In the presence of this complication the sputum will acquire a bluish discoloration in twelve to twenty four hours or sooner depending on the rate of pleural fluid formation and its viscosity When facilities for gas analysis are available the existence of a bronchopleural fistula may be suggested by a determination of the oxygen and carbon dioxide content of specimens obtained from the pleural cavity This is a tedious procedure and is mentioned in passing only for the sake of completeness

Although proper examination of pyogenic pleural effusions usually supplies the etiologic diagnosis in a substantial number of instances the assistance of additional diagnostic clinical and laboratory aids must be sought For example a positive blood culture will frequently supply the answer Even the presence of pathogenic parasites in the stool may be significant and related to pleural disease This little help in the diagnosis of inflammatory effusions There may be a high leukocytosis with an absolute increase in polymorphonuclear cells This is especially true in pneumococcal pleurisy On the other hand the white blood count may present no significant abnormality Eosinophils may predominate in the blood and pleural fluid in the case of Loeffler s syndrome Anemia usually complicates empyemas Proper bacteriologic survey of the sputum with indicated stains and cultures will demonstrate the etiologic agent responsible for the underlying pulmonary disease Gross examination of the sputum may reveal the true primary clinical picture This is the case in bronchiectasis pulmonary abscess and to a lesser degree in bronchopleural fistula

Skin tests may be used to prove a diagnosis of blastomycosis coccidioidomycosis actinomycosis histoplasmosis and other fungus diseases Casoni s intradermal test is specific for echinococcal disease Precipitin and complement fixation tests are of real value in the diagnosis of virus and fungus disease When significant positive results are obtained they may be considered diagnostic A rising or falling titer is of prognostic as well as diagnostic import in blastomycosis and coccidioidomycosis Specific immunologic response to the causative organism producing pleural fluid has also been demonstrated recently

Bronchoscopy may provide excellent assistance in ascertaining the etiologic diagnosis of pleural fluid This is especially true in the case of pulmonary neoplasms Biopsy of local and distant neoplastic lesions should be performed Careful observation of a solitary nodule a prominent lymph node or an ulcerating lesion will frequently supply the answer to a difficult diagnostic problem If all other diagnostic procedures have failed to establish a satisfactory diagnosis one may resort to thoracoscopy and finally an exploratory thoracotomy

Sterile inflammatory exudates are usually a local manifestation of serious systemic diseases and may be bilateral The diagnosis in these instances is dependent on an accurate assessment of the general clinical findings

In spite of the intelligent use of all available diagnostic aids in an occasional case of nontuberculous pleurisy the etiology cannot be determined accurately

TREATMENT

The treatment of pleurisy is both symptomatic and specific Successful management depends greatly on the course of the primary disease which it may complicate Because fibrinous pleuritis is generally very painful early attention should be directed toward the alleviation of this distressing symptom The judicious use of narcotics not only controls the pain but also dispels the patient s appre-

available the etiologic diagnosis of complicating pleurisies presents no special problem

Fibrinous pleurisy may be confused with such clinical entities as incipient herpes zoster of the thoracic wall or intercostal neuralgia The development of typical physical findings however, soon dispels the confusion Here, again knowledge of the underlying disease process facilitates early accurate diagnosis Roentgen ray examination of the chest in fibrinous pleurisy is generally of little or no assistance unless blunting of the costophrenic angle is detected

As regards pleurisy with effusion roentgen ray examination fluoroscopy and diagnostic thoracentesis afford the most useful and dependable diagnostic aids Typically, in the usual erect postero anterior film of the chest, pleural fluid casts a shadow which is similar in density to that of the heart diaphragm and subdiaphragmatic organs Generalized inflammatory pleural effusions tend to be unilateral and occupy the most dependent portions of the pleural cavity They cast a dense shadow which as a rule reaches its greatest height in the lateral part of the thorax (Fig 9) Loculated or encapsulated effusions may occupy any part of the pleural cavity or may be confined to the interlobar fissures Pleural effusions however, may assume bizarre contours and cast very unusual roentgen ray shadows To derive the maximum benefits of available roentgenographic aid the patient should if indicated, be examined not only in the erect postero-anterior position but films should also be obtained in the erect anteroposterior lateral oblique supine lordotic and lateral decubitus positions The latter position is almost indispensable in the detection of small pleural effusions Examination of the chest in these various positions will reveal the inconsistent and mobile nature of the dense shadow cast by fluid The differentiation of pleural effusion from other endothoracic as well as upper abdominal diseases may be based on these characteristics The roentgen ray is indispensable in the diagnosis of pleural fluid Relatively large accumulations of pleural fluid frequently yield essentially normal physical findings and may be suspected and diagnosed only by proper roentgen ray examination

Fluoroscopic examination of the chest is an indispensable adjunct to roentgen ray studies This procedure provides a means for direct visualization of the altered endothoracic mechanics Limitation of diaphragmatic and other respiratory movements can be observed on the affected side Observation of the compensatory respiratory effort of the contralateral side is also invaluable Additionally after the introduction of a contrast medium such as iodized oil appropriate fluoroscopic and roentgenographic studies will reveal accurately the boundaries of the pleural fluid When a bronchopleural fistula is suspected the introduction of iodized oil into the bronchial tree or pleural cavity prior to roentgen ray examination and fluoroscopy will establish the diagnosis In suspected empyema necessitatis the introduction of iodized oil into a draining sinus may confirm pleural communication Draining sinuses of pleuropulmonary actinomycosis can be outlined accurately with this relatively harmless technic

The accidental or intentional presence of air in the pleural cavity will provide a straight linear demarcation of the upper limit of the effusion Diagnostic pneumothorax is an effective means of differentiating between pleural pulmonary and other endothoracic diseases In order to avoid future complications for the patient and interference with therapy however, it is advisable to produce only a very minimal degree of pneumothorax Diagnostic pneumoperitoneum is likewise valuable in differentiating between pleural fluid and subdiaphragmatic disease Herniation of the stomach or other portions of the gastrointestinal tract may be very confusing at times The use of diagnostic pneumothorax and pneumoperitoneum may help the solution to this problem A barium meal or enema will yield the final answer Aerograms of the stomach or colon are likewise very valuable diagnostic aids

Unequivocal proof of the existence of a pleural effusion depends on aspiration of fluid by thoracentesis Unless specifically indicated air should not be introduced into the pleural cavity during or following diagnostic aspiration Macroscopic examination of the fluid may to the etiologic diagnosis It is in note the color, viscosity and serosanguineous fluid for e gest a pulmonary infarct green fluid is typical thorax Foul smelling presence of anaer

determination of the specific gravity will differentiate quickly between a transudate and an exudate In doubtful instances the protein content of the fluid may be determined The protein level of transudates is generally less than 2 5 per cent Bacteriologic examinations must include a satisfactory stain of a direct smear of the fluid Cultures and other procedures may be indicated Fluid which has developed synpneumonically or metapneumonically should be typed for specific pneumococci If one suspects malignancy part of the specimen should be examined histopathologically for the possible presence of neoplastic cells With proper study the determination of the specific etiologic diagnosis in pyogenic effusions is ordinarily accomplished by the well trained physician with relative ease Before withdrawing the aspirating needle, 10 cc of 1 per cent methylene blue or some other suitable dye may be injected if a bronchopleural fistula is suspected In the presence of this complication the sputum will acquire a bluish discoloration in twelve to twenty four hours or sooner depending on the rate of pleural fluid formation and its viscosity When facilities for gas analysis are available the existence of a bronchopleural fistula may be suggested by a determination of the oxygen and carbon dioxide content of specimens obtained from the pleural cavity This is a tedious procedure and is mentioned in passing only for the sake of completeness

Although proper examination of pyogenic pleural effusions usually supplies the etiologic diagnosis in a substantial number of instances the assistance of additional diagnostic clinical and laboratory aids must be sought For example a positive blood culture will frequently supply the answer Even the presence of pathogenic parasites in the stool may be significant and related to pleural disease This especially true in Loeffler s syndrome and in ...ic disease involving the pleura As a ... hematologic and urinary studies offer ... help in the diagnosis of inflammatory ...ions There may be a high leukocytosis with an absolute increase in polymorphonuclear cells This is especially true in pneumococcal pleurisy On the other hand the white blood count may present no significant abnormality Eosinophils may predominate in the blood and pleural fluid in the case of Loeffler s syndrome Anemia usually complicates empyema Proper bacteriologic survey of the sputum with indicated stains and cultures will demonstrate the etiologic agent responsible for the underlying pulmonary disease Gross examination of the sputum may reveal the true primary clinical picture This is the case in bronchiectasis pulmonary abscess and to a lesser degree in bronchopleural fistula

Skin tests may be used to prove a diagnosis of blastomycosis coccidioidomycosis actinomycosis histoplasmosis and other fungus diseases Casoni s intradermal test is specific for echinococcal disease Precipitin and complement fixation tests are of real value in the diagnosis of virus and fungus disease When significant positive results are obtained they may be considered diagnostic A rising or falling titer is of prognostic as well as diagnostic import in blastomycosis and coccidioidomycosis Specific immunologic response to the causative organism producing pleural fluid has also been demonstrated recently

Bronchoscopy may provide excellent assistance in ascertaining the etiologic diagnosis of pleural fluid This is especially true in the case of pulmonary neoplasms Biopsy of local and distant neoplastic lesions should be performed Careful observation of a solitary nodule a prominent lymph node or an ulcerating lesion will frequently supply the answer to a difficult diagnostic problem If all other diagnostic procedures have failed to establish a satisfactory diagnosis one may resort to thoracoscopy and, finally an exploratory thoracotomy

Sterile inflammatory exudates are usually a local manifestation of serious systemic diseases and may be bilateral The diagnosis in these instances is dependent on an accurate assessment of the general clinical findings

In spite of the intelligent use of all available diagnostic aids in an occasional case of non tuberculous pleurisy the etiology cannot be determined accurately

TREATMENT

The treatment of pleurisy is both symptomatic and specific Successful management depends greatly on the course of the primary disease which it may complicate Because fibrinous pleuritis is generally very painful early attention should be directed toward the alleviation of this distressing symptom The judicious use of narcotics not only controls the pain but also dispels the patient s appre-

available the etiologic diagnosis of complicating pleurisies presents no special problem

Fibrinous pleurisy may be confused with such clinical entities as incipient herpes zoster of the thoracic wall or intercostal neuralgia The development of typical physical findings however, soon dispels the confusion Here again knowledge of the underlying disease process facilitates early accurate diagnosis Roentgen ray examination of the chest in fibrinous pleurisy is generally of little or no assistance unless blunting of the costophrenic angle is detected

As regards pleurisy with effusion roentgen ray examination fluoroscopy and diagnostic thoracentesis afford the most useful and dependable diagnostic aids Typically in the usual erect postero anterior film of the chest pleural fluid casts a shadow which is similar in density to that of the heart diaphragm and subdiaphragmatic organs Generalized inflammatory pleural effusions tend to be unilateral and occupy the most dependent portions of the pleural cavity They cast a dense shadow which as a rule reaches its greatest height in the lateral part of the thorax (Fig 9) Loculated or encapsulated effusions may occupy any part of the pleural cavity or may be confined to the interlobar fissures Pleural effusions however may assume bizarre contours and cast very unusual roentgen ray shadows To derive the maximum benefits of available roentgenographic aid the patient should if indicated be examined not only in the erect postero anterior position but films should also be obtained in the erect anteroposterior lateral oblique supine lordotic and lateral decubitus positions The latter position is almost indispensable in the detection of small pleural effusions Examination of the chest in these various positions will reveal the inconsistent and mobile nature of the dense shadow cast by fluid The differentiation of pleural effusion from other endothoracic as well as upper abdominal diseases may be based on these characteristics The roentgen ray is indispensable in the diagnosis of pleural fluid Relatively large accumulations of pleural fluid frequently yield essentially normal physical findings and may be suspected and diagnosed only by proper roentgen ray examination visualization of the altered endothoracic mechanics Limitation of diaphragmatic and other respiratory movements can be observed on the affected side Observation of the compensatory respiratory effort of the contralateral side is also invaluable Additionally after the introduction of a contrast medium such as iodized oil appropriate fluoroscopic and roentgenographic studies will reveal accurately the boundaries of the pleural fluid When a bronchopleural fistula is suspected the introduction of iodized oil into the bronchial tree or pleural cavity prior to roentgen ray examination and fluoroscopy will establish the diagnosis In suspected empyema necessitatis the intro-

be outlined accurately with t
harmless technic

The accidental or intentional presence of air in the pleural cavity will provide a straight linear demarcation of the upper limit of the effusion Diagnostic pneumothorax is an effective means of differentiating between pleural pulmonary and other endothoracic diseases. In order to avoid future complications for the patient and interference with therapy however it is advisable to produce only a very minimal degree of pneumothorax Diagnostic pneumoperitoneum is likewise valuable in differentiating between pleural fluid and subdiaphragmatic disease Herniation of the stomach or other portions of the gastrointestinal tract may be very confusing at times The use of diagnostic pneumothorax and pneumoperitoneum may help the solution to this problem A barium meal or enema will yield the final answer Aerograms of the stomach or colon are likewise very valuable diagnostic aids

Unequivocal proof of the existence of a pleural effusion depends on aspiration of fluid by thoracentesis Unless specifically indicated, air should not be introduced into the pleural cavity during or following diagnostic aspiration Macroscopic examination of the fluid may point to the etiologic diagnosis It is important to note the color, viscosity and odor A thin, serosanguineous fluid for example may suggest a pulmonary infarct while creamy yellow green fluid is typical of pneumococcal empyema Foul smelling exudates suggest the presence of anaerobic bacteria Immediate

determination of the specific gravity will differentiate quickly between a transudate and an exudate In doubtful instances the protein content of the fluid may be determined The protein level of transudates is generally less than 2 5 per cent Bacteriologic examinations must include a satisfactory stain of a direct smear of the fluid Cultures and other procedures may be indicated Fluid which has developed spontaneously or metapneumonically should be typed for specific pneumococci If one suspects malignancy part of the specimen should be examined histopathologically for the possible presence of neoplastic cells With proper study the determination of the specific etiologic diagnosis in pyogenic effusions is ordinarily accomplished by the well trained physician with relative ease Before withdrawing the aspirating needle 10 cc of 2 per cent methylene blue or some other suitable dye may be injected if a bronchopleural fistula is suspected In the presence of this complication the sputum will require a bluish discoloration in twelve to twenty four hours or sooner, depending on the rate of pleural fluid formation and its viscosity When facilities for gas analysis are available the existence of a bronchopleural fistula may be suggested by a determination of the oxygen and carbon dioxide content of specimens obtained from the pleural cavity This is a tedious procedure and is mentioned in passing only for the sake of completeness

Although proper examination of pyogenic pleural effusions usually supplies the etiologic diagnosis in a substantial number of instances the assistance of additional diagnostic clinical and laboratory aids must be sought For example a positive blood culture will frequently supply the answer Even the presence of pathogenic parasites in the stool may be significant and related to pleural disease This is especially true in Loeffler s syndrome and amebic disease involving the pleura As a rule hematologic and urinary studies offer little help in the diagnosis of inflammatory effusions There may be a high leukocytosis with an absolute increase in polymorphonuclear cells This is especially true in pneumococcal pleurisy On the other hand the white blood count may present no significant abnormality Eosinophilia may predominate in the blood and pleural fluid in the case of Loeffler s syndrome Anemia usually complicates empyemas Proper bacteriologic survey of the sputum with and without stains and cultures will demonstrate the etiologic agent responsible for the underlying pulmonary disease Gross examination of the sputum may reveal the true primary clinical picture This is the case in bronchiectasis pulmonary abscess and to a lesser degree in bronchopleural fistula

Skin tests may be used to prove a diagnosis of histoplasmosis coccidioidomycosis actinomycosis histoplasmosis and other fungus diseases Casoni s intradermal test is specific for echinococcal disease Precipitin and complement fixation tests are of real value in the diagnosis of virus and fungus disease When significant positive results are obtained they may be considered diagnostic A rising or falling titer is of prognostic as well as diagnostic import in blastomycosis and coccidioidomycosis Specific immunologic response to the causative organism producing pleural fluid has also been demonstrated recently

Bronchoscopy may provide excellent assistance in ascertaining the etiologic diagnosis of pleural fluid This is especially true in the case of pulmonary neoplasms Biopsy of local and distant neoplastic lesions should be performed Careful observation of a solitary nodule a prominent hilar node or an ulcerating lesion will frequently supply the answer to a difficult diagnostic problem If all other diagnostic procedures have failed to establish a satisfactory diagnosis one may resort to thoracoscopy and finally an exploratory thoracotomy

Sterile inflammatory exudates are usually a local manifestation of serious systemic diseases and may be bilateral The diagnosis in these instances is dependent on an accurate assessment of the general clinical findings

In spite of the intelligent use of all available diagnostic aids in an occasional case of non tuberculous pleurisy the etiology cannot be determined accurately

TREATMENT

The treatment of pleurisy is both symptomatic and specific Successful management depends greatly on the course of the primary disease which it may complicate Because fibrinous pleurisy is generally very painful early attention should be directed toward the alleviation of this distressing symptom The judicious use of narcotics not only controls the pain but also dispels the patient s appre-

hension Additionally, strapping of the affected hemithorax with adhesive tape may provide dramatic relief of the pain An occasional patient will be found who has a sensitivity to adhesive tape Therefore it is advisable to question the patient regarding the possible existence of this idiosyncrasy In its presence it is advisable to forego the benefits of this therapeutic measure rather than risk the subsequent complications A wide binder may serve the same purpose Injection of the intercostal nerves over the inflamed pleura with an anesthetic agent such as procaine or novocaine also may provide effective relief of the pain Effective relief of pain has been reported following the intravenous use of calcium A hot water bottle is always comforting With adequate control of the pleuritic pain the patient s clinical condition will show marked general improvement Dyspnea if due to voluntary restriction of respiratory movement will soon disappear Before satisfactory relief of the pleural pain is obtained it may become necessary to administer oxygen to combat dyspnea As the severity of the disease subsides acetylsalicylic acid will usually provide control of the pain Likewise it may be used to lower the temperature in the event of a severe febrile reaction The treatment of fibrinous pleuritis which complicates those clinical entities for which specific therapeutic measures are not available is wholly symptomatic This group unfortunately includes a considerable number of very common diseases and the results obtained with available therapeutic measures are usually discouraging

When pleurisy complicates primary diseases of bacterial origin the use of specific drugs may be indicated Drug sensitive bacterial pleurisies will respond to specific chemotherapeutic and antibiotic agents Actually a significant decrease in the incidence of drug sensitive bacterial pleurisies has resulted from the increased utilization of indicated sulfa drug preparations penicillin streptomycin aureomycin chloromycetin terramycin or other specific agents in the treatment of the responsible primary diseases The relative infrequence in recent years of empyema following lobar and bronchopneumonia is an excellent example

Aside from the added problem of fluid in the pleural cavity the treatment of serofibrinous pleurisy is similar to the management of fibrinous pleurisy As a rule it is inadvisable to aspirate a serofibrinous effusion unless the responsible agent is drug sensitive Careless thoracentesis may convert a relatively harmless serofibrinous effusion into a troublesome empyema In the presence of massive effusions resulting in marked dyspnea thoracentesis is indicated Aspiration of the pleural cavity should be preceded by careful localization of the fluid This can be accomplished with the aid of physical signs roentgenograms of the chest in various positions and fluoroscopy In spite of all possible precautions unsuccessful and traumatic thoracentesis may be encountered Even large effusions may be very difficult to locate with the aspirating needle Prior to aspiration, phenobarbital or some other suitable sedative should be administered This has the effect of allaying apprehension and also minimizing the possibility of serious accidents due to the use of any of the popular local anesthetic agents Sodium amytal and aminophyllin should be available for immediate intravenous administration in the event of an untoward reaction The use of sympathomi

accomplished with the patient in a sitting position A high back rest or the lateral decubitus position may be necessary for those patients who are unable to maintain sitting posture After proper sterilization of the selected site and satisfactory anesthesia of the skin subcutaneous tissues and parietal pleura is obtained an 18 or 19 gauge needle should be introduced carefully into the pleural cavity Large gauge needles may be required in thick effusions

In the author s experience the syndrome of pleural shock was never encountered If a bloody tap transpires the aspirating needle should be withdrawn immediately and thoracentesis should be attempted at another site Generally it is advisable to introduce the needle near the most dependent part of the fluid At no time should the operator force air through the needle in an attempt to locate and aspirate the pleural fluid This practice is very dangerous Fatal air embolism may result Successful withdrawal of thick exudates is accomplished more easily and safely after normal saline solution is instilled into the pleural cavity Management of thick exudates has recently been made simpler and more

successful with the intrapleural use of proteolytic enzymes The use of heparin in the pleural cavity to decrease or prevent fibrin formation requires additional investigation before its utilization can be recommended Once a free flow of fluid is obtained the needle may be fixed in place with a small hemostat This precaution will decrease local trauma and avoid accidental laceration of the underlying lung

There is no definite rule regarding the amount of fluid which may be aspirated It is a good practice to remove all the fluid possible before signs of cardiorespiratory distress supervene When the patient complains of a pulling sensation in the chest dyspnea or coughs slightly thoracentesis must be terminated These symptoms are the result of a too rapid re expansion of the collapsed lung or a shifting mediastinum with consequent torsion of the great vessels at the base of the heart The introduction of a small amount of air will relieve the symptoms and provide more satisfactory roentgenographic and fluoroscopic localization of the fluid Before the aspirating needle is withdrawn 50 000 units of penicillin should be instilled prophylactically in an effort to prevent secondary infection To avoid draining sinuses the site of entrance should be massaged briskly and the patient should be encouraged to lie on the opposite side for several hours The latter suggestion may be impossible to observe in the presence of marked dyspnea Subsequent aspirations if necessary should be performed at other sites in order to avoid local complications When the needle is in place the patient must never be permitted to move the arm on the ipsilateral side Pulmonary laceration may result or the needle may be broken

If the serofibrinous effusion is due to a penicillin sensitive organism 50 000 units of this drug may be instilled daily or twice daily until the fluid is sterile on seven successive cultures or the effusion is resorbed Once a serofibrinous exudate resorbs it does not tend to recur The introduction of concentrated penicillin solutions into the pleural cavity may be accompanied by pain or severe febrile reactions If sufficient fluid remains in the pleural cavity it will act as a diluent for the penicillin Otherwise it is best to dissolve the penicillin in normal saline in such proportions that the resulting solution will not contain more than 500 to 1 000 units per cc If the organism is penicillin resistant streptomycin may be substituted As much as 500 000 units (1/2 gm) may be instilled once or twice daily The concentration of streptomycin should not exceed 10 000 units per cc Simultaneous administration of systemic chemotherapeutic and antibiotic agents is necessary to obtain a lasting cure Both penicillin and streptomycin are absorbed from the pleural cavity General drug allergy has been observed after the intrapleural use of these drugs without concomitant or previous systemic administration To accelerate recovery from this complication the pleural cavity should be evacuated and thoroughly washed with a solution of normal saline

Prior to the era of antibiotics it was the general tendency for various reasons to avoid aspiration of both bacterial and non bacterial serofibrinous pleural exudates unless absolutely necessary Some men still adhere to this restriction The intelligent use of indicated antibiotics in bacterial serofibrinous pleural effusions, unquestionably prevents the development of a large number of empyemas The very satisfying experience with repeated antibiotic instillation and aspiration in indicated cases of bacterial serofibrinous exudates supports the continued use of this therapeutic and prophylactic practice All bacterial serofibrinous effusions should be considered potential empyemas and treated accordingly

The successful treatment of pyothorax depends on the accomplishment of the following objectives sterilization and removal of the fluid and obliteration of the empyema cavity with subsequent re-expansion of the lung The overwhelming majority of non tuberculous empyemas is due to the pneumococcus streptococcus and other bacteria with known susceptibility to available antibiotic agents Non surgical achievement of the enumerated objectives in the treatment of these empyemas depends on the intelligent utilization of indicated antibiotics systemically and locally The method of treatment is generally the same as that recommended for antibiotic susceptible serofibrinous exudates There are a few important differences in technic The fluid must be aspirated completely each day and the pleural cavity washed with normal saline solution In the presence of thick exudates the use of intrapleural proteolytic enzymes should be considered Instillation of 200 000 units of

streptokinase and 50 000 units of streptodornase (varidase®) or trypsin (tryptar®) ■ 25 to 0 5 gm into the pleural cavity may facilitate aspiration ■f thick exudates and multiloculated effusions Twelve to eighteen hours should be allowed for optimal enzyme activity prior to thoracentesis Moderately severe pyrogenic reactions may accompany the use of either of these preparations/ If the same result can be achieved with normal saline irrigation the use of either of these enzymes should be avoided Reexpansion of the lung should not be too rapid Loculated collections of pus may develop if re-expansion occurs before sterilization of the pleural cavity is accomplished Once sterility of the pleural cavity is achieved re-expansion of the lung should proceed without restriction It is imperative to follow the condition of the lung with daily roentgenographic or fluoroscopic examinations throughout the duration of the treatment Additionally bacteriologic studies of the fluid must be performed each day These precautions will provide important information regarding the endothorax and facilitate intelligent and safe management of each case Conservative management must be abandoned however if demonstrable evidence of clinical and bacteriologic improvement is not apparent after three or four days of treatment Failures are common in mixed putrid encapsulated and multiloculated empyemas. Likewise empyemas which develop in spite of antibiotic therapy for the primary disease are also apt to resist conservative management Empyemas associated with bronchopleural fistulas rarely respond to this form of therapy Poor results predominate the over all clinical results achieved in the treatment of chronic empyemas In cases of empyema necessitatis due to antibiotic sensitive bacteria medical management is usually successful The sinus will be obliterated and healed after the pleural cavity is freed of infection Empyemas due to septic pulmonary infarction may also respond to conservative management only to recur each time an infected embolus lodges in the lungs Lasting cures in this instance will be achieved only after proper surgical treatment of the primary disease In the face of therapeutic failure conservative management of empyema should be abandoned The patient should be given the benefit of surgical treatment without undue delay Systemic and local administration of antibiotic agents in indicated cases prior to surgical intervention will augment the therapeutic benefits of surgery Postoperatively the use of systemic and local antibiotic therapy ■ definitely indicated and unquestionably exerts a beneficial effect on the course ■f the disease

Supportive therapy in the conservative and surgical management of empyema ■ very important One should pay attention to the general condition of the patient Maintenance of a satisfactory state of nutrition is an essential prerequisite to successful conservative or surgical treatment of empyema patients Anemia malnutrition and avitaminosis are quite common Anemia should be treated with repeated blood transfusions The treatment of malnutrition and avitaminosis requires a nutritious diet high in carbohydrate protein and vitamin content The diet should be supplemented with additional vitamins by mouth or parenterally Occasionally the use of any of the popular protein preparations is indicated Other complications are treated as they arise

Successful treatment of pyothorax requires the close cooperation of the internist and thoracic surgeon Both must be open to suggestion and constructive criticism If a feeling of mutual respect for each other s opinions prevails patients with empyema will derive the full therapeutic benefits of cooperative medical and surgical management of their disease

MECHANICO-CIRCULATORY DISEASES OF THE PLEURA

Physical changes in the thorax altered capillary fragility and permeability and physi [illegible] and individually [illegible] sponsible for [illegible] of important [illegible] ons changes in the pleura proper are usually minimal or absent as contrasted with the definite alterations of the membrane characteristic of inflammatory diseases Nevertheless mechanico-circulatory diseases of the pleura are only the secondary manifestations of usually serious primary disease processes The pathogenesis and pathology of some of these pleural entities such as effusion associated with Meigs syndrome or with cirrhosis of the liver are not too clearly understood Systemic thoracic abdominal and other distant disease foci may be responsible for mechanico-circulatory dis-

turbances of the pleura The latter are all characterized by the abnormal presence of fluid or gas in the pleural cavity The type of abnormal pleural content affords a convenient and satisfactory basis for subdividing mechanico circulatory diseases of the pleura into four general groups hydrothorax hemorrhagic pleural effusion chylothorax and pneumothorax

Hydrothorax The presence of a non inflammatory serous effusion in the pleural cavity is known as hydrothorax This type of fluid is a clear pale straw colored transudate free of debris and does not clot on standing Its specific gravity is always less than 1 018 and as a rule varies from 1 012 to 1 014 The protein content may reach 2 5 per cent but is invariably less than 4 per cent Desquamated endothelial lining cells and a few lymphocytes constitute the cellular content These characteristics of a transudate differentiate it from an exudate If lymphocytes are present in unusually large numbers a transudate may be confused with a tuberculous effusion until additional differentiating studies are completed

Hydrothorax may be bilateral but in association with such clinical entities as Meigs syndrome cirrhosis of the liver or congestive heart failure it shows an unusual predilection for the right hemithorax Hydrothorax most frequently is the result of cardiac or renal failure As previously stated it usually occupies the right hemithorax in cardiac failure but may be bilateral and on rare occasions only the left pleural cavity is involved Loculated pleural effusions have also been observed in occasional cases of cardiac decompensation In renal failure such as that which accompanies true nephrosis or the nephrotic stage of nephritis it is usually bilateral Effusions of the right hemithorax characterize both cirrhosis of the liver and Meigs syndrome The exact mechanism responsible for the pleural transudate in both of these instances and their almost uniform presence in the right hemithorax is a fact without reasonable explanation As originally described Meigs syndrome was characterized by fibroma of the ovary ascites and the presence of an effusion in the right hemithorax Recently however thecomas multilocular cystadenomas and other benign pelvic tumors have also been identified with Meigs syndrome Anemia malnutrition wet beriberi the pressure of intrathoracic tumor masses, thrombotic occlusion of large endothoracic veins and the mechanical effect of a good sized pneumothorax may also be responsible for hydrothorax

The signs symptoms and diagnosis of hydrothorax are generally the same as those of inflammatory effusions Therapeutic management of hydrothorax depends entirely on the nature and progress of the underlying disease process To relieve annoying dyspnea thoracentesis may be performed when indicated The beneficial effects of this symptomatic measure however are relatively short lived Unless the responsible primary cause is eliminated the fluid re accumulates rapidly Since transudates are excellent culture media for bacteria thoracentesis should be avoided or delayed if possible Flawless sterile technic must be observed or else the risk of superimposed bacterial infection will dwarf the expected therapeutic benefits Surgical removal of the pelvic tumor in Meigs syndrome results in complete and permanent resorption of the hydrothorax

Hemorrhagic Pleural Effusion The presence of frank blood in the pleural cavity is known as hemothorax It is usually due to thoracic trauma or rupture of a thoracic aneurysm When the pleural fluid contains enough red blood cells to produce pink or reddish color but is not frank blood it is referred to as a hemorrhagic effusion A minimum of 5 000 to 6 000 red blood cells per cu mm is required for the production and gross recognition of hemorrhagic effusions The color of the fluid depends on the condition as well as the number of the red blood cells Degeneration of the red corpuscles is followed by changes in the hemoglobin which may produce a brown or amber colored effusion In hemorrhagic pleural effusions eosinophil cells may be present in unexplained large numbers and examination of the circulating blood may also reveal an absolute eosinophilia

Under certain conditions any pleural effusion may become hemorrhagic Primary and metastatic malignancies of the pleura however are responsible for about 85 per cent of all hemorrhagic effusions This complication is likewise not an uncommon finding in association with such clinical entities as pulmonary infarction congestive heart failure leukemia thrombocytopenic purpura hemorrhagica cirrhosis of the liver pneumonia rheumatic fever or nephritis Hemorrhagic effusions in association

with tuberculosis of the pleura have been observed only rarely by the author This observation differs sharply from previous teachings and prevailing popular clinical opinions on the matter The presence of traumatic blood in aspirated fluid at the very beginning or at the conclusion of thoracentesis must not be confused with hemorrhagic pleural effusions

The signs symptoms and methods of diagnosis of hemorrhagic pleural effusions are generally similar to the observations made in connection with the discussion of the other types of pleural effusions Treatment depends on the type of the original fluid and the nature of the primary disease

Chylothorax Medical dictionaries define chylothorax as the presence of milky fluid in the pleural cavity True chyle chyliform fluid and pseudochylous effusions are all included in this loose non specific definition Consequently much unnecessary confusion has resulted from the defined use of the word In this presentation the use of the term chylothorax is restricted to the designation of chyle in the pleural cavity Pseudochylous or chyliform fluids are regarded as peculiar or complicating characteristics of certain non chylous pleural effusions Some clinicians and pathologists have even attempted to differentiate between pseudochylous and chyliform effusions This practice has resulted unfortunately, in only additional confusion If both terms are retained it is best that they be used interchangeably Chyle contains varying amounts of emulsified fats Macroscopically, it has an opalescent homogenous milky appearance After standing a creamy supernatant layer may develop Clotting may also occur, but this is an uncommon characteristic The fat content may vary from 0 4 per cent to 4 0 per cent and its presence may be verified by staining the fluid with Sudan III Microscopic examination of an unstained specimen reveals

of chyle is alkaline and its specific gravity is greater than 1 012 Proteins and white blood cells are present in variable amounts Lymphocytes however, are the predominating cells Unless secondarily infected the fluid is sterile and usually odorless These are the characteristics of chyle which readily differentiate it from the pseudochylous fluid of long standing encysted effusions lipoid nephrosis or effusions associated with the nephrotic stage of glomerulonephritis Microscopically pseudochylous effusions have a more homogeneous appearance than chylous fluid

Chylothorax has been recognized with increasing frequency in recent years and is by no means as rare as previously believed It may occur at any age but is relatively uncommon in infancy Malignant involvement of the thoracic duct its tributaries the left subclavian vein or other large veins of the thorax is most frequently responsible for the development of chylothorax Malignant invasion of one or more of the enumerated vessels or direct pressure of the tumor mass on any of these structures may result in this complication Tumors of the lymphoblastoma group are commonly responsible for chylothorax The presence of chyle in the pleural cavity is due to trauma in about one-third of the cases Perforating lymphangitis the pressure of inflammatory endothoracic lymph nodes cirrhosis of the liver filariasis or ruptured aneurysms of the thoracic duct may also cause chylothorax Spontaneous rupture of the thoracic duct occurs most frequently in infants Since the thoracic duct traverses the greater part of the thorax to the right of the vertebral column most chylothoraces involve the hemithorax on that side The thoracic duct is an extrapleural structure Consequently chylous fluid may be present in the extrapleural space for considerable periods of time before entering the pleural cavity

In addition to the usual signs and symptoms of fluid in the pleural cavity chylothorax is associated with other characteristic clinical findings Emaciation malnutrition oliguria and thirst may all be manifest The severity of the symptoms varies with the degree and duration of the chylothorax The author once observed the development of a peptic ulcer followed by fatal hemorrhage in a young child of seven suffering from chylothorax In this case the marked hypoproteinemia was thought to be responsible for the development of the ulcer The diagnosis of chylothorax is easily established after aspiration and examination of the pleural fluid

The treatment of chylothorax is generally unsatisfactory When trauma is the responsible cause healing of the thoracic duct and subsequent recovery may be expected in about 50

per cent of the cases The results are uniformly poor when chylothorax is due to malignancy Irradiation of radiosensitive lymphoblastomas may give temporary relief General symptomatic measures directed at maintaining a satisfactory state of nutrition are essential The replacement of lost proteins and fats should receive special attention Any attempt to accomplish this objective especially in cases due to malignancy usually ends in failure Intravenous readministration of chyle aspirated from the pleural cavity has been tried The results of this form of therapy are likewise not only equivocal but frequently fatal Surgical repair of the thoracic duct in spontaneous chylothoraces and those due to trauma is a very difficult undertaking and usually ends in failure The results achieved from paralysis of the corresponding hemidiaphragm or the induction of an artificial pneumothorax are also very discouraging Since chyle reaccumulates very rapidly after thoracentesis this measure should be avoided if possible and reserved for the alleviation of severe dyspnea Aspiration offers only temporary symptomatic relief and may initiate a harmful vicious cycle

NEOPLASTIC DISEASES OF THE PLEURA

Tumors of the pleura may be primary or secondary Primary tumors are exceedingly rare while secondary tumors are not uncommon The most important and probably the only primary malignancy of the pleura is the mesothelioma In the 19th century the term tubercle like lymphadenoma was used to describe this tumor Later the name endothelioma was proposed for this malignancy because it was ascribed to a vascular origin Recent reliable investigations together with the fact that the pleura is a mesodermal derivative have established the term mesothelioma as a more descriptive and appropriate identification of this tumor

Tumors arising in the pleura will display both epithelial and mesenchymal characteristics Mesotheliomas are ordinarily composed of large epithelioid cells separated by collagenous fibers of tumor cell origin The cellular elements have a tendency to arrange themselves as alveolar rests or rows Unfortunately not all pleural mesotheliomas present this typical histopathologic pattern Pleomorphism and multidirectional lines of evolution complicate the proper identification and classification of this new growth This tendency to frequent deviation has been paralleled by equally numerous attempts by well intentioned investi

is clouded and confusing Conclusive investigation and authoritative evaluation of this controversial problem have been limited by the paucity of cases available for study Only one and probably less than one case in every one thousand postmortem examinations is a proved pleural mesothelioma If primary malignancies of the pleura do occur the weight of the available evidence supports the contention that they are all mesotheliomas with inherent possibilities of wide structural variation

This opinion however is not shared by all clinicians and pathologists There is a sizable group of reliable investigators who do not admit the possible existence of primary tumors of the pleura This contention is a very disarming possibility when one considers the large volume of literature which has been written on the subject of pleural mesothelioma by innumerable reliable investigators It is true nevertheless that many pleural tumors diagnosed originally as mesotheliomas are proved eventually to be metastatic lesions from the underlying bronchopulmonary tissue or neighboring thoracic and even more distant organs A small primary malignant nodule in the lung is not infrequently the source of widespread pleural involvement Unless the pulmonary tissue is examined diligently in all cases of suspected pleural mesothelioma a small primary tumor nodule may be overlooked A high index of suspicion should be maintained at all times regarding this possibility in order to avoid erroneous diagnoses of pleural mesothelioma Primary malignancies frequently arise in relation to the parietal pleura They have their origin in the fascia of the intercostal muscles nerve sheaths and other thoracic structures Angiosarcomas lipomyxosarcomas neurosarcomas round cell or spindle-cell sarcomas rhabdomyosarcomas or chondrosarcomas which arise from these tissues may be attributed erroneously to a pleural origin because of the intimate relationship of the

with tuberculosis of the pleura have been observed only rarely by the author This observation differs sharply from previous teachings and prevailing popular clinical opinions on the matter The presence of traumatic blood in aspirated fluid at the very beginning or at the conclusion of thoracentesis must not be confused with hemorrhagic pleural effusions

The signs symptoms and methods of diagnosis of hemorrhagic pleural effusions are generally similar to the observations made in connection with the discussion of the other types of pleural effusions Treatment depends on the type of the original fluid and the nature of the primary disease

Chylothorax Medical dictionaries define chylothorax as the presence of milky fluid in the pleural cavity True chyle chyliform fluid and pseudochylous effusions are all included in this loose non specific definition Consequently much unnecessary confusion has resulted from the defined use of the word In this presentation the use of the term chylothorax is restricted to the designation of chyle in the pleural cavity Pseudochylous or chyliform fluids are regarded as peculiar or complicating characteristics of certain non chylous pleural effusions Some clinicians and pathologists have even attempted to differentiate between pseudochylous and chyliform effusions This practice has resulted unfortunately in only additional confusion If both terms are retained it is best that they be used interchangeably Chyle contains varying amounts of emulsified fats Macroscopically it has an opalescent homogenous milky appearance After standing a creamy supernatant layer may develop Clotting may also occur but this is an uncommon characteristic The fat content may vary from 0 4 per cent to 4 0 per cent and its presence may be verified by staining the fluid with Sudan III Microscopic examination of an unstained specimen reveals its oily nature Removal of the fat and clearing of the fluid may be accomplished by shaking an alkalinized specimen with ether The reaction of chyle is alkaline and its specific gravity is greater than 1 012 Proteins and white blood cells are present in variable amounts Lymphocytes however are the predominating cells Unless secondarily infected the fluid is sterile and usually odorless These are the characteristics of chyle which readily differentiate it from the pseudochylous fluid of long standing encysted effusions lipoid nephrosis or effusions associated with the nephrotic stage of glomerulonephritis Microscopically pseudochylous effusions have a more homogeneous appearance than chylous fluid

Chylothorax has been recognized with increasing frequency in recent years and is by no means as rare as previously believed It may occur at any age but is relatively uncommon in infancy Malignant involvement of the thoracic duct its tributaries the left subclavian vein or other large veins of the thorax is most frequently responsible for the development of chylothorax Malignant invasion of one or more of the enumerated vessels or direct pressure of the tumor mass on any of these structures may result in this complication Tumors of the lymphoblastoma group are commonly responsible for chylothorax The presence of chyle in the pleural cavity is due to trauma in about one third of the cases Perforating lymphangitis the pressure of inflammatory endothoracic lymph nodes cirrhosis of the liver, filariasis or ruptured aneurysms of the thoracic duct may also cause chylothorax Spontaneous rupture of the thoracic duct occurs most frequently in infants Since the thoracic duct traverses the greater part of the thorax to the right of the vertebral column most chylothoraces involve the hemithorax on that side The thoracic duct is an extrapleural structure Consequently chylous fluid may be present in the extrapleural space for considerable periods of time before entering the pleural cavity

In addition to the usual signs and symptoms of fluid in the pleural cavity, chylothorax is associated with other characteristic clinical findings Emaciation malnutrition oligiuria and thirst may all be manifest The severity of the symptoms varies with the degree and duration of the chylothorax The author once observed the development of a peptic ulcer followed by fatal hemorrhage in a young child of seven suffering from chylothorax In this case the marked hypoproteinemia was thought to be responsible for the development of the ulcer The diagnosis of chylothorax is easily established after aspiration and examination of the pleural fluid

The treatment of chylothorax is generally unsatisfactory When trauma is the responsible cause healing of the thoracic duct and subsequent recovery may be expected in about 50

per cent of the cases The results are uniformly poor when chylothorax is due to malignancy Irradiation of radiosensitive lymphoblastomas may give temporary relief General symptomatic measures directed at maintaining a satisfactory state of nutrition are essential The replacement of lost proteins and fats should receive special attention Any attempt to accomplish this objective, especially in cases due to malignancy, usually ends in failure Intravenous readministration of chyle aspirated from the pleural cavity has been tried The results of this form of therapy are likewise not only equivocal but frequently fatal Surgical repair of the thoracic duct in spontaneous chylothoraces and those due to trauma is a very difficult undertaking and usually ends in failure The results achieved from paralysis of the corresponding hemidiaphragm or the induction of an artificial pneumothorax are also very discouraging Since chyle reaccumulates very rapidly after thoracentesis, this measure should be avoided if possible and reserved for the alleviation of severe dyspnea Aspiration offers only temporary symptomatic relief and may initiate a harmful vicious cycle

NEOPLASTIC DISEASES OF THE PLEURA

Tumors of the pleura may be primary or secondary Primary tumors are exceedingly rare while secondary tumors are not uncommon The most important and probably the only primary malignancy of the pleura is the mesothelioma In the 19th century the term, "tubercle-like lymphadenoma," was used to describe this tumor Later the name, "endothelioma," was proposed for this malignancy because it was ascribed to a vascular origin Recent reliable investigations together with the fact that the pleura is a mesodermal derivative have established the term mesothelioma as a more descriptive and appropriate identification of this tumor

Tumors arising in the pleura will display both epithelial and mesenchymal characteristics Mesotheliomas are ordinarily composed of large epithelioid cells separated by collagenous fibers of tumor cell origin The cellular elements have a tendency to arrange themselves as alveolar rests or rows Unfortunately, not all pleural mesotheliomas present this typical histopathologic pattern Pleomorphism and multidirectional lines of evolution complicate the proper identification and classification of this new growth This tendency to frequent deviation has been paralleled by equally numerous attempts by well intentioned investigators to prove the existence of more than one type of primary pleural malignancy The problem of pleural malignancies, consequently, is clouded and confusing Conclusive investigation and authoritative evaluation of this controversial problem have been limited by the paucity of cases available for study Only one, and probably less than one, case in every one thousand postmortem examinations is a proved pleural mesothelioma If primary [illegible]

with inherent possibilities of wide structural variation

This opinion, however, is not shared by all clinicians [illegible] group of [illegible] mit the [illegible] of the pleura This contention is a very disarming possibility when one considers the large volume of literature which has been written on the subject of pleural mesotheliomas by innumerable reliable investigators It is true, nevertheless, that many pleural tumors diagnosed originally as mesotheliomas are proved eventually to be metastatic lesions from the underlying bronchopulmonary tissue or neighboring thoracic and even more distant organs A small primary malignant nodule in the lung is not infrequently the source of widespread pleural involvement Unless the pulmonary tissue is examined diligently in all cases of suspected pleural mesothelioma, a small primary tumor nodule may be overlooked A high index of suspicion should be maintained at all times regarding this possibility in order to avoid erroneous diagnoses of pleural mesothelioma Primary malignancies frequently arise in relation to the parietal pleura They have their origin in the fascia of the intercostal muscles, nerve sheaths and other thoracic structures Angiosarcomas, lipomyxosarcomas, neurosarcomas, round cell or spindle-cell sarcomas, rhabdomyosarcomas or chondrosarcomas which arise from these tissues may be attributed erroneously to a pleural origin because of the intimate relationship of the [illegible]

in diagnosis After careful consideration this author is satisfied to conclude that such an entity as pleural mesothelioma does exist That it probably occurs much less frequently than one time in every 1 000 postmortem examinations also appears to be a valid assumption

There are no primary benign tumors of the pleura Just as the tumors which arise in relationship to the parietal pleura are malignant those which occur in association with the visceral pleura are ordinarily benign Fibromas lipomas and chondromas have their origin in the subserous connective tissues Giant sarcomas which arise in relation to the visceral pleura do not possess metastatic or invasive properties They grow slowly but may attain tremendous size Primary tumors which arise in relation to the visceral pleura, with the possible exception of giant sarcomas, are asymptomatic They are very small and usually discovered only by accident during surgical procedures or postmortem examinations Surgical excision of these growths is the method of treatment

Metastatic malignancies of the pleura are common Any tumor which is capable of producing metastases may involve the pleura Metastatic pleural lesions are most frequently secondary to tumors of the underlying bronchopulmonary tissue Tumors of the breast also involve the pleura with great frequency Malignant lesions of the esophagus are a frequent source of metastatic pleural involvement Tumors of the other thoracic structures stomach adrenals prostate thyroid pancreas and uterus are additional common sources of pleural metastases Whenever a pleural malignancy is discovered it is imperative that these and other sites in the body be carefully scrutinized for a possible source of metastasis

Primary or metastatic lesions of the pleura may be diffuse or localized Either variety produces hemorrhagic pleural effusions Any unexplained pleural effusion whether hemorrhagic or otherwise however in individuals past the age of forty should arouse strong suspicions of a possible underlying malignant process The chemical physical and cytologic characteristics of the fluid depend upon the nature of the malignancy, duration location and extent of pleural involvement Occasionally the effusion develops the characteristics of a true hemothorax

The tendency to rapid reaccumulation following thoracentesis is a regular characteristic of effusions produced by malignant diseases of the pleura Following the detection of hemorrhagic pleural effusion indicated clinical and laboratory study to establish the correct etiology is in order However, one should bear in mind that a hemorrhagic pleural effusion is a possible manifestation of such clinical entities as pulmonary infarction congestive heart failure thrombocytopenic purpura hemorrhagica cirrhosis of the liver pneumonia rheumatic fever nephritis or pulmonary tuberculosis Under certain conditions any pleural hemorrhagic effusions Although roentgenographic and fluoroscopic examination of the chest are without rival in detecting pleural reactions accurate identification of the etiologic factor depends upon other clinical and laboratory studies

Diagnostic thoracentesis should be performed as soon as the presence of a pleural effusion has been determined An anticoagulant should be added to the aspirated material to avoid clotting Complete withdrawal of the effusion should be attempted in order to facilitate more satisfactory roentgenographic examination of the underlying lung Should the symptoms of dyspnea cough pulling sensation or pain in the chest develop during the procedure the introduction of a small quantity of air usually suffices to control these manifestations of changing intrathoracic pressures and position of the heart and great vessels Aspiration of the effusion may then be continued until all the fluid is withdrawn repeating small injections of air as necessary Production of pneumothorax in the presence of a hemorrhagic pleural effusion due to a malignancy is actually desirable for diagnostic purposes Introduction of air should be minimal or avoided after the diagnosis is established Since bloody effusions are excellent culture media for bacteria strict asepsis must be practiced in performing each thoracentesis To avoid troublesome complications such as pyohemothorax penicillin or any other suitable antibiotic agent should be instilled into the pleural cavity and along the needle tract when the thoracentesis is completed

Determination of the specific gravity and chemical analysis of hemorrhagic pleural effusions due to malignancy are of no diagnostic value The fluid may be thin and easy to aspirate or very thick and gelatinous and difficult to remove Cytologic examination of properly prepared specimens of the hemor-

of repeated diligent study

If identification of the tumor does not follow pleural fluid examination, other diagnostic studies should be considered A careful search for enlarged lymph nodes or overt tumor growths in the immediate thoracic or more distant regions of the body may be fruitful The breast thyroid uterus and prostate deserve special attention Surgical biopsy of an abnormal lymph node or other lesion may provide the diagnosis after histopathologic study Aspiration biopsies of the pleura are generally failures Punch biopsies with a Vim Silverman needle are more successful in these instances Larger and more satisfactory pieces of tissues are made available for study by this latter procedure Many condemn the use of aspiration or punch biopsies because of the possible danger of stimulating or actually producing metastatic lesions In the presence of malignant pleural effusions one need not hesitate to perform either an aspiration or punch biopsy of the pleura This observer has heard and read many reports of secondary seeding and metastasis following either of these procedures but has never experienced or witnessed these misfortunes Furthermore how much significant harm can one produce in the presence of either a primary or secondary pleural malignancy? Actually and with rare exceptions determination of an accurate diagnosis in these instances is of academic interest only

Since malignant tumors of the pleura are frequently secondary to primary lesions of the bronchopulmonary tissue bronchoscopic examination should be performed routinely The responsible primary tumor may be visualized Specimens of bronchopulmonary secretions and frequently biopsy material may be obtained in this fashion for histopathologic review Additionally, careful study of the position and configuration of the bronchoscopically accessible portions of the tracheobronchial tree may be of valuable diagnostic assistance Bronchography should be used for indirect visualization of those portions of the tracheobronchial network which are inaccessible for direct bronchoscopic study Careful roentgenographic and fluoroscopic examinations of the lung in various positions are especially helpful Examination of the gastrointestinal tract with an opaque material may reveal the source of pleural metastasis A high serum acid phosphatase level will incriminate the prostate Alkaline phosphatase determination is of no special value If existence and identification of a malignancy is not established or confirmed by the enumerated procedures, one should not hesitate to recommend thoracoscopic examination of the pleura and preferably, a diagnostic thoracotomy Many other diagnostic procedures may be attempted In this presentation however, only those procedures which are most frequently indicated practicable and generally useful have been discussed and evaluated

Since mesothelioma is considered the only primary malignancy of the pleura it deserves some special attention Pleural mesotheliomas may occur in all ages but are most frequent in the adult age group Males are affected twice as often as females Both hemithoraces are probably involved with equal frequency but opinion is divided on this point The onset of the tumor is insidious Non productive cough and pain in the chest are early symptoms Fever becomes a manifestation when secondary infection supervenes but may occur without this complication Later, the cough may acquire expectorant qualities Massive accumulation of a hemorrhagic pleural effusion occurs with distressing regularity Dyspnea ensues and quickly assumes the position of paramount concern among all other symptoms The patient becomes cachetic with startling rapidity Loss of weight anemia and weakness are typical observations Dependent edema may occur at any stage of the illness The panorama of symptoms changes frequently to correspond to the rapid growth of the tumor Frequent thoracenteses are indicated for the palliative relief of dyspnea Resistance to the introduction of the aspirating needle may be marked

As previously indicated the benefits of thoracenteses are very temporary since the fluid reaccumulates rapidly Occasionally daily thoracenteses are necessary to relieve the cardiorespiratory embarrassment The fluid is easily aspirated early in the illness but gradually it becomes thicker and more difficult to remove Reaccumulation has been observed to occur less rapidly after the pleural fluid assumes a thicker character There is no effective treatment for pleural mesothelioma or any other malignant involvement of the pleura Metastases are common and the tumor may extend to involve the other pleural cavity, pericardium, peritoneum and capsules of abdominal viscera Patients usually die within six to twelve months following detection of the tumor

Spontaneous Pneumothorax—Clinical Diagnosis and Management

DONALD S TISINGER, JR, M D AND GEORGE R MENEELY, M D, *Nashville, Tennessee*

From the Research Laboratory, Thayer Veterans Administration Hospital and the Department of Medicine Vanderbilt University School of Medicine Nashville Tennessee

HIPPOCRATES noted the succussion splash in chest disease but did not recognize pneumothorax as an entity About 1770 Henson noted an instance of air in the thorax Itard in 1803 first related spontaneous pneumothorax to tuberculosis Laennec gave a full description in 1819 and suspected emphysematous blebs as a cause This Devilliers confirmed in 1826 In 1895 Foralini first suggested its use therapeutically [1]

INCIDENCE

The incidence of spontaneous pneumothorax varies in different reports from one in 500 to one in 1,000 in various population samples It is two to five times as frequent in men as in women and more common on the right side than the left [2-6] Twenty to thirty years ago some 78 per cent were reported due to tuberculosis[5] whereas recent studies show only 6 to 10 per cent associated with tuberculosis [6 7]

Rapport[8] suggests a classification of disease

disease including (*a*) tuberculosis (*b*) pneumonia and pneumonitis, (*c*) abscess, (*d*) bronchiectasis and its complications, (3) emphysema including (*a*) the obstructive types of emphysema, giant bulbous emphysema and bleb formation secondary to obstruction *

* A bleb differs from a bulla in that a bulla is freely communicative and can be collapsed whereas a bleb is due to interstitial air usually over the surface of the lungs and when pressed out in one spot moves to another without collapsing

(*b*) localized distentions due to atelectasis, fibrosis, sarcoidosis, pneumonia etc, (*c*) senile

weights, fractured ribs, piercing chest cage

list covers in a general classified form those processes which may give rise to spontaneous pneumothorax

The actual cause is leakage of air from the respiratory passages or alveoli into the pleural space This as a rule is due to rupture of an alveolar septum or to a tear of the bronchial wall Air migrates out under the pleural surface with bleb formation or ruptures into the pleural space directly A tear in the visceral pleura may occur as a result of adhesions Occasionally air will dissect back along the course of the bronchus instead of out toward the pleural surface This may continue into the hilus and mediastinum and then through the visceral pleura to produce pneumothorax Such instances are often associated with clinical evidence of mediastinal emphysema and sometimes subcutaneous emphysema As a result of the tear, air irritation or vascular involvement there may be fluid or blood in the pleural space In cases in which pneumothorax is due to an infectious process there may be empyema as well

TYPES

The pneumothorax thus produced is either (1) closed pneumothorax (following the initial leakage) which will re expand as air is reabsorbed, (2) open pneumothorax (where there is a fistulous opening between the lung and the pleural space) which will not re-expand until the fistulous passage closes, and (3) tension

pneumothorax (where a valve like action occurs at the site of leakage) in which progressive increase of pressure pneumothorax occurs

CLINICAL FEATURES

Acute chest pain is present in almost 100 per cent of cases It is a sharp cutting, tearing or stabbing pain on the affected side seemingly pleuritic in nature The next most common symptom is dyspnea Next in order are sweating cyanosis and in some 10 per cent of instances fever *Fluid* may be present either blood pus or a serous effusion The patient may then experience a splashing sensation in the chest The patient usually assumes a sitting position Pallor and sometimes cyanosis may be observed Respiration is difficult The affected side is usually distended with poor respiratory excursions There may be venous dilatation over the affected side The heart and *trachea are shifted away from the affected side* Tactile fremitus is decreased The percussion note is hyper resonant Breath sounds are decreased If much fluid is present a succussion splash can be elicited Occasionally a whistle bubble or metallic tinkle can be heard in open pneumothorax Coin sounds can frequently be elicited [4 6 8]

The chief problem presented in spontaneous pneumothorax is one of disturbed intrathoracic pressure In order to maintain respiration the chest cage and diaphragm must be able to produce enough negative pressure to expand the lungs In open pneumothorax air exchange into the lungs is in competition with that going through the leak into the pleural cavity Thus it is easy to see why a patient with a rigid chest cage poor diaphragmatic movement low vital capacity poor lung elasticity or obstructed *bronchiolar and bronchial passages does poorly* with this added respiratory embarrassment The contralateral lung is also affected by reduc

pneumothorax has general causes (1) Pain increases metabolism (2) Increased muscular effort to maintain negative pressure is necessary to maintain respiration with subsequent muscle fatigue (3) The fact that the lungs collapse to a greater extent than usual brings into play the expiratory side of the Hering Breuer reflex to a much greater degree than normally (4) In the normal lung the differential circulation to various parts of the lung is due to local oxygen concentration differences This normally prevents shunting phenomena In diseased lungs in which these differentials are not maintained the shunting phenomena may take place with consequent reduced oxygen saturation and increased carbon dioxide retention Both tend to produce dyspnea (5) As the lung is changed in volume the pulmonary vascular bed fails to act as the fluid buffer system it is normally This may add a burden

circulatory function Coupled with shunting phenomena this also decreases oxygen supply to the heart ending further to reduce cardiac efficiency Movement of the mediastinum with respiration will impair the efficiency of the contralateral lung The psychic response of *the patient to pain and dyspnea is an additional* factor which will vary from person to person [10 14]

MANAGEMENT

numerous are of larger size and do not have the expansive resistance of bronchi and vessels to which the inner and more medial alveoli are subject Second the lymphatics of the outer layer drain around the periphery to the hilus rather than along the bronchial tree Third the outer portion contains only small size capillary vessels Fourth the outer layer is the first subjected to negative pressure as it develops and thus expands first in inspiration since it has least resistance to expansion the inner *alveoli depending largely on the elongation* of the bronchi to allow their expansion Thus the outer alveoli are very important from a respiratory standpoint Any restrictive process over these alveoli will reduce the number of *effective respiratory units* [13 14] *These points* are of principal importance in relation to the long term implications of therapeutic measures for preservation of pulmonary function Further the acute complications of spontaneous pneumothorax such as extreme respiratory

that must be managed

The choices of treatment are (1) Palliative support with bedrest, oxygen and other drugs as indicated (2) Repeated aspirations as required there [illegible] danger in putting a needle into the chest, for, as the lung [illegible] drawn out, new tears could be made in the visceral surface which would provide new sites for air leakage These simple methods of management may require somewhat longer hospitalization than some of the more radical methods however, they may be justified by the long term results in terms of preservation of lung function (3) Indwelling needle with water seal this will undoubtedly expand the lung more rapidly Here again the danger of the needle tearing the visceral surface of the lung is a problem The needle in some instances is hard to keep in place (4) Thoracotomy tube with underwater seal this probably introduces more blood than the preceding methods and it undoubtedly causes more pleural reaction than the previously mentioned methods These tubes, however, are easier to keep in place The water seal has been mentioned as dangerous from the standpoint of forming a continuous fluid column from the pleural space (5) Three-bottle suction with the Stedman pump the bottle connected with the thorax contains only air The second bottle contains fluid The tube from the first bottle enters only to the neck of the second and the tube to the third bottle comes from the neck of the second to the third bottle which contains air and [illegible] attached to continuous suction The amount of suction is controlled in the second bottle containing fluid by the depth to which a third tube communicating to room air is immersed in the fluid As [illegible]

room through the middle bottle on inspiration As the lung becomes expanded after the tear heals, there will be continuous bubbling in the middle bottle (6) Thoracotomy and surgical repair of tears This is reserved for large tears or obvious bronchopleural fistula Decortication is usually recommended in four to six weeks following the original episode [6 17–20]

Prevention of recurrence in patients who have had several episodes presents a thorny problem Surgical exploration with plication of suspicious areas as well as the introduction of hypertonic glucose talcum powder, the patient's own blood, silver nitrate, gomonol in oil, or some other irritant to cause synthesis or obliteration of the pleural space have all been tried There are reported successes with each The fact remains that failure is more often the rule, whatever the method employed In general conservative treatment is the best policy and only those patients subject to frequent recurrence should be considered for intervention of this sort The specific measure chosen will depend on the experience of the responsible physician [18 19 21 22]

Spontaneous pneumothorax is, then, a clinical entity which occurs with sufficient frequency that virtually every practitioner should be familiar with it Usually an essentially benign phenomenon, at times it presents as a dire emergency Aside from this latter situation when immediate relief of tension by needle is imperative, conservative management holds most promise for long term preservation of pulmonary function Treatment must be individualized Prevention of recurrence remains the major unsolved problem

REFERENCES

1 DICKIE, H A Spontaneous mediastinal emphysema and spontaneous pneumothorax A report of 20 cases *Ann Int Med* 28 61[illegible] 1948

[illegible]

healthy young adults *Am J M Sc* 211 138 1946

4 CRENSHAW G L Etiology treatment and surgical indications of non tuberculous non traumatic spontaneous pneumothorax *Dis of Chest* 17 369 1950

5 BROCK, R C Recurrent and chronic spontaneous pneumothorax *Thorax* 3 88 1948

6 RAPPORT R L THURLOW A A and KLASSEN K P Etiology and management of spontaneous pneumothorax *Arch Surg* 67 266 1953

7 BRIGGS J N WALTERS R W and BRYON F X Spontaneous pneumothorax *Dis of Chest* 24 564 1953

[illegible]

Injuries to the Thorax Surgical Clinics of North America p 1069 Philadelphia 1953 W B Saunders Co

10 BEST C H and TAYLOR, N B The Physiologic Basis of Medical Practice p 304 Baltimore 1945 Williams and Wilkins Co

[illegible] COURNAND A BROCH H J RAPPAPORT J and

RICHARDS, [illegible] W, JR Disturbance of action of respiratory musculature as a contributory cause of dyspnea *Arch Int Med*, 57 1008, 1936

12 COURNAND, A Some aspects of the pulmonary circulation in normal man and in chronic cardio [illegible]

SCHREIBER, H LITTLE, R C and SEELY, R D Study of simultaneous right and left arterial pressure pulses under normal and experimental altered conditions *Am J Physiol*, 154 258, 1948

15 KEITH, A The Mechanism of Respiration in Man In Further Advances in Physiology Edited by L Hill London, 1909 Edward Arnold

16 DRINKER, C K Pulmonary Edema and Inflammation Cambridge, Mass, 1945 Harvard Univ Press

17 KIRCHER, L T, JR and SWARTZEL, R. L Spontaneous pneumothorax and its treatment *J A M A*, 155 24 1954

18 DUBOSE, H M, PRICE, H J and GUILFOIL, P H [illegible]

19 D [illegible] lous chest disease treatment of spontaneous pneumothorax *Tr Nat Tuberc A*, 48 66, 1952

20 NALLS, W A and MATHEWS, J H Idiopathic spontaneous hemopneumothorax An evaluation of its treatment and report of three cases *Dis of Chest*, 15 612, 1949

21 GROSSMAN, L A Recurrent bilateral spontaneous pneumothorax treated with artificial hemothorax *Ann Int Med*, 39 1303 1953

22 SMITH, F R Talc poudrage treatment of recurrent and chronic spontaneous pneumothorax *Northwest Med* 52 937, 1953

Spontaneous Pneumothorax—With Emphasis on Treatment

JOHN N BRIGGS, M D AND FRANCIS X BYRON, M D, *Los Angeles, California*

ALTHOUGH the etiology of spontaneous pneumothorax is sometimes unknown, the most common reported cause is rupture of an emphysematous bleb Formerly, tuberculosis was thought to be one of the more common causes, now it is known to be a rather rare cause of this condition The onset of spontaneous pneumothorax does not necessarily occur during a period of straining or heavy lifting, but most often occurs during normal activity In a recent review of eighty four cases of spontaneous pneumothorax it was discovered that in all but two of the incidences, the pneumothorax occurred during normal activities [1]

Although Wilson has reported five asymptomatic cases, it has been our experience that symptoms are always present [1,2] In order of frequency the symptoms are pain in the chest, dyspnea and cough Because symptoms are always present, no case should be unsuspected and undiagnosed A chest x ray will always confirm the diagnosis

It is important that all cases of spontaneous pneumothorax be recognized and treated, because if untreated it may be fatal When death occurs, tension pneumothorax is usually responsible Due to a check valve mechanism at the point of pleural leak, the intrapleural pressure builds up, causing increasing atelectasis on the affected side and progressive shift of the mediastinum to the unaffected side Death results from inadequate oxygenation and torsion of the great vessels

TREATMENT

Spontaneous pneumothorax may be treated by a variety of methods and all are acceptable in most instances At the present time there are three principal methods of treatment for this condition (1) bedrest alone, (2) aspiration of air from the pleural space by thoracentesis, (3) closed thoracotomy with catheter water seal drainage

It is true that most pneumothoraces will re-expand with bed-rest alone The principal disadvantage to this treatment is that it takes a month or more to re-expand the lung During this time the patient is unable to work, remaining in bed at home or in the hospital Because of its frequency in young males, the breadwinner of a family may be unable to work for one month or more The second modality of treatment, aspiration of the pleural space, has a disadvantage similar to the first, namely, that it takes an average of twenty-two days to re-expand the lung In contrast to the foregoing when closed thoracotomy is used, complete re-expansion occurs on the average of three days

In all cases of spontaneous pneumothorax with more than minimal collapse we advocate the third method of treatment Yore and Morgan,[5] Hughes and his associates,[2] and others[1,3] have had excellent results with the closed thoracotomy treatment It is time saving for both the patient and his physician Because the lung expands rapidly (three days or less), the patient is able to leave the hospital and return to work sooner The physician can perform a closed thoracotomy more rapidly than he can do a thoracentesis and air aspiration In addition, it is comforting for him to know that the water sealed drainage is a safety valve preventing tension pneumothorax

Closed drainage prevents other complications [illegible] complications Empyema occurs when there is a persistent air space which eventually becomes infected or when a bronchopleural fistula remains open with continuous soiling of the pleural space with tracheobronchial pathogens

In all cases of spontaneous pneumothorax a small bronchopleural fistula exists In some instances if the lung is not expanded, the fistula will remain open Rapid expansion causes the pleural surfaces to be opposed, thereby sealing the leak If a pneumothorax is present over a long time, with or without a bronchopleural fistula a non-expandable or 'captive' lung may result Its treatment of course, is decortication *either with enzymes or by surgical* means Had the lung been rapidly expanded, this would not have occurred

The technic of establishing catheter drainage [illegible] the equipment (Fig 1) It includes a trocar, catheter scalpel syringe hypodermic needles, tissue forceps, mosquito forceps medicine glass procaine, needle holder, needles silk and a few sponges The skin subcutaneous tissue and pleura over the second or third intercostal space in mid-clavicular line are infiltrated with procaine A small transverse incision just *large enough to accommodate* the trocar and cannula is made The trocar and cannula are then plunged into the pleural space the trocar withdrawn and the catheter passed into the pleural space through the cannula (Fig 2) The cannula is then withdrawn over the catheter and the catheter sutured to the skin The catheter is then attached to the water sealed bottle, and a dry dressing is applied around the catheter and over the wounds

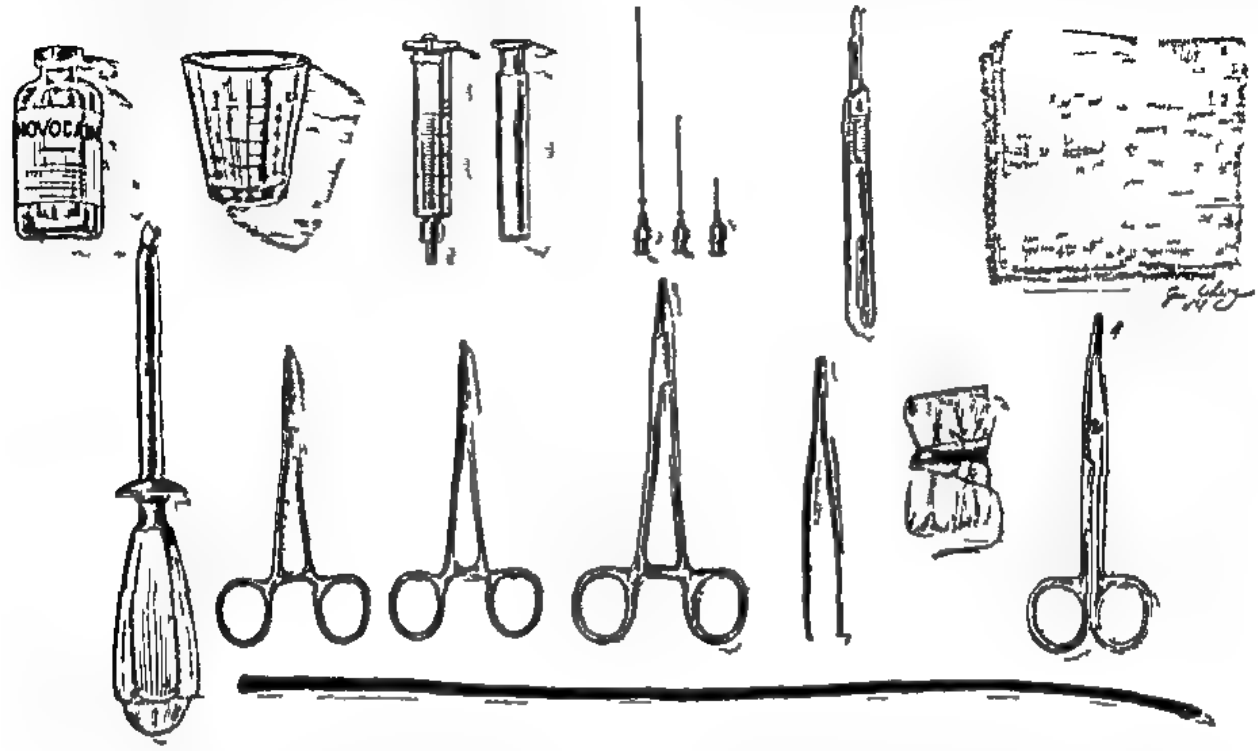

FIG 1 Necessary equipment for insertion of the intercostal catheter

The water sealed bottle acts as a check valve allowing air to escape during coughing or expiration but no air returns during inspiration Negative pressure is established within the *pleural space, and under most circumstances* the lung expands rapidly (Fig 3) In event the bronchopleural fistula is large gentle suction may be applied to the water sealed bottle, so that air is withdrawn from the pleural space more rapidly than it can escape into the space through the fistula

This same general plan of treatment is very effective in traumatic pneumothorax where it is of equal importance to obtain rapid re expansion of the lung

As long as the water sealed bottle fluctuates and air escapes through it it is functioning and is allowed to remain When no more air escapes [illegible] is cut and the catheter withdrawn It is unnecessary to suture the catheter hole in the skin *Vaseline gauze placed over the* wound will



FIG 2 After infiltration with novocain and a small skin incision on the trocar and cannula are introduced to the free pleural space bracing the guiding hand against the chest wall to prevent trocar from plunging too deeply The catheter (usually 18 F) is inserted through the cannula The catheter is fixed at the chest wall and the cannula withdrawn over it

prevent air from re entering the pleural space X rays and the presence of breath sounds on the affected side are of value in determining whether or not the lung is re expanded

A possible disadvantage of the closed thora cotomy is the development of empyema as a result of placing a catheter in the pleural space This did not occur in our series [1] The probable reason is that antibiotics were given in generous amounts and with rapid expansion of the lung there was no potential space to become infected

FIG 3 Schema of water seal system in place The connection of the tubing to the underwater glass tube should be double-checked Fluctuation should be visible in the glass tube

SUMMARY

Spontaneous pneumothorax is usually due to a ruptured emphysematous bleb Ordinarily it comes on during normal activities and is not necessarily associated with pulmonary tuberculosis It is always accompanied by symptoms either pain in the chest or dyspnea and is present it is suggested that closed thoracotomy catheter water seal drainage be established immediately This method of treatment is advocated because it is simple and time saving both for the patient and for the doctor If there is a tension pneumothorax it may be life saving Further it tends to prevent other complications from spontaneous pneumothorax which are empyema persistent bronchopleural fistula and captive lung

REFERENCES

1 BRIGGS J N WALTERS R W and BYRON F X Spontaneous pneumothorax *Dis of Ches* 24 564 1953
2 HUGHES T A KRAEFT N H and LOWRY C C Treatment of idiopathic spontaneous pneumothorax *J A M A* 146 244 1951
3 KIRCHER, T., JR. and SWARTZEL, R L. Spontaneous pneumothorax and its treatment *J A M A* 155 24 1954
4 WILSON J L. Spontaneous pneumothorax *Internal Clin* 1 157 1937
5 YORE, R W and MORGAN T H Spontaneous pneumothorax aggressive treatment *Bull Mason Clin* 7 1 1953

106

Surgical Considerations in Decortication

PAUL C SAMSON, M D, *Oakland, California*

ONE of the important advances in thoracic surgery during World War II was the rediscovery, remodeling and reapplication of "decortication"[4] In its narrowest medical sense, pulmonary decortication denotes only the stripping of a pathologic peel, cortex, fibroblastic membrane or rind from an essentially normal surface, the pleura Since 1945 this concept has been extended to a variety of pathologic conditions and has included the development of some new surgical technics These will be reviewed in the present chapter

The history of decortication up to World War II has been adequately covered elsewhere[2, 9] and repetition would be superfluous except for emphasis on basically important points Suffice it to say that Fowler (1893)[7] and Delorme (1894)[8] first reported the principle of the operation independently although the word "decortication" apparently was not employed until 1896 and then by Delorme[6]

Both Fowler and Delorme recognized the process of fibroplasia within the thorax and the essential normalcy of the pleura, yet the mistaken idea of "thickened pleura" repeatedly found its way into the literature While the correct pathologic condition was recognized by a number of individuals throughout the years, the concept of thickened pleura has also remained even to the present, both in a medical dictionary where decortication is defined as "the removal of the pleura for the relief of empyema," and in a recent French surgical volume by Iselin[10]

With few exceptions, notably Lilienthal,[16] nearly all the original decortications were attempted on patients with chronic pleural disease Several types of procedures were employed and results were uniformly poor by present day standards These facts led to a virtual abandonment of the operation as a routine procedure This has happened to other major surgical advances, discovered perhaps, too far ahead of complementary specialties for a successful outcome

In the early days of World War II the mass effect of large numbers of soldiers with organizing and infected hemothoraces once more focused attention on the inevitable crippling and chronic invalidism resulting from these complications, attention which had rather waned between the wars This time, however, decortication was shortly reborn The time was ripe Blood replacement with blood became routine, anesthetic methods had improved, thoracic surgeons were intrepid and frequently were entering the thorax in the early stages of certain diseases, antibiotics were soon to appear, although I emphasize that only the sulfas were available in 1943 when the pioneering decortications were performed

Apparently the spark was first generated by extended discussions among thoracic surgeons of the Second Auxiliary Surgical Group early in the African campaign The first planned decortication was for an uninfected organizing hemothorax, performed by Burford in May, 1943[12] This operation was shortly followed by many others at the earliest overseas Thoracic Center and in September, 1943, I first demonstrated the feasibility of applying decortication to a totally collapsed lung complicated by massive post-traumatic empyema[23] In this patient, an Italian Captain prisoner of war, there was prompt pulmonary re-expansion and primary healing in spite of the fact that the operation was performed through a completely infected field It was inevitable that the news of successful operations such as these should travel widely, and, as so often happens, independent observations also were made During the latter part of the War and in the early civilian years, the American and English literature alone contained independent

as well as supplementary contributions by many surgeons [1–3 11 12 15 20 26 28 29 32]

By 1946 it was obvious that surgeons should think of applying the successful technics learned under the stress of combat to conditions and diseases more closely identified with civilian life The extension of indications for decortication, however, has been built entirely upon its complete success in the treatment of the complications of hemothorax and is predicated on certain fundamental responses of the pleurae and pleural cavity to insult and injury Probably these can be best understood by a brief review of the pathogenesis of hemo-organization We still cannot explain the vagaries of the clotting mechanism as applied to free blood in the pleural cavity but the progression of organization has been followed microscopically on numerous occasions

PATHOGENESIS OF HEMO-ORGANIZATION

Hemo organization begins with the laying down of a thin film of fibrin and blood cells over both pleural surfaces A closed sac or envelope is shortly formed, the "inner" surface of which is bathed by the liquid and coagulated elements of the hemothorax and the "outer" surface loosely adherent to the pleurae Within seven days there is microscopic evidence of angioblastic and fibroblastic proliferation in this thickening layer The process is first visible extending into the walls of the envelope from both pleural surfaces The peel increases in thickness through the progressive organization of the clotted blood which becomes attached to the inside of the envelope The advancing inner border of active organization remains composed of young cellular tissue and wandering fibroblasts occasionally can be seen

Within four weeks adult fibrous tissue can be seen forming the outer portion of the peel with the fibers and nuclei arranging themselves roughly parallel to the outer surface Most of the capillaries appear to extend into the peel at right angles to the surface, having obviously penetrated from the pleurae The parietal segment of the peel is always thicker than the visceral, a still unexplained finding Within eight weeks small arterioles with recognizable smooth muscle and elastic fibrils can be demonstrated in the outer or older portion of the peel Microscopic calcium particles may be deposited in the peel within three or four weeks and this has not always been a response to infection In some cases layers of fat cells have developed in the peel along the older or pleural surface, this may be a regressive process, a forewarning of eventual degeneration or resorption of the peel In rare cases the peel may develop complete fibrous tissue union with the pleura which then loses its identity as a delimiting membrane I suspect that these are cases in which there is disease of the underlying lung

That the pleura itself does not become thickened requires continued reemphasis For the most part, it remains a translucent elastic membrane The occasional microscopic finding of pleural edema or a slight increase in subpleural connective tissue cannot be translated in radiologic terms The term "thickened pleura" as used by many radiologists and others should be discarded The complete incorrectness of this concept is obvious from the microscopic study of many decorticates of differing ages and from the knowledge of cleavage planes developed through extensive operative experience For instance, thin, wavy elastic fibers are characteristically found immediately beneath the visceral pleura but are never seen in a resected peel unless the visceral pleura is knowingly taken with the peel and sectioned This is well illustrated in Lindskog and Liebow[17] although I do not agree with their concept that a thickened subpleural areolar tissue will seal the alveoli If the visceral pleura is removed, inevitably there is air leakage In older peels, short curled elastic fibers may be found in the walls of the intrinsic arterioles These findings are at complete variance with the description of Williams's pathologist who purported to show numerous elastic fibers in the peel itself[31] This simply does not occur

The development of pyogenic infection in the central fluid of the hemothorax seems to speed the process of organization and, in some instances, to make the peel tougher but there is no qualitative change which can be recognized microscopically Continuing experience with the formation of peels associated with either a pyogenic or a specific infection confirms that the microscopic evidence of these infections is always found on the inner surface of the peel In the case of pyogenic infection, the fibrin and blood clot which is in the process

of organization shows infiltration with polymorphonuclear leukocytes In tuberculosis, for example, the epithelioid reaction, the giant cells, and/or evidence of caseation necrosis is only found along the youngest and most cellular (inner) surface of the peel I have never seen diffuse infiltration of the peel by any tissue reaction which could be recognized as characteristically tuberculous

During the war years it was common belief that there was some peculiar property of blood or blood clot which was responsible for the formation of the fibroblastic membrane It is now known that this is a function of the pleurae, activated by a number of exciting agents in addition to blood The peel may develop in response to pyogenic infections, specific infections (tuberculosis and coccidioidomycosis), transudates from heart failure non infectious inflammatory exudates (virus chylothorax, chemical irritation), pneumothorax with or without clinical fluid, "dry pleurisy," and neoplastic effusion Thick or thin, the fully developed membrane in each case is composed of adult fibrous tissue relatively poor both in nuclei and in blood supply It is an inelastic membrane which keeps the lung compressed and immobilized In all intrapleural cortices the outer portions and the pleural "surface" of the envelope are basically the same as in organizing hemothorax i e, there seems to be a fundamental substrate, a common reaction of the pleura to irritation, to inflammation or to actual infection It thus becomes obvious that decortication is only possible because all these changes are essentially within the confines of the interpleural space Since the pleura is not ordinarily affected, a cleavage plane can be developed

It is probable that the process of organization continues as long as fluid or air is present but ceases and remains relatively static when the envelope becomes obliterated While the appearance of fat cells is thought to be a retrogressive process, these have been seen only in young peels and there is little evidence that adult scar tissue (the mature fibrous membrane) ever disappears from the pleural cavity

Much of the success of decortication depends upon the condition of the lung rather than on the length of time the peel has been present Continuing pulmonary disease means some degree of parenchymal damage and greater cellular intimacy between pleura and peel, consequently decortication may be more difficult and pulmonary expansion delayed It is probable that this is responsible for more decortication failures than any other single factor Prompt, complete obliteration of the pleural space is our best insurance against both the renewal of pulmonary collapse and original or recurring empyema

INDICATIONS FOR DECORTICATION

It is difficult to give more than very general indications when considering the various types of disease in which decortication may be used

Organizing Hemothorax and Its Complications One must first briefly consider the newer chemical decorticants which have been more or less popular in the past few years, namely, SK-SD and tryptar® Fibrinolysing agents have been moderately successful where the peel was composed either of fibrin or of relatively young tissue While these agents have enjoyed a certain vogue, they have been all but discarded by a number of physicians[30] Many patients have had severe febrile reactions following injection and good results have not been universal Enzymatic debridement has almost always failed when used in more chronic situations in which the peel is composed of adult scar tissue

In uninfected organizing hemothorax decortication may be considered in from three to five weeks under the following circumstances Granted lack of enthusiasm for the injection of enzymes, decortication should be performed in a patient who has continuing thoracic discomfort, radiologic evidence of a hazy chest, a compression of 25 per cent or more of the lung with a collapsed apex, and retraction or narrowing of the interspaces If infection supervenes in the organizing hemothorax, I recommend decortication as soon after infection is evident as the patient can be made a reasonable operative risk Under these circumstances the operation becomes much more emergent than in an uninfected case In infected organizing hemothorax, any degree of pulmonary compression, particularly if the apex is collapsed would call for immediate surgical intervention

Post traumatic or Hemothoracic Empyema Of course, if the patient had been followed carefully, decortication should have been

decided upon long before gross pus became evident in the pleural cavity If however one is presented with such a patient decortication should be performed as soon as the patient becomes suitable for major surgery The indications would include a pocket of more than 300 cc any degree of apical depression and any presumption that there is a foreign body in the chest In these days of multiple antibiotics sensitivity tests should be undertaken prior to surgery so that the patient has his best chance to be protected against invasive infection The presence of a clostridial empyema (frequent in war rare in civilian life) would make no difference as to the treatment The decision as to the necessity for preliminary rib resection drainage rests entirely upon the condition of the patient If he can be made a sufficiently good risk by means of the usual supportive therapy primary decortication should be undertaken[2] and preliminary drainage is then not only unnecessary but also unwise Most often patients with acute and subacute empyemas can be sufficiently improved without preliminary drainage Occasionally in a patient with chronic empyema wasting and debilitation stop gap external drainage may be necessary prior to decortication

Finally there is the problem of the old neglected fibrothorax with or without calcification A symptomatic thoracogenic scoliosis may be present Even at this late date decortication may be indicated It is possible to remove a cuirass of calcium which will give better function to the chest wall and which may well allow subsequent corrective surgical therapy for the scoliosis [13]

Miscellaneous Pyogenic Infections Indications for decortication in these cases are not quite as clear cut as in hemothorax Primary decortication is not indicated in smaller empyemas with expanded pulmonary apex our medical confrères have cured many of these by aspiration lavage and the injection of the proper antibiotic The time honored method of adequate dependent rib resection drainage is likewise almost a certain cure for the usual posterior and lateral pocket On the other hand one may be faced with a massive empyema and chronic subtotal collapse of the lung or with a smaller empyema unobliterated even by adequate drainage In such patients supportive therapy plus early decortication will give a high percentage of cures [14, 15] Decortication should shortly follow the decision (regardless of how long this is delayed) that the lung will not expand under the regimen being used

Miscellaneous Irritative or Inflammatory Effusions This group covers such varied diagnoses as postviral pleural fluid effusions of unknown etiology evanescent leakage without infection from a neighboring viscus such as stomach esophagus or liver and chylothorax In the past effusions of this sort have been treated most often by repeated aspiration with the acceptance of pleural scar and immobile thorax or by drainage if a pyogenic infection supervened after multiple thoracenteses There is no doubt that decortication is frequently indicated in this type of pleural inflammatory reaction Continuing experience with these irritative exudates has shown that a peel may develop relatively soon often within a week or two If it becomes evident that pulmonary re expansion obliteration of the pleural cavity and restoration of good respiratory function will be impossible under conservative management decortication becomes urgently indicated as an early procedure

The development of a neoplastic effusion may rarely be an indication for exploratory operation with decortication and/or parietal pleurectomy When the diagnosis is known thoracotomy may still be undertaken because of the increasing difficulties of frequent aspirations In such cases it has been found that the lung is tied down by a non specific fibrinous sheet whereas the parietal pleural element of the peel is composed primarily of shaggy neoplasm In several such instances we have performed decortication of the visceral pleura and a subtotal parietal pleurectomy not of course for cure but in an effort to do away with difficult and painful thoracenteses In two cases of pleural lymphoma with effusion this goal has been achieved

DECORTICATION IN PULMONARY TUBERCULOSIS

Apparently Gurd s report caused a renewal of enthusiasm for decortication in tuberculosis [9] Mulvihill [10] Weinberg[11] and others[14, 15] added important technical contributions The invaluable protection afforded by streptomycin and other antituberculosis drugs against invasive infection and spread in tuberculosis cannot be overestimated [24] Assuming stable surgical technics these agents given on a

long term basis have made decortication in tuberculosis safe A combination of operations is frequent Thus decorticaton may be the main procedure, it may share importance with thoracoplasty and/or resection, or it may even be a relatively minor maneuver accompanying lobectomy

In tuberculosis the pre-existing conditions of the underlying lung and bronchi are of prime importance in a decision for or against decortication [25] Therefore, wherever possible, serial x rays of the chest must be reviewed including those prior to pneumothorax or pneumoperitoneum Preoperative bronchoscopy is mandatory Knowledge of extensive though healed tuberculosis or of bronchial stenosis (each suggesting a poor re expansion potential) may not contraindicate an advisable decortication but it would counsel the necessity for a concomitant thoracoplasty to reduce the size of the pleural space

Both tuberculous pleura effusion and primary empyema have been followed by static lung compression For all practical purposes, the lung must be considered normal and, therefore, expandable Hence decortication is indicated An effective pneumothorax may be complicated by the development of a peel and a non-expandable lung Fluid may persist or increase due to the development of high negative pressures when attempting to expand the lung Empyema may develop Decortication is frequently very useful under these circumstances often combined with resection and/or a small tailoring thoracoplasty depending on the condition of the underlying lung The alternative procedure, with which we were all too familiar in the past, is an extensive deforming thoracoplasty Ineffectual pneumothoraces with pleural complications are still occasionally seen and here again decortication (almost always combined with resection) appears the procedure of choice There is a fairly large group of cases in which decortication is now being performed almost casually as an accompaniment of resection In these, due either to a former pneumothorax, dry pleurisy or what not, there has developed a thin, translucent but inelastic glove over the remaining lobes This must be removed else the remaining lobes will expand poorly and the success of the resection will become thereby jeopardized

Finally, there remain a few patients whose lungs were captive because of a constricting peel and who obliterated a pneumothorax space more by mediastinal and cardiac shift than by pulmonary re-expansion Some of these patients complain of dyspnea tachycardia and thoracic discomfort or actual pain Poor respiratory excursions are obvious In one patient a heart murmur developed, apparently the result of cardiac torsion Selected individuals in this limited group can be helped greatly by thoracotomy and total removal of the scar which has immobilized the lung and the thoracic parieties

TECHNICS OF PULMONARY DECORTICATION

Many factors including developmental contributions, have caused variations in the performance of this operation The age of the peel, the presence or absence of infection, the condition of the underlying lung and whether or not appreciable pulmonary or chest wall surgery was envisioned also have been important determinants Perhaps the actual technic employed is not as important as the remembrance of the basic aim to be accomplished complete emancipation of the lung

The incision has become fairly standard a posterior and lateral thoracotomy of generous length Personally, I prefer to remove a rib because I believe that a more secure chest wall closure can be performed There seems to be no object in making a fetish of an intercostal incision In general, fine non-absorbable suture material is used throughout If raw lung tissue needs to be repaired, I use fine catgut on an atraumatic needle Electrocautery is a great time saver and is always at hand

In what might be termed the simplest or basic type of case, that of organizing hemothorax, the interior of the envelope is entered directly by incision through the parietal pleural segment The central contents together with all shaggy detritus are evacuated Sharp incision is made through the visceral segment of the peel and by combined dissection, the cleavage plane between peel and pleura is identified Frequently this can be aided by slight positive pressure through the anesthetic bag As one carries this dissection from the visceral on to the parietal peel, an obliterated space can be entered where the

recognition of this plane and the ease with

which it is developed that prompted the technical contributions of Williams[32] and of Paulson[21] They tend to enter this space first and re expand the lung from the hilum outward, as it were, saving the removal of the visceral peel to the last Once the lung is freed down to the hilum, any infoldings of the lobes are rectified as emphasized by Langston and Tuttle[18] The fissures are opened, patches of older membrane not removed by the primary decortication are either peeled off, or subjected to discission In the meantime the anesthetist has given intermittent and progressive positive pressure so that by the end of the operation in favorable cases, the lung practically fills the thoracic cavity This seems to be a better way of obtaining re-expansion than attempting it all at once by unduly high endobronchial pressures The diaphragm is freed and decorticated insofar as possible and the costophrenic sulcus is reconstituted In these simple cases, I have usually not attempted parietal decortication as the results do not appear appreciably bettered There is no absolute objection to the removal of the parietal peel, but it does not always seem to be necessary It does increase the operating time and the bleeding It is important that all pockets be opened The parietal membrane must be smooth and should be thoroughly scraped When established infection is present, however, our technic differs and routinely the parietal peel is removed This is most often done following visceral decortication (1) to give the patient the benefit of better aeration as soon as possible, (2) to insure pulmonary re-expansion even if the operation has to be abruptly terminated

As stressed early by Weinberg[31] and others, when peel and empyema are chronic such as typified in long-standing tuberculous infection, it is attempted to remove the envelope completely without opening it or spilling the contents It is surprising how often this can be accomplished even after twenty years I am convinced, however, that on the chest wall side the parietal pleura is removed with the peel most of the time—a fact not generally appreciated Actually I do a parietal pleurectomy from preference because the cleavage plane is more easily developed extrapleurally than it is between pleura and peel and there is much less chance of breaking into the envelope These operations are very time-consuming and it is advisable to have a great deal of blood on hand The critical point of such an operation employing pleurectomy is recognition of the exact line where the two pleurae themselves come into apposition When the line is reached, further extrapleural dissection is unnecessary The cleavage plane should be changed from extrapleural to interpleural and the hilar structures identified and freed One can then come back on the visceral pleural surface and, by degrees, complete a true decortication When the technic is successful, a bag filled with pus may be totally removed from the thoracic cavity without leakage of contents The advantages, particularly in tuberculous infections, are obvious A natural extension of this means of treating chronic empyema is the technic of Sarot[27] in which the extrapleural separation is carried to the hilum and pneumonectomy performed Thus a badly damaged lung and an extensive empyema can be eviscerated en masse without spillage

The technic of the "casual" decortication which may be associated with lobectomy is not difficult The important point is to recognize that a thin, non-opaque peel is present and that such a peel is relatively inelastic It is amazing how tough fibered such peels are and it is highly gratifying to note the improvement of re-expansion following their removal The proper cleavage plane is identified after meticulous incision of the peel with the lung supported by moderate positive pressure Small blunt gauze or cotton dissectors will uncover glistening visceral pleura covered with meniscule punctate hemorrhages from the divided vessels entering the peel If an air leak develops, the visceral pleural is being dissected with the peel

Air leaks are inevitable in most decortications and for the most part can be ignored If they are troublesome or if on expansion the amount of leakage seems unduly great, the area of parenchymal denudation may be either patched by spare peel or the edges approximated by continuous fine catgut Postoperative adequate drainage is mandatory and two forty-caliber right angle tubes have been found useful Rarely a third tube may be necessary A simple water seal system is employed and it is only in the presence of undue air leakage that increased negative suction is applied

The postoperative treatment differs in no way from other major thoracotomies Rigorous

arm and shoulder exercises are instituted early as are Harken's remedial breathing exercises.

CONCOMITANT OPERATIONS

As indicated throughout this report decortication may necessarily be combined with other operations. If there are chest wall wounds these should be excised and closed with separate instruments prior to making the main thoracotomy incision. The handling of sinus tracks previously established for the drainage of an empyema has varied. In the case of endocutaneous flaps of the Lloesser type (frequently used in mixed infection tuberculous empyemas) an elliptic incision has been made with removal of skin and the subcutaneous portion of the track down to the ribs. With further dissection between the ribs a flap has been folded in and sutured to be removed with the empyema sac at later thoracotomy. Muscle and skin are then closed over the area. Gowns gloves and instruments discarded and the thoracotomy incision made with a new set up. Dependent tube drainage smuses may well be left alone and the same track used for the insertion of the postdecortication drainage tube. Necessary work on the inner portion of the chest wall for rib spicules etc. or the removal of foreign bodies from the lungs must await the completion of decortication tissue relationships can then be more accurately assessed and foreign bodies palpated.

The exact order of the concomitant operations most often employed in tuberculosis depends upon what is considered to be the main pathologic disorder. In cases of empyema or unexpanded lung decortication would be the primary operation. On the other hand resection of some type may be proceeded with first and decortication of varying degree then acts as a supplemental operation. Usually the decision for or against a tailoring thoracoplasty is delayed until it is seen whether pulmonary re expansion is adequate following decortication and/or resection.

SUMMARY

The history of pulmonary decortication particularly during and since World War II has been briefly reviewed. It has been noted that within the past ten years decortication has been employed in a variety of pathologic conditions. This has necessitated certain variations of surgical technic.

The pathogenesis of hemo-organization has been described. The formation of a mature peel in organizing hemothorax and in other pathologic states of the pleurae has been discussed. It has been emphasized that the development of a peel or fibroblastic membrane is a function of the pleurae and is in response to a number of exciting causes.

Indications for, and differing technics of decortication have been listed in the following morbid conditions: organizing hemothorax with or without infection, pyogenic empyemas of varying etiologies, specific pleural infections such as tuberculosis and coccidioidomycosis, persisting pneumothorax, either transudates or exudates arising from a variety of irritative, inflammatory or chemical sources, neoplastic effusions.

REFERENCES

1. Blades, B. and Dugan, D. J. War wounds of the chest. J. Thoracic Surg. 13: 294, 1944.
2. Burford, T. H. Parker, E. F. and Samson, P. C. Early pulmonary decortication in the treatment of posttraumatic empyema. Ann. Surg. 122: 163, 1945.
3. Chamberlain, J. M. In discussion Samson and Burford.
4. Churchill, E. D. The surgical management of the wounded in the Mediterranean theatre at the time of the fall of Rome. Ann. Surg. 120: 268, 1944.
5. Delorme, E. Nouveau traitement des empyèmes chroniques. Gaz. d. hôp. Par. 67: 94, 1894.
6. Delorme, E. Du traitement des empyèmes chroniques par la décortication du poumon. 10 ième Congrès Français de Chirurgie, 1896, p. 379.
7. Fowler, G. R. A case of thoracoplasty for the removal of a large cicatricial fibrous growth from the interior of the chest, the result of an old empyema. M. Rec. 44: 838, 1893.
8. Gurd, F. B. Decortication in chronic empyema of tuberculous origin. J. Thoracic Surg. 16: 587, 1947.
9. Harken, D. E. A review of the activities of the thoracic center for the III and IV hospital groups European theatre of operations. J. Thoracic Surg. 15: 31, 1946. Quoted in Gurd.
10. Iselin, M. Certain aspects of battle wounds of the thoracic cavity. Surgery, 20: 26, 1946.
11. Johnson, J. War injuries of the chest. Surg. Gynec. & Obst. 82: 13, 1946.
12. Kay, E. B. and Meade, R. H. Pleural decortication in the prevention and treatment of thoracogenic scoliosis. Arch. Surg. 61: 705, 1950.
13. Kergin, F. G. and Dewar, F. P. Decortication in the treatment of tuberculous empyema. Arch. Surg. 56: 1, 1948.
14. Lam, C. R.

15 LANGSTON, H T and TUTTLE, W M The pathology of chronic traumatic hemothorax *J Thoracic Surg*, 16 99, 1947
16 LILIENTHAL, H Empyema *Ann Surg* 62 309, 1915
17 LINDSKOG, G E and LIEBOW, A A Thoracic Surgery and Related Pathology, p 7 New York, 1953, Appleton Century Crofts Inc
18 MULVIHILL, D A and KLOPSTOCK, R Decortication of the nonexpandable postpneumothorax tuberculous lung *J Thoracic Surg*, 17 723, 1948 See also discussion of Gurd [8]
19 O ROURKE P V O BRIEN E J and TUTTLE, W M Decortication of the lung in patients with pulmonary tuberculosis *Am Rev Tuberc*, 59 30, 1949
20 PARKER E F and BURFORD, T H Pulmonary decortication in the treatment of early pyogenic empyema *Surgery*, 24 371, 1948
21 PAULSON D L In discussion of Samson and Burford [22]
22 SAMSON P C and BURFORD, T H Total pulmonary decortication *J Thoracic Surg*, 16 127, 1947
23 SAMSON P C, BURFORD, T H, BREWER, L A and BURBANK, B The management of war wounds of the chest in a base center *J Thoracic Surg*, 15 1, 1946
24 SAMSON, P C The prophylactic administration of streptomycin before and after major thoracic surgical operations *Am Rev Tuberc*, 58 38, 1948
25 SAMSON, P C Decortication in pulmonary tuberculosis *Tuberculology*, 12 142, 1951
26 SANGER, P W Decortication in acute empyema thoracis *Surg, Gynec & Obst*, 82 71, 1946
27 SAROT, I A Extrapleural pneumonectomy and pleurectomy in pulmonary tuberculosis *Thorax*, 4 173, 1949
28 SOMMER G N J and MILLS W O Hemothorax and empyema in a thoracic center *J Thoracic Surg*, 16 154 1947
29 TUTTLE, W M, LANGSTON, H T, and CROWLEY R T The treatment of organizing hemothorax by pulmonary decortication *J Thoracic Surg*, 16 117, 1947
30 VALLE A R Management of war wounds of the chest *J Thoracic Surg*, 24 457, 1952
31 WEINBERG, J and DAVIS, J D Pleural decortication in pulmonary tuberculosis *Am Rev Tuberc*, 60 288 1949, decortication of the unexpanded tuberculous lung following pneumothorax *J Thoracic Surg*, 18 363 1949
32 WILLIAMS, M H The technique of pulmonary decortication and pleurolysis *J Thoracic Surg* 20 652 1950

Pleuropulmonary Resection—Excision of Chronic Empyema

IRVING ARTHUR SAROT, M D, *New York, New York*

PLEURAL involvement is a frequent complication of pulmonary malignancies, suppuration or tuberculosis Until quite recently pulmonary resection was often unfeasible because the surgeon could not overcome the serious technical problems occasioned by the presence of dense and widespread pleuropulmonary adhesions (pleural symphysis) or empyema

In tuberculosis particularly, and in chronic pulmonary suppurations the difficulties in resection caused by the presence of pleural symphysis served for many years to keep pulmonary extirpation from achieving its present acceptance as a form of therapy Not infrequently operations which had been begun to remove a lung had to be abandoned because the lung could not be separated from the chest wall, or the operations were so prolonged by dissection through dense adhesions and manipulation of the lung so great that operative shock was frequent, anesthetic difficulties due to spillage of secretions common and postoperative spreads of disease not unusual Rupture of adherent cavity walls and incision of diseased parenchyma or pleura were frequent sources of contamination

A second limiting factor was the tenet that pleural infection or empyema was a contraindication to pulmonary resection [1] Many patients with pulmonary disease suitable for such treatment were denied resection because empyema was present In other cases excisional procedures already begun were not completed because of the unexpected operative finding of an empyema

Although Tuffier[30] as early as 1913 had successfully resected the tuberculous apex of a lung extrapleurally, and Fowler[9] in 1901 had noted the importance of removing the entire diseased pleura in empyema, these isolated observations were ignored because of a universal reluctance to damage or remove the parietal pleura surgically This reluctance was based on the accepted belief[11] that under no circumstances should the parietal pleura be removed, especially in tuberculosis, since its removal would permit the spread of infection to tissues beyond

THE EXTRAPLEURAL APPROACH[22 23]

Extrapleural dissection in lobectomy and pneumonectomy has made it possible to circumvent the difficulties occasioned by dense and [illegible] are exposed in a region relatively uninvolved by disease The connective tissues about the bronchus and the pulmonary vessels in the mediastinum are not usually involved to any great degree by the inflammatory processes of the lung and pleura

The extrapleural approach to the hilus for pneumonectomy avoids difficult dissection through matted nodes since the greatest degree of lymph node involvement in inflammatory states is usually at the bifurcation of the main bronchus, distal to the region in which the bronchus is exposed The infratracheal nodes and the peribronchial nodes of the main bronchus usually separate from the bronchus quite easily if the peribronchial connective tissue sheath is incised and the bronchus freed within it The division of the bronchus at the carina, the suturing of the proximal end and the ligation of the vessels are achieved in an unobstructed and clean field The lung with the adherent pleura, or if empyema is present, with the entire empyema sac, is then freed by extrapleural dissection and removed

The widest application of the technic of extrapleural resection has been in pulmonary tuberculosis[22] in which cases with complete pleural symphysis or empyema, previously

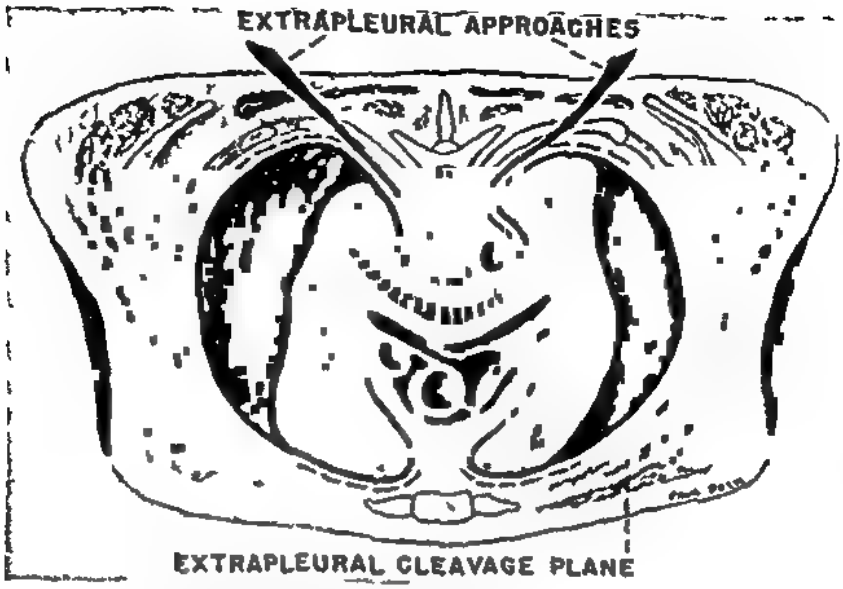

FIG 1 Diagrammatic sketch illustrating the posterior extrapleural approach (By courtesy of the Editors of *Thorax* and the British Medical Association [11])

considered inoperable, have become suitable for resection (Fig 2) Tuberculous or mixed infection empyema with or without bronchopleural fistula, previously a most difficult condition to control or cure, especially when complicated by underlying active pulmonary tuberculosis, can now be treated successfully by extrapleural pulmonary resection and pleurectomy with a mortality and morbidity rate no greater than that in resection for extensive but uncomplicated pulmonary tuberculosis [24] Extrapleural resection has thus become

proving results

Extrapleural resection is applicable to non tuberculous disease [25] Many surgeons have reported the freeing of very adherent portions of the lung by limited extrapleural dissection as a matter of convenience at the moment However, it has not been recognized generally that this should be the procedure of choice When the extrapleural procedure is planned and developed primarily, tedious and often dangerous intrapleural dissection of adherent lung is avoided Since, as already mentioned, the mediastinal aspect of the lung and the mediastinal pleura are relatively uninvolved in extensive inflammatory processes of the lung and costal and diaphragmatic pleura, it is usually possible to approach the hilus extrapleurally with ease even in cases in which the entire lung is destroyed by chronic abscesses or bronchiectasis This permits the bronchus to be clamped early in the operative procedure, lessening the danger of bronchial dissemination of infected secretions After the hilar structures are divided, the lung can be freed with less danger of hemorrhage

Circumscribed carcinomas of the lung may be of the "parenchymal" type entirely within

tinum [6] The former type usually has a pseudocapsule about it, is not invasive locally, but may, when it involves the surface of the lung, be densely adherent to the regional parietal pleura Such a tumor may be resected conveniently with the adherent pleura by extrapleural resection When circumscribed carcinoma of the peripherally invasive type involves parietes which are resectable, the involved chest wall and adherent and adjacent pleura must be resected *en bloc* with the neoplasm and lung If during the surgical exploration of a case of carcinoma of the lung the lung is found to be densely adherent to the parietal pleura, it may be freed and the hilar structures exposed more safely and easily by extrapleural dissection than by attempting to separate the lung from the parietal pleura

Metastatic pleural involvement from underlying pulmonary carcinoma occurs frequently, and the presence of pleural effusion containing

FIG 2 Lung destroyed by tuberculosis with bronchopleural fistula and empyema pleuropneumonectomy A lateral view empyema has been opened to demonstrate bronchopleural fistula B mediastinal aspect shows characteristic sharp delineation of pleural thickening and relative uninvolvement of mediastinal pleura C cut surface

carcinoma cells is considered a contraindication to resection by most surgeons However, in suitable cases the pleura and lung may be removed as a palliative measure Even when the diaphragm is intrinsically involved, the reaccumulation of fluid in the thoracic cavity abates when the parietal pleura has been removed and, aided by the addition of cobalt or radioactive gold therapy, some palliation may be obtained Cotton[4] has added hemidiaphragmectomy in such cases He has also reported successful pleuropneumonectomy in pleuropulmonary involvement by higher bacteria

THE ROLE OF THE PLEURA

As the scope of application of pleuropulmonary resection has been broadened in the treatment of pulmonary and pleural inflammatory and neoplastic processes, it has been inevitable

that concepts and ideas previously accepted should be re-examined

Tchertkoff and Selikoff[79] first pointed out that extrapleural resection which began as a technical convenience achieved a greater effect by removing the parietal pleura This membrane has no useful function after pneumonectomy its removal eliminates its great reactive and secretory power and any residual foci of pleural infection from which empyema may develop if the pleura is permitted to remain The pleura is sensitive to infection responding to contamination with exudation and in tuberculosis with caseation and empyema In contrast the extrapleural tissues which line the thoracic cavity after the parietal pleura has been removed are relatively resistant to infection and respond to contamination with productive changes rather than empyema Contamination of the operative field from rupture into a tuberculous cavity or from incision through densely adherent tuberculous tissue or suppurating lung is largely eliminated in extrapleural dissection Rupture into an empyema (when present) occurs frequently but such contamination is less likely to be followed by empyema after the pleura has been removed

When thoracostomy and cavernostomy openings and empyema necessitatis and other sinus tracts are transected during intrapleural pneumonectomy empyema or wound infection is invited despite antibiotics In contrast when they are removed *en bloc* during pleuropulmonary resection empyema and prolonged wound infection are less likely to result

Bronchopleural fistula is still the most dangerous postoperative complication following pneumonectomy Other than residual malignant disease and tuberculous or other intrinsic disease in the stump of the resected bronchus the two factors which seem to act to cause such fistulas are postoperative local infection or the presence of a long bronchial stump which is prevented from retracting into the mediastinum by adhesions to the pleura and to the extrapleural connective tissues It is probable that the lesser incidence of clinically evident bronchopleural fistula following extrapleural dissections is due in part to the reduced incidence of infection and empyema after pleurectomy and also to the greater ease with which a high bronchial amputation close to the carina can be obtained A short bronchial stump freed from the surrounding hilar and extrapleural fascia retracts into the mediastinum and is covered promptly by the adjacent tissues Stemmermann Daniels and Auerbach[73] have recently stressed the role of local infection in the pathogenesis of postpneumonectomy bronchial fistula

During an extrapleural dissection one may encounter extensive fibrosis in the extrapleural apical tissues and must guard against damage to the large vessels Policard and Galy[18] have studied the many layers in the extrapleural fascia and have demonstrated well our operative finding that one does not always dissect in the same cleavage layer In fact on occasion it is necessary to dissect extrafascially when dense inflammatory reaction has sealed the extrapleural tissue planes Great difficulty may arise during the dissection from the inferior vena cava on the right side and during the dissection from the diaphragm Usually the hilar structures are severed and the apical and mediastinal dissection completed before the diaphragmatic dissection is begun The cleavage plane between an empyema wall or the diseased lung and the diaphragm is often difficult to enter Policard and Galy[18] and others have shown that the diaphragmatic pleura differs from the other portions of the parietal pleura in that the deep fibroelastic layer is intimately connected with the muscle

A cleavage plane can be developed and the diaphragm identified more easily after it has been paralyzed by interruption of the phrenic nerve The diaphragmatic cleavage plane can always be entered more easily from the mediastinal aspect where there is less pleural involvement than if dissection is begun in the costophrenic sulcus where the adhesions are usually more severe

PLEUROPULMONARY RESECTION AFTER THORACOPLASTY FAILURE

After thoracoplasty (and possibly Schede resection) has failed in the treatment of empyema associated with perforated pulmonary abscess bronchiectasis or tuberculosis because [illegible] of ronic [illegible] tion [illegible] the lung when an intrapleural dissection is impos

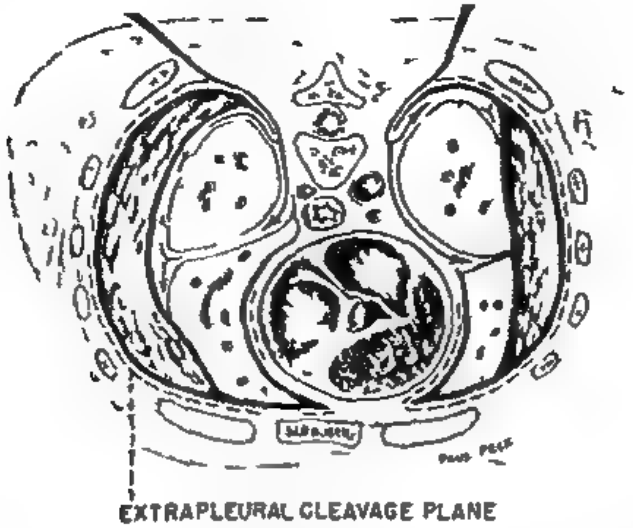

FIG 3 By courtesy of the Editors of *Thorax* and the British Medical Association [15]

sible technically or fraught with the danger of infection due to operative rupture of the diseased lung or incomplete removal of diseased pleura and lung

In tuberculosis the results of treatment of residual cavities by revision operations have been disappointing [10 15] The success achieved by resection of the diseased lung in these cases is particularly gratifying The antecedent thoracoplasty may render the extrapleural excision more difficult technically but the postoperative course of these cases is notably benign

Usually the scar of the previous thoracoplasty is excised the uppermost intact rib below the thoracoplasty is resected paravertebrally and the extrapleural plane entered through its bed The regenerated bony plate above is cut paravertebrally and lifted away by a rib spreader as the underlying lung is stripped from it extrapleurally or even extrafascially to lessen the risk of opening into a cavity or diseased lung

The extrapleural dissection is continued to the hilus in the usual manner and the main bronchus and vessels are divided if the preoperative indication has been definitely for pneumonectomy If the extent of the disease permits partial excision of the lung is possible The mediastinal (parietal) pleura which has been freed is incised and the proper cleavage plane between parietal and visceral pleura is entered In tuberculosis usually and in other inflammatory conditions frequently the mediastinal regions of the interlobar fissures are less involved in the inflammatory processes and adhesions less pronounced Therefore these fissures may be entered here more easily and the lobes separated Lobectomy and even segmental resection are facilitated (Fig 3) Densely adherent upper lobes especially those containing large cavities close to the surface are freed more easily if the dissection is done extrapleurally The densely adherent pleura should be removed with the lobe or segment, but the less adherent and adjacent pleura may be permitted to remain after lobectomy or segmentectomy to exercise its absorptive and gliding functions to aid in the prompt re expansion of the remaining lung The lobar [illegible] aids in exposing the right upper lobe bronchus and the apical branch of the pulmonary artery

The average intrapleural pneumonectomy requires about 2 000 to 2 500 cc. of blood during and immediately after operation A difficult extrapleural resection may require two to three times as much but this disadvantage of greater blood loss is more than compensated for by the other advantages of the extrapleural approach

PLEUROPULMONARY RESECTION FOR CHRONIC PULMONARY DISEASE WITH EMPYEMA

The beneficial effects of isoniazid in tuberculosis (in combination with streptomycin and

FIG 4 Tuberculous right upper lobe resected extrapleurally with chronic tuberculous empyema

PAS) have been demonstrated universally since its introduction into clinical use in 1952 Because of this new chemotherapeutic agent many formerly accepted concepts of treatment are in the process of revision and surgery is being withheld perhaps wrongly in some patients with pulmonary cavities but persistently negative sputum Only further time and study will clarify this problem

The concomitant decline in pneumothorax therapy has acted to make empyema a less frequent and pressing problem Greater attention is again being given to the treatment of empyema by injection of chemotherapeutic agents and antibiotics and by repeated aspirations Trypsin or varidase® controlled by an intercostal tube drain may facilitate rapid re-expansion of the lung in early empyema especially if no bronchopleural fistula is present If resection becomes necessary after the lung has been re-expanded the pleura should be resected with the lung to avoid subsequent empyema from residual foci of pleural infection

Siddons and Konstam[17] have recently reviewed a series of cases of tuberculous empyema (treated before isoniazid was available) and have reported the good results of careful and complete aspiration therapy However they stress the importance of prompt surgical intervention when a patent pulmonary cavity bronchopleural fistula or unexpandable lung is present These are the same indications which have been presented previously[21] for pleuropulmonary resection in such cases

Spontaneous perforation of the lung in a patient not yet under chemotherapy for acute tuberculosis need no longer carry with it the lethal significance of former years and early tube drainage may suffice to tide the patient over the acute phase of tension pneumothorax The lung may re-expand rapidly to obliterate the pleural space while chemotherapy controls the disease and helps the fistula to heal In some cases the patient may not even run a significantly febrile course and the external wound may heal without excision

Despite chemotherapy perforation secondary to badly managed pneumothorax or pneumonolysis still leads to empyema spontaneous perforation does still occur although less often in patients under adequate chemotherapy resulting in severe empyema with or without persistent bronchopleural fistula The indication for prompt total or partial pulmonary resection and pleurectomy still exists in such cases to save lives and shorten the duration of the disease Despite the extremely beneficial effect of chemotherapy patients who are not doing well must not be permitted to wait too long before active surgical measures are applied for if such cases become chronic despite intensive chemotherapy the outlook is worse

Prior to the introduction of pleuropneumonectomy[19 20] the disappointing results obtained by all forms of surgical collapse therapy for uncontrolled pulmonary tuberculosis complicated by tuberculous empyema (with or without bronchopleural fistula) were part of the experience of every thoracic surgeon One could not fail to be impressed even in the successful cases by the further permanent collapse of healthy lung and by the long period of surgical treatment that these patients suffered yielding only meager results with much misery and deformity Early mortality ran higher than 60 per cent in some series and cures were obtained in less than 15 per cent[7] These results were the final products of drainage subsequent complete thoracoplasty Schede or Keller resections of the infected parietal (costal) pleura and where necessary plastic operations such as muscle-flap transplants to close the persistent bronchopleural fistula The disaster which followed so fre-

5A 5B 5C

FIG 5 Excised empyema A visceral aspect B cut surface C, parietal aspect Tubercle bacilli were found in smear of pus but did not grow in culture or guinea p g

quently was inherent in each case by virtue of the underlying disease which remained to contaminate the surgical field and to destroy the transplanted tissues Even if the bronchopleural fistula healed caseating infected pleura and visceral wall of empyema remained after Schede thoracoplasty and was a persistent cause of dissolution and ultimate non healing of the wounds

Analysis of all available experience with thoracoplasty in the treatment of uncontrolled pulmonary tuberculosis complicated by empyema indicates that the failure of this approach is due to several unavoidable deficiencies (1) multiple operative procedures with increased opportunity for operative mortality (2) prolonged duration of treatment inviting mortality from tuberculous spreads toxemia and exhaustion and amyloidosis (3) failure to control the underlying lung disease (4) the deleterious effect on wound healing of the residuum of infected caseating pleura and (5) the frequent inability to control the bronchopleural fistula Therefore any procedure designed to meet the problem of uncontrolled pulmonary tuberculosis and empyema must be (1) single stage (2) of short over all duration and (3) must control the underlying lung disease the *infected caseous pleura and the bronchopleural* fistula (if one is present) It is apparent that in order to cure a patient with uncontrolled pulmonary tuberculosis and a tuberculous or mixed infection empyema one must accomplish the removal *en masse* of the underlying diseased lung the bronchopleural fistula (if one is present) and the entire empyema including the infected caseating parietal pleura Pleuropneumonectomy fulfills these requisites Its variations pleurolobectomy (Fig 4) and pleurosegmentectomy (partial pulmonary resection with excision of empyema) provide a means of excising the diseased lung and pleura while preserving and restoring to function the non diseased parts of the lung in contrast to the usual effect of thoracoplasty

In cases of limited involvement of the lung under an empyema the extent of the disease cannot always be determined accurately by even the best methods before operation By the extrapleural procedure with entry through the incision in the mediastinal pleura into the interlobar fissures and the cleavage plane between visceral pleura and parietal pleura or empyema visceral wall the lobes can be freed more easily and decortication is facilitated (Fig 3) Lung tissue which is palpably free of

FIG 4 Tuberculous right upper lobe resected extra pleurally with chronic tuberculous empyema

PAS) have been demonstrated universally since its introduction into clinical use in 1952 Because of this new chemotherapeutic agent many formerly accepted concepts of treatment are in the process of revision and surgery is being withheld, perhaps wrongly, in some patients with pulmonary cavities but persistently negative sputum Only further time and study will clarify this problem

The concomitant decline in pneumothorax therapy has acted to make empyema a less *frequent and pressing problem Greater atten* tion is again being given to the treatment of empyema by injection of chemotherapeutic

expansion of the lung in early empyema, especially if no bronchopleural fistula is present If resection becomes necessary after the lung has been re-expanded, the pleura should be resected with the lung to avoid subsequent empyema from residual foci of pleural infection

Siddons and Konstam[17] have recently reviewed a series of cases of tuberculous empyema (treated before isoniazid was available) and have reported the good results of careful and complete aspiration therapy However, they stress the importance of prompt surgical intervention when a patent pulmonary cavity, bronchopleural fistula or unexpandable lung is present These are the same indications which have been presented previously[21] for pleuropulmonary resection in such cases

Spontaneous perforation of the lung in a patient not yet under chemotherapy for acute tuberculosis need no longer carry with it the lethal *significance of former years and early* tube drainage may suffice to tide the patient over the acute phase of tension pneumothorax The lung may re-expand rapidly to obliterate the pleural space while chemotherapy controls the disease and helps the fistula to heal In some cases the patient may not even run a significantly febrile course and the external wound may heal without excision

Despite chemotherapy, perforation secondary to badly managed pneumothorax or pneumonolysis still leads to empyema, spontaneous perforation does still occur, although less often in patients under adequate chemotherapy, resulting in severe empyema with or without persistent bronchopleural fistula The indication for prompt total or partial pulmonary resection and pleurectomy still exists in such cases to save lives and shorten the duration of the disease Despite the extremely beneficial effect of chemotherapy, patients who are not doing well must not be permitted to wait too long before active surgical measures are applied for if such cases become chronic despite intensive chemotherapy the outlook is worse

Prior to the introduction of pleuropneumonectomy[19 20] the disappointing results obtained by all forms of surgical collapse therapy *for uncontrolled pulmonary tuberculosis* complicated by tuberculous empyema (with or without bronchopleural fistula) were part of the experience of every thoracic surgeon One could not fail to be impressed, even in the successful cases, by the further permanent collapse of healthy lung and by the long period of surgical treatment that these patients suffered, yielding only meager results with much misery and deformity Early mortality ran higher than 60 per cent in some series and cures were obtained in less than 15 per cent[7] These results were the final products of drainage, subsequent complete thoracoplasty, Schede or Keller resections of the infected parietal (costal) pleura and, where necessary plastic operations such as muscle-flap transplants to close the persistent bronchopleural fistula The disaster which followed so fre-

5A 5B 5C

FIG 5 Excised empyema A visceral aspect B cut surface, C, parietal aspect Tubercle bacilli were found in smear of pus but did not grow in culture or guinea pig

quently was inherent in each case by virtue of the underlying disease which remained to contaminate the surgical field and to destroy the transplanted tissues Even if the bronchopleural fistula healed, caseating infected pleura and visceral wall of empyema remained after Schede thoracoplasty and was a persistent cause of dissolution and ultimate non healing of the wounds.

Analysis of all available experience with thoracoplasty in the treatment of uncontrolled pulmonary tuberculosis complicated by empyema indicates that the failure of this approach is due to several unavoidable deficiencies (1) multiple operative procedures with increased opportunity for operative mortality, (2) prolonged duration of treatment inviting mortality from tuberculous spreads, toxemia and exhaustion, and amyloidosis, (3) failure to control the underlying lung disease, (4) the deleterious effect on wound healing of the residuum of infected caseating pleura, and (5) the frequent inability to control the bronchopleural fistula Therefore any procedure designed to meet the problem of uncontrolled pulmonary tuberculosis and empyema must be (1) single stage, (2) of short over-all duration, and (3) must control the underlying lung disease, the

monary tuberculosis and a tuberculous or mixed infection empyema one must accomplish the removal en masse of the underlying diseased lung the bronchopleural fistula (if one is present) and the entire empyema including the infected caseating parietal pleura Pleuropneumonectomy fulfills these requisites Its variations, pleurolobectomy (Fig 4) and pleurosegmentectomy (partial pulmonary resection with excision of empyema), provide a means of excising the diseased lung and pleura

ction the

ntrast to

the lung

under an empyema the extent of the disease cannot always be determined accurately by even the best methods before operation By the extrapleural procedure with entry through the incision in the mediastinal pleura into the interlobar fissures and the cleavage plane between visceral pleura and parietal pleura or empyema visceral wall, the lobes can be freed more easily and decortication is facilitated (Fig 3) Lung tissue which is palpably free of

6A 6B 6C

FIG 6A B and C Chron c empyema with no evidence of residual pulmonary d sease preoperative views

6D 6E

FIG 6D and E Same case Appearance of chest following excis on of the empy ema in Figure 5

disease and which expands well when inflated by the anesthetist after being *easily* decorticated should be conserved Its prosthetic value in filling the hemithorax outweighs any possible subsequent demonstration of reduced function by spirometry A lobe or segment which is not readily decorticated or which will not expand easily is undoubtedly the seat of chronic fibrosis or disease continuous with the pleural involvement In non tuberculous conditions it may be safe to leave such a portion of lung with its adherent pleura while resecting other parts however in tuberculosis the surgeon must be prepared to resect such questionably diseased lung tissue Overconservatism on the part of surgeons in the resection of such doubtful areas has probably been a major factor in some of the poor results from decortication Decortication alone is not often advisable in tuberculosis except in unusual cases in which there is gross pleural thickening following effusion with little pulmonary disease[5,21]

Occasional cases of encysted chronic empyema tuberculous (Fig 5) or non tuberculous are encountered with no demonstrable residual pulmonary disease Such an empyema may be resected through an intercostal incision by extrapleural dissection beyond the limits of the thickened parietal pleura Entry into the pleural space is gained by incising the parietal pleura beyond the area of thickening surrounding the empyema and the lung is separated from the internal wall of the empyema which is then removed frequently intact (Fig 6) Such a procedure is preferable to prolonged drainage and possibly multiple rib resection to close the space

The results reported previously[4] of three years' experience with pleuropulmonary resec

of the patients were restored to health Further statistics of our cases will be reported in the

pyema by pleuropulmonary resection and have agreed that this procedure is usually to be preferred for such cases except in rare and special instances Thoracoplasty may be indicated (1) if in a case of pulmonary disease controlled by extensive previous thoracoplasty a basal empyema should occur recur or persist and the possibility of re-expanding the lung does not exist because the chest cage has been collapsed, or because of the extent of the previously active pulmonary disease re-expansion should be undesirable (2) if a case presents a laterally placed single small cavity (less than 5 cm diameter) in an adherent and expanded upper lobe without much pleural thickening over the upper lobe a basal empyema without bronchopleural fistula and nodular disease is present in the lower lobe to an extent which would preclude leaving it after upper lobectomy but which may heal after thoracoplasty

Since the advent in the past two decades of the sulfa drugs penicillin and other antibiotics chronic pulmonary suppurations have become much less frequent However, cases are seen of severe suppuration in the lung with empyema secondary to bronchial carcinoma or other obstructing lesions Such patients suffer most from the fever and cachexia due to the infection Palliation may be achieved in cases of malignancy, and cure in benign conditions by pleuropulmonary resection Other types of chronic lung abscess and bronchiectasis may be complicated by pleural infection and this difficult combination is usually best treated in the same manner When however an older or debilitated individual has localized empyema secondary to mild or asymptomatic bronchiectasis especially if this is widespread or bilateral and pulmonary or cardiac function is poor drainage and thoracoplasty may be preferable even if permanent drainage openings persist in the scar

SUMMARY

In cases of combined pleural and pulmonary disease it is usually not adequate to deal with the pleura without treating the underlying lung The technic of extrapleural dissection makes it possible for both components to be treated simultaneously and permits the fulfillment of the surgical principle of complete excision of the disease in many types of cases in which it was previously not possible to accomplish this desirable effect Not only is resection facilitated but also complications are minimized This has been clearly shown in tuberculosis as well as in non tuberculous disease

REFERENCES

1 BAILEY C P Pulmonary Resection for Tuberculosis in Diagnosis and Management of the Thoracic Patient p 1 Philadelphia 1945 J B Lippincott Co

2 BERARD M and JUTTIN P Les interventions d exerese dans le traitement de la pleurisie purulente tuberculeuse *Le Poumon* 7 197 1951

3 BICKFORD H J EDWARDS F R ESPLEN J R GIFFORD J G and THOMAS O F A further report on lung resection for tuberculosis Thorax 7 310 1952

4 COTTON H and PENINO J Pleuropulmonary resection with hemidiaphragmectomy *J Thoracic Surg* 22 474 1951

5 D ABREU A L A Practice of Thoracic Surgery p 257 London 1953 Edward Arnold & Co

6 DAEMS J and PANNIER R Pleuropneumonectomy in the treatment of tuberculous empyema *Dis of Chest* 22 193 1952

7 DAVIDSON L R Mixed infection empyema *Quart Bull Sea View Hosp* 6 382 1941

8 EDITORIAL Decortication in pulmonary tuberculosis *Lancet* 1 34 1954

9 FOWLER G R Decortication of the lung for chronic empyema *N Engl J Med* 78 933 1901

10 HOCHBERG L A FINK, I and DENIZE A Revision thoracoplasty study of 80 cases *Quart Bull Sea View Hosp* 8 205 1936

11 LILIENTHAL, H Thoracic Surgery 2nd ed p 13 New York 1925 W B Saunders Co

12 LLOYD M S and NACLERIO E A Combined resection of the lung and parietal pleura in the treatment of pulmonary suppuration and empyema *New York State J Med* 49 1293 1949

13 MATHEY J OUSERIERES G and BICAL R Traitement des pyothorax tuberculeux chroniques par les operations d exérese pleurale et pulmonaire *Le Poumon* 9 503 1951

14 MATHEY J Indications et resultats de la decortication dans le traitement de l empyeme tuberculeux *Arch chir belg* 6 523 1952

15 [illegible]

16 NEUHOF H RABIN C B and SABOT J A A topographic classification of cancer of the lung with special reference to the surgical implications of the circumscribed variety *J Thoracic Surg* 11 388 1942

17 OVERHOLT, R H, WILSON, N J and GEHRIG, L. J The place of pulmonary resection in the treatment of tuberculosis *Dis of Chest*, 21 32, 1952

18 POLICARD, A and GALY, P La Plèvre Paris, 1942 Masson et Cie

19 SAROT, I A and GILBERT, L Pneumonectomy, total pleurectomy and thoracoplasty for uncontrolled pulmonary tuberculosis with bronchopleural fistula and mixed infection empyema *Quart Bull, Sea View Hosp*, 9 183 1947

20 SAROT, I A and GILBERT, L Pneumonectomy, total pleurectomy and thoracoplasty for pulmonary tuberculosis and empyema in the presence of a contralateral pneumothorax *Quart Bull, Sea View Hosp*, 9 234, 1947

21 SAROT, I A Decortication and lobectomy for uncontrolled pulmonary tuberculosis with tuberculous empyema or unexpandable lung *Quart Bull, Sea View Hosp*, 10 47, 1948

22 SAROT, I A Extrapleural pneumonectomy and pleurectomy in pulmonary tuberculosis *Thorax*, 4 173, 1949

23 SAROT I A Extrapleural pulmonary resection (pleuropneumonectomy) *J Mt Sinai Hosp*, 17 700 1951

24 SAROT, I A Discussion of pathogenesis of bronchopleural fistula and paper by Stemmermann, G N, Daniels, C F and Auerbach, O *J. Thoracic Surg*, 22 409, 1951

25 SAROT, I A Discussion of pleuropulmonary resection and paper by Cotton, B and Penido, J *J Thoracic Surg*, 22 488, 1951.

26 SCANNELL, J G Medical progress thoracic surgery *New England J Med*, 247 843, 1952

27 SIDDONS, A H M and KONSTAM, M. L Treatment of tuberculous empyema by aspiration *Tubercle*, 32 85, 1951

28 STEMMERMANN, G N, DANIELS, C F and AUERBACH, O The pathogenesis of bronchopleural fistulas following excisional therapy for tuberculosis *J Thoracic Surg*, 22 392, 1951

29 TCHERTKOFF, I G and SELIKOFF, I J Role of the pleura in intra- and extrapleural pneumonectomy follow up of 77 consecutive cases *Quart Bull, Sea View Hosp*, 9 277, 1947

30 TUFFIER, M Decollement pleuro parietale in chirurgie pleuropulmonaire *Arch méd-chir de l'app respir*, 1 28, 1926

31 WATERMAN, D H and DOMM, S E Decortication of the unexpandable pneumothorax lung *Dis of Chest*, 19 1, 1951

108

Surgery of the Bronchi and Trachea

LYMAN A BREWER, III, M D AND ANGEL F BAI, M D, *Los Angeles, California*

SURGERY of the trachea and bronchi now have an important role in the management of diseases of the respiratory tract This surgery can be performed with a high degree of success by use of the viable pedicled pericardial fat graft devised by one of us (L A B) in 1949 [1] After a considerable clinical and experimental trial this living graft has proved to be just as effective in securing airtight tracheal or bronchial closure in pulmonary resections as has the abdominal omentum in gastrointestinal operations Encouraged by these successes this technic of bronchial reinforcement has been extended to plastic and excisional operations of the trachea and bronchi in order to effect a conservation of lung tissue During the past five years we have employed viable pedicled pericardial fat graft in 293 cases of bronchial division and closure and in twenty one cases of plastic or resection operations on the trachea or bronchi The technics employed and the results obtained in this combined series of 313 cases are reviewed

DEVELOPMENT OF THE VIABLE PERICARDIAL FAT GRAFT

The presence of the adipose tissue lying over the pericardium has received little attention in anatomy books for this tissue seemed to have no special function or surgical use If one studies this portion of the mediastinum, he will note that the pericardial fat pad or thoracic omentum is most prominent over the apex of the heart which is embraced by finger like projections (Fig 1) This adipose tissue, which is covered with mediastinal pleura, rests on the pericardium where it can be dissected free without damaging the blood supply The blood supply comes from the branches of the internal mammary and anastomosing trunks, from the pericardiophrenic and musculophrenic vessels Our present method of developing the pericardial fat graft is essentially the same as has been previously reported [1] By preserving the branches of the internal mammary artery the pericardial fat tissue extending down the cardiophrenic angle can be mobilized The blood supply will be conserved to the tip of this "thoracic omentum" by the anastomosing branches from the musculophrenic and pericardiophrenic arteries Adipose tissue extending anteriorly toward the midline, beneath the sternum, can be completely mobilized up to the branches of the internal mammary artery since there are no vessels coming from the midline Alternate methods of developing fat graft reinforcement[1] are found in the pericardial fat tissue extending upward to the superior mediastinum where the blood supply is less constant and less extensive Also, in cases in which the phrenic nerve is to be sacrificed the adipose tissue accompanying the nerve, although small in amount, has an excellent blood supply from the pericardiophrenic vessel

In our experience pleura, either free or pedicled, lymph nodes and areolar tissue do not provide satisfactory reinforcement of the bronchial closure Furthermore, in cases of bronchogenic carcinoma it is important to perform a very thorough resection of mediastinal lymph nodes and areolar tissue from the cervical region down to the diaphragm This leaves no tissue adjacent to the trachea or bronchial stump for reinforcement In cases in which partial pericardectomy is necessary to obtain satisfactory ligation of the pulmonary vessels, a huge pericardial defect may be present Herniation of the heart through this opening has resulted in fatal outcome due to improper cardiac filling The sling of the pericardial fat graft may be sewn to the pericardium to prevent cardiac displacement Care

must be taken to mobilize sufficient length of the graft to prevent constriction of the pulmonary vessels In the case of upper lobe or middle lobe resection it is possible to avoid vascular obstruction by placing the graft posterior to the pulmonary artery

insuring the patency of the airways, tends to pull apart the sutures used in closing the divided bronchus This characteristic of the bronchus was not considered important in the early days of mass ligation of the hilar structures. The sloughing of the ligated mass was

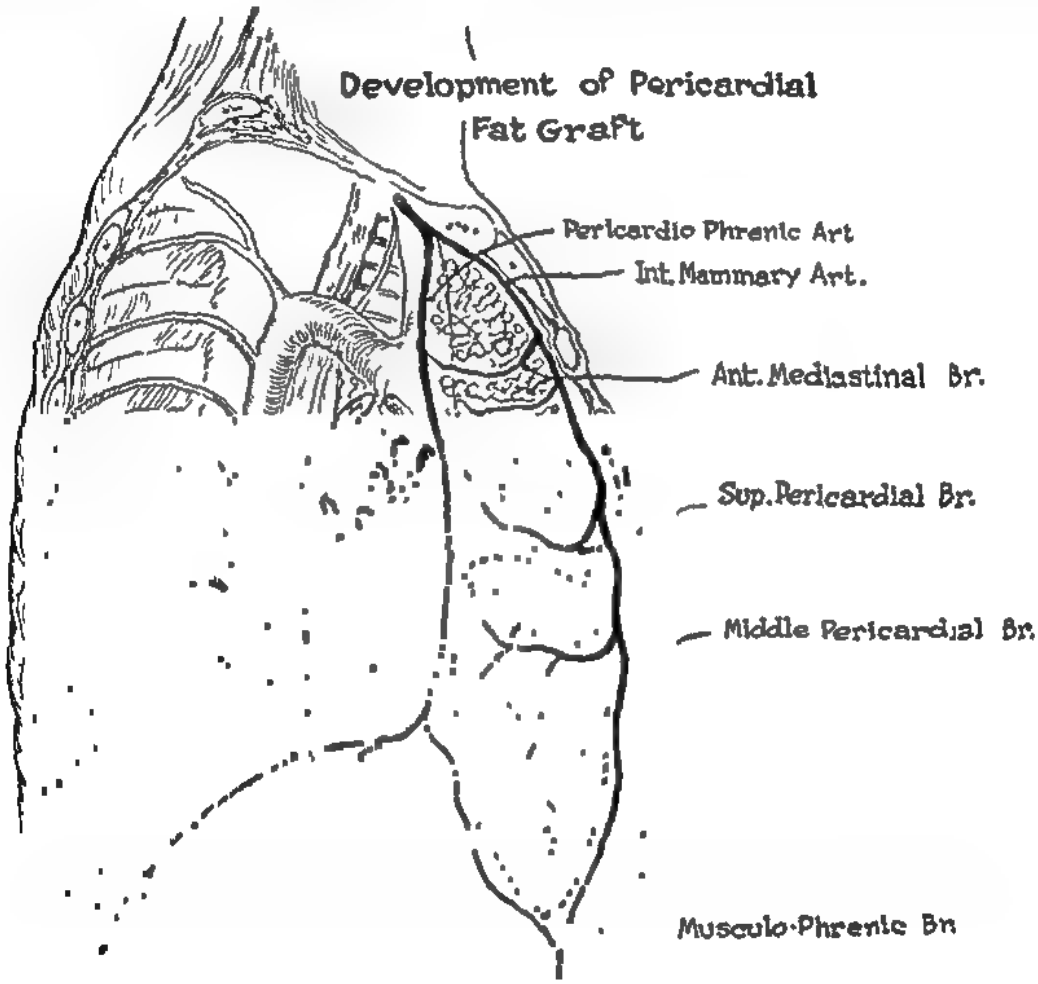

FIG 1 Pedicled pericardial fat graft is fashioned by dividing branches of musculophrenic and pericardiophrenic vessels Middle pericardial branch of internal mammary vessels provides adequate blood supply to graft

BRONCHIAL CLOSURE IN PULMONARY RESECTION

An understanding of the anatomy and function of the bronchi is important in effecting a *successful closure of the divided bronchus in* pulmonary resection. The bronchi are semirigid tubes whose function is to permit the passage of gases in and out of the lungs The spring-like action of the bronchial cartilage,

followed by bronchopleural fistula. Although the first successful lobectomy was performed before the turn of the century,[2] it was not until the individual ligation technic of the vessels and bronchi was developed for pulmonary resection[3-4] that bronchial closure became a precise surgical technic.

The technic that is most commonly reported

today is the division of the bronchus at right angles to the long axis and closure under varying degrees of tension with either interrupted or running sutures The authors' procedure consists of fashioning an oval shaped flap of the pliable posterior membranous portion of the bronchus and drawing this up to meet the rigid cartilaginous wall (Fig 2) This insures a closure without tension on the suture line To avoid trauma to the delicate bronchial mucosa no clamps are used and the bronchial vessels are preserved down to the point of division The bronchus is then alternately divided and sutured If excessive secretion is present in the trachea or bronchi, a catheter may be inserted into the open bronchus to aspirate this material directly Care must be exercised to prevent blood from entering into the bronchus before it is completely closed In suturing the bronchial stump the stitches should be about 3 mm deep and the same distance apart If tied too tightly, the sutures may cut through the bronchial wall so that the cut ends of the bronchus are only snugly approximated For the main bronchi we prefer the 0 007 tantalum wire, which is a strong non irritating suture When used with a swaged atraumatic needle, only a tiny hole is made in the bronchial wall, approximately the same diameter as the suture material The cut ends of the wire are turned in to prevent trauma to adjacent vessels Additional protection to the cut ends of the wire is offered by the pericardial fat graft For lobar bronchi where the cartilages are smaller, weaker and more irregularly developed, fine silk sutures are most often strong enough Furthermore, the chance of a wire suture perforating an adjacent pulmonary artery, particularly in upper and middle lobe resections, is obviated Care must be taken to preserve the bronchial arteries so the blood supply is maintained up to the bronchial stump Following the closure of the bronchial stump the suture line is tested by covering it with isotonic saline solution Positive pressure equivalent to that of hard coughing is applied by the anesthetist to the closed intratracheal system Any leaks in the suture line are readily apparent and can be closed quickly by the use of additional sutures The bronchial stump is now covered

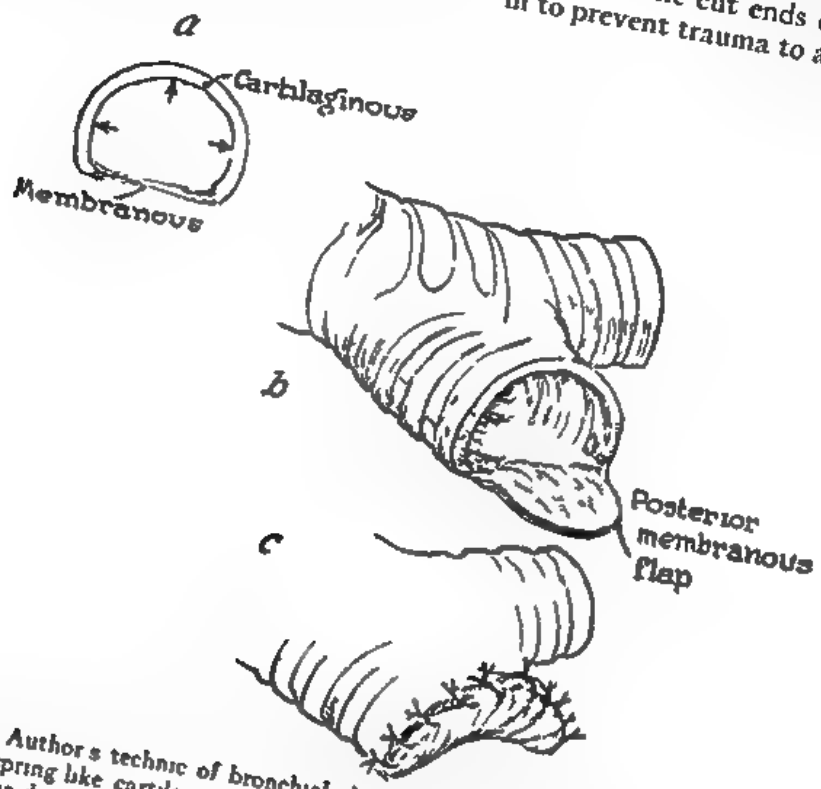

FIG 2 Author s technic of bronchial closure (a) Cross section of bronchus shows spring like cartilage and pliable but fragile membranous portion (b) Bronchus divided membranous flap developed (c) Membranous flap sutured to cartilaginous wall with interrupted sutures 3 mm apart and 3 mm deep

by the mobilized fat graft, fixed in place by at least four sutures placed equidistant around the circumference of the bronchus (Fig 3)

EXPERIMENTAL OBSERVATIONS WITH THE PEDICLED PERICARDIAL FAT GRAFT

In our original series of experimental animals the pedicled pericardial fat graft reinforcement

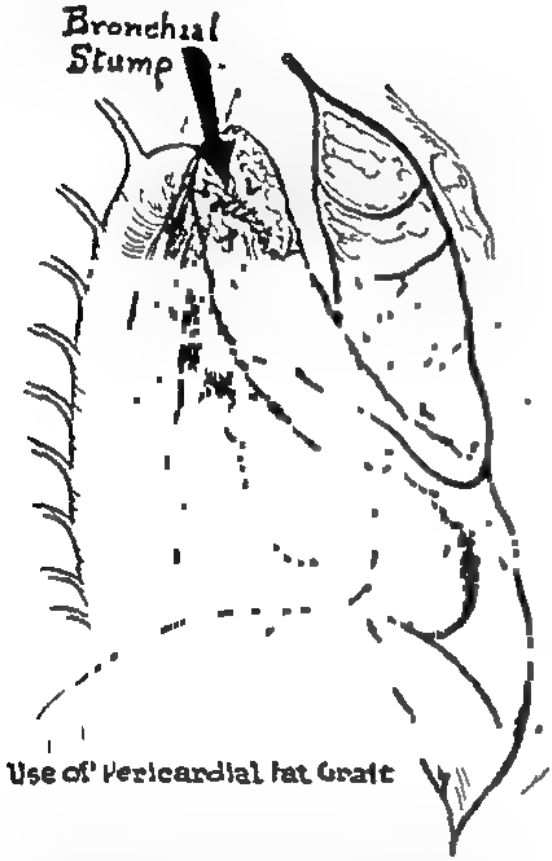

FIG 3 Fixation of the pedicled pericardial fat graft to the bronchial stump Four or more interrupted, fine silk sutures placed at equal intervals around the bronchus insure an airtight reinforcement

was used to cover over the incompletely closed bronchus in twenty-one dogs [1] In all instances the grafts were effective in sealing over these apertures and no bronchopleural fistula developed The blood supply to the pericardial fat graft is not as extensive in the dog as in the human being, and the amount of adipose tissue is less However, the grafts were found to be viable By the third day on microscopic section fibroblastic proliferation formed a permanent union with the fat graft and the bronchial stump In eight days columnar epithelium lined the defect filled by the graft By one month's time the portion of the fatty tissue next to the bronchus showed adult fibrous tissue, with some extension peripherally Slight increase in the fibrous tissue was found on observations up to one year Recently we have made an additional study of a series of nine dogs operated upon with the above technic in which the viability of the fat graft was observed for periods up to two years Results in this newer series confirmed that of the original group Grafts were viable and intact and effectively reinforced the incompletely closed bronchial stump in all instances No change in the microscopic appearance of the graft was noted in the second year

CLINICAL RESULTS IN PULMONARY RESECTION

We have employed the pedicled pericardial fat graft in 293 cases of total pneumonectomy or lobectomy The results of this larger series are very similar to those of our original report There have been no bronchial fistulas before the third week following operation This means that in no case was bronchial fistula a problem during the early critical postoperative period when the reopening of the bronchus can be a disasterous complication No patient died as a result of the bronchopleural fistula Thus, this [illegible] pleural fistulas after the third week and up to the seventh month of 2 0 per cent There is wide variance in the literature regarding the early incidence of bronchopleural fistula The average is, perhaps, from 8 to 15 per cent Late fistulas are generally not reported In all instances the late occurring bronchopleural fistulas in our series closed with simple drainage of the empyema, except where there was recurrent carcinoma in the bronchial stump Furthermore, in cases in which empyema developed the empyema was localized and the morbidity was not great

There have been three instances when an aspirating catheter has been passed inadvertently through the right bronchial stump following pneumonectomy during the first twenty-four hours after operation In all of these cases a portion of the trachea had been removed along with the right bronchus so that the bronchial stump was a continuation of the right lateral tracheal wall Leakage of air was sudden and profuse In less than one hour

marked subcutaneous emphysema was present which in one case involved subcutaneous tissues from scalp to scrotum The prompt insertion of a catheter in the second intercostal space which was connected to an underwater drainage system allowed for the escape of air coming out through the bronchial stump In each one of these cases the thoracic omentum had been used to reinforce the bronchial stump In each instance the leaking aperture sealed off in thirty six hours or less and there was an uneventful recovery Prior to the use of the pedicled pericardial fat graft we would have taken these patients to surgery to resuture a leaking bronchial stump during the early hours after operation

Bronchial fistula occurring six months after surgery probably develops on the basis of bronchial disease and peribronchial infection It is quite likely in the pneumonectomies that organisms close to the bronchial stump surrounded with fibrin and clot are thus amply protected from antibiotics placed in the pleural cavity following surgery After a period of time a loculated pleural abscess close to the end of the divided bronchus may erode through the line of closure and a fistula develops It is of considerable interest that we have had a number of cases of empyema following pneumonectomy in which the divided bronchus protected by the pedicled pericardial fat graft did not develop a bronchopleural fistula Table 1 shows cases of pulmonary resection in this series in which the thoracic omentum was used to reinforce the bronchial stump The operative mortality for this group was 2 5 per cent

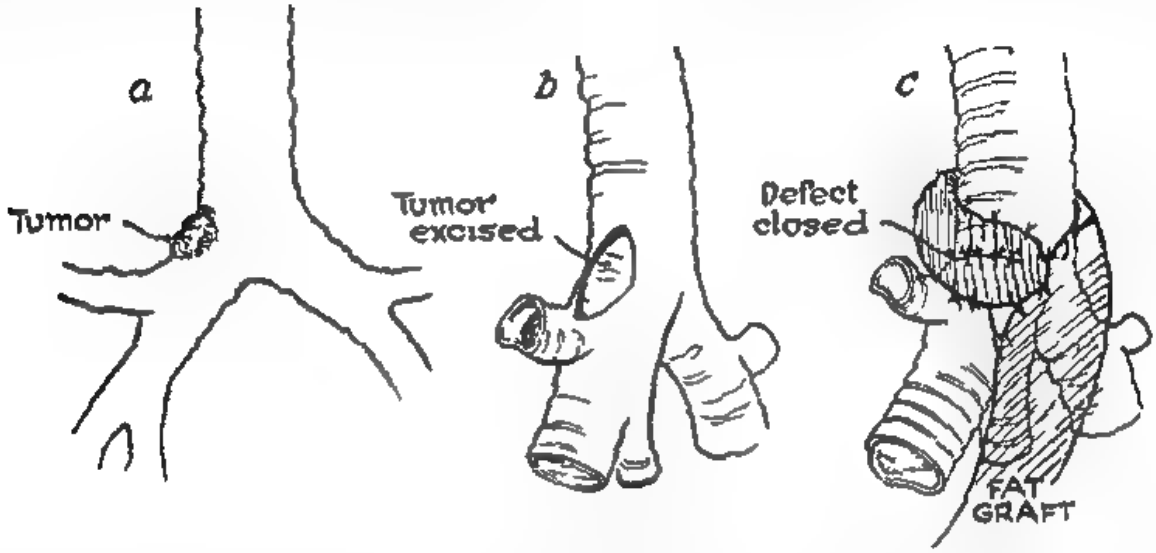

FIG 4 Case 1 Bronchotomy with excision of small bronchial adenoma (a) Adenoma of right upper lobe and main bronchus (b) Bronchial wall excised in longitudinal axis (c) Closure in transverse axis does not constrict lumen Graft of thoracic omentum seals off tiny apertures in closure

TECHNICS OF PLASTIC AND RESECTION PROCEDURES ON TRACHEA AND BRONCHI

Bronchotomy Bronchotomy and closure of the bronchus represents the simplest type of bronchoplastic operation which was successfully performed by Goeltz[6] and Eloesser[7] The bronchus may be opened at either longitudinal or transverse plane the pathologic process removed from the wall of the bronchus and small portions of the bronchus itself excised If a portion of the bronchial wall has been excised closure of the bronchus in the transverse plane usually will preserve the lumen of the bronchus and only shorten its length to a negligible amount (Fig 4) Of course if a larger portion of the bronchial wall is excised some sort of a bronchial replacement will have to be made In performing bronchotomy care must be taken so that the sutures do not pull together the walls of the bronchus and thus produce a stricture Furthermore if there is too much tension on the suture line the sutures will cut through and a fistula will certainly develop unless the graft of thoracic omentum has been used In our experience the pedicled

can be fashioned to reconstruct the bronchus or trachea following the removal of a lobe or lobes of the lung This is possible mainly in benign

bronchial conditions, as reported by Gebauer,[10] for it is rare that the surgeon would preserve a flap of bronchus close to malignant tumor. With this technic a tongue of bronchial wall is preserved and drawn up over the defect like a trap door to reconstruct the bronchus or trachea (Fig. 5). Thus, the airway may be maintained to the orifice of a lobe which would otherwise have to be resected. In a similar manner the tracheal airway may be maintained. We have used a single layer of interrupted sutures (either silk or tantalum wire) to make the anastomosis, which is then reinforced with the pedicled pericardial fat graft.

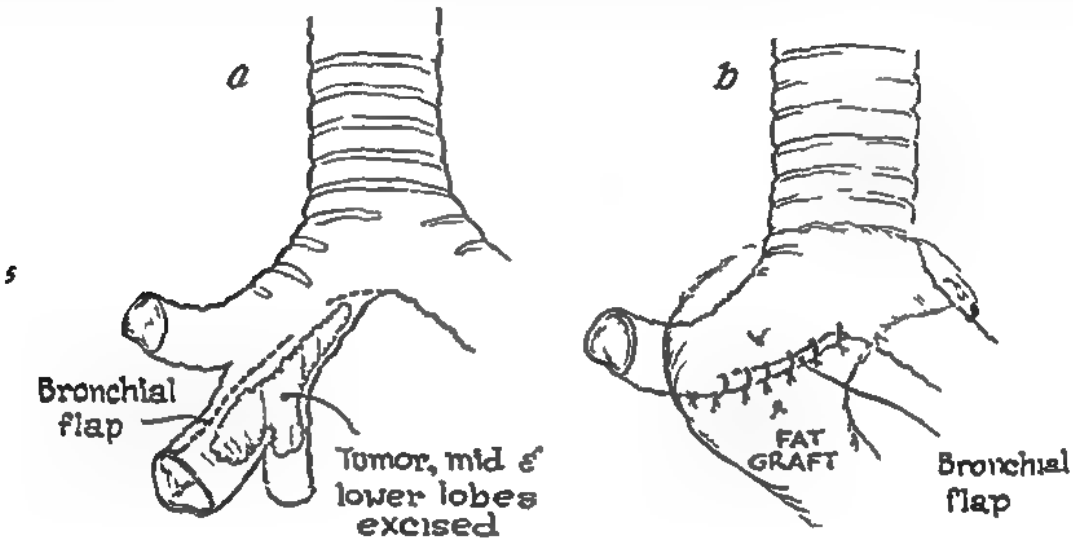

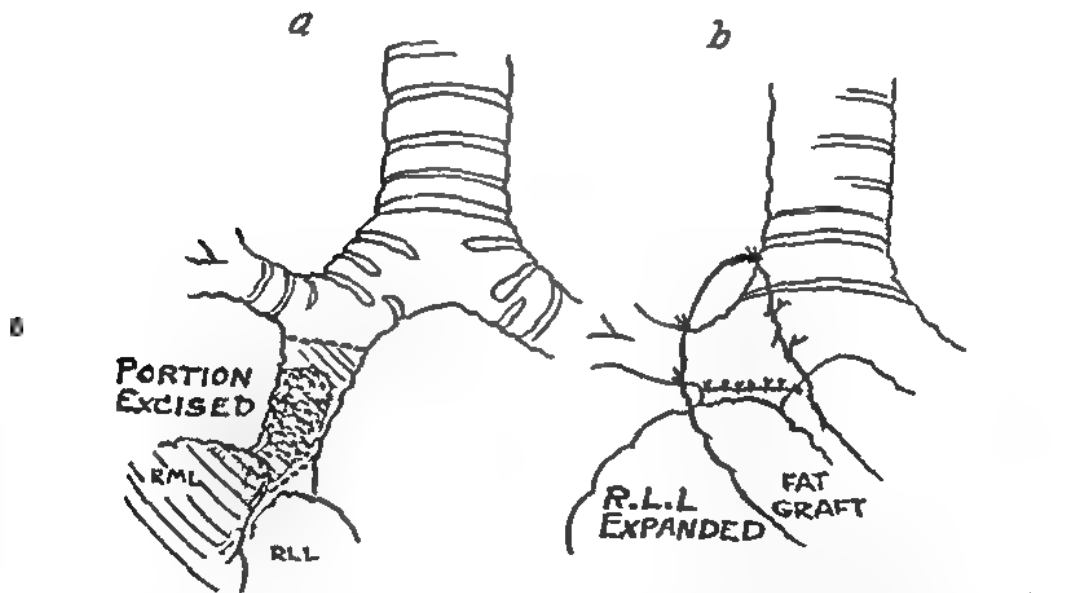

FIG. 5. Case II. Flap procedure. (a) Excision of tumor at bronchus intermedius including right middle and lower lobes. Lateral wall of bronchus intermedius is saved for a bronchial flap. (b) Bronchial flap of lateral wall of bronchus intermedius is sutured to right main bronchus and carina to preserve right upper lobe. Fat graft insures airtight closure.

FIG. 6. Case III. Lobar transplant. (a) Tumor of bronchus intermedius and destroyed right middle lobe are excised. Normal right lower lobe is saved with pulmonary vessels intact. Bronchus cut diagonally. (b) Right lower lobe bronchus sutured to right main bronchus. Diagonally cut bronchus to right lower lobe of sufficient size for anastomosis. Graft of "thoracic omentum" protects suture line.

If the closure of the anastomosis is incomplete, the "thoracic omentum" is invaluable in sealing over the apertures

Lobar Transplants Obstructive lesion of the main or intermediate bronchi may not necessarily mean extensive pulmonary resection or pneumonectomy Preservation of one or more lobes of the lung may be achieved by the re-anastomosis of the peripheral but uninvolved *lobe or lobes of the lung to the trachea* or main bronchus after the resection of the obstructing lesion of the main bronchus, as described by Tuttle [8] In performing this operation not only must the pulmonary artery and vein to the transplanted lobe be preserved but also the bronchial or tracheal vessels at the site where the lobar bronchus is to be re anastomosed Anastomosis is made with simple interrupted sutures reinforced by the "thoracic omentum" (Fig 6) Constriction or torsion on a bronchial lumen is to be avoided or atelectasis of the grafted lobe will result

Trachea or Bronchial Replacement Considerable experimental experience has now accumulated with the resection of trachea or bronchus and replacement of the bronchial wall by artificial or fresh and preserved portions of the *trachea and bronchi from one animal to* another and from one location in the same animal to another location A review of this experience is outside the limits of this communication However, it should be recorded that small transplants are well tolerated, while extensive transplants of trachea and bronchus have eventually been absorbed and replaced with scar tissue [9–12] The bronchial or tracheal [illegible]

or tracheal graft results in a constriction with diminution of the lumen of the airway Various artificial prostheses have been developed which maintain adequate patency of the lumen of the reconstructed trachea or bronchus [13–15] These prostheses must be rigid enough to provide a constantly adequate airway and to permit the successful raising of secretion Airtight connections with the trachea or bronchus and the prosthetic graft is essential It is here that the pedicled pericardial fat graft has a most important role for it makes possible the completion of an airtight anastomosis which otherwise might be technically impossible Three main types of grafts and prosthetic replacements have been used (1) metal screen covered with fascia lata,[16] (2) polyethylene or metal tubes,[17–18] and (3) dermis grafts reinforced with stainless steel wire [19] The technics of employing these grafts are depicted in Figures 7A, B and C

CLINICAL APPLICATION OF THE RESECTION AND PLASTIC PROCEDURES (TABLE II)

Benign Tumors of the Trachea and Bronchi

Benign tumors arising in the trachea and major bronchi may be resected with the conservation of the pulmonary tissue peripheral to the tumors, providing irreversible changes in the lung have not taken place Benign tumors of the trachea are exceedingly rare In 1946 Belsey[6] excised a tracheal adenoma by a right transpleural approach, repairing the defect with fascia lata reinforced with fine wire mesh Since then a number of resections of benign tracheal tumors have been carried out [17 21 22] We have had no case of primary benign tracheal tumor However, in one case of a benign [illegible]

successfully repaired With the pedicled pericardial fat graft reinforcement, an airtight closure of the bronchus and trachea was effected

Benign tumors of the bronchi are much more common than benign neoplasms of the trachea for they make up about 5 per cent of all new growths of the bronchus In a series of twenty benign tumors we have found three which were located in the bronchus in such a manner that they could be removed with conservation of peripheral lobes of the lung A number of cases of resection of benign bronchial tumors have been reported with plastic procedures to conserve lung tissue [23–25] The main technics in our cases were (1) bronchotomy, (2) flap procedures and (3) lobar transplants

Bronchotomy for Bronchial Adenoma A fifty year old woman (Case 1) had repeated hemoptyses over a period of eleven years Unsuccessful attempts had been made to destroy an adenoma which was located in the right upper lobe bronchus by means of bronchoscopic fulguration Through a right transpleural approach the trachea and right upper lobe bronchus were exposed and the t[illegible]

excised by a longitudinal elliptic incision Closure was effected in the transverse plane by bringing the right upper lobe to the trachea The thoracic omentum graft made the closure airtight (Fig 4) The right lung expanded completely and has remained so for over a period of two years Pre- and postoperative x-rays are shown in Figure 8

Flap Procedure for Bronchial Adenoma A thirty-six year old woman (Case 11) had the signs and symptoms of a progressive pulmonary infection due to an adenoma arising in the right upper lobe orifice X-rays revealed collapse of the right middle and lower lobes which had been destroyed by the prolonged bronchial obstruction and secondary infection (Fig 9)

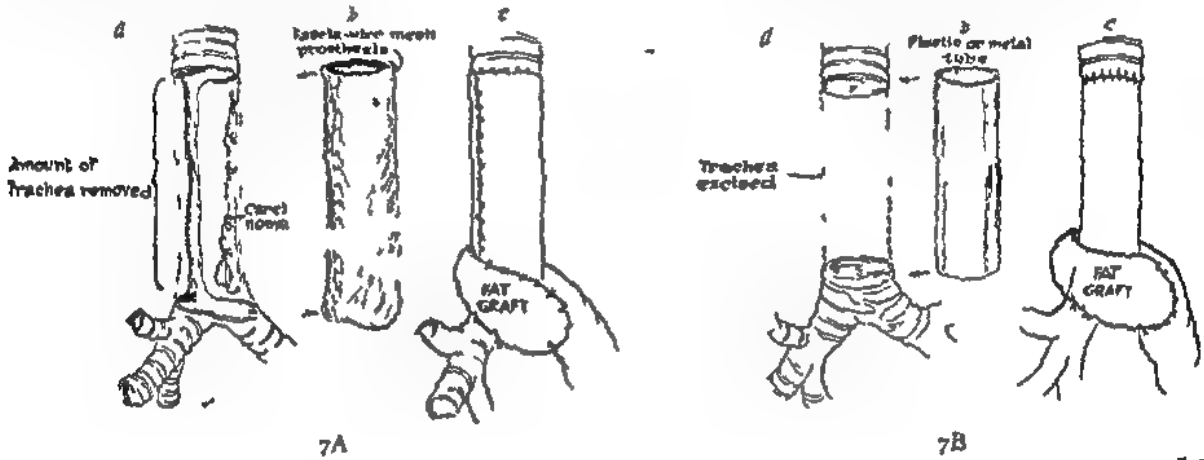

FIG 7A Case 11 Metal screen covered with fascia for extensive trachea replacement (a) Extensive resection of

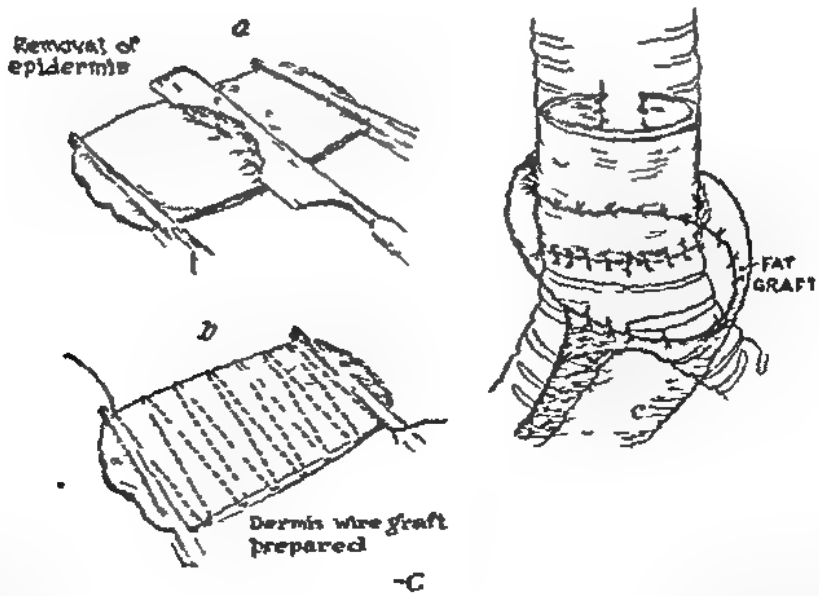

FIG -C. Dermis-wire graft for tracheal replacement (Gebauer) (a) Preparation of full thickness piece of skin by excising the epidermis. (b) No 30 steel wire is laced through the dermis graft to provide rigidity of the wall (c) Dermis-wire graft replaces excised trachea Pericardial fat graft reinforces suture line

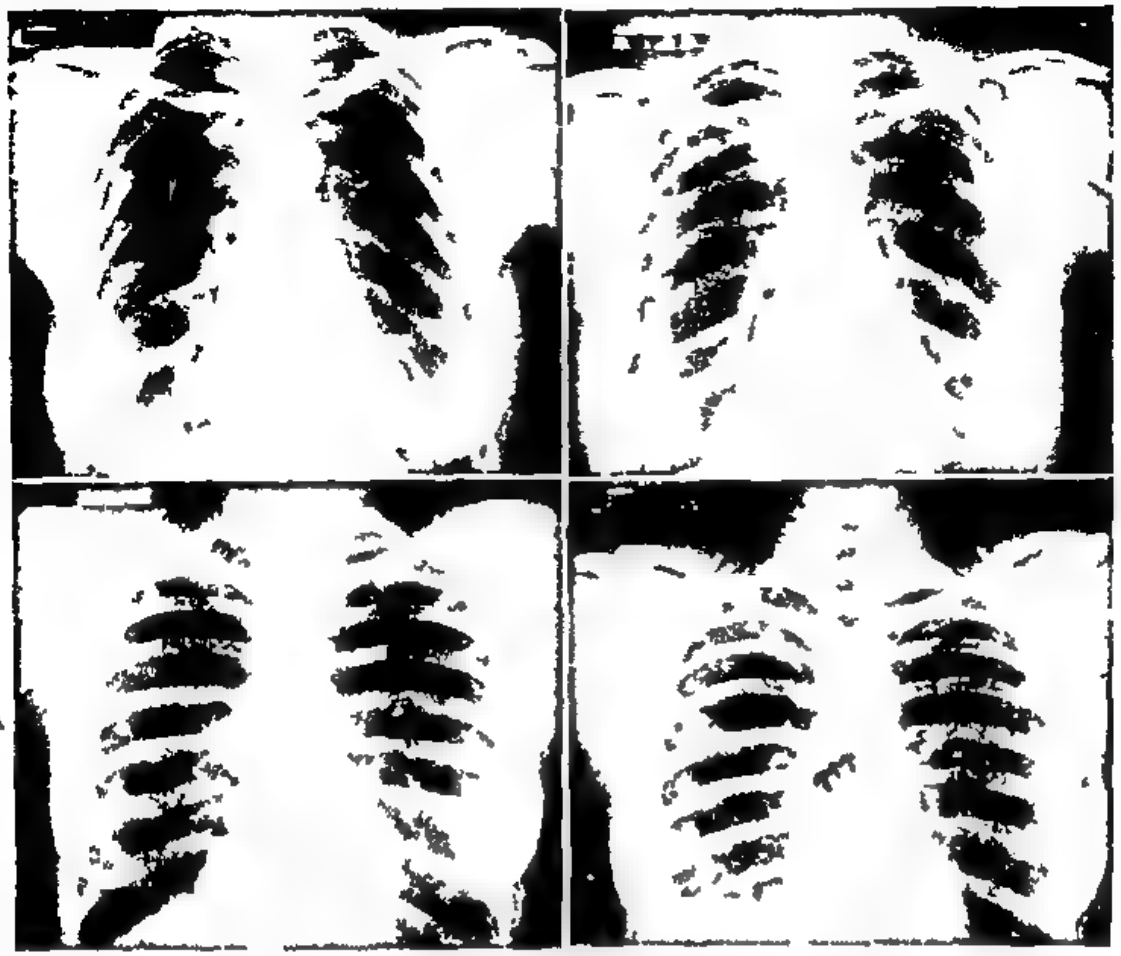

FIG 8 Case I A bronchotomy with partial bronchial excision for adenoma preoperative film shows minimal infiltration right upper lobe No tumor visible B x ray six months after transthoracic excision of bronchial adenoma Bronchial closure solid Lung appears normal

A right thoracotomy was performed on January 4 1952 The right middle and lower lobes were removed The upper lobe was saved by fashioning a flap of the uninvolved bronchus intermedius below the upper lobe and sewing this to the carina in order to preserve the airway to the right upper lobe (Fig 5) This plastic closure was not airtight and the viable pedicled pericardial fat graft was needed to seal off the tiny apertures in the union Thus the anastomosis was made leak proof by the graft and her recovery was uneventful The right upper lobe expanded well and she has been without symptoms for two years nine months (Fig 9)

Lobar Transplant for Bronchial Adenoma A forty four year old woman (Case III) complained of recurrent pneumonia and hemoptysis due to an adenoma of the bronchus intermedius portion of the right main bronchus X rays demonstrated atelectasis of the right middle lobe (Fig 10) However the right upper lobe and right lower lobe were normal On August 11, 1954 thoracotomy was performed The right middle lobe and the bronchus intermedius were resected The right lower lobe bronchus was then sutured to the right main bronchus at the junction of the right upper lobe The anastomosis leaked air However with the help of the thoracic omentum reinforcement the suture line was made airtight The right lower lobe aerated well The upper lobe was slow to aerate probably due to blood aspirated in the upper lobe from trauma to a branch of the bronchial artery However in three months' time the right

excised by a longitudinal elliptic incision. Closure was effected in the transverse plane by bringing the right upper lobe to the trachea. The thoracic omentum graft made the closure airtight (Fig. 4). The right lung expanded completely and has remained so for over a period of two years. Pre- and postoperative x-rays are shown in Figure 8.

Flap Procedure for Bronchial Adenoma. A thirty-six year old woman (Case 11) had the signs and symptoms of a progressive pulmonary [illegible] had been destroyed by the prolonged bronchial obstruction and secondary infection (Fig. 9)

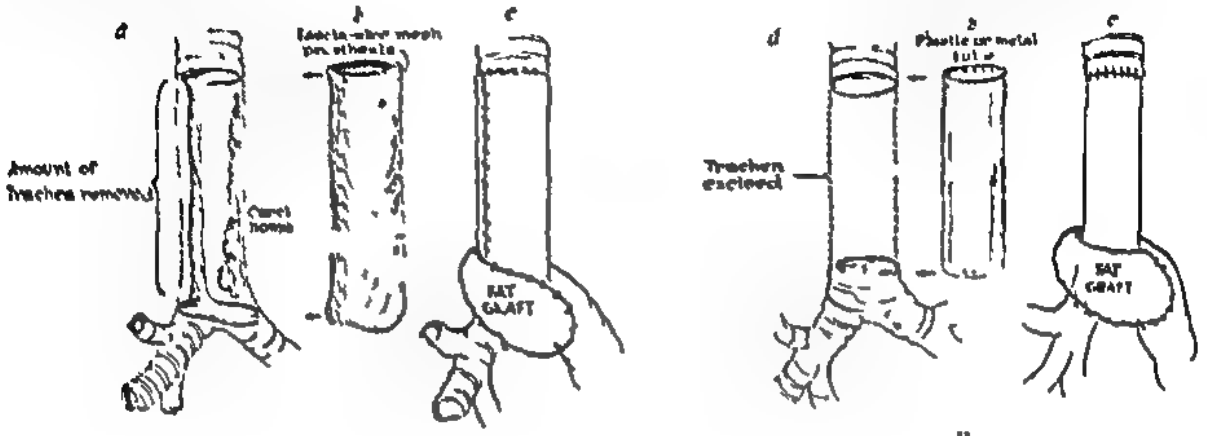

-A -B

[illegible] (a) Extensive resection [illegible]

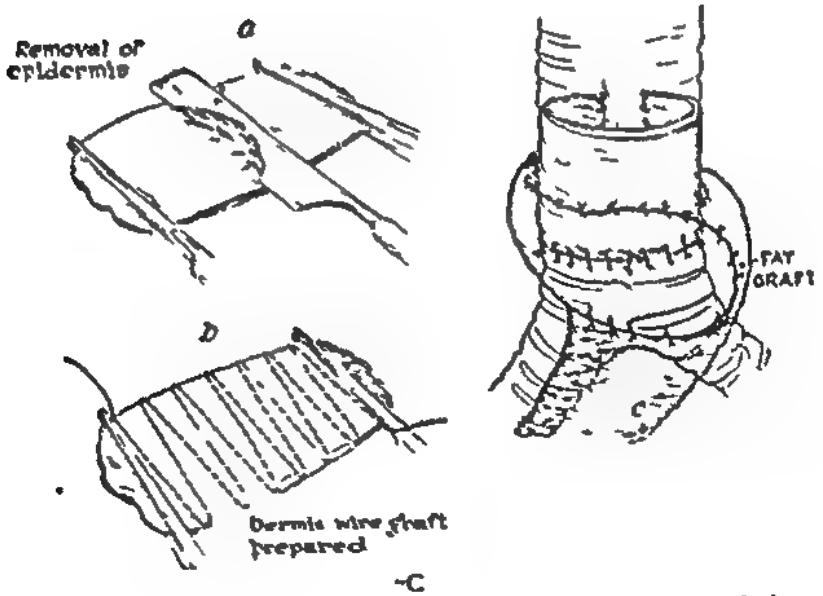

-C

[illegible] thickness piece of skin by [illegible] wall (c)

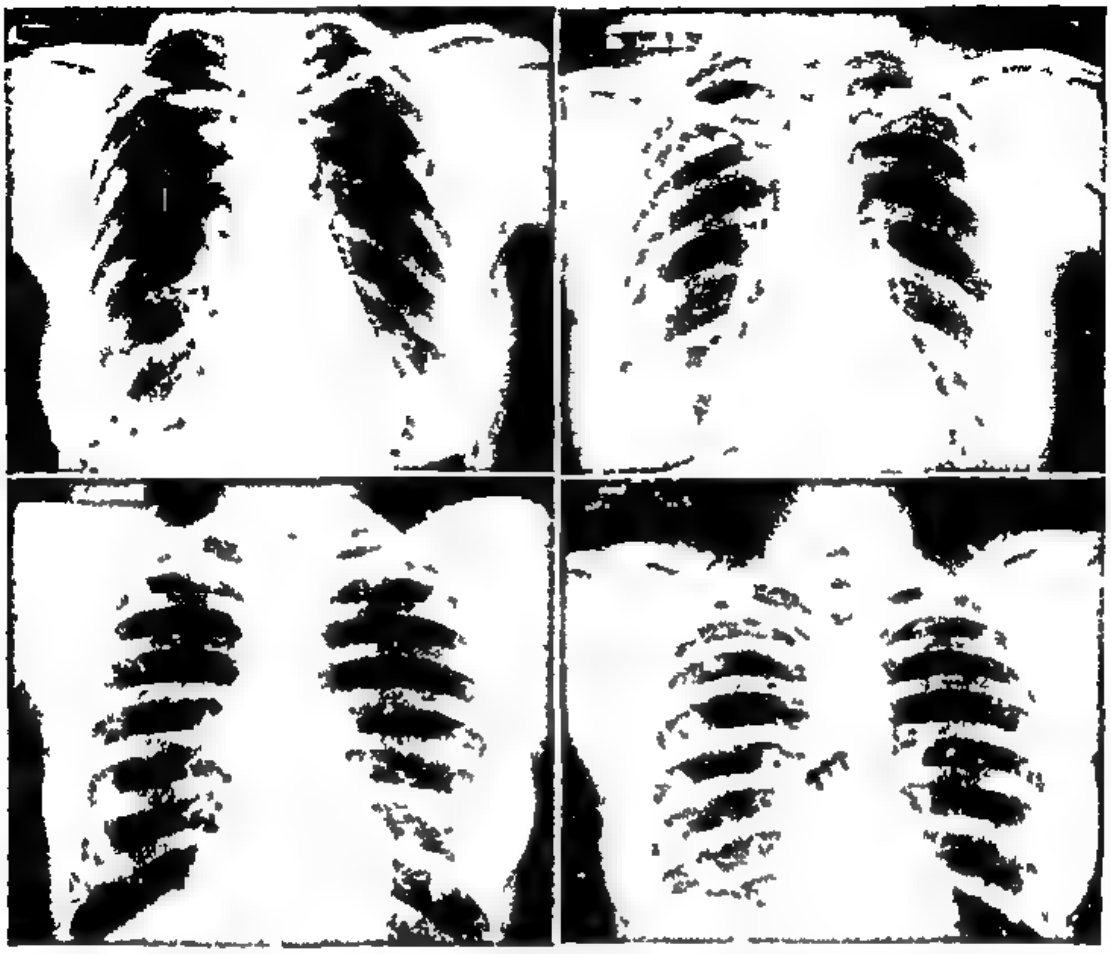

FIG 8 Case I A bronchotomy with partial bronchial excision for adenoma preoperative film shows minimal infiltration right upper lobe No tumor visible B x ray six months after transthoracic excision of bronchial adenoma Bronchial closure solid Lung appears normal

tantalum sutures holding flap in place

A right thoracotomy was performed on January 4, 1952 The right middle and lower lobes were removed The upper lobe was saved by fashioning a flap of the uninvolved bronchus intermedius below the upper lobe and sewing this to the carina in order to preserve the airway to the right upper lobe (Fig 5) This plastic closure was not airtight and the viable pedicled pericardial fat graft was needed to seal off the tiny apertures in the union Thus the anastomosis was made leak proof by the graft and her recovery was uneventful The right upper lobe expanded well and she has been without symptoms for two years nine months (Fig 9)

Lobar Transplant for Bronchial Adenoma A forty-four year old woman (Case III) complained of recurrent pneumonia and hemoptysis due to an adenoma of the bronchus intermedius portion of the right main bronchus X-rays demonstrated atelectasis of the right middle lobe (Fig 10) However, the right upper lobe and right lower lobe were normal On August 11, 1954, thoracotomy was performed The right middle lobe and the bronchus intermedius were resected The right lower lobe bronchus was then sutured to the right main bronchus at the junction of the right upper lobe The anastomosis leaked air However, with the help of the thoracic omentum reinforcement the suture line was made airtight The right lower lobe aerated well The upper lobe was slow to aerate, probably due to blood aspirated in the upper lobe, from trauma to a branch of the bronchial artery However, in three months' time the right

10A 10B

FIG. 10 Case III A lobar transplant for bronchial adenoma atelectasis of right middle lobe is shown on the PA and lateral films before operation Two and a half months after resection of the bronchus intermedius and right middle lobe the lower lobe which has been transplanted to the right main bronchus is well expanded B some residual atelectasis of upper lobe is seen

upper lobe was almost completely aerated (Fig 10)

Malignant Tumor of the Trachea and Bronchus

Primary malignant tumors of the trachea are extremely uncommon Although a portion

TABLE I

SERIES OF 292 CASES OF TOTAL PNEUMONECTOMY AND LOBECTOMY EMPLOYING PEDICLED PERICARDIAL FAT GRAFT

Disorder	Pneumonectomy	Lobectomy
Carcinoma (excluding cases with partial tracheal resection)	98	23
Bronchiectasis	10	61
Tuberculosis	25	42
Pulmonary abscess		13
Pulmonary cyst		4
Benign tumor	2	6
Chronic pneumonitis		8
Total	135	157

of the cervical trachea was removed before the turn of the century,[26] and a number have been performed since then, resection of the thoracic trachea has been reported on only a few occasions Belsey[11] partially resected the trachea, replacing the defect with wire reinforced fascia, leaving a small strip of the trachea *in place* Clagett[17] has replaced the resected trachea by a polyethylene tube Since then a number of other resections have been reported using the fascia reinforced with the wire mesh on a rigid plastic or metal tube or dermis graft reinforced with wire[18 27 35]

Extensive Resection of Trachea for Primary Adenocarcinoma A forty-nine year old housewife (Case IV) had a cough for a number of years

TABLE II

PLASTIC AND RESECTION PROCEDURES ON TRACHEA AND BRONCHI EMPLOYING PEDICLED PERICARDIAL FAT GRAFT

Partial excision of trachea with total pneumonectomy for carcinoma	15
Extensive resection of trachea for carcinoma	1
Bronchotomy for broncholith	2
Partial bronchial excision for benign tumor	1
Flap procedure for benign tumor	1
Lobar transplant for benign tumor	1
Total	21

with exacerbation and choking spells in recent months Although the standard chest films were not particularly abnormal, planograms and bronchograms showed a tumor at lower end of trachea (Fig 11A and B) On bronchoscopy, the tumor extended on the left side from a point about 5 cm below the larynx down to the level where the left main bronchus came off the trachea Severe chronic bronchitis was controlled with repeated aspirations of bronchial secretion and antibiotic therapy Because we feared it might be necessary to remove the left lung, a left sided approach was made on March 18, 1953, through a posterolateral incision, resecting the fifth rib Mobilizing the aortic arch, by dividing the upper intercostal vessels, the trachea and carina were



11A 11B

[illegible] the carina.

FIG 11C Case IV Postmortem specimen Death occurred 3 months after surgery from coronary occlusion Tracheal epithelium lines completely the wire mesh fascia tube Cervical tracheotomy opening at upper end of prosthesis Airway is adequate Lung is well aerated

12A 12B

FIG 12 Case v A bronchotomy for bronchol th as s bronchol ths are sl own on the poster or anter or chest flm in the reg on of the left ma n bronchus Lateral view reveals the irregular character of the stones B two months follo ving transthoracic bronchotomy and exc s on of a stag horn calculus th s stone s not seen The left lung has some res dual inf ltrat on

exposed Opening the trachea the tumor extended from just above the level of the carina to the lower cervical region Fortunately it was not necessary to resect the left lung The tracheal tumor was resected leaving a small strand of right posterior tracheal wall in place from the carina to the level of the clavicle A long intratracheal tube had been inserted into the right main bronchus and a thick fascia lata graft was placed about a steel mesh tube that had been fashioned around the intratracheal tube Because of the difficulty of exposing the right main bronchus from the left side it was impossible to get an airtight closure of the fascia lata wire mesh tube and the right main bronchus Here the pericardial fat graft wrapped around the carina saved us from a desperate situation in making the closure airtight (Fig 7A) After the completion of the thoracotomy a cervical tracheotomy was performed The tracheotomy tube entered the newly formed artificial trachea The patient recovered from the operation only to die three months later of a coronary occlus on Autopsy revealed the reconstructed trachea to be a sturdy tube with a good airway (Fig 11C) The tube was lined by a normal appearing mucosa The airway was adequate although there was evidence of recurrent carcinoma in the region of the carina This case is of interest for a number of reasons (1) So far as we know it is the first time the thoracic trachea has been resected from the left sided approach with reconstruction of the trachea (2) The pedicled pericardial fat graft made the anas tomosis airtight where otherwise it would have been impossible (3) There was complete epithelialization of the graft replacing the resected trachea extending from the level of the clavicle to the carina

In resecting a lung for bronchogenic car cinoma removal of a portion of the trachea along with the main bronchus is not uncom mon This technic has been reported recently by Abbott[29] and others We have removed portions of the trachea in fifteen instances in a series of 150 resections for lung cancer The pedicled pericardial fat graft was successful in all instances to reinforce the tracheal closure of the trachea and carina There was one fatality in this series not from leaking of the bronchus but from collapse of the bronchus in a case in wh ch a portion of the tracheal wall and carina had been resected along with the right lung Although the remaining portions of the trachea and left main bronchus had an adequate diameter and seemed stiff enough to provide a satisfactory airway at the time of operation the trachea and left stem bronchus collapsed follo ving surgery Death occurred in thirty six hours apparently due to resp ratory failure caused by the collapse of the trachea and the left main bronchus In this case failure to provide proper support for the trachea and bronchus could have been obviated by a securely anchored intralumenal plastic tube or a reinforced wire graft

Broncholiths

Broncholiths are relatively uncommon sources of bronchial obstruction hemorrhage or secondary infection of the lung[30] Most

often these stones are either coughed up or may be removed by the bronchoscope If there has been destruction of the pulmonary tissue, secondary to bronchial obstruction, pulmonary resection is indicated These are the usual [illegible]

scopic extraction is impossible We have had experience with two such cases

Bronchotomy for Broncholithiasis A sixty year old housewife (Case x) had coughed up broncholiths for over seven years Because of dyspnea and blood spitting medical aid was sought X rays demonstrated broncholiths at the left hilum (Fig 12) Bronchoscopy showed granulation tissue which was thought at first to be a tumor After removing bits of this tissue the tip of a stone was uncovered which completely blocked the left main bronchus 1 cm below the carina Attempts to remove the stone through the bronchoscope were unsuccessful as this calcareous mass was firmly imbedded in the bronchial wall On September 11, 1950, through a posterolateral thoracotomy approach, the left main bronchus was freed from surrounding structures A long incision was made in the soft membraneous posterior wall of the bronchus, extending from a point just below the carina down to the left lower lobe A large, two-pronged "stag horn" type of calculus, 2 by 1 5 by 5 cm, was removed Several smaller calculi were also lifted from the bronchial wall Bronchotomy opening was closed with interrupted tantalum wire sutures and the suture line reinforced with a pedicled pericardial fat graft There was no bronchial leak and the patient has been well for four years with an excellent airway in the left main bronchus, as observed on subsequent bronchoscopy

Tuberculous Endobronchitis

Tracheal or bronchial stenosis occurs as the end result of tuberculous infection of these structures In most instances the tracheal or bronchial lesion is secondary to extensive pulmonary disease which, in turn, is refractory to treatment because of the bronchial obstruction However, when the tracheal or bronchial stenosis is healed and the pulmonary disease is controlled, the stenotic lesion may lend itself to plastic operations designed to improve the airway and conserve pulmonary tissue We have been following one case of tracheal stenosis for a possible plastic operation However, the bilateral pulmonary disease has not yet been controlled sufficiently to permit operation In a series of 450 cases of pulmonary resection of all types for pulmonary tuberculosis from our various services, in no instance has a bronchoplastic procedure been indicated Experience, however, varies considerably for Gebauer,[31] in a series of 136 patients with tuberculous tracheal bronchitis, reported eleven cases in which plastic procedures to the trachea or bronchus were carried out He has developed a dermograft reinforced with No 30 stainless steel wire This gives a strong graft which is stiff enough to insure patency of the airway In ten of eleven grafts reported by him a successful result has been effected Others have employed this technic with similar success We believe it is the procedure of choice for small grafts of the bronchus and trachea, provided a large portion of the trachea or bronchi has not been resected

Trauma

Injuries to the trachea or main bronchi result in the escape of large amounts of air into the mediastinum or pleura, and as such present urgent indications for emergency thoracotomy These wounds are not common in either civilian life or warfare One of us (L A B) was privileged to treat a large number of thoracic injuries as a member of an Auxiliary Surgical Group in World War II * In a series of 1,249 severe wounds of the chest managed by the thoracic surgeons of this group in the Mediterranean and European Theaters of Operation, there were only three instances in which bronchial laceration was an indication for thoracotomy Sanger[31] has reported the repair of lacerations of the bronchus due to penetrating missiles Furthermore, the bronchus may also be ruptured by blunt nonpenetrating injuries, as reported by Kinsella When the diagnosis is made early, simple suture of the torn trachea or bronchus will usually suffice If the patient survives the original wound, to go on to tracheal or bronchial stricture, a bronchoplastic operation may be indicated However, when secondary infection results in irreparable damage to the lung

* Second Auxiliary Surgical Group



12A 12B

FIG 12 Case v A bronchotomy for broncholithiasis broncholiths are shown on the poster or anterior chest film in the region of the left main bronchus Lateral view reveals the irregular character of the stones B two months following transthoracic bronchotomy and excision of a stag horn calculus this stone is not seen The left lung has some residual infiltration

exposed Opening the trachea the tumor extended from just above the level of the *carina to the lower cervical region* Fortunately it was not necessary to resect the left lung The tracheal tumor was resected leaving a small strand of right posterior tracheal wall in place, from the carina to the level of the clavicle A long intratracheal tube had been inserted into the right main bronchus and a thick fascia lata graft was placed about a steel mesh tube that had been fashioned around the intratracheal tube Because of the difficulty of exposing the right main bronchus from the left side, it was impossible to get an airtight closure of the fascia lata wire mesh tube and the right main bronchus Here the pericardial *fat graft wrapped around the carina saved us* from a desperate situation in making the closure airtight (Fig 7A) After the completion of the thoracotomy a cervical tracheotomy was performed The tracheotomy tube entered the newly formed artificial trachea The patient recovered from the operation only to die three months later of a coronary occlusion Autopsy revealed the reconstructed trachea to be a sturdy tube with a good airway (Fig 11C) The tube was lined by a normal appearing mucosa The airway was adequate although there was evidence of recurrent carcinoma in the region of the carina This case is of interest for a number of reasons (1) So far as we know it is the first time the thoracic trachea has been resected from the left sided approach with reconstruction of the trachea (2) The pedicled pericardial fat graft made the anastomosis airtight where otherwise it would have been impossible (3) There was complete epithelialization of the graft replacing the *resected trachea extending from the level of* the clavicle to the carina

In resecting a lung for bronchogenic carcinoma removal of a portion of the trachea along with the main bronchus is not uncommon This technic has been reported recently by Abbott[29] and others We have removed portions of the trachea in fifteen instances in a series of 150 resections for lung cancer The pedicled pericardial fat graft was successful in all instances to reinforce the tracheal closure of the trachea and carina There was one fatality in this series not from leaking of the bronchus but from collapse of the bronchus in *a case in which a portion of the tracheal* wall and carina had been resected along with the right lung Although the remaining portions of the trachea and left main bronchus had an adequate diameter and seemed stiff enough to provide a satisfactory airway at the time of operation the trachea and left stem bronchus and the left main bronchus In this case failure to provide proper support for the trachea and bronchus could have been obviated by a securely anchored intralumenal plastic tube or a reinforced wire graft

Broncholiths

Broncholiths are relatively uncommon sources of bronchial obstruction hemorrhage or secondary infection of the lung[30] Most

often these stones are either coughed up or may be removed by the bronchoscope If there has been destruction of the pulmonary tissue, secondary to bronchial obstruction, pulmonary resection is indicated These are the usual

scopic extraction is impossible We have had experience with two such cases

Bronchotomy for Broncholithiasis A sixty year old housewife (Case v) had coughed up bronchoiths for over seven years Because of dyspnea and blood splitting medical aid was sought X-rays demonstrated bronchoiths at the left hilum (Fig 12) Bronchoscopy showed granulation tissue which was thought at first to be a tumor After removing bits of this tissue the tip of a stone was uncovered which completely blocked the left main bronchus 1 cm below the carina Attempts to remove the stone through the bronchoscope were unsuccessful as this calcareous mass was firmly imbedded in the bronchial wall On September 11, 1950, through a posterolateral thoracotomy approach, the left main bronchus was freed from surrounding structures A long incision was made in the soft membraneous posterior wall of the bronchus, extending from a point just below the carina down to the left lower lobe A large, two-pronged "stag-horn" type of calculus, 2 by 1 5 by 5 cm, was removed Several smaller calculi were also lifted from the bronchial wall Bronchotomy opening was closed with interrupted tantalum wire sutures and the suture line reinforced with a pedicled pericardial fat graft There was no bronchial leak and the patient has been well for four years with an excellent airway in the left main bronchus as observed on subsequent bronchoscopy

Tuberculous Endobronchitis

Tracheal or bronchial stenosis occurs as the end result of tuberculous infection of these structures In most instances the tracheal or bronchial lesion is secondary to extensive pulmonary disease which, in turn, is refractory to treatment because of the bronchial obstruction However, when the tracheal or bronchial stenosis is healed and the pulmonary disease is controlled, the stenotic lesion may lend itself to plastic operations designed to improve the airway and conserve pulmonary tissue We have been following one case of tracheal stenosis for a possible plastic operation However, the bilateral pulmonary disease has not yet been controlled sufficiently to permit operation In a series of 450 cases of pulmonary resection of all types for pulmonary tuberculosis from our various services, in no instance has a bronchoplastic procedure been indicated Experience, however, varies considerably for Gebauer,[21] in a series of 136 patients with tuberculous tracheal bronchitis, reported eleven cases in which plastic procedures to the trachea or bronchus were carried out He has developed a dermograft reinforced with No 30 stainless steel wire This gives a strong graft which is stiff enough to insure patency of the airway In ten of eleven grafts reported by him a successful result has been effected Others have employed this technic with similar success We believe it is the procedure of choice for small grafts of the bronchus and trachea, provided a large portion of the trachea or bronchi has not been resected

Trauma

Injuries to the trachea or main bronchi result in the escape of large amounts of air into the mediastinum or pleura, and as such present urgent indications for emergency thoracotomy These wounds are not common in either civilian life or warfare One of us (L. A B) was privileged to treat a large number of thoracic injuries as a member of an Auxiliary Surgical Group in World War II * In a series of 1,249 severe wounds of the chest managed by the thoracic surgeons of this group in the Mediterranean and European Theaters of Operation, there were only three instances in which bronchial laceration was an indication for thoracotomy Sanger[22] has reported the repair of lacerations of the bronchus due to penetrating missiles Furthermore, the bronchus may also be ruptured by blunt nonpenetrating injuries, as reported by Kinsella [23] When the diagnosis is made early, simple suture of the torn trachea or bronchus will usually suffice If the patient survives the original wound, to go on to tracheal or bronchial stricture, a bronchoplastic operation may be indicated However, when secondary infection results in irreparable damage to the lung

* Second Auxiliary Surgical Group

distal to the obstruction, as in other obstructive lesions discussed previously, pulmonary resection must be employed Pedicled pericardial fat graft is particularly indicated to reinforce the bronchial and tracheal closures in repair of wounds of these organs

Other Lesions

We believe that plastic procedures might be employed for both congenital non-specific obstruction of the bronchus, such as those produced by the presence of a foreign body, or a localized destructive process of the trachea or bronchus The same principles would apply to these lesions as those that have been discussed previously It is important to stress, however, that plastic repair of trachea and bronchial obstructions must be made before irreversible changes develop in the lung tissue supplied by the trachea or bronchus

COMMENTS

The importance of the general over-all management of the patient, including control of infection nutrition, preoperative preparation, skillful anesthesia, postoperative care, etc , is now widely appreciated Of course, a thorough evaluation of the pathologic lesion should be treated as essential Thus, it must be made

upon From experience gained in the management of these cases we believe that certain technical aspects should be stressed (1) Preservation of blood supply to the bronchus and trachea and avoidance of the use of crushing clamps, (2) use of fine interrupted sutures (007 inches tantalum wire, No 000 silk) with minimal trauma needles, (3) prevention of tension on the suture line, (4) insuring adequate bronchial or tracheal airway by non constricting suturing and proper support of the weakened bronchial or tracheal wall by stent, wire, etc , (5) reinforcement of the suture line with the viable, pedicled pericardial fat graft

After reviewing the cases presented we can conclude that when attention is paid to the aforementioned principles, the operative procedures for division and closure of the bronchus, bronchotomy, flap procedures and lobar transplants are sound and will be followed with a high degree of success Certainly there should be no hesitation on the part of the surgeon to employ them when the occasion is presented

While these technics are well established, replacement of large segments of the trachea represents a controversial problem Each of the technics presented has inherent technical difficulties and the clinical experience to date has not been great Because of failure to obtain airtight connections with a plastic tube in subtotal resection of the trachea in dogs, we employ the fascia lata reinforced graft in the reported case Yet, the life of a huge fascial graft is not long and one wonders if the fibroblastic granulation tissue would always be sufficiently formed by the time that the fascia has disintegrated We left a small strip of the posterior wall of the trachea, from the carina to the cervical region in this case Regeneration of the mucosa was complete Because the carcinoma recurred, a more extensive operation was desirable There is no question, however, that this technic is excellent for benign lesions

However, the plastic or metal tube replacement tube technic is simpler and probably permits wider resection of the trachea If multiple point fixation can be made of the tube to the trachea, and sufficient overlap of the trachea over the tube is effected, a reasonably airtight union should be made The fat graft will be of considerable help in protecting this connection These plastic or metal tubes must be very firmly anchored as a permanent prosthesis to the trachea, for collapse of the fibrous-reformed trachea has been the inevitable consequence of the removal or displacement of these prosthetic tubes If sufficient pericardial fat graft could be mobilized to cover the plastic or metal prosthesis, rapid regeneration of the fibrous tracheal wall and the mucosa could be anticipated This would obtain for a wire mesh graft as well The wire-supported dermis grafts have not been used for extensive tracheal reconstruction, although they have proven highly successful for partial resections of the wall In all cases of tracheal resection of any moment it is most important that a tracheotomy tube be placed in the trachea after operation Not only can blood and secretions be aspirated frequently through the tracheotomy tube, but also the presence of the tube prevents the development of a high positive pressure in coughing that might tear out the suture line, resulting in mediastinal emphysema or tension pneumothorax The subsequent mediastinitis

or empyema might prove to be a fatal complication The tracheotomy tube may be placed in the reconstructed trachea, as was done in our case

It is certain that the last word has not been written on extensive tracheal replacement The technics presented have proved to be effectual and further trial of these methods is warranted

SUMMARY

1 The development and use of the viable pedicled pericardial fat graft in surgery of the trachea and bronchus are presented

2 Our method of division and closure of the bronchus, reinforced by the "thoracic omentum" in total pneumonectomy and lobectomy has resulted in no instance of bronchopleural fistula before the third week in 292 cases Late fistula, up until the seventh month, occurred in 2 0 per cent of all the cases

3 The technic of resection and plastic operations on the trachea and bronchi employed by the authors ■ reviewed These include (1) bronchotomy, (2) flap procedures, (3) lobar transplants, (4) resection and replacement of the tracheal and bronchial walls

4 A review ■ made of the clinical application of these technics based on personal experience in twenty-one cases These procedures are sound and are followed with satisfactory results

5 A wider application of these technics is possible and will result in the saving of lives and the conservation of pulmonary tissue

REFERENCES

1 BREWER L A, III, KING, E L, LILLY, L J and BAI A F Bronchial closure in pulmonary resection a clinical and experimental study using a pedicled pericardial fat graft reinforcement *J Thoracic Surg*, 26 507, 1953

2 TUFFIER, T Resection du sommet du pomon dract pour tuberculose pulmonaire Presentation du mala de quarte ans et deux mois opres l operation Congres Francaise de Chirurgie 9, Session 87 1895

3 RIENHOFF, W F Pneumonectomy *Bull Johns Hopkins Hosp*, 53 390 1933

4 CHURCHILL, E D and BELSEY Segmental pneumonectomy in bronchiectasis The lingula segment of the left upper lobe *Ann Surg*, 109 481, 1939

5 KENT, E M and BLADES B The anatomical approach to pulmonary resection *Ann Surg*, 116 782 1942

6 GOELTZ F A Successful anterior thoraco-bronchotomy for foreign body impacted in the bronchus *Ann Surg*, 45 369 1907

7 LOESSER, L Transthoracic bronchotomy for removal of benign tumors of the bronchi *Ann Surg*, 112 1067, 1940

8 TUTTLE, W and HAMPTON, T In discussion of JACKSON, T L and LEFKIN, P An experimental study in bronchial anastomosis *J Thoracic Surg*, 18 630, 1949

9 JACKSON T L, O BRIEN, E J, TUTTLE, W and MEYER J The experimental use of homogenous tracheal transplants in the restoration of the continuity of the tracheobronchial tree *J Thoracic Surg*, 20 598, 1950

10 CARTER, M G and STRIEDER, J W Resection of the trachea and bronchi An experimental study *J Thoracic Surg*, 20 613, 1950

11 MARRANGONI, A G Homotransplantation of tracheal segments preserved by lyphdization An experimental study *J Thoracic Surg*, 21 398, 1951

12 PACHECO, C R, RIVERO, O and PORTER J K Experimental reconstruction surgery of the trachea *J Thoracic Surg* 27 554 1954

13 TAPPEL, M The repair of tracheal and bronchial defects with free fascia grafts *Surgery*, 8 56, 1940

14 D [illegible]

15 G [illegible] H J Experimental surgery of the thoracic trachea and its bifurcation Preliminary report *Proc Staff Meet, Mayo Clin*, 24 555, 1949

16 BELSEY R Stainless steel wire suture technique in thoracic surgery *Thorax*, 1 39, 1946

17 CLAGETT O T, GRINDLAY, J H and MOERSCH, H J Resection of the trachea An experimental study and a report of a case *Arch Surg*, 57 253 1948

18 JARVIS, F J Discussion of references 9 and 10

19 GERAUER, P W Experiences with surgical reconstruction of the trachea *Am Rev Tuberc*, 62 176 1950

20 GERAUER, P W Pulmonary salvage by bronchial resection *Surg, Gynec & Obst*, 94 347 1952

21 GIBBON, J H Discussion of reference 13

22 EVANS B Personal communication

23 GOLDMAN A The surgical treatment of bronchial adenoma *Dis of Chest*, 13 321, 1947

24 LANGSTON, H T The indication for posterior transpleural bronchotomy in the management of intrabronchial tumors *Surg Gynec & Obst*, 86 192, 1948

25 PALLSON, D L and SHAW, R L Bronchial anastomosis and bronchoplastic procedures in the interest of preservation of lung tissue *J Thoracic Surg*, in press

26 BRUNS, P Resektion der Trachea bei Primaren Tracheal krebs *Beitr z Klin chir*, 2 284 1898

27 ROB C G and BATEMAN G H Reconstruction of the trachea and cervical esophagus *Brit J Surg*, 37 202 1949

28 COTTON, B Resection of the trachea for carcinoma *J Thoracic Surg*, 24 231, 1952

29 ABBOTT, O A Experiences with surgical resection

of human carina, tracheal wall and contralateral wall in cases of right total pneumonectomy *J Thoracic Surg*, 19 906, 1950

30 SCHMIDT, H W, CLAGETT, O T and MCDONALD, J R Broncholithiasis *J Thoracic Surg*, 19 226, 1950

31 GEBAUER, P W Plastic reconstruction of tuberculous bronchostenosis with dermograft *J Thoracic Surg*, 19 609 1950

32 Forward Surgery of the Wounded, Vol 1, pp 506 Second Auxiliary Surgical Group, Aug 27 1945

33 SANGER, P W Evacuation hospital experiences with war wounds and injuries of the chest *Ann Surg*, 122 147, 1945

34 KINSELLA, T J and JOHNSRUD L W Traumatic rupture of the bronchus *J Thoracic Surg* 16 571, 1947

Bronchoplastic Procedures

DONALD L. PAULSON, M.D. AND ROBERT R. SHAW, M.D., *Dallas, Texas*

From the Department of Surgery, Southwestern Medical School, the University of Texas and Baylor Hospital, Dallas, Texas

SEGMENTAL resection of pulmonary tissue is now a well established thoracic surgical procedure and is a particularly valuable technic in the interest of preservation of lung tissue. Bronchial anastomosis and bronchoplastic procedures in the interest of preservation of lung tissue are relatively new developments in the field of thoracic surgery. A traumatic, inflammatory or neoplastic lesion of the bronchus does not always require resection of all of the lung tissue supplied by the bronchus. By means of various types of repair it is possible to excise the bronchial lesion and preserve a portion or all of the lung tissue distal to the point of excision.

The reports of Gebauer[1-4] have demonstrated very well the merit of the concept of pulmonary salvage through bronchial reparative procedures, particularly with reference to tuberculous bronchostenosis, but including bronchial tumors. Others through individual published reports and discussion of Gebauer's papers have recorded the successful application of various reconstructive procedures of the bronchus following excision of tumors, traumatic strictures and accidental bronchial division.

TABLE I

TRAUMATIC BRONCHIAL RUPTURE

Case	Sex and Age	Diagnosis	Surgical Procedure	Date	Result
1. L. M.	M. 22	Traumatic bronchial occlusion, right main bronchus, 7 wk. following injury	Plastic reconstruction of right main bronchus by means of dermal graft (Plate 1, Fig. 1)	July 2, 1949	Bronchus patent, lung fully expanded
2. B. S.	M. 21	Traumatic bronchial rupture, left main bronchus, 6 wk. following injury	End to end anastomosis of left main bronchus (Plate 1, Fig. 2)	August 8, 1951	Bronchus healed, lung fully expanded
3. J. C.	M. 19	Traumatic bronchial rupture, 6 hr. following injury	End-to-end anastomosis, left lower lobe bronchus to left main bronchus (Plate 1, Fig. 3)	April 19, 1951	Bronchus healed, lung fully expanded
4. B. H.	M. 23	Traumatic bronchial rupture, 2 hr. following injury	Tracheotomy, suture of tear involving right main, intermediary and superior segmental bronchi (Plate 1, Fig. 4)	January 20, 1954	Bronchus healed, lung fully expanded

The authors have used a variety of procedures to restore bronchial continuity and

of human carina, tracheal wall and contralateral wall in cases of right total pneumonectomy. *J Thoracic Surg*, 19 906, 1950

30 SCHMIDT, H W, CLAGETT, O T and MCDONALD, J R Broncholithiasis *J Thoracic Surg*, 19 226, 1950

31 GEBAUER, P W Plastic reconstruction of tuberculous bronchostenosis with dermograft *J Thoracic Surg*, 19 609, 1950

32 Forward Surgery of the Wounded, Vol 1, pp 506 Second Auxiliary Surgical Group, Aug 27, 1945

33 SANGER, P. W Evacuation hospital experiences with war wounds and injuries of the chest *Ann Surg*, 122 147, 1945

34 KINSELLA, T. J and JOHNSRUD L. W. Traumatic rupture of the bronchus *J Thoracic Surg*, 16 571, 1947

Bronchoplastic Procedures

DONALD L. PAULSON, M.D. AND ROBERT R. SHAW, M.D. *Dallas, Texas*

From the Department of Surgery, Southwestern Medical School, the University of Texas and Baylor Hospital, Dallas, Texas

SEGMENTAL resection of pulmonary tissue is now a well established thoracic surgical procedure and is a particularly valuable technic in the interest of preservation of lung tissue. Bronchial anastomosis and bronchoplastic procedures in the interest of preservation of lung tissue are relatively new developments in the field of thoracic surgery. A traumatic inflammatory or neoplastic lesion of the bronchus does not always require resection of all of the lung tissue supplied by the bronchus. By means of various types of repair it is possible to excise the bronchial lesion and preserve a portion or all of the lung tissue distal to the point of excision.

The reports of Gebauer[1-3] have demonstrated very well the merit of the concept of pulmonary salvage through bronchial reparative procedures, particularly with reference to tuberculous bronchostenosis, but including bronchial tumors. Others through individual published reports and discussion of Gebauer's papers have recorded the successful application of various reconstructive procedures of the bronchus following excision of tumors, traumatic strictures and accidental bronchial division.

TABLE 1
TRAUMATIC BRONCHIAL RUPTURE

Case	Sex and Age	Diagnosis	Surgical Procedure	Date	Result
1 L. M.	M. 22	Traumatic bronchial occlusion, right main bronchus, 7 wk. following injury	Plastic reconstruction of right main bronchus by means of dermal graft (Plate 1, Fig. 1)	July 2, 1949	Bronchus patent, lung fully expanded
2 B. S.	M. 21	Traumatic bronchial rupture, left main bronchus, 6 wk. following injury	End-to-end anastomosis of left main bronchus (Plate 1, Fig. 2)	August 8, 1951	Bronchus healed, lung fully expanded
3 J. C.	M. 19	Traumatic bronchial rupture, 6 hr. following injury	End to end anastomosis, left lower lobe bronchus to left main bronchus (Plate 1, Fig. 3)	April 19, 1951	Bronchus healed, lung fully expanded
4 B. H.	M. 23	Traumatic bronchial rupture, 2 hr. following injury	Tracheotomy, suture of tear involving right main, intermediary and superior segmental bronchi (Plate 1, Fig. 4)	January 20, 1954	Bronchus healed, lung fully expanded

The authors have used a v[illegible] of procedures to restore [illegible]

of human carina, tracheal wall and contralateral wall in cases of right total pneumonectomy *J Thoracic Surg*, 19 906, 1950

30 SCHMIDT, H W, CLAGETT, O T and MCDONALD J H Broncholithiasis *J Thoracic Surg*, 19 226 1950

31 GEBAUER P W Plastic reconstruction of tuberculous bronchostenosis with dermograft *J Thoracic Surg*, 19 609, 1950

32 Forward Surgery of the Wounded, Vol 1, pp 506 Second Auxiliary Surgical Group, Aug 27, 1945

33 SANGER, P W Evacuation hospital experiences with war wounds and injuries of the chest *Ann Surg* 122 147, 1945

34 KINSELLA, T J and JOHNSRUD, L W Traumatic rupture of the bronchus *J Thoracic Surg* 16 571, 1947

Bronchoplastic Procedures

DONALD L. PAULSON M D AND ROBERT R SHAW M D, *Dallas Texas*

From the Department of Surgery Southwestern Medical School the University of Texas and Baylor Hospital Dallas Texas

SEGMENTAL resection of pulmonary tissue is now a well established thoracic surgical procedure and is a particularly valuable technic in the interest of preservation of lung tissue Bronchial anastomosis and bronchoplastic procedures in the interest of preservation of lung tissue are relatively new developments in the field of thoracic surgery A traumatic inflammatory or neoplastic lesion of the bronchus does not always require resection of all of the lung tissue supplied by the bronchus By means of various types of repair it is possible to excise the bronchial lesion and preserve a portion or all of the lung tissue distal to the point of excision

The reports of Gebauer[1-3] have demonstrated very well the merit of the concept of pulmonary salvage through bronchial reparative procedures particularly with reference to tuberculous bronchostenosis but including bronchial tumors Others through individual published reports and discussion of Gebauer's papers have recorded the successful application of various reconstructive procedures of the bronchus following excision of tumors traumatic strictures and accidental bronchial division

The authors have used a variety of procedures to restore bronchial continuity and

TABLE 1

TRAUMATIC BRONCHIAL RUPTURE

Case	Sex and Age	Diagnosis	Surgical Procedure	Date	Result
1 L M	M 22	Traumatic bronchial occlusion right main bronchus 7 wk following injury	Plastic reconstruction of right main bronchus by means of dermal graft (Plate 1 Fig 1)	July 2 1949	Bronchus patent lung fully expanded
2 B S	M 21	Traumatic bronchial rupture left main bronchus, 6 wk following injury	End to-end anastomosis of left main bronchus (Plate 1 Fig 2)	August 8 1951	Bronchus healed lung fully expanded
3 J C	M 19	Traumatic bronchial rupture 6 hr following injury	End to-end anastomosis, left lower lobe bronchus to left main bronchus (Plate 1 Fig 3)	April 19 1951	Bronchus healed lung fully expanded
4 B H	M 23	Traumatic bronchial rupture 2 hr following injury	Tracheotomy suture of tear involving right main intermediary and superior segmental bronchi (Plate 1 Fig 4)	January 20 1954	Bronchus healed lung fully expanded

preserve good lung tissue in eighteen patients The bronchial lesions so treated include traumatic occlusion(2), acute traumatic rupture(2), tuberculous stenosis(3), adenoma(2) and carcinoma(9) The individual cases are summarized in Tables I to IV, with appropriate illustrations The first sixteen cases have been reported previously [1-6]

TRAUMA

Rupture of the bronchus may result from non-penetrating trauma of the chest The diagnosis during the period immediately following the injury can be readily made if one keeps in mind the possibility of a tear of the bronchus in a patient who has sustained non-

TABLE II
TUBERCULOUS BRONCHOSTENOSIS

Case	Sex and Age	Diagnosis	Surgical Procedure	Date	Result
5 A T	F 20	Pulmonary tuberculosis with 2 cavities persisting following thoracoplasty in 1950, healed stenosis right main bronchus	Right upper and right middle lobectomies, plastic reconstruction of right main bronchus and lower trachea by means of dermal graft reinforced by steel wire mesh (Plate II, Fig 1)	December 15, 1951	Bronchus healed, good expansion of lower lobe, sputum negative
6 D C	F, 34	Pulmonary tuberculosis, right upper lobe healed stenosis, right main and right upper lobe bronchi	Resection of right upper lobe and right main bronchus, end to end anastomosis of intermediary bronchus to trachea (Plate II, Fig 2)	July 30, 1953	Bronchus healed right middle and lower lobes fully expanded, sputum negative
7 R B	F, 31	Pulmonary tuberculosis with destruction of right upper lobe	Right upper lobectomy which compromised the lumen of the right main bronchus, transverse division of bronchus and end to-end anastomosis	November 7 1953	Bronchus healed right middle and lower lobes fully expanded, sputum negative

TABLE III
BRONCHIAL ADENOMA

Case	Sex and Age	Diagnosis	Surgical Procedure	Date	Result
8 J S	F, 24	Bronchial adenoma medial wall of right main bronchus	Wedge resection and transverse suture (Plate II, Fig 3)	June 12 1951	Bronchus healed, lung fully expanded, well to date
9 L. H	M, 43	Bronchial adenoma anterolateral wall, left lower lobe bronchus	Left lower lobectomy and excision of adenoma, preserving a flap of bronchial wall used for reconstruction (Plate II, Fig 4)	June 2, 1952	Bronchus healed, left upper lobe fully expanded, well to date

TABLE 15
BRONCHOGENIC CARCINOMA

Case	Sex and Age	Diagnosis	Surgical Procedure	Date	Result
L. McC	M 57	Bronchogenic carcinoma epidermoid right main bronchus trachea and coryna with lymph node metastases	Resection of right lung lower trachea coryna and medial wall of left main bronchus reconstruction of left main bronchus by transverse suture of left main bronchus to trachea (Plate III Fig 1)	June 1 1951	1 yr survival empyema and fistula developed at site of suture line which healed with drug therapy and drainage died June 14 1952 of carcinoma
V S	M 56	Bronchogenic carcinoma epidermoid, right upper lobe bronchus with lymph node metastases emphysema with poor respiratory function	Right upper lobectomy wedge resection of right main bronchus and transverse suture (Plate III Fig 2)	November 11 1952	Leak at suture line and empyema healed with drainage by February, 1953 well to date
S S	M 58	Bronchogenic carcinoma epidermoid left lower lobe bronchus with lymph node metastases emphysema with poor respiratory function	Resection left lower lobe and left main bronchus end to end anastomosis left upper and left main bronchus (Plate III Fig 4)	April 9 1953	Bronchus healed and left upper lobe expanded pelvic metastasis died August 30 1953 with recurrence of carcinoma in bronchus and mediastinum
13 H F	M 47	Bronchogenic carcinoma undifferentiated superior segmental bronchus left lower lobe with lymph node metastases	Resection of left lower lobe and portion of left main bronchus end to-end anastomosis left upper lobe and left main bronchi (Plate III Fig 4)	April 21 1953	Bronchus healed left upper lobe well expanded well to date
14 A B	M 50	Bronchogenic carcinoma epidermoid superior segmental bronchus left lower lobe with metastasis to one lymph node	Resection of left lower lobe and portion of left main bronchus end to-end anastomosis of left upper lobe and left main bronchi tracheotomy (Plate III Fig 4)	June 13 1953	Emphysema relieved by tracheotomy bronchus healed left upper lobe well expanded well to date
15 C. F	M, 50	Bronchogenic carcinoma epidermoid right main bronchus, with metastases to regional lymph nodes left 8 rib thoracoplasty for tuberculosis, 1946	Resection right main bronchus and right upper lobe end to-end anastomosis of intermediary bronchus to trachea tracheotomy (Plate III Fig 3)	June 8 1953	Bronchus healed right middle and lower lobes expanded well died October 16 1953 of carcinoma in right bronchial tree

TABLE IV (*Continued*)

Case	Sex and Age	Diagnosis	Surgical Procedure	Date	Result
16 J K	M 55	Bronchogenic carcinoma epidermoid apical posterior bronchus left upper lobe no node involvement	Left upper lobectomy left lower lobe bronchus compromised by closure wedge resection and transverse closure	March 12 1954 March 16 1954	Bronchus healed left lower lobe well expanded well to date
17 C B	M 51	Bronchogenic carcinoma epidermoid right upper lobe no node involvement	Resection of right upper lobe and portion of right main bronchus end-to-end anastomosis of right main bronchus and intermediary bronchus (Plate III Fig 3)	May 19 1954	Bronchus healed right lower lobe well expanded well to date
18 B C	M 47	Bronchogenic carcinoma epidermoid right with metastases to trachea and lymph nodes	Right pneumonectomy and resection of lower tracheal carina and portion of left main bronchus end-to-end anastomosis of left main bronchus to trachea (Plate III Fig 5)	June 28 1954	Died July 11 1954 of inadequate pulmonary function anastomosis healed

penetrating trauma of the chest and in whom a tension pneumothorax and/or mediastinal emphysema rapidly develops A bronchial tear should be suspected if following decompression of the tension pneumothorax air continues to bubble vigorously through the water seal system and if the lung fails to expand Bronchoscopy performed immediately following the injury will reveal in most cases the site of the bronchial tear as it usually occurs in either main bronchus at or within a few centimeters of the carina However secondary bronchi may be torn There may be either a partial tear or complete transection of the bronchus A great many of these injuries have ended fatally within a short time following the accident because of failure to make the diagnosis until autopsy revealed the true condition

Prompt recognition of a traumatic bronchial rupture must be followed immediately by thoracotomy and repair of the torn bronchus as illustrated in Cases 3 and 4 By means of an end to-end anastomosis the left lower lobe was preserved in Case 3 The suture of a large tear involving the right main, intermediary and superior segmental bronchi resulted in the salvage of an entire lung in Case 4

If the patient survives the early post traumatic period the unrepaired bronchus heals with either complete occlusion or stricture of the bronchus Bronchial anastomosis is indicated for complete traumatic bronchial occlusion should such a patient be seen months or even years after the initial injury Pneumonectomy is not justified unless pulmonary suppuration is present and this cannot occur in the case of complete occlusion [4,5] The collection of thick viscid mucus within the bronchi of the lung blocked by complete bronchial occlusion must not be mistaken for suppuration The lung itself, although atelectatic undergoes no pathologic change A bronchoplastic procedure as carried out in Case 1, or an end to-end anastomosis as done in Case 2 should be performed to relieve the bronchial occlusion and restore bronchial continuity The atelectatic lung will re expand and resume function if bronchial continuity is restored even years after the initial injury Samson and Evans[6] have recently successfully re-expanded a lung

by means of a bronchial anastomosis in a patient fifteen years after a traumatic bronchial occlusion was sustained

The pulmonary suppuration which will develop if the bronchial tear heals by stricture formation without complete occlusion makes imperative the early diagnosis and resection of the traumatic bronchial stricture and restoration of bronchial continuity by end to end anastomosis By early diagnosis and bronchial reconstructive procedures, the mortality of bronchial rupture can be markedly reduced and lung function preserved

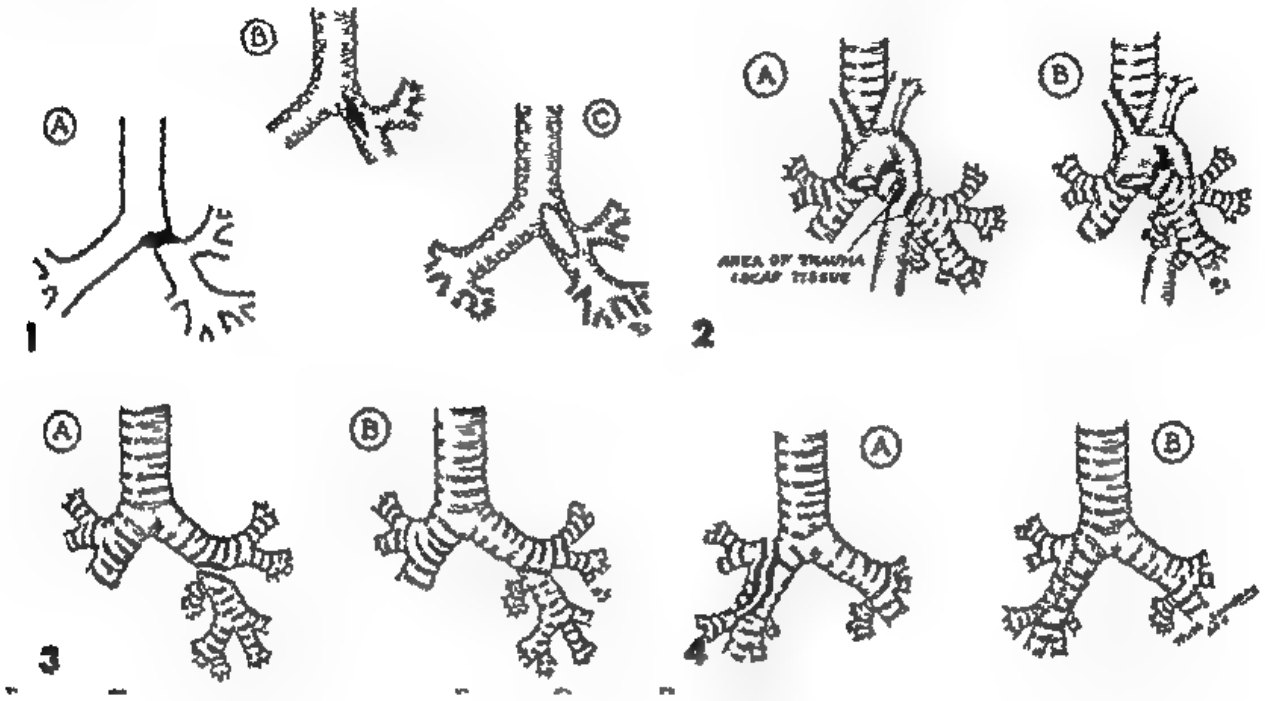

bronchi Suture two hours following injury

TUBERCULOUS BRONCHOSTENOSIS

Healed tuberculous bronchostenosis usually involving the primary and secondary bronchi may be resected and bronchial anastomoses performed If the stenosis involves the main bronchus and the lower trachea, as in Case 5 plastic reconstruction by means of a dermal graft reinforced by steel wire mesh may be utilized after incising the stenotic area Lobectomy or segmental resection may be performed at the same time as the bronchial anastomosis or plastic reconstruction By re establishing bronchial continuity the remaining healthy lobes of lung are preserved, as illustrated in Cases 5 6 and 7 By means of these procedures a total of five lobes of lung were preserved in these patients with tuberculous bronchostenosis There were no complications and no mortalities

BRONCHIAL ADENOMA

Because bronchial adenoma is a tumor of low-grade malignancy it lends itself well to localized resection and bronchial reconstructive procedures in the interest of preservation of healthy lung tissue Only in the presence of distal pulmonary suppuration is the resection of lung tissue justified Case 8 illustrates the preservation of an entire right lung which was healthy in spite of an adenoma in the medial wall of the right main bronchus Wedge resection and transverse suture resulted in complete excision of the tumor with restoration of bronchial continuity

Bronchial adenomas may be so situated that a tumor, in addition to producing suppuration cases it is unnecessary to sacrifice the healthy lung tissue because a bronchoplastic procedure

or bronchial anastomosis may be carried out, which will permit wide excision of the tumor and yet preserve the healthy lobe By means of a flap of bronchial wall it was possible to preserve the left upper lobe in Case 9 Pneumonectomy and loss of function would otherwise

instances pulmonary function may be dimin-
ished
tion
resect
resection and bronchial anastomosis the removal of a carcinoma involving the right

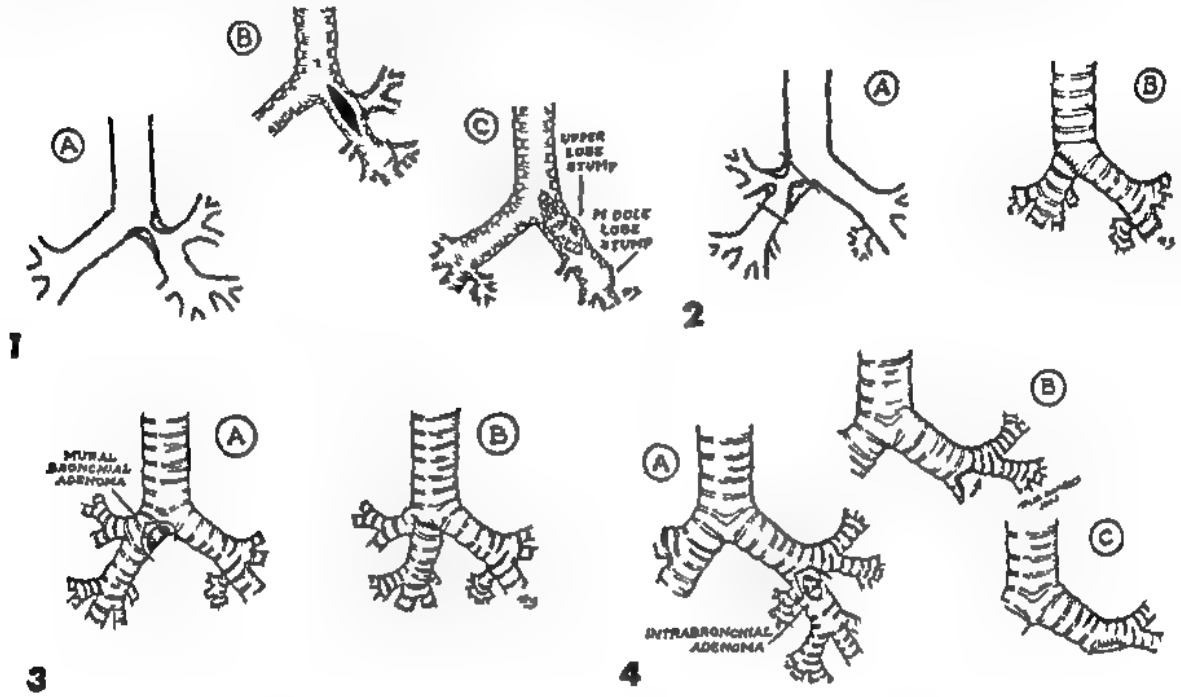

have been necessary for adequate removal of the adenoma

BRONCHOGENIC CARCINOMA

The authors are of the opinion that bronchial

main bronchus was made possible in Case 15 Pneumonectomy was out of the question because a contralateral thoracoplasty had been performed seven years before for tuberculosis

verse suture or dermal graft it is possible to restore bronchial continuity following resection of an entire lung the coryna and a portion of the opposite main bronchus for a bronchogenic carcinoma This procedure, as suggested by Abbott,[7] extends the operability of certain lesions which impinge upon the coryna and trachea, as illustrated in Case 10 End-to-end anastomosis of a main bronchus to the trachea is also possible following resection of an entire lung and coryna as in Case 18 In certain other

function In four patients (Cases 13 14 16 and 18) lobectomy and bronchial anastomosis were performed deliberately on the premise that these procedures were adequate operations for these particular carcinomas

Of the nine patients in whom a bronchial reconstruction was performed following resection for bronchogenic carcinoma a total of ten lobes of lung were preserved One patient died of inadequate pulmonary function twelve days following the operation Three patients died of carcinoma, four, five and twelve months,

respectively, after the operation It is interesting that in two of these three patients a limited resection and bronchial anastomosis were performed as a compromise with pneumonectomy because of poor pulmonary function The remaining patients are alive and well one five, fourteen sixteen and twenty one months respectively, following the operation It is noteworthy that four of these five surviving patients were those in whom limited resections and bronchial anastomoses were performed deliberately as an adequate operation for their respective carcinomas

An empyema developed in two patients following wedge resection and transverse suture in both instances Both responded promptly to treatment A mediastinal and subcutaneous emphysema developed immediately postoperatively in one patient (Case 14) due to a leak of air from the bronchial anastomosis and was relieved by tracheotomy There was one operative mortality (Case 17) twelve days after an end to end anastomosis of the left main bronchus and trachea following resection of the right lung and coryna Postmortem examination revealed the anastomosis to be intact Death was due to inadequate pulmonary function

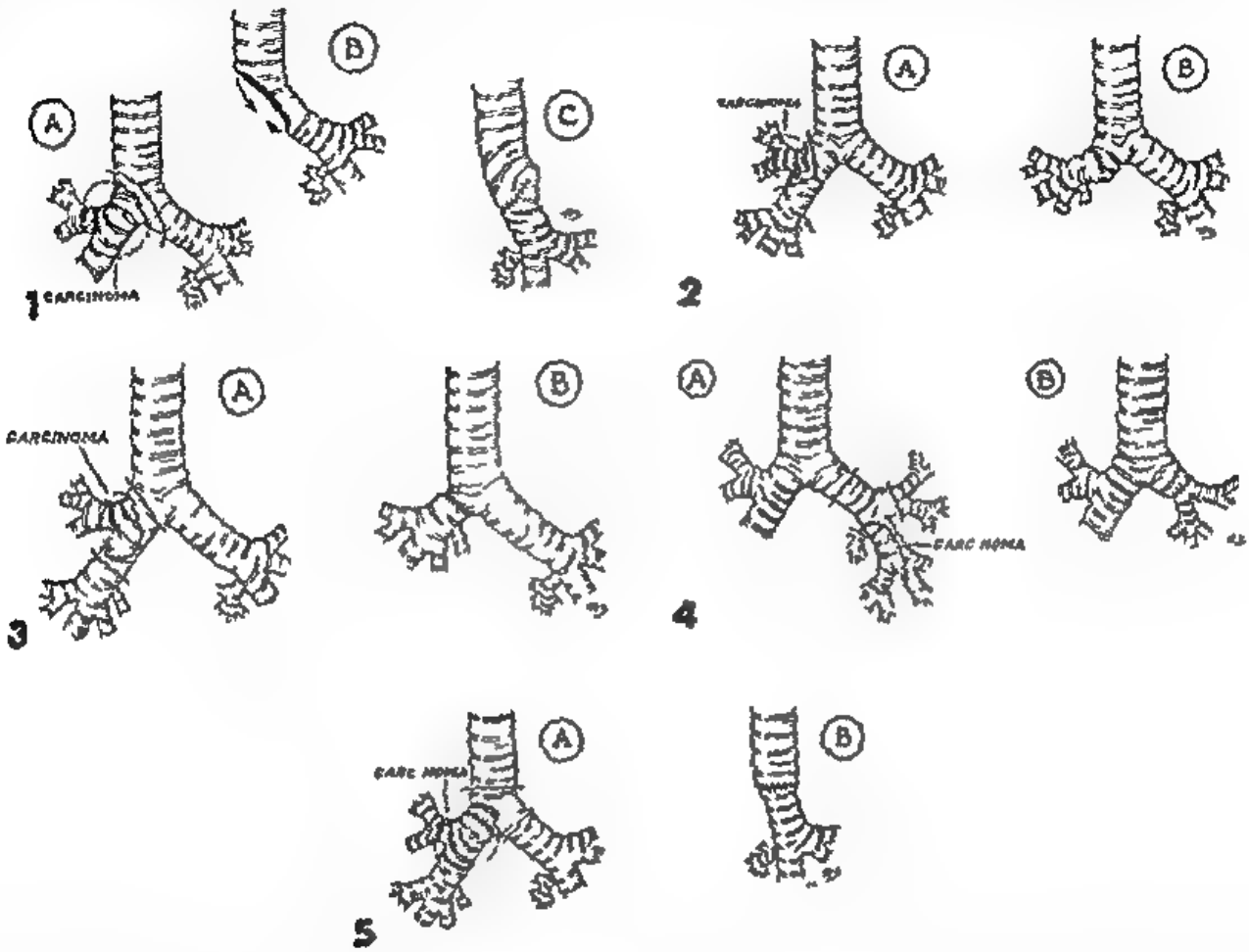

PLATE III Bronchogenic carcinoma Fig 1 (Case 10) Epidermoid carcinoma of right main bronchus, trachea and coryna Resection of right lung lower trachea coryna and medial wall of left main bronchus Reconstruction by

performed as a compromise with pneumonectomy because of poor respiratory function

TECHNIC

The amazing healing powers of the bronchus have been well demonstrated for years by the simple closures of bronchial stumps used by thoracic surgeons Experimental and clinical observation with bronchial anastomoses have further substantiated this fact

No attempts were made to preserve the bronchial vessels in this series of cases The bronchus was cleanly divided and any bleeding from the bronchial vessels controlled Careful suturing was done using interrupted fine cotton or cable wire sutures, so placed as to bring the mucosal edges into careful apposition Insofar as possible the suture was placed through the bronchial wall and submucosa to avoid piercing the mucosa and tied on the outside of the bronchus Care was taken to make the closure of the wall air-tight

Tracheotomy was not performed routinely The bronchial secretions, which were usually troublesome during the first few days postoperatively, were removed in most instances by means of intratracheal catheter and suction In those cases in which pulmonary function is reduced to an extreme degree, tracheotomy should be performed at the time of the operation, as in Cases 15 and 18 Should an air leak at the site of the suture line develop in the immediate postoperative period, tracheotomy should be performed to reduce the intratracheal and intrabronchial pressure

Postoperative bronchoscopy was avoided Such instrumentation early in the postoperative period may traumatize the delicate mucosa at the line of suture or reconstruction Late bronchoscopy for the purpose of inspection of the anastomotic site is unnecessary unless the patient is having symptoms, such as an irritative cough, indicating that sutures are lying within the lumen of the bronchus Should this occur, bronchoscopic removal is indicated

The use of the prone position during any reconstructive procedure involving the bronchus or trachea facilitates the operation considerably from the standpoint of anatomic exposure, anesthesia and maintenance of a clear airway Because the main bronchi are situated posteriorly, the most direct exposure for most bronchial anastomoses is obtained with the patient lying in the prone position In this position the patient tolerates an open bronchus for longer periods of time than in the lateral position because of the absence of the need for positive pressure anesthesia Indeed, the patient may respire room air through the bronchotomy opening for short periods of time with no deleterious effects

The airway remains clear of bloody drainage because any bleeding usually drains out into the pleural cavity rather than into the bronchus

The passage of the intratracheal tube into the contralateral bronchus is usually unnecessary in the prone position However, in the case of extensive resections about the coryna, this is desirable. In some instances in this series of patients the main bronchus was temporarily closed by means of a soft clamp, a sponge or interrupted fine sutures In two instances (Cases 15 and 18) a small intratracheal tube was introduced into the distal bronchus, brought out through the wound, and the remaining lung tissue respired by means of a second anesthetic machine

In the case of bronchogenic carcinoma the prone position makes possible an extensive mediastinal and pericardial dissection even in those instances in which a lobectomy is performed All lymph node–bearing areas can be readily approached

COMMENTS

There can be no question of the usefulness of bronchial suture, bronchial anastomosis and bronchoplastic procedures for traumatic bronchial rupture, tuberculous bronchostenosis and bronchial adenoma These procedures should be considered in the surgical attack on any benign bronchial lesion to avoid unnecessary sacrifice of good lung tissue

The utilization of these procedures in the surgical attack on bronchogenic carcinoma must be carefully considered Inadequate pulmonary reserve and the extension of operability justify their use in certain instances The authors are of the opinion that in the interest of [illegible] mortal-

and bronchial anastomosis may be performed deliberately in those cases in which it is believed to be an adequate operation for the tumor

Our experience with the treatment of bronchogenic carcinoma has indicated that lobectomy, where feasible, yields at least as good results as pneumonectomy, with a lower mortality The mortality rate in our hands for the

239 resections performed for bronchogenic carcinoma during the period from 1945 to 1954 was 10 6 per cent for pneumonectomy and 3 1 per cent for lobectomy (Table v) The survival rates for four years or more for resections done for bronchogenic carcinoma in the

TABLE V

OPERATIVE MORTALITY FOR BRONCHOGENIC CARCINOMA 1945 1954

Type of Resection	Patients (No)	Deaths (No)	Mortality (%)
Pneumonectomy	141	15	10 6
Lobectomy	98	3	3 1
Total	239	18	7 5

years 1945 through 1950 are 25 per cent for lobectomy compared with 13 per cent for pneumonectomy (Table vi) In many instances more favorable lesions such as the well localized peripheral carcinoma, were removed by lobectomy, although this was not entirely true, the indications being in some instances chest wall involvement and poor pulmonary or cardiac reserve

TABLE VI

SURVIVAL RATES OF PATIENTS WITH BRONCHOGENIC CARCINOMA RESECTED 1945 1950

Type of Resection	Patients (No)	Survivors (No)	Survival Rate (%)
Pneumonectomy	83	11	13 2
Lobectomy	40	10	25 0
Total	123	21	17 0

Pneumonectomy is the ideal cancer operation in the majority of bronchogenic carcinomas However a group of localized lesions remains for which lobectomy may be a desirable and practical operation because of the lower mortality rate and the advantages resulting from the preservation of lung tissue In addition to the indications for lobectomy already stated this operation combined with bronchial resection and anastomosis may be considered for the well localized, small centrally located lesions Furthermore this procedure will permit wider excision of the bronchus in those patients in whom limited cardiac or respiratory reserve makes lobectomy imperative

SUMMARY

1 Bronchoplastic procedures are feasible and are indicated under certain conditions to preserve healthy lung tissue A traumatic, inflammatory or neoplastic lesion of the bronchus does not always require resection of all of the lung tissue supplied by the bronchus

2 The authors have used a variety of procedures to restore bronchial continuity in eight men patients The bronchial lesions so treated include traumatic occlusion acute traumatic rupture tuberculous stenosis, adenoma and carcinoma

3 The indications for the use of bronchoplastic procedures with resection for bronchogenic carcinoma in nine patients were made quate pulmonary reserve in three to extend operability in two and deliberately for small centrally located lesions in four patients One operative mortality occurred due to inadequate pulmonary function following resection of an entire lung coryna and trachea Three patients died of carcinoma within one year of the operation The remaining five patients, in four of whom the operation was performed deliberately are alive and well one, five fourteen sixteen and twenty-one months respectively

REFERENCES

1 GEBAUER, P W Plastic reconstruction of tuberculous bronchostenosis with dermal grafts J Thoracic Surg 19 604, 1950

2 GEBAUER P W Reconstructive surgery of the trachea and bronchi late results with dermal graft J Thoracic Surg 22 568 1951

3 GEBAUER, P W Bronchial resection and anastomosis J Thoracic Surg 26 241 1953

4 PAULSON D L Traumatic bronchial rupture with plastic repair J Thoracic Surg 22 636 1951

5 PAULSON D L Plastic reconstruction of the trachea and bronchi Am J Surg 18 403 1952

6 PAULSON D L and SHAW R R Preservation of lung tissue by means of bronchoplastic procedures J Thoracic Surg To be published

7 SAMSON P and EVANS B H Personal communication.

8 ABBOTT D A Experiences with surgical resection of human carcinoma tracheal wall and contralateral bronchial wall in cases of right total pneumonectomy J Thoracic Surg 19 906 1950

XXXI. FUNDAMENTAL CONSIDERATIONS IN MANAGEMENT

110

Impaired Respiratory Function

JAMES L. WHITTENBERGER, M.D., *Boston, Massachusetts*

From the Department of Physiology, Harvard School of Public Health, Boston, Massachusetts

SINCE impaired respiratory function may occur in neuromuscular, cardiac and other diseases in which pulmonic effects are not primary, it is necessary to limit the scope of this chapter. Difficulties remain even if discussion is restricted to chronic pulmonary disease of non specific origin.

A precise definition of impaired respiratory function cannot be given without detailed consideration of cardiorespiratory physiology and the relationship between respiratory demand and respiratory capabilities; consequently only a working definition will be proposed.

In spite of intense interest in the measurement of pulmonary function over a period of years, it must be admitted that only crude information is provided by the usual battery of pulmonary function tests done on a given patient. Microscopic examination, if possible, would reveal many lesions which are undetectable by the best standardized tests. Even radiography, valuable though it is, can be quite misleading from a functional point of view.

Two basic causes underlie shortcomings in the interpretation of pulmonary function tests; one is the lack of sufficiently precise standards of reference, the other is the integration of respiratory and circulatory function at the microscopic level, with the result that disturbances in one system lead automatically to compensatory adjustments in the other. In other words, if ventilation of a lobule is impaired, circulation is also reduced, with passage of time this compensation is often complete, and functionally the lung has merely lost a part of its substance. If standards of reference were sufficiently good, the loss might be detected. In general, however, a given value must be compared with a "normal" range which may include ±10 or 15 per cent of the mean value based on a population previously studied.

Since a patient is his own best control, the patient's symptoms may be the most sensitive guide to the adequacy of respiratory performance. The difficulty in interpreting this estimate is the impossibility of measuring a subjective evaluation. Thus an athlete in the early stages of diffuse pulmonary disease may note that dyspnea occurs at a high level of physical activity which was not previously associated with dyspnea. All pulmonary function tests may give results "above normal" yet such a patient's symptom must obviously be taken seriously. At the same time his symptom of dyspnea cannot be quantitatively compared with the dyspnea sensed by a semi invalid.

With the foregoing reservations in mind one can propose that impaired respiratory function will be understood to mean a significant reduction of respiratory reserve, a loss which an average patient would recognize in the course of his usual activities. At least one of several types of pulmonary function tests would be expected to be significantly below the "normal" limits.

tory impairment is more profitably examined from the point of view of integrated respiratory and circulatory activities. To keep the arterial blood gases normal, the air must go where the blood is and both must have the same rate of replenishment. To be sure, diseases attack primarily one system or the other, in uncomplicated asthma the pulmonary problem starts as one in respiratory mechanics. In a later and extreme form of asthma, or in emphysema associated with chronic bronchitis, non uniform alveolar ventilation is combined with non uniform alveolar perfusion in a system in which

large forces are necessary to drive both air and blood

Since the latter type of pulmonary impairment is probably most common today and is likely to increase in the future, it will receive most consideration in the discussion which follows

PREVENTION OF RESPIRATORY DISEASE

The logical beginning of the management of respiratory impairment is the prevention of respiratory disease Much has been accomplished in the control of industrial lung diseases, although severe problems remain, as in coal miners' pneumoconioses [1,2] The extent to which chronic pulmonary disease in the general population is preventable is not known Some experience suggests that industrial air pollution may contribute to the incidence and severity of chronic pulmonary disease, Flint found that the most common etiologic type of heart disease in an English industrial city was cor pulmonale,[3] Pemberton and Goldberg found a significant correlation between air pollution and deaths from bronchitis [4] Furthermore, there was a high incidence of deaths among patients with chronic pulmonary diseases in the 1952 smog episode in London [5] If this relationship is established, a preventable type of pulmonary disease will have been uncovered, the cost of prevention has not been estimated

Circumstantial evidence suggests that the incidence of pulmonary neoplasms could be substantially reduced if more people were to stop smoking [6-8] Whether other pulmonary diseases are associated with tobacco smoking has not been proved Pulmonary function tests have been quite disappointing to those who have attempted to establish such a relationship On the other hand there is little doubt that some cases of chronic cough associated with chronic purulent expectoration clear up when the habit of smoking is terminated Whether this kind of chronic bronchial irritation is associated with more serious pulmonary disease is not known

Despite its effective protective mechanisms, the respiratory system is basically a large and delicate membrane in close contact with the atmospheric environment Chemical, physical and microbiologic invaders of the lungs must leave their marks in injury and repair, and these must accumulate with age Also the senescent processes of elastic and collagenous tissues are not in abeyance in the lungs Consequently the gains in prevention may be obscured by the losses to senescence in our population

CONTROL OF RESPIRATORY IMPAIRMENT

The next stage in the management of respiratory impairment is the arrest of disease and preservation of function There is, of course, overlap between this and the earlier and later stages of management For example, in cases in which evidence of industrial pneumoconiosis is present, the worker would be removed as effectively as possible from the source of exposure

Having corrected environmental factors to the extent possible, attention should be directed toward the respiratory and general hygiene of the patient Respiratory infections, although not avoidable, should be treated more diligently in this type of patient In more seriously ill patients respiratory infections are notoriously likely to develop into respiratory failure and even death [9,10]

Since tobacco smoke is an irritant, avoidance should be encouraged

Preservation of respiratory function requires, in addition, a consideration of respiratory demand The normal respiratory response to muscular exercise is an excellently adjusted increase of respiratory minute volume in proportion to the increased metabolic demands of the body In states of anxiety, fatigue or poor fitness due to lack of exercise or other factors the respiratory response is exaggerated out of proportion to the metabolic increase, and excess respiratory effort is often associated with pronounced awareness of breathing or dyspnea The respiratory muscles themselves may be "unfit" although this would be difficult to establish

A similar reaction may develop in patients with pulmonary disease who are unnecessarily restricted by doctor's orders or their own fears and lack of motivation As in the case of physical fitness in general, activity and stress breed fitness, inactivity inevitably corrodes fitness Therefore, it appears wise to encourage the habits of regular exercise and other physical activities, including work, up to the limit of tolerance General measures such as maintenance of normal or less than average weight should also be undertaken

MEDICAL TREATMENT AND REHABILITATION

This chapter is not intended to deal with medical management of specific etiologic dis-

ease types such as pulmonary tuberculosis neoplasms allergic asthma etc Some of the measures recommended for treatment of impaired respiratory function will naturally however apply to certain stages of such diseases

As in most diseases the importance of psychologic factors should not be underestimated Strong motivation is effective compensation for even severe physical handicaps in respiratory function Confidence in the physician and the power of suggestion can benefit the patient when medications and physical therapy are of no objectively determinable merit whatever This fact makes the evaluation of a therapeutic agent or method a difficult one indeed

Bronchodilators The abnormal distribution of ventilation and increased air flow resistance which characterize emphysematous changes in the lungs often appear to have a functional component The administration of bronchodilator agents frequently has the effect of diminishing air flow resistance and improving respiratory function Ephedrine epinephrine and other sympathomimetic drugs are effective Agents such as isuprel® (1 3 4 dihydroxy phenyl 2 isopropylaminoethanol hydrochloride 1 200) can be administered as aerosols either alone or in conjunction with O_2 therapy By diminishing bronchospasm these drugs provide the accomplishment of two objectives the distribution of pulmonary ventilation is improved by reduction of the number of high resistance pathways the respiratory muscles need develop less force to provide a given rate of air flow—respiratory effort and work are diminished

Pressure Breathing The mechanics of diseased lungs are very complex Not only are the primary elements of mechanical behavior abnormal but also the degree of involvement is highly variable throughout the lungs The local nature of blebs and cysts and the patchy character of emphysema atelectasis make funct
whole
resistar
reased This results in an increase of the work of breathing and if high resistance is not uniform a distortion of ventilation distribution Distensibility of the lungs is also reduced in part because of loss of lung substance and in part because the high resistance pathways effectively block some portions of the lungs from ventilation The circulation through the lungs may be affected by the lung disease and if pulmonary hypertension is present the distensibility of the lungs may in turn be influenced by the turgor of the vascular bed Lastly as emphysematous lung disease progresses the over all lung volume increases the diaphragm descends and respiratory muscles operate under poor mechanical conditions

Beset by these mechanical problems the respiratory muscles carry out with difficulty their function of providing adequate alveolar ventilation It should cause little wonder then that pulmonary infections cause respiratory failure by increasing metabolic demands at the same time they further impede the respiratory muscles by accentuating air flow resistance and diminishing lung distensibility

Nevertheless the use of external aids to lessen respiratory effort has not been promoted until recently Motley and his associates[1] found that patients were benefited by bronchodilator aerosols and O_2 given by means of special pressure breathing devices These devices gave adjustable degrees of inspiratory positive pressure in a face mask were cycled from one phase of respiration to the other by the patient and had a high flow capacity thus satisfying the inspiratory demand of even dyspneic patients Other investigators have also been impressed with the value of this therapeutic regimen However it is not easy to separate the effects of the bronchodilator and O_2 from those of the pressure breathing In other words could a patient breathing deeply by effort of his own muscles obtain the same benefit from bronchodilator aerosols and O_2?

Fowler Helmholz and Miller[11] compared the effects of bronchodilators and O_2 with and without pressure breathing in a group of patients with chronic pulmonary disease They found definite improvement with bronchodilators and O_2 but were unable to establish a significant effect for the pressure breathing itself It appears likely that if a patient is capable of moving his lungs through a sufficient volume range he can obtain results from O_2 and bronchodilators similar to those obtained with the aid of a pressure-breathing device The value of positive pressure would therefore be in assisting the patient to breathe deeply to a level of lung distention which he was unable or unwilling to achieve by his own efforts

Pressure-breathing devices in general cause hyperventilation and this effect is desirable in a patient bordering on hypoventilation

Other Mechanical Adjuncts In the more

severe phases of chronic emphysema several measures can be undertaken to improve pulmonary ventilation none of which alters the basic disturbances in the lung parenchyma but which permit the respiratory muscles to work more effectively Breathing exercises promote the effectiveness of both diaphragmatic and intercostal muscles abdominal belts and pneumoperitoneum elevate the diaphragm to a more favorable position

Without training one is usually unaware of the extent to which diaphragm abdominal intercostal and accessory muscles participate in the respiratory movements With conscious effort these muscles can be controlled and more effective use can be made of them in cases of emphysema Furthermore trunk movements such as spinal extension are known to cause ventilation of the lungs in apneic individuals [illegible] Changes of posture arm and trunk movements and respiratory muscle re-education may all be used to advantage in breathing exercises for patients with emphysema [illegible]

Elastic and pneumatic abdominal belts tend to compress the abdomen and force the diaphragm upward Although the mechanical advantage of the diaphragm is thereby increased the work which has to be done on inspiration is at the same time increased and the difficulty of distending the abdomen becomes progressively greater as inspiration proceeds Ideally the abdominal wall should be relaxed on inspiration and compressed only on expiration That abdominal belts are not a complete solution to the problem of disturbed mechanics is suggested by the fact that some patients appear to be greatly benefited others are not helped at all

Pneumoperitoneum has been advocated for the same purpose as abdominal belts [illegible] Beneficial results are difficult to predict in a given patient

The increase of tracheobronchial secretions which may accompany infections chemical irritant exposure or autonomic nervous activity suggests the importance of tracheobronchial drainage Most of the therapeutic measures mentioned have been said to promote bronchial drainage Similar claims are made for the use of detergent and proteolytic enzyme aerosols expectorant and other cough mixtures All of these observations may be valid but it is disappointing that there have been few efforts to make an objective and quantitative comparison of different therapeutic methods

Recently Barach and his associates have developed methods for imitating certain features of a cough [illegible] If the method is found to be sufficiently safe it might be of significant value in preventing postoperative pulmonary complications in post thoracotomy patients who are incapable of coughing effectively The machine is connected to the patient by a face mask or mouthpiece a high flow capacity vacuum blower is arranged with valves so that a slowly rising inspiratory mask pressure is converted instantly to a subatmospheric expiratory phase Thus a high rate of air flow is made to occur at the beginning of expiration The lungs must be well distended on inspiration This is accomplished by raising the airway pressure to 30 or 40 mm Hg Since this level of static intrapulmonary pressure has been found to produce emphysema in experimental animals[29] its use should be undertaken with caution in postsurgical patients

Oxygen Therapy Reduction of alveolar ventilation by progressive disease and the continuation of blood flow to poorly ventilated alveoli lead eventually to the inadequacy of arterial O_2 tension and the need for O_2 enrichment of the inspired air This is particularly likely to occur during exacerbations of bronchopulmonary infections Administration of O_2 in these circumstances often is known to be unsatisfactory and sometimes dangerous [illegible] Basically the problem is one of respiratory control mechanisms in which the patient s ventilatory drive has become blunted to CO_2 concentration and is dependent on the presence of anoxemia Administration of O_2 in severe cases of this type removes the stimulus to breathe just as surely as if morphine or other respiratory depressants were administered in the presence of a depressed respiratory center

Although minimal O_2 administration has been recommended for these cases it appears wise to direct attention first to other measures which will improve ventilation of the lungs These measures include vigorous use of bronchodilators, antibiotics (for pulmonary infections which are often inapparent) postural drainage and mechanical aids to ventilation if available If adequate pulmonary ventilation is assured by a mechanical apparatus or is known to occur by measurement of the patient s unassisted ventilation then O_2 can be given in the concentration required to relieve anoxia

Other Forms of Therapy When respiratory impairment is sufficient to cause retention of

CO_2 the patient is not only subject to the hazard of further respiratory depression but is also the victim of symptoms associated with CO_2 itself The latter relate particularly to functions of the central nervous system Such patients are improved by measures which lower the body levels of CO_2

A chemical means for promoting CO_2 elimination is available in the form of a carbonic anhydrase inhibitor (diamox®) (2 acetylamino-1,-3,4-thiadiazole 5 sulfonamide) This drug affects renal function, leading to excess excretion of sodium and CO_2 (as bicarbonate) [22] The lowering of blood CO_2 and metabolic acidosis which result are accompanied by a slight elevation of alveolar ventilation and lowering of arterial CO_2 tension The drug has given encouraging results in the control of chronic emphysema with CO_2 retention

Cortisone and adrenocorticotropic hormone have demonstrated their value in the control of bronchial asthma and bronchospastic crises of emphysema [23] However, the general metabolic and endocrine effects of these drugs are such that they should be used circumspectly, infrequently and only when simpler bronchodilators have failed

CONCLUSIONS

Until asthma and chronic bronchitis can be prevented, chronic pulmonary emphysema will be a common disease and a distressing therapeutic problem Although anatomic damage in the lungs is cumulative and largely irreversible, there is usually a significant component of functional bronchospasm which can be treated The episodes of acute respiratory failure, often associated with infections, are also amenable to treatment, directed mainly at diminishing respiratory effort and increasing alveolar ventilation Between such episodes the patient is often able to maintain satisfactory, if not normal, activities, the degree of improvement may be remarkable in view of the desperate condition of the patient in a respiratory crisis

REFERENCES

1 FLETCHER C M Pneumoconiosis of coal miners. *Brit M J* 1 1015–1065, 1948

2 MOTLEY, H L, LANG, L P and GORDON, B Studies on the respiratory gas exchange in one hundred anthracite coal miners with pulmonary complaints *Am Rev Tuberc*, 61 201, 1950

3 FLINT, F J Cor pulmonale—incidence and aetiology in an industrial city *Lancet*, 2 51, 1954

4 PEMBERTON, J and GOLDBERG, C. Air pollution and bronchitis. *Brit M J*, 2 567, 1954

5 LOGAN, W P D Mortality in the London fog incident, 1952 *Lancet*, 1 336, 1953

6 DOLL, R and HILL, A B A study of the aetiology of carcinoma of the lung *Brit M J*, 2 1271, 1952

7 WYNDER, E L and GRAHAM, E A Tobacco smoking as possible etiologic factor in bronchiogenic carcinoma, a study of 684 proved cases. *J A M A*, 143 329 1950

8 DOLL, R and HILL, A B The mortality of doctors in relation to their smoking habits *Brit M J*, 1 1451, 1954, 2 240, 1954

9 STONE, D J, SCHWARTZ, A, NEWMAN, W, FELTMAN, J A and LOVELOCK, F J Precipitation by pulmonary infection of acute anoxia, cardiac failure and respiratory acidosis in chronic pulmonary disease *Am J Med*, 14 14, 1953

10 SIMPSON, T Acute respiratory infections in emphysema An account of 118 cases *Brit M J*, 1 297, 1954

11 MOTLEY, H L, LANG L. P. and GORDON, B Use of intermittent positive pressure breathing combined with nebulization in pulmonary disease *Am J Med*, 5 853 1948

12 FOWLER W S, HELMHOLZ, M F and MILLER R D Treatment of pulmonary emphysema with aerosolized bronchodilator drugs and intermittent positive pressure breathing *Proc Staff Meet, Mayo Clin*, 28 743, 1953

13 KARPOVICH, P V Adventures in Artificial Respiration New York 1952 Ac

14 SEGAL, M C
Treatmen
Am Rev

15 BARACH, A L, BICKERMAN, H A and BECK G Advances in the treatment of non tuberculous pulmonary disease *Bull New York Acad Med*, 28 353 1952

16 GAENSLER, E A and CARTER, M G Ventilation measurements in pulmonary emphysema treated with pneumoperitoneum *J Lab & Clin Med*, 35 945 1950

17 SEGAL, M S and DULFANO M J Chronic Pulmonary Emphysema, p 139 New York, 1953 Grune & Stratton, Inc

18 BRACKENRIDGE, R D C and JONES, A T Pulmonary emphysema treated by pneumoperitoneum *Brit M J*, 1 1135 1953

19 BARACH, A L, BECK, G J and SMITH, W H Mechanical production of expiratory flow rates surpassing the capacity of human coughing *Am J M Sc*, 226 241, 1953

20 MARCOTTE, R J, PHILLIPS, F J, ADAMS, W L and LIVINGSTONE, H Differential intrabronchial pressures and mediastinal emphysema *J Thoracic Surg*, 9 346 1940

21 COMROE J H, JR. and DRIPPS R D The Physiological Basis for O_2 Therapy Springfield Ill., 1950 Charles C Thomas

22 NADELL, J The effects of the carbonic anhydrase inhibitor "6063" on electrolytes and acid base balance in two normal subjects and two patients with respiratory acidosis *J Clin Investigation*, 32 622, 1953

23 SEGAL, M S and DULFANO, M J Chronic Pulmonary Emphysema, p 107 New York, 1953 Grune & Stratton, Inc

Inhalational Therapy

MAURICE S SEGAL M D AND ERNST ATTINGER, M D, *Boston, Massachusetts*

From the Department of Medicine, Tufts College Medical School and the Department of Inhalational Therapy, Boston City Hospital, Boston, Mass

THE knowledge of the physiopathologic mechanisms responsible for the sequence of events that occurs in the patient with bronchial asthma and pulmonary emphysema is necessary for the correct management The patient with intractable bronchial asthma usually presents a picture of marked physiologic imbalance Evidence of hypoxia cyanosis, dehydration, drug intoxication, disturbed psyche and peripheral vascular shock is usually observed [1] Further disturbances may be noted because of the changes induced by the widespread use of the antimicrobial agents, hormonal and oxygen therapy In fact death may come from any of these enumerated factors Formerly death was more commonly due to asphyxia resulting from the plugged bronchi and bronchioles, oversedation or to the failure of endogenous discharge of adrenal hormones which are necessary in the defense mechanism against stress [2]

The patient with chronic pulmonary emphysema is afflicted with a diffuse, progressive, obstructive and hypoxic type of chronic emphysema in which pathologic distention of alveoli has persisted for some time [3] This type of emphysema commonly occurs with or as a complication of chronic bronchial asthma, but may be associated with practically all pulmonary diseases, particularly bronchiectasis serious pulmonary infection, the pneumoconioses sarcoidosis and tuberculosis The common denominator appears to be bronchiolar constriction and retardation of expiratory air flow [3] Clinical manifestations depend upon the degree of pulmonary insufficiency They may range from coughing wheezing and shortness of brea[illegible]
effects
retenti
chronic

final stages [4] Many patients do not survive to the final stage

There appears to be an increasing incidence of chronic pulmonary emphysema in this country which may be related directly to the increase in industrial and environmental inhalant vapors, gases, fumes, dusts and tars, or indirectly to the increased incidence of respiratory infections or allergies under these circumstances These various irritants to the bronchioles produce progressive narrowing and eventually the typical overdistention of the lungs seen in emphysema This may well be the price we have to pay for our advances in living and in industry

The various factors responsible—allergic, hormonal, psychic, occupational, infectious, etc —should be analyzed in every patient The

[illegible]
scription' rather than one that can be written on the doctor's prescription pad Repeated and long periods of hospitalization along with a variety of mechanical breathing apparatus, physiotherapeutic rehabilitation employing diaphragmatic breathing training,[5] antimicrobial and hormonal agents, and the careful use of therapeutic aerosols and oxygen therapy make it possible to prolong life and restore many of these patients to a life of economic usefulness [3]

This discussion will be limited to only several

(adrenergic agents), pamine bromide (anticholinergic agent) pancreatic dornase (pus liquefying enzyme), cold water vapors (humidity therapy), alevaire® (detergent agent) and dusts of cortisone acetate and hydrocortisone Equipment for the preceding (air pump and Neb-*ELizer* croup tent apparatus)

(2) Oxygen therapy Reactions to the use of

oxygen the carbon dioxide intoxication syndrome—respiratory acidosis

(3) Pressure breathing therapy Intermittent positive pressure breathing—inspiratory (IPPB/I), alternating positive-negative pressure breathing (P and N)

THERAPEUTIC AEROSOLS

Bronchodilator Aerosols Aerosols of the proved sympathomimetic drugs vaponefrin (2 25 per cent racemic epinephrine) and isuprel® 1 200 (dihydroxyphenylisopropylaminoethanol) are of great value for the relief of bronchospasm and in expectoration Our laboratory studies employing the protection study technic revealed that isuprel offered the best protection against the effect of acetylcholine and vaponefrin the best against the effect of histamine[6] As little as approximately 0 05 to 0 10 cc of these preparations nebulized by two to six compressions of the hand bulb of the vaponefrin nebulizer may abort or relieve a mild bronchospastic episode The relief however may be short lived Treatments should not be repeated more often than hourly intervals This technic has replaced to a large measure the use of epinephrine with the hypodermic syringe More severe bronchospasm may require 0 5 to 1 0 cc nebulized by continuous flows of oxygen[7] A Y tube or simple button like opening into the oxygen or air feed line allows interruption of aerosol production during expiration This treatment generally requires ten to fifteen minutes when 5 L per minute flows of oxygen are employed We have recently used the simple portable Eliot Air Pump unit* for the production of continuous aerosols of all types It requires an A C outlet for electric power and does away with the need for the oxygen tank and regulator The air flow rate can be adjusted by a simple turn of an air jet valve to the requirements of the therapeutic agent (rate of delivery cc per minute) The bronchodilator aerosols may also be introduced along with intermittent positive pressure (inspiratory) thus obtaining the physiologic advantages of bronchodilatation and improved alveolar ventilation[8] A useless cough is often converted to a productive one with this therapy

We have investigated several new adrenergic bronchodilator drugs particularly dapanone®* 5 per cent and dylephrin † These bronchodilator agents are capable of improving the time—vital capacity relationships and maximum breathing capacities of mild and moderately ill patients with chronic bronchial asthma Dylephrin (2 50 per cent racemic epinephrine plus atropine) has the advantages of an added anticholinergic agent in a stable form It appears of value in the wet asthmatic and in those patients with associated disorders particularly cardiac asthma

Fortunately refractoriness to any one of these preparations apparently is not immediately passed on to the others The individual toxicities and degrees of pressor response should be noted by the physician and patient in selecting the preferred drug Clinically one patient's asthma frequently responds better to one of these drugs than the other The reverse order of efficiency may be true in the same patient at another time

Pamine Bromide Aerosols It was suggested that the combination of a good antihistaminic and a good anticholinergic drug with bronchodilator properties would be a most ideal therapeutic agent in bronchial asthma[1] Parasympatholytic agents particularly atropine scopolamine and bellafoline have demonstrated excellent anticholinergic protection in our laboratory[9] The mild central sedative effects of these alkaloids on the mucous membrane of the tracheobronchial tree may lead to further inspissation of the already semi solid plugs making coughing and their expulsion more difficult

We have employed aerosols of pamine®‡ (epoxytropine tropate methylbromide) an anticholinergic agent for the relief of bronchospasm[10] Doses of 0 33 mg dissolved in 1 0 cc of saline or distilled water were employed with the direct nebulizer oxygen technic and also with the nebulizer IPPB/I Bennett unit valve In a series of thirty four patients with mild chronic bronchial asthma an average improvement of 300 cc in the vital capacity was noted after treatment with 1 cc pamine aerosols The average improvement though lower com

* Manufactured by Eliot Medical Plastics, Inc Lynn Mass

* Kindly supplied by Sharp & Dohme Inc., Philadelphia Pa

† Kindly supplied by Irwin Neisler and Company Decatur Ill

‡ Kindly supplied by the Upjohn Laboratories, Kalamazoo Mich

pares favorably with that noted with several adrenergic aerosols studied in a similar group of patients in our laboratory [11] No side reactions were observed with pamine aerosols

In a series of gastric antisecretory compounds under investigation pamine was found to be one of the most effective adjuncts with the least troublesome reactions [12] Anticholinergic aerosols such as pamine may be of some value in the depleted sick asthmatic who is hypotensive and sweating profusely and may be considered to exhibit a systemic picture of parasympathetic stimulation We are presently exploring the advisability of combining pamine with an effective antihistaminic or adrenergic aerosol

Pancreatic Dornase Aerosols (Pus Lytic Enzyme) In the presence of bronchial infection, bronchiectasis or viscid, tenacious, mucopurulent secretions, the use of a new pus liquefying enzyme, pancreatic dornase * as a therapeutic adjuvant may be most helpful [13] The harmful potentialities of these secretions by obstructing airways and acting as a culture medium for infectious microorganisms is recognizable The rapid and safe evacuation of these secretions in the simplest possible manner is a problem of great importance The use of dornase prior to and after lung operations in asthmatic patients may make it safer for the thoracic surgeon and may furthermore increase the patient's chances for a more prompt recovery, freer of complications which may be crippling or even fatal

Pancreatic desoxyribonuclease (pancreatic dornase) is prepared from beef pancreas Desoxyribonucleoprotein is an important constituent of purulent exudate and it determines the character, viscosity and amount of sediment of such exudates [14] Desoxyribonuclease, whether of streptococcal origin (streptodornase) or of pancreatic origin (pancreatic dornase) is a pus liquefying enzyme and is capable of degrading desoxyribonucleoprotein [15 16] The action of pancreatic dornase is primarily one of depolymerization and but little degradation of desoxyribonucleoprotein occurs [17] The absence of appreciable amounts of noxious degradation products which might be absorbed systemically, permits its relatively safe use We have not observed any side effects in our preliminary series of treated patients

Nevertheless because of the protein nature of pancreatic dornase allergic reactions should be watched for in allergic or previously sensitized subjects Usually one may observe decreased viscosity of sputum, greater ease of expectoration and a more productive cough then gradual diminution, and finally, following the evacuation of secretions, less bronchoconstriction

We have employed dosages of 50 000 to 100,000 units per treatment, one to three treatments daily for one to six days as a full course of therapy Clinical improvement, decrease in cough and volume of sputum may be used as a therapeutic guide for dosage and continuation of therapy The dornase is mixed with 1 or 2 cc of a buffer solution (Sorenson) or saline shortly before its administration One cubic centimeter of a potent bronchodilator aerosol should be added to the mixture when bronchoconstriction is evident The pancreatic dornase solution is aerosolized with the direct vaponefrin nebulizer oxygen flow technic,[7] or with the nebulizer Eliot air pump unit or with the intermittent positive pressure nebulizer-Bennett valve unit [8] The air or oxygen flow rates should be kept at 4 or 5 L per minute flow to avoid foaming in the nebulizer

Continuous Aerosol Therapy with Cold Moist Air and or Aleaire There is suggestive evidence that infection of the respiratory tract may depend upon changes in the physiology of the respiratory tract itself The high incidence of upper respiratory infections in our New England states in the late fall and winter months may be precipitated in large part by the hot, dry air present in homes and offices, tending to dry the lung tissues to some extent This change in pulmonary physiology may predispose to infection This is a particular problem in the management of recurring bronchitis, especially in asthmatic children and to a lesser extent in the adult patient with chronic sinobronchitic disease asthma and emphysema, in whom the allergic hunt has not been revealing The bronchitic attack frequently triggers a bout of asthma and generally is responsible for the intractable course particularly in the adult group

Humidification therapy should be considered in the treatment of these patients [18] The use of the steam kettle and the high humidity steam room is an archaic mode of achieving such therapy Unfortunately, it is not relatively

* Kindly supplied by Sharp & Dohme Inc Philadelphia, Pa

simple to attain nearly 100 per cent water-vapor saturation in an environment of about 70°F (or slightly lower) Even when this is achieved at the oropharynx, the inspired air enters the bronchial tree where the temperature is 90°F or above (with fever) The air must not only be fully saturated, but also contain fine moist droplets to ensure the high percentage of humidity as it passes into the lungs [19]

The continuous administration of cold water vapors or non-toxic detergent aerosols (alevaire) is most effective therapeutically when introduced into enclosed oxygen tent units The therapeutic objectives are the following first, high humidity, second, stability of small particle size aerosols, third, adequate cool temperature control within the tent, and fourth, prevention of "raining out" on the patient or in the tent due to the formation of loose droplets of moisture when the humidified, moisture-laden air becomes rapidly dehumidified by impact with cold currents of air

We have found the NebELizer-Permatent croup apparatus* simple, practical and convenient for prolonged nebulization of cold water vapor or alevaire [20] The NebELizer apparatus* produces a continuous fine fog of water or alevaire, originating from the attached 500 cc reservoir of solution [21] The patient's head is placed in the enclosing transparent plastic Permatent unit A single oxygen tank and regulator set at flows of 12 L per minute, attached to the special adaptor of the NebELizer, insures continuous nebulization, without "rain outs" of large particles onto the patient Water vapor saturation over 90 per cent, temperatures below 70°F and oxygen concentrations between 40 and 50 per cent can be obtained quickly and maintained comfortably within the tent with this technic When employed as a home croup unit the NebELizer can be attached directly to the ABC plastic face tent* or to the O E M meter mask † The air pump unit may be substituted for the oxygen tank when intermittent therapy for periods up to twenty to thirty minutes are considered satisfactory The oxygen nipple feed, which is marked for the Permatent entrance, is closed off with this technic and the flow rates may then be reduced one-half

Employing alevaire* (triton, sodium bicarbonate, glycerin) we generally advise 100 per cent concentrations with alternating cold water vapor therapy—500 cc of each Alevaire helps to lower the surface tension of the adherent mucopurulent secretions and may thus act as a cleansing agent This has proved most helpful in the management of troublesome bronchitis in small children and adults Therapy may be continuous for one or more days or intermittent as needed We have not observed any toxic effects from alevaire therapy However, in the enfeebled patient, unable to expectorate freely, the adequate use of repeated tracheal catheter aspirations or, when available, the use of exsufflation should be resorted to, in order to prevent the literal "drowning in their own secretions" which may be noted in some of these patients [22 23]

We have employed dusts of cortisone acetate and hydrocortisone, cortef† acetate and emulsions of hydrocortisone, for topical nasal therapy in some of the patients treated in this series during periods when they were not receiving any other form of hormonal therapy A total of eighty-two patients were treated with either cortisone (thirty-seven patients) or hydrocortisone (forty-five patients) dusts Their complaints centered about the following seasonal hay fever, perennial vasomotor rhinitis, nasal polyposis, recurring sinobronchitis and the common cold The cortisone acetate was prepared in a 5 mg capsule and the hydrocortisone acetate in a 15 mg capsule The gelatin top of the capsule was removed and the bottom part of the capsule filled with the powder was seated in the Upjohn plastic powder inhaler The nasal tip was placed into the nares and the patient instructed to sniff deeply and slowly while squeezing the bulb When there was evidence of marked nasal obstruction, each treatment was preceded by spray or displacement therapy with an effective nasal vasoconstrictor to insure more successful deposit of the dust The patients were permitted to take two or three sniffs into each nostril at one to two-hour intervals as needed The majority of the patients (72 per

* Manufactured by Eliot Medical Plastics Inc, Lynn, Mass

† Manufactured by O E M Corporation E Norwalk, Conn

* Kindly supplied by Winthrop-Stearns Inc., New York N Y

† Kindly supplied by The Upjohn Company Kalamazoo, Mich

cent) noted some relief from itching, cessation of rhinitis, lessening of the postnasal drip and relief from headaches These effects were but short lasting in most applications Nevertheless, they were considered of some definite topical value There were no systemic effects noted and the main side effect was "caking of the nares" in some patients Even this appeared better tolerated than the rhinorrhea in some On the whole the better results were observed in the patients treated with hydrocortisone acetate dust A hydrocortisone emulsion 15 mg per cc, was tolerated fairly well when employed in the form of continuous nasal nebulization, using 1 cc with the vaponefrin nebulizer-nasal tips oxygen technic and usually gave adequate relief from the associated nasal obstruction An interesting trial with hydrocortisone dust aerosols was made in seven patients with severe common colds during the winter months Five described reduction in the manifestations and duration of their colds' (rhinitis) and nasal obstruction and sinus pain Two patients had no benefit Further studies with combinations of antihistaminic and hydrocortisone dusts in similar problems are under way The absence of systemic effects with this form of therapy, employing these particular drugs, and their peculiar anti inflammatory properties at the shock organ-nasal site would indicate their possible usefulness in the aforementioned types of patients This may serve as a boon to hay fever subjects and may permit smaller systemic dosage with hydrocortisone or hyposensitization therapy during seasonal treatment

OXYGEN THERAPY

TH [illegible]

centration of oxygen desired, should be considered in selecting the type of equipment to be used[1] Unfortunately, most patients in status asthma tolerate poorly the tight fitting rubber face masks which are necessary when concentrations of oxygen above 60 per cent are indicated The newer types of "iceless" refrigeration tent units are comfortable and effective means of administering oxygen in concentrations of 40 to 60 per cent However, they involve costly apparatus and maintenance The Permatent apparatus[24] has proved ideal for routine ice tent-administered oxygen and permits average concentrations of 50 to 60 per cent with temperatures below 70°F The simple ABC Plastic Face Tent[25] supplies average concentrations of 50 per cent oxygen in the inspired air with oxygen flow rates of 6 L per minute The patients do not complain of claustrophobia or a sense of suffocation *

In general, there has been an overemphasis on the danger of inducing the carbon dioxide intoxication syndrome and respiratory acidosis by the sudden administration of high concentrations of oxygen in patients with classic intractable bronchial asthma This danger, however is always present in patients with chronic hypoxia, secondary to chronic pulmonary emphysema or chronic pulmonary heart disease, particularly if respiratory depressing drugs are administered preceding or along with the high concentration of oxygen[3] In these patients the nasal catheter-humidification technic is best employed Initial low concentrations of about 30 per cent with flow rates of 4 L per minute should be used The flow rates may be cautiously increased by daily increments to 6 L per minute and subsequently the therapy may be maintained more simply and safely with the ABC Plastic Face Tent

The medullary respiratory centers in these patients appear to have lost their sensitivity to the pCO_2 stimulus for respiration (centrogenic drive) The chemoreflex drive for respiration (the hypoxic stimulus from the sensory nerve ending in the carotid and aortic bodies) is then mainly responsible for maintaining respiration The sudden injudicious relief of hypoxia may be followed by a breakdown in the homeostatic mechanisms sustaining respiration and further hypoventilation may ensue The carbon dioxide retention usually brings about a compensatory increase in the alkali reserve (metabolic alkalosis) and a fall in serum chlorides and increase in urine chlorides Greater increase in the arterial pCO_2 and content may follow, and ultimately respiratory acidosis with a drop in arterial pH These factors appear primarily responsible for producing weakness headache, air hunger, neurologic

* An analysis of alveolar ventilation reveals that for most pulmonary patients an oxygen concentration of 30 per cent is sufficient for normal arterial blood saturation

manifestations, drowsiness, coma, delirium and death, which may develop progressively under such conditions

This troublesome syndrome should not occur if one does not further depress respiration by the use of the respiratory depressing drugs (e g , [illegible]

patient is avoided [illegible]

Should respiratory depression occur following the administration of one of the opiate respiratory depressing drugs or demerol,® intravenous nalline® (N-allylnormorphine hydrochloride) is the antagonist of choice [26 27] Five to ten mg injected intravenously followed by a slow drip of 10 mg of nalline in 1,000 cc of glucose in water will, as a rule, increase ventilation promptly This remarkable "opiate antagonist" should be in the doctor's bag at all times

A carefully graded program of oxygen therapy should be employed in these patients [28] consisting of daily increases in concentrations at the beginning of therapy and a gradual daily reduction toward its cessation At the outset one should employ flows of 1 L per minute with the nasal catheter humidified oxygen technic The flows may be increased 1 L daily until 6 L per minute flows of oxygen are obtained [21] A concentration of 38 per cent oxygen in the inspired air can be obtained at this flow Some variations in the flow rates may be necessary from time to time

A very gradual reduction in the pulmonary ventilation may follow this therapy This slow change in ventilation permits the progressive development of further compensatory metabolic alkalosis, and prevents a sudden drop in arterial pH There may also be observed a [illegible] pCO_2 and CO_2 content [illegible]

The sensitivity of the medullary respiratory center to pCO_2 may be restored with a graded oxygen program

The treatment of respiratory acidosis[8] has been summarized in Table 1, and centers about [illegible]

[illegible] "treating" hypoxia with oxygen concentrations about 50 per cent, will encounter this syndrome all too frequently in patients with chronic hypoxia secondary to chronic pulmonary emphysema and pulmonocardiac disease The most important aim in the treatment of respiratory acidosis is to improve ventilation for only by doing so can one rid the blood and

TABLE 1

TREATMENT OF RESPIRATORY ACIDOSIS*

1 Preventive (Best Treatment)
   (a) [illegible]
   (b)
   (c)
   (d)
   (e) Vigorous antimicrobial therapy
2 Etiologic
   (a) Drug intoxication
      Opiates—N allylnormorphine
      Barbiturates—picrotoxin
   (b) Acute obstruction of airways
      Bronchoscopy
      Tracheotomy
3 Symptomatic
   (a) IPPB/I Bennett unit
   (b) Mechanical respirator chambers (Emerson Drinker units)
   (c) Emergency pneumoperitoneum
   (d) Graded program of oxygen therapy
   (e) Etiologic treatments when indicated

* From Chronic Pulmonary Emphysema Physiopathology and Treatment by M S Segal and M J Dulfano Courtesy of Grune & Stratton Inc New York 1953

tissues of the accumulated excess of carbon dioxide, and permit the respiratory centers of the medulla to regain their normal sensitivity Emergency treatment should center about one or more of the following measures The use of IPPB/I with Bennett valve, employing 30 per cent concentrations of oxygen and bronchodilator aerosols, the use of respiratory body chambers (Emerson and Drinker types), institution of pneumoperitoneum the graded program of oxygen therapy just described and finally etiologic therapy when indicated These measures may be life saving when employed early

PRESSURE BREATHING THERAPY

Physiology of Pressure Breathing The effects of pressure breathing on ventilation and circulation have been the subject of considerable discussion in recent years [29 31 41–43 53] Numerous mechanical devices have been widely employed in a variety of ventilatory disorders

The positive pressure applied during pressure breathing inflates the lung to a greater extent than normal inspiration, thereby provid

ing better ventilation and extensive inspiratory bronchodilation with more uniform ventilation However, it should always be kept in mind that this form of therapy may produce untoward changes in cardiopulmonary dynamics unless properly employed

The pressure volume diagram as developed by Rahn Fenn and Otis[30-33] is especially helpful in the understanding of the mechanics of breathing This reveals that vital capacity

at some undetermined point The residual capacity is much greater with continuous positive pressures because the expiratory muscles are unable to deflate the chest against the pressure during expiration Furthermore some 200 to 500 cc of blood are squeezed out of the lungs by the developed positive pressure, thus adding further to the increase of residual capacity With breathing at a continuous positive pressure of more than 9 mm Hg the chest never comes to rest because the patient continuously exerts some expiratory pressure even during inspiration When breathing against negative pressure the reverse occurs continuous inspiratory pressure is exerted by the patient in order to prevent the chest from collapsing

Hence continuous pressure breathing may increase the work and fatigue of breathing This disadvantage can be mitigated by the use of IPPB The latter, however may introduce the hazard of hyperventilation and acapnia Cournand and his group[34] have shown a regular rise of pH with concomitant drop of arterial pCO_2 corresponding to an increase in minute volume from 23 to 132 per cent during IPPB/I, depending on the type of mask pressure used At positive pressures of more than 40 to 50 mm Hg air leakage occurs and at pressures of 60 to 100 mm Hg the lung ruptures[35] Extreme negative pressures lead to vasodilation and finally pulmonary hemorrhage Injury to the lung itself is caused by overdistention[36] the distention being related to time as well as to the pressure exerted Hence it would appear that a high pressure applied over a short period of time might be safer than a lower pressure applied over a longer period of time

Positive pressure may be transmitted into the gastrointestinal tract and lead to distention of the stomach and intestines This may produce undesirable vagal reflexes following the gastrointestinal dilatation, increased difficulties of expanding the lungs by any means and actual retardation of the venous return by a tense abdomen

During deep breathing the stroke volume of the two ventricles is different[40] The increase in intrathoracic pressure during expiration reduces the filling pressure of the right heart and therefore the stroke volume At the same time the output from the left heart is increased because of increased return from pulmonary circulation

In IPPB the same mechanism comes into play in reverse fashion, but the decrease of right heart output during rising mask pressure may be made up during the phase of falling mask pressure The reverse occurs in the left heart but with limitations, because increased output during inspiration with IPPB can be maintained only during short periods (three to five pulses) by displacement of pulmonary blood If the inspiratory mask pressure is prolonged, the arterial pulse pressure decreases after the initial rise Thus the variation in stroke volume in the right ventricle is the important part to consider in relation to changes in cardiac output

The right ventricular net filling pressure during IPPB is decreased during periods of increased intrapleural pressure The reverse occurs during periods of decreasing intrapleural pressure Starling's law postulates that the deficit in cardiac output during increased intra-

tion may be complete

Depending on the presence of normal circulating blood volume, existing vascular tone and capacity of reflex vasoconstriction, the peripheral pressure rises with the rise of right auricular pressure, thus reconstituting the venous pressure gradient The increased peripheral pressure increases the capillary filtration pressure resulting in water loss to the tissues It has been shown[42] that positive pressure breathing for thirty minutes at 30 mm Hg causes a loss of 4 per cent of blood volume to the tissues

for hyperactive sympathetic pathways where maximal reflex vasoconstriction has already been utilized

In order to compensate for the decreased right ventricular output during the inspiratory phase of rising intrathoracic pressure an ideal mask pressure with the following characteristics has been proposed [38] (a) Gradual increase to a maximum of 25 cm H_2O during inspiration, (b) rapid pressure drop early in expiration with mean pressure during expiration near to zero (c) inspiratory time should not exceed expiratory time thereby allowing as many heart beats to occur during expiration with increased stroke volume as during inspiration

Maloney et al [4, 44] have repeatedly stressed the advantage of positive and negative pressure breathing in the presence of respiratory failure and/or circulatory embarassment the IPPB/I type machines causing a decrease in cardiac output which may be very serious They found that cardiac output and arterial blood pressure varied with the mean airway pressure during the respiratory cycle rather than with any particular wave form

Present Studies In our most recent studies with pressure breathing we have employed the Bennett [38] Halliburton Emerson M S A and Vent EL-Aire units for IPPB/I the Eliot Exsufflator[23] to simulate the cough mechanism and the Vent EL-Aire for positive and negative pressure breathing Employing a four channel direct writing oscillograph we simultaneously recorded arterial pressures peripheral venous pressures mouth or esophageal pressures and pneumotachographic tracings

Stroke volumes were calculated with Starr's formula[45, 46] for direct arterial measurements this method allowing the calculation of rapid changes in stroke volumes The stroke volumes of both ventricles during pressure breathing being different the latter method will probably not give absolute values but should at least give some indication as to the degree and direction of the variation in stroke volume

The results of our preliminary studies appear to be of interest * With the exception of the M S A apparatus all of the IPPB machines employed produce a mask pressure curve of the type III described by the Cournand group The end of the inspiratory phase occurs when the peak of the mask pressure is reached The inspiratory time at identical pressure settings may vary considerable from patient to patient and also in the same patient as the duration of IPPB treatment goes on Figure 1 shows a typical example mask pressure set at 26 cm H_2O At the beginning the mean mask pressure* is 12 15 cm H_2O inspiratory time is 1 8 seconds the expiratory time 1 second respiratory rate has fallen to 15 the pulse rate has risen to 92 The arterial pressure was 136/80 mm Hg at the end of inspiration with a reduction of the stroke volume of 7 3 per cent and 107/65 at the end of expiration with a reduction of stroke volume of 5 8 per cent The respiratory changes in venous pressure become apparent 11 cm H_2O during late expiration—early inspiration and a rise to 13 cm H_2O during late inspiration—early expiration After ten minutes of treatment the mean mask pressure [illegible] 13 8 cm H_2O Inspiration time varies from 2 2 to 2 8 seconds expiration time from 1 4 to 1 [illegible] seconds respiratory rate 14 pulse rate 102 Arterial pressures and stroke volume are the same as at five minutes but the changes in venous pressure now range from 12 to 19 5 cm H O

Figure 2 demonstrates the physiologic changes in an asthmatic subject after fifteen minutes of breathing with the Vent EL Aire unit † Mask pressure is set at 26 cm H_2O the mean mask pressure has risen from 6 5 to 9 3 cm H_2O inspiratory and expiratory time are equal both having dropped from 2 2 to 1 3 seconds The respiratory rate has risen from 14 to 22 5 and the pulse rate has fallen slightly the end of expiration with no change in stroke volume as compared to ambient air breathing After five minutes of treatment the mean mask pressure has risen to 13 3 cm H_2O the inspiratory time is variable from 1 8 to 3 seconds the expiratory time 1 4 to 1 6 seconds The respiratory rate has fallen to 15 the pulse rate has risen to 92 The arterial pressure was 136/80 mm Hg at the end of inspiration with a reduction of the stroke volume of 7 3 per cent and 107/65 at the end of expiration with a reduction of stroke volume of 5 8 per cent The respiratory changes in venous pressure become apparent 11 cm H_2O during late expiration—early inspiration and a rise to 13 cm H_2O during late inspiration—early expiration After ten minutes of treatment the mean mask pressure [illegible] 13 8 cm H_2O Inspiration time varies from 2 2 to 2 8 seconds expiration time from 1 4 to 1 [illegible] seconds respiratory rate 14 pulse rate 102 Arterial pressures and stroke volume are the same as at five minutes but the changes in venous pressure now range from 12 to 19 5 cm H O

* We gratefully acknowledge the assistance of Dr R G Monroe Assistant Resident in Medicine Third Medical Service (Tufts) Boston City Hospital in assisting in these studies

* The mean mask pressure has been obtained by planimetric measurement of three to six respiratory cycles according to the formula

$$\text{Mean Mask Pressure} = \frac{\text{Calibration Factor} \times \text{Area mm}^2}{\text{X Axis mm}}$$

† Manufactured by Eliot Medical Plastics Inc., Lynn Mass

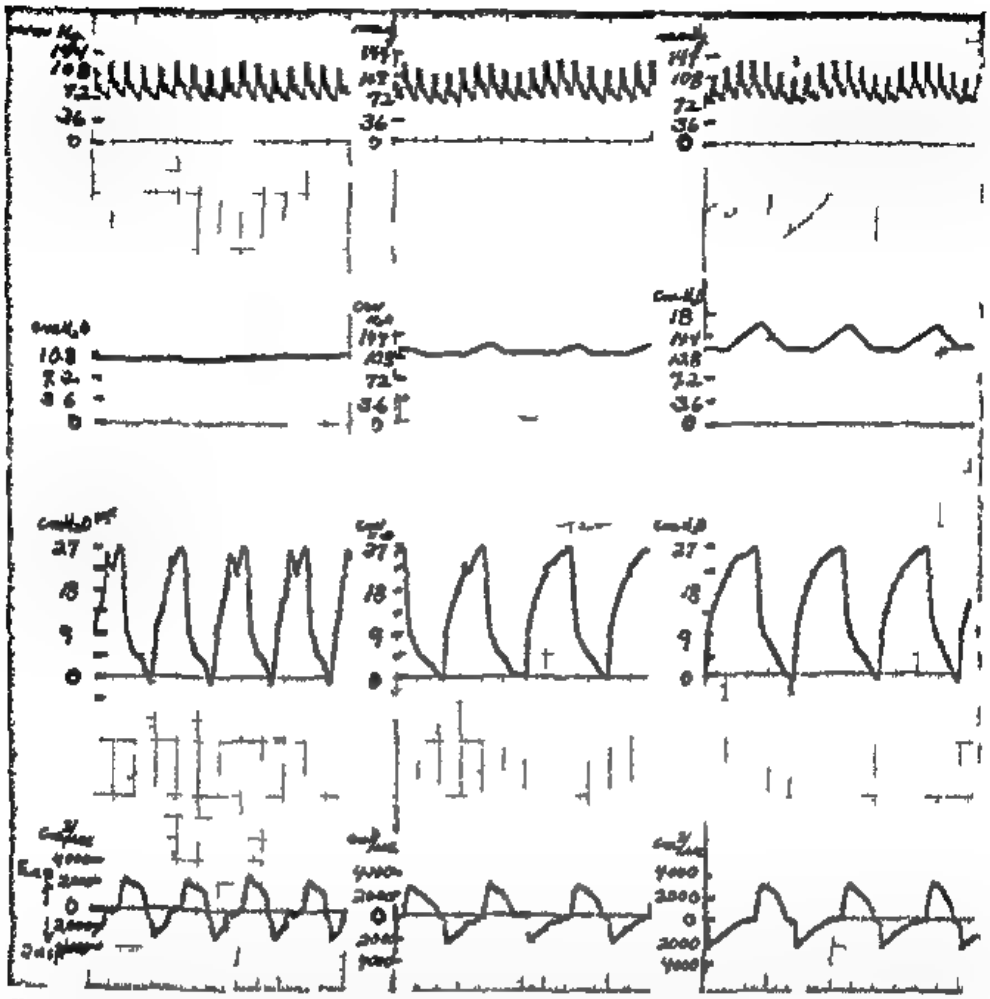

FIG 1 IPPB/I (Bennett valve) mask pressure at 26 cm H O After 1 5 and 10 (left to r ght) of treatment record ngs f om top to bottom are arter al pressu e venous pressure *mouth pressure and pneumotachogram The paper speed was 5 mm per second (Note* insp at on air flow pattern downward exp rat on upward)

from 64 to 60 Arterial pressure recorded during late inspiration early expiration at the begin ning of treatment was 129/86 mm Hg with an increase in stroke volume of 18 per cent as compared to ambient air breathing and after fifteen minutes treatment is 129/93 mm Hg with a decrease in stroke volume of 3 per cent The arterial pressure during late expiration early inspiration was 111/7- mm Hg with a reduction in stroke volume of 3 per cent and after fifteen minutes treatment was 122 79 with a reduction in stroke volume of 10 per ent. *There was no significant change in venous* pressure

F gure 3 demonstrates the physiologic effects of alternating positive and negative breath ng *with* the Vent EL Aire unit at two different settings for expiratory time The mask pressure is set at plus 13 5 to minus 12 cm H_2O the mean mask pressure for the short expiratory time setting is 2 - cm and for the long setting zero cm H-O The settings were as follows for the short setting 1 6 seconds inspiratory time and 0 8 seconds expiratory time for the long setting 2 seconds inspiratory time and 1 6 sec onds expiratory time The arterial pressures vary from 143 86 to 136 100 mm Hg for the short settings and from 136 100 to 122/86 mm Hg for the long settings The changes in venous pressure vary for both settings from 17 to 19 cm H_2O respiratory rate from 2- 5 for the *short and 17 per minute for the long setting* The stroke volume dropped 30 per cent for the long setting and 20 per cent for the short setting

The first forty experiments in six subjects (four normals and two patients with chronic bronchial asthma free of circulatory involve-

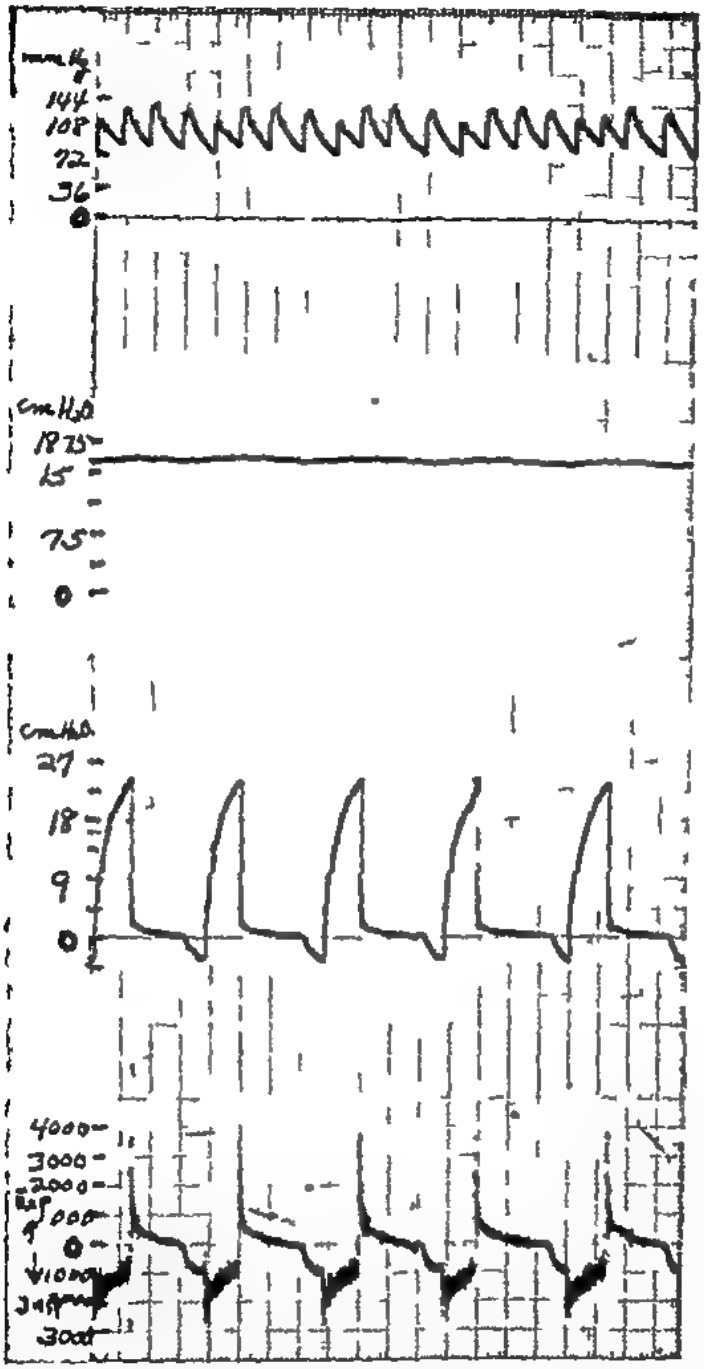

FIG 2 IPPB/I (Vent EL Aire unit) mask pressure at 26 cm H_2O Recorded after 15 therapy with readings as described in Figure 1

nt) demonstrated that the influence of ssure breathing on circulation is a function t only of mean mask pressure but also of the absolute time during which the peak ssures are exerted, and (2) the length of atment Some of the highest changes in oke volume occurred in patients who had a an mask pressure of zero and some of the lowest changes in patients with mean mask pressure of +12 to +14

In the course of these studies we were able to demonstrate a significant drop in the pulmonary artery pressure in a patient with *chronic* pulmonary emphysema by means of IPPB/I The drop became manifest after ten minutes and was striking after fifteen minutes The

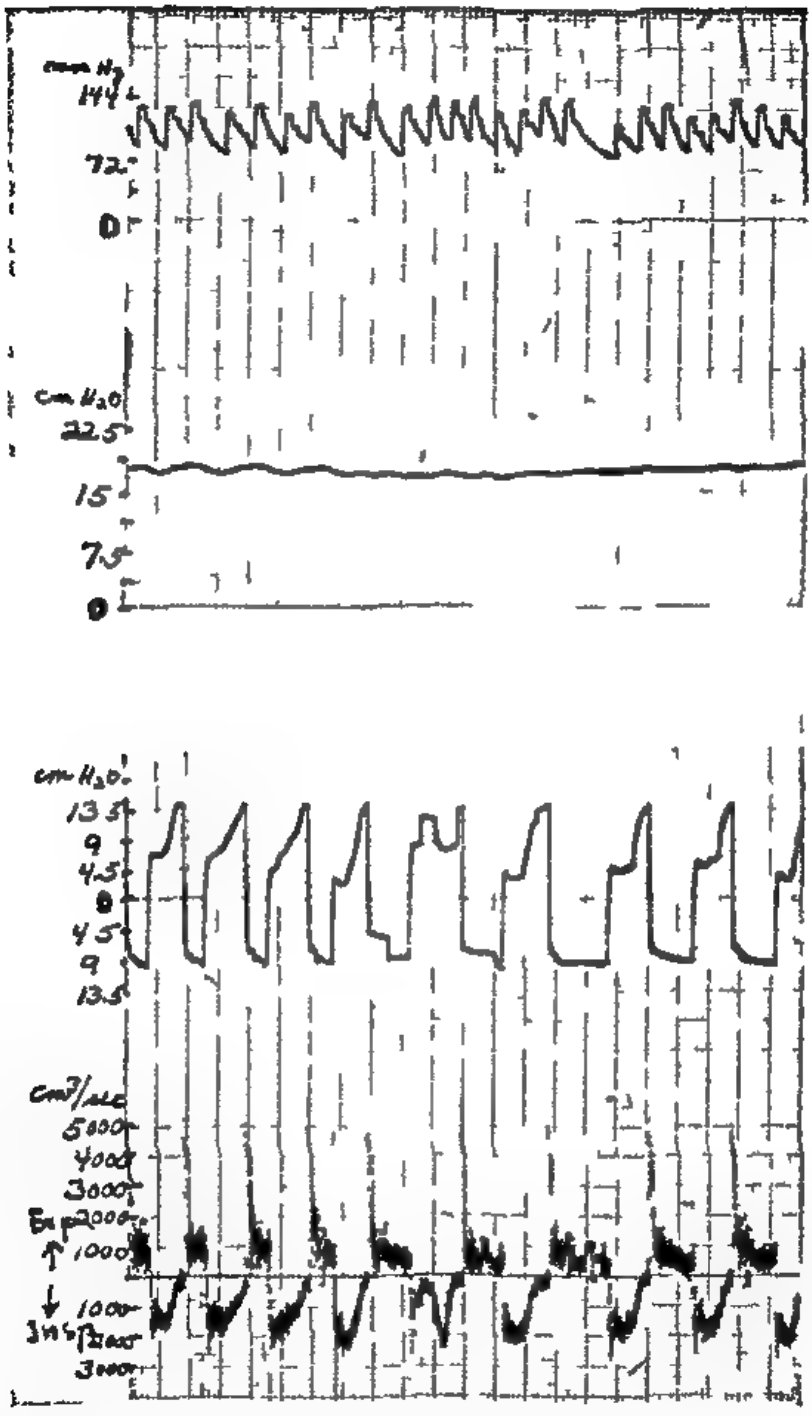

FIG 3 P and N breathing (Vent EL Aire unit) mask pressures at +13 5 and −10 cm H O At left setting for short expiration and at right setting for long expiration Readings as in Figure 1

IPPB/I was administered with the Bennett valve with pressures of 26 cm H_2O No simultaneous bronchodilation therapy was employed Further studies are under way in order to determine how much of the drop is due to the administration of oxygen alone and how much to the IPPB/I

Clinical Applications of Pressure Breathing Therapy The application of positive pressure to the airway during the inspiratory phase of respiration (with the use of a mask or mouthpiece), commonly referred to as intermittent positive pressure breathing, may be abbreviated as IPPB/I The expiratory phase of respiration is entirely passive The devices usually consist of an inspiratory demand

valve operating on a flow sensitive or pressure sensitive principle and require the use of oxygen or oxygen air mixtures The more commonly employed are the Bennett, M S A Emerson and Halliburton valves Positive pressures of 10 to 20 cm H_2O are usually employed and have been well tolerated Therapeutic aerosols are generally administered during the inspiratory positive pressure phase of breathing This type of therapy has found its greatest usefulness in progressive bronchospastic disorders wherein uneven pulmonary ventilation exists particularly when employed along with bronchodilator aerosols [illegible] It is especially helpful in respiratory acidosis

It is generally assumed that during inspiration positive pressure by mask is comparable to the negative pressure by body respirator and that during expiration negative pressure by mask is comparable to positive pressure by body respirator [illegible] This is probably true for normal lungs However in patients with changes of viscoelastic properties of the lungs these pressures might not be transmitted as exact equivalents since the equilibrium of the elastic and coordinating structures has been upset by the uneven damaging of the intermediate tissues

We would stress again that this form of pressure breathing should not be employed in patients under circulatory stress e g patients who are on the verge of or in peripheral vascular collapse heart failure or those having spinal anesthesia

The application of positive pressure during inspiration and negative pressure during expiration has recently been the subject of extensive study by Barach and Maloney and their associates and other groups [illegible] Barach and his associates have described their technic as exsufflation with negative pressure (EWNP) and have demonstrated its usefulness in the removal of pulmonary secretions in a variety of pulmonary and non pulmonary disorders [illegible] Maloney et al have stressed the importance of the negative pressure

pos [illegible]
pressures) [illegible]

Numerous devices have been employed for the production of exsufflation with negative pressure particularly the Coflator—O E M unit [illegible] and the Exsufflator—Eliot unit [illegible] There are also numerous P and N pressure devices commonly employed for resuscitation purposes We are presently studying the application of positive and negative pressure breathing in the treatment of various pulmonary disorders complicated by retention of bronchial secretions Barach and his associates demonstrated the clinical value of gradual inflation of the lungs followed by a high volume flow rate during expiration produced by a sudden rapidly induced negative pressure during expiration This technic facilitated the removal of mucoid and purulent sputum from the lungs in a large number of their patients The expiratory flow rate exceeded that produced during cough by many of their normal subjects and their patients with bronchial asthma chronic pulmonary emphysema bronchiectasis or poliomyelitis This type of therapy has found its greatest usefulness in patients with inadequate cough mechanisms

We are presently employing in our studies the Vent EL Aire a multipurpose air pressure breathing unit that combines the four therapeutic functions of (1) IPPB/I—intermittent positive pressure breathing during inspiration (2) E W N P —exsufflation with a rapid negative pressure (cough) (3) resuscitation—by means of alternating positive pressure on inspiration with passive or negative pressure on expiration (4) therapeutic aerosols—independent supply of therapeutic aerosols during inspiration only

This apparatus may be used in a variety of pulmonary disorders depending upon which function is employed (1) IPPB/I with bronchodilator aerosols for the management of progressive bronchospastic disorders such as chronic bronchial asthma and pulmonary emphysema (2) E W N P as a cough machine for the removal of bronchopulmonary secretions in the treatment of atelectasis bronchiectasis lung abscess postoperative pulmonary aspirations poliomyelitis etc (3) resuscitation whenever indicated and (4) for the independent administration of therapeutic aerosols employing bronchodilator antimicrobial enzymatic or detergent agents

The basic functions of the Vent EL Aire are carried out as follows

1 When the dial is adjusted for IPPB/I the machine becomes a complete demand unit with positive pressure on inspiration only and passive expiration The time of inspiration

(approximately one to three seconds) and the desired positive pressure (0 to 40 cm H_2O) are both adjustable Upon reaching the preset positive pressure the machine shuts off the air flow and allows the patient to breathe out passively A slight inspiration by the patient starts the positive pressure and the cycle is repeated

2 When the dial is adjusted for 'cough," the apparatus supplies controlled demand positive pressure on inspiration with adjustable pressures ranging from 0 to 40 cm H_2O The time during which the patient becomes inflated (approximately one to three seconds) is adjustable by means of an air flow control Upon reaching the preset positive pressure, the machine automatically cycles to negative pressure This shiftover occurs in 04 seconds by means of an electrical solenoid valve The negative pressure is adjustable for 0 to 40 cm H_2O By dropping the mask or mouthpiece of +40 cm during inspiration to −40 cm H_2O during expiration, a rapid expiratory air flow rate is produced, simulating the human cough The time for the negative or expiratory phase is controlled by an electric time delay mechanism which is adjustable from one to three seconds The pressure changes are visible at all times on the face dial gauge

3 Resuscitation may be accomplished by setting the desired positive pressure and a small amount of negative pressure on expiration (P and N pressures) The automatic time delay mechanism on expiration is put into operation with patients with no demonstrable or very shallow respirations When the patients starts to breathe again the unit may be turned to demand intermittent positive pressure breathing—inspiratory only This function should be set up with an anesthetic tracheal airway and mask in place

4 The Vent-EL-Aire unit also contains an auxiliary oil free diaphragm air pump with tubal connection to a nebulizer inserted into the mouth or face piece This function provides the necessary air flows for the production of therapeutic aerosols during inspiration only In this manner bronchodilator (e g, vapone frin), antimicrobial (e g, penicillin) enzymatic (e g, pancreatic dornase), or detergent (e g, alevaire) aerosols may be administered whenever indicated

SUMMARY

1 Advances in the use of therapeutic aerosols, oxygen therapy and pressure breathing therapy in the management of patients with chronic bronchial asthma, pulmonary emphysema and suppurative lung disease are discussed

2 A new air pump apparatus for the production of all types of continuous aerosol therapy and the NebELizer croup tent apparatus for the administration of cold water vapors (humidity therapy) and alevaire (detergent agent) therapy are described

3 The use of three new therapeutic aerosols —an anticholinergic agent (pamine bromide) and dusts and emulsions of cortisone and hydrocortone for allergic nasal states—are discussed

4 The hazards of the carbon dioxide intoxication syndrome and respiratory acidosis in patients with chronic anoxia secondary to chronic pulmonary emphysema and pulmonocardiac disease are presented Their recognition, prevention and specific management are briefly discussed The hazard of opiate-induced respiratory acidosis is considerably reduced with the availability of nalline, a remarkable opiate antagonist

[illegible]

alternating positive-negative pressures are discussed

6 A new multipurpose air pressure unit, the Vent-EL-Aire, combining four of the main therapeutic functions in inhalational therapy is described for the first time

Acknowledgment The authors wish to make grateful acknowledgment to Mrs Dorothy Belgard, Mrs Doris Koss and Miss Thelma Adelman for their technical assistance, and to Drs J A Herschfus, M J Dulfano, and A Salomon for laboratory assistance in the preparation of some of the material

REFERENCES

1 SEGAL, M S The Management of the Patient with Severe Bronchial Asthma Springfield, Ill, 1950 Charles C Thomas

2 W [illegible] 33 134 1950

3 SEGAL, M S and DULFANO M J Chronic Pulmonary Emphysema Physiopathology and Treatment New York 1953 Grune & Stratton Inc

4 SEGAL, M S SALOMON A and HERSCHFUS J A Treatment of chronic pulmonary emphysema *Am Rev Tuberc* 69 915 1954

5 BARACH A L BICKERMAN H A and BECK G J Advances in the treatment of non tuberculous pulmonary disease Bull New York Acad Med 28 353 1952

6 BRESNICK E BEAKEY J F LEVINSON L and SEGAL, M S Evaluation of therapeutic substances employed for the relief of bronchospasm v Adrenergic agents *J Clin Investigation* 28 1182 1949

7 BARACH A L Physiologic methods in the diagnosis and treatment of bronchial asthma and pulmonary emphysema *Ann Int Med* 12 454 1938

8 SEGAL, M S SALOMON A DULFANO M J and HERSCHFUS J A Intermittent positive pressure breathing Its use in the inspiratory phase of respiration *New England J Med* 250 225 1954

9 BEAKEY J F BRESNICK E LEVINSON L and SEGAL, M S Evaluation of therapeutic substances employed for the relief of bronchospasm III Anticholinergic agents *Ann Allergy* 7 113 1949

[illegible]

and SEGAL, M S A new sympathomimetic amine (neosuprel) in the treatment of bronchial asthma *Ann Allergy* 9 769 1951

12 KIRSNER J B and PALMER W L Newer gastric antisecretory compounds *J A M A* 151 798 1953

13 SALOMON A HERSCHFUS J A and SEGAL, M S Aerosols of pancreatic dornase in bronchopulmonary disease *Ann Allergy* 12 71 1954

14 SHERRY S JOHNSON A and TILLETT W S The action of streptococcal desoxyribonuclease on purulent exudates *Proc New York Path Soc* p 96 1948–1949

15 SHERRY S JOHNSON A and TILLETT W S The action of streptococcal desoxyribose nuclease (streptodornase) in vitro and on purulent pleural exudations of patients *J Clin Investigation* 28 1094, 1949

16 TILLETT W S and SHERRY S The effect in patients of streptococcal fibrinolysin and streptococcal desoxyribonuclease on fibrinous, purulent and sanguinous pleural exudations. *J Clin Investigation* 28 1173 1949

17 McCARTY M Purification and properties of desoxyribonuclease isolated from beef pancreas *J Gen Physiol* 29 123 1945

18 SEGAL, M S SALOMON A and HERSCHFUS J A Advances in inhalational therapy *South M J.*, 47 888 1954

19 LEVINE, E R BARACH A L PEABODY J W and SEGAL, M S Effective Inhalational Therapy Chicago 1953. National Cylinder Gas Co

20 SALOMON A RADOVSKY S S and SEGAL, M S A new croup tent apparatus employing the nebELizer for continuous aerosol administration *GP* 10 60 1954

21 SEGAL, M S and SALOMON A A new apparatus for continuous aerosol therapy The nebELizer *Journal Lancet* 74 447 1954

22 BARACH A L BECK, G J and SMITH W H Mechanical production of expiratory flow rates surpassing the capacity of human coughing *Am J M Sc* 226 241 1953

23 SEGAL, M S SALOMON A and HERSCHFUS J A Alternating positive negative pressures in mechanical respiration *Dis of Chest* 25 640 1954.

24 SEGAL M S DULFANO M J and HERSCHFUS J A Advances in the physiology and treatment of bronchial asthma *Quart Rev Allergy* 6 399 1952

25 SEGAL, M S and HERSCHFUS J A Oxygen therapy Description of a new face tent *Bull New England M Center* 13 244 1951

26 DULFANO M J MACK F X and SEGAL, M S Treatment of respiratory acidosis with n allyl normorphine (nalline) *New England J Med* 248 931 1953

27 SALOMON A MARCUS P S HERSCHFUS J A and SEGAL, M S N allylnormorphine (nalline)—action on narcotized and non narcotized subjects *Am J Med* 17 214 1954

28 BARACH A L Treatment of anoxia in clinical medicine *Bull New York Acad Med* 25 370, 1950

29 COURNAND A MOTLEY H L WERKO L and RICHARDS D W JR. Physiological studies of the effects of intermittent positive pressure breathing on cardiac output in man *Am J Physiol* 152 163 1948

30 MOTLEY H L COURNAND A ECKMAN M and RICHARDS D W JR Physiological studies on man with pneumatic balance resuscitator Burns model *J Aviation Med* 17 431 1946

31 WHITTENBERGER J L and SARNOFF S J Physio- [illegible] tory [illegible]

32 [illegible] D [illegible] of mechanical respiration *J Applied Physiol.*, 6 517 1954

33 BARACH A L FENN W O FERRIS F B and SCHMIDT C F Physiology of pressure breathing *J Aviation Med* 18 73 1947

34 FENN W O OTIS A B RAHN H CHADWICK, L. E. and HEGNAUER, A H Displacement of blood from the lungs by pressure breathing *Am J Physiol* 151 258 1947

35 FENN W O and CHADWICK, L. E Effect of pressure breathing on blood flow through the finger *Am. J Physiol* 151 270 1947

36 RAHN H OTIS A B CHADWICK, L. E. and FENN W O Pressure volume diagram of the thorax and lung *Am J Physiol.*, 146 161 1946

37 OTIS A B FENN W O and RAHN H Mechanics

of breathing in man *J Applied Physiol*, 2 592, 1950

38 FENN, W O Mechanics of respiration. *Am J Med*, [illegible] 77, 1951.

39 DAY, R, GOODFELLOW, A M, APGAR, V and BECK, G J Pressure time relations in the safe correction of atelectasis in animal lungs *Pediatrics*, 10 593, 1952

40 LAUSON, H D, BLOOMFIELD R A and COURNAND, A The influence of the respiration on the circulation in man with specific reference to pressures in the right auricle, right ventricle femoral artery and peripheral veins *Am J Med*, 1 315, 1946

41 HENRY, J P, HENDRICKSON I, MOVITT, E and MEEHAN J P Estimations of the decrease in effective blood volume when pressure breathing at sea level Committee on Aviation Medicine, Report No 452, 1945

42 MALONEY, J V. and HANDFORD S W Circulatory responses to intermittent positive pressure breathing and alternating positive negative pressure breathing *J Applied Physiol*, 6 453 1954

43 MALONEY, J. V, ELAM, J O, HANDFORD S W BALLA G A, EASTWOOD, D W, BROWN E S and TEN PAS R H Importance of negative pressure phase in mechanical respiration *J A M A*, 152 212, 1953

44 WHITTENBERGER, J L and MALONEY J V Physiologic factors in the use of body respirators for impaired respiratory function *Dis of Chest* 22 141, 1952

45 STARR, I, SCHNABEL, T G, ASKOWITZ S I and SCHILD, A Studies made by simulating systole [illegible] necropsy IV On the relation between pulse pressure and cardiac stroke volume leading to a clinical method of estimating cardiac output from blood pressure and age *Circulation* 9 648 1954

46 STARR, I Clinical tests of the simple method of estimating cardiac stroke volume from blood pressure and age *Circulation*, [illegible] 664, 1954

47 MOTLEY, H L, WERKO, L, COURNAND, A and RICHARDS, D W, JR. Observations on clinical use of intermittent positive pressure breathing *J Aviation Med*, 18 417, 1947

48 MOTLEY, H L, LANG, L P and GORDON, B The use of intermittent positive pressure breathing combined with nebulization in pulmonary disease *Am J Med*, 5 853 1948

49 MOTLEY, H L and TOMASHEFSKI, J F Treatment of chronic pulmonary diseases with intermittent positive pressure breathing *Arch Med Hyg*, 5 1, 1952

50 SMART, R H, DAVENPORT C. K and PEARSON, G W Intermittent positive pressure breathing in emphysema of chronic lung diseases *J A M A*, 150 1385 1952

51 MALONEY, J V and WHITTENBERGER, J L Clinical implications of pressures used in the body respirators *Am J M Sc*, 221 425, 1952

52 BECK, G J SEANOR, H E, BARACH A L and GATES, D Effects of pressure breathing on venous pressure *Am J M Sc*, 224 169, 1952

53 BARACH A L. BECK, G J, BICKERMAN, H A and SEANOR, H E Physical methods simulating cough mechanisms *J A M A*, 150 1380, 1952

[illegible]

mechanisms of the human cough *J Applied Physiol*, 5 85 1952

56 BICKERMAN, H A, BECK, G J, GORDON, C. A and BARACH A L Physical methods of simulating mechanisms of the human cough *J Applied Physiol* 5 92 1952

Corticotrophin and Corticosteroids

MAURICE S SEGAL M D J A HERSCHFUS M D AND A SALOMON M D Boston Massachusetts

From the Lung Station (Tufts) Boston City Hospital and the Department of Medicine Tufts University School of Medicine Boston Massachusetts

THE use of corticotrophin and corticosteroids in the treatment of pulmonary diseases should represent but a single phase albeit important in the total therapeutic program The earlier unbridled enthusiasm for this form of hormone therapy has been replaced by a more cautious attitude based on experiences with larger series of patients with various disease entities and with a wide variety of side effects and toxic reactions Although these hormones frequently have a striking ameliorative clinical effect and the progress of the disease itself may appear arrested it is not usually suppressed The over all value of hormonal therapy should be considered from not only the degree of remission obtained and its duration but also from the price paid by the patient namely adrenal hypercorticism personality changes and other reactions In accomplishing a remission an imbalance may be created in the hypothalamic anterior pituitary adrenocortical axis which did not exist before therapy This is of particular importance in dealing with the patient with pulmonary disease who may need surgical care The added surgical stress in patients who have been receiving hormonal therapy creates a greater hazard

The application of these hormones to the treatment of pulmonary diseases was based on earlier observations and experimental studies on other disease entities It was noted that the administration of desoxycorticosterone in animals produced changes resembling those seen in rheumatic and hypertensive diseases particularly nephrosclerosis periarteritis nodosa hyaline necrosis of arterioles and arthritic changes [1-4] Such changes could be counteracted by the administration of glucocorticoids such as cortisone Histopathologic studies of hypersensitivity reactions in man and those produced experimentally in animals showed morphologic findings which are seen in such conditions as rheumatic fever periarteritis nodosa Loeffler s syndrome and rheumatoid arthritis [5-9] The basic changes which all of these pathologic states have in common are evidence of increased capillary permeability myxomatous swelling of ground substance fibrinoid necrosis of collagen and cellular infiltration The necrosis of collagen and cellular infiltrations frequently occur in relation to small vessels with or without involvement of the vessel wall

The concept of diseases of adaptation followed the development of the theory of the alarm reaction evolved by Selye [10] In essence this theory states that any stress condition will cause reflex stimulation of the adrenal glands via the anterior pituitary by means of the corticotrophic hormones and the compounds poured out by the adrenals the individual is helped to adapt himself to the abnormal environmental situation Lack of proper adaptation or adjustment (falling by the wayside) will result in the development of one of the so called diseases of adaptation i e periarteritis nodosa rheumatoid arthritis and bronchial asthma It is of interest that many of the diseases of adaptation belong in the category of the so-called collagen diseases and these in turn have a common denominator namely the histopathologic changes seen in diseases of hypersensitivity reactions

After the development of cortisone and ACTH by Hench Kendall and others these hormones were first used in the treatment of rheumatoid arthritis and rheumatic fever As larger supplies became available their effect was tested in most of the diseases classified as diseases of adaptation collagen diseases and diseases of hypersensitivity Thus in the realm of pulmonary diseases these hormones were soon used in the treatment of bronchial asthma pulmonary emphysema Loeffler s syndrome and in the pulmonary infiltrations associated

with periarteritis nodosa and disseminated lupus erythematosus

From the vast volume of experimental and clinical observations of the effects of corticotrophin and corticosteroids it was concluded that these hormones modify in a protective manner the body s response to injury the usual response of cellular reaction with exudation and the elaboration of collagen appeared suppressed By suppressing the inflammatory process the subsequent development of fibrosis and scarring appeared delayed or even prevented However granulation tissue already present was not resolved by these hormones

With these observations in mind the next step was of course to employ these hormones in the treatment of pulmonary beryllosis silicosis sarcoidosis and other pulmonary diseases which are characterized by the development of various types of fibrosis

General Indications for the Use of These Hormones in Pulmonary Diseases The indications for the use of these hormones in pulmonary diseases are essentially the same as for other diseases The hormones are ma nly to be used when other drugs and the conventional methods of treatment are ineffective in securing remission or cure of the disease The hormones are then used in conjunction with other medication For example the patient in status asthmaticus who does not respond to the usual therapy with aminophylline bronchodilator aerosols antimicrobials etc is a candidate for treatment with one of these hormones In patients with overwhelming pneumonia unresponsive to adequate antimicrobial therapy the physician is justified in trying intravenous ACTH The response may indeed be life-saving

These hormones are indicated in diseases in which development of inflammatory reaction and subsequent fibrosis or necrosis threatens the survival of the individual The early use of the hormones in these patients will suppress the inflammatory phase of the disease Hence their early use is indicated in disseminated lupus erythematosus periarteritis nodosa and the like

The use of these hormones is indicated in certain pulmonary diseases for which no other specific therapy is available for instance Loeffler s syndrome and selective cases of pulmonary sarcoidosis

SPECIFIC PULMONARY DISEASES TREATED WITH CORTICOTROPHIN AND CORTICOSTEROIDS

Chronic Bronchial Asthma and Status Asthmaticus

The greatest clinical experience with these hormones in pulmonary disease has been amassed in this group of patients In general the dosages forms of application etc employed apply to the other diseases to be discussed

Hormonal therapy should not be used until all of the other therapeutic and physiologic measures which may be indicated have been employed for example continuous intravenous infusions of aminophylline intermittent positive pressure breathing with bronchodilator aerosols the use of therapeutic gases under pressure bronchoscopic aspiration antimicrobial agents iodides and the like Finally hormonal therapy is best employed in con

from side reactions

In the management of our patients we have employed the following preparations ACTH lyophilized aqueous for intramuscular and intravenous use and ACTH gel (highly purified)* for intramuscular use only cortisone intramuscular and oral † and hydrocortisone oral ‡

Treatment with Corticotrophin We have administered 281 courses of ACTH therapy (intramuscularly and intravenously) to 192 patients with intractable bronchial asthma In this group there were 123 women and sixty nine men Their ages ranged from nine to seventy three years and the duration of their asthma from five months to thirty two years

1 The original lyophilized intramuscular preparation of ACTH was administered to fifty two patients who were given a total of eighty two courses of therapy (one to four days average ten days

2 The highly purified ACTH gel the slow release intramuscular preparation was administered to twenty three patients They were

* Supplied by The Armour Laboratories, Kankakee Ill.

† Supplied by Merck & Co Inc Rahway N J

‡ Supplied by The Upjohn Co Kalamazoo Mich

given a total of twenty-five courses of therapy (one to two courses each) The average total dose required to produce remission was 160 mg The duration of treatment was two to seven days

TABLE I
CORTICOTROPHIN THERAPY*

Cort cotroph n	No of Patients	No of Courses	Aver age Dose (mg)	Days of Treat ment
Intramuscular	52	82	605	235 19
Intramuscular highly pur fied gel	23	25	160	2 7
Intravenous	117	174	70	1–9

* One hundred n nety two pat ents w th chron c bronchial asthma rece ved 281 courses of therapy by various routes

3 Continuous intravenous ACTH therapy was administered to 117 patients, who were given a total of 174 courses of therapy (one to five courses each) The average total dose required to produce remission was 70 mg The duration of treatment was one to nine days, *average four days (Table 1)*

The results were as follows The immediate therapeutic effects were considered excellent in 59 per cent, with good effects persisting for *longer than four weeks, 25 per cent demon*strated good results, the therapeutic effects persisting for two to four weeks, 13 per cent *showed fair results, the therapeutic effects per*sisting for one to two weeks, and 3 per cent were considered failures because the improvement persisted for less than one week after therapy was stopped Supportive therapeutic measures were carried out in all of these patients Aminophylline, in the form of con*tinuous intravenous infusions or rectally, and* antimicrobial coverage to minimize the possibility of intercurrent infection, were administered

The intravenous route is the more efficacious one for the hospitalized patient in serious status *asthmaticus The use of ACTH gel may be* reserved for the less seriously ill patient in the *hospital or at home and for the patient with* veins not suitable for intravenous technic The patient was started on a continuous infusion of 5 per cent glucose in distilled water, 30 drops per minute flow, thus ensuring approximately 3 L per twenty-four hours Aminophylline, 0 25 to 0 5 gm , was added to each liter de*pending upon the patient's response* and tolerance to aminophylline ACTH was added, 10 mg per L , and a total dose of 30 mg per twenty-four hours was given for one to three days The quantitative eosinophils were usually low or absent by the second day of this program With improvement the ACTH was administered only in the first liter of fluid daily for several *more days In the most severe cases* the infusion of glucose and aminophylline was continued for an additional one or more days

With intravenous therapy the immediate results were generally more striking and the therapeutic effects more adequately continued The total dose, and thus the cost to the patient, was one-fifth to one-eighth of that required when ACTH was given intramuscularly However, the physiologic hazards, particularly disturbances in psyche and potassium *imbalance, were more pronounced with intra*venous therapy

The remissive state was maintained with the use of rectal aminophylline solution or oral preparations of aminophylline (dainite and cardalin*) and bronchodilator sprays† as needed During treatment and following re*mission the patients noted that they could* "do more with considerably less" of their therapeutic armamentarium It is thus apparent that the remissive state was usually only *partial rather than complete*

Treatment with Corticosteroids A second group of 118 patients received corticosteroid *therapy Oral cortisone was given to seventy*-two patients and oral hydrocortisone was given to forty-six patients There were thirty nine patients with seasonal bronchial asthma due largely to air-borne allergens and seventy nine patients with chronic bronchial asthma with evidence of recurring sinobronchitis, nasal *polyposis, bronchiectasis and emphysema* Infectious, physical and depletion factors appeared to trigger their attacks The patients in this series were almost entirely confined to home and ambulatory

The following dosage schedule was employed, with occasional revisions cortisone, oral, 50 mg *every six hours for three days*, then 25 mg every six hours for four days and finally 12 5 mg every six hours for maintenance therapy Approximately one third of the patients in this group were able to remain on maintenance therapy of 12 5 mg every eight hours, another one-third *required 12 5 mg* every six

* *Supplied by Irwin Neisler & Co* Decatur, Ill
† Supplied by the Vaponefrin Co , Upper Darby, Pa

hours, and the remaining one-third required 25 mg every eight hours Those receiving hydrocortisone were placed on the following dosage schedule 20 to 40 mg (depending on how refractory their asthma had proved until then) every six hours for three days, then one-half of the dosage employed for the next four days and finally 10 mg every six hours for maintenance therapy Approximately one third of this group were able to remain on 10 mg every six hours for maintenance therapy, another one-third required 20 mg every eight hours, and the remaining one third required 20 mg every six hours A single course of therapy, as outlined for both cortisone and hydrocortisone, was continued for four to six weeks—very rarely any longer and more usually for only four weeks

Withdrawal from the corticosteroids was carried out slowly over a period of six to nine days Occasionally it was found necessary to return to the maintenance dose schedule, or slightly higher for several days longer, before once again attempting complete withdrawal Approximately one-half of the total group treated with cortisone or hydrocortisone were given ACTH gel (20 units daily for four or more consecutive days) just as the withdrawal schedule was started This was employed to stimulate adrenocortical hormone formation which might have become suppressed during corticosteroid therapy and also in view of the fact that exogenous cortisone (as well as corticotrophin) is known to inhibit the formation of corticotrophin by the anterior pituitary In fact both may be responsible for suppression of adrenocortical hormone formation in treated patients To minimize the possibility of intercurrent infection most of our patients were given maintenance doses of antimicrobial agents, generally remanden®* 100 000 units every twelve hours, or one of the broad spectrum drugs (terramycin®† or tetracyn‡), 100 mg every eight hours

The results were considered satisfactory (improvement persisting for more than two weeks) in 68 per cent, and unsatisfactory in 32 per cent The best results were noted in the group of seasonal asthmatics, in which the results were 87 per cent satisfactory and 13 per cent unsatisfactory Of the more perennial asthmatics, 58 per cent had satisfactory results and 42 per cent unsatisfactory

The better results on the whole were noted with hydrocortisone Improvement was noted more rapidly, the dosage required was considerably smaller and it was generally easier to restore balance when treatment had been stopped On the other hand, more rapid evidence of hypercorticism (mooning, weight gain, etc) was noted with hydrocortisone

Chronic Pulmonary Emphysema

We have treated twenty-two patients with chronic pulmonary emphysema and associated bronchospastic crises with corticotrophin by the intramuscular or intravenous route The use of the hormone is indicated when chronic hypoxia, dyspnea with wheezing and evidence of chronic cor pulmonale are not alleviated through the intensive use of bronchodilators, aminophylline, intermittent positive pressure breathing on inspiration (IPPB/I), oxygen, antimicrobials, venesection and so forth [12] The presence of heart failure in these patients is not an absolute contraindication to the use of these hormones Hypoxia is the dominant mechanism which eventually leads to the development of chronic cor pulmonale and ultimately cardiopulmonary failure The relief afforded by these hormones from the bronchoconstriction, resultant hypoxia and pulmonary hypertension is worth the risk of potential sodium and water retention Physiologic measures for the management of cardiopulmonary failure (namely, fluid and sodium chloride restriction use of digitalis, mercurials, venesection, etc) must be used concomitantly and vigorously, their effectiveness may indeed seem improved (when the use of the hormones is added) The doses of these hormones and methods of administration were the same as discussed for bronchial asthma

The majority of the patients whose acute illness was complicated by a large element of bronchospasm were benefited by hormone therapy Remissions were of the same order as those seen in the patients with bronchial asthma There was dramatic improvement with ACTH in one patient with severe chronic pulmonary emphysema with pulmonary fibrosis who was bedridden because of secondary pulmocardiac failure After each course of therapy

* Supplied by Sharp & Dohme Inc Philadelphia, Pa

† Supplied by Chas Pfizer & Co Inc New York, N Y

‡ Supplied by J B Roerig & Co Chicago Ill

he was able to be up and about for several weeks However remissions were brief following two courses of therapy and death followed about six months after the first course of ACTH The temporary relief justified the means considering the comfort attendant to the patient s relief from dyspnea

We have noted quite frequently the persistence of bronchitis and progression of emphysematous changes in patients with chronic bronchial asthma who have received multiple courses of hormone therapy The residual bronchitis responded generally to intensive maintenance antimicrobial therapy iodides and antihistaminics It may represent a lowering of local tissue resistance by virtue of the inhibition of the inflammatory response of the mucosa to hormone therapy We generally urge antimicrobial coverage in these patients

Pulmonary Granulomatoses

Many diseases of known and unknown etiology with pulmonary involvement manifest themselves by granulomatous lesions in the lung parenchyma i e tuberculosis leprosy brucellosis mycoses sarcoidosis asbestosis silicosis berylliosis and the like

In this group the diseases have a chronic course and are generally characterized by dyspnea on exertion and frequently at rest a dry hacking cough anorexia lassitude weakness and frequently loss of weight Cor pulmonale cyanosis and clubbing of the fingers are frequently present especially during the advanced stages of the disease During the acute phase of the disease fever and toxicity are usually present

In most cases granulomas eventually develop in the lung sufficiently to produce roentgenologic abnormalities These changes appear either as a fine reticular network following the course of small blood vessels and lymphatics as scattered miliary or nodular shadows or a combination of these These processes may be generalized or localized and need not be symmetric Hilar adenopathy is commonly seen and is generally bilateral especially in sarcoidosis

These structural and infectious changes in the lung are responsible for the alterations in pulmonary functions Three patterns of pulmonary dysfunction have been described (1) All lung volumes are reduced but gas exchange is unchanged (2) Impairment of gas exchange across the alveolar capillary membrane constitutes the major disturbances (3) The pattern of pulmonary emphysema with increased residual volume and total lung capacity etc is found Treatment with corticotrophin and corticosteroids has been attempted in some of these diseases [11 22]

A variable degree of subjective and objective improvement has been observed in the course of treatment improved ventilation better arterial oxygen saturation less dyspnea and cough The variability of changes is probably related to the degree of suppression of inflammation resolution of granulomas and the extent of fibrosis resulting from these changes Changes in x ray appearance of the granulomas after treatment if any were minimal Lack of correlation between radiologic appearance and pulmonary function measurements was noted in most instances As a rule there was an early relapse in most cases after cessation of treatment

We have treated five patients with pulmonary sarcoidosis [24] Pulmonary function studies and roentgenograms were obtained before and after treatment All patients showed marked pulmonary involvement three patients had ocular involvement one patient had uveoparotitis with secondary Bell s palsy and three patients had minimal cutaneous involvement The patients had a low exercise tolerance and an elevated resting ventilation A slight decrease of maximal breathing capacity was present in two patients One patient had hypoxia after exercise The impairment in lung volumes was compatible with the findings of minimal pulmonary emphysema

Four patients were treated with ACTH and one with cortisone Each patient was started with 80 units of ACTH (H P) gel daily this was gradually reduced toward the end of treatment A total of 1 500 to 2 000 units was given over a thirty five to forty five day period Cortisone was given initially in a dose of 300 mg a day for three days followed by 200 mg for five days and then 100 mg daily for the remaining thirty four days making a total dose of 5 300 mg Concomitantly with this treatment 600 000 units of crystacillin daily were given to three patients and 1 gm of terramycin daily was administered to the other two patients

A marked suppressive effect of ACTH and cortisone upon the sarcoidosis lesions in general

was observed in the five patients The most striking regressions were noted objectively in the les ons of the skin peripheral lymph nodes parotid glands and of the eyes There was partial clearing radiologically of the lung lesions Subjectively there was marked improvement in the dyspnea cough and general well being of all five patients Six months after treatment the patients still had remission One patient had acute bronchitis four months after treatment which cleared promptly with penicillin therapy

Pulmonary Fibrosis

Pulmonary fibrosis in its various forms—bronchial interstitial alveolar vascular pleural or a combination of these—is frequently seen in a large variety of systemic diseases such as polyarteritis nodosa disseminated lupus erythematosus scleroderma erythema nodosum hypersensitivity reactions mitral stenosis and eosinophilic granuloma As a rule the pulmonary fibrosis will be a late manifestation of those diseases However occasionally it may be early in its appearance or it may be the only manifestation in an accelerated form of the disease

These diseases with the exception of mitral stenosis and eosinophilic granuloma have clinical and histopathologic findings in common and are often referred to as collagen diseases as defined by Klemperer [25]

In general the course of these diseases can be divided into two phases The first is characterized by constitutional symptoms including malaise myalgia arthralgia frequently fever and at some time visceral manifestations These result from the structural and functional derangements caused by the degeneration of parenchymal cells and by the simultaneous proliferation of connective tissue in such diverse organs and tissues as skin subcutaneous tissue muscle tendon and fascia bones blood vessels serous surfaces internal organs endocrine glands and nervous system Most of these diseases have a chronic course ranging from several months to years and frequently terminate fatally Therefore the second phase of these diseases usually consists of the advanced picture of widespread systemic involvement and its crippling sequelae

The pulmonary functional changes that occur in pulmonary fibrosis include both ventilatory and respiratory disturbances The results of treatment with corticotrophin and corticosteroids have been variable and largely

general rule relapse will occur after treatment and discontinued

We have treated three patients with generalized scleroderma and pulmonary involvement [7] Roentgenograms skin biopsies and pulmonary function studies were obtained before and after treatment Clinical findings common to all three patients were severe exertional dyspnea cyanosis a dry nonproductive hacking cough weakness anorexia fatigue and marked loss of weight during the progress of the disease X rays of the lungs showed an increase in linear markings and peribronchial infiltration of the parenchyma throughout both lung fields involving primarily the lower two-thirds and with a marked increase in density at the lung roots There was no apparent involvement of the apices

The lung volume measurements revealed findings similar to those of chronic pulmonary fibrosis with compensatory emphysema The total lung capacity as well as the vital capacity were diminished in two of the three patients The ventilation studies showed some slight disturbance but none of significant degree

for oxygen but not for carbon dioxide which is more readily diffusible and requires greater ventilatory or membrane defects in order to deviate There was no disturbance of the acid base balance

Each patient was given a total dose of 4 600 mg of cortisone orally over a period of thirty five days While no significant modification of the objective pathology of the visceral lesions was observed after treatment there was definite improvement in the clinical picture A marked increase in exercise tolerance and decrease in dyspnea was noted by all The hacking cough disappeared in two and

demonstrated by x ray after treatment was terminated Interestingly enough however the

constrictive changes in the esophagus present in two patients prior to treatment could not be demonstrated by visualization of the esophagus after therapy In our three patients the treatment with cortisone had a favorable effect upon the skin but relapse occurred after approximately three to six months We did not observe acceleration of progress of the disease following treatment It was apparent that treatment resulted in only temporary improvement, with early relapse

Pulmonary Infiltrations with Eosinophilia

Pulmonary infiltrations with eosinophilia of known or unknown etiology associated with or without other systemic manifestations occur quite commonly The interest in this subject has increased tremendously, largely because of the therapeutic implications of the eosinopenic influences of adrenocorticotropic or corticosteroid hormones The following are the more commonly discussed entities in this group Loeffler's syndrome, tropical eosinophilia, parasitic infestations (protozoan or metazoan infestations), periarteritis nodosa and eosinophilic leukemia

It is generally assumed that the eosinophilic pneumonopathies, exclusive of eosinophilic leukemia, represent an unusual reaction of hypersensitivity involving the alveoli with or without the bronchi At times these pneumonopathies are seen in patients known to have allergic diatheses, while in others, parasitic infestations appear to be the etiologic factor, cutaneous helminth, ascaris, Trichuris trichiuria, Strongyloides stercoralis, microfilaria, Fasciola hepatica, acarina (mites), amoeba, brucella, coccidioides and others have been found in many of these cases [28–31]

Crofton and associates[31] postulated that hypersensitivity involving only the alveoli gives rise to either Loeffler's syndrome or "prolonged pulmonary eosinophilia" This latter syndrome is characterized by prolonged or recurrent infiltrations without asthma, the infiltrations lasting for more than one month and the course of the syndrome lasting up to six months When both the alveoli and bronchi are involved by the process of hypersensitivity, "pulmonary eosinophilia with asthma" will result Tropical eosinophilia is thought to be the result of bronchial infestations with mites Hypersensitivity involving the pulmonary vessels gives rise to polyarteritis nodosa However, few cases of polyarteritis nodosa are seen with eosinophilia and pulmonary infiltration About two-thirds of the patients with these findings have bronchial asthma, although in some these findings occur only during their final illness [31]

Loeffler's syndrome is the most common of these entities and occurs more frequently than any of the others in this country Its course is characterized by shifting pulmonary infiltrates, localized or diffuse, with or without areas of atelectases or effusions, and high blood and sputum eosinophilia The pulmonary infiltrates are generally fan-shaped and homogeneous with indefinite borders More usually its course is benign with malaise and a simple bronchitic type of episode with wheezing respirations It may even go unrecognized or respond quite simply to home care There have been recurrences However, more severe types have been noted, associated with high fever, cough, hemoptysis, dyspnea, cyanosis, pleuritic pain, pleural effusions and the like The course may simulate that of miliary tuberculosis or viral pneumonia and, in fact, any disease of the lungs with miliary, granulomatous or interstitial infiltrations It must also be differentiated from Hodgkin's disease, periarteritis nodosa, eosinophilic leukemia and familial eosinophilia Its etiology has not been clearly defined but the common denominator appears to be hypersensitivity with stress situations as precipitating factors

One of us (M S S) recently was asked to see an acutely and critically ill eighteen year old college girl She had been ill for several days with a progression of symptoms, namely, malaise, short ineffective cough, tightness of the chest, dyspnea, chilliness and temperature of 105°F The entire past history and family history were of no significance The respirations [illegible] and the pulse rate appeared

antimicrobial agents A presumptive diagnosis of atypical pneumonia had been made The white blood count increased progressively to 13,000 and on the fifth day of her illness, when first seen by one of us, the eosinophil count was 2,760 Chest films showed diffuse, bilateral, fine interstitial seedings with progressive small pleural effusions variously interpreted as suggesting miliary tuberculosis, acute beryllium pneumonitis, interstitial pneumonitis etc On

the basis of a presumptive diagnosis of eosinophilic pneumonopathy of Loeffler's type ACTH was administered intravenously The clinical improvement was short of miraculous During the initial administration of 1,500 cc of 5 per cent glucose in distilled water containing 30 mg ACTH, the patient's temperature promptly dropped to normal and the respirations dropped to 65 per minute Recovery was progressive although protracted over a period of seven to ten days, and the cure was ultimately complete The respiratory rate remained unusually elevated but dropped slowly to normal during this period The patient was treated with intravenous ACTH during the first ten days and subsequently hydrocortisone for a period of ten days Exhaustive routine laboratory studies including cultures agglutination and skin testing for tuberculosis periarteritis nodosa, lupus erythematosus tropical and parasitic eosinophilia coccidioidomycosis viral and influenzal disease were all negative

Management of this syndrome in the past has been largely symptomatic Antihistamines ephedrine aminophylline and antimicrobial agents have been without definite value More recently, corticotrophin and corticosteroids have appeared quite effective Clinical improvement is usually promptly manifested and radiologic improvement at times has been compared to the use of an eraser at the black board/The infiltrations and effusions clear up rapidly Marks [illegible] in his cases employed cortisone in doses of 100 mg intramuscularly every four hours for one day and then every twelve hours until objective (x ray) and subjective improvement took place Duration of treatment was usually three to six days Others have noted a similar rapid resolution on using ACTH [illegible]

/The other diseases previously referred to with eosinophilia and pulmonary infiltrates should be distinguished from Loeffler s syndrome, for they require different management and, moreover, do not as a rule respond to the hormones in such a specific manner Tropical eosinophilia usually occurs in the Far East [illegible] Geographic and climatic factors are important Fever leukocytosis eosinophilia splenomegaly pulmonary infiltrates paroxysmal cough, wheezing respirations and chronic course unless adequate treatment is instituted are characteristic of this disease The bronchitic aspect may last for months and is followed by an asthmatic phase which may last several years and may resolve spontaneously [illegible] The radiologic picture shows diffuse, localized or generalized mottling and hilar adenopathy especially in children There is leukocytosis of over 15 000 and eosinophilia of 20 to 90 per cent The etiology is uncertain although infestation of the respiratory tract with a mite has been incriminated ACTH may produce only a moderate decrease of the eosinophilia but does not influence the clinical course or the radiologic picture [illegible] The use of an inorganic arsenical carbarsone followed by neoarsphenamine appears to be specific and may be followed by cure in a matter of days [illegible]

Changes Noted during and Subsequent to Hormone Therapy

Accumulation of several years' clinical experience and extensive laboratory studies with these hormones have resulted in recognition of the many side effects and toxic reactions as well as an appreciation of the precautions and contraindications to be observed

The undesirable effects that may follow their clinical use can generally be classified into two groups (1) those due to overdosage and (2) those due to withdrawal of the hormone [illegible] Since successful steroid therapy depends upon a state of hormone overdosage, it is unavoidable that effective hormone therapy will be associated with an exaggeration of their normal physiologic actions These abnormal metabolic reactions are seen with intensive and prolonged therapy and manifest themselves when compensatory mechanisms of homeostasis are no longer adequate Any of the symptoms and finally the full blown picture of Cushing's syndrome may develop

Symptoms of hormone withdrawal are due to a state of adrenal insufficiency created by hormonal suppression of adrenocortical function The symptoms may be mild or severe depending upon the dosages employed, duration of therapy and rate of withdrawal of the hormone This state of relative adrenal insufficiency may resemble the course of Addison s disease Any additional stress in the form of trauma shock, surgery or severe infection during this state of insufficiency may prove disastrous to the patient.

On decreasing the dose during withdrawal of the hormones aches and pains, lassitude and a wide spectrum of personality changes may

occur These symptoms usually clear up when the dose is increased, but may recur when another attempt is made to decrease the dose This situation is seen more often in women after the menopause than in other patients [42] Finally, it must be realized that the disease being treated may flare up again with even greater severity and rapidity after having been suppressed with hormone therapy

TABLE II
CHANGES DURING AND SUBSEQUENT TO CORTICOTROPHIN AND CORTICOSTEROID THERAPY

Less Serious
Facial mooning acne edema hirsutism skin pigmentation
Headaches aches pains weakness lassitude
Mild euphoria to mild depression mental and physical hyperactivity
Hypertension tachycardia
Hyperglycemia glycosuria aggravation of existing diabetes
Depressed thyroid function
Thrombophlebitis
Sensitivity reactions (to intramuscular ACTH)—skin rashes pruritus urticaria occasionally wheezing and angioneurotic edema

More Serious
Potassium deficiency, muscular weakness
Negative nitrogen balance
Osteoporosis—fractures especially in women after menopause and immobilized patients
Masked infections spread of existing infection serious spread of non pathogenic inhabitants of the gastrointestinal and respiratory tracts
Mental confusion to severe psychotic manifestations convulsions
Exacerbation of quiescent ulcers hemorrhage and perforation in the gastrointestinal tract
Activation and spread of unsuspected or inactive tuberculosis
Sensitivity reaction—anaphylactic shock

Most Serious (Fatal)
Withdrawal syndrome adrenocortical storm
Poor tolerance to trauma shock and infections

The wide variety of changes noted during and subsequent to corticotrophin or corticosteroid therapy are listed in Table II We have been particularly concerned with the more serious events and deaths as noted in five patients in our series of 192 patients with severe, chronic bronchial asthma treated with 281 courses of corticotrophin therapy and 118 patients treated with 182 courses of corticosteroid therapy Those who died were one man and four women ranging in age from forty eight to sixty five years These patients gave histories of repeated bouts of sinusitis, bronchitis, bronchial asthma and chronic pulmonary emphysema of various degrees Three of the patients had nasal polyps All had received at least three prior courses of hormone therapy at other medical centers during the previous two years or had been on almost continuous hormone therapy These patients were believed to have in common the trigger mechanisms responsible for the intractability of their disease, namely, infectious psychic, estrogen and physical depletion factors Several of the side effects had occurred at various times in these patients while they were receiving hormone therapy

Contraindications to the Use of Corticotrophin and Corticosteroids

There are few absolute contraindications to the use of these hormones especially if the course of treatment is of short duration and the total dose is rather small

These hormones should not be used in the presence of active or inactive tuberculosis recent or chronic gastrointestinal ulcers active considered a contraindication to the use of the hormones However, Goolker and Schem[43] concluded from their studies that the psychic reaction to the hormones bore no relationship to the pretreatment personality In fact, they observed a complete discrepancy between the dosage the pretreatment state and the psychic outcome

There are other conditions which are frequently considered as contraindications because these diseases can be aggravated by the administration of the hormones With the brief courses of treatment that we usually employ, we do not consider them absolute contraindications We must only watch the patient more closely while he is being treated The following are examples of these conditions Diabetes mellitus may or may not be temporarily aggravated by the hormones an increase of insulin may be necessary until treatment is completed Only prolonged therapy for several months may cause or permanently aggravate diabetes The same holds true for hypertension or osteoporosis We do not hesitate to administer the hormones in the presence of congestive heart failure if this is secondary to the underlying pulmonary dis

ease The use of the diet low in sodium chloride, mercurial diuretics and the additional use of potassium are necessary safeguards

LABORATORY PROCEDURES

If corticotrophin is to be used, one must be sure of the presence of a responsive adrenal cortex The eosinophil response may be determined simply, a decrease of 80 per cent or more of the eosinophils indicates excellent response Eosinophil counts are also a guide to the adequacy of dosage We generally prefer to observe the response to intravenous administration of ACTH rather than intramuscular administration A drop of 80 per cent or more from the total (control) eosinophil count should appear by the time that 20 units of aqueous corticotrophin in 1 L. of 5 per cent glucose in distilled water have been administered at a flow rate of 30 drops per minute This would tend to rule out primary adrenocortical insufficiency It would indicate adequate adrenocortical reserve for the stress that may follow surgery

Daily blood pressure readings and weight recordings are important An electrocardiogram and test of blood sugar level before and at intervals during treatment are important when therapy is to be continued for periods longer than ten to fourteen days The determination of serum potassium, sodium and chlorides should be performed to evaluate possible disturbances in electrolyte balance

THERAPEUTIC PRECAUTIONS

Among the precautions to be followed are restriction of sodium chloride in the diet to 5 to 750 mg daily The occasional use of mercurial diuretics may be helpful when indicated by excessive weight gain from fluid retention Potassium may be routinely administered in the form of potassium chloride, 8 to 20 gm daily, with supplemental potassium in the form of orange juice, 8 to 12 ounces daily In the presence of infection or suspected infection the concomitant use of an antimicrobial is necessary, the use of streptomycin is advised when treating sarcoidosis or other granulomatous lesions. In general, the patient should receive a high protein diet to offset the tendency for negative nitrogen balance In patients with a tendency toward gastric hyperacidity it is advisable to prescribe antacids and belladonna alkaloids during hormone therapy The use of androgens and/or estrogens is perhaps indicated when the patient receiving hormone therapy has evidence of osteoporosis As indicated before, the hormones are capable of inducing hypothyroidism When this occurs, the patient may cease to respond to corticotrophin treatment until function is restored to normal by the administration of thyroid [44]

Although the adrenal cortex may appear normal about twenty days after a course of cortisone is stopped, it is believed by some that the danger of hypocorticism and concomitant pituitary changes may continue for many months [45, 46] These patients should receive adequate supplemental doses of corticosteroids in case of surgery, severe trauma or other forms of major stress [44] The eosinopenic response to intravenous corticotrophin described heretofore may be used to determine the need for supplemental corticosteroid therapy during and after surgical procedures

COMMENTS AND SUMMARY

The use of the corticotrophins and corticosteroids in the treatment of various pulmonary diseases followed naturally in the wake of the demonstrations of the interrelationship between hypersensitivity reactions collagen diseases, diseases of adaptation and the adrenal cortex From the immense volume of clinical, laboratory and animal observations it became apparent that despite the multiplicity of effects these hormones have on the bodily functions the hormones only modify the response of the host to infection, essentially by suppressing the inflammatory and toxic reactions By so doing the hormones may enable the host to rally more effectively and recover more quickly and fully from the damaging effects of a disease The hormones will serve to support the patient until the disease has been cured (Loeffler's syndrome) or has disappeared (seasonal exacerbation of bronchial asthma) In the treatment of chronic diseases the reason for using the hormones and their beneficial effect may be likened in a sense to the administration of blood transfusions or substitutes periodically to patients suffering from various types of blood disorders The patient who is suffering from intractable bronchial asthma which is persisting or becoming more severe despite all treatment will welcome the period of relief, short as it may be, made possible by treatment with these hormones In addition, their early

occur These symptoms usually clear up when the dose is increased, but may recur when *another attempt is made to decrease the dose* This situation is seen more often in women after the menopause than in other patients [42] Finally, it must be realized that the disease being treated may flare up again with even greater severity and rapidity after having been suppressed with hormone therapy

TABLE II

CHANGES DURING AND SUBSEQUENT TO CORTICOTROPHIN AND CORTICOSTEROID THERAPY

Less Serious

Facial mooning acne edema hirsutism skin pigmentation
Headaches aches pains weakness lassitude
Mild euphoria to mild depression mental and physical hyperactivity
Hypertension tachycardia
Hyperglycemia glycosuria aggravation of existing diabetes
Depressed thyroid function
Thrombophlebitis
Sensitivity reactions (to intramuscular ACTH)—skin rashes pruritus urticaria occasionally wheezing and angioneurotic edema

More Serious

Potassium deficiency muscular weakness
Negative nitrogen balance
Osteoporosis—fractures especially in women after menopause and immobilized patients
Masked infections spread of existing infection serious spread of non pathogenic inhabitants of the gastrointestinal and respiratory tracts
Mental confusion to severe psychotic manifestations convulsions
Exacerbation of quiescent ulcers hemorrhage and perforation in the gastrointestinal tract
Activation and spread of unsuspected or inactive tuberculosis
Sensitivity reaction—anaphylactic shock

Most Serious (Fatal)

Withdrawal syndrome adrenocortical storm
Poor tolerance to trauma shock and infections

The wide variety of changes noted during and subsequent to corticotrophin or corticosteroid therapy are listed in Table II We have been particularly concerned with the more serious events and deaths as noted in five patients in our series of 192 patients with severe, chronic bronchial asthma treated with 281 courses of corticotrophin therapy and 118 patients treated with 182 courses of corticosteroid therapy Those who died were one man and four women ranging in age from forty eight to sixty five years These patients gave histories of repeated bouts of sinusitis bronchitis, bronchial asthma and chronic pulmonary emphysema of various degrees Three of the patients had nasal polyps All had received at least three prior courses of hormone therapy at other medical centers during the previous two years or had been on almost continuous hormone therapy These patients were believed to have in common the trigger mechanisms responsible for the intractability of their disease namely, infectious psychic, estrogen and physical depletion factors Several of the side effects had occurred at various times in these patients while they were receiving hormone therapy

Contraindications to the Use of Corticotrophin and Corticosteroids

There are few absolute contraindications to the use of these hormones especially if the course of treatment is of short duration and the total dose is rather small

These hormones should not be used in the presence of active or inactive tuberculosis recent or chronic gastrointestinal ulcers active

hormones However, Goolker and Schein[43] concluded from their studies that the psychic reaction to the hormones bore no relationship to the pretreatment personality In fact, they observed a complete discrepancy between the dosage, the pretreatment state and the psychic outcome

There are other conditions which are frequently considered as contraindications because these diseases can be aggravated by the administration of the hormones With the brief courses of treatment that we usually employ, we do not consider them absolute contraindications We must only watch the patient more closely while he is being treated The following are examples of these conditions Diabetes mellitus may or may not be temporarily aggravated by the hormones an increase of insulin may be necessary until treatment is completed Only prolonged therapy for several months may cause or permanently aggravate diabetes The same holds true for hypertension or osteoporosis We do not hesitate to administer the hormones in the presence of congestive heart failure if this is secondary to the underlying pulmonary dis

ease The use of the diet low in sodium chloride, mercurial diuretics and the additional use of potassium are necessary safeguards

LABORATORY PROCEDURES

If corticotrophin is to be used, one must be sure of the presence of a responsive adrenal cortex The eosinophil response may be determined simply, a decrease of 80 per cent or more of the eosinophils indicates excellent response Eosinophil counts are also a guide to the adequacy of dosage We generally prefer to observe the response to intravenous administration of ACTH rather than intramuscular administration A drop of 80 per cent or more from the total (control) eosinophil count should appear by the time that 20 units of aqueous *corticotrophin in 1 L. of 5 per cent glucose in* distilled water have been administered at a flow rate of 30 drops per minute This would tend to rule out primary adrenocortical insufficiency It would indicate adequate adrenocortical reserve for the stress that may follow surgery

Daily blood pressure readings and weight recordings are important. An electrocardiogram and test of blood sugar level before and at intervals during treatment are important when therapy is to be continued for periods longer than ten to fourteen days The determination of serum potassium, sodium and chlorides should be performed to evaluate possible disturbances in electrolyte balance

THERAPEUTIC PRECAUTIONS

Among the precautions to be followed are restriction of sodium chloride in the diet to 250 to 750 mg daily The occasional use of mercurial diuretics may be helpful when indicated by excessive weight gain from fluid retention Potassium may be routinely administered in the form of potassium chloride, 8 to 20 gm daily, with supplemental potassium in the form of orange juice, 8 to 12 ounces daily In the presence of infection or suspected infection the concomitant use of an antimicrobial is necessary, the use of streptomycin is advised when treating sarcoidosis or other granulomatous lesions In general the patient should receive a high protein diet to offset the tend-

use of androgens and/or estrogens is perhaps indicated when the patient receiving hormone therapy has evidence of osteoporosis As indicated before, the hormones are capable of inducing hypothyroidism When this occurs the patient may cease to respond to corticotrophin treatment until function is restored to normal by the administration of thyroid [44]

Although the adrenal cortex may appear normal about twenty days after a course of cortisone is stopped, it is believed by some that the danger of hypocorticism and concomitant pituitary changes may continue for many months [45 46] These patients should receive adequate supplemental doses of corticosteroids in case of surgery, severe trauma or other forms of major stress [46] The eosinopenic *response to intravenous corticotrophin* described heretofore may be used to determine the need for supplemental corticosteroid therapy during and after surgical procedures

COMMENTS AND SUMMARY

The use of the corticotrophins and corticosteroids in the treatment of various pulmonary diseases followed naturally in the wake of the demonstrations of the interrelationship between hypersensitivity reactions, collagen diseases, diseases of adaptation and the adrenal cortex From the immense volume of clinical, laboratory and animal observations it became apparent that despite the multiplicity of effects these hormones have on the bodily functions the hormones only modify the response of the host to infection, essentially by suppressing the inflammatory and toxic reactions By so doing, the hormones may enable the host to rally more effectively and recover more quickly and fully from the damaging effects of a disease The hormones will serve to support the patient until the disease has been cured (Loeffler's syndrome) or has disappeared (seasonal exacerbation of bronchial asthma) In the treatment of chronic diseases the reason for using the hormones and their beneficial effect may be likened in a sense to the administration of blood transfusions or substitutes periodically to patients suffering from various types of blood disorders The patient who is suffering from intractable bronchial asthma which is persisting or becoming more severe despite all treatment will welcome the period of relief, short as it may be, made possible by treatment with these hormones In addition, their early

use in pulmonary granulomatoses or fibroses may prevent or delay the extent of ultimate involvement This may be of only theoretic value, for by the time the pathologic process is recognized it is usually too late to accomplish lasting benefit Nevertheless, most patients will derive temporary improvement in their symptoms from these hormones

Prolonged use of these hormones can produce serious metabolic and hormonal changes Cushing's syndrome, diabetes mellitus, Addison's disease, hypothyroidism, hypertension, osteoporosis, etc, may eventually occur We advocate short courses of hormone therapy in the treatment of pulmonary diseases as a safeguard against the occurrence of serious side effects Nevertheless, frequent courses of therapy may seriously injure the homeostasis of the hypothalamus-pituitary adrenal axis in some patients The fatal instances which we have observed were probably related to this poorly understood mechanism

There is evidence in laboratory animals and clinically in man that the hormones, corticosteroids more consistently than corticotrophin, depress resistance to infection or actually may enhance the susceptibility for non-pathogens to form fatal infections, and that they suppress or inhibit the inflammatory response to infection allowing the spread and multiplication of pathogens [47] Therefore the simultaneous use of an antimicrobial is advisable when treating chronic bronchial diseases These diseases tend to harbor infection in the bronchi because of damage to mucosa and parenchyma of the lung, with resultant impairment of ciliary function bronchial peristalsis, etc

We believe the use of these hormones is contraindicated in the presence of active tuberculosis However, recent experimental work in rats, rabbits and guinea pigs indicates that the combined use of ACTH of cortisone with dihydrostreptomycin may be more effective in controlling tuberculous infections than dihydrostreptomycin alone [48] No equivalent studies in humans are available at present

The ambulatory patient is best treated with oral cortisone or hydrocortisone in divided doses, or with ACTH in gelatin form given in a single intramuscular dose daily The hospitalized patient may be treated with lyophilized ACTH given intravenously This route permits the smallest possible dose to accomplish the desired effects in the shortest period of time

Although corticotrophin and the corticosteroids have not fulfilled our early hopes of optimism of a "cure-all," these hormones are nonetheless additional important and powerful agents in our therapeutic armamentarium, available for restricted and considered use when all other conventional methods of therapy have proved ineffective in securing remission or cure of certain pulmonary diseases Unfortunately, in the management of many of the chronic pulmonary disorders the physician pushing therapy may find himself like "the man holding the tiger's tail" because of the problems attendant to withdrawal therapy

Addendum Since submitting this manuscript we have employed extensively the newer cortisone analogues (meticorten, deltra® and deltrasone) and the most recent hydrocortisone analogue, hydeltra Our experience with these preparations has been very good and there appears to be reason for more hope and enthusiasm with these newer corticosteroid analogues Therapeutic and maintenance dosages one quarter to one fifth those employed with the earlier corticosteroids proved effective Side reactions have been fewer but by no means absent It has been possible to tailor the maintenance doses to as little as 1 mg three times a day The striking antiphlogistic effects of hydeltra were noted particularly in patients with intractable bronchial asthma, chronic obstructive pulmonary emphysema and idiopathic pulmonary fibrosis

REFERENCES

1 DARROW D C and MILLER, H C The production of cardiac lesions by repeated injections of desoxycorticosterone acetate J Clin Investigation, 21 601, 1942

2 SELYE H and PENTZ E I Pathogenetical correlations between periarteritis nodosa, renal hypertension and rheumatic lesions Canad M A J 49 264 1943

3 SELYE, H Production of hypertension and hyalinosis by desoxycortisone Brit M J, 1 203 1950

4 SELYE, H The general adaptation syndrome and the diseases of adaptation Am J Med, 10 549 1951

5 [illegible] 225 433 1941

6 RICH, A R and GREGORY, J E The experimental demonstration that periarteritis nodosa is a

manifestation of hypersensitivity *Bull Johns Hopkins Hosp*, 72 65, 1943

7 RICH A R and GREGORY, J E. Experimental evidence that lesions with the basic characteristics of rheumatic carditis can result from anaphylactic hypersensitivity *Bull Johns Hopkins Hosp*, 73 239 1943

8 BERGSTRAND, H Morphological equivalents in polyarthritic rheumatica periarteritis nodosa transient eosinophilic infiltration of the lung and other allergic syndromes *J Path & Bact* 58 399, 1946

9 MORE, R H and McLEAN C R Lesions of hypersensitivity induced in rabbits by massive injections of horse serum *Am J Path* 25 413 1949

10 SELYE, H Stress Montreal 1950 Acta Inc

11 SUTLIFF, W D and NORMAN S L Adrenocorticotrophic Hormone in Cutaneous and Systemic North American Blastomycosis Proceedings of the Second Clinical ACTH Conference vol 2 p 381 Edited by Mote J R Philadelphia 1951 Blakiston & Co

KENNEDY, B J PARE A P PEMP K K BECK J C and BROWNE, J S L. Response of Beryllium Granulomatosis and Silicosis to ACTH Proceeding of the Second Clinical ACTH Conference vol 2 p 440 Edited by Mote J R Philadelphia, 1951 Blakiston Company

3 KENNEDY B J, PARE A P PEMP K K BECK J C, JOHNSON, L G LIPSTEIN N B VENNING E H and BROWNE J S L Effect of adrenocorticotropic hormone (ACTH) in beryllium granulomatosis and silicosis *Am J Med* 11 134, 1951

14 WEST J R McCLEMENT J H CARROLL, D BLISS H A KLEGINER M RICHARDS D W Jr and COURNAND A Effects of cortisone and ACTH in cases of chronic pulmonary disease with impairment of alveolarcapillary diffusion *Am J Med.*, 10 156 1951

15 GALDSTON, M, WEISENFELD S BENJAMIN B and ROSENBLUTH, M B Effect of ACTH in chronic lung disease *Am J Med* 10 166 1951

16 SONES, M, ISRAEL, H L DRATMAN M B and FRANK, J H Effect of cortisone in sarcoidosis *New England J Med*, 244 209 1951

17 DE NARDI J M Symposium on the treatment of chronic beryllium poisoning with ACTH and cortisone Chronic pulmonary interstitial granulomatosis *Arch Indust Hyg* 3 543 1951

18 HARDY, H L, BARTTER F C and JAFFIN A L Metabolic study of a case of chronic beryllium poisoning treated with ACTH *Arch Indust Hyg*, 3 579 1951

19 SILTZBACH L E Effects of cortisone in sarcoidosis *Am J Med*, 12 139 1952

20 McCLEMENT, J H, RENZETTI A D HIMMELSTEIN, A and COURNAND A Cardiopulmonary function in the pulmonary form of Boeck's sarcoid and its modification by cortisone therapy *Am Rev Tuberc*, 67 154, 1953

21 STONE, D J, SCHWARTZ, A, FELTMAN J A and LOVELOCK, F J Pulmonary function in sarcoidosis Results with cortisone therapy *Am J Med*, 15 468, 1953

22 LOVELOCK, F J and STONE D J The therapy of sarcoidosis *Am J Med*, 15 477, 1953

23 HARDY H L. Occupational medicine *New England J Med*, 247 473 1952

24 SALOMON A, APPEL, B, COLLINS, S T, HERSCHFUS, J A and SEGAL, M S Sarcoidosis pulmonary and skin studies before and after ACTH and cortisone therapy (Unpublished data)

25 KLEMPERER, P Editorial Collagen diseases *Am J Med* 10 405 1951

26 ENGEL F L and RAGAN C Proceedings of the Second Clinical ACTH Conference vol 2, p 456 Edited by Mote, J R Philadelphia 1951 Blakiston Co

27 SALOMON A APPEL, B DOUGHERTY E T HERSCHFUS J A and SEGAL, M S Scleroderma pulmonary and skin studies before and after treatment with cortisone *Arch Int Med*, 95 103 1955

28 HAM J C and ZINDAHL, W T Loeffler's syndrome and pulmonary infiltrations accompanied by peripheral eosinophilia *Ann Int Med*, 29 488 1948

29 CARTWRIGHT G T An unusual case of clonorchiasis with marked eosinophilia and pulmonary infiltrations *Am J Med* 6 259 1949

3 SHEERAN A Pulmonary infiltration with blood eosinophilia *Am J Med* 10 269 1951

31 CROFTON J W LIVINGSTONE J L, OSWALD N C and ROBERTS A T M Pulmonary eosinophilia *Thorax* 7 1 1952

32 MARKS L Loeffler's syndrome with a report of twenty three cases *Dis of Chest* 25 128 1954

33 HERBERT P and ROSE B Observations on the effect of adrenocorticotrophic hormone on a case of Loeffler's syndrome and a case of eosinophilia *J Allergy* 20 79 1949

34 HERBERT P DE VRIES J A and ROSE B Studies on the effect of ACTH on a case of Loeffler's syndrome and a case of tropical eosinophilia *J Allergy* 21 12 1950

35 ROSE B Studies on the Effect of ACTH on Eosinophilia and Bronchial Asthma Proceedings of the First Clinical ACTH Conference p 491 Edited by Mote J R Philadelphia 1950 Blakiston Company

36 REEDER W H and GOODRICH, B E Pulmonary infiltration with eosinophilia (PIE syndrome) *Ann Int Med*, 36 1217 1952

37 WEINGARTEN R J Tropical eosinophilia *Lancet*, 1 103 1943

38 PARSONS SMITH B J Tropical eosinophilia *Lancet*, 1 433 1944

39 EMERSON K Tropical eosinophilia *U S Nav M Bull* 42 118 1944

40 CARTER H F WEDD G and D ABRERA, V Occurrence of mites (acarina) in human sputum and their possible significance *Indian M Gaz* 78 163 1944 Cited by Reeder and Goodrich

41 THORN G W, JENKINS D, LAIDLAW, J C, GOETZ, F C, DINGMAN, J F, ARONS, W L, STREETEN, D H P and McCRACKEN, B H Pharmacologic aspects of adrenocortical steroids and ACTH in man *New England J Med*, 248 588 1953

42 SLOCUMB, C H Rheumatic complaints during chronic hypercortisonism and syndromes during withdrawal of cortisone in rheumatic patients *Proc Staff Meet, Mayo Clin*, 28 655, 1953

43 GOOLKER, P and SCHEIN, J Psychic effects of ACTH and cortisone *Psychosom Med*, 15 589, 1953

44 WOLFSON, W Q, BEIERWALTES, W H, ROBINSON, W D, DUFF, I F, JONES, J R, KNORPP, C T, SIEMIENSKI, J S and EVA, M Corticogenic [illegible]

45 BENNETT, W A Histopathologic changes in the adrenal and anterior pituitary in patients treated with cortisone preliminary impressions *Proc Staff Meet, Mayo Clin*, 28 658, 1953

46 SALASSA, R M, KEATING, F R JR and SPRAGUE, H G Clinical aspects of supression of adrenal cortical function after use of cortisone *Proc Staff Meet, Mayo Clin*, 28 662, 1953

47 KASS, E H and FINLAND, M Adrenocortical hormones in infection and immunity *Ann Rev Microbiol*, 7 361, 1953

48 BACOS, J M and SMITH, D T The effect of corticotropin (ACTH), dihydrostreptomycin, and corticotropin dihydrostreptomycin on bovine tuberculosis in the rabbit *Am Rev Tuberc*, 67 201, 1953

49 SEGAL, M E and HERSCHFUS, J A Management of the patient in status asthmaticus *Postgrad Med*, 9 435, 1951

50 SEGAL, M S and HERSCHFUS, J A and LEVINSON L ACTH and chronic bronchial asthma *GP*, 3 33–39 1951

51 SEGAL, M S and HERSCHFUS, J A Intravenous ACTH therapy in the treatment of bronchial asthma *Dis of Chest*, 6 575, 1951.

52 SEGAL, M S and DULFANO, M J Chronic Pulmonary Emphysema Physiopathology and Treatment New York, 1953 Grune & Stratton Inc

Anesthetic Management of Patients with Altered Pulmonary Function

JOSEPH G GILFFRIDA M D AND DANTE BIZZARRI M D, *Brooklyn, New York*

From the Departments of Anesthesia Columbia Hospital and New York City Hospital New York New York

DERANGEMENTS of the respiratory system are of great concern to the anesthesiologist because they influence the choice of anesthetic agent and technic, the conduct of anesthesia and the postoperative course of the patient

The principal objective of this chapter is to discuss the problems presented to the anesthetist by patients with diseases affecting pulmonary function Attention will be directed mainly to the more commonly encountered bronchopulmonary diseases and to lesions causing respiratory obstruction Conditions which alter intrapleural dynamics neuromuscular diseases the full stomach and obesity are also included In addition criteria of good pre- and postoperative care and of correct anesthetic management are considered

RESPIRATORY OBSTRUCTION

Patients in whom the patency of the nasopharynx larynx or trachea has been seriously decreased by neoplasm inflammation (e g Ludwig s angina parapharyngeal abscess) or by neurogenic disturbances (e g abductor paralysis of the vocal cords) constitute a group for which an adequate airway must be guaranteed by either endotracheal intubation or by tracheostomy prior to the induction of general anesthesia Which of the two methods is to be used can be determined preoperatively by visualization of the affected area and by an evaluation of the efficiency of the airway If a good airway is not established before general anesthesia is begun complete respiratory obstruction may develop early in induction as voluntary respiratory efforts are weakened by the loss of consciousness At this level of anesthesia nasopharyngeal and oropharyngeal airways or the endotracheal tube are not tolerated Obviously anesthesia cannot be deepened by inhalation technic Attempts to establish via the intravenous route conditions suitable for endotracheal intubation usually complicate matters Barbiturates or muscle relaxants have to be given in doses large enough to produce profound hypotension and serious respiratory depression in many cases If, despite these measures endotracheal intubation cannot be performed emergency tracheostomy becomes mandatory This may not be completed in time to avoid a fatality Although life may be saved complications such as pneumothorax pneumomediastinum mediastinitis and subcutaneous emphysema frequently result because of the haste with which the tracheostomy is performed It is evident therefore that failure to insure an adequate airway prior to the induction of general anesthesia in these patients is to court disaster

In the preoperative examination one must look for evidence of poor oral hygiene dehydration thick inspissated secretions dyspnea and or depressed pharyngolaryngeal reflexes Whenever possible these conditions should be corrected so as to facilitate the conduct of anesthesia and reduce the incidence of postoperative complications

Measures instituted in the immediate postanesthetic period to maintain a clear airway and adequate ventilation will diminish the incidence of complications The oropharynx and tracheobronchial tree must be freed of secretions The patient should be kept in the operating room until reflex activity has returned and until one is certain that respirations remain unobstructed If this is not possible it is wise to return the patient to his room with an endotracheal tube in place

DISEASES OF THE BRONCHOPULMONARY SYSTEM

Although the bronchopulmonary system may be affected by numerous diseases those of greatest interest to the anesthetist are emphysema fibrosis chronic bronchitis (smoker s cough) bronchial asthma and those associated

with considerable intrabronchial suppuration The effect of these diseases on pulmonary function depends upon the amount of bronchoconstriction, fibrosis, emphysema and intrabronchial secretions present

Bronchoconstriction produces mechanical interference to the ingress and egress of air It is most clearly observed in allergic bronchial asthma when spasm and edema of the smaller bronchi occur in paroxysms Patients with fibrosis and emphysema have decreased vital capacity, increased residual air, impaired mixing of gases within the air sacs and reduced diffusion across the alveolocapillary membrane These disturbances result in hypoxia, hypercapnia and a depressed respiratory center Compensatory polycythemia is a frequent concomitant finding Long standing cases may show evidence of cor pulmonale

Increased secretions, hyperirritability of the tracheobronchial tree, cough and varying degrees of dyspnea are common findings in chronic pulmonary diseases Because in allergic bronchial asthma and in chronic pulmonary emphysema there is difficulty in expelling air from the lungs, expiration is forcible and prolonged When considerable intrabronchial suppuration exists, the patient is endangered by the threat of drowning and contamination of healthy lung tissue, this hazard is greatest during general anesthesia

Preoperatively, patients with bronchopulmonary diseases warrant specific therapy since the physiologic changes may be reversed to some extent Treatment should be directed toward the control of infection, elimination of secretions and relief of bronchoconstriction, hypoxia and hypercapnia Specific cardiac therapy is to be employed when indicated

Preanesthetic sedatives are best prescribed in smaller doses than usual They should, perhaps, be omitted for patients with marked pulmonary insufficiency Opiates increase the adhesiveness and cohesiveness of exudates, suppress cough, depress respiration and favor bronchoconstriction Demerol® is preferable because it produces these undesirable effects to a lesser extent Only minimal doses of belladonna drugs should be given to patients with thick secretions so that these will not be further inspissated

For patients with bronchopulmonary diseases, regional anesthesia, which includes subarachnoid block, is the method of choice because it does not disturb the airway, does not increase the irritability of the tracheobronchial tree, does not obtund the protective reflexes of the respiratory tract and least alters general body physiology In addition, it allows the early application of the stir up regimen so important in the prevention of postoperative pulmonary complications

Spinal anesthesia is of greatest value in surgery of the lower extremities, perineum and lower abdomen For upper abdominal surgery its advantages over inhalation anesthesia are questionable, since when it is used for these cases it often produces motor paralysis of the lower six intercostal muscles Although the resultant impaired ventilation may be of no great significance in patients with normal pulmonary function, it may predispose to serious consequences in the patients under discussion Furthermore since spinal anesthesia usually does not prevent the discomfort to the patient caused by traction reflexes, complementary general anesthesia of one form or another is usually necessary The combination of paralysis of the lower thoracic cage and the depressant effect of general anesthetic agents, administered often under unfavorable circumstances, may be pernicious to respiration and circulation

In discussing general anesthesia it can be stated that even under the most favorable circumstances it deranges respiration and alters body physiology First, the apparatus in common use increase the dead air space and the resistance to respiration Also, they favor respiratory acidosis and may interfere with heat dissipation Second, most general anesthetic agents irritate the respiratory tract, promote cough and in deeper stages of anesthesia depress the respiratory center and protective tracheobronchial reflexes

Cyclopropane and pentothal® are undesirable for patients with bronchial asthma and emphysema because they have a tendency to initiate paroxysms of cough, produce laryngospasm and/or bronchospasm and to depress respirations Although nitrous oxide and ethylene are innocuous when combined with safe concentrations of oxygen, they are relatively impotent when used in this manner However, they can be utilized within safe limits as supplemental agents to other anesthetic drugs. Although ether irritates the respiratory mucosa and stimulates the flow of secretions, it is preferred as a maintenance agent because it is potent, dilates the bronchi and stimulates respiration

When basal hypnosis is indicated avertin® is preferred to barbiturates since it does not predispose to bronchospasm

Muscle relaxant drugs should be administered with caution because of their depressant effect upon respiration When given the anesthetist must be prepared for endotracheal intubation and positive pressure respiration The synthetic muscle relaxants are preferred to curare for patients with bronchial asthma fibrosis and chronic pulmonary emphysema inasmuch as curare may produce diffuse bronchospasm

To attain a smooth anesthetic course it is essential that certain basic principles be observed The airway must be kept patent and free of secretions It is important that the technic used offers minimal resistance to respiration and that it does not increase the dead air space considerably Lastly optimal oxygen and carbon dioxide concentrations must be maintained by sufficient flows of oxygen efficient carbon dioxide elimination mechanisms and by an adequate effective minute volume

Although the value of the endotracheal tube in maintaining an efficient airway is well recognized its usefulness in patients with bronchopulmonary diseases may be mitigated by certain untoward reactions These patients have hyperirritable tracheobronchial reflexes so that the introduction of an endotracheal tube may set off a persistent spasm of the entire bronchial tree This drastically reduces oxygenation which may be extremely dangerous for the already hypoxic patient Topical anesthesia prior to intubation cannot be relied upon to prevent this reaction in all cases In the presence of persistent bronchospasm the anesthetist faces two alternatives He must either withdraw the offending tube or produce apnea by the administration of muscle relaxants and employ controlled respiration At this point it should be emphasized that a paroxysm of asthma is not an indication for endotracheal intubation but demands bronchodilating and antihistamine drug therapy

Patients with allergic bronchial asthma or with chronic pulmonary emphysema exhibit a phenomenon which we have termed 'the expiratory squeeze' This occurs at the end of a prolonged forcible expiration and constitutes a final effort of the expiratory muscles to expel air from the lungs The expiratory squeeze begins during induction and continues throughout the course of anesthesia Since the abdominal muscles play a major part in this effort relaxation becomes difficult to attain The anesthetist plagued by this difficulty may overdose the patient with anesthetic agents or muscle relaxants or a combination of the two Surgeons who are cognizant of these difficulties will adapt themselves to an unfavorable operative field rather than compel the anesthetist into unsafe practices

Postoperative pulmonary complications occur frequently in the patients under discussion and may contribute to hypoxia carbon dioxide retention disturbances of cardiovascular function abdominal distention and wound dehiscence The incidence of these complications can be reduced to a minimum by returning the patient to as near a normal physiologic state as possible in the immediate postanesthetic period It is important that the conduct of anesthesia be directed toward the early return of reflex activity In addition it is essential that the respiratory tract be cleared of secretions By direct observation we have come to realize that catheter suction through the endotracheal tube during extubation often fails to remove all oropharyngeal secretions The remaining secretions may be aspirated during the first forceful inspiratory effort made by the patient following withdrawal of the endotracheal tube To avoid this the 'double suction' technic recommended by Naclerio is of value This involves aspiration of secretions from the oropharynx under direct vision by an assistant while the anesthetist uses catheter suction through the endotracheal tube (Fig 1) This method is essential for patients in poor general condition especially those with limited pulmonary reserve because in these cases any further reduction in ventilatory capacity may be fatal

The benefits of the early institution of the stir up regimen in preventing atelectasis are clearly appreciated in this group of patients Detergents and hydration may be necessary to thin sticky inspissated secretions If the patient cannot expectorate effectively, one may have to introduce a catheter into the trachea to stimulate cough apply the exsufflator or resort to bronchoscopy Should these measures fail tracheostomy may be necessary

The restlessness of the hypoxic patient is frequently misinterpreted as a manifestation

1A

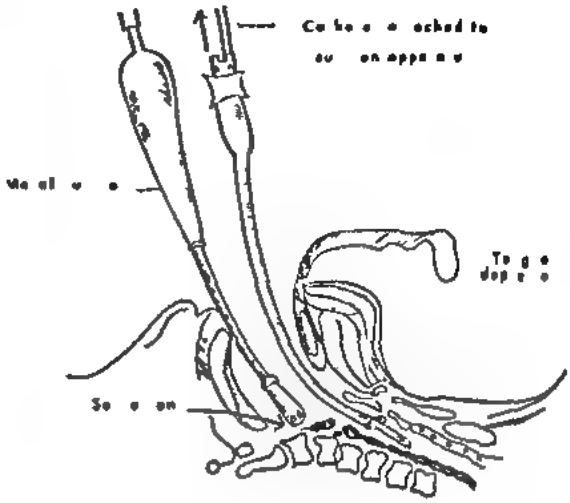

1B

and metal suction tip in oropharynx

of postoperative pain Attempts to control it by sedation may lead to further hypoxia and depression of the cough reflex respiration and circulation The correct treatment necessitates the administration of oxygen through a clear airway In the emphysematous patient oxygen therapy must be governed by the known fact that these patients do not tolerate high oxygen concentrations Some emphysematous patients

pulse may be warning signs of hypoxia and hypercapnia

CONDITIONS WHICH ALTER INTRAPLEURAL DYNAMICS

Whenever the intrapleural space is invaded by tumors gases (pneumothorax) or fluids (hydro- hemo- or pyothorax) the negative intrapleural pressure is reduced This produces varying degrees of atelectasis Lung expansion may also be diminished by conditions which impede movement of the thoracic cage or of the diaphragm such as thoracoplasty chest wall trauma and intra abdominal distention

The condition of the patient depends upon the degree of pulmonary collapse and is most grave when there has been pre-existing low vital capacity The major symptom of these patients is dyspnea some also show evidence of circulatory embarrassment

Before anesthesia is administered the surgeon should attempt to increase the respiratory capacity of the patient Depending upon the cause of the atelectasis he may accomplish this by aspiration of the pleural or peritoneal cavities by decompression of the gastrointestinal tract or by sealing off an open pneumothorax

Patients with reduced vital capacity should receive only minimal doses of sedatives since they tolerate oversedation poorly

In handling these hypoxic patients the anesthetist must direct his efforts toward oxygenating them adequately He can best accomplish this by using an endotracheal tube during anesthesia so that respirations can be controlled or assisted and tracheobronchial secretions can be aspirated Although both ether and cyclopropane are well tolerated the latter is preferred for the patient in shock

These patients require meticulous postoperative care to avoid further atelectasis In addition tracheostomy may be indicated in the presence of paradoxic motion of the chest persistently poor ventilation and copious secretions

NEUROMUSCULAR DISTURBANCES

Bilateral abductor paralysis of the vocal cords causes serious respiratory obstruction It may result from direct or indirect trauma to the laryngeal motor nerves or from intracranial or peripheral nerve lesions Patients with this condition must be assured an adequate airway either by endotracheal intubation or by tracheostomy before general anesthesia is begun

Bilateral adductor paralysis of the vocal cords is found most frequently in conjuction with cerebral lesions Sensory paralysis of the larynx often exists unrecognized in bulbar lesions of tabes in myasthenia gravis and in syringomyelia In both instances the anesthetist is faced with the problem of preventing aspiration This is best accomplished by the use of a cuffed endotracheal tube inserted before induction of general anesthesia

Myasthenia gravis and anterior poliomyelitis may affect the muscles of respiration Myasthenia gravis will be discussed because it has an underlying biochemical disturbance which contraindicates the administration of some of the drugs commonly used in the practice of anesthesia This disease is believed to result from excessive destruction of acetylcholine by cholinesterase at the myoneural junction Patients with myasthenia gravis have extreme fatiguability of muscles which leads to depressed respiration, difficulties in deglutition decreased pharyngolaryngeal reflexes and impairment of the cough mechanism These factors predispose to aspiration and asphyxia

The main concerns of the anesthetist are to [illegible]

must include a period of rest control of infection and therapeutic doses of prostigmin * This drug may have to be repeated during surgery It is important that atropine be combined with it so as to counteract its stimulatory effect on smooth muscles and mucous glands Care must be exercised in prescribing any preoperative sedation

As a rule anesthesia is poorly tolerated by the myasthenic patient Since spinal anesthesia intensifies the existing muscular weakness and since it does not provide favorable conditions for assisted or controlled respirations and for tracheobronchial toilet it is contraindicated Inhalation anesthesia administered through an endotracheal tube allows the anesthetist to have constant control of respiration and is therefore the method of choice Inasmuch as muscle relaxants aggravate the physiologic dysfunction already present they are interdicted Since ether has a curare like action it is to be avoided whenever possible Pentothal because of its depressant effect on respiration and circulation should be used with great caution Cyclopropane is the agent of choice It is potent does not aggravate the existing disturbance at the myoneural junction and allows the use of adequate concentration of oxygen

Patients with myasthenia gravis are prone to have serious respiratory difficulties postoperatively It is important therefore that close attention be given to their airway and tidal exchange Tracheostomy is indicated if the patient has marked difficulty in maintaining an unobstructed airway

THE FULL STOMACH

Patients may come to surgery with a full stomach because of the recent ingestion of food or fluid or as the result of gastrointestinal obstruction These patients are ever threatened by the danger of asphyxia consequent to a sudden inundation of the respiratory tract with gastrointestinal contents Therefore they constitute a grave anesthetic risk

Regional anesthesia affords the greatest safety to these patients They retain control of their airway and most times are able to protect themselves against aspiration When spinal anesthesia is used the continuous technic is preferred to the single dose method since it reduces the uncertainty of dosage permits better control of the level of anesthesia and diminishes the need for supplemental general anesthesia

The proper management of general anesthesia depends upon the early establishment of an effective barrier between the alimentary and respiratory tracts This must be carried out even in the presence of a Miller Abbott or Levin tube since experience has shown that in many instances neither adequately empties the gastrointestinal tract of its contents The barrier should be established before the start of general anesthesia for aspiration may occur during induction This is usually attempted by the insertion of a cuffed endotracheal catheter

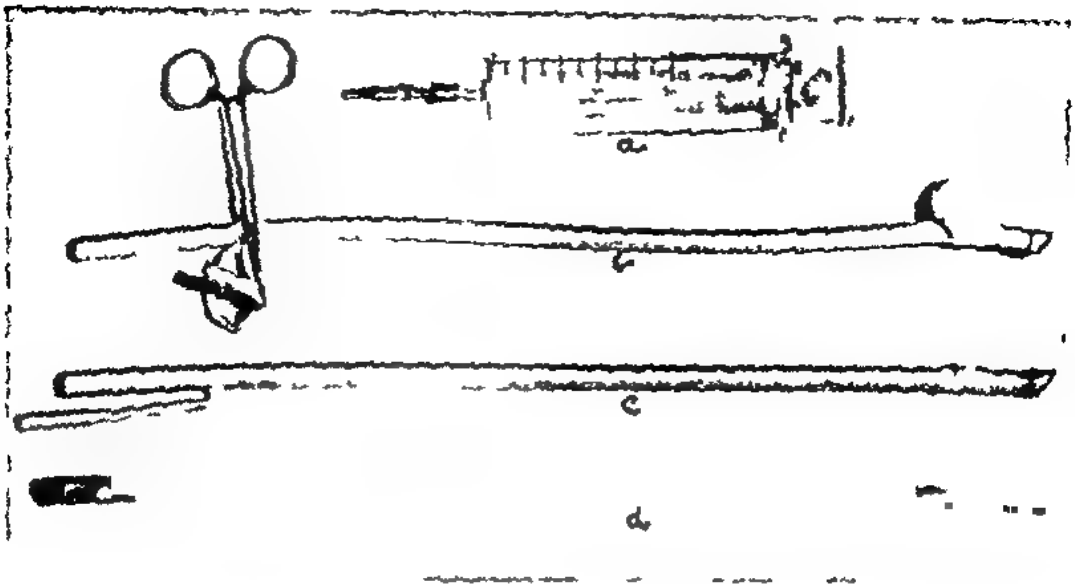

a and c) 32F
amped (d)
ostatic bag

drain is not at all as

FIG 3 Photograph of conscious patient with endoesophageal tube in situ Balloon of tube is being inflated with about 30 cc of air Proximal end of tube protrudes from oral cavity Passage of the endoesophageal tube causes no greater discomfort to the patient than does the insertion of a Levin tube

following topical anesthetization of the larynx and trachea However, a simpler and most effective method, which has been used by the authors for the past ten years, is the intubation of the esophagus with a cuffed tube * (Fig 2) With minimum discomfort to the patient the tube can be passed easily through the mouth into the esophagus without the use of anesthesia It is inserted for a distance of about 30 cm so that the cuff lies beyond the bifurcation of the trachea The proximal end of the tube is left protruding from the oral cavity so that ejected stomach contents will be expelled to the exterior The cuff is inflated with air to the point of resistance so as to insure that any regurgitation of stomach contents will take place only through the tube (Fig 3)

Following endotracheal or endoesophageal intubation, the anesthetist induces the patient into general anesthesia The airway of the patient who has an esophageal tube is to be maintained patent—our practice is to use endotracheal intubation

The following objections have been levelled against our method of esophageal intubation* Intolerance of the conscious patient to the procedure, compression of the trachea causing respiratory embarrassment, ulceration of the esophageal mucosa due to pressure and cardiac irregularities Clinically, the authors have not observed any such untoward effects Studies including bronchoscopy, esophagoscopy and

* The tube found by us to be most suitable for this purpose is a 32F suprapubic Foley hemostatic bag drain because of its length, caliber and the capacity of its bag

4A 4B

FIG 4 A x ray of patient with tube in esophagus and bronchoscope in trachea Balloon of tube filled with 30 cc

radiography have substantiated this clinical experience (Fig 4) Therefore, esophageal intubation with a cuffed tube is a safe, simple and effective procedure which should be used whenever the indication arises for it may be life saving

OBESITY

A discussion of this condition is included because many obese patients manifest some degree of respiratory embarrassment, and because their respirations are frequently characterized by a prolonged and forcible expiratory phase which renders difficult adequate abdominal relaxation during general anesthesia

Because these patients often obstruct early during the induction of general anesthesia they are frequently referred to as "poor breathers" The oropharyngeal airway is not only ineffective in relieving the obstruction but also many times initiates vomiting and laryngospasm Attempts at endotracheal intubation at this stage are often traumatic because of poor relaxation, active pharyngeal and laryngeal reflexes, and because the habitus of the patient makes visualization of the larynx most difficult Therefore, the best way to insure the patency of the airway of the obese patient who is to receive general anesthesia is to intubate him while he is conscious

The difficulties encountered in maintaining the patency of the airway and in producing good abdominal relaxation render general anesthesia a poor choice for these patients Therefore, whenever possible, regional anesthesia should be selected

Since pulmonary complications are prone to develop, these patients must be given the same care postoperatively as described for those with bronchopulmonary diseases

SUMMARY

The authors have discussed certain clinical entities that affect pulmonary function and have shown how the knowledge of the disturbances involved aids in the selection of the correct anesthetic agent and technic We have stressed the importance of preinduction endotracheal intubation and tracheostomy as a means to obviate serious respiratory obstruction We have presented a method of preventing aspiration by the use of the endoesophageal tube Finally, we have emphasized the importance of meticulous care of the patient during the immediate postanesthetic period in the prevention of postoperative pulmonary complications

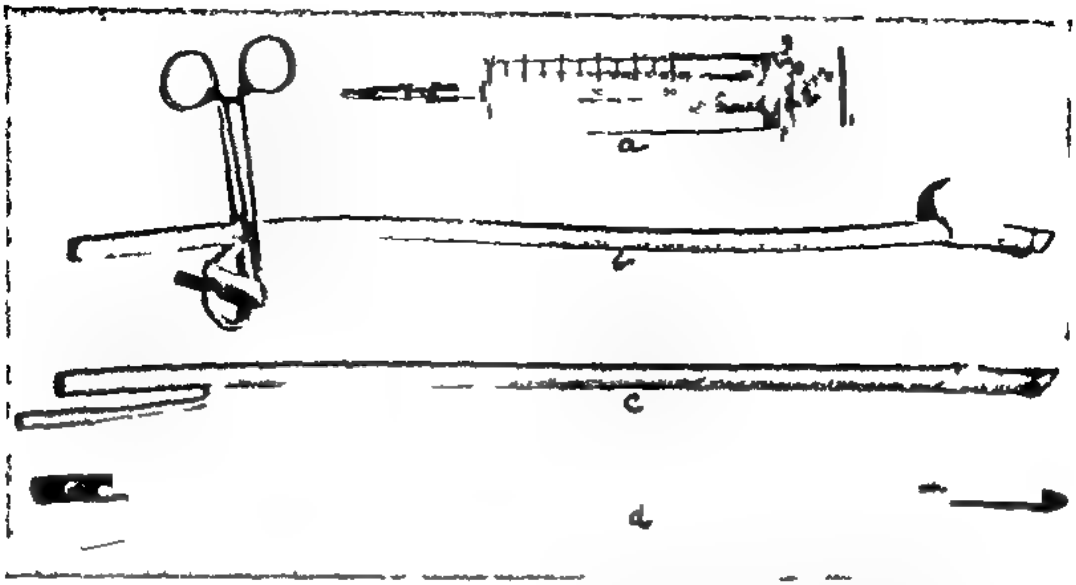

(a) Syringe for inflating balloon (b and c) 32F
xe to the inflated balloon has been clamped (d)
This tube may be used if Foley hemostatic bag

FIG 3 Photograph of conscious patient with endo esophageal tube in situ Balloon of tube is being inflated with about 30 cc of air Proximal end of tube protrudes from oral cavity Passage of the endo-esophageal tube causes no greater discomfort to the patient than does the insertion of a Levin tube

following topical anesthetization of the larynx and trachea However, a simpler and most effective method, which has been used by the authors for the past ten years is the intubation of the esophagus with a cuffed tube * (Fig 2) *With minimum discomfort to the patient the* tube can be passed easily through the mouth into the esophagus without the use of anes thesia It is inserted for a distance of about 30 *cm so that the cuff lies beyond the bifurca* tion of the trachea The proximal end of the tube is left protruding from the oral cavity so that ejected stomach contents will be expelled to *the exterior The cuff is inflated with air* to the point of resistance so as to insure that any regurgitation of stomach contents will take place only through the tube (Fig 3)

Following endotracheal or endoesophageal intubation the anesthetist induces the patient into general anesthesia The airway of the patient who has an esophageal tube is to be maintained patent—our practice is to use endotracheal intubation

The following objections have been levelled against our method of esophageal *intubation* Intolerance of the conscious patient to the procedure compression of the trachea causing respiratory embarrassment ulceration of the *esophageal mucosa due to pressure and* cardiac irregularities Clinically, the authors have not observed any such untoward effects Studies including bronchoscopy, esophagoscopy *and*

* The tube found by us to be most suitable for this purpose is a 32F suprapubic Foley *hemostat* bag drain because of its length caliber and the capacity of its bag

4A 4B

FIG 4 A x ray of patient with tube in esophagus and bronchoscope in trachea Balloon of tube filled with 30 cc of barium Bronchoscopic observations made on a number of patients has not revealed compression of any part of the tracheobronchial tree by the inflated balloon B x ray of patient with tube in esophagus Balloon filled with 60 cc of barium In practice balloon is usually distended to 30 cc This x ray demonstrates that distention of balloon to 60 cc does not cause tracheal compression

radiography have substantiated this clinical experience (Fig 4) Therefore esophageal intubation with a cuffed tube is a safe, simple and effective procedure which should be used whenever the indication arises for it may be life saving

OBESITY

A discussion of this condition is included because many obese patients manifest some degree of respiratory embarrassment, and because their respirations are frequently characterized by a prolonged and forcible expiratory phase which renders difficult adequate abdominal relaxation during general anesthesia

Because these patients often obstruct early during the induction of general anesthesia they are frequently referred to as "poor breathers" The oropharyngeal airway is not only ineffective in relieving the obstruction but also many times initiates vomiting and laryngospasm Attempts at endotracheal intubation at this stage are often traumatic because of poor relaxation active pharyngeal and laryngeal reflexes and because the habitus of the patient makes visualization of the larynx most difficult Therefore the best way to insure the patency of the airway of the obese patient who is to receive general anesthesia is to intubate him while he is conscious

The difficulties encountered in maintaining the patency of the airway and in producing good abdominal relaxation render general anesthesia a poor choice for these patients Therefore whenever possible, regional anesthesia should be selected

Since pulmonary complications are prone to develop these patients must be given the same care postoperatively as described for those with bronchopulmonary diseases

SUMMARY

The authors have discussed certain clinical entities that affect pulmonary function and have shown how the knowledge of the disturbances involved aids in the selection of the correct anesthetic agent and technic We have stressed the importance of preinduction endotracheal intubation and tracheostomy as a means to obviate serious respiratory obstruction We have presented a method of preventing aspiration by the use of the endoesophageal tube Finally, we have emphasized the importance of meticulous care of the patient during the immediate postanesthetic period in the prevention of postoperative pulmonary complications

Tracheotomy*

MARK H WILLIAMS M D Binghamton New York

From the Surgical Departments of Binghamton City Hospital Binghamton New York Ideal Hospital End cott New York and C S Wilson Memorial Hospital Johnson City New York

FOLLOWING serious thoracic injury or extensive thoracotomy recovery of the patient frequently depends largely upon meticulous attention to keeping the tracheobronchial tree clear of blood and secretions To accomplish this objective special nursing technics are utilized which assist the patient in raising In addition intratracheal catheter suction is frequently required and bronchoscopic aspiration may occasionally be necessary In certain situations all of these measures are inadequate or ineffectual and a direct surgical approach to the problem by tracheotomy is required Recently the increased utilization of this simple procedure has gained wide acceptance and ascendency and many fatalities have been prevented which formerly would have been attributed to traumatic or postoperative pneumonia heart failure and lung congestion or traumatic wet lung

It is the intent of this section to attempt to set in proper perspective the role of tracheotomy in thoracic surgery Several categories of patients in whom the procedure has been utilized will be considered with emphasis on its application in those having multiple rib fractures Technical aspects of the operation and certain considerations in aftercare which are believed to be of practical value will be presented

General Considerations The application of tracheotomy for indications under consideration here is a wide departure from its traditional role of bypassing a high or laryngeal obstruction We are concerned here with low obstruction produced by blood or secretions occurring as a complication of a thoracic operation or injury It might be added parenthetically that for purposes of this discussion thoracotomy and chest injuries can be considered synonymous

Some difficulty in raising tracheobronchial secretions can be anticipated after any thoracic injury or operation The problem is increased directly with the volume of the secretions and the severity of the postoperative pain and inversely with the respiratory reserve of the patient These factors in turn are related to other considerations which include the stability of the chest wall diaphragmatic function arthritis pulmonary emphysema bronchospasm and finally such intangibles as the stamina and determination of the patient

Although tracheotomy has been utilized as a prophylactic measure it is a more conventional indication for the operation arises when clearing of the tracheobronchial tree by ordinary methods has failed In the latter circumstance the patient is unable to raise secretions effectually despite encouragement and assistance and tracheobronchial suction or bronchoscopic aspiration is required at such frequent intervals as to make these methods impractical In this situation operation should be performed without delay before the inevitable pneumonia or atelectasis has had time to develop

Benefits of Tracheotomy The most important single benefit gained by tracheotomy is the provision of a dependable avenue for thorough tracheobronchial aspiration After introduction of the tube clearing of the airways can be accomplished by the average nurse at an instant s notice constant attendance by medical attendants skilled in the use of a tracheobronchial catheter or bronchoscopy is not required The operation also permits the administration of oxygen directly into the bronchi in concentrations approximating 100 per cent and permits the administration of antibiotics by the highly effectual intratracheal route

In addition to the straightforward mechanical benefits noted heretofore certain important

* In addition to the classical indications for tracheotomy other important indications for prompt tracheotomy are fully discussed in the previous chapter

additional physiologic advantages are gained by tracheotomy These include a decrease in respiratory resistance, decrease in the dead space and stabilization of the chest wall [illegible] and correction of hypercapnia and acidosis [illegible] Carter and Giuseffi have made original experimental studies which support their views regarding the changes which occur in resistance and dead space Experience gained in this study has confirmed their contention that paradoxic chest wall movement is decreased by tracheotomy alone

CRUSHING INJURIES TO THE CHEST

In an earlier publication[illegible] it was shown that desperately ill patients in this category in cluding those having bilateral pneumonia may recover if tracheotomy is utilized These patients commonly enter the hospital in fairly good condition After an interval of twenty four to seventy two hours the accumulation of tracheobronchial secretions may initiate a vicious circle of increasing dyspnea paradoxic chest wall movement pain and anoxia which can be dramatically broken by tracheotomy

Patients in this crushed chest category usually do well if they have no bronchial secretions if they do not smoke or if they are able to cough effectually If tracheobronchial secretions are present in sufficient quantity to cause anoxia the administration of oxygen may mask the clinical picture Some patients do not require oxygen until several hours after injury and in this circumstance it may usually be presumed that an accumulation of tracheobronchial secretions has occurred It has been convenient to consider these patients in two categories (1) those who are unwilling to cough because of pain and (2) those who are unable to cough because of weakness and anoxia Effectual cough can almost always be established in the former in the latter group tracheotomy should be performed promptly if the therapeutic problem is not solved by in frequent tracheobronchial or bronchoscopic aspiration

In addition to the four cases described in an earlier study[illegible] nine additional patients with severe injuries to the chest have now been treated with tracheotomy * In every instance the injury was unusually severe and earlier experience indicates that without tracheotomy all would have failed to recover

Data referable to this entire group of patients have been assembled in Table 1 It is seen that all of the patients were men whose average age was forty eight, and that in almost half of the entire group the injury occurred in an automobile accident The number of ribs fractured varied from two to twelve and bilateral fractures were not uncommon It was exceptional for the patient not to have associated injuries and these were commonly multiple and of considerable magnitude Included is an example of fracture of a dorsal vertebra (patient O T) with transverse myelitis Cough was completely ineffectual in this patient because of muscle paralysis rather than pain and anoxia A previous report of the utilization of tracheotomy in this particular situation has not been found As might be expected atelectasis pneumothorax and hemothorax were frequent complications and four closed thoracotomies were performed This procedure was performed for pneumothorax in every instance and it is believed that the procedure should be utilized more frequently for hemothorax

It is of interest to note that paradoxic movement of the chest wall of sufficient severity to require traction was present in two patients one of whom died The other patient s chest wall was sufficiently stable to permit removal of the sternal traction after one week The oxygen requirements varied considerably and averaged ten days Many of the patients were given oxygen intermittently for a longer period especially after tracheal suction In general the patient s chest wall stability his strength and ability to cough and his oxygen requirements determined the time that the tracheotomy tube was left in place The average for the group was fifteen days It has been observed that pain from rib fractures usually disappears at least one week before solid healing occurs Among the thirteen patients there were twelve consecutive recoveries one patient died

In general the trend now is to perform the operation early before complications have developed Desperately anoxic patients similar to those described in the original report have been exceptional The following two cases are presented as additional examples of the bene

* Included are two patients operated upon by Dr Judson Griffin and Dr Michael Rizzuto who were seen in consultation

TABLE I

Patient and Date Seen	Sex and Age	No. of Ribs Fractured	Chest Wall Traction	Associated Injuries	Pulmonary Complications	Time from Injury to Tracheotomy	Type of Accident	Thoracentesis Required	Closed Thoracotomy	Time Oxygen was Required (days)	No. of Days Tracheotomy Tube was Used	Result
L. W.* 1930	M 44	1-7 R 1-4 L	No	Fractured right patella, left tibia and fibula	Hematoma of left upper lobe	24 hr	Automobile	No	No	10	20	Recovery
R. C.* 1950	M 61	4-8 L	No	Cerebral concussion	Atelectasis	4 days	Fall down elevator shaft	No	No	20	25	Recovery permanent cerebral damage from anoxia
J. McE.* 1950	M 42	6-11 R	No	Fractured scapula	Bilateral pneumonia	65 hr	Run over by bulldozer	No	Yes	16	21	Recovery
M. G.* 1951	M 59	9-11 L 9-8 R	No	Contusions, abrasions	None	72 hr	Fall down fire escape	No	No	3	12	Recovery
O. T. 11/13/51 to 2/3/52	M 32	3-4 L 7-9 12 R	No	Cerebral concussion, fracture dorsal spine D4, transection of spinal cord, paraplegia	Atelectasis, right pneumonia, bilateral	48 hr	Automobile	No	No	7	12	Recovery; complete paraplegia
W. A. (Case 1) 1932	M 13	None, gunshot wound of chest	No	Wound of left arm, axilla and chest wall	Hemothorax, atelectasis	48 hr	Gunshot wound	No	Yes	7	18	Recovery
M. R. 6/15/53	M 42	4-5-9-10 L	No	Laceration of face	Atelectasis, left lower lobe, hemothorax	2 hr	Automobile	Yes	No	9	12	Recovery
L. J. 7/27/53 to 9/11/53	M 40	5-7 L	No	Fracture dislocation of left hip, fractured pelvis, fractured right clavicle	Atelectasis, right lower lobe, traumatic pneumothorax, right	24 hr and 50 min	Automobile	Yes	Yes	11	13	Recovery
W. G. 10/2/53 to 11/25/53	M 74	2-3 L	No	Compression fracture of dorsal spine, hematoma of neck	Pulmonary emphysema, atelectasis, left lower lobe, bronchopneumonia	90 hr and 20 min	Patient struck by falling tree	No	No	6	8	Recovery
E. L. 3/20/54 to 4/1/54	M 37	1-5, 6, 8-9 R 3-5 L	No	Pneumothorax, right, multiple fractures of right femur, hemothorax, right, fractured skull	Traumatic pneumothorax, right, atelectasis, pulmonary hematoma	3 hr	Automobile	Yes	No	14	19	Recovery
W. S. 3/17/54 to 6/9/54	M 46	2-11 L 10-11 R	Yes	Concussion, compression fracture	Interpulmonary hemorrhage, wet lung, patchy atelectasis	4 hr	Automobile	No	No	7	16	Recovery
G. F. S. (Case 11) 3/10/54 to 7/24/54	M 63	4-8 L 3 R	No	Fractured pelvis, ruptured posterior urethra	Atelectasis, left lower lobe, traumatic hemothorax	26 hr and 15 min	Fall a distance of 25 ft. to black top driveway	Yes	No	18	23	Recovery
H. L., Sr. 8/13/54 to 8/16/54	M 63	2-6 L	Yes	Bilateral hip dislocation, bilateral pneumothorax	Traumatic pneumothorax, bilateral, atelectasis	36 hr	Automobile	Yes	Yes	3½	2	Died 3½ days

* Previously reported.

1 2

FIG 1 Chest roentgenogram exposed two days after injury demonstrates hemothorax on the left and evidence of patchy atelectasis Although the lungs appear to be fairly well aerated the patient was in coma due to retained tracheobronchial secretions and anoxia

FIG 2 Chest roentgenogram exposed approximately five weeks after injury demonstrates complete recovery from the chest injury

fits that may be obtained in situations in which the prognosis appears extraordinarily grim

CASE I This patient recovered without residual neurologic damage despite grave and prolonged anoxia His response to operation demonstrates that an excellent result may be obtained even when the patient s condition appears irremediable The utilization of the bronchoscope in administering oxygen and clearing the tracheobronchial tree before and during tracheotomy is illustrated

This thirteen year old boy accidently shot himself with a shotgun on November 2 1952, and sustained an extensive wound of the left arm, left axilla and adjacent chest wall He was admitted to the hospital where 1,000 cc of blood were administered the wound was debrided and a left closed thoracotomy was performed When first seen by me forty eight hours later the patient had been in coma for twelve hours Coarse palpable rales were present over the right lung and he was dyspneic despite oxygen administration Bronchoscopic aspiration was done without anesthesia and about 20 cc of thick purulent secretion were removed Oxygen was administered through the bronchoscope which was left in place during the performance of tracheotomy A No 4 tube was utilized and oxygen was subsequently administered through it The patient began to move his hands and feet after the operation but did not regain consciousness until the following day This boy subsequently made a complete recovery from the injury to the chest (Figs 1 and 2)

CASE II Another patient sustained a fractured pelvis and ruptured urethra in addition to an unusually severe injury to the chest This patient s progress as regards the injury to the chest followed a conventional pattern Atelectasis developed which required tracheotomy twenty four hours following injury, subsequently multiple chest aspirations were necessary

During a civil defense exercise on May 10 1954 a moderately obese, muscular sixty three year old man who was securely tied to a stretcher, was accidently dropped a distance of 25 feet He fell on his left side on a blacktop driveway On admission to a hospital shortly thereafter he was in severe shock and 1,000 cc of blood were administered When first seen by me four hours after injury the shock had been corrected and examination demonstrated evidence of multiple rib fractures and hemothorax on the left fracture of the pelvis and

3 4

FIG 3 Chest roentgenogram exposed t enty four hours after injury and immed ately before tracheotomy demonstrates atelectas s of the lower lobe of tl e left lung Cyanos s and dy spnea were present desp te oxygen admin strat on

FIG 4 Chest roentgenogram exposed approx mately ten eeks after injury There s ev dence of organ zed l emothorax at the left base the Flm is otherwise not remarkable

rupture of the urethra The patient was trans ferred by ambulance a distance of 70 miles and a few hours later emergency cystostomy was performed * The patient tolerated the opera tion well but the following day he was dyspneic and dusky despite oxygen Roentgenogram of the chest demonstrated atelectasis of the lower lobe of the left lung (Fig 3) Tracheotomy was performed and there was immediate improve ment following thorough tracheobronchial as piration and the administration of oxygen through the tracheotomy tube A large left hemothorax subsequently developed which re quired repeated aspiration The patient s respiratory reserve was severely limited and he became dusky with every tracheal aspira tion Intratracheal oxygen was required con tinuously for eighteen days after tracheotomy the tube was left in place for twenty three days The patient made an excellent recovery and was ambulatory when discharged twelve weeks after his injury (Fig 4)

POSTOPERATIVE LARYNGEAL EDEMA

Laryngeal trauma blind intubation or the use of an intratracheal tube which is too large may produce postoperative laryngeal or sub glottic edema [5 6 14] The narrowing may occa sionally be sufficiently severe to produce serious respiratory obstruction in other in stances the laryngeal edema produces a bottle neck which prevents the effectual raising of tracheobronchial secretions This complication is particularly prone to occur in children re producing the familiar signs of severe laryngo tracheobronchitis In this circumstance trache otomy may be urgently required Severe laryngeal obstruction occurred in Cases III and IV in Case V retained tracheobronchial secretions was the outstanding feature

CASE III K C a six year old boy under went left lower lobe lobectomy for bronchiecta sis on March 13 1941 The anesthetic agent was intratracheal ether oxygen The following day inspiratory and expiratory stridor de veloped with marked sternal retraction Trache otomy was performed as an emergency meas ure striking relief followed immediately and

evidence of patent ductus arteriosus An opera tion was performed on November 10 194 under intr (5 mm tub nic was sternal retraction moist rales in both lungs dyspnea and s gns of anoxia developed withi twelve hours after operation Emergenc tracheotomy was performed rel ef follo ve

* Dr Herbert Bandell

immediately and the patient made a good recovery

CASE V A thirty eight year old woman underwent left pneumonectomy for ulcerative pulmonary tuberculosis and tuberculous bronchitis* on October 30 1951 The anesthetic agent was intratracheal ether oxygen The patient tolerated the procedure well but forty-eight hours later hoarseness developed with difficulty in raising bronchial secretions progression of these symptoms and signs of retained bronchial secretions developed during the next twenty four hours and the patient required oxygen Tracheotomy gave immediate relief The tube was removed after one week the patient recovered and has remained well

TRACHEOTOMY FOLLOWING THORACOTOMY

After observing the benefits of tracheotomy in patients having anoxia due to retention of tracheobronchial secretions every surgeon of experience can recall earlier fatalities which might have been averted if this operation had been employed This is particularly the case in the field of thoracic surgery where increasing utilization of tracheotomy as both a therapeutic and prophylactic measure has recently proceeded apace In current practice the operation may be carried out prophylactically especially in patients having impaired pulmonary function when it can be predicted that unusual difficulty in raising copious tracheobronchial secretions will occur postoperatively Included in this category are patients having suppurative pulmonary disease who are explored and found to be inoperable or whose condition during operation does not permit completion of a definitive procedure Among these are examples of bronchogenic carcinoma having complicating bronchopulmonary suppuration The fairly high mortality currently being reported for exploratory operation for this particular malignancy might be favorably influenced by the more frequent utilization of tracheotomy

Impressive clinical data supporting the utilization of prophylactic tracheotomy after resection of carcinoma of the esophagus have been reported[12] Following this operation Holinger[8] has continued to employ the procedure as both a prophylactic and therapeutic measure in more than an occasional case In response to an inquiry Garlock[8] MacManus[11] and Sweet[12] all have reported utilization of this operation Garlock is opposed to its use prophylactically, and Sweet notes that he has never found it necessary following resection of lesions at the gastric cardia Inasmuch as these workers employ various incisions[7 10 12] it would appear that the operative approach itself is an unimportant consideration

TRACHEOTOMY FOR HIGH TRACHEAL COMPRESSION

A tumor producing narrowing of the trachea at the thoracic inlet may result in laryngeal edema requiring emergency tracheotomy In this circumstance the grave anoxia requires preliminary bronchoscopy and administration of oxygen through this instrument

CASE VI An obese seventy year old white man had noticed swelling of his neck for several months when laryngeal stridor and alarming anoxia suddenly developed A bronchoscope was introduced oxygen was administered through it and tracheotomy was performed Exposure of the trachea required traversing a firm tumor microscopic study of which demonstrated malignant lymphoma (reticulum cell type) Relief of the anoxia was immediate and striking The patient subsequently received intensive x ray therapy but failed to respond and died two months after operation

OPERATIVE TECHNIC AND AFTERCARE

Disfiguring scars contractures and delay in healing are considerations which have led to the routine utilization of a transverse rather than a vertical incision A T shaped incision in the trachea is made below the thyroid isthmus a large tube (usually No 6) is used The wound is left wide open and is usually packed loosely with plain gauze Oxygen 2 to 3 L per minute is administered through the tracheotomy and aspirations are done deeply A prostatic type catheter is frequently used to facilitate aspiration of the left bronchus At intervals of 4 to 6 hours penicillin dissolved in saline is instilled (1 to 2 cc containing 50 000 to 100 000 units) Changing the tracheotomy tube is required infrequently it can be removed as soon as the chest wall is reasonably stable and the patient is able to cough effectually Complete occlusion of the tracheotomy tube for twenty four hours is done before it is removed

* Previously reported[12]

SUMMARY

An indication for tracheotomy following thoracic injuries or thoracotomy may arise when there is serious difficulty in raising tracheobronchial secretions The procedure may be life saving and should be employed promptly when more simple measures are ineffectual in clearing the tracheobronchial tree

Experience with the operation in a group of patients having thoracic injuries is recorded with one exception all of the patients in this category recovered The utilization of tracheotomy following thoracic operations is discussed and its more frequent employment following exploratory thoracotomy for bronchogenic carcinoma is suggested Technical aspects of the operation and aftercare are outlined

REFERENCES

1 BLALOCK A Operative closure of the patent ductus arteriosus *Surg Gynec & Obst* 82 113 1946
2 CARTER, B N and GIUSEFFI J Tracheotomy—a useful procedure in thoracic surgery with particular reference to its employment in crushing injuries of the thorax *J Thoracic Surg* 21 495 1951
3
4 otomy—one solution for pulmonary problems in the critically ill patient *Journal Lancet* 71 43 1951
5 EISTEN B and MAILER, D Subglottic membrane a complication of endotracheal intubation *New England J Med* 245 957 1951
6 FLAGG P J Incidence and control of trauma accompanying endotracheal anesthesia *Arch Otolaryng* 53 439 1951
7 GARLOCK J H Combined abdominothoracic approach for carcinoma of cardia and lower esophagus *Surg Gynec & Obst* 83 737 1946
8 GARLOCK J H Personal communication
9 HOLINGER P H Personal communication
10 MACMANUS J E Combined left abdominal and right thoracic approach to resection of esophageal neoplasms *Surgery* 24 9 1948
11 MACMANUS J E Personal communication
12 REYNOLDS J T et al Role of tracheotomy in the postoperative care of patients subjected to esophagectomy *Arch Surg* 60 211 1950
13 SAMSON P C Immediate care of thoracic injuries, *GP* 3 39 1951
14 SHAW W M Edema of larynx rare complication of endotracheal anesthesia case report *Anesthesiology* 7 416 1946
15 SWEET R H Discussion of KENT E M and HARBISON S P Combined abdominal and right thoracic approach to lesions of middle and upper thirds of esophagus *J Thoracic Surg* 19 567 1950
16 SWEET R H Personal communication
17 VONLEDEN H A new concept of tracheotomy
18
19 bronchitis *J Thoracic Surg* 24 530 1952

Selection and Management of Patients for Air Travel

BURGESS GORDON, M D, *Philadelphia, Pennsylvania*

From the Department of Medicine, The Woman's Medical College Philadelphia Pennsylvania Read at the meeting of the Cuban Chapter of the American College of Chest Physicians, Havana Cuba December 1, 1954

DURING the earlier years of flying selection of patients with pulmonary diseases for air transportation was done with a view toward the calculated risk to be taken because of serious illness and only a small chance of recovery Little was known about the physiologic disturbances associated with lack of oxygen, vomiting and dehydration With the advent of modern pressurized airplanes and the perfection of technics of flying since the beginning of World War II, the dangers and contraindications have been greatly minimized [1] Illustrating the efficiency and wide margin of safety for air travel was the movement of countless injured and sick during the Korean action, a feat that would have been impossible even ten years ago Notwithstanding, the concern of patients and relatives who are not fully informed about air travel places considerable responsibility on the attending physician, especially in cases in which there are marked physiologic disturbances

In order to throw light on the safety of air transportation analysis was made of the medical histories of forty patients who flew from Philadelphia to their homes in the Middle West, Far West and Southwest Studies undertaken at the Jefferson Hospital and the Hospital of the Woman's Medical College included x rays of the lungs, sputum studies and, in certain instances, physiologic determinations of the pulmonary reserve by Dr Hurley L Motley The following conditions were present emphysema associated with silicosis, nine cases, fibrosis associated with tuberculosis or etiology unknown, seven, spontaneous pneumothorax, one, artificial pneumothorax two, pulmonary neoplasm, four, asthma nine, atelectasis, three pulmonary abscess, two, pneumonitis, one, and extensive consolidation of the lung associated with retained pulmonary secretions, two

It was emphasized to the patients that they should travel only in pressurized airplanes and as far as possible to avoid transfers from one airplane to another They were also advised to remain seated during the flight, except for toilet privileges Letters concerning the diagnosis, emergency oxygen treatment and provisions for boarding the airplane were sent to the appropriate officials twenty four hours before flight time A lift was advised for patients with dyspnea on exertion so that they could avoid climbing stairs into the airplane

The number of patients arriving without incident was thirty-six, four were removed at intermediate airports as a precaution Of those removed, one suffered from extreme nervousness with no significant disturbance of the lungs one with a pulmonary abscess experienced a mild bout of hemoptysis, the third a patient with emphysema, was anxious because of dyspnea, in the fourth patient manifestations developed which suggested tension pneumothorax

The following patients of the group with advanced pulmonary emphysema illustrate the safety of air travel Patient R H, age sixty three years, with a marked increase of residual air in the lungs (55 8 per cent of total lung volume), low oxygen saturation of the arterial blood (93 per cent) and reduced maximal breathing capacity (78 1 per cent based on predicted figure), returned to his home satisfactorily and recently has traveled extensively in the United States and South America He uses intermittent positive pressure (oxygen) breathing in flight as necessary, the apparatus being portable and easily employed It is interesting that he has crossed the Andes

Mountains comfortably in turbulent air Patient H T age sixty four years with severe emphysema the *function tests indicating a* high content of residual air in the lungs (54 7 per cent of total lung volume) with decreased arterial oxygen (92 per cent) and reduced vital capacity (41 *per cent decrease* of the predicted figure) returned to his home uneventfully by airplane a distance of approximately 1 850 miles

The disturbances of pulmonary diseases that may become prominent under certain conditions in air travel are elucidated in the physiologic studies of coal miners According to Motley [2] the basic factors are decreased ventilation as evidenced by lowered vital capacity and maximal breathing capacity, increased residual air characteristic of pulmonary emphysema with attendant mixing and dilution problems impaired diffusion due to increased resistance in the pulmonary membrane as in acute pulmonary edema, and unequal alveolar aeration and perfusion as found responsible for lowered oxygen tension Pulmonary fibrosis leads to impairment of the air circulation and although perfusion may be present ventilation becomes inadequate The respiratory problems are accentuated when the disturbed alveoli are perfused but non aerated causing circulatory pathways that act as small shunts thus reducing oxygen saturation While the distribution factor is a common disturbance in pulmonary fibrosis it is also noted in obstructive diseases such as atelectasis consolidation of the lung retained bronchiolar *secretions and bronchospasm*

In addition to the physiologic disturbances resulting from pulmonary diseases *per se* there are certain conditions of the pleural cavity that cause impairment of pulmonary function According to Smedal [3] two forces occur as the airplane gains altitude One force (and the more important of the two) is that which presses against the lung causing varying degrees of compression the second force directed to the thoracic cage causes expansion with elevation of the chest With expansion of the thoracic cage the thorax tends to assume a position of true inspiration which in the presence of a diseased lung greatly disturbs pulmonary function

The present considerations deal primarily with pulmonary disease and the *associated* influences of pneumothorax In certain cases the question has been posed regarding additional factors that may cause difficulties in *breathing* especially the behavior of the coronary arteries Smedal [3] mentions that individuals with coronary disease tolerate a degree of anoxia remarkably well This is *attributed to the extraordinary compensation* gained through an accelerated heart rate increased vital capacity and vasodilation especially of the coronary blood vessels attained at *the higher altitudes It should be realized* however that the real capacity of diseased coronary arteries is difficult to evaluate and understand The electrocardiograms taken of normal individuals subjected to 10 per cent oxygen in the inspired air corresponding approximately to an altitude of 18 000 feet may show far greater variations than are noted in abnormal subjects

In selecting patients for air travel the possi [illegible] appraisal Patients with paroxysmal cough severe dyspnea tension pneumothorax and bronchospasm easily provoked by smoke and odors should not travel by air Proper rest and assurance twenty four hours before departure of the plane are essential Both fatigue and anxiety are precipitating factors for intolerance to flight even at a moderate altitude and should be strictly avoided The common cold may be detrimental especially in complicating bronchiolitis and nasal sinusitis With reference to bronchial infections there is always the *possibility of dissemination of secretions* into the alveoli with resultant atelectasis and marked accentuation of pulmonary dysfunction Middle ear conditions might be provoked in cases of sinusitis in such cases it is desirable to postpone the flight Air travel for patients with active pulmonary tuberculosis should be discouraged since public health technics are difficult to arrange and there is always the possibility of hemoptysis

The treatment of disturbed function in emphysema requires the use of special apparatus prevention of attack is accomplished with assurance and instruction in the effective manner of breathing and expectorating It is essential for patients contemplating air travel to be relieved of their anxiety state otherwise *land conveyances should be used* For patients with bronchospasm the use of a bronchodilator

drug such as vaponefrin with nebulization should be employed before and during flight In cases of emphysema with shortness of breath on slight exertion apparatus for employing intermittent positive pressure breathing (oxygen) should be used before flight time, and in severe cases the apparatus should be taken aboard for periodic treatments As pointed out by Motley and co-workers[4] this type of treatment will relieve dyspnea when other forms of therapy fail In order to facilitate diaphragmatic breathing[5] especially in patients with a relaxed abdomen a special type of abdominal support should be worn[5] patients should be told to sit up straight and not slouch in order to favor adequate ventilation of the lungs with any desire to expectorate patients should take a full breath then cough at the end of expiration In cases of artificial pneumothorax it is advisable to reduce the intrapleural pressure a day or two before plane time in order to compensate for any possible expansion of air at the higher altitudes Pleural effusions with associated pneumothorax should receive adequate drainage before the flight Dramamine[9] is advised for air sickness

Patients often inquire about the advisability of smoking during flight Barach and co-workers[6] found that carbon monoxide poisoning due to the inhalation of tobacco smoke may under certain circumstances impair resistance to anoxia especially when the passenger is traveling without supplementary oxygen at altitudes of 10 000 to 12 000 feet In the modern pressurized cabin the possibilities of a significant disturbance due to smoking is unlikely yet it is desirable to use every precaution Smoking is not advised and as a further precaution patients should request a seat with a person who does not smoke

CONCLUSIONS

The present data indicate that air travel by patients with chronic non tuberculous pulmonary diseases may be entirely safe and comfortable The basic physiologic disturbances call for certain precautions notably the avoidance of fatigue undue exercise and anxiety states before flight time and moving about while in the plane It is essential for patients to employ proper breathing habits during air travel, and to use bronchodilator drugs with or without oxygen inhalations for attacks of dyspnea With proper therapeutic measures the maximum utilization of impaired pulmonary function is possible even in cases of marked disability

SUMMARY

1 There is considerable leeway for air transportation of patients with chronic pulmonary conditions

2 The physiologic disturbances of pulmonary diseases are discussed with special reference to aggravation that may occur in the presence of bronchospasm and upper respiratory tract infections

3 The physiology of pleuropulmonary conditions as manifested at the higher altitudes is discussed

4 Prevention and treatment of symptoms encountered during air travel are outlined

REFERENCES

Gordon B The select on of pat ents with cardio pulmonary diseases for air travel *D s of Chest* 23 [illegible] 102 1953

2 [illegible]

3 [illegible]

t on Med 23 33 37 1952

4 Motley H L Gordon B Lang L P and Theodos P A Impairment of pulmonary function in anthracosilicosis *Arch Indust Hyg* 1 133 1950

5 Gordon B The mechanism and use of abdominal supports in the treatment of pulmonary d seases *Am J M Sc* 187 692-699 1934

6 Barach A L Eckman M and Molomut N Modification of res stance to anoxia with especial reference to h gh altitude flying *Am J M Sc* 202 336 1941

Index

Abscess, ameb c hepatic 424
lung 62 6, 608-623
ang ocardiography in 153
asp ration type of 64
bacteri l gy of 608
bronchoscopy in 95 619
compl c itions of 65 609-610
differential d agnosis of 680
pathogenes s of 608-609
postoperative 457
residual cavities in 65
site of 608
solitary les n in 794
sputum examinat on in 85
surgical consideration in 617-623
treatment of 610-615
aerow l therapy 613
ant biot cs 610 620
aspiration 613
bronch oscopy 613
external drainage 614 621
pneumonectomy 615
postural drainage 612 620
resection 461 615 621
subdiaphragmatic fluoroscopy in 124
iromycin* in abscess of lung 611
resp ratory infecti ns 604
base balance 44 45
os s, resp ratory in emphysema 354
reatment of 898
l See Corticotrophin and cort costeroids
Acti-dione* in bronchomonil asis 396
Actinomycosis 404 406
resection in 463
Adaptation d sease 908
Addison s disease pulmonary changes in 271
Adenocarcinoma 695 804
resection of trachea in 872
Adenoids, infected and cough 224
Adenoma bronchial 665 666
bronchoplasty in 883
bronchoscopy in 94 97 673
bronchotomy in 869
carcinoid 665
cyl ndroid, 666
flap procedure in 870
lobar transplant in 871
oncocyto d 665
resect on in 460
sol tary 795 799
Adenomatos s pulmonary 665 735
Adolescents tuberculosis in 574 580
Aeration gradient 40
Aerosol th erapy 894 898
in abscess of lung 613 620
alevaire* 232 357 896
bronchodilators 894
in bronchomonilasis 396
continu us 895 897
in cough 232
in emphysema 357
panmic bromide* 894
pancreatic d rnase 895
in resp r tory imp irment 893
vaponefrin* 232 265 357 620 894
Agenes s of lung 144 309-313
angiocard ograph 3 143
d agnosis of 31
pathogenes s of 309
Air leaks in surgery 2 8,
Air space abn rm l t es See Cystic d sease
Air travel cons d r t ons 933 937
Alarm react n 9 8
Alevaire* 896
in cough 232
in emphysema 357
Alkalos s respiratory 178
Allergy 251 268
bronchi l asthma 253 267
bronchial d sease sputum ex amination in 86
cough from 224 232 259
extracts n 254
to fo ds 253
to fung 253
to insects 253
nasal tests 254
ophthalm c tests, 254
poll nosis 251 259
rhinitis 251 259
skin tests 253
status asthmaticus 267 268
vascular and asthma 261 263
Alveolar capillary membrane 31
cell tumor 460 735
equation 30
gas exchange with pulmonary cap llaries, 29
ventilation 28 34
Amebias s, 424
Amidone in cough 230
Am nophylline in bronchial asti ma 264
in cough 231
in emphysema 255
Aminopterin in leukemia 771
Ammonium cl lorid in co gh 230
Amyloidosis, pulmonary changes in 272
Anaphylaxis leukocyte count after 24
Anatomy of bronchi 12 16
of larynx 17 18
of lungs 1 10 17 23
of pleura 817
of tracheobronch al tree 18 19
Ancylostoma duodenale 426
Anemia s ckle cell pulmonary changes in 270
Anesthes ol gy 477 485 921-927
atelectas s in risk of 453
in bronchography 144
in bronchopulmonary disease 921-924
postoperative care 923
preoperative care 922
cardiac arrest in 498
circulation maintenance in 483 484
equipment for 484
in intrapleural disorders 924
in med astinal shift 480
in neuromuscular d sturbances 925
in obes ty 927
paradoxic resp rati n in 480
respirati n maintenance in 478-483
respirat ry bstruction 481 483 921
in surgery for c rcin ma 715
in the full stomach 925-927
vent l t on during operat on 493
Aneurysm arteriovenous of lung 321 325
course of 324
diagnosis of 324
laboratory f nd ngs in 323
p thologic anatomy of 321
physiology of 322
roentgenology in 323
symptoms of 322 323
treatment of 325
dissecting pulmonary complications of 194
of great vessels ang ocard ography in 155
Rasmussen s, ruptured in hemorrhage of tuberculosis 553
Ang ocard ography 80 138 147 161
in agenesis of lung 149
in aneurysm af great vessels 155

Angiocardiography (*contd*)
in anomalies of pulmonary arteries 147
in anomalies of pulmonary veins 150–151
in bullous emphysema 156
in cancer of lung 160–161
in cystic disease 650
in fibrosis pulmonary 155
in fistula arteriovenous pulmonary 151
in infections pulmonary 151 155
method of 147
in miscellaneous pulmonary diseases 156
in thrombosis pulmonary 218
in tumors benign 672
Angiomatosis arteriovenous differential diagnosis of 680
Anomalies of bronchi 12 16
of lungs 1 10
Anthrax pulmonary 306
Antibiotics in abscess of lung 610 620
in surgery 496
Anticoagulants in pulmonary embolism 212
long term therapy 213 215
Antigen 251
Antihistaminics in allergic rhinitis 257
in cough 232
Aortic arch double 187
right 187
Aplasia of lungs 2 309
Aralen® in malaria 423
Arteries bronchial 21
carbon dioxide content in disease 178
oxygen saturation in disease 177 387
pulmonary 21
absence of angiocardiography in 147
anomalies of 9
embolism and infarction of 209–215
occlusion of angiocardiography in 155
thrombosis of 217 222
Arteriovenous aneurysm of lung 321 325
See also Aneurysm arteriovenous of lung
angiomatosis differential diagnosis of 680
fistula resection in 464
Arthritis rheumatoid 284
Artificial circulation 501
cough 360 891 904
respiration 43 316 478 501
See also Pressure breathing
Asbestosis, 388–389
diagnosis of 388
pathogenesis of 380
Ascariasis 426
Aspergillosis 402 404
resection in 464
Asphyxia neonatorum and atelectasis 315
Aspiration diagnostic, 78
in amebiasis 425
in carcinoma of lung 704 712
in lipoid pneumonia 347
in pleurisy with effusion 826
therapeutic in abscess of lung 613
double suction technic 923
in hydatid cyst 449
Asthma bronchial 225 259–267
bronchopulmonary reactions in 260–261
bronchoscopy in 97
cardiovascular complications in 260–261
in children 265
chronic sinus disease in 264
clinical picture of 260–263
diagnosis of 263
etiology of 259
pseudo-asthma 470 471
sputum examination in 86
status asthmaticus 267 268
hormone therapy in 909 910
treatment of 264
corticosteroids 910
corticotrophin 909
nerve surgery 469
vascular allergy in 261 263
Atelectasis 65–66 447 450 625
acquired 447 449
bronchial obstruction in 447
bronchoscopy in 97
in childhood resection in 571–572
compression in, 447
diagnosis of 449 451
differential diagnosis of 211
fluoroscopy in 125
massive pulmonary collapse in 449–450
myocardial infarction and 194
of newborn 314 320
and asphyxia neonatorum 315
clinical picture of 314
differential diagnosis of 315
incidence of 314
management of 315 317
new method of treatment 317–320
pathogenesis of 314
prognosis of 315
physiology of 448
postoperative 508
prevention of 227
prognosis of 449
prophylaxis of 453 454
symptoms of 449
syphilis and 193
treatment of 449 454
Aureomycin *See* Chlortetracycline
Aurin Tricarboxyl ■ Acid (ATA)
in beryllosis 392
Autosen®, in cough 230
Avertin® anesthesia 923
Azygos vein lobe of 8
roentgenology of 139

Bacterial diseases with pulmonary changes 304–306
brucellosis 305
diphtheria 305
endocarditis 190
pertussis 304
salmonellosis 305
scarlet fever 304
typhoid fever 305
Bamboo phenomenon 489
Barium enema x rays 133
swallow procedure 132 133
Belts abdominal in respiratory impairment 891
Benadryl® in hay fever 257
Bennett breathing unit 46 360 9
Benylin® in cough 230
Berylliosis 390–392
roentgenology in 390
treatment of 391
Bicillin® in lung abscess 611
Bilobectomy 458
Biopsies diagnostic 79
aspiration *See* Aspiration diagnostic
in disseminated pulmonary disease 89–92
technics 89
in hemoptysis 208
in pleural tumors 835
scalenus fat pad in sarcoidosis 288
Blast injury 811 812
Blastomycosis 397 399
diagnosis of 398
mode of infection 398
onset of 398
pulmonary involvement in 398
resection in 464
treatment of 398 399
Blebs emphysematous 71 114 641–644 837
See also Cystic disease
Blood arterial oxygen in 41
cultures as diagnostic aid 77
diseases with pulmonary changes, 269–271
hemosiderosis 270
leukemia 269 771 774
myeloma multiple 270
plasmacytoma 270
polycythemia vera 270
sickle cell anemia 270
flow diversion of 502
hemoglobin in cardiopulmonary disease 177
supply to lungs, 21 22
vessels *See* Arteries Vascular conditions and Veins

Breast cancer inoperable 766 767
Breath fetid 224
Breathing exercises 358 371 516 891
pressure *See* Pressure breathing
See also Respiration
Bronchial conditions arteries 21
asthma 259–267
See also Asthma bronchial
bleeding into bronchial 482
closure of divided bronchus 864 866
eparterial 5–6
fistula 248 250
lobar 6 141
mucoid impaction resection in 462
obstructions, 66 672
and atelectasis 447
ball valve 627 642
in children 636–638
posteparterial 6
preeparterial 6
roentgenology 111 113
segmental 6 12 16
sequestration 8–9
stenosis in childhood 574
subsegmental displacement of 6
surgery in 863–877
veins 22
Bronchiectasis 62–65 596–607
in adolescents, resection in 578
angiocardiography in 153
bronchography in 136 143
in children resection in 572
complications of 64
cystic *See* Cystic disease
diagnosis of 597 603
differential diagnosis of 239
dry 596
etiology of 596
in older patients, 603–607
roentgenology in, 114
sinusitis and 225
sputum examination in 86
symptoms of 596
syphilis and 193
treatment of 597–600 603–607
antibiotics 598
nerve surgery 471
pneumonectomy for hemorrhage 604
postural drainage 598
resection 461
surgical excision 598
Bronchiolar carcinoma 735–745
Bronchiole terminal 17 355 604
Bronchiolectasis 63
Bronchitis, 235 240
in children 237 239
chronic 226
ciliary action in 237
collateral respiration in 236
cough in 236
diagnosis of 238 239
emphysema and 354
Bronchitis (*contd.*)
fibrinous 237
roentgenology in 116
secretions in 237
sinobronchitis 225
sputum examination in 85 86
treatment of 239–240
Bronchobiliary fistula 249
Bronchocolic fistula 249
Bronchoconstriction and emphysema 357
vagotomy in 469
Bronchodilators 894
Bronchoesophageal fistula 247
Bronchogenic carcinoma 667 677 686–690 694–698
Bronchogluteal fistula 250
Bronchography 135 136 138 143 146
anesthesia in 144
in bronchiectasis 59 603
bronchoscopic method 145
in congenital anomalies
in children 146
contrast media 143
in cystic disease 652
dangers in 146
indications for 143
methods of 144 146
preparation for patient 144
subglottic 145
supraglottic 144
transglottic 142
Broncholithiasis, 241 243
bronchoscopic features of 244
bronchoscopy in removal of 96
bronchotomy in 874 875
clinical features of 242
diagnosis of 244
endobronchial 242
intramural 242
pathogenesis of 241 242
roentgen features of 243
treatment of 245
Bronchomoniliasis 394 396
diagnosis of 395
mild 395
mode of infection 394
severe 395
treatment of 396
Bronchopericnephric fistula 249
Bronchoplastic procedures 869–876 879–887
in adenocarcinoma 872
in bronchial adenoma 869 870 871 883
in carcinoma bronchogenic 874 884 895
flap procedures 867 870
technic of 886
in trauma 875 880–883
in tuberculous bronchostenosis 883
in tuberculous endobronchitis 875
See also Bronchotomy
Bronchopleural fistula 246–250
Bronchopneumonia sputum examination in 85
Bronchopneumonic infiltrations in sarcoidosis 294
Bronchopulmonary
anesthesia in disease 921–924
lobes, 140
segments 12 16
sequestration intralobar 657 663
suppuration in children 635 636
tension cystic disease in childhood 632–634
Bronchoscopy, 78 93–98
in abscess of lung 95 613 619
in adenoma 94 97 673
in agenesis of lung 310
in anesthesiology 482
in asthma 97
in atelectasis 97 454
in bronchiectasis 603
in bronchography 145
in broncholiths, 96 244
in carcinoma 94 705 708 712
in children 96
contraindications to 93
in cystic disease 650 655
in foreign bodies 96 444
in hemoptysis 95 207
indications for 93
in multiple primary cancers 725 726
in pleurisy with effusion 827
in stridor or wheezing 95
in tracheal stenosis 96
in tracheobronchial tuberculosis 94 96
as treatment 96–97
in tumors benign 673
Bronchospasm and emphysema 357
vagotomy in 469
Bronchostenosis, 574 875 883
Bronchosubphrenic fistula 248
Bronchotomy 867
in bronchial adenoma 869
in bronchiolithiasis 874 875
in tumors benign 673
Brucellosis pulmonary changes in 305
Bucky chest x rays 132
Bullae emphysematous 71 114 642 837
See also Cystic disease
Bullet wounds 815
Burns 812–813
Butazolidin® in Hodgkin's disease 760
Butyn® anesthesia 144

Calcification cartilage fluoroscopy in 118
chondral fluoroscopy in 118
in corn lesions 786–787 793
lymph node 241

Calcifications (*contd*)
metastatic, of lungs, 271
roentgenology in, 108
Calcreose®, in cough, 231
Calculi, bronchial, 241–245
See also Broncholithiasis
Cambridge glass electrode, 45
Camoquin®, in malaria, 423
Candidin, in bronchomoniliasis, 396
Caramiphen ethanedisulfonate, in cough, 229
Carbon dioxide, arterial and venous content, in cardiopulmonary disease, 178
effect of, in respiration, 33
intoxication, 897
regulation in body, 42–44
therapy, in cough, 231
Carcinoma, adenocarcinoma, 695, 804, 872
bronchiolar, 735
diagnosis of, 742–743
etiology of, 740
histogenesis of, 740
incidence of, 741
metastases in, 743
pathology of, 740–741
prognosis of, 744
radiography in, 742
symptoms of, 741
treatment of, 743–744
bronchogenic, 67, 694 698
angiocardiography in 160–161
aspiration in, 704
bronchoscopy in, 94 705–708, 712
causes of death, 697
cytology in, 691–693 704
diagnosis of 783–784
differential diagnosis of, 211, 67[illegible]
exploratory thoracotomy in, 709–710
from liquid petrolatum, 351
laboratory findings in, 697
pathology of, 694–696
physical findings in chest, 697
pleural effusions in 697
preclinical, 686–690
prognosis of, 697
roentgenology in, 699 702, 703–704
differential diagnosis, 701–702
in hilar tumor 699
in parenchymal tumors 699
in peripheral tumors, 700
site of tumors, 699–701
selection of cases, 704 710
small cell type, 695
solitary lesions in, 798
squamous cell type, 695
surgical technics, 712–721
anesthesia, 715
extent of operation, 714
operability, 713–714
Carcinoma, bronchogenic, surgical technics (*contd*)
preoperative preparation, 714
radical pneumonectomy, 715–721
symptoms of, 696
treatment of, 697
bronchoplasty, 884–885
extrapleural resection, 854
nerve surgery, 470
resection, 710–711
tracheal resection, 874
tracheotomy, 933
inoperable, 761–772
accurate diagnosis of, 761
anatomic disturbances in, 762
of breast, 766–767
bronchogenic, 764
leukemias, 771
lymphomas, 767
metastatic, 765–766
physiologic disturbances in, 763
prostatic, 767
pulmonary disturbances in, 762
supportive measures in, 771
of thyroid, 767
treatment of, 764–772
metastases. *See* Tumors, metastatic
multiple primary cancers, 722–733
compilation of cases, 724–725
diagnosis of, 725–727
diagnostic criteria, 723 724
histologic types of, 727
oral cavity cancers, 728
solitary metastases, 729
synchronous and metachronous, 724
treatment of 727
Carcinosarcoma, 754
Carcinosis, miliary, 749
Cardalin®, in emphysema, 231, 357
Cardiopulmonary diseases, 173–198
arterial oxygen saturation in, 177
bacterial endocarditis, 190
blood hemoglobin in, 177
carbon dioxide content of arteries and veins, 178
chronic cor pulmonale, 196–198
circulation time in, 176
circulatory function studies 183
classification of, 173
clinical picture of, 183
congenital cardiac lesions, 187–188
cyanosis in, 175
differentiation between pulmonary and cardiac disease, 173–179
dissecting aneurysm, 194
dyspnea in, 174
electrocardiogram in, 176, 184–185
Cardiopulmonary diseases (*contd*)
embolism, pulmonary, 210
emphysema and, 361
etiology of, 173–174, 180
extremities, appearance of, 174
hematocrit in, 177
hemoptysis in, 175
incidence of, 180
intrapericardial pressure, 191
laboratory tests in, 176–179
lung function studies, 178
mitral valvular disease, 189–190
myocardial infarction, 193–194
neoplasms, 195–196
pathogenesis of, 181–183
pericarditis, 190
pleural effusion in, 175
pulmonary disease affecting heart, 180–185
pulmonary disease secondary to heart disease, 187–198
rheumatic fever, 188–189
roentgenology in, 176 183
symptoms and signs of, 173 176
syphilis, 192–193
treatment of, 185
venous pressure in, 176
Cartilage calcifications, fluoroscopy of, 118
Casoni test, in hydatid cyst, 435, 440
Catarrh, in upper respiratory infection, 223
Cavernostomy, in tuberculosis, 524, 564
Cavities
in children, 570
in coccidioidomycosis, 418
pseudocavity, 121
roentgenology in, 103 113
in tuberculosis, 537–542
Cells, foam, 350
Cesium, radioactive, 780
Chicken pox, pulmonary changes in, 302
Childhood disorders
bronchial asthma, treatment of, 265
bronchial occlusions, 636–638
bronchitis, 237, 239
bronchopulmonary malformations, 632–634
bronchopulmonary suppuration, 635 636
foreign bodies, 442
hamartoma, 670
inoperable tumors, 771
lobar emphysema, 642
pleural fistulas, 638–639
resection in, 568–581
tension disorders, pulmonary, 631–639
tracheotomy in postoperative laryngeal edema, 932
Chloramphenicol, in abscess of lung, 611

Chlo amphen col (*contd*)
  ■ emphysema 357
  n pneumon a 339
Chloromycet n* *See* Chloran phen col
Chlortetracycl ne *in* absc ss f lung 611
  n emphysema 357
  n pneumonia 339
Chlor tr meton * in hay fever 257
Cholesterol pneumon t s, resect on n 462
Ch nd oma 667 678
Chordae tend neae ruptured and pulmonary d sease 190
Chor wen ng t s lymphocyt c pulmonary changes in 303
Chrom c phosphate rad oact ve coll dal 778
Chylothorax 832
Cil a re p ratory 19
Cil a y act n n bronch t 237
Circulat on art f c al 501
  collateral 448
  d term nat ons d agnost c 8
  funct on stud es 183
  ma ntenance n anesthes 483
  pulmonary 49–58
    b ochem cal funct on of lung, 57
    congenit. l anomal es of 147 151
    erythrocytes 49
    leukocytes 49
    physiology of 49–50
    platelet product on 55 57
    removal of leukocytes by lung 50–55
  resp ratory 35 36
  t me in card opulmonary d sease 176
Cirrhos s of l ver and pleural d s orders, 830
Clubb ng in arter ovenous aneu rysm pulmonary 323
  in carc noma 697
Cobalt teletherapy 779
Cocc d o domycos s 399–40 417 422
  bronchopleural f stula ■ 420
  cav t es n 418 420
    check valve mechan sm w th 420
    giant 4 9
    nfected 419
    ruptured, 420
  compl cat ons of 4 7
  empyema in 420
  hemoptys s in 420
  non expans le lung in 42
  pleu al effus on in 420
  resect on n 463
  surg cal consderat ons n 420–421
Cocc d oma 420
Code ne in cough 229
Collator 904
Co n f s ons 83 805
  in abscess 794
  adenon a of b onch us 795 99
  ben n tu nors 794
  calc cat n of 86–787 793 797
  c re n m 798
  case reports 8 790
  f gn s s of 92 96 8 3
    ob t cles to 92
  gr nulom tous 794 799
  han rtoma 795 8 0
  n hydat d d ase 94
  ne dence f 8 3
  n f ct on 94
  m t st t c nodules 796 98
  pleu l mesothel oma 8
  n pn un on t s, 794 8 0
  p n ary o l gnant tumors 95
  ro tgen l gy o 783 93 8 3
  s rcoma 798
  sk n tests n 794
  surgery ■ 803 805
  tre t nent of 804
  n vascular abn n al t s 33
Coll gen d s, 9 2 3 286
  et ology of 2 3
  pathology of 2 3
  periarter t s nod s 274 2 8
  rh eumat ■ fe r 284
  rh eumato d arth 284
  treatm nt l 285
Collapse ma s v f uln v 449 45
Collapse the py f tuba culos 523 560 56
  pneumop n o eum 23
  pneumotho 523
  thoracoplasty 23
Collater l c rculat on 448
  resp rat on 22 23 29 34 66 236 627
Comp ess on atelectas s, 44
  card c 50 502
Concuss on njury 8 8 2
Congen tal d se ses 309 32
  card ac les ons 18 88
    doubl aort c arch 8
    p tent ductus arter osus 88
    r ght aort c arch 8
  pulmonar l s ons agenes s of lung 4 49 309 3 3
    ing oc d og apl y n 47 51
    apl s a 2 300
    atelectas s of newbo n 314 320
      rt r ovenous aneurysm 321 325
    cyst c lung 64
    hern 329
    hypoplas a 309
Congest ve heart fa lure and pul monary stenos s 89
Copper sulphate n act nomycos s, 406
Cor pulmonale *See* Card opul monary d sease
Coram ne* n cough 231
Cor c din syrup* n cough 230
Cortef* in emphysema 357
Cort cotroph n and cort costero ds 908–918
  in beryll os s 391
  in bronch al asthma 265 909–911
  contra nd cat ons to 9 8
  dusts of nort sone 896
  effects of therapy 915–916
  n emphysema 357 911
  n f bros s pulmonary 185 913
  n granulomatoses pulmonary 912
  in hay fever 257
  n Hodgkin s d sease 760
  n nf ltrat ons th eos nophl a 9 4–9 5
  laboratory procedures n 917
  n leukem a 771
  prec ut ons in 9 7
  n resp ratory funct on impr r ment 892
    sarco dos s 897
  ■ status asthmat cus 9 9–911
Cort sone *See* Cort cotroph n and cort cost ro ds
Cosanyl* n cough 230
Cough 226–233
  allerg c 259
  art fic al 360 891 904
  n bronch ectas s 596 603
  n bronch t s 236
  n bronchol th as s 232
  n carc noma 696
  n ch ldr ■ 228
  in emphysema 354 369
    treatment of 355
  etiology of 226
  nab l ty to in trauma 920
  management of 227 228
    a rosol therapy 232
    ammon um chlo de 230
    d hydrocode none 229
    drug therapy 228 233
    gases 23
    morph ne 229
    ■ l nst llat ons 232
    panc rat c dornase 232
    potass um od de 230
    rad at on 232
    surg cal intervent on 227
  pathology of 227
  pharyngeal 238
  n pleur sy 823
  reflex 20
  in resp ratory infection upper 223
  tuss ve syncope 227
Creosotes in cough 231
Croup apparatus, 896
Crush ng injur es, ■ 4–815
  tracheotomy n 929–932
Cryptococcos s 397
  resect on n 464
Cryst c il n* n pulmonary sar co dos s 912

Cutaneous reaction in histoplasmosis 410
Cyanosis in cardiopulmonary disease 175 323
Cystic disease 624 663
angiocardiography in 156
atelectasis 625
bronchial occlusions 636-638
bronchopulmonary malformations 632 634
bronchopulmonary suppuration 635 636
causes for enlargement of cysts 642 644
in children 631-639
clinical findings in 631
compensatory overexpansion 625
compression 625
diagnosis of 649-650
differential diagnosis of, 680
emphysematous blebs and bullae 641 644
etiology of 8 642-644
hemorrhage 638
infected 646-647 654 656
course of 654
diagnosis of 655
intralobar bronchopulmonary sequestration 657-663
diagnosis of 657
incidence of 657
pathologic aspects of 658
symptoms of 657
natural history of 628 629
overdistention 624
overinflation 624
pathologic classification of 631 632
pleural fistulas 638-639
primary defect in 627-628
pulmonary function disturbances 643
roentgenology in 114
tension in children 631 639
reversibility of 625-627
rupture 637
spontaneous pneumothorax 837-844
therapeutic concept 645-652
treatment of 651-652
Cysts hatrachian 641
echinococcus roentgenology in 114
hydatid 430-441 *See also* Hydatid cysts
pulmonary 641
differential diagnosis of 65
resection in, 463
roentgenology of 109 114
sputum examination in 87
Cytology 601-603
See also Sputum examination

Dainite®, in emphysema 231 327
Dapsone®, 894
Dead space respiratory, 27
Decortication 845-851
concomitant operations 851
in empyema 847 848
in fibrosis of lung 70
in hemothorax 847
indications for 847 848
pathogenesis of hemo-organization 846-847
technics of 849-851
in tuberculosis 524 848 849
Defibrillation 503
Deltasone® in emphysema 358
Deltra® 918
in emphysema 358
Deltrasone® 918
Demerol® in bronchial asthma 265
Denervation autonomic 466-475
in bronchial asthma 469
in bronchiectasis 471
in bronchogenic carcinoma 470
in emphysema 472-474
in pneumothorax chronic recurrent 471
Dermatomyositis 282
Desoxyribonuclease pancreatic 895
in cough 232
Deve s lobe 142
Dextromethorphan hydrobromide
in cough 229
Diabetes pulmonary changes in 271
Diagnosis 73 80
angiocardiography 80
biopsies 79 89-92
blood cultures 77
bronchography 79
bronchoscopy 93-98
circulation time 80
complement fixation test 77
deep roentgen ray therapy 80
electrocardiogram 80
endoscopy 78
fluoroscopy 78
gastric contents 77
hematologic studies 75
history 73 75
laboratory aids 75-80
methods 73 80
physical examination 75
pleural fluid and gases 78
pneumoperitoneum 79 134
pneumothorax 79 133
precipitin test 77
radioactive isotopes 80
roentgenology 77
sedimentation rate 77
skin tests 77
sputum examination 76-77 81-87
thoracotomy 80
thoracoscopy 79
urine examination 76
venous pressure 80
Diamor® in respiratory function *impairment* 892
Diaphragm fluoroscopy of movements 121
roentgenology of *111 116*
Diaphragmatic breathing 316 937
Diffusion 29-32
Dihydrocodeinone in cough 229
Dihydrostreptomycin in abscess of lung 611
in tuberculosis, 521
Dilantin® sensitization to 261
Dionosil aqueous®, in bronchography 144
Dioxyephedrine hydrochloride in cough 230
Diphtheria pulmonary changes in 305
Dolophine® in cough 230
Dornase pancreatic 895
in cough 232
Drainage postural 598 612 620
surgical 405 507
Dramamine® in air sickness 937
Drawning mechanism of 57 58
Dust allergy to 258
Dylefrin® 894
in emphysema 357
Dyspnea in bronchiectasis 604
in carcinoma 696
in cardiopulmonary disease 174
causes of 225
in metastatic tumors 748
in pleurisy, 823
in spontaneous pneumothorax 838

Echinococcus granulosus 431
Edema postoperative laryngeal tracheotomy in 932
pulmonary 66 200-204
etiology 201-202
and mitral valvular disease, 189
and myocardial infarction 194
results of studies, 200-201
roentgenology in, 109
symptoms of 202
treatment of, 203-204
Electrocardiograms 80
in bronchial asthma, 262
in cardiac arrest 500
in cardiopulmonary disease, 176 184 187
pulmonary P wave 177
in thrombosis pulmonary, 218
Eliot breathing devices 360 894 900
Ellis S-line in pleurisy 824
Embolism and infarction pulmonary 209-215
and abscess of lung 609
complications of, 210
differential diagnosis of 210-211
findings in, 210
postoperative, 456
fat embolism, 456
prevention of 211 213

Embolism and infarction pulmonary (*contd*)
roentgenology in 115
signs of 210
symptoms of 209
treatment of 211–213
long term anticoagulant therapy 213 215
Embryology of bronchi 12 16
of lungs, 1–10
Emerson breathing unit 46 900
Emphysema 70–71 354 376
blebs and bullae 641 644 83[illegible]
See also Cystic disease
and bronchiectasis, 602
bronchiolectatic *See* Cystic disease
and bronchitis 237
and bronchoconstriction 35[illegible]
cardiopulmonary complications 181, 364
chronic pulmonary 354 361
compensatory 70 448 62[illegible]
reversibility of 626
and cough 228 231, 233
etiology of 362
fluoroscopy in 126
interstitial 807
lobar in children, 642
management of 355
mediastinal formation of 80[illegible]
obstructive [illegible]0
in infancy 636–638
manifestations of *See* Cystic disease
physiopathology of 354 355, 363
roentgenology in, 113 114
senile 70
subcutaneous, 808
symptoms of, 354
treatment 355 361
abdominal supports 358
antimicrobial agents, 357
breathing exercises 358 370
corticotrophin and corticosteroids 357 911
cough remedies 355
exsufflation 364
manual compression of chest 370
mechanical respiration 360
nerve surgery 472 474
oxygen 359
pneumoperitoneum 359 373 376
pressure application 362 372
sympathomimetic amines 357
tranquilizers 355
from tuberculous foci 543
vesicular 642
Empyema 820–823
in abscess of lung 613
in coccidioidomycosis 420
decortication in 847
encysted 860
excision of 853 861
Empyema (*contd*)
physical signs of 824
pneumococcal 821
postoperative 509 513
streptococcal 821
in tuberculosis pleuropulmonary resection in 857 861
See also Pleural conditions effusions
Endarteritis carcinomatous [illegible]63
Endobronchial lithiasis 242
tuberculosis 60 875
Endocarditis bacterial [illegible]
Endo-house dust 258
Endoscopy in tumors benign 672
Endothelioma pleural 833
vascular 667
Enucleation in tumors benign 6[illegible]4
Eosinophilia and allergy 263
pulmonary *See* Loeffler's syndrome
Eosinophilic granuloma pulmonary changes in 2[illegible]2
Eosinotactic factor [illegible]
Ephedrine, in cough 23
in emphysema 3 6
in respiratory [illegible]
Epinephrine in bronchial asthma 265
leukocytes and platelets [illegible]
in respiratory [illegible]
Epithelial tumors, 6[illegible]5 66[illegible]
Erythema multiforme exudativum pulmonary changes 3 2
Erythrocyte production 4[illegible]
Erythromycin® in abscess [illegible] 611
in pneumonia 33[illegible]
Esophageal intubation [illegible]26
Esophagogram 132
Esophagoscopy 70
Examination physical [illegible]
Excision wedge 458
Exercises breathing, 358 [illegible]0 [illegible]6 891
postoperative 516–519
Expectorants 229
Expectoration 224
in bronchial fistulas 246
Expiration fluoroscopy in 123
roentgenology in 130
See also Respiration
Expiratory
reserve 2[illegible]
squeeze 923
Exsufflation with negative pressure 904
in emphysema 362 372
Extosen® in cough 230
Extracts, in allergy 254
Extremities in cardiopulmonary disease 174
Eye test 254

Fat embolism 456
Fever in broncholithiasis 242
Fever (*contd*)
in carcinoma 696
in metastatic tumors 748
Fibrillation ventricular in surgery, 502
Fibrin balls 819
Fibrin bodies roentgenology in 109
Fibrocystic disease of pancreas pulmonary changes in 271
Fibroma 667
Fibrosis of lungs 68–70
angiocardiography in 154
bronchial pattern of 68
bronchiectasis and 602
cardiopulmonary disease and 185
corticotrophin and corticosteroids in 913
fluoroscopy in 126
interstitial pattern of 68
parenchymal pattern of 69
pleural pattern of, 69
in sarcoidosis 295
tuberculous foci causing 543
vascular pattern of 69
Fibrothorax tuberculous angiocardiography in 153
Fick principle 35
Filariasis 427
Fissure of lung supernumerary 7
Fistula bronchial 246–250
bronchobiliary 249
bronchocolic 249
bronchoesophageal 247
bronchogluteal 250
bronchopelvic 249
bronchopleural 246–250
in coccidioidomycosis 420
postoperative 509–513
bronchopulmonary in tuberculosis with empyema 859
bronchosubphrenic 248
pleural in children 638–630
pulmonary arteriovenous angiocardiography in 151
resection in 464
roentgenology in 109
Fluid thorax 809 814
Flap procedures 867 869
in bronchial adenoma 870
Fluid levels fluoroscopy of 120
Flukes 427 428
Fluoroscopy 78 117 127 138–139
in atelectasis 125
blood vessels 120
cartilage calcifications 118
confusing normal shadows, 118
in cystic disease 650
detailed survey 119
diaphragm 121
in emphysema 126
examination 117 123
expiration 123
in fibrosis pulmonary 126
fluid levels, 120
general survey 117
in hemoptysis 207

Fluoroscopy (*contd*)
infiltrations, 120
inspiration, 123
law of circle, 118
localization, 118
lymph nodes, 120
mediastinal shadow, 118
mediastinum, 123
neck, 118
nipple, 118
pathologic conditions, 123 127
in pleural effusion, 126, 826
in pneumonia, intrathoracic, 124
in pneumothorax, 126
positioning, 118
pseudocavity, 121
special problems, 120
spine 118
in subdiaphragmatic abscess, 124
in substernal thyroid, 124
in tracheal deviations, 123 124
vertebral borders of scapula, 118
visible lesion, 117
Flutter, mediastinal, 494
Foam cells, 350
Foods, allergy to, 253, 258
Foreign bodies, 442–446
ball-valve phenomenon, 443
in bronchus, 238
bypass-valve action, 443
check-valve phenomenon, 443
diagnosis of, 443–444
prognosis of, 445–446
removal by bronchoscopy, 96
stop-valve phenomenon, 443
treatment of, 444–445
Formalin injection of hydatid cyst, 440
Fracture, fat embolism after, 456
rib, 816, 929
Friction rub, in pleurisy, 823
Friedländer pneumonia, chemotherapy in, 342
Fungi, allergy to, 253
Fungus disease *See* Mycoses

Ganglionectomy, 466
Gangrene, pulmonary, resection in, 461
Gantrisin®, in respiratory infections, 604
Gas transport, 32–35
Gases, in cough, 231
Gastric
contents, as diagnostic aid, 77
cultures, tubercle bacilli in, 81
Gaucher's disease, pulmonary changes in, 271
Gilchrist's disease, 397–399
See also Blastomycosis
Glanders, pulmonary changes in, 307
Glyceryl guaiacolate, in cough, 230
Gold, radioactive *See* Radiogold
Graft, pericardial fat, 863–86-
Granuloma, eosinophilic, pulmonary changes in, 272
corticotrophin and corticosteroids in, 912
solitary lesions, 794, 799
Grocco's triangle, 824
Gunshot wounds, 815

Halliburton breathing unit, 46, 900
Hamartochondroma, 678, 679
Hamartoma, 669, 678 685
cystic, 632, 633
differential diagnosis of, 679–680
roentgenology in, 671
solitary lesion in, 795, 800
Hamman's sign, 807
Hand Schuller Christian disease, pulmonary changes in, 272
Hay fever, seasonal, 251–259
Heart, arrest during pulmonary resection, 498–504
in bronchial asthma, 260
compression of, 501–502
congenital lesions of, 187–188
disease, pulmonary, 173–198
See also Cardiopulmonary disease
failure, congestive, differential diagnosis of, 211
in surgery, 509
Hemangiomas, 678
capillary, 667
resection in, 464
diagnosis of, 671
Hematocrit, in cardiopulmonary disease, 177
Hematologic role of lung, 49–58
Hematology, as diagnostic aid, 75
See also Blood
Hemoglobin, in cardiopulmonary disease, 177
oxyhemoglobin, 32, 40
Hemo-organization, pathogenesis of, 846–847
Hemoptysis, 206–208
in abscess of lung, 613
in arteriovenous aneurysm, pulmonary, 323
in bronchiectasis, 596, 604
in broncholithiasis, 242
bronchoscopy in, 95
in carcinoma, 696
in cardiopulmonary disease, 175
causes of, 206
in coccidioidomycosis, 420
diagnosis of, 207–208
in embolism and infarction, pulmonary, 209
prognosis of, 208
treatment of, 208
in tuberculosis, 520
in upper respiratory tract infection, 224
Hemorrhage, into bronchi, 482
in cystic disease, 648
pulmonary, 206–208
Hemorrhage (*contd*)
in surgery, 506
in trauma, 810, 815
in tuberculosis, fatal, 546–553
See also Hemoptysis
Hemosiderosis, pulmonary, 270
Hemothorax, 831, 834
decortication in, 847
See also Hemorrhage
Hering-Breuer reflex, 838
Hernia, mediastinal, 329–330
pulmonary, 328 331
See also Cystic disease and Pneumatocele
Hilar node enlargement, in sarcoidosis, 289–292
Histaminase content in lungs, 57
Histamine, content in lungs, 57
leukocyte count after, 52
Histoplasmosis, 401, 408–415
bacteriology in, 410
cutaneous reaction in, 410
pathology of, 411–414
resection in, 464
serologic studies in, 411
symptoms of, 409
History of patient, 73–75
Hodgkin's disease, 755
bronchitic, 755, 757
clinical aspects of, 759
etiology of, 759
histologic findings in, 757–758
lobar, 755, 756
lobular, 755, 756
lung pathology in, 755–757
miliary, 755, 757
nature of disease, 760
nodular, 755, 756
pathogenesis of, 759
treatment of, 759, 767
Honeycomb lungs, 272
See also Cystic disease
Hookworm infection, 427
Hormone therapy *See* Corticotrophin and corticosteroids
HP acthar gel®, in bronchial asthma, 266
Humidification therapy, 895
Hycodan bitartrate®, in cough, 229
Hydatid
cysts, 430–441
biologic features of, 433–435, 440
daughter cysts, 432, 438
diagnosis of, 435–437, 440
solitary lesion in, 794
symptoms of, 435
treatment of, 437–441
sand, 432
Hydeltra®, 918
in emphysema, 358
Hydryllin®, in cough, 230, 355
Hydrocortisone *See* Corticotrophin and corticosteroids
Hydrothorax, 831

Hypertens on pulmonary roent
genology in 10[illegible]
Hypervent lation 40
Hypoplasia of lungs, 2 3 19
Hypo ent lat on 40
Hypor a carbon d ox de concentra
t on in 43
card ac arrest an l 499
cause s of 32

farct on myocard al 193 194
ulmonary 19 194 2 19
d fferent f d gno s of 68
roentgenology in, 1 19
sol tary l s on n 34
putum exam nat on in 87
ed cyst c disease 646 64
4, 656
infect ous d seases an l pulm nary
ch nges, 300–307
pasteurell infect ons, 3 [illegible]
r ckett l d seases 303 304
v ral d seases, 300–303
See also spec fic d sea es
Infiltrat ons w th eos noph l See
Loeffler s synd ome
Influenza pulmonary changes in
300–30
sputum exam nat on in 87
Inhalants, allergy to 258
traum from 813
Inhal t onal therapy 893 9 5
aerosols, 894–898
oxygen 897–898
pressure breath ng 898–903
See also specific s ems
halato s oxygen in 44
ects, allergy to 253
o at on fluorosc py in 123
es ure breath ng in 903
See also Press re breath ng
roentgenology n 130
See also Resp rat on
In p ato y capac ty 25
Inst llat ons o l 143
n b onchomon l s s, 396
Insufflat on mouth to-mouth 362
Interm ttent p sit ve pressure
b eath ng (IPPB) See Pressure
b eath ng
Intubation, endoesophageal 926
I d des n act nomycos s 406
n b onch al asthma 265
n bronchomon l as s 396
n cough 355
Iod ne rad oact ve n thyro d can
ce 67 773
Ipecac n cough 230
IPPB (nterm ttent pos t ve pres
sure breath ng) See Pressure
b e th ng
I dium rad o ct ve 789
I on lung act v ty and ron storage
57
o de s ch ated leukocyte
count after 53

Ison az d n tuberculos s 52
Isuprel® 894
n abscess of lung 62
in bronch l asthma 265
in e ugl 232
in emphysem 357
in s l cos s 387

Jaags ekte 740

K enbock s phenome on 122
Kl s e puln onary b ps 80
Klebs ll pneumon them
th py n 342 343
Kn fe w unde, 8 3
Kopl k s spot 30
Kypl c l os s n l he t l w
96

Lan n gr ph 3[illegible]
in ere n m
in hamarton s 68
Larvas n g at h 42[illegible] 42
Laryngotra h bro l
exam n t on n R u
Laryn 7 8
ed ma pos ope t
tomy n 32 cl
Le omyoma 168
Letterer S w l s
changes n 2 l
Leukem pul n n h ns
269
rad oph sph ru th py
treatment of 4
Leukem d or u n l k
cytes f om 5
Leukocyte count 4
after anaphylax 4
after ep nepl e 56
after h stam n 2
after ecte l f gn n te a s 53
aft r sooch r ted x de 53
after t u ext ets 5
after tr nsfu n 50
Leukocyte r moval and l by
lung 5 35
Lip odol® n bronch graphy 43
b onchomon l as s 396
Lipo d pneum 346 35
Lipom 668
Lipophages 350
L t l asis bronch l 24 245
See also Bronchol th as s
endobronc al 242
Liver am b e 424
c rrhos s of and pl u al disorders,
830
Lobe access ry roentg nology of
39
azygos 8
roentgenol gy of 39
bronchopuln n ry 40
congen t lly fused 7
Devi 139 42

Lobe con d
m ddle lobe synd on e 243 580
resect on n 462
Nelson dp s l lobe 7
Rokitansky lobes 4
Lobectomy 458
n bronch olar carc noma 43
extraple r l d ssect on n 853 855
n hyd t d cyst 437 438
n mult ple pr mary c ncers 727
n sol tary tumo s 8 4
n tumors ben gn 6 4
Lobule p mary 7
Loefll r s syndrome 262 272 403
62 909 9 4
c rt cotroph n and cort cos
tero ds n 9 4–9 5
l gnos s of 6
entgenol gy n o
l u s ngl of 8
l gs abscess of 62 65
at on gr d nt 40
ge es s of 4 49 309 313
anatomy of o 7 23
aplas 2 3 19
arter l am l es 9
arter es 2
See al o Arter s puln onary
atelectas s 65–66
b ochen cal funct on 5
b opsy n d ssemnat d d sease
89–92
n bl od d sorders See Blood d s-
eases w th pul non ry
cl anges
blood suppl to 2 22
bro cl c 4 s 62–65 596–607
See also Bronch ectas s
c p c ty 25 38 39 8
c p lla es nd gas exchange w th
lveol 29
c culat on pl ys ology 49–58
See also C rculat on pulmonary
collate al v nt lat on 22 23 28
34 66 236 627
compl nce of 25 39 79
congest on of roentgenology in
96
cyst c disease 624–663
See al o Cyst c d sease
cysts, 64
developmental anomal es of 1 19
d sease secon fary to heart disease
8 98
See also Card opulmonary
d s es
d se ses affect ng he rt 173 85
See al o Card opulmona y
d seases
d spl cement of bronch 6
See al o B onch l cond t ons
edema 66 200–204
See al o Edema pulmonary
embryology of 1 o
emphysema 70–7 354 376
See also Emphysema

Lungs (*contd.*)
epiarterial bronchus, 5–6
expiratory conditions *See* Expiration
fibrosis of, 68–70
See also Fibrosis of lungs
fissures, supernumerary, 7
function studies, 178, 179
in silicosis, 386
hematologic role of, 49 58
histamine content of, 57
honeycomb, 272
See also Cystic disease
hypoplasia of, 2, 300
infarction of *See* Infarction *pulmonary*
inspiratory conditions *See* Inspiration
iron storage in, 57
lability of pulmonary vessels, 35
lobe conditions *See* lobe
lobectomy *See* Lobectomy
lobule primary, 17
megakaryocytes in, 55
musculature of, 19–20
nerves of 20–21
non-aeration, acute, 65–66
oxygen transport in, 40–42
platelet production in, 55
pleuropulmonary diseases, 817–861
pneumatocele *See* Pneumatocele
pneumoconiosis, 377–392
pneumomediastinum, diagnostic, 134–135
pneumonectomy *See* Pneumonectomy
pneumonia *See* Pneumonia
pneumonitis *See* Pneumonitis
pneumotherapy *See* Pneumoperitoneum *and* Pneumothorax
pneumotyphoid syndrome, 306
prothrombin decrease in capillaries, 57
removal and release of leukocytes by, 50–55
residual volume, 25, 38
resistance, 25 179
respiration *See* Respiration
sequestration of, 8–9, 634
supernumerary, 4–5
in systemic diseases 269–307
transpulmonary pressure, 27
trauma, 806–816
tuberculosis *See* Tuberculosis
vanishing, 160
See also Cystic disease
vascular resistance, 47
venous anomalies, [illegible]
visceral lung function, 628
volume measurements, 25, 37–40, 178
wet lung, 482, 508, 810, 812
Lupus erythematosus, disseminated, 278
Lutembacher's syndrome, 189

Lymph, fluid, and pulmonary edema, 200
nodes, calcified, 241
fluoroscopy of, 120
tuberculosis of, 60
Lymphadenoma, tubercle-like, 833
Lymphatic spread of cancer cells, 747
Lymphocytic choriomeningitis, pulmonary changes in, 303
Lymphoma, 669
malignant *See* Hodgkin's disease
treatment of, 767
Lysholm grid, 132

Madone, in cough, 230
Malaria, 423
Maximal breathing capacity (MBC), 38
Measles, pulmonary changes in, 301
Mediastinal
emphysema, 807
fixation, in carcinoma, 705
fluoroscopy, 118, 123
flutter, 494
hernia, 329–330
roentgenology, 112, 116
shift, anesthesiology in, 480
Megakaryocytes in lung, 55
Meigs' syndrome, and pleural disorders, 830
Membrane component, 31
Mesoazygos, 8
Mesodermal tumors, 666–670
Mesotheliomas, pleural, 801, 833
Metabolic disorders and pulmonary changes, 271 272
Addison's disease, 271
amyloidosis, 272
diabetes, 271
fibrocystic disease of pancreas, 271
metastatic calcification of lungs, 271
tuberous sclerosis, 272
xanthomatoses, 271, 669
Metabolism needs in respiration, 27
Metacortelone, in bronchial asthma, 265
Metacortin, in bronchial asthma, 265
in hay fever, 257
Metastatic tumors, 746–751
See also Tumors, metastatic
Metazoa, 425 429
blood flukes, 427
long flukes, 428
roundworms, 426
Methadone®, in cough, 230
Methojade®, in cough, 230
Meticorten®, 918
in emphysema, 359
Miliary nodulation, in sarcoidosis, 292–294
Milibis®, in intestinal amebiasis, 425

Mineral oil, and lipoid pneumonia, 346
Mitral valvular disease, 189–190
Molds, allergy to, 253
Monaldi drainage, in cystic disease, 651
Monilia infection of lungs, 394–396
Mononucleosis, infectious, pulmonary changes in, 302
Morphine, in cough, 229
M S A. apparatus, 900
Mucoviscidosis, 237
Mueller maneuver, in fluoroscopy, 122, 124
leukocyte count after, 52
in roentgenology, 103, 130, 324
Mumps, pulmonary changes in, 301
Muscles of lungs, 19–20
Mustargen®, in carcinoma, 764
Myasthenia gravis, anesthesia in, 925
Mycoses, 393–422
actinomycosis, 404–406
allergenic, 253
aspergillosis, 402–404
blastomycosis, 397–399
bronchomoniliasis, 394–396
coccidioidomycosis, 399–401, 417–422
cryptococcosis, 397
histoplasmosis, 401, 408–415
mold like fungi, 394
resection in, 463–464
roentgenology in, 108
sporotrichosis, 402
sputum examination in, 87
yeast like fungi, 394
Mycostatin, in bronchomoniliasis, 396
Myeloma, multiple, pulmonary changes in, 270
Myoblastoma, 668
Myocardial infarction, 193–194

Naclerio double suction technic, 923
Nasal tests, in allergy, 254
Neck, fluoroscopy of, 118
Necrotic foci, subapical, after chemotherapy, 61
Nelson, dorsal lobe of, 7
Nembutal® anesthesia, 607
Neo-cortef®, in emphysema, 357
Neo-penil®, in abscess of lung, 610
Neoplasms, bronchial, 238
cardiac, 195
pleural, 833–836
pulmonary, and lung abscess, 609
resection in, 459
sputum examination in, 87
See also Tumors
Neosynephrine®, in abscess of lung, 620
in cough, 232
in emphysema, 357
in silicosis, 387
Nerve surgery, 466–475, 523

(approximately one to three seconds) and the desired positive pressure (0 to 40 cm H_2O) are both adjustable Upon reaching the preset positive pressure the machine shuts off the air flow and allows the patient to breathe out passively A slight inspiration by the patient starts the positive pressure and the cycle is repeated Therapeutic aerosols (e g bronchodilators) are provided during inspiration only with the use of the enclosed auxiliary air pump unit

2 When the dial is adjusted for cough the apparatus supplies controlled demand positive pressure on inspiration with adjustable pressures ranging from 0 to 40 cm H_2O The time during which the patient becomes inflated (approximately one to three seconds) is adjustable by means of an air flow control Upon reaching the preset positive pressure the machine automatically cycles to negative pressure This shiftover occurs in 04 seconds by means of an electrical solenoid valve The negative pressure is adjustable for 0 to 40 cm H_2O By dropping the mask or mouthpiece of +40 cm during inspiration to −40 cm H_2O during expiration a rapid expiratory air flow rate is produced simulating the human cough The time for the negative or expiratory phase is controlled by an electric time delay mechanism which is adjustable from one to three seconds The pressure changes are visible at all times on the face dial gauge

3 Resuscitation may be accomplished by setting the desired positive pressure and a small amount of negative pressure on expiration (P and N pressures) The automatic time delay mechanism on expiration is put into operation with patients with no demonstrable or very shallow respirations When the patients starts to breathe again the unit may be turned to demand intermittent positive pressure breathing—inspiratory only This function should be set up with an anesthetic tracheal airway and mask in place

4 The Vent EL Aire unit also contains an auxiliary oil free diaphragm air pump with tubal connection to a nebulizer inserted into the mouth or face piece This function provides the necessary air flows for the production of therapeutic aerosols during inspiration only In this manner bronchodilator (e g vapone-frin) antimicrobial (e g penicillin) enzymatic (e g pancreatic dornase) or detergent (e g alevaire) aerosols may be administered whenever indicated

1 Advances in the use of therapeutic aerosols oxygen therapy and pressure breathing therapy in the management of patients with chronic bronchial asthma pulmonary emphysema and suppurative lung disease are discussed

2 A new air pump apparatus for the production of all types of continuous aerosol therapy and the NebELizer croup tent apparatus for the administration of cold water vapors (humidity therapy) and alevaire (detergent agent) therapy are described

3 The use of three new therapeutic aerosols —an anticholinergic agent (pamine bromide) of value in certain types of bronchoconstriction pancreatic dornase a pus-liquefying enzyme of value in evacuating bronchial secretions and dusts and emulsions of cortisone and hydrocortone for allergic nasal states—are discussed

4 The hazards of the carbon dioxide intoxication syndrome and respiratory acidosis in patients with chronic anoxia secondary to chronic pulmonary emphysema and pulmonary cardiac disease are presented Their recognition prevention and specific management are briefly discussed The hazard of opiate induced respiratory acidosis is considerably reduced with the availability of nalline a remarkable opiate antagonist

5 The physiologic changes associated with pressure breathing therapy and clinical applications are discussed Typical recordings of the physiologic effects of IPPB inspiratory and alternating positive negative pressures are discussed

6 A new multipurpose air pressure unit the Vent EL Aire combining four of the main therapeutic functions in inhalational therapy is described for the first time

Acknowledgment The authors wish to make grateful acknowledgment to Mrs Dorothy Belgard Mrs Doris Koss and Miss Thelma Adelman for their technical assistance and to Drs J A Herschfus M J Dulfano and A Salomon for laboratory assistance in the preparation of some of the material

REFERENCES

1 SEGAL, M S The Management of the Patient with Severe Bronchial Asthma Springfield, Ill., 1950 Charles C Thomas.

2 [illegible]

adaptation syndrome' *Ann Int Med*, 33 134, 1950

3 SEGAL, M S and DULFANO, M J Chronic Pulmonary Emphysema Physiopathology and Treatment. New York, 1953 Grune & Stratton, Inc

4 SEGAL, M S, SALOMON, A and HERSCHFUS, J A Treatment of chronic pulmonary emphysema *Am Rev Tuberc* 69 915, 1954

5 BARACH, A L, BICKERMAN, H A and BECK, G J Advances in the treatment of non-tuberculous pulmonary disease *Bull New York Acad Med*, 28 353, 1952

6 BRESNICK, E, BEAKEY, J F, LEVINSON, L and SEGAL, M S Evaluation of therapeutic substances employed for the relief of bronchospasm v Adrenergic agents *J Clin Investigation*, 28 1182, 1949

7 BARACH, A L Physiologic methods in the diagnosis and treatment of bronchial asthma and pulmonary emphysema *Ann Int Med*, 12 454, 1938

8 SEGAL, M S, SALOMON, A, DULFANO, M J and HERSCHFUS, J A Intermittent positive pressure breathing Its use in the inspiratory phase of respiration *New England J Med*, 250 225, 1954

9. BEAKEY, J F, BRESNICK, E, LEVINSON L and SEGAL, M S Evaluation of therapeutic substances employed for the relief of bronchospasm iii Anticholinergic agents *Ann Allergy* 7 113, 1949

10. SALOMON, A, HERSCHFUS, J A and SEGAL, M S Pamine bromide aerosols in the management of bronchoconstriction Submitted for publication

11 HERSCHFUS, J A, BRESNICK, E, LEVINSON, L and SEGAL, M S A new sympathomimetic amine ("neosuprel") in the treatment of bronchial asthma *Ann Allergy*, 9 769, 1951

12 KIRSNER, I B and PALMER, W L Newer gastric antisecretory compounds *J A M A*, 151 798, 1953

13 SALOMON, A, HERSCHFUS J A and SEGAL, M S Aerosols of pancreatic dornase in bronchopulmonary disease *Ann Allergy*, 12 71, 1954

14 SHERRY S JOHNSON, A and TILLETT, W S The action of streptococcal desoxyribonuclease on purulent exudates *Proc New York Path Soc*, p 96, 1948-1949

15 SHERRY, S, JOHNSON, A and TILLETT, W S The action of streptococcal desoxyribose nuclease (streptodornase) in vitro and on purulent pleural exudations of patients *J Clin Investigation*, 28 1094, 1949

16 TILLETT, W S and SHERRY, S The effect in patients of streptococcal fibrinolysin and streptococcal desoxyribonuclease on fibrinous, purulent and sanguinous pleural exudations. *J Clin Investigation*, 28 173 1949

17 MCCARTY, M Purification and properties of desoxyribonuclease isolated from beef pancreas. *J Gen Physiol*, 29 123, 1945

18 SEGAL, M S, SALOMON, A and HERSCHFUS, J A Advances in inhalational therapy *South. M. J.*, 47 888 1954

19 LEVINE, E R., BARACH, A L., PEABODY, J W and SEGAL, M S Effective Inhalational Therapy Chicago, 1953 National Cylinder Gas Co

20 SALOMON, A, RADOVSKY, E S and SEGAL, M S A new croup tent apparatus employing the nebELizer for continuous aerosol administration. *GP*, 10 60, 1954

21. SEGAL, M S and SALOMON, A A new apparatus for continuous aerosol therapy The *nebELizer Journal Lancet*, 74 447, 1954.

22 BARACH, A L., BECK, G. J and SMITH, W H Mechanical production of expiratory flow rates surpassing the capacity of human coughing *Am J M Sc*, 226 241, 1953

23 SEGAL, M S, SALOMON, A and HERSCHFUS, J A Alternating positive negative pressures in mechanical respiration *Dis of Chest*, 25 640 1954

24 SEGAL, M S, DULFANO, M J and HERSCHFUS J A Advances in the physiology and treatment of bronchial asthma *Quart Rev Allergy*, 6 399, 1952

25 SEGAL, M S and HERSCHFUS, J A Oxygen therapy Description of a new face tent *Bull New England M Center*, 13 244 1951

26 DULFANO, M J, MACK, F X and SEGAL, M S Treatment of respiratory acidosis with n allylnormorphine (nalline) *New England J. Med*, 248 931, 1953

27 SALOMON, A MARCUS, P S, HERSCHFUS, J. A and SEGAL, M S *N allylnormorphine (nalline)*—action on narcotized and non narcotized subjects. *Am J Med*, 17 214 1954

28 BARACH A L Treatment of anoxia in clinical medicine *Bull New York Acad Med*, 25 370, 1950

29 COURNAND A, MOTLEY, H L, WERKO, L. and RICHARDS, D W, JR. Physiological studies of the effects of intermittent positive pressure breathing on cardiac output in man *Am J. Physiol*, 152 163 1948

30 MOTLEY H L COURNAND A, ECKMAN, M and RICHARDS D W, JR Physiological studies on man with pneumatic balance resuscitator, "Burns model" *J Aviation Med*, 17 431, 1946

31 WHITTENBERGER, J L. and SARNOFF, S J Physiological principles in the treatment of respiratory failure *M Clin North America* p 1335, 1950.

32 PRICE, H L, CONNER, E H and DRIPPS, R D Some respiratory and circulatory effects of mechanical respiration *J Applied Physiol*, 6 517, 1954.

[illegible]

L. E and HEGNAUER, A H Displacement of [illegible]

35 [illegible]

36 [illegible]

37 OTIS, A B., FENN, W O and RAHN, H Mechanics

of breathing in man *J Applied Physiol* 2 592 1950

38 FENN W O Mechanics of respiration *Am. J Med.* 10 77 1951

39 DAY R GOODFELLOW A M APGAR, V and BECK G J Pressure-time relations in the safe correction of atelectasis in animal lungs. *Pediatrics* 10 593 1952

40. LAUSON H D BLOOMFIELD, R A and COURNAND, A The influence of the respiration on the circulation in man with specific reference to pressures in the right auricle right ventricle femoral artery and peripheral veins *Am J Med* 1 315 1946.

41 HENRY J P HENDRICKSON L, MOVITT E and MEEHAN J P Estimations of the decrease in effective blood volume when pressure breathing at sea level Committee on Aviation Medicine Report No. 452 1945

42 MALONEY J V and HANDFORD S W Circulatory responses to intermittent positive pressure breathing and alternating positive negative pressure breathing *J Applied Physiol* 6 453 1954.

43 MALONEY J V ELAM, J O HANDFORD, S W BALLA G A EASTWOOD D W BROWN E S and TEN PAS R H Importance of negative pressure phase in mechanical respiration *J A M A* 152 212 1953

44 WHITTENBERGER, J L. and MALONEY J V Physiological factors in the use of body respirators for impaired respiratory function *Dis of Chest* 22 141 1952

45 STARR, I SCHNABEL, T G ASKOWITZ S I and SCHILD A Studies made by simulating systole at necropsy IV On the relation between pulse pressure and cardiac stroke volume leading to a clinical method of estimating cardiac output from blood pressure and age *Circulation* 9 648 1954

46 STARR, I Clinical tests of the simple method of estimating cardiac stroke volume from blood pressure and age. *Circulation* 9 664 1954.

47 MOTLEY H L WERKO L. COURNAND A and RICHARDS, D W JR. Observations on clinical use of intermittent positive pressure breathing *J Aviat on Med* 18 417 1947

48 MOTLEY H L. LANG L P and GORDON B The use of intermittent positive pressure breathing combined with nebulization in pulmonary disease *Am J Med* 5 853 1948

49 MOTLEY H L and TOMASHEFSKI J F Treatment of chronic pulmonary diseases with intermittent positive pressure breathing *Arch Med Hyg* 5 1 1952

50 SEART R H DAVENPORT C K and PEARSON G W Intermittent positive pressure breathing in emphysema of chronic lung diseases *J A M A* 150 1385 1952

51 MALONEY J V and WHITTENBERGER, J L. Clinical implications of pressures used in the body respirators *Am J M Sc* 221 425 1952

52 BECK G J SEANOR, H E BARACH A L and GATES D Effects of pressure breathing on venous pressure *Am J M Sc* 224 169 1952

53 BARACH A L. BECK, G J BICKERMAN, H A and SEANOR, H E Physical methods simulating cough mechanisms. *J A M A* 150 1380 1952

54 BARACH A L and BECK, G J Insufflation with negative pressure *Arch Int Med* 93 825 1954

55 BARACH A L BECK G J BICKERMAN H A and SEANOR H E Physical methods simulating mechanisms of the human cough *J Applied Physiol* 5 85 1952

56 BICKERMAN H A BECK, G J GORDON C A and BARACH A L Physical methods of simulating mechanisms of the human cough *J Applied Physiol* 5 92 1952

Corticotrophin and Corticosteroids

MAURICE S SEGAL, M D, J A HERSCHFUS, M D AND A SALOMON, M D, *Boston, Massachusetts*

From the Lung Station (Tufts) Boston City Hospital and the Department of Medicine, Tufts University School of Medicine Boston, Massachusetts

THE use of corticotrophin and corticosteroids in the treatment of pulmonary diseases should represent but a single phase, albeit important, in the total therapeutic program The earlier unbridled enthusiasm for this form of hormone therapy has been replaced by a more cautious attitude based on experiences with larger series of patients with various disease entities and with a wide variety of side effects

appear arrested, it is not usually suppressed The over-all value of hormonal therapy should be considered from not only the degree of remission obtained and its duration but also from the price paid by the patient, namely,

thalamic-anterior pituitary adrenocortical axis which did not exist before therapy This is of particular importance in dealing with the patient with pulmonary disease who may need surgical care The added surgical stress in patients who have been receiving hormonal therapy creates a greater hazard

The application of these hormones to the treatment of pulmonary diseases was based on earlier observations and experimental studies on other disease entities It was noted that the administration of desoxycorticosterone in animals produced changes resembling those seen in rheumatic and hypertensive diseases, particularly nephrosclerosis, periarteritis no-

sensitivity reactions in man and those produced experimentally in animals showed morphologic findings which are seen in such conditions as rheumatic fever, periarteritis nodosa, Loeffler's syndrome and rheumatoid arthritis[6-9] The basic changes which all of these pathologic states have in common are evidence of in-

sis of collagen and cellular infiltrations frequently occur in relation to small vessels with or without involvement of the vessel wall

The concept of "diseases of adaptation" followed the development of the theory of the "alarm reaction" evolved by Selye[10] In essence, this theory states that any stress condition will cause reflex stimulation of the adrenal glands via the anterior pituitary, by means of the corticotrophic hormones and the compounds poured out by the adrenals the individual is helped to adapt himself to the abnormal environmental situation Lack of proper adaptation or adjustment (falling by the wayside) will result in the development of one of the so-called diseases of adaptation, i e, periarteritis nodosa, rheumatoid arthritis and bronchial asthma It is of interest that many of the diseases of adaptation belong in the category of the so-called collagen diseases, and these in turn have a common denominator, namely, the histopathologic changes seen in diseases of hypersensitivity reactions

After the development of cortisone and ACTH by Hench, Kendall and others these hormones were first used in the treatment of rheumatoid arthritis and rheumatic fever As larger supplies became available, their effect was tested in most of the diseases classified as diseases of adaptation, collagen diseases and diseases of hypersensitivity Thus, in the realm of pulmonary diseases these hormones were soon used in the treatment of bronchial asthma, pulmonary emphysema, Loeffler's syndrome and in the pulmonary infiltrations associated

with periarteritis nodosa and disseminated lupus erythematosus.

From the vast volume of experimental and clinical observations of the effects of corticotrophin and corticosteroids, it was concluded that these hormones modify in a protective manner the body's response to injury, the usual response of cellular reaction with exudation and the elaboration of collagen appeared suppressed By suppressing the inflammatory process, the subsequent development of fibrosis and scarring appeared delayed or even prevented However, granulation tissue already present was not resolved by these hormones With these observations in mind the next step was, of course, to employ these hormones in the treatment of pulmonary berylliosis, silicosis, sarcoidosis and other pulmonary diseases which are characterized by the development of various types of fibrosis

General Indications for the Use of These Hormones in Pulmonary Diseases The indications for the use of these hormones in pulmonary diseases are essentially the same as for other diseases The hormones are mainly to be used when other drugs and the conventional methods of treatment are ineffective in securing remission or cure of the disease The hormones are then used in conjunction with other medication For example, the patient in status asthmaticus who does not respond to the usual therapy with aminophylline, bronchodilator aerosols, antimicrobials, etc, is a candidate for treatment with one of these hormones In patients with overwhelming pneumonia unresponsive to adequate antimicrobial therapy, the physician is justified in trying intravenous ACTH The response may indeed be life-saving

These hormones are indicated in diseases in which development of inflammatory reaction and subsequent fibrosis or necrosis threatens the survival of the individual The early use of the hormones in these patients will suppress the inflammatory phase of the disease Hence their early use is indicated in disseminated lupus erythematosus, periarteritis nodosa and the like

The use of these hormones is indicated in certain pulmonary diseases for which no other "specific" therapy is available, for instance, Loeffler's syndrome and selective cases of pulmonary sarcoidosis

SPECIFIC PULMONARY DISEASES TREATED WITH CORTICOTROPHIN AND CORTICOSTEROIDS

Chronic Bronchial Asthma and Status Asthmaticus

The greatest clinical experience with these hormones in pulmonary disease has been amassed in this group of patients In general the dosages, forms of application, etc., employed apply to the other diseases to be discussed

Hormonal therapy should not be used until all of the other therapeutic and physiologic measures which may be indicated have been employed, for example, continuous intravenous infusions of aminophylline, intermittent positive pressure breathing with bronchodilator aerosols, the use of therapeutic gases under pressure, bronchoscopic aspiration, antimicrobial agents, iodides and the like Finally, hormonal therapy is best employed in conjunction with the foregoing measures to secure a more effective and lasting remission with the lowest possible dosage schedule and freedom from side reactions

In the management of our patients we have employed the following preparations ACTH, lyophilized aqueous for intramuscular and intravenous use, and ACTH gel (highly purified)* for intramuscular use only, cortisone, intramuscular and oral,† and hydrocortisone, oral ‡

Treatment with Corticotrophin We have administered 281 courses of ACTH therapy (intramuscularly and intravenously) to 192 patients with intractable bronchial asthma In this group there were 123 women and sixty-nine men Their ages ranged from nine to seventy-three years, and the duration of their asthma from five months to thirty-two years

1 The original lyophilized intramuscular preparation of ACTH was administered to fifty two patients, who were given a total of eighty-two courses of therapy (one to four courses each) The average total dose required to produce remission was 605 mg The duration of treatment was two and a half to nineteen days, average ten days.

2 The highly purified ACTH gel, the slow release intramuscular preparation, was administered to twenty three patients. They were

* Supplied by The Armour Laboratories, Bankakee,
† Supplied by Merck & Co, Inc, Rahway, N J
‡ Supplied by The Upjohn Co Kalamazoo, Mich

given a total of twenty-five courses of therapy (one to two courses each) The average total dose required to produce remission was 160 mg The duration of treatment was two to seven days

TABLE I
CORTICOTROPHIN THERAPY*

Cort cotroph n	No of Pat ents	No of Courses	Aver age Dose (mg)	Days of T eat ment
Intramuscular	52	82	605	235 19
Intramuscular h ghly pur fed gel	33	25	160	3 7
Intra enous	117	174	0	1 9

* One l undr d n nety two pat ents w th chron c bronch al asthma ree ved 281 courses of therapy by various routes

3 Continuous intravenous ACTH therapy was administered to 117 patients, who were given a total of 174 courses of therapy (one to five courses each) The average total dose required to produce remission was 70 mg The duration of treatment was one to nine days, average four days (Table I)

The results were as follows The immediate therapeutic effects were considered excellent in 59 per cent, with good effects persisting for longer than four weeks, 25 per cent demonstrated good results, the therapeutic effects persisting for two to four weeks, 13 per cent showed fair results, the therapeutic effects persisting for one to two weeks, and 3 per cent were considered failures because the improvement persisted for less than one week after therapy was stopped Supportive therapeutic measures were carried out in all of these patients Aminophylline in the form of con

10 mg per L , and a total dose of 30 mg pe twenty four hours was given for one to thre days The quantitative eosinophils were usuall low or absent by the second day of this progran With improvement the ACTH was admini tered only in the first liter of fluid daily fo several more days In the most severe case the infusion of glucose and aminophylline wa continued for an additional one or more day

With intravenous therapy the immediat results were generally more striking and th therapeutic effects more adequately con tinued The total dose, and thus the cost to th patient, was one-fifth to one-eighth of tha required when ACTH was given intramuscu larly However, the physiologic hazards par ticularly disturbances in psyche and potassiun imbalance, were more pronounced with intra venous therapy

The remissive state was maintained with th use of rectal aminophylline solution or ora preparations of aminophylline (dainite an cardalin*) and bronchodilator sprays† a needed During treatment and following re mission the patients noted that they coul 'do more with considerably less' of thei therapeutic armamentarium It is thus appar ent that the remissive state was usually only partial rather than complete

Treatment with Corticosteroids A seconc group of 118 patients received corticosteroic therapy Oral cortisone was given to seventy two patients and oral hydrocortisone was given to forty six patients There were thirty nine patients with seasonal bronchial asthma due

The intravenous route is the more efficacious one for the hospitalized patient in serious status asthmaticus The use of ACTH gel may be reserved for the less seriously ill patient in the hospital or at home and for the patient with veins not suitable for intravenous technic The patient was started on a continuous infusion of 5 per cent glucose in distilled water, 30 drops per minute flow, thus ensuring approximately 3 L per twenty four hours Aminophylline, 0 25 to 0 5 gm , was added to each liter depending upon the patient's response and tolerance to aminophylline ACTH was added,

fectious, physical and depletion factors appeared to trigger their attacks The patients in this series were almost entirely confined to home and ambulatory

The following dosage schedule was employed, with occasional revisions cortisone oral 50 mg every six hours for three days, then 25 mg every six hours for four days and finally 12 5 mg every six hours for maintenance therapy Approximately one-third of the patients in this group were able to remain on maintenance therapy of 12 5 mg every eight hours, another one-third required 12 5 mg every six

* Supplied by Irwin, Neisler & Co Decatur, Ill
† Supplied by the Vaponefrin Co Upper Darby Pa.

hours, and the remaining one third required 25 mg every eight hours Those receiving hydrocortisone were placed on the following dosage schedule 20 to 40 mg (depending on how refractory their asthma had proved until then) every six hours for three days then one-half of the dosage employed for the next four days and finally 10 mg every six hours for maintenance therapy Approximately one third of this group were able to remain on 10 mg every six hours for maintenance therapy, another one-third required 20 mg every eight hours, and the remaining one-third required 20 mg every six hours A single course of therapy, as outlined for both cortisone and hydrocortisone, was continued for four to six weeks—very rarely any longer and more usually for only four weeks.

Withdrawal from the corticosteroids was carried out slowly over a period of six to nine days occasionally it was found necessary to return the maintenance dose schedule or slightly higher for several days longer before once again attempting complete withdrawal Approximately one half of the total group treated with cortisone or hydrocortisone were given ACTH gel (20 units daily for four or more consecutive days) just as the withdrawal schedule was started This was employed to stimulate adrenocortical hormone formation which might have become suppressed during corticosteroid therapy and also in view of the fact that exogenous cortisone (as well as corticotrophin) is known to inhibit the formation of corticotrophin by the anterior pituitary In fact both may be responsible for suppression of adrenocortical hormone formation in treated patients To minimize the possibility of intercurrent infection most of our patients were given maintenance doses of antimicrobial agents generally remanden ®» 100 000 units every twelve hours or one of the broad spectrum drugs (terramycin®† or tetracyn‡) 100 mg every eight hours

The results were considered satisfactory (improvement persisting for more than two weeks) in 68 per cent and unsatisfactory in 32 per cent The best results were noted in the group of seasonal asthmatics in which the results were 87 per cent satisfactory and 13 per cent unsatisfactory Of the more perennial asthmatics 58 per cent had satisfactory results and 42 per cent unsatisfactory

The better results on the whole were noted with hydrocortisone Improvement was noted more rapidly the dosage required was considerably smaller and it was generally easier to restore balance when treatment had been stopped On the other hand, more rapid evidence of hypercorticism (mooning weight gain etc) was noted with hydrocortisone

Chronic Pulmonary Emphysema

We have treated twenty two patients with chronic pulmonary emphysema and associated bronchospastic crises with corticotrophin by the intramuscular or intravenous route The use of the hormone is indicated when chronic hypoxia dyspnea with wheezing and evidence of chronic cor pulmonale are not alleviated through the intensive use of bronchodilators, aminophylline intermittent positive pressure breathing on inspiration (IPPB/I) oxygen antimicrobials venesection and so forth ¹² The presence of heart failure in these patients is not an absolute contraindication to the use of these hormones Hypoxia is the dominant mechanism which eventually leads to the development of chronic cor pulmonale and ultimately cardiopulmonary failure The relief afforded by these hormones from the bronchoconstriction resultant hypoxia and pulmonary hypertension is worth the risk of potential sodium and water retention Physiologic measures for the management of cardiopulmonary failure (namely fluid and sodium chloride restriction use of digitalis mercurials venesection etc) must be used concomitantly and vigorously their effectiveness may indeed seem improved (when the use of the hormones is added) The doses of these hormones and methods of administration were the same as discussed for bronchial asthma

The majority of the patients whose acute illness was complicated by a large element of bronchospasm were benefited by hormone therapy Remissions were of the same order as those seen in the patients with bronchial asthma There was dramatic improvement with ACTH in one patient with severe chronic pulmonary emphysema with pulmonary fibrosis who was bedridden because of secondary pulmocardiac failure After each course of therapy

* Supplied by Sharp & Dohme Inc Philadelphia Pa

† Supplied by Chas. Pfizer & Co Inc New York, N Y

‡ Supplied by J B Roerig & Co Chicago, Ill

he was able to be up and about for several weeks However, remissions were brief following two courses of therapy and death followed about six months after the first course of ACTH The temporary relief justified the means, considering the comfort attendant to the patient's relief from dyspnea

We have noted quite frequently the persistence of bronchitis and progression of emphysematous changes in patients with chronic bronchial asthma who have received multiple courses of hormone therapy The residual bronchitis responded generally to intensive maintenance antimicrobial therapy, iodides and antihistaminics It may represent a lowering of local tissue resistance by virtue of the inhibition of the inflammatory response of the mucosa to hormone therapy We generally urge antimicrobial coverage in these patients

Pulmonary Granulomatoses

Many diseases of known and unknown etiology with pulmonary involvement manifest themselves by granulomatous lesions in the lung parenchyma, i e, tuberculosis, leprosy, brucellosis, mycoses, sarcoidosis, asbestosis, silicosis, berylliosis and the like

In this group the diseases have a chronic course and are generally characterized by dyspnea on exertion and frequently at rest, a dry hacking cough, anorexia, lassitude, weakness and frequently loss of weight Cor pulmonale, cyanosis and clubbing of the fingers are frequently present, especially during the advanced stages of the disease During the acute phase of the disease fever and toxicity are usually present

In most cases granulomas eventually develop in the lung sufficiently to produce roentgenologic abnormalities These changes appear either as a fine reticular network following the course of small blood vessels and lymphatics, as scattered miliary or nodular shadows, or a combination of these These processes may be generalized or localized and need not be symmetric Hilar adenopathy is commonly seen and is generally bilateral, especially in sarcoidosis

These structural and infectious changes in the lung are responsible for the alterations in pulmonary functions Three patterns of pulmonary dysfunction have been described (1) All lung volumes are reduced but gas exchange is unchanged (2) Impairment of gas exchange across the alveolar-capillary membrane constitutes the major disturbances (3) The pattern of pulmonary emphysema, with increased residual volume and total lung capacity etc, is found Treatment with corticotrophin and corticosteroids has been attempted in some of these diseases [11–22]

A variable degree of subjective and objective improvement has been observed in the course of treatment improved ventilation, better arterial oxygen saturation, less dyspnea and cough The variability of changes is probably related to the degree of suppression of inflammation, resolution of granulomas and the extent of fibrosis resulting from these changes Changes in x-ray appearance of the granulomas after treatment, if any, were minimal Lack of correlation between radiologic appearance and pulmonary function measurements was noted in most instances As a rule there was an early relapse in most cases after cessation of treatment

We have treated five patients with pulmonary sarcoidosis [24] Pulmonary function studies and roentgenograms were obtained before and after treatment All patients showed marked pulmonary involvement, three patients had ocular involvement, one patient had uveoparotitis with secondary Bell's palsy, and three patients had minimal cutaneous involvement The patients had a low exercise tolerance and an elevated resting ventilation A slight decrease of maximal breathing capacity was present in two patients One patient had hypoxia after exercise The impairment in lung volumes was compatible with the findings of minimal pulmonary emphysema

Four patients were treated with ACTH and one with cortisone Each patient was started with 80 units of ACTH (H P) gel daily, this was gradually reduced toward the end of treatment A total of 1,500 to 2,000 units was given over a thirty-five- to forty five-day period Cortisone was given initially in a dose of 300 mg a day for three days, followed by 200 mg for five days and then 100 mg daily for the remaining thirty-four days, making a total dose of 5,300 mg Concomitantly with this treatment, 600,000 units of crysticillin* daily were given to three patients and 1 gm of terramycin daily was administered to the other two patients

A marked suppressive effect of ACTH and cortisone upon the sarcoidosis lesions in general

was observed in the five patients The most striking regressions were noted objectively in the lesions of the skin, peripheral lymph nodes, parotid glands and of the eyes There was partial clearing radiologically of the lung lesions. Subjectively, there was marked improvement in the dyspnea, cough and general well-being of all five patients Six months after treatment the patients still had remission One patient had acute bronchitis four months after treatment which cleared promptly with penicillin therapy

Pulmonary Fibrosis

Pulmonary fibrosis in its various forms—bronchial, interstitial, alveolar, vascular, pleural or a combination of these—is frequently seen in a large variety of systemic diseases such as polyarteritis nodosa, disseminated lupus erythematosus, scleroderma, erythema nodosum, hypersensitivity reactions, mitral stenosis and eosinophilic granuloma As a rule the pulmonary fibrosis will be a late manifestation of those diseases However, occasionally it may be early in its appearance or it may be the only manifestation in an accelerated form of the disease

These diseases, with the exception of mitral stenosis and eosinophilic granuloma have clinical and histopathologic findings in common and are often referred to as 'collagen diseases,' as defined by Klemperer 9

In general, the course of these diseases can be divided into two phases The first is characterized by constitutional symptoms including malaise, myalgia, arthralgia, frequently fever and at some time visceral manifestations These result from the structural and functional derangements caused by the degeneration of parenchymal cells and by the simultaneous proliferation of connective tissue in such diverse organs and tissues as skin, subcutaneous tissue, muscle, tendon and fascia, bones, blood vessels, serous surfaces, internal organs, endocrine glands and nervous system Most of these diseases have a chronic course ranging from several months to years and frequently terminate fatally Therefore, the second phase of these diseases usually consists of the advanced picture of widespread systemic involvement and its crippling sequelæ

The pulmonary functional changes that occur in pulmonary fibrosis include both ventilatory and respiratory disturbances The results of treatment with corticotrophin and corticosteroids have been variable and largely dependent on the disease being treated. It is as Either hormone will temporarily suppress inflammatory changes and will effect subjective and objective improvement However, as a general rule relapse will occur after treatment is discontinued.

We have treated three patients with generalized scleroderma and pulmonary involvement 7 Roentgenograms, skin biopsies and pulmonary function studies were obtained before and after treatment Clinical findings common to all three patients were severe exertional dyspnea, cyanosis, a dry non-productive hacking cough, weakness, anorexia, fatigue and marked loss of weight during the progress of the disease X-rays of the lungs showed an increase in linear markings and peribronchial infiltration of the parenchyma throughout both lung fields, involving primarily the lower two-thirds and with a marked increase in density at the lung roots There was no apparent involvement of the apices

The lung volume measurements revealed findings similar to those of chronic pulmonary fibrosis with compensatory emphysema The total lung capacity as well as the vital capacity were diminished in two of the three patients The ventilation studies showed some slight disturbance but none of significant degree Likewise, the maximal breathing capacity was moderately decreased in only one patient The arterial blood studies showed diffusion difficulty for oxygen, but not for carbon dioxide which is more readily diffusible and requires greater ventilatory or membrane defects in order to deviate There was no disturbance of the acid-base balance

Each patient was given a total dose of 4,600 mg of cortisone orally over a period of thirty five days While no significant modification of the objective pathology of the visceral lesions was observed after treatment, there was definite improvement in the clinical picture A marked increase in exercise tolerance and decrease in dyspnea was noted by all The hacking cough disappeared in two and improved in one A general sense of well-being and an increased appetite were probably due to the effect of cortisone No significant changes in the diffuse lesions of the lungs could be demonstrated by x-ray after treatment was terminated Interestingly enough, however, the

constrictive changes in the esophagus present in two patients prior to treatment could not be demonstrated by visualization of the esophagus after therapy In our three patients the treatment with cortisone had a favorable effect upon the skin but relapse occurred after approximately three to six months We did not observe acceleration of progress of the disease following treatment It was apparent that treatment resulted in only temporary improvement, with early relapse

Pulmonary Infiltrations with Eosinophilia

Pulmonary infiltrations with eosinophilia of known or unknown etiology associated with or without other systemic manifestations occur quite commonly The interest in this subject has increased tremendously, largely because of the therapeutic implications of the eosinopenic influences of adrenocorticotropic or corticosteroid hormones The following are the more commonly discussed entities in this group Loeffler's syndrome, tropical eosinophilia, parasitic infestations (protozoan or metazoan infestations), periarteritis nodosa and eosinophilic leukemia

It is generally assumed that the eosinophilic pneumonopathies, exclusive of eosinophilic leukemia, represent an unusual reaction of hypersensitivity involving the alveoli with or without the bronchi At times these pneumonopathies are seen in patients known to have allergic diatheses, while in others, parasitic infestations appear to be the etiologic factor, cutaneous helminth, ascaris, Trichuris trichiuria, Strongyloides stercoralis, microfilaria, Fasciola hepatica, acarina (mites), amoeba, *brucella, coccidioides and others have been* found in many of these cases [29–31]

Crofton and associates[31] postulated that hypersensitivity involving only the alveoli gives rise to either Loeffler's syndrome or "prolonged pulmonary eosinophilia" This latter syndrome is characterized by prolonged or recurrent infiltrations without asthma, the infiltrations lasting for more than one month and the course of the syndrome lasting up to six months When both the alveoli and bronchi are involved by the process of hypersensitivity, "pulmonary eosinophilia with asthma" will result Tropical eosinophilia is thought to be the result of bronchial infestations with mites Hypersensitivity involving the pulmonary vessels gives rise to polyarteritis nodosa However, few cases of polyarteritis nodosa are seen with eosinophilia and pulmonary infiltration About two-thirds of the patients with these findings have bronchial asthma, although in some these findings occur only during their final illness [31]

Loeffler's syndrome is the most common of these entities and occurs more frequently than any of the others in this country Its course is characterized by shifting pulmonary infiltrates, localized or diffuse, with or without areas of atelectases or effusions, and high blood and sputum eosinophilia The pulmonary infiltrates are generally fan-shaped and homogeneous with indefinite borders More usually its course is benign with malaise and a simple bronchitic type of episode with wheezing respirations It may even go unrecognized or respond quite simply to home care There have been recurrences However, more severe types have been noted, associated with high fever, cough, hemoptysis, dyspnea, cyanosis, pleuritic pain, pleural effusions and the like The course may simulate that of miliary tuberculosis or viral pneumonia and in fact, any disease of the lungs with miliary, granulomatous or interstitial infiltrations It must also be differentiated from Hodgkin's disease, periarteritis nodosa, eosinophilic leukemia and familial eosinophilia Its etiology has not been clearly defined but the common denominator appears to be hypersensitivity with stress situations as precipitating factors

One of us (M S S) recently was asked to see an acutely and critically ill eighteen year old college girl She had been ill for several days with a progression of symptoms, namely, *malaise, short ineffective cough,* tightness of the chest, dyspnea, chilliness and temperature of 105°F The entire past history and family history were of no significance The respirations were 80 per minute and the patient appeared

of atypical pneumonia had been made The

pleural effusions variously interpreted as suggesting miliary tuberculosis, acute beryllium pneumonitis, interstitial pneumonitis, etc On

the basis of a presumptive diagnosis of eosinophilic pneumonopathy of Loeffler's type ACTH was administered intravenously The clinical improvement was short of miraculous During the initial administration of 1,500 cc of 5 per cent glucose in distilled water containing 30 mg ACTH, the patient s temperature promptly dropped to normal and the respirations dropped to 65 per minute Recovery was progressive although protracted, over a period of seven to ten days and the cure was ultimately complete The respiratory rate remained unusually elevated but dropped slowly to normal during this period The patient was treated with intravenous ACTH during the first ten days and subsequently hydrocortisone for a period of ten days Exhaustive routine laboratory studies including cultures agglutination and skin testing for tuberculosis periarteritis nodosa, lupus erythematosus tropical and parasitic eosinophilia, coccidioidomycosis viral and influenzal disease were all negative Management of this syndrome in the past has been largely symptomatic Antihistamines, ephedrine, aminophylline and antimicrobial agents have been without definite value More recently, corticotrophin and corticosteroids have appeared quite effective Clinical improvement is usually promptly manifested and radiologic improvement at times has been compared to the use of an eraser at the blackboard/The infiltrations and effusions clear up rapidly Marks [illegible] in his cases employed cortisone in doses of 100 mg intramuscularly every four hours for one day and then every twelve hours until objective (x ray) and subjective improvement took place Duration of treatment was usually three to six days Others have noted a similar rapid resolution on using ACTH [illegible]

/The other diseases previously referred to with eosinophilia and pulmonary infiltrates should be distinguished from Loeffler s syndrome, for they require different management and, moreover, do not as a rule respond to the hormones in such a specific manner Tropical eosinophilia usually occurs in the Far East [illegible] Geographic and climatic factors are important Fever leukocytosis eosinophilia splenomegaly pulmonary infiltrates paroxysmal cough, wheezing respirations and chronic course, unless adequate treatment is instituted, are characteristic of this disease The bronchitic aspect may last for months and is followed by an asthmatic phase which may last several years and may resolve spontaneously [illegible] The radiologic picture shows diffuse localized or generalized, mottling and hilar adenopathy especially in children There is leukocytosis of over 15 000 and eosinophilia of 20 to 90 per cent The etiology is uncertain although infestation of the respiratory tract with a mite has been incriminated ACTH may produce only a moderate decrease of the eosinophilia but does not influence the clinical course or the radiologic picture [illegible] The use of an inorganic arsenical carbarsone followed by neoarsphenamine appears to be specific and may be followed by cure in a matter of days [illegible]

Changes Noted during and Subsequent to Hormone Therapy

Accumulation of several years' clinical experience and extensive laboratory studies with these hormones have resulted in recognition of the many side effects and toxic reactions as well as an appreciation of the precautions and contraindications to be observed

The undesirable effects that may follow their clinical use can generally be classified into two groups (1) those due to overdosage and (2) those due to withdrawal of the hormone [illegible] Since successful steroid therapy depends upon a state of hormone overdosage, it is unavoidable that effective hormone therapy will be associated with an exaggeration of their normal physiologic actions These abnormal metabolic reactions are seen with intensive and prolonged therapy, and manifest themselves when compensatory mechanisms of homeostasis are no longer adequate Any of the symptoms and finally the full blown picture of Cushing's syndrome may develop

Symptoms of hormone withdrawal are due to a state of adrenal insufficiency created by hormonal suppression of adrenocortical function The symptoms may be mild or severe depending upon the dosages employed duration of therapy and rate of withdrawal of the hormone This state of relative adrenal insufficiency may resemble the course of Addison s disease Any additional stress in the form of trauma shock, surgery or severe infection during this state of insufficiency may prove disastrous to the patient.

On decreasing the dose during withdrawal of the hormones aches and pains, lassitude and a wide spectrum of personality changes may

occur These symptoms usually clear up when the dose is increased, but may recur when another attempt is made to decrease the dose This situation is seen more often in women after the menopause than in other patients [42] Finally it must be realized that the disease being treated may flare up again with even greater severity and rapidity after having been suppressed with hormone therapy

TABLE II

CHANGES DURING AND SUBSEQUENT TO CORTICOTROPHIN AND CORTICOSTEROID THERAPY

Less Serious

Facial mooning acne edema hirsutism skin pigmentation
Headaches aches pains weakness lassitude
Mild euphoria to mild depression mental and physical hyperactivity
Hypertension tachycardia
Hyperglycemia glycosuria aggravation of existing diabetes
Depressed thyroid function
Thrombophlebitis
Sensitivity reactions (to intramuscular ACTH)—skin rashes, pruritus, urticaria occasionally wheezing and angioneurotic edema

More Serious

Potassium deficiency muscular weakness
Negative nitrogen balance
Osteoporosis—fractures especially in women after menopause and immobilized patients
Masked infections, spread of existing infection serious spread of non pathogenic inhabitants of the gastrointestinal and respiratory tracts
Mental confusion to severe psychotic manifestations convulsions
Exacerbation of quiescent ulcers hemorrhage and perforation in the gastrointestinal tract
Activation and spread of unsuspected or inactive tuberculosis
Sensitivity reaction—anaphylactic shock

The wide variety of changes noted during and subsequent to corticotrophin or corticosteroid therapy are listed in Table II We have been particularly concerned with the more serious events and deaths as noted in five patients in our series of 192 patients with severe, chronic bronchial asthma treated with 281 courses of corticotrophin therapy and 118 patients treated with 182 courses of corticosteroid therapy Those who died were one man and four women ranging in age from forty eight to sixty five years These patients gave histories of repeated bouts of sinusitis, bronchitis, bronchial asthma and chronic pulmonary emphysema of various degrees Three of the patients had nasal polyps All had received at least three prior courses of hormone therapy at other medical centers during the previous two years or had been on almost continuous hormone therapy These patients were believed to have in common the trigger mechanisms responsible for the intractability of their disease namely, infectious, psychic, estrogen and physical depletion factors Several of the side effects had occurred at various times in these patients while they were receiving hormone therapy

Contraindications to the Use of Corticotrophin and Corticosteroids

There are few absolute contraindications to the use of these hormones, especially if the course of treatment is of short duration and the total dose is rather small

These hormones should not be used in the presence of active or inactive tuberculosis, recent or chronic gastrointestinal ulcers active syphilis, renal insufficiency or, perhaps, severe congestive failure if the failure is not the result of pulmonary disease Psychosis is generally considered a contraindication to the use of the hormones However, Goolker and Schein[44] concluded from their studies that the psychic reaction to the hormones bore no relationship to the pretreatment personality In fact, they observed a complete discrepancy between the dosage, the pretreatment state and the psychic outcome

There are other conditions which are frequently considered as contraindications be ploy, we do not consider them absolute contraindications We must only watch the patient more closely while he is being treated The following are examples of these conditions Diabetes mellitus may or may not be temporarily aggravated by the hormones, an increase of insulin may be necessary until treatment is completed Only prolonged therapy for several months may cause or permanently aggravate diabetes The same holds true for hypertension or osteoporosis We do not hesitate to administer the hormones in the presence of congestive heart failure if this is secondary to the underlying pulmonary dis-

ease. The use of the diet low in sodium chloride mercurial diuretics and the additional use of potassium are necessary safeguards

LABORATORY PROCEDURES

If corticotrophin is to be used one must be sure of the presence of a responsive adrenal cortex The eosinophil response may be determined simply a decrease of 80 per cent or more of the eosinophils indicates excellent response Eosinophil counts are also a guide to the adequacy of dosage. We generally prefer to observe the response to intravenous administration of ACTH rather than intramuscular administration A drop of 80 per cent or more from the total (control) eosinophil count should appear by the time that 20 units of aqueous corticotrophin in 1 L of 5 per cent glucose in distilled water have been administered at a flow rate of 30 drops per minute This would tend to rule out primary adrenocortical insufficiency It would indicate adequate adrenocortical reserve for the stress that may follow surgery

Daily blood pressure readings and weight recordings are important An electrocardiogram and test of blood sugar level before and at intervals during treatment are important when therapy is to be continued for periods longer than ten to fourteen days The determination of serum potassium sodium and chlorides should be performed to evaluate possible disturbances in electrolyte balance

THERAPEUTIC PRECAUTIONS

Among the precautions to be followed are restriction of sodium chloride in the diet to 250 to 750 mg daily The occasional use of mercurial diuretics may be helpful when indicated by excessive weight gain from fluid retention Potassium may be routinely administered in the form of potassium chloride 8 to 20 gm daily with supplemental potassium in the form of orange juice, 8 to 12 ounces daily In the presence of infection or suspected infection the concomitant use of an antimicrobial is necessary the use of streptomycin is advised when treating sarcoidosis or other granulomatous lesions In general the patient should receive a high protein diet to offset the tendency for negative nitrogen balance In patients with a tendency toward gastric hyperacidity it is advisable to prescribe antacids and belladonna alkaloids during hormone therapy The use of androgens and/or estrogens is perhaps indicated when the patient receiving hormone therapy has evidence of osteoporosis As indicated before, the hormones are capable of inducing hypothyroidism When this occurs the patient may cease to respond to corticotrophin treatment until function is restored to normal by the administration of thyroid "

Although the adrenal cortex may appear normal about twenty days after a course of cortisone is stopped it is believed by some that the danger of hypocorticism and concomitant pituitary changes may continue for many months " " These patients should receive adequate supplemental doses of corticosteroids in case of surgery severe trauma or other forms of major stress " The eosinopenic response to intravenous corticotrophin described heretofore may be used to determine the need for supplemental corticosteroid therapy during and after surgical procedures

COMMENTS AND SUMMARY

The use of the corticotrophins and corticosteroids in the treatment of various pulmonary diseases followed naturally in the wake of the demonstrations of the interrelationship between hypersensitivity reactions, collagen diseases diseases of adaptation and the adrenal cortex From the immense volume of clinical laboratory and animal observations it became apparent that despite the multiplicity of effects these hormones have on the bodily functions, the hormones only modify the response of the host to infection essentially by suppressing the inflammatory and toxic reactions By so doing the hormones may enable the host to rally more effectively and recover more quickly and fully from the damaging effects of a disease The hormones will serve to support the patient until the disease has been cured (Loeffler s syndrome) or has disappeared (seasonal exacerbation of bronchial asthma) In the treatment of chronic diseases the reason for using the hormones and their beneficial effect may be likened in a sense to the administration of blood transfusions or substitutes periodically to patients suffering from various types of blood disorders The patient who is suffering from intractable bronchial asthma which is persisting or becoming more severe despite all treatment will welcome the period of relief short as it may be made possible by treatment with these hormones In addition their early

occur These symptoms usually clear up when the dose is increased, but may recur when another attempt is made to decrease the dose This situation is seen more often in women after the menopause than in other patients [42] Finally, it must be realized that the disease being treated may flare up again with even greater severity and rapidity after having been suppressed with hormone therapy

TABLE II
CHANGES DURING AND SUBSEQUENT TO CORTICOTROPHIN AND CORTICOSTEROID THERAPY

Less Serious
Facial mooning acne edema hirsutism skin pigmentation
Headaches aches, pains weakness lassitude
Mild euphoria to mild depression mental and physical hyperactivity
Hypertension tachycardia
Hyperglycemia glycosuria aggravation of existing diabetes
Depressed thyroid function
Thrombophlebitis
Sensitivity reactions (to intramuscular ACTH)—skin rashes pruritus urticaria occasionally wheezing and angioneurotic edema

More Serious
Potassium deficiency muscular weakness
Negative nitrogen balance
Osteoporosis—fractures especially in women after menopause and immobilized patients
Masked infections spread of existing infection serious spread of non pathogenic inhabitants of the gastrointestinal and respiratory tracts
Mental confusion to severe psychotic manifestations convulsions
Exacerbation of quiescent ulcers hemorrhage and perforation in the gastrointestinal tract
Activation and spread of unsuspected or inactive tuberculosis
Sensitivity reaction—anaphylactic shock

Most Serious (Fatal)
Withdrawal syndrome adrenocortical storm
Poor tolerance to trauma shock and infections

The wide variety of changes noted during and subsequent to corticotrophin or corticosteroid therapy are listed in Table II We have been particularly concerned with the more serious events and deaths as noted in five patients in our series of 192 patients with severe, chronic bronchial asthma treated with 281 courses of corticotrophin therapy and 118 patients treated with 182 courses of corticosteroid therapy Those who died were one man and four women ranging in age from forty eight to sixty five years These patients gave histories of repeated bouts of sinusitis, bronchitis, bronchial asthma and chronic pulmonary emphysema of various degrees Three of the patients had nasal polyps All had received at least three prior courses of hormone therapy at other medical centers during the previous two years or had been on almost continuous hormone therapy These patients were believed to have in common the trigger mechanisms responsible for the intractability of their disease, namely, infectious, psychic, estrogen and physical depletion factors Several of the side effects had occurred at various times in these patients while they were receiving hormone therapy

Contraindications to the Use of Corticotrophin and Corticosteroids

There are few absolute contraindications to the use of these hormones, especially if the course of treatment is of short duration and the total dose is rather small

These hormones should not be used in the presence of active or inactive tuberculosis recent or chronic gastrointestinal ulcers, active syphilis, renal insufficiency or, perhaps severe congestive failure if the failure is not the result of pulmonary disease Psychosis is generally considered a contraindication to the use of the hormones However, Goolker and Schein[43] concluded from their studies that the psychic reaction to the hormones bore no relationship to the pretreatment personality In fact, they observed a complete discrepancy between the dosage, the pretreatment state and the psychic outcome

There are other conditions which are frequently considered as contraindications be-

ploy, we do not consider them absolute contraindications We must only watch the patient more closely while he is being treated The following are examples of these conditions Diabetes mellitus may or may not be temporarily aggravated by the hormones, an increase of insulin may be necessary until treatment is completed Only prolonged therapy for several months may cause or permanently aggravate diabetes The same holds true for hypertension or osteoporosis We do not hesitate to administer the hormones in the presence of congestive heart failure if this is secondary to the underlying pulmonary dis

ease The use of the diet low in sodium chloride, mercurial diuretics and the additional use of potassium are necessary safeguards

LABORATORY PROCEDURES

If corticotrophin is to be used, one must be sure of the presence of a responsive adrenal cortex The eosinophil response may be determined simply, a decrease of 80 per cent or more of the eosinophils indicates excellent response Eosinophil counts are also a guide to the adequacy of dosage. We generally prefer to observe the response to intravenous administration of ACTH rather than intramuscular administration A drop of 80 per cent or more from the total (control) eosinophil count should appear by the time that 20 units of aqueous corticotrophin in 1 L. of 5 per cent glucose in distilled water have been administered at a flow rate of 30 drops per minute This would tend to rule out primary adrenocortical insufficiency It would indicate adequate adrenocortical reserve for the stress that may follow surgery

Daily blood pressure readings and weight recordings are important. An electrocardiogram and test of blood sugar level before and at intervals during treatment are important when therapy is to be continued for periods longer than ten to fourteen days. The determination of serum potassium, sodium and chlorides should be performed to evaluate possible disturbances in electrolyte balance

THERAPEUTIC PRECAUTIONS

Among the precautions to be followed are restriction of sodium chloride in the diet to 250 to 750 mg daily The occasional use of mercurial diuretics may be helpful when indicated by excessive weight gain from fluid retention Potassium may be routinely administered in the form of potassium chloride, 8 to

tion the concomitant use of an antimicrobial is necessary, the use of streptomycin is advised

donna alkaloids during hormone therapy The use of androgens and/or estrogens is perhaps indicated when the patient receiving hormone therapy has evidence of osteoporosis As indicated before, the hormones are capable of inducing hypothyroidism When this occurs, the patient may cease to respond to corticotrophin treatment until function is restored to normal by the administration of thyroid [44]

Although the adrenal cortex may appear normal about twenty days after a course of cortisone is stopped, it is believed by some that the danger of hypocorticism and concomitant pituitary changes may continue for many months [45, 46] These patients should receive adequate supplemental doses of corticosteroids in case of surgery, severe trauma or other forms of major stress [46] The eosinopenic response to intravenous corticotrophin described heretofore may be used to determine the need for supplemental corticosteroid therapy during and after surgical procedures

COMMENTS AND SUMMARY

The use of the corticotrophins and corticosteroids in the treatment of various pulmonary diseases followed naturally in the wake of the demonstrations of the interrelationship between hypersensitivity reactions, collagen diseases, diseases of adaptation and the adrenal cortex From the immense volume of clinical, laboratory and animal observations it became apparent that despite the multiplicity of effects these hormones have on the bodily functions the hormones only modify the response of the host to infection, essentially by suppressing the inflammatory and toxic reactions By so doing, the hormones may enable the host to rally more effectively and recover more quickly and fully from the damaging effects of a disease The hormones will serve to support the patient until the disease has been cured (Loeffler's syndrome) or has disappeared (seasonal exacerbation of bronchial asthma) In the treatment of chronic diseases the reason for using the hormones and their beneficial effect may be likened in a sense to the administration of blood transfusions or substitutes periodically to patients suffering from various types of blood disorders The patient who is suffering from intractable bronchial asthma which is persisting or becoming more severe despite all treatment will welcome the period of relief, short as it may be, made possible by treatment with these hormones In addition, their early

use in pulmonary granulomatoses or fibroses may prevent or delay the extent of ultimate involvement This may be of only theoretic value, for by the time the pathologic process is recognized it is usually too late to accomplish lasting benefit Nevertheless, most patients will derive temporary improvement in their symptoms from these hormones

Prolonged use of these hormones can produce serious metabolic and hormonal changes Cushing's syndrome, diabetes mellitus, Addison's *disease*, hypothyroidism, hypertension, osteoporosis, etc, may eventually occur We advocate short courses of hormone therapy in the treatment of pulmonary diseases as a safeguard against the occurrence of serious side effects Nevertheless, frequent courses of therapy may seriously injure the homeostasis of the hypothalamus-pituitary-adrenal axis in some patients The fatal instances which we have observed were probably related to this poorly understood mechanism

There is evidence in laboratory animals and clinically in man that the hormones, corticosteroids more consistently than corticotrophin, *depress resistance to infection or* actually may enhance the susceptibility for non-pathogens to form fatal infections, and that they suppress *or inhibit the inflammatory* response to infection allowing the spread and multiplication of pathogens [47] Therefore, the simultaneous use of an antimicrobial is advisable when treating chronic bronchial diseases These diseases tend to harbor infection in the bronchi because of damage to mucosa and parenchyma of the lung, with resultant impairment of ciliary function, bronchial peristalsis, etc

We believe the use of these hormones is contraindicated in the presence of active tuberculosis However, recent experimental work in rats, rabbits and guinea pigs indicates that the combined use of ACTH of cortisone with dihydrostreptomycin may be more effective in controlling tuberculous infections than dihydrostreptomycin alone [48] No equivalent studies in humans are available at present

The ambulatory patient is best treated with oral cortisone or hydrocortisone in divided *doses, or* with ACTH in gelatin form given in a single intramuscular dose daily The hospitalized patient may be treated with lyophilized ACTH given intravenously This route permits the smallest possible dose to accomplish the desired effects in the shortest period of time

Although corticotrophin and the corticosteroids have not fulfilled our early hopes of optimism of a "cure-all," these hormones are nonetheless additional important and powerful agents in our therapeutic armamentarium, available for restricted and considered use *when all other conventional methods of therapy* have proved ineffective in securing remission or cure of certain pulmonary diseases Unfortunately, in the management of many of the chronic pulmonary disorders the physician 'the the

Addendum Since submitting this manuscript we have employed extensively the newer cortisone analogues (meticorten, deltra® and deltrasone) and the most recent hydrocortisone analogue, hydeltra Our experience with these preparations has been very good and there appears to be reason for more hope and enthusiasm with these newer corticosteroid analogues Therapeutic and maintenance dosages *one-quarter to one-fifth those employed* with the earlier corticosteroids proved effective Side reactions have been fewer but by no means absent *It has been possible to tailor* the maintenance doses to as little as 1 mg three times a day The striking antiphlogistic effects of hydeltra were noted particularly *in* patients with intractable bronchial asthma, chronic obstructive pulmonary emphysema and idiopathic pulmonary fibrosis

REFERENCES

1 DARROW, D C and MILLER, H C The production of cardiac lesions by repeated injections of desoxycorticosterone acetate *J Clin Investigation*, 21 601, 1942

2 SELYE, H and PENTZ, E I Pathogenetical correlations between periarteritis nodosa, renal hypertension and rheumatic lesions *Canad M A J*, 49 264 1943

3 SELYE H Production of hypertension and hyalinosis by desoxycortisone *Brit M J*, 1 203 1950

4 SELYE H The general adaptation syndrome and the diseases of adaptation *Am J Med* 10 549

5

225 433, 1941

6 RICH, A H and GREGORY, J E. The experimental demonstration that periarteritis nodosa is a

manifestation of hypersensitivity Bull Johns Hopkins Hosp 72 65, 1943
7 RICH, A R and GREGORY, J E Experimental evidence that lesions with the basic characteristics of rheumatic carditis can result from anaphylactic hypersensitivity Bull Johns Hopkins Hosp, 73 239 1943
8. BERGSTRAND, H Morphological equivalents in polyarthritic rheumatica, periarteritis nodosa transient eosinophilic infiltration of the lung and other allergic syndromes. J Path & Bact 58 399, 1946
9 MORE, R H and MCLEAN C R Lesions of hypersensitivity induced in rabbits by massive injections of horse serum Am J Path 25 413 1949
10 SELYE, H Stress Montreal 1950 Acta Inc
11 SUTLIFF, W D and NORMAN S I Adrenocorticotrophic Hormone in Cutaneous and Systemic North American Blastomycosis Proceedings of the Second Clinical ACTH Conference Vol 2 p 381 Edited by Mote J R Philadelphia 1951 Blakiston & Co
12 KENNEDY, B J PARE A P PEMP A K BECK J C and BROWNE, J S L. Response of Beryllium Granulomatosis and Silicosis to ACTH Proceeding of the Second Clinical ACTH Conference Vol 2, p 449 Edited by Mote J R Philadelphia, 1951 Blakiston Company
13 KENNEDY, B J, PARE A P PEMP A K BECK J C, JOHNSON, L G LISTER N B FRANKLIN E H and BROWNE, J S L Effect of adrenocorticotropic hormone (ACTH) on beryllium granulomatosis and silicosis Am J Med 1 134, 1951
WEST, J R, MCCLEMENT J H CARROLL D BLISS, H A, KUSCHNER M RICHARDS D W JR and COURNAND A Effects of cortisone and ACTH in cases of chronic pulmonary disease with impairment of alveolarcapillary diffusion Am J Med, 10 156 1951
GALDSTON, M, WEISENFELD S BENJAMIN B and ROSENBLUTH, M B Effect of ACTH in chronic lung disease Am J Med 10 166 1951
5 SONES, M, ISRAEL, H L DRATMAN M B and FRANK, J H Effect of cortisone in sarcoidosis New England J Med, 244 209 1951
17 DE NARDI J M Symposium on the treatment of chronic beryllium poisoning with ACTH and cortisone Chronic pulmonary interstitial granulomatosis Arch Indust Hyg 3 543 1951
18 HARDY, H L, BARTTER, F C and JALLIN A L Metabolic study of a case of chronic beryllium poisoning treated with ACTH Arch Indust Hyg, 3 579, 1951
19 SILTBACH L E Effects of cortisone in sarcoidosis Am J Med, 12 139 1952
20 MCCLEMENT, J H RENZETTI A D HIMMELSTEIN, A and COURNAND, A Cardiopulmonary function in the pulmonary form of Boeck's sarcoid and its modification by cortisone therapy Am Rev Tuberc 67 154, 1953
21 STONE, D J, SCHWARTZ, A, FELTMAN J A and LOVELOCK, F J Pulmonary function in sarcoidosis Results with cortisone therapy Am J Med, 15 468, 1953
22 LOVELOCK, F J and STONE, D J The therapy of sarcoidosis Am J Med 15 477, 1953
23 HARDY H L Occupational medicine New England J Med, 247 373, 1952
24 SALOMON A, APPEL, B, COLLINS, S F, HERSCHFELD J A and SEGAL, M S Sarcoidosis pulmonary and skin studies before and after ACTH and cortisone therapy (Unpublished data)
25 KLEMPERER, P Editorial Collagen diseases Am J Med 10 405 1951
26 ENGEL, F L and RAGAN C Proceedings of the Second Clinical ACTH Conference, vol 2 p 456 Edited by Mote, J R Philadelphia 1951 Blakiston Co
27 SALOMON A APPEL B DOUGHERTY, E F, HERSCHFELD J A and SEGAL, M S Scleroderma pulmonary and skin studies before and after treatment with cortisone Arch Int Med 95 103 1955
28 HAM J C and ZINDAHL, W T Loeffler's syndrome and pulmonary infiltrations accompanied by peripheral eosinophilia Ann Int Med 29 488 1948
21 CARTWRIGHT G T An unusual case of elonorchia with marked eosinophilia and pulmonary infiltrations Am J Med 6 259 1949
30 SHEEHAN A Pulmonary infiltration with blood eosinophilia Am J Med 10 269 1951
31 CROFTON J W LIVINGSTONE J L OSWALD N C and ROBERTS A T M Pulmonary eosinophilia Thorax 7 1 1952
32 MARKS I Loeffler's syndrome with a report of twenty three cases Dis of Chest 25 128 1954
33 HERBERT P and ROSE B Observations on the effect of adrenocorticotrophic hormone on a case of Loeffler's syndrome and a case of eosinophilia J Allergy 20 79 1949
34 HERBERT P DE VRIES J A and ROSE B Studies on the effect of ACTH on a case of Loeffler's syndrome and a case of tropical eosinophilia J Allergy 21 12 1950
35 ROSE B Studies on the Effect of ACTH on Eosinophilia and Bronchial Asthma Proceedings of the First Clinical ACTH Conference p 491 Edited by Mote J R Philadelphia, 1950 Blakiston Company
36 REEDER W H and GOODRICH B E Pulmonary infiltration with eosinophilia (PIE syndrome) Ann Int Med 36 1217, 1952
37 WEINGARTEN R J Tropical eosinophilia Lancet, 1 103 1943
38 PARSONS SMITH B J Tropical eosinophilia Lancet 1 433 1944
39 EMERSON K Tropical eosinophilia U S Nav M Bull 42 118, 1944
40 CARTER, H F WEDD G and D ABRERA V Occurrence of mites (acarina) in human sputum and their possible significance Indian M Gaz, 79 163 1944 Cited by Reeder and Goodrich "
41 THORN G W, JENKINS, D, LAIDLAW, J C, GOETZ F C DINGMAN, J F ARONS W L, STREETEN, D H P and MCCRACKEN, B H Pharmacologic aspects of adrenocortical steroids and ACTH in man New England J Med, 248 588, 1953

42 SLOCUMB, C. H Rheumatic complaints during chronic hypercortisonism and syndromes during withdrawal of cortisone in rheumatic patients *Proc Staff Meet, Mayo Clin*, 28 655 1953

43 GOOLKER P and SCHEIN J Psychic effects of ACTH and cortisone *Psychosom Med*, 15 589, 1953

44 WOLFSON, W Q, BEIERWALTES, W H, ROBINSON, W D DUFF, I F, JONES J R, KNORPP, C T, SIEMIENSKI, J S and EYA, M Corticogenic Hypothyroidism Its Incidence Clinical Significance and Management during Prolonged Treatment with ACTH or Cortisone Proceedings of the Second Clinical ACTH Conference, vol 2, p 95 Edited by Mote, J R Philadelphia, 1951 Blakiston Company

45 BENNETT W A Histopathologic changes in the adrenal and anterior pituitary in patients treated with cortisone preliminary impressions *Proc Staff Meet Mayo Clin* 28 658 1953

46 SALASSA R M, KEATING, F R JR and SPRAGUE R G Clinical aspects of supression of adrenal cortical function after use of cortisone *Proc Staff Meet, Mayo Clin*, 28 662, 1953

47 KASS, E H and FINLAND, M Adrenocortical hormones in infection and immunity *Ann Rev*

48 [illegible]

corticotropin-dihydrostreptomycin on bovine tuberculosis in the rabbit *Am Rev Tuberc*, 67 201, 1953

49 SEGAL, M S and HERSCHFUS, J A Management of the patient in status asthmaticus *Postgrad Med*, 9 435 1951

50 SEGAL, M S and HERSCHFUS, J A and LEVINSON L ACTH and chronic bronchial asthma *GP* 3 33–39, 1951

51 SEGAL, M S and HERSCHFUS J A Intravenous ACTH therapy in the treatment of bronchial asthma *Dis of Chest*, 6 575 1951

52 SEGAL M S and DULFANO M J Chronic Pulmonary Emphysema Physiopathology and Treatment New York, 1953 Grune & Stratton Inc

Anesthetic Management of Patients with Altered Pulmonary Function

JOSEPH G. GILFERIDA, M.D. AND DANTE BIZZARRI, M.D., *Brooklyn, New York*

From the Departments of Anesthesia, Columbus Hospital and New York City Hospital, New York, New York

DERANGEMENTS of the respiratory system are of great concern to the anesthesiologist because they influence the choice of anesthetic agent and technic, the conduct of anesthesia and the postoperative course of the patient.

The principal objective of this chapter is to discuss the problems presented to the anesthetist by patients with diseases affecting pulmonary function. Attention will be directed mainly to the more commonly encountered bronchopulmonary diseases and to lesions causing respiratory obstruction. Conditions which alter intrapleural dynamics, neuromuscular diseases, "the full stomach" and obesity are also included. In addition, criteria of good pre- and postoperative care and of correct anesthetic management are considered.

RESPIRATORY OBSTRUCTION

Patients in whom the patency of the nasopharynx, larynx or trachea has been seriously decreased by neoplasm, inflammation (e.g., Ludwig's angina, parapharyngeal abscess) or by neurogenic disturbances (e.g., abductor paralysis of the vocal cords) constitute a group for which an adequate airway must be guaranteed by either endotracheal intubation or by tracheostomy prior to the induction of general anesthesia. Which of the two methods is to be used can be determined preoperatively by visualization of the affected area and by an evaluation of the efficiency of the airway. If a good airway is not established before general anesthesia is begun, complete respiratory obstruction may develop early in induction as voluntary respiratory efforts are weakened by the loss of consciousness. At this level of anesthesia, nasopharyngeal and oropharyngeal airways or the endotracheal tube are not tolerated. Obviously anesthesia cannot be deepened by inhalation technic. Attempts to establish, via the intravenous route, conditions suitable for endotracheal intubation usually complicate matters. Barbiturates or muscle relaxants have to be given in doses large enough to produce profound hypotension and serious respiratory depression in many cases. If, despite these measures, endotracheal intubation cannot be performed, emergency tracheostomy becomes mandatory. This may not be completed in time to avoid a fatality. Although life may be saved, complications such as pneumothorax, pneumomediastinum, mediastinitis and subcutaneous emphysema frequently result because of the haste with which the tracheostomy is performed. It is evident, therefore, that failure to insure an adequate airway prior to the induction of general anesthesia in these patients is to court disaster.

In the preoperative examination one must look for evidence of poor oral hygiene, dehydration, thick inspissated secretions, dyspnea and/or depressed pharyngolaryngeal reflexes. Whenever possible these conditions should be corrected so as to facilitate the conduct of anesthesia and reduce the incidence of postoperative complications.

Measures instituted in the immediate postanesthetic period to maintain a clear airway and adequate ventilation will diminish the incidence of complications. The oropharynx and tracheobronchial tree must be freed of secretions. The patient should be kept in the operating room until reflex activity has returned and until one is certain that respirations remain unobstructed. If this is not possible, it is wise to return the patient to his room with an endotracheal tube in place.

DISEASES OF THE BRONCHOPULMONARY SYSTEM

Although the bronchopulmonary system may be affected by numerous diseases, those of greatest interest to the anesthetist are emphysema, fibrosis, chronic bronchitis (smoker's cough), bronchial asthma and those associated

with considerable intrabronchial suppuration The effect of these diseases on pulmonary function depends upon the amount of bronchoconstriction, fibrosis, emphysema and intrabronchial secretions present

Bronchoconstriction produces mechanical interference to the ingress and egress of air It is most clearly observed in allergic bronchial asthma when spasm and edema of the smaller bronchi occur in paroxysms Patients with fibrosis and emphysema have decreased vital capacity, increased residual air, impaired mixing of gases within the air sacs and reduced diffusion across the alveolocapillary membrane These disturbances result in hypoxia, hypercapnia and a depressed respiratory center Compensatory polycythemia is a frequent concomitant finding Long standing cases may show evidence of cor pulmonale

Increased secretions hyperirritability of the tracheobronchial tree, cough and varying degrees of dyspnea are common findings in chronic pulmonary diseases Because in allergic bronchial asthma and in chronic pulmonary emphysema there is difficulty in expelling air from the lungs, expiration is forcible and prolonged When considerable intrabronchial suppuration exists, the patient is endangered by *the threat of drowning and contamination of* healthy lung tissue, this hazard is greatest during general anesthesia

Preoperatively, patients with bronchopulmonary diseases warrant specific therapy since the physiologic changes may be reversed to some extent Treatment should be directed *toward the control of infection, elimination of* secretions and relief of bronchoconstriction, *hypoxia and hypercapnia Specific cardiac therapy* is to be employed when indicated

Preanesthetic sedatives are best prescribed in smaller doses than usual They should, perhaps, be omitted for patients with marked pulmonary insufficiency Opiates increase the adhesiveness and cohesiveness of exudates suppress cough, depress respiration and favor bronchoconstriction Demerol® is preferable because it produces these undesirable effects to a lesser extent Only minimal doses of belladonna drugs should be given to patients with thick secretions so that these will not be further inspissated

For patients with bronchopulmonary diseases, regional anesthesia, which includes subarachnoid block, is the method of choice because it does not disturb the airway, does not increase the irritability of the tracheobronchial tree, does not obtund the protective reflexes of the respiratory tract and least alters general body physiology In addition it allows the early application of the stir up regimen so important in the prevention of postoperative pulmonary complications

Spinal anesthesia is of greatest value in surgery of the lower extremities, perineum and lower abdomen For upper abdominal surgery its advantages over inhalation anesthesia are questionable, since when it is used for these cases it often produces motor paralysis of the lower six intercostal muscles Although the resultant impaired ventilation may be of no great significance in patients with normal pulmonary function, it may predispose to serious consequences in the patients under discussion Furthermore, since spinal anesthesia usually does not prevent the discomfort to the patient caused by traction reflexes, complementary general anesthesia of one form or another is usually necessary The combination of paralysis pernicious to respiration and circulation

In discussing general anesthesia it can be *stated that even under the most favorable circumstances* it deranges respiration and alters body physiology First, the apparatus in common use increase the dead air space and the resistance to respiration Also, they favor respiratory acidosis and may interfere with heat dissipation Second, most general anesthetic agents irritate *the respiratory tract,* promote cough and in deeper stages of anesthesia depress *the respiratory center and protective* tracheobronchial reflexes

Cyclopropane and pentothal® are undesirable for patients with bronchial asthma and emphysema because they have a tendency to initiate paroxysms of cough produce laryngospasm and/or bronchospasm and to depress respirations Although nitrous oxide and ethylene are innocuous when combined with safe concentrations of oxygen they are relatively impotent when used in this manner *However,* they can be utilized within safe limits as supplemental agents to other anesthetic drugs Although ether irritates the respiratory mucosa and stimulates the flow of secretions, it is preferred as a maintenance agent because it is potent, dilates the bronchi and stimulates respiration

When basal hypnosis is indicated avertin® is preferred to barbiturates since it does not predispose to bronchospasm

Muscle relaxant drugs should be administered with caution because of their depressant effect upon respiration When given the anesthetist must be prepared for endotracheal intubation and positive pressure respiration Synthetic muscle relaxants are preferred to curare for patients with bronchial asthma fibrosis and chronic pulmonary emphysema inasmuch as curare may produce diffuse bronchospasm

To attain a smooth anesthetic course it is essential that certain basic principles be observed The airway must be kept patent and free of secretions It is important that the technic used offers minimal resistance to respiration and that it does not increase the dead air space considerably Lastly optimal oxygen and carbon dioxide concentrations must be maintained by sufficient flows of oxygen, efficient carbon dioxide elimination mechanisms and by an adequate effective minute volume

Although the value of the endotracheal tube in maintaining an efficient airway is well recognized, its usefulness in patients with bronchopulmonary diseases may be mitigated by certain untoward reactions These patients have hyperirritable tracheobronchial reflexes so that the introduction of an endotracheal tube may set off a persistent spasm of the entire bronchial tree This drastically reduces oxygenation which may be extremely dangerous for the already hypoxic patient Topical anesthesia prior to intubation cannot be relied upon to prevent this reaction in all cases In the presence of persistent bronchospasm the anesthetist faces two alternatives He must either withdraw the offending tube or produce apnea by the administration of muscle relaxants and employ controlled respiration At this point it should be emphasized that a paroxysm of asthma is not an indication for endotracheal intubation but demands bronchodilating and antihistamine drug therapy

Patients with allergic bronchial asthma or with chronic pulmonary emphysema exhibit a phenomenon which we have termed the expiratory squeeze This occurs at the end of a prolonged forcible expiration and constitutes a final effort of the expiratory muscles to expel air from the lungs The expiratory squeeze begins during induction and continues throughout the course of anesthesia Since the abdominal muscles play a major part in this effort relaxation becomes difficult to attain The anesthetist, plagued by this difficulty may overdose the patient with anesthetic agents or muscle relaxants or a combination of the two Surgeons who are cognizant of these difficulties will adapt themselves to an unfavorable operative field rather than compel the anesthetist into unsafe practices

Postoperative pulmonary complications occur frequently in the patients under discussion and may contribute to hypoxia carbon dioxide retention disturbances of cardiovascular function abdominal distention and wound dehiscence The incidence of these complications can be reduced to a minimum by returning the patient to as near a normal physiologic state as possible in the immediate postanesthetic period It is important that the conduct of anesthesia be directed toward the early return of reflex activity In addition it is essential that the respiratory tract be cleared of secretions By direct observation we have come to realize that catheter suction through the endotracheal tube during extubation often fails to remove all oropharyngeal secretions The remaining secretions may be aspirated during the first forceful inspiratory effort made by the patient following withdrawal of the endotracheal tube To avoid this the double suction technic recommended by Naclerio is of value This involves aspiration of secretions from the oropharynx under direct vision by an assistant while the anesthetist uses catheter suction through the endotracheal tube (Fig 1) This method is essential for patients in poor general condition especially those with limited pulmonary reserve because in these cases any further reduction in ventilatory capacity may be fatal

The benefits of the early institution of the stir up regimen in preventing atelectasis are clearly appreciated in this group of patients Detergents and hydration may be necessary to thin sticky inspissated secretions If the patient cannot expectorate effectively one may have to introduce a catheter into the trachea to stimulate cough apply the exsufflator or resort to bronchoscopy Should these measures fail tracheostomy may be necessary

The restlessness of the hypoxic patient is frequently misinterpreted as a manifestation

1A

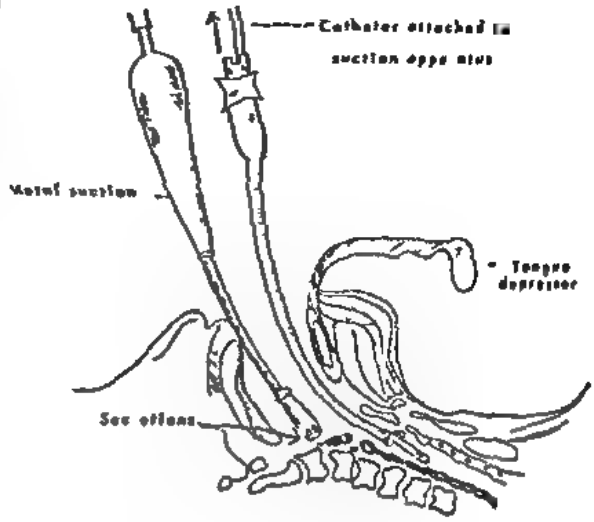

1B

and metal suction tip in oropharynx

of postoperative pain Attempts to control it by sedation may lead to further hypoxia and depression of the cough reflex, respiration and circulation The correct treatment necessitates the administration of oxygen through a clear airway In the emphysematous patient oxygen therapy must be governed by the known fact that these patients do not tolerate high oxygen concentrations Some emphysematous patients require intermittent positive pressure breathing

Finally, it must be borne in mind that a rising blood pressure and a bounding slow pulse may be warning signs of hypoxia and hypercapnia

CONDITIONS WHICH ALTER INTRAPLEURAL DYNAMICS

Whenever the intrapleural space is invaded by tumors, gases (pneumothorax) or fluids (hydro-, hemo- or pyothorax), the negative intrapleural pressure is reduced This produces varying degrees of atelectasis Lung expansion may also be diminished by conditions which impede movement of the thoracic cage or of the diaphragm, such as thoracoplasty, chest wall trauma and intra abdominal distention

The condition of the patient depends upon the degree of pulmonary collapse and is most grave when there has been pre-existing low vital capacity The major symptom of these patients is dyspnea, some also show evidence of circulatory embarrassment

Before anesthesia is administered the surgeon should attempt to increase the respiratory capacity of the patient Depending upon the cause of the atelectasis, he may accomplish this by aspiration of the pleural or peritoneal cavities, by decompression of the gastrointestinal tract or by sealing off an open pneumothorax

Patients with reduced vital capacity should receive only minimal doses of sedatives since they tolerate oversedation poorly

In handling these hypoxic patients the anesthetist must direct his efforts toward oxy-

[illegible]

or assisted and tracheobronchial secretions can be aspirated Although both ether and cyclopropane are well tolerated, the latter is preferred for the patient in shock

These patients require meticulous postoperative care to avoid further *atelectasis* In addition, tracheostomy may be indicated in the presence of paradoxic motion of the chest, persistently poor ventilation and copious secretions

Anesthetic Management of Patients

Neuromuscular Disturbances

Bilateral abductor paralysis of the vocal cords causes serious respiratory obstruction It may result from direct or indirect trauma to the laryngeal motor nerves or from intracranial or peripheral nerve lesions Patients with this condition must be assured an adequate airway either by endotracheal intubation or by tracheostomy before general anesthesia is begun

Bilateral adductor paralysis of the vocal cords is found most frequently in conjunction with cerebral lesions Sensory paralysis of the larynx often exists unrecognized in bulbar lesions of tabes, in myasthenia gravis and in syringomyelia In both instances the anesthetist is faced with the problem of preventing aspiration This is best accomplished by the use of a cuffed endotracheal tube inserted before induction of general anesthesia

Myasthenia gravis and anterior poliomyelitis may affect the muscles of respiration Myasthenia gravis will be discussed because it has an underlying biochemical disturbance which contraindicates the administration of some of the drugs commonly used in the practice of anesthesia This disease is believed to result from excessive destruction of acetylcholine by cholinesterase at the myoneural junction Patients with myasthenia gravis have extreme fatiguability of muscles which leads to depressed respiration, difficulties in deglutition decreased pharyngolaryngeal reflexes and impairment of the cough mechanism These factors predispose to aspiration and asphyxia

The main concerns of the anesthetist are to maintain adequate ventilation prevent aspiration and to choose drugs which will not aggravate the biochemical disturbance

The preparation of the patient for surgery must include a period of rest control of infection and therapeutic doses of prostigmin This drug may have to be repeated during surgery It is important that atropine be combined with it so as to counteract its stimulatory effect on smooth muscles and mucous glands Care must be exercised in prescribing any preoperative sedation

As a rule anesthesia is poorly tolerated by the myasthenic patient Since spinal anesthesia intensifies the existing muscular weakness and since it does not provide favorable conditions for assisted or controlled respirations and for tracheobronchial toilet it is contraindicated Inhalation anesthesia administered through an endotracheal tube allows the anesthetist to have constant control of respiration and is, therefore, the method of choice Inasmuch as muscle relaxants aggravate the physiologic dysfunction already present they are interdicted Since ether has a curare-like action it is to be avoided whenever possible Pentothal because of its depressant effect on respiration and circulation should be used with great caution Cyclopropane is the agent of choice It is potent does not aggravate the existing disturbance at the myoneural junction and allows the use of adequate concentration of oxygen

Patients with myasthenia gravis are prone to have serious respiratory difficulties post operatively It is important, therefore, that close attention be given to their airway and tidal exchange Tracheostomy is indicated if the patient has marked difficulty in maintaining an unobstructed airway

The Full Stomach

Patients may come to surgery with a full stomach because of the recent ingestion of food or fluid or as the result of gastrointestinal obstruction These patients are ever threatened by the danger of asphyxia consequent to a sudden inundation of the respiratory tract with gastrointestinal contents Therefore, they constitute a grave anesthetic risk

Regional anesthesia affords the greatest safety to these patients They retain control of their airway and most times are able to protect themselves against aspiration When spinal anesthesia is used the continuous technic is preferred to the single dose method since it reduces the uncertainty of dosage permits better control of the level of anesthesia and diminishes the need for supplemental general anesthesia

The proper management of general anesthesia depends upon the early establishment of an effective barrier between the alimentary and respiratory tracts This must be carried out even in the presence of a Miller Abbott or Levin tube since experience has shown that in many instances neither adequately empties the gastrointestinal tract of its contents The barrier should be established before the start of general anesthesia for aspiration may occur during induction This is usually attempted by the insertion of a cuffed endotracheal catheter

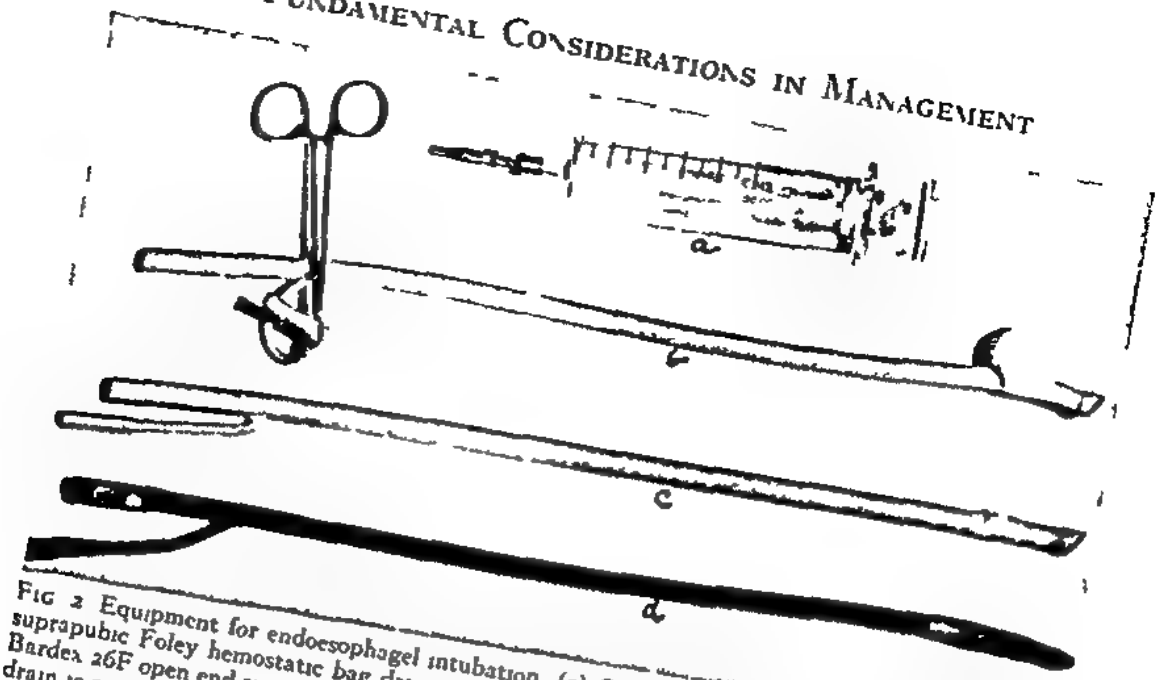

FIG 2 Equipment for endoesophagel intubation (a) Syringe for inflating balloon (b and c) 32F suprapubic Foley hemostatic bag drains Pilot tube to the inflated balloon has been clamped (d) Bardex 26F open end suprapubic cystostomy tube This tube may be used if Foley hemostatic bag drain is not available

FIG 3 Photograph of conscious patient with endoesophageal tube in situ Balloon of tube is being inflated with about 30 cc of air Proximal end of tube protrudes from oral cavity Passage of the endoesophageal tube causes no greater discomfort to the patient than does the insertion of a Levin tube

following topical anesthetization of the larynx and trachea However, a simpler and most effective method, which has been used by the authors for the past ten years, is the intubation of the esophagus with a cuffed tube * (Fig 2) With minimum discomfort to the patient the tube can be passed easily through the mouth into the esophagus without the use of anesthesia It is inserted for a distance of about 30 cm so that the cuff lies beyond the bifurcation of the trachea The proximal end of the tube is left protruding from the oral cavity so that ejected stomach contents will be expelled to the exterior The cuff is inflated with air to the point of resistance so as to insure that any regurgitation of stomach contents will take place only through the tube (Fig 3)

Following endotracheal or endoesophageal intubation, the anesthetist induces the patient into general anesthesia The airway of the patient who has an esophageal tube is to be maintained patent—our practice is to use endotracheal intubation

The following objections have been levelled against our method of esophageal intubation Intolerance of the conscious patient to the procedure, compression of the trachea causing respiratory embarrassment, ulceration of the esophageal mucosa due to pressure and cardiac irregularities Clinically, the authors have not observed any such untoward effects Studies including bronchoscopy, esophagoscopy and

* The tube found by us to be most suitable for this purpose is a 32F suprapubic Foley hemostatic bag drain because of its length, caliber and the capacity of its bag

4A 4B

FIG 4 A x ray of patient w th tube in esophagus and bronchoscope n trachea Balloon of tube filled w th 30 cc

radiography have substantiated this clinical experience (Fig 4) Therefore, esophageal intubation with a cuffed tube is a safe simple and effective procedure which should be used whenever the ind cation arises for it may be life saving

OBESITY

A discussion of this condition is included because many obese patients manifest some degree of respiratory embarrassment and be cause their respirations are frequently char acterized by a prolonged and forcible expiratory phase which renders difficult adequate ab dominal relaxation during general anesthesia

Because these patients often obstruct early during the induction of general anesthes a they times initiates vomiting and laryngospasm Attempts at endotracheal intubation at this stage are often traumatic because of poor relaxation active pharyngeal and laryngeal reflexes and because the habitus of the patient makes visualization of the larynx most difficult Therefore the best way to insure the patency of the airway of the obese patient who is to receive general anesthesia is to intubate him while he is conscious

The difficulties encountered in maintaining the patency of the airway and in producing good abdominal relaxation render general anesthesia a poor choice for these patients Therefore whenever poss ble regional anes thesia should be selected

Since pulmonary complications are prone to develop these patients must be given the same care postoperatively as described for those with bronchopulmonary diseases

SUMMARY

The authors have discussed certain clinical entities that affect pulmonary function and have shown how the knowledge of the dis turbances involved aids in the selection of the correct anesthetic agent and techn c We have stressed the importance of pre nduction endo tracheal intubation and tracheostomy as a means to obviate serious respiratory obstruc tion We have presented a method of preventing aspiration by the use of the endoesophageal tube Finally we have emphas zed the impor tance of meticulous care of the patient dur ing the immediate postanesthetic period in the prevention of postoperative pulmonary complications

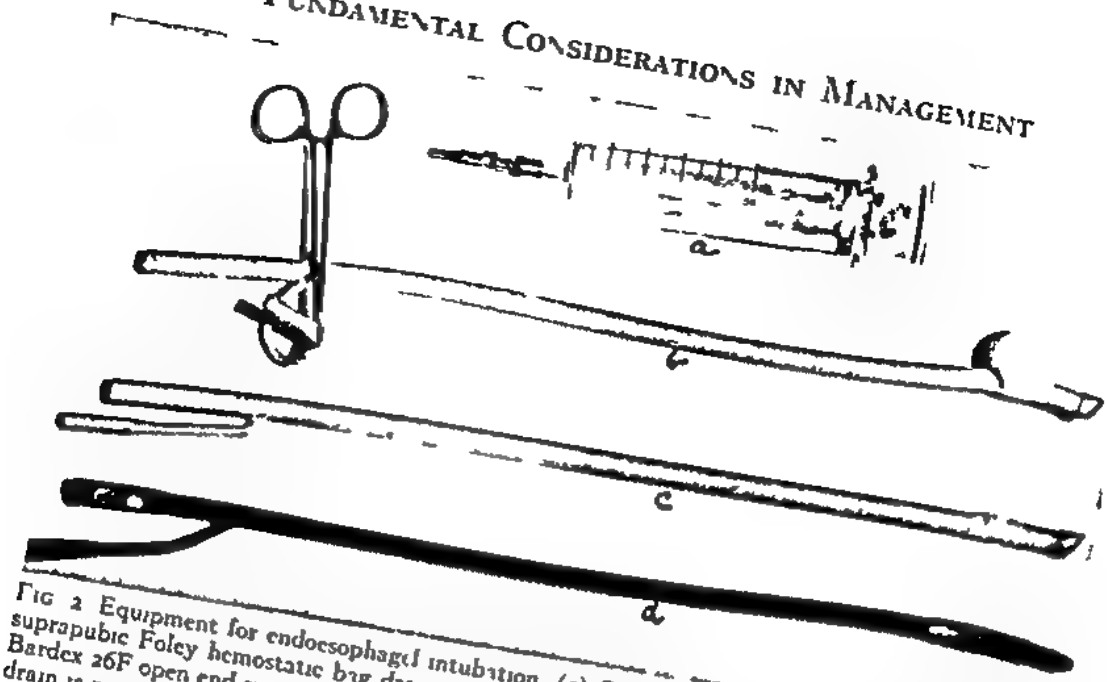

FIG 2 Equipment for endoesophageal intubation (a) Syringe for inflating balloon (b and c) 32F suprapubic Foley hemostatic bag drains Pilot tube to the inflated balloon has been clamped (d) Bardex 26F open end suprapubic cystostomy tube This tube may be used if Foley hemostatic bag drain is not available



FIG 3 Photograph of conscious patient with endoesophageal tube *in situ* Balloon of tube is being inflated with about 30 cm of air Proximal end of tube protrudes from oral cavity Passage of the endoesophageal tube causes no greater discomfort to the patient than does the insertion of a Levin tube

following topical anesthetization of the larynx and trachea However, a simpler and most effective method, which has been used by the authors for the past ten years, is the intubation of the esophagus with a cuffed tube * (Fig 2) With minimum discomfort to the patient the tube can be passed easily through the mouth into the esophagus without the use of anesthesia It is inserted for a distance of about 30 cm so that the cuff lies beyond the bifurcation of the trachea The proximal end of the tube is left protruding from the oral cavity so that ejected stomach contents will be expelled to the exterior The cuff is inflated with air to the point of resistance so as to insure that any regurgitation of stomach contents will take place only through the tube (Fig 3)

Following endotracheal or endoesophageal intubation the anesthetist induces the patient into general anesthesia The airway of the patient who has an esophageal tube is to be maintained patent—our practice is to use endotracheal intubation

The following objections have been levelled against our method of esophageal intubation Intolerance of the conscious patient to the procedure compression of the trachea causing respiratory embarrassment, ulceration of the esophageal mucosa due to pressure and cardiac irregularities Clinically, the authors have not observed any such untoward effects Studies including bronchoscopy, esophagoscopy and

* The tube found by us to be most suitable for this purpose is a 32F suprapubic Foley hemostatic bag drain because of its length caliber and the capacity of its bag

4A 4B

FIG 4 A, x ray of patient with tube in esophagus and bronchoscope in trachea Balloon of tube filled with 30 cc of barium Bronchoscopic observations made on a number of patients has not revealed compression of any part of the tracheobronchial tree by the inflated balloon B, x ray of patient with tube in esophagus Balloon filled with 60 cc of barium. In practice balloon is usually distended to 30 cc This x ray demonstrates that distention of balloon to 60 cc does not cause tracheal compression

radiography have substantiated this clinical experience (Fig 4) Therefore, esophageal intubation with a cuffed tube is a safe, simple and effective procedure which should be used whenever the indication arises for it may be life saving

OBESITY

A discussion of this condition is included because many obese patients manifest some degree of respiratory embarrassment, and because their respirations are frequently characterized by a prolonged and forcible expiratory phase which renders difficult adequate abdominal relaxation during general anesthesia

Because these patients often obstruct early times initiates vomiting and laryngospasm Attempts at endotracheal intubation at this stage are often traumatic because of poor relaxation, active pharyngeal and laryngeal reflexes, and because the habitus of the patient makes visualization of the larynx most difficult Therefore, the best way to insure the patency of the airway of the obese patient who is to receive general anesthesia is to intubate him while he is conscious

The difficulties encountered in maintaining the patency of the airway and in producing good abdominal relaxation render general anesthesia a poor choice for these patients Therefore, whenever possible, regional anesthesia should be selected

Since pulmonary complications are prone to develop, these patients must be given the same care postoperatively as described for those with *bronchopulmonary diseases*

SUMMARY

The authors have discussed certain clinical entities that affect pulmonary function and have shown how the knowledge of the disturbances involved aids in the selection of the correct anesthetic agent and technic We have stressed the importance of preinduction endotracheal intubation and tracheostomy as a means to obviate serious respiratory obstruction We have presented a method of preventing aspiration by the use of the endoesophageal tube Finally, we have emphasized the importance of meticulous care of the patient during the immediate postanesthetic period in the prevention of postoperative pulmonary complications

Tracheotomy*

MARK H WILLIAMS, M D, Binghamton, New York

From the Surgical Departments of Binghamton City Hospital Binghamton New York Ideal Hospital Endicott New York and C S Wilson Memorial Hospital Johnson City New York

FOLLOWING serious thoracic injury or extensive thoracotomy recovery of the patient frequently depends largely upon meticulous attention to keeping the tracheobronchial tree clear of blood and secretions To accomplish this objective special nursing technics are utilized which assist the patient in raising In addition intratracheal catheter suction is frequently required and bronchoscopic aspiration may occasionally be necessary In certain situations all of these measures are inadequate or ineffectual and a direct surgical approach to the problem by tracheotomy is required [illegible] Recently the increased utilization of this simple procedure has gained wide acceptance and ascendency and many fatalities have been prevented which formerly would have been attributed to 'traumatic' or 'postoperative' pneumonia 'heart failure and lung congestion or traumatic wet lung'

It is the intent of this section to attempt to set in proper perspective the role of tracheotomy in thoracic surgery Several categories of patients in whom the procedure has been utilized will be considered, with emphasis on its application in those having multiple rib fractures Technical aspects of the operation and certain considerations in aftercare which are believed to be of practical value, will be presented

General Considerations The application of tracheotomy for indications under consideration here is a wide departure from its traditional role of bypassing a high or laryngeal obstruction We are concerned here with low obstruction produced by blood or secretions occurring as a complication of a thoracic operation or injury It might be added parenthetically that for purposes of this discussion thoracotomy and chest injuries can be considered synonymous

Some difficulty in raising tracheobronchial secretions can be anticipated after any thoracic injury or operation The problem is increased directly with the volume of the secretions and the severity of the postoperative pain, and inversely with the respiratory reserve of the patient These factors in turn are related to other considerations which include the stability of the chest wall, diaphragmatic function arthritis, pulmonary emphysema, bronchospasm and finally such intangibles as the stamina and determination of the patient

Although tracheotomy has been utilized as a prophylactic measure, is a more conventional indication for the operation arises when clearing of the tracheobronchial tree by ordinary methods has failed In the latter circumstance the patient is unable to raise secretions effectually despite encouragement and assistance, and tracheobronchial suction or bronchoscopic aspiration is required at such frequent intervals as to make these methods impractical In this situation operation should be performed without delay before the inevitable pneumonia or atelectasis has had time to develop

Benefits of Tracheotomy The most important single benefit gained by tracheotomy is the provision of a dependable avenue for thorough tracheobronchial aspiration After introduction of the tube, clearing of the airways can be accomplished by the average nurse at an instant's notice, constant attendance by medical attendants skilled in the use of a tracheobronchial catheter or bronchoscopy is not required The operation also permits the administration of oxygen directly into the bronchi in concentrations approximating 100 per cent and permits the administration of antibiotics by the highly effectual intratracheal route

In addition to the straightforward mechanical benefits noted heretofore, certain important other important indications for prompt tracheotomy are fully discussed in the previous chapter

* In addition to the classical indications for tracheotomy

additional physiologic advantages are gained by tracheotomy These include a decrease in changes which occur in resistance and dead space Experience gained in this study has confirmed their contention that paradoxic chest wall movement is decreased by tracheotomy alone

CRUSHING INJURIES TO THE CHEST

In an earlier publication[19] it was shown that desperately ill patients in this category including those having bilateral pneumonia, may recover if tracheotomy is utilized These patients commonly enter the hospital in fairly good condition After an interval of twenty four to seventy two hours the accumulation of tracheobronchial secretions may initiate a vicious circle of increasing dyspnea, paradoxic chest wall movement, pain and anoxia which can be dramatically broken by tracheotomy

Patients in this 'crushed chest category usually do well if they have no bronchial secretions, if they do not smoke or if they are able to cough effectually If tracheobronchial secretions are present in sufficient quantity to cause anoxia the administration of oxygen may mask the clinical picture Some patients do not require oxygen until several hours after injury and in this circumstance it may usually be presumed that an accumulation of tracheobronchial secretions has occurred It has been convenient to consider these patients in two categories (1) those who are unwilling to cough because of pain and (2) those who are unable to cough because of weakness and anoxia Effectual cough can almost always be established in the former, in the latter group tracheotomy should be performed promptly if the therapeutic problem is not solved by infrequent tracheobronchial or bronchoscopic aspiration

In addition to the four cases described in an earlier study[18] nine additional patients with severe injuries to the chest have now been treated with tracheotomy * In every instance the injury was unusually severe and earlier experience indicates that without tracheotomy all would have failed to recover

Data referable to this entire group of patients have been assembled in Table 1 It is seen that all of the patients were men whose average age was forty eight, and that in almost half of the entire group the injury occurred in an automobile accident The number of ribs fractured varied from two to twelve and bilateral fractures were not uncommon It was exceptional for the patient not to have associated injuries and these were commonly multiple and of considerable magnitude Included is an example of fracture of a dorsal vertebra (patient O T) with transverse myelitis Cough was completely ineffectual in this patient because of muscle paralysis rather than pain and anoxia A previous report of the utilization of tracheotomy in this particular situation has not been found As might be expected atelectasis, pneumothorax and hemothorax were frequent complications, and four closed thoracotomies were performed This procedure was performed for pneumothorax in every instance and it is believed that the procedure should be utilized more frequently for hemothorax

It is of interest to note that paradoxic movement of the chest wall of sufficient severity to require traction was present in two patients one of whom died The other patient's chest wall was sufficiently stable to permit removal of the sternal traction after one week The oxygen requirements varied considerably and averaged ten days Many of the patients were given oxygen intermittently for a longer period especially after tracheal suction In general the patient's chest wall stability, his strength and ability to cough, and his oxygen requirements determined the time that the tracheotomy tube was left in place The average for the group was fifteen days It has been observed that pain from rib fractures usually disappears at least one week before solid healing occurs Among the thirteen patients there were twelve consecutive recoveries, one patient died

In general the trend now is to perform the operation early before complications have developed Desperately anoxic patients similar to those described in the original report have been exceptional The following two cases are presented as additional examples of the bene

* Included are two patients operated upon by Dr Judson Griffin and Dr Michael Rizzuto who were seen in consultation

TABLE 1

Patient and Date Seen	Sex and Age	No of Ribs Fractured	Chest Wall Traction	[illegible]	Time from Injury to Tracheotomy	Thora centesis Required	Closed Thoracotomy	Time Oxygen was Required (days)	No of Days Tracheotomy Tube was Used	Result
I W * 1950	M 44	1–7 R 1 4 L	No	a, left	24 hr	No	No	10	20	Recovery
R C * 1950	M, 63	4 8 L	No		4 days	No	No	20	23	Recovery, permanent cerebral damage from anoxia
J McC * 1950	M, 47	6–11 R	No		65 hr	No	Yes	16	21	Recovery
M G * 1951	M, 59	5–11 L 5–8 R	No		72 hr	No	No	3	12	Recovery
O T 11/23/51 to 2/4/52	M, 32	3 4 L 7–9, 12 R	No	frac cord	68 hr	No	No	7	12	Recovery, complete paraplegia
W A (Case I) 1952	M 13	None gun st at wound of chest	No	axilla	48 hr	No	Yes	7	18	Recovery
M R 6/23/53	M, 44	4 5 9 10 L	No		3 hr	Yes	No	9	12	Recovery
L J 7/27/53 to 9/16/53	M 40	5 7 L	No	of left frac	24 hr and 50 min	Yes	Yes	11	13	Recovery
W G 10/6/53 to 11/25/53	M, 74	2 3 L	No	of ma of	90 hr and 20 min	No	No	6	8	Recovery*
E L 3/10/54 to 4/17/54	M, 37	1 3 6 8, 9 R 2–5 L	No	multiple right;	2 hr	Yes	No	14	19	Recovery
W S 3/1*/54 to 4/9/54	M, 46	1 11 L 10, 11 R	Yes	ion	4 hr	No	No	7	16	Recovery
G F S (Case II) 5/10/54 to 7/14/54	M, 63	4 8 L 3 R	No	tured	26 hr and 15 min	Yes	No	18	23	Recovery
H L, Sr 8/13/54 to 8/16/54	M 63	2–6 L	Yes	atrox cea	36 hr	Yes	Yes	3½	2	Died, 3½ days

* Previously reported

1 2

FIG 1 Chest roentgenogram exposed two days after injury demonstrates hemothorax on the left and evidence of patchy atelectasis Although the lungs appear to be fairly well aerated the patient was in coma due to retained tracheobronchial secretions and anoxia

FIG 2. Chest roentgenogram exposed approximately five weeks after injury demonstrates complete recovery from the chest injury

fits that may be obtained in situations in which the prognosis appears extraordinarily grim

CASE I This patient recovered without residual neurologic damage despite grave and prolonged anoxia His response to operation demonstrates that an excellent result may be obtained even when the patient's condition appears irremediable The utilization of the bronchoscope in administering oxygen and clearing the tracheobronchial tree before and during tracheotomy is illustrated

This thirteen year old boy accidently shot himself with a shotgun on November 2 1952, and sustained an extensive wound of the left arm, left axilla and adjacent chest wall He was admitted to the hospital where 1 000 cc of blood were administered, the wound was debrided and a left closed thoracotomy was performed When first seen by me forty eight hours later the patient had been in coma for twelve hours Coarse palpable rales were present over the right lung and he was dyspneic despite oxygen administration Bronchoscopic aspiration was done without anesthesia and about 20 cc of thick purulent secretion were was utilized and oxygen was subsequently administered through it The patient began to move his hands and feet after the operation but did not regain consciousness until the following day This boy subsequently made a complete recovery from the injury to the chest (Figs 1 and 2)

CASE II Another patient sustained a fractured pelvis and ruptured urethra in addition to an unusually severe injury to the chest This patient s progress as regards the injury to the chest followed a conventional pattern Atelectasis developed which required tracheotomy twenty four hours following injury, subsequently multiple chest aspirations were necessary

During a civil defense exercise on May 10 1954 a moderately obese, muscular sixty three year old man, who was securely tied to a stretcher was accidently dropped a distance of 25 feet He fell on his left side on a blacktop driveway On admission to a hospital shortly thereafter he was in severe shock and 1,000 cc of blood were administered When first seen by me four hours after injury the shock had been corrected and examination demonstrated evidence of multiple rib fractures and hemothorax on the left fracture of the pelvis and

3

4

FIG 3 Chest roentgenogram exposed twenty four hours after injury and immediately before tracheotomy demonstrates atelectasis of the lower lobe of the left lung Cyanosis and dyspnea were present despite oxygen administration

FIG 4 Chest roentgenogram exposed approximately ten weeks after injury There is evidence of organized hemothorax at the left base the film is otherwise not remarkable

rupture of the urethra The patient was transferred by ambulance a distance of 70 miles, and a few hours later emergency cystostomy was performed * The patient tolerated the operation well but the following day he was dyspneic and dusky despite oxygen Roentgenogram of the chest demonstrated atelectasis of the lower lobe of the left lung (Fig 3) Tracheotomy was performed and there was immediate improvement following thorough tracheobronchial aspiration and the administration of oxygen through the tracheotomy tube A large left hemothorax subsequently developed which required repeated aspiration The patient's respiratory reserve was severely limited and he became dusky with every tracheal aspiration Intratracheal oxygen was required continuously for eighteen days after tracheotomy, the tube was left in place for twenty-three days The patient made an excellent recovery and was ambulatory when discharged twelve weeks after his injury (Fig 4)

POSTOPERATIVE LARYNGEAL EDEMA

Laryngeal trauma, blind intubation or the use of an intratracheal tube which is too large may produce postoperative laryngeal or subglottic edema [5 8 14] The narrowing may occasionally be sufficiently severe to produce serious respiratory obstruction, in other instances the laryngeal edema produces a bottle neck which prevents the effectual raising of tracheobronchial secretions This complication is particularly prone to occur in children, producing the familiar signs of severe laryngotracheobronchitis In this circumstance tracheotomy may be urgently required Severe laryngeal obstruction occurred in Cases III and IV, in Case V retained tracheobronchial

sis on March 13, 1941 The anesthetic agent was intratracheal ether oxygen The following day inspiratory and expiratory stridor developed with marked sternal retraction Tracheotomy was performed as an emergency measure, striking relief followed immediately and the patient made a good recovery

CASE IV A nine year old girl was found to have a typical machinery murmur and other evidence of patent ductus arteriosus An operation was performed on November 10 1949 under intratracheal ether-oxygen anesthesia (5 mm tube), and ligation by Blalock's technic[1] was accomplished Laryngeal stridor, sternal retraction, moist rales in both lungs, dyspnea and signs of anoxia developed within twelve hours after operation Emergency tracheotomy was performed, relief followed

* Dr Herbert Bandell

immediately and the patient made a good recovery

CASE V A thirty eight year old woman underwent left pneumonectomy for ulcerative pulmonary tuberculosis and tuberculous bronchitis* on October 30, 1951 The anesthetic agent was intratracheal ether oxygen The patient tolerated the procedure well but forty eight hours later hoarseness developed with difficulty in raising bronchial secretions Progression of these symptoms and signs of retained bronchial secretions developed during the next twenty four hours and the patient required oxygen Tracheotomy gave immediate relief The tube was removed after one week the patient recovered and has remained well

TRACHEOTOMY FOLLOWING THORACOTOMY

After observing the benefits of tracheotomy in patients having anoxia due to retention of tracheobronchial secretions every surgeon of experience can recall earlier fatalities which might have been averted if this operation had been employed This is particularly the case in the field of thoracic surgery where increasing utilization of tracheotomy as both a therapeutic and prophylactic measure has recently proceeded apace. In current practice the operation may be carried out prophylactically especially in patients having impaired pulmonary function when it can be predicted that unusual difficulty in raising copious tracheobronchial [illegible]

[illegible] found to be inoperable or whose condition during operation does not permit completion of a definitive procedure Among these are examples of bronchogenic carcinoma having complicating bronchopulmonary suppuration The fairly high mortality currently being reported for exploratory operation for this particular malignancy might be favorably influenced by the more frequent utilization of tracheotomy

Impressive clinical data supporting the utilization of prophylactic tracheotomy after resection of carcinoma of the esophagus have been reported Following this operation Holinger[9] has continued to employ the procedure as both a prophylactic and therapeutic measure in more than an occasional case In response to an inquiry Garlock[8] MacManus[11] and Sweet[16] all have reported utilization of lesions at the gastric cardia Inasmuch as these workers employ various incisions[7 10 15] it would appear that the operative approach itself is an unimportant consideration

TRACHEOTOMY FOR HIGH TRACHEAL COMPRESSION

A tumor producing narrowing of the trachea at the thoracic inlet may result in laryngeal edema requiring emergency tracheotomy In [illegible] requires [illegible] administration

CASE VI An obese seventy year old white man had noticed swelling of his neck for several months when laryngeal stridor and alarming anoxia suddenly developed A bronchoscope was introduced oxygen was administered through it and tracheotomy was performed Exposure of the trachea required traversing a firm tumor microscopic study of which demonstrated malignant lymphoma (reticulum cell type) Relief of the anoxia was immediate and striking The patient subsequently received intensive x ray therapy but failed to respond and died two months after operation

OPERATIVE TECHNIC AND AFTERCARE

Disfiguring scars contractures and delay in healing are considerations which have led to the routine utilization of a transverse rather than a vertical incision A T shaped incision in the trachea is made below the thyroid isthmus a large tube (usually No 6) is used The wound is left wide open and is usually packed loosely with plain gauze Oxygen, 2 to 3 L per minute is administered through the tracheotomy and aspirations are done deeply A prostatic type catheter is frequently used to facilitate aspiration of the left bronchus At intervals of 4 to 6 hours penicillin dissolved in saline is instilled (1 to 2 cc containing 50 000 to 100 000 units) Changing the tracheotomy tube is required infrequently it can be removed as soon as the chest wall is reasonably stable and the patient is able to cough effectually Complete occlusion of the tracheotomy tube for twenty four hours is done before it is removed

* Previously reported[13]

SUMMARY

An indication for tracheotomy following thoracic injuries or thoracotomy may arise when there is serious difficulty in raising tracheobronchial secretions The procedure may be life saving and should be employed promptly when more simple measures are ineffectual in clearing the tracheobronchial tree

Experience with the operation in a group of patients having thoracic injuries is recorded, with one exception all of the patients in this category recovered The utilization of tracheotomy following thoracic operations is discussed and its more frequent employment following exploratory thoracotomy for bronchogenic carcinoma is suggested Technical aspects of the operation and aftercare are outlined

REFERENCES

1 BLALOCK, A Operative closure of the patent ductus arteriosus *Surg Gynec & Obst* 82 113 1946
2 CARTER, B N and GIUSEFFI J Tracheotomy—a useful procedure in thoracic surgery with particular reference to its employment in crushing injuries of the thorax *J Thoracic Surg* 21 495 1951
3 CARTER, B N and GIUSEFFI J The use of tracheotomy in the treatment of crushing injuries of the chest *Surg Gynec & Obst* 96 55 1953
4 DICKMAN R W and BARONOFSKY I D Tracheotomy—one solution for pulmonary problems in the critically ill patient *Journal Lancet*, 71 43, 1951
5 ETSTEN B and MAHLER, D Subglottic membrane a complication of endotracheal intubation *New England J Med* 245 957 1951
6 FLAGG P J Incidence and control of trauma accompanying endotracheal anesthesia *Arch Otolaryng* 53 439 1951
7 GARLOCK, J H Combined abdominothoracic approach for carcinoma of cardia and lower esophagus. *Surg Gynec & Obst* 83 737 1946
8 GARLOCK J H Personal communication
9 HOLINGER, P H Personal communication
10 MACMANUS J E Combined left abdominal and right thoracic approach to resection of esophageal neoplasms *Surgery*, 24 9 1948
11 MACMANUS J E Personal communication
12 REYNOLDS J T et al Role of tracheotomy in the postoperative care of patients subjected to esophagectomy *Arch Surg* 60 211 1950
13 SAMSON P C Immediate care of thoracic injuries, *GP* 3 39 1951
14 SHAW W M Edema of larynx rare complication of endotracheal anesthesia case report *Anesthesiology* 7 416 1946
15 SWEET R H Discussion of Kent E M and Harbison S P Combined abdominal and right thoracic approach to lesions of middle and upper thirds of esophagus *J Thoracic Surg* 19 567 1950
16 SWEET R H Personal communication
17 VONLEDEN H A new concept of tracheotomy *J Internat Coll Surgeons* 19 175 1953
18 WILLIAMS M H Multiple rib fractures an indication for tracheotomy *Surgery* 30 664, 1951
19 WILLIAMS M H Acute tuberculous fibrinous bronchitis *J Thoracic Surg* 24 530 1952

115

Selection and Management of Patients for Air Travel

BURGESS GORDON, M D, *Philadelphia, Pennsylvania*

From the Department of Medicine, The Woman's Medical College, Philadelphia, Pennsylvania Read at the meeting of the Cuban Chapter of the American College of Chest Physicians, Havana Cuba, December 1, 1954

DURING the earlier years of flying selection of patients with pulmonary diseases for air transportation was done with a view toward the calculated risk to be taken because of serious illness and only a small chance of recovery Little was known about the physiologic disturbances associated with lack of oxygen, vomiting and dehydration With the advent of modern pressurized airplanes and the perfection of technics of flying since the beginning of World War II, the dangers and contraindications have been greatly minimized [1] Illustrating the efficiency and wide margin of safety for air travel was the movement of countless injured and sick during the Korean action, a feat that would have been impossible even ten years ago Notwithstanding, the

especially in cases in which there are marked physiologic disturbances

Philadelphia to their homes in the Middle West, Far West and Southwest Studies undertaken at the Jefferson Hospital and the Hospital of the Woman's Medical College included x rays of the lungs, sputum studies and, in certain instances, physiologic determinations

fibrosis associated with tuberculosis or etiology unknown, seven, spontaneous pneumothorax, one, artificial pneumothorax, two, pulmonary neoplasm, four, asthma nine, atelectasis, three pulmonary abscess, two, pneumonitis, one, and extensive consolidation of the lung associated with retained pulmonary secretions, two

It was emphasized to the patients that they should travel only in pressurized airplanes and as far as possible to avoid transfers from one airplane to another They were also advised to remain seated during the flight, except for toilet privileges Letters concerning the diagnosis, emergency oxygen treatment and provisions for boarding the airplane were sent to the appropriate officials twenty four hours before flight time A lift was advised for patients with dyspnea on exertion so that they could avoid climbing stairs into the airplane

The number of patients arriving without incident was thirty six, four were removed at intermediate airports as a precaution Of those removed, one suffered from extreme nervousness with no significant disturbance of the lungs one with a pulmonary abscess experienced a mild bout of hemoptysis, the third a patient with emphysema, was anxious because of dyspnea, in the fourth patient manifestations developed which suggested tension pneumothorax

The following patients of the group with advanced pulmonary emphysema illustrate the safety of air travel Patient R H, age sixty three years, with a marked increase of residual air in the lungs (55 8 per cent of total lung volume), low oxygen saturation of the arterial blood (93 per cent) and reduced maximal breathing capacity (78 1 per cent based on predicted figure), returned to his home satisfactorily and recently has traveled extensively in the United States and South America He uses intermittent positive pressure (oxygen) breathing in flight as necessary, the apparatus being portable and easily employed It is interesting that he has crossed the Andes

ains comfortably in turbulent air Pa-
H T, age sixty-four years, with severe
sema, the function tests indicating a
content of residual air in the lungs
per cent of total lung volume) with
ased arterial oxygen (92 per cent) and
ced vital capacity (41 per cent decrease
he predicted figure), returned to his home
ventfully by airplane, a distance of ap-
ximately 1,850 miles

The disturbances of pulmonary diseases that
n become prominent under certain condi-
ons in air travel are elucidated in the physio-
gic studies of coal miners According to
Motley,[1] the basic factors are decreased
entilation as evidenced by lowered vital
apacity and maximal breathing capacity, in-
reased residual air characteristic of pulmonary
emphysema, with attendant mixing and dilu-
tion problems, impaired diffusion due to in-
creased resistance in the pulmonary membrane
as in acute pulmonary edema, and unequal
alveolar aeration and perfusion as found re-
sponsible for lowered oxygen tension Pulmo-
nary fibrosis leads to impairment of the air
circulation, and although perfusion may be
present, ventilation becomes inadequate The
respiratory problems are accentuated when
the disturbed alveoli are perfused but non-
aerated, causing circulatory pathways that act
as small shunts thus reducing oxygen saturat-
tion While the distribution factor is a common
disturbance in pulmonary fibrosis, it is also
noted in obstructive diseases such as atelectasis,
consolidation of the lung, retained bronchiolar
secretions and bronchospasm

In addition to the physiologic disturbances
resulting from pulmonary diseases per se
there are certain conditions of the pleural
cavity that cause impairment of pulmonary
function According to Smedal,[2] two forces oc-
cur as the airplane gains altitude One force
(and the more important of the two) is that
which presses against the lung, causing varying
degrees of compression, the second force,
directed to the thoracic cage, causes expansion
with elevation of the chest With expansion of
the thoracic cage the thorax tends to assume
a position of true inspiration which in the
presence of a diseased lung greatly disturbs
pulmonary function

The present considerations deal primarily
with pulmonary disease and the associated
influences of pneumothorax In certain cases
the question has been posed regarding addi-
tional factors that may cause difficulties in
breathing, especially the behavior of the
coronary arteries Smedal[2] mentions that
individuals with coronary disease tolerate a
degree of anoxia remarkably well This is
attributed to the extraordinary compensation
gained through an accelerated heart rate, in-
creased vital capacity, and vasodilation, espe-
cially of the coronary blood vessels, attained
at the higher altitudes It should be realized,
however, that the real capacity of diseased
coronary arteries is difficult to evaluate and
understand The electrocardiograms taken of
normal individuals subjected to 10 per cent
oxygen in the inspired air, corresponding
approximately to an altitude of 18,000 feet,
may show far greater variations than are noted
in abnormal subjects

In selecting patients for air travel the possi-
bilities of aggravation of the disturbed physiol-
ogy should be considered The decision calls for
careful taking of history as well as physiologic
appraisal Patients with paroxysmal cough,
severe dyspnea, tension pneumothorax and
bronchospasm easily provoked by smoke and
odors should not travel by air Proper rest and
assurance twenty-four hours before departure
of the plane are essential Both fatigue and
anxiety are precipitating factors for intolerance
to flight, even at a moderate altitude, and
should be strictly avoided The common cold
may be detrimental, especially in complicating
bronchiolitis and nasal sinusitis With reference
to bronchial infections there is always the
possibility of dissemination of secretions into
the alveoli with resultant atelectasis and
marked accentuation of pulmonary dysfunc-
tion Middle ear conditions might be provoked
in cases of sinusitis, in such cases it is desirable
to postpone the flight Air travel for patients
with active pulmonary tuberculosis should be
discouraged since public health technics are
difficult to arrange and there is always the
possibility of hemoptysis

The treatment of disturbed function in
emphysema requires the use of special appara-
tus, prevention of attack is accomplished with
assurance and instruction in the effective
manner of breathing and expectorating It is
essential for patients contemplating air travel
to be relieved of their anxiety state, otherwise
land conveyances should be used For patients
with bronchospasm the use of a bronchodilator

drug such as vaponefrin with nebulization should be employed before and during flight In cases of emphysema with shortness of breath on slight exertion, apparatus for employing intermittent positive pressure breathing (oxygen) should be used before flight time and in severe cases the apparatus should be taken aboard for periodic treatments As pointed out by Motley and co-workers[4] this type of treatment will relieve dyspnea when other forms of therapy fail In order to facilitate diaphragmatic breathing[5] especially in patients with a relaxed abdomen a special type of abdominal support should be worn[6] patients should be told to sit up straight and not slouch in order to favor adequate ventilation of the lungs, with any desire to expectorate patients should take a full breath then cough at the end of expiration In cases of artificial pneumothorax it is advisable to reduce the intrapleural pressure a day or two before plane time in order to compensate for any possible expansion of air at the higher altitudes Pleural effusions with associated pneumothorax should receive adequate drainage before the flight Dramamine[8] is advised for air sickness

Patients often inquire about the advisability of smoking during flight Barach and co-workers[6] found that carbon monoxide poisoning due to the inhalation of tobacco smoke may under certain circumstances impair resistance to anoxia, especially when the passenger is traveling without supplementary oxygen at altitudes of 10 000 to 12 000 feet In the modern pressurized cabin the possibilities of a significant disturbance due to smoking is unlikely, yet it is desirable to use every precaution Smoking is not advised and as a further precaution patients should request a seat with a person who does not smoke

CONCLUSIONS

The present data indicate that air travel by patients with chronic non tuberculous pulmonary diseases may be entirely safe and comfortable The basic physiologic disturbances call for certain precautions, notably the avoidance of fatigue undue exercise and anxiety states before flight time and moving about while in the plane It is essential for patients to employ proper breathing habits during air travel and to use bronchodilator drugs with or without oxygen inhalations for attacks of dyspnea With proper therapeutic measures the maximum utilization of impaired pulmonary function is possible even in cases of marked disability

SUMMARY

1 There is considerable leeway for air transportation of patients with chronic pulmonary conditions

2 The physiologic disturbances of pulmonary diseases are discussed with special reference to aggravation that may occur in the presence of bronchospasm and upper respiratory tract infections

3 The physiology of pleuropulmonary conditions as manifested at the higher altitudes is discussed

4 Prevention and treatment of symptoms encountered during air travel are outlined

REFERENCES

1 GORDON B The selection of patients with cardiopulmonary diseases for air travel. *Dis of Chest* 23 38 102, 953

2 MOTLEY H L The use of oxygen in comatose states *Bull New York Acad Med* 26 479–494 1950

3 SHEDAL H A Air transportation of persons with cardiorespiratory disease and/or injury *J Aviation Med* 23 33 37 1952

4 MOTLEY H L GORDON B LANG L P and THEODOS P A Impairment of pulmonary function in anthracosilicosis *Arch Indust Hyg* 1 133 1950

5 GORDON B The mechanism and use of abdominal supports in the treatment of pulmonary diseases *Am J M Sc* 187 692–699 1934

6 BARACH A L ECHMAN M and MOLOIT N Modification of resistance to anoxia with especial reference to high altitude flying *Am J M Sc* 202 336 1941

Index

Abscess, ameb c l epat c 424
lung, 62 6, 608 623
ang oc rd ograpl y in, 193
asp ration type of 64
bacter logy of 608
b onchoscopy n 95 6 9
compl cations of 65 609–610
different al d gnosis of 680
pathogenesis of 608–608
po toperat c 457
residu l cav t es in 65
site of 608
sol tary les on in 94
sputum exam nat on n 85
surgical considerat on n 617
623
treatment of 610–6 9
aerosol therapy 613
ant b ot cs, 610 620
asp rat on 613
broncl oscopy 6 3
external dra nage 614 62
pneumon ectomy 615
postural dra nage 6 2 620
resect on 46 6 5 621
subdiaphragmat c fluoroscopy
n 124
Achromyc n* n abscess of lung,
611
n resp ratory nfect ns, 604
Ac d base balance 44 45
Ac dosis, resp ratory n en pl y
sema 354
treatn ent of 898
ACTH *See* Cort cotroph n and
cort coster ds
Acu-d one* n bronchomon l as s
396
Actinomyco s 404 406
resection in 463
Adaptat on d sease 9 8
Add son s disease pulmonary
changes ■ 271
Adenocarcinoma 695 804
resect on of tracl ea n 872
Adeno ds nfected and cougl 224
Adenoma bronch al 665–666
b onchoplasty n 883
bronchoscopy n 94 97 673
bronchotomy n 869
ca c no d 665
cyl ndro d 666
flap procedure n 8 o
lobar transplant ■ 871
oncocyto d 665
resect on n 460
sol tary 95 99
Adenomatos s pulmonary 665 735
Adolesce ts tuberculosis n 574
580
Acrat on grad ent 40
Acrosol therapy 894 898
in abscess of lung 613 620
aleva re* 232 357 896
broncl od lators 894
n broncl omo l s s 3 6
cont nu us, 895 89
n cough 232
n empl ysen 3
pa n n b o d* 894
pancrea c l rnase 894
n resp ratory n p men 890
vaponefr n* 232 2f 5 35 620
894
Agenes s of lung 4 3 9 3 3
ang ocard g pl n 49
d agnosis of 3
patl ogenes s of 3 9
A r l aks n su g r 850
Air pace ab r n l « See C st c
d se se
A r tra l co d t on n 935
937
Alarm r act n 8
Aleva * 89
n cough 232
n empl ysema 3 8
Alkalos s, r sp r to
Allergy 25 268
bronch l sthma 2 26
bronch l d sease sputum e
am n t on 86
cough f om 224 232 259
extracts ■ 254
to f x ds 2 3
to fung 253
to nsects 2 3
nasal tests 254
ophthalm c t sts 254
poll nos s 25 259
rh n t s, 25 259
skin tests 253
status a tl mat cus, 267 268
vascular and sthma 26 263
Alveolar cap ll ry membrane 3
cell tumor 460 735
equat on 30
gas exchange w th pulmonary
cap llar es 2 3
vent lat on 28 34
Ameb as s 424
Am done n cough 230
Am nophyll ne in b onch l asthma
264
n cough 231
n emphysema 255
Am nopter n n leukem a 771
Amn on un chlor de n cougl 230
Amylo dos s puln onary changes
n 272
Anaphylax s leukocyte count after
54
Anaton y of bronch 12 6
of larynx 17 18
of lungs 1 o 17 23
of pleura 817
of tracheobroncl l tree 18 3
Ancylostoma duodenale 426
Anem a s ckle cell pulmonary
changes n 2 o
Anesthes ology 477 485 92 –927
atelectas s in r sk of 453
n broncl ography 144
n bronchopulmo ary d sease
921–924
postoperat ve care 923
p eoperat ve care 922
c rd ac r st n 498
c culat on ma ntenance 483
484
qu pment for 484
n ntrapleural d sorders 924
n med ast n l sl ft 480
n neuromuscular d sturbances
925
n obes t 927
p radox c r p rat on n 480
resp at on ma nt nance n 478–
483
resp t ry obstruct on 481 483
32
n surgery for c n n a 7 5
n the full stom ch 92,–927
vent l t on du ng oper t o 493
Aneurysm arter ov nous of lung
32 325
course of 324
d agnosis of 324
laboratory f nd ngs n 323
patholog c anatomy of 32
phys ology of 322
roentgenology in 323
symptoms of 322 323
treatment f 325
d sscet ng pulmonary compl ca
t ons of 94
of great vessels ang oca d og
raphy n 152
Rasmussen s ruptu ed n hemor
rhage of tub rculos s 5 3
Ang ocard ography 80 38 147
6
n gene s of lung 149
n aneurysm of great vess ls 55

Angiocardiography (*contd*)
in anomalies of pulmonary arteries, 147
in anomalies of pulmonary veins, 150–151
in bullous emphysema, 156
in cancer of lung, 160–161
in cystic disease, 650
in fibrosis, pulmonary, 155
in fistula, arteriovenous pulmonary, 151
in infections, pulmonary, 151–155
method of, 147
in miscellaneous pulmonary diseases, 156
in thrombosis, pulmonary, 218
in tumors, benign, 672
Angiomatosis, arteriovenous, differential diagnosis of, 680
Anomalies, of bronchi, 12–16
of lungs, 1 10
Anthrax, pulmonary, 306
Antibiotics, in abscess of lung 610, 620
in surgery, 496
Anticoagulants in pulmonary embolism, 212
long term therapy, 213 215
Antigen, 251
Antihistaminics, in allergic rhinitis, 257
in cough, 232
Aortic arch, double, 187
right 187
Aplasia of lungs 2 309
Aralen®, in malaria, 423
Arteries, bronchial, 21
carbon dioxide content in disease 178
oxygen saturation in disease, 177 387
pulmonary 21
absence of, angiocardiography in, 147
anomalies of, 9
embolism and infarction of, 209–215
occlusion of, angiocardiography in, 155
thrombosis of, 217–222
Arteriovenous, aneurysm of lung, 321–325
See also Aneurysm arteriovenous, of lung
angiomatosis, differential diagnosis of, 680
fistula, resection in, 464
Arthritis, rheumatoid, 284
Artificial, circulation, 501
cough, 360, 891, 904
respiration, 43, 316, 478, 501
See also Pressure breathing
Asbestosis, 388–389
diagnosis of, 388
pathogenesis of, 380
Ascariasis, 426
Aspergillosis, 402–404
resection in, 464
Asphyxia neonatorum, and atelectasis, 315
Aspiration, diagnostic, 78
in amebiasis, 425
in carcinoma of lung, 704, 712
in lipoid pneumonia, 347
in pleurisy with effusion, 826
therapeutic, in abscess of lung, 613
double suction technic, 923
in hydatid cyst, 440
Asthma, bronchial, 225, 259–267
bronchopulmonary reactions in, 260–261
bronchoscopy in, 97
cardiovascular complications in, 260–261
in children, 265
chronic sinus disease in, 264
clinical picture of, 260–263
diagnosis of, 263
etiology of, 259
pseudo-asthma, 470, 471
sputum examination in, 86
status asthmaticus, 267–268
hormone therapy in, 909, 910
treatment of, 264
corticosteroids, 910
corticotrophin, 909
nerve surgery, 469
vascular allergy in, 261–263
Atelectasis, 65–66, 447–450, 625
acquired, 447–449
bronchial obstruction in, 447
bronchoscopy in, 97
in childhood, resection in, 571–572
compression in, 447
diagnosis of, 449, 451
differential diagnosis of, 211
fluoroscopy in, 125
massive pulmonary collapse in, 449–450
myocardial infarction and, 194
of newborn, 314–320
and asphyxia neonatorum, 315
clinical picture of, 314
differential diagnosis of, 315
incidence of, 314
management of, 315–317
new method of treatment, 317–320
pathogenesis of, 314
prognosis of, 315
physiology of, 448
postoperative, 508
prevention of, 227
prognosis of, 449
prophylaxis of, 453 454
symptoms of, 449
syphilis and, 193
treatment of, 449, 454
Aureomycin *See* Chlortetracycline
Aurin Tricarboxylic Acid (ATA), in beryllosis, 392
Autosen®, in cough, 230
Avertin® anesthesia, 923
Azygos vein, lobe of, 8
roentgenology of, 139

Bacterial diseases with pulmonary changes, 304–306
brucellosis, 305
diphtheria, 305
endocarditis, 190
pertussis, 304
salmonellosis, 305
scarlet fever, 304
typhoid fever, 305
Bamboo phenomenon, 489
Barium, enema x-rays, 133
swallow procedure, 132 133
Belts, abdominal, in respiratory impairment, 891
Benadryl®, in hay fever, 257
Bennett breathing unit, 46, 360, 900
Benylin®, in cough, 230
Beryllosis, 390–392
roentgenology in, 390
treatment of, 391
Bicillin®, in lung abscess, 611
Bilobectomy, 458
Biopsies, diagnostic, 79
aspiration. *See* Aspiration, diagnostic
in disseminated pulmonary disease, 89–92
technics, 89
in hemoptysis, 208
in pleural tumors, 835
scalenus fat pad, in sarcoidosis, 288
Blast injury, 811–812
Blastomycosis, 397–399
diagnosis of, 398
mode of infection, 398
onset of, 398
pulmonary involvement in, 398
resection in, 464
treatment of, 398–399
Blebs, emphysematous, 71, 114, 641–644, 837
See also Cystic disease
Blood, arterial, oxygen in, 41
cultures as diagnostic aid, 77
diseases with pulmonary changes, 269–271
hemosiderosis, 270
leukemia, 269, 771, 774
myeloma, multiple, 270
plasmacytoma, 270
polycythemia vera, 270
sickle cell anemia, 270
flow, diversion of, 502
hemoglobin in cardiopulmonary disease, 177
supply to lungs, 21–22
vessels. *See* Arteries, Vascular conditions *and* Veins

Breast cancer ■operable 66 67
Breath fet d 224
Breath ng, exerc ses, 3,8 3 ,16
891
pressure. See Pressure breathing
See also Resp rat on
Bronchial co ditio s, arterits 21
asthma 259–267
See also Asthma bronc al
bleeding into bronc 482
closure of div ded bronc us 8(4
866
eparter al 5–6
f stula 248 250
lobar 6 141
muco d 1 p ct o resect n in
462
obstruct ons, 66 627
and atelectasis 44
ball valve 627 642
in ch ldren 636–638
posteparter al 6
pre-eparterial 6
roentgenology 1 113
segmental 6 12 16
sequestration 8–9
steno s, n ch ldl ood 574
subsegmental d splacem ent f 6
surgery n 863 877
ve ns, 22
Bronchiectas s 62 6, 5,6–6 7
n adolescents resection n , 8
angiocard ography in 1,3
bronchography in 136 143
in children ■sectio s in ,72
complications of 64
cyst c See Cyst c d sease
diagnosis of 597 603
d fferential d agnosis of 239
dry 596
etiology of 596
n older pat ents 6 3–60
roentgenology in 114
sinusit s and, 225
sputum exam nat on in 86
symptoms of 5,6
typhd s and, 193
treatment of 597–600 603–607
antibiot cs 598
nerve surgery 471
pneumonectomy for hemor
rhage 604
postural dra nage 598
resect on 461
surg cal exers on 5,8
Bronch olar carc noma, 73, 745
Bronchiole term nal 17 355 604
Bronch olectas s 63
Bronch tis, 235 240
n ch ldren 237 239
chronic 226
cil ary act on in 237
collateral respirat on n 236
cough in 236
diagnos s of 238 239
emphysema and 354
Bronchitis (contd)
f brinous 237
roentgenology n 1 6
secret o s in 23
s nobronchitis 225
sputum examinat on 85 86
treatm ent of 239–240
Bronchob l ary f stula 24,
Broncl ocol c f stula 249
Bronchoco str ct on and c npl
sin a 357
vagoto my n 469
Bronch d lators 894
Bro cl o v pl ageal f stul 24
Bro choge n c carc non (7 4 0
686–690 694–698
Bronchoglutcal f stuln 25
Broncl ography 9 136 38 143
146
anesthes a 44
in bronch xt s 5, 6 3
bronch sc p c th d 4,
in c rc n n
in cl ld en 14(
contrast n d 43
n cyst c d se se f f
dangers n 46
ind cat ns for 43
methods of 144 4(
prepar t on f p n 44
subgl tt c 46
supragl tt c 44
tra sglot c 4,
Broncl ol th s s 24 24
bronchoscop c fe tu l 244
bronchoscopy n r n o l of 96
bronchotomy n 8 4 8 5
cl nical features of 242
d agnos s of 244
end br nch al 242
intramural 242
pathogen sis f 24 242
roentgen fe tures of 243
treatment f 245
Bronchon n l s s 334 396
diagn sis of 39,
mild 395
mode f nf ct on 334
severe 39,
treatment of 396
Bronchop r nephr c f stula 249
Broncl oplast c procedures 869–
8 6 879–887
n adenocarc no n 872
in bronch al adenoma 869 8 o
87 883
n carcinoma bronchogen c 874
884 885
flap procedures 867 870
techn c of 886
n trauma, 875 880–883
in tuberculous bronchostenos s
883
n tuberculous endobronch t s
875
See also Bronchotomy
Bronchopleural f stula 246–250
Bronchopneumon a sputum ex
am nat on in 85
Bronchopneumon c inf ltrat ons in
sarco dos s 294
Bronchopulmonary
anesthes a in disease 921–924
lobes 140
segments 12 ■
sequestrat on intralobar 6,7
663
suppurat on in children 63, 636
tens on cyst c d sease n ch ld
hood 632–634
Bronchoscopy 78 93–98
in abscess of lung), 6 3 619
in adenoma 94 97 673
in agenes s of lung 310
n anesthes ology 482
n asti ma ,7
n atel ctas s 97 424
bronch ectas s 603
n bronchograpl y 14,
n bronchol ths 96 244
in carc noma 94 05 708 712
n children ,6
contraindicat ons to 93
in cyst c d sease 650 655
in foreign bodies 96 444
in hemoptys s 95 207
ind cat ons for 93
n mult ple pr mary cancers 72,
726
n pleurisy w th effus on 827
in str dor or wheezing 95
n tracheal stenos s 96
in tracheobronch al tuberculos s,
94 96
as tre tment ,6–97
n tun ors, ben gn 673
Broncl ospasm and emphysema
3,7
v got my n 469
Broncl ostenos s 574, 87, 883
Bronchosubphren c f stula 248
Bronchotomy 867
n bronch al adenoma 869
in bronchol th ts s, 874 875
in tumors ben gn, 673
Brucellos s, pulmonary changes in
305
Bucky chest x rays 132
Bullae empl ysematous, 71 114
642 837
See also Cyst c d sease
Bullet wounds 815
Burns 812 8 3
Butazol d n* ■ Hodgkin s d se se
760
Butyn* anesthes a 144

Calc f cat ons cart lage fluoro
scopy ■ 118
cl ondral fluoroscopy n 118
n co n tes ons 786–787 93
lymph no le 241

Calcifications (*contd*)
metastatic, of lungs, 271
roentgenology in, 108
Calcreose®, in cough, 231
Calculi, bronchial, 241–245
See also Broncholithiasis
Cambridge glass electrode, 45
Camoquin®, in malaria, 423
Candidin, in bronchomoniliasis, 396
Caramiphen ethanedisulfonate, in cough, 229
Carbon dioxide, arterial and venous content, in cardiopulmonary disease, 178
effect of, in respiration, 33
intoxication, 897
regulation in body, 42–44
therapy, in cough, 231
Carcinoma, adenocarcinoma, 695, 804, 872
bronchiolar, 735
diagnosis of, 742–743
etiology of, 740
histogenesis of, 740
incidence of, 741
metastases in, 743
pathology of, 740–741
prognosis of, 744
radiography in, 742
symptoms of, 741
treatment of, 743–744
bronchogenic, 67, 694–698
angiocardiography in, 160–161
aspiration in, 704
bronchoscopy in, 94 705–708, 712
causes of death, 697
cytology in, 691–693, 704
diagnosis of, 783 784
differential diagnosis of, 211, 679
exploratory thoracotomy in, 709–710
from liquid petrolatum, 351
laboratory findings in, 697
pathology of, 694–696
physical findings in chest, 697
pleural effusions in, 697
preclinical, 686–690
prognosis of 697
roentgenology in, 699–702, 703–704
differential diagnosis, 701–702
in hilar tumor, 699
in parenchymal tumors, 699
in peripheral tumors, 700
site of tumors, 699–701
selection of cases, 704–710
small cell type, 695
solitary lesions in, 798
squamous cell type, 695
surgical technics, 712–721
anesthesia, 715
extent of operation, 714
operability, 713–714
Carcinoma, bronchogenic, surgical technics (*contd*)
preoperative preparation, 714
radical pneumonectomy, 715–721
symptoms of, 696
treatment of, 697
bronchoplasty, 884 885
extrapleural resection, 874
nerve surgery, 470
resection, 710–711
tracheal resection, 874
tracheotomy, 933
inoperable, 761–772
accurate diagnosis of, 761
anatomic disturbances in, 762
of breast, 766–767
bronchogenic, 764
leukemias, 771
lymphomas, 767
metastatic, 765 766
physiologic disturbances in, 763
prostatic, 767
pulmonary disturbances in, 762
supportive measures in, 771
of thyroid, 767
treatment of, 764 772
metastases *See* Tumors, metastatic
multiple primary cancers, 723–733
compilation of cases, 724–725
diagnosis of, 725–727
diagnostic criteria, 723–724
histologic types of, 727
oral cavity cancers, 728
solitary metastases, 729
synchronous and metachronous, 724
treatment of 727
Carcinosarcoma, 754
Carcinosis, miliary, 749
Cardalin®, in emphysema, 231, 357
Cardiopulmonary diseases, 173–198
arterial oxygen saturation in, 177
bacterial endocarditis, 190
blood hemoglobin in, 177
carbon dioxide content of arteries and veins, 178
chronic cor pulmonale, 196–198
circulation time in, 176
circulatory function studies, 183
classification of, 173
clinical picture of, 183
congenital cardiac lesions, 187–188
cyanosis in, 175
differentiation between pulmonary and cardiac disease, 173–179
dissecting aneurysm, 194
dyspnea in, 174
electrocardiogram in, 176, 184–185
Cardiopulmonary diseases (*contd*)
embolism, pulmonary, 210
emphysema and, 361
etiology of, 173–174, 180
extremities, appearance of, 174
hematocrit in, 177
hemoptysis in, 175
incidence of, 180
intrapericardial pressure, 191
laboratory tests in, 176–179
lung function studies, 178
mitral valvular disease, 189–190
myocardial infarction, 193–194
neoplasms, 195–196
pathogenesis of, 181–183
pericarditis, 190
pleural effusion in, 175
pulmonary disease affecting heart, 180–185
pulmonary disease secondary to heart disease, 187–198
rheumatic fever, 188–189
roentgenology in, 176, 183
symptoms and signs of, 173–176
syphilis, 192–193
treatment of, 185
venous pressure in, 176
Cartilage calcifications, fluoroscopy of, 118
Casoni test, in hydatid cyst, 439, 440
Catarrh, in upper respiratory infection, 223
Cavernostomy, in tuberculosis 524, 564
Cavities
in children, 570
in coccidioidomycosis, 418
pseudocavity, 121
roentgenology in, 103, 113
in tuberculosis, 537–542
Cells, foam, 350
Cesium, radioactive, 789
Chicken pox, pulmonary changes in, 302
Childhood disorders
bronchial asthma, treatment of, 265
bronchial occlusions, 636–638
bronchitis, 237, 239
bronchopulmonary malformations, 632 634
bronchopulmonary suppuration, 635–636
foreign bodies, 442
hamartoma, 670
inoperable tumors, 771
lobar emphysema, 642
pleural fistulas, 638–639
resection in, 568–581
tension disorders, pulmonary, 631–639
tracheotomy in postoperative laryngeal edema, 932
Chloramphenicol, in abscess of lung, 611

Chloramphenicol (*contd*)
n empl ysen a 357
n pneu non a 339
Chloromycetin® *See* Chloramphe cul
Chlortetracycl ne in abs c ss of lung 611
n emphysema 357
■ pneumonia 339
Chlor tr meton® in hay fever 257
Cholesterol pneumonitis, resect o ■ 462
Chond on a 667 678
Chordae tend neae ruptured and pulmonary d sease 130
Chor omen ngit s lympl ocyt c pulmonary changes in 3 3
Chrom c pl osphate rad oact vc collo dal 778
Chylothorax 832
Cilia resp ratory 19
Cil ary act on in broncl tis 237
Ci culation art ficial 50
collateral 448
det rm nat ons, d agnost c 80
function stud es, 183
— ntenance n anesti es a, 483
d nonary 49–58
biochem cal funct on of lung, 57
congenital anomal s of 147
151
erythrocytes, 49
leukocytes, 49
physiology of 49–50
platelet product on 55 57
removal of leukocytes by lung 50–55
resp ratory 35 36
time in cardiopulmonary d sease 176
Cirrhosis of l ver and pleural d s- orders, 830
Clubb ng, n arter ovenous aneu rysm pulmonary 323
n carc noma 697
Cobalt teletherapy 779
Cocc dio domyconas 399–40 417 422
bronchopleural f stula n 420
ca t es in 4 8 42
check valve mechanism w th 420
giant 4 9
nfected 419
ruptured, 420
compl cations of 417
empyema in 420
hemoptysis in, 420
non expans le lung n 42
pleural effus on in 420
resect on in 463
su gical considerat ons ■ 420–421
Coccid oma, 420
Code ne, n coug 229
Collator 904
Co n les ons 83 805
n abscess 44
ade on a of br nchus 795 799
ben g tu ors 794
calc f cat n of 786–787 793 797
carc non 8
case reports 87 7)
d gn sis of 92 6, 803
ob tacles to 792
granulo natous 794 9)
l am rton a 95 800
n hydat d d sease 94
nc de ce of 8 3
in fa ct on 94
met stat c nodules 96 98
pleu l mesotl l o na 8
n pn an on t s, 794 8 o
p ary n al gnant tum rs 795
ro ntgen l g n 83 93 803
sar oma 8
skin tests n 734
surgery ■ 803 805
tr t nent of 804
n ascular abno nal t 93
Collagen d se se 2 3 280
et ology of 2 3
pathology o 2 3
periarter t s nod 274 2 8
rheum t c fev r 284
rl eumato d arti 284
treatm nt f 28
Collapse mass c pu m v 449 45
Collapse therapy tube cul s 523 560 6
pneumoper t n um 23
pneun otho 23
thoracoplasty 523
Collater l c culat on 448
resp rat on 22 23 28 34 66 236 627
Comp ess on atelectas s 44
card ac 50 502
Concuss on n ury 8 8 2
Congen tal d seases 309 325
card ac les ons 87 88
double aort c arch 87
patent ductus arter osus 88
r ght aort c arch 87
pulmon rv l s ons agenes s of lung 4 49 309–3 3
ang oca d grapl y n 47 5
aplas a 2 3 9
at lectas s of newborn 314 320
arter o enous aneurysm 321 325
cyst c lung 64
hern a 329
hypoplas a 309
Congest ve heart fa lure and pul monary stenos s 89
Co pper sulphate n act nomycos s 406
Cor pulmonale *See* Card opul mon d sease
Co an ■
Cor c din syrup® in cough 230
Cortef® in ■ nphysema, 357
Cort cotropl n and cort costero ds 908–918
in beryll os s 391
in broncl al asthma 26, 909–911
contra nd cat ons to 916
dusts of cort sone 896
effects of tl erapy 915–916
n en physema 357 911
in fibros s pulmonary 185 913
in granulo natoses pulmonary 912
n hay fever 257
n Hodgkin s d sease 760
n nf ltrat ons w th eos noph l a 9 4–9 5
laboratory p ocedures n 917
n leukem a 771
precaut ons n 9 7
n resp ratory funct on impa r ment 892
n sarco dos s 297
n status asthmat cus 909–911
Cortisone *See* Cort cotrophin and cort costero ds
Cosanyl® n cough 230
Cough 226–233
allerg c 259
art f c al 360 89 904
n broncl ectasis, 596, 603
n broncl t s 236
n bronchol th asis 242
n carc noma 696
in ch ldren 228
n emphysema 354 369
treatment of 355
et ology of 226
nab l ty to n trauma 929
n anagen ent of 227 228
aerosol therapy 232
ammon um chlor de 230
d hydrocodeinone 229
drug therapy 228 233
gases 231
morph ne 229
o l inst llat ons 232
pancreat c dornase, 232
potass um od de 230
radiat on 232
surg cal intervent on 227
pathology of 227
pharyngeal 238
n pleur sy 823
reflex 20
n resp ratory infection upper 223
tussive syncope 227
Creosotes, in cough 231
Croup apparatus 896
Crush ng njur es, 814–815
tracheotomy in 929–932
Cryptococcos s 397
resect on n 464
Cryst c ll n® ■ pulmonary sar co dos s 912

Cutaneous reaction, in histoplasmosis, 410
Cyanosis, in cardiopulmonary disease, 175, 323
Cystic disease, 624–663
angiocardiography in, 156
atelectasis, 625
bronchial occlusions, 636–638
bronchopulmonary malformations, 632–634
bronchopulmonary suppuration, 635–636
causes for enlargement of cysts, 642 644
in children, 631–639
clinical findings in, 631
compensatory overexpansion, 625
compression, 625
diagnosis of, 649–650
differential diagnosis of, 680
emphysematous blebs and bullae, 641–644
etiology of, 8, 642–644
hemorrhage, 648
infected, 646–647, 654–656
course of, 654
diagnosis of, 655
intralobar bronchopulmonary sequestration, 657 663
diagnosis of, 657
incidence of, 657
pathologic aspects of, 658
symptoms of, 657
natural history of, 628–629
overdistention, 624
overinflation, 624
pathologic classification of, 631–632
pleural fistulas, 638–639
primary defect in, 627–628
pulmonary function disturbances, 645
roentgenology in, 114
tension, in children, 631–639
reversibility of, 625–627
rupture, 647
spontaneous pneumothorax, 837–844
therapeutic concept, 645–652
treatment of, 651–652
Cysts, batrachian, 641
echinococcus, roentgenology in, 114
hydatid, 430–441, *See also* Hydatid cysts
pulmonary, 641
differential diagnosis of, 65
resection in, 463
roentgenology of, 109, 114
sputum examination in, 87
Cytology, 691–693
See also Sputum examination

Dainite®, in emphysema, 231, 357
Dapanone®, 894
Dead space, respiratory, 27
Decortication, 845 851
concomitant operations, 851
in empyema, 847–848
in fibrosis of lung, 70
in hemothorax, 847
indications for, 847–848
pathogenesis of hemo organization, 846–847
technics of, 849–851
in tuberculosis, 524, 848–849
Defibrillation, 503
Deltasone®, in emphysema, 358
Deltra®, 918
in emphysema, 358
Deltrasone®, 918
Demerol®, in bronchial asthma, 265
Denervation, autonomic, 466–475
in bronchial asthma, 469
in bronchiectasis, 471
in bronchogenic carcinoma, 470
in emphysema, 472–474
in pneumothorax, chronic recurrent, 471
Dermatomyositis, 282
Desoxyribonuclease, pancreatic, 895
in cough, 232
Deve s lobe, 142
Dextromethorphan hydrobromide, in cough, 229
Diabetes, pulmonary changes in, 271
Diagnosis, 73–80
angiocardiography, 80
biopsies, 79, 89–92
blood cultures, 77
bronchography, 79
bronchoscopy, 93–98
circulation time, 80
complement fixation test, 77
deep roentgen ray therapy, 80
electrocardiogram, 80
endoscopy, 78
fluoroscopy, 78
gastric contents, 77
hematologic studies, 75
history, 73 75
laboratory aids, 75 80
methods, 73–80
physical examination, 75
pleural fluid and gases, 78
pneumoperitoneum, 79, 134
pneumothorax, 79, 133
precipitin test, 77
radioactive isotopes, 80
roentgenology, 77
sedimentation rate, 77
skin tests, 77
sputum examination, 76–77, 81–87
thoracotomy, 80
thoracoscopy, 79
urine examination, 76
venous pressure, 80
Diamox®, in respiratory function impairment, 892
Diaphragm, fluoroscopy of movements, 121
roentgenology of, 111, 116
Diaphragmatic breathing, 516, 937
Diffusion, 29–32
Dihydrocodeinone, in cough, 229
Dihydrostreptomycin, in abscess of lung, 611
in tuberculosis, 521
Dilantin®, sensitization to, 261
Dionosil aqueous®, in bronchography, 144
Dioxyephedrine hydrochloride, in cough, 230
Diphtheria, pulmonary changes in, 305
Dolophine®, in cough, 230
Dornase, pancreatic, 895
in cough, 232
Drainage, postural, 598, 612, 620
surgical, 495, 507
Dramamine®, in air-sickness, 937
Drawing, mechanism of, 57–58
Dust, allergy to, 258
Dylefrin®, 894
in emphysema, 357
Dyspnea, in bronchiectasis, 604
in carcinoma, 696
in cardiopulmonary disease, 174
causes of, 225
in metastatic tumors, 748
in pleurisy, 823
in spontaneous pneumothorax, 838

Echinococcus granulosus, 431
Edema, postoperative laryngeal, tracheotomy in, 932
pulmonary, 66, 200–204
etiology, 201–202
and mitral valvular disease, 189
and myocardial infarction, 194
results of studies, 200–201
roentgenology in, 109
symptoms of, 202
treatment of, 203–204
Electrocardiograms, 80
in bronchial asthma, 262
in cardiac arrest, 500
in cardiopulmonary disease, 176, 184–185
pulmonary P wave, 177
in thrombosis, pulmonary, 218
Eliot breathing devices, 360, 894, 900
Ellis S-line in pleurisy, 824
Embolism and infarction, pulmonary, 209–215
and abscess of lung, 609
complications of, 210
differential diagnosis of, 210–211
findings in, 210
postoperative, 456
fat embolism, 456
prevention of, 211–213

Embol sm and nfarct on pul
monary (*contd*)
roentgenology n, 115
s g s of 210
syn ptoms of 209
treatment of 211 213
long term ant co gulant
therapy 2 3 2 5
Embryology of b onch 12 16
of lungs, 1 10
Emerson breathing unit 46 300
Emphysema 0–71 354 3 6
blebs and bullae 641 644 837
See also Cyst c d sease
and bronchiectasis, 602
bronch olectat c. *See* Cyst c d s-
ease
and bronch tis 237
and bronchoconstr ct on 327
cardiopulmonary compl cat ons
181 361
chron c puln onary 354 361
compensatory 70 448 625
reversib l ty of 626
and cough 228 231 233
et ology of 362
fluoroscopy in 126
nterstit al 807
lobar in children 642
management of 355
mediastinal format on of 807
obstructive, 70
n nfancy 636–638
manifestations of *See* Cyst c
disease
physiopathology of 354 355 363
oentgenology in, 113 114
senile 0
subcutaneous, 808
symptoms of 354
treatment 355 36
abdom nal supports 358
antimicrob al agents 357
breathing exercises 358 370
cort cotropl n and cort co
stero ds 357 91
cough remed es 355
ersufflat on 364
manual compress on of chest
370
mechanical resp rat on 360
nerve surgery 472 474
oxygen 359
pneumope toneum 359 373
376
pressure appl cat on 362 372
sympathom met c am nes 357
tranquilize s 355
f om tuberculous foci 543
vesicular 642
Empyema 820–823
n abscess of lung, 6 3
■ coccid o domycos s 420
decort cat on in 847
encysted 860
exc sion of 853 861
Em pyem a (*cont d*)
pl ys c l s gns of 824
pn u nococcal 82
postop erat ve 509 5 3
str ptococcal 82
n tuberculosis pleuropulm nary
resect on n 857 86
See also l leural co d ons
effusions
Endarter t s, c rc n n at us 63
Endob onch al l tl s 242
tuberculosis, 60 8
Endocardit s b t r al n
Endo-hou e dust 298
Endose j v n tun s be gn 672
Endoth l n pleur 833
vascul r 66
Enucleat on n tum b g 674
Eosinophil a d all 263
pulmonary *See* Lo s
dro n
Eosinophil c granul f ul n
changes n 2 2
Eosinotactic f ct r
Ephedr ne, n c ug 23
n emphys m 3 f
in resp ratory 80
Ep nephr nc n br n f h
265
leukocytes a d l f 6
n resp ratory
Ep thel l tun o
Erythema mult f
pulmonary l g 3 2
Erythrocyte p xlu n
Erythromyc n
61
n pneum o 33
Esopl ageal tub
Esopl agog m 32
Esophagoscopy
Exam nat n phy l
Exc s on wedge 458
Exere ses l eath ng 3 8 3 o 6
89
postoper t e 5 6 5 9
Expectorants 229
Expectorat on 224
in bronch al f stulas 246
Exp rat on fluoroscopy n 23
roentg nology n 30
See also Resp rat on
Exp ratory
reserv 25
squ eze 923
Exsufflt on w th neg t v p ssu
904
n emphysema 362 372
Extoxin n cough 23
Extracts, in allergy 254
Extremit es n cardiopulm onary
d s ase 74
Eye test 254

Fat embol sm 456
Fever n bronchol th as s 242
Fever (*contd*)
n carc noma 696
n metastat c tun ors 748
F brillat on ventr cular n surgery
502
F br n balls 819
F br n bod es roentgenology in 109
F brocyst c disease of panc eas
pulmonary changes in 271
F broma 667
F bros s of lungs 68–70
ang ocard ography n 155
bronchial pattern of 68
bronchiectasis and 602
card opulmonary d sease and 185
corticotroph n and cort costero ds
n 913
fluoroscopy n 26
nterst t al pattern of 68
parenchymal pattern of 69
pl ural pattern of 69
n sarco dos s 295
tuberculous foc caus ng 543
vascul r pattern of 69
F b oth ax tuberculous ang o
card ography n 153
F ch princ ple, 3
F la s 2 427
F ssu e of lu g supernumerary 7
F ul s bronch al 246–250
b on hob l ary 249
b nchocel e 249
hoesophageal 247
h l gluteal 250
n l ope neph c 249
l h pleural 246–250
oc l o domycosis, 420
x top at ve 509–513
f n h pulmonary n tuberculo
s s l empyema 859
b o cl osubph enic 248
pl u l children 638–639
pulmon y art r o enous ang o
card ography in 5
esect on n 464
oentgenology in 109
Fla l tho ax 809 8 4
Flap p ocedures 867 869
br nch al adenoma 870
Flu d levels fluo oscopy of 120
Flukes 427 428
Fluoroscopy 78 7 27 38–139
n atelectas s 125
blood ess ls 20
ca t lage calc f cat ons 118
confusing norm al shadows, 118
n cyst c d se se 650
dete led survey 9
d aphragm 21
n emphysema 126
exam nat on 7 23
exp ration 123
n f bros s pulmonary 26
flu d levels, 120
general survey 17
n hemoptys s, 207

Fluoroscopy (contd.)
infiltrations, 120
inspiration, 123
law of circle, 118
localization, 118
lymph nodes, 120
mediastinal shadow, 118
mediastinum, 123
neck, 118
nipple, 118
pathologic conditions, 123–127
in pleural effusion, 126, 826
in pneumonia, intrathoracic, 124
in pneumothorax, 126
positioning, 118
pseudocavity, 121
special problems, 120
spine 118
in subdiaphragmatic abscess, 124
in substernal thyroid 124
in tracheal deviations 123 124
vertebral borders of scapula, 118
visible lesion, 117
Flutter, mediastinal, 494
Foam cells, 350
Foods, allergy to, 253, 258
Foreign bodies, 442–446
ball valve phenomenon, 443
in bronchus, 238
bypass-valve action, 443
check-valve phenomenon, 443
diagnosis of, 443–444
prognosis of, 445–446
removal by bronchoscopy, 96
stop-valve phenomenon, 443
treatment of, 444–445
Formalin injection of hydatid cyst, 440
Fracture, fat embolism after, 456
rib, 816, 929
Friction rub, in pleurisy, 823
Friedländer pneumonia, chemotherapy in, 342
Fungi, allergy to, 253
Fungus disease See Mycoses

Ganglionectomy 466
Gangrene, pulmonary resection in, 461
Gantrisin®, in respiratory infections, 604
Gas transport, 32–35
Gases, in cough, 231
Gastric
contents, as diagnostic aid, 77
cultures, tubercle bacilli in, 81
Gaucher's disease, pulmonary changes in, 271
Gilchrist's disease, 397–399
See also Blastomycosis
Glanders, pulmonary changes in, 307
Glycerylguaiacolate, in cough, 230
Gold, radioactive See Radiogold
Graft, pericardial fat, 863–867
Granuloma, eosinophilic, pulmonary changes in, 272
corticotrophin and corticosteroids in, 912
solitary lesions, 794, 799
Grocco's triangle, 824
Gunshot wounds, 815

Halliburton breathing unit, 46, 900
Hamartochondroma, 678, 679
Hamartoma, 669, 678–685
cystic, 632, 633
differential diagnosis of, 679–680
roentgenology in, 671
solitary lesion in, 795, 800
Hamman's sign, 807
Hand-Schuller Christian disease, pulmonary changes in, 272
Hay fever, seasonal, 251–259
Heart, arrest during pulmonary resection, 498–504
in bronchial asthma, 260
compression of, 501–502
congenital lesions of, 187–188
disease, pulmonary, 173–198
See also Cardiopulmonary disease
failure, congestive, differential diagnosis of, 211
in surgery, 509
Hemangiomas, 678
capillary, 667
resection in, 464
diagnosis of, 671
Hematocrit, in cardiopulmonary disease, 177
Hematologic role of lung, 49–58
Hematology, as diagnostic aid, 75
See also Blood
Hemoglobin, in cardiopulmonary disease, 177
oxyhemoglobin, 32, 40
Hemo-organization, pathogenesis of, 846–847
Hemoptysis, 206–208
in abscess of lung, 613
in arteriovenous aneurysm, pulmonary, 323
in bronchiectasis, 596, 604
in broncholithiasis, 242
bronchoscopy in, 95
in carcinoma, 696
in cardiopulmonary disease, 175
causes of, 206
in coccidioidomycosis, 420
diagnosis of, 207–208
in embolism and infarction, pulmonary, 209
prognosis of, 208
treatment of, 208
in tuberculosis, 520
in upper respiratory tract infection, 224
Hemorrhage, into bronchi, 482
in cystic disease, 648
pulmonary, 206–208
Hemorrhage (contd.)
in surgery, 506
in trauma, 810, 815
in tuberculosis, fatal, 546–553
See also Hemoptysis
Hemosiderosis, pulmonary, 270
Hemothorax, 831, 834
decortication in, 847
See also Hemorrhage
Hering Breuer reflex, 838
Hernia, mediastinal, 329–330
pulmonary, 328–331
See also Cystic disease and Pneumatocele
Hilar node enlargement, in sarcoidosis, 289–292
Histaminase content in lungs, 57
Histamine, content in lungs, 57
leukocyte count after, 52
Histoplasmosis, 401, 408–415
bacteriology in, 410
cutaneous reaction in, 410
pathology of, 411–414
resection in, 464
serologic studies in, 411
symptoms of, 409
History of patient, 73–75
Hodgkin's disease, 755
bronchitic, 755, 757
clinical aspects of, 759
etiology of, 759
histologic findings in, 757–758
lobar, 755, 756
lobular, 755, 756
lung pathology in, 755–757
miliary, 755, 757
nature of disease, 760
nodular, 755, 756
pathogenesis of, 759
treatment of, 759, 767
Honeycomb lungs, 272
See also Cystic disease
Hookworm infection, 427
Hormone therapy See Corticotrophin and corticosteroids
HP acthar gel®, in bronchial asthma, 266
Humidification therapy, 895
Hycodan bitartrate®, in cough, 229
Hydatid
cysts, 430–441
biologic features of, 433–435, 440
daughter cysts, 432, 438
diagnosis of, 435–437, 440
solitary lesion in, 794
symptoms of, 435
treatment of, 437–441
sand, 432
Hydeltra®, 918
in emphysema, 358
Hydryllin®, in cough, 230, 355
Hydrocortisone See Corticotrophin and corticosteroids
Hydrothorax, 831

Hypertension pulmonary roentgenology in 106
Hyperventilation 40
Hypoplasia of lungs, 2 3 9
Hypoventilation 40
Hypoxia carbon dioxide concentration in 43
cardiac arrest and 439
causes of 32

Infarction, myocardial 193 194
pulmonary 190 194 2 9
differential diagnosis of 68 9
roentgenology in 109
solitary lesion in 794
sputum examination in 87
Infected cystic disease 646–647 654, 656
Infectious diseases and pulmonary changes, 300–307
pasteurella infections 3 6
rickettsial diseases 303 3 4
viral diseases 300–303
See also specific diseases
Infiltrations with eosinophils *See* Loeffler's syndrome
Influenza, pulmonary changes in 3 0–301
sputum examination in, 87
Inhalants allergy to 258
trauma from 813
Inhalational therapy 893 9 5
aerosols 894 898
oxygen 897 898
pressure breathing 898–905
See also specific items
Inhalators, oxygen in 44
Insects, allergy to 253
Inspiration fluoroscopy in 123
pressure breathing in 903
See also Pressure breathing
roentgenology in 130
See also Respiration
Inspiratory capacity, 25
Instillations oil 143
in bronchomoniliasis 396
Insufflation mouth-to-mouth, 362
Intermittent positive pressure breathing (IPPB) *See* Pressure breathing
Intubation, endoesophageal 926
Iodides in actinomycosis 406
in bronchial asthma 265
in bronchomoniliasis 396
in cough 355
Iodine radioactive in thyroid cancer 767 773
Ipecac, in cough 230
IPPB (intermittent positive pressure breathing) *See* Pressure breathing
Iridium radioactive 780
Iron lung activity and iron storage 57
oxide saccharated leukocyte count after 53
Isoniazid in tuberculosis, 521
Isuprel® 894
in abscess of lung 620
in bronchial asthma 265
in cough 232
in emphysema 357
in silicosis 387

Jaagsiekte 740

Jaenbock's phenomenon 122
Jaissen pulmonary biopsy 80
Klebsiella pneumonia chemotherapy in 342 343
Knife wounds 815
Koplik's spots 301
Kyphoscoliosis and heart disease 196

Laminagraphy 136
in carcinoma 701
in hamartoma 689
Larvas migrating 426 427
Laryngotracheobronchitis sputum examination in 87
Larynx 17 18
edema postoperative tracheotomy in 932
Leiomyoma 668
Letterer Siwe's disease pulmonary changes in 271
Leukemia pulmonary changes in 269
radiophosphorus therapy in 774
treatment of 771
Leukemic donor infusion of leukocytes from 51
Leukocyte count 49
after anaphylaxis 54
after epinephrine 56
after histamine 52
after injected foreign materials 53
after saccharated iron oxide 53
after tissue extracts 55
after transfusion 50
Leukocytes, removal and release by lung 50–55
Lipiodol® in bronchography 143
in bronchomoniliasis 396
Lipoid pneumonia 346–351
Lipoma 668
Lipophages 350
Lithiasis bronchial 241 245
See also Bronchoolithiasis
endobronchial 242
Liver amebic 424
cirrhosis of and pleural disorders 830
Lobe accessory roentgenology of 139
azygos 8
roentgenology of 139
bronchopulmonary 140
congenitally fused 7
Dever 139 142
Lobe (*contd*)
middle lobe syndrome 243 580
resection in 462
Nelson dorsal lobe 7
Rokitansky lobes 4
Lobectomy 458
in bronchiolar carcinoma 743
extrapleural dissection in 853 855
in hydatid cyst 437 438
in multiple primary cancers 727
in solitary tumors 804
in tumors benign 674
Lobule primary 17
Loeffler's syndrome 262 272 403 827 909 914
corticotrophin and corticosteroids in 914–915
diagnosis of 76
roentgenology in, 110
Louis angle of 18
Lungs abscess of 62 65
circulation gradient 40
genesis of 1 4 149 309 313
anatomy of 1–10 17 23
aplasia 2 309
arterial anomalies 9
arteries 21
See also Arteries pulmonary
atelectasis 65 66
biochemical function 57
biopsy in disseminated disease 89–92
in *blood disorders See Blood diseases with pulmonary changes*
blood supply to 21 22
bronchiectasis 62 65 596–607
See also Bronchiectasis
capacity 25 38 39 178
capillaries and gas exchange with alveoli 29
circulation physiology 49–58
See also Circulation pulmonary
collateral ventilation 22 23 28 34 66 236 627
compliance of 25 39 179
congestion of roentgenology in 106
cystic disease 624 663
See also Cystic disease
cysts 641
developmental anomalies of 1 10
disease secondary to heart disease 187–198
See also Cardiopulmonary diseases
diseases affecting heart 173 185
See also Cardiopulmonary diseases
displacement of bronchi 6
See also Bronchial conditions
edema 66 200–204
See also Edema pulmonary
embryology of 1 10
emphysema 70–71 354–376
See also Emphysema

Lungs (*contd.*)
eparterial bronchus, 5 6
expiratory conditions *See* Expiration
fibrosis of, 68–70
See also Fibrosis of lungs
fissures, supernumerary, 7
function studies, 178, 179
in silicosis 386
hematologic role of, 49–58
histamine content of, 57
honeycomb, 272
See also Cystic disease
hypoplasia of, 2, 309
infarction of *See* Infarction, pulmonary
inspiratory conditions *See* Inspiration
iron storage in, 57
lability of pulmonary vessels, 35
lobe conditions *See* lobe
lobectomy *See* Lobectomy
lobule, primary, 17
megakaryocytes in, 55
musculature of 19–20
nerves of, 20–21
non aeration, acute, 65–66
oxygen transport in, 40–42
platelet production in, 55
pleuropulmonary diseases, 817–861
pneumatocele *See* Pneumatocele
pneumoconiosis, 377–392
pneumomediastinum, diagnostic, 134–135
pneumonectomy *See* Pneumonectomy
pneumonia *See* Pneumonia
pneumonitis *See* Pneumonitis
pneumotherapy *See* Pneumoperitoneum and Pneumothorax
pneumotyphoid syndrome 306
prothrombin decrease in capillaries, 57
removal and release of leukocytes by, 50–55
residual volume, 25, 38
resistance, 25, 179
respiration *See* Respiration
sequestration of, 8–9, 634
supernumerary, 4–5
in systemic diseases, 269–307
transpulmonary pressure, 27
trauma, 806–816
tuberculosis *See* Tuberculosis
vanishing, 160
See also Cystic disease
vascular resistance, 47
venous anomalies, 9
visceral lung function, 628
volume measurements, 25, 37–40, 178
wet lung, 482, 508, 810, 812
Lupus erythematosus, disseminated, 278
Lutembacher's syndrome, 189

Lymph, fluid, and pulmonary edema, 200
nodes, calcified, 241
fluoroscopy of, 120
tuberculosis of, 60
Lymphadenoma, tubercle-like, 833
Lymphatic spread of cancer cells, 747
Lymphocytic choriomeningitis, pulmonary changes in, 303
Lymphoma, 669
malignant *See* Hodgkin's disease
treatment of, 767
Lysholm grid, 132

Madone, in cough, 230
Malaria, 423
Maximal breathing capacity (MBC), 38
Measles, pulmonary changes in, 301
Mediastinal
emphysema, 807
fixation, in carcinoma, 705
fluoroscopy, 118, 123
flutter, 494
hernia, 329–330
roentgenology, 112, 116
shift, anesthesiology in 480
Megakaryocytes in lung, 55
Meigs' syndrome, and pleural disorders, 830
Membrane component, 31
Mesoazygos, 8
Mesodermal tumors, 666–670
Mesothelioma, pleural, 801, 833
Metabolic disorders and pulmonary changes, 271–272
Addison's disease, 271
amyloidosis, 272
diabetes, 271
fibrocystic disease of pancreas, 271
metastatic calcification of lungs, 271
tuberous sclerosis, 272
xanthomatoses, 271, 669
Metabolism needs in respiration, 27
Metacortelone, in bronchial asthma, 265
Metacortin, in bronchial asthma, 265
in hay fever, 257
Metastatic tumors, 746–751
See also Tumors, metastatic
Metazoa, 425–429
blood flukes, 427
long flukes, 428
roundworms, 426
Methadone®, in cough, 230
Methajade®, in cough, 230
Meticorten®, 918
in emphysema, 359
Miliary nodulation, in sarcoidosis, 292–294
Milibis®, in intestinal amebiasis, 425

Mineral oil, and lipoid pneumonia, 346
Mitral valvular disease, 189–190
Molds, allergy to, 253
Monaldi drainage, in cystic disease, 651
Monilia infection of lungs, 394–396
Mononucleosis, infectious, pulmonary changes in, 302
Morphine, in cough, 229
M.S.A. apparatus, 900
Mucoviscidosis, 237
Mueller maneuver, in fluoroscopy, 122, 124
leukocyte count after, 52
in roentgenology, 103, 130, 324
Mumps, pulmonary changes in, 301
Muscles of lungs, 19–20
Mustargen®, in carcinoma, 764
Myasthenia gravis, anesthesia in, 925
Mycoses, 393–422
actinomycosis, 404–406
allergenic, 253
aspergillosis, 402–404
blastomycosis, 397–399
bronchomoniliasis, 394–396
coccidioidomycosis, 399–401, 417–422
cryptococcosis, 397
histoplasmosis, 401, 408–415
mold like fungi, 394
resection in, 463 464
roentgenology in, 108
sporotrichosis, 402
sputum examination in, 87
yeast-like fungi, 394
Mycostatin, in bronchomoniliasis, 396
Myeloma, multiple, pulmonary changes in, 270
Myoblastoma, 668
Myocardial infarction, 193–194

Nadeno double suction technic, 923
Nasal tests, in allergy, 254
Neck, fluoroscopy of, 118
Necrotic foci, subapical, after chemotherapy, 61
Nelson, dorsal lobe of, 7
Nembutal® anesthesia, 607
Neo-cortef®, in emphysema, 357
Neo-penil®, in abscess of lung, 610
Neoplasms, bronchial, 238
cardiac, 195
pleural, 833–836
pulmonary, and lung abscess, 609
resection in, 459
sputum examination in, 87
See also Tumors
Neosynephrine®, in abscess of lung, 620
in cough, 232
in emphysema, 357
in silicosis, 387
Nerve surgery, 466–475, 523

Nerves of lungs, 20–21
Neurogenic tumors, 669
Neuromuscular disorders, anesthesia in 925
Nickerson Kveim cutaneous reaction 288
Niemann Pick's disease, pulmonary changes in 271
Nipple fluoroscopy of 118
Nitrogen mustard in breast cancer 767
in bronchogenic carcinoma 764
in Hodgkin's disease 760 767
Nocardiosis resection in 463
Nodal enlargement hilar in sarcoidosis 289–292
Nodes, lymph 60 120 241
Nodular form of metastatic tumors, 749, 796 798
Nodulation miliary in sarcoidosis, 292 294
Nodules, isolated 783 805
See also Coin lesions
neoplastic, roentgenology of 108
Nonotine® in cough 355
Nose and throat pathology 223 225
allergic rhinitis, 251–259
allergy tests in 254
asthma 225
bronchiectasis 225
cough 223 224
dyspnea and wheeze 225
expectoration 224
fetid odor 224
hemoptysis, 224
rhinobronchitis, 225
sinusitis See Sinusitis

Obesity surgical considerations in 491 927
Obstruction respiratory anesthesia in, 481 483
in children 636–638
Oil aspiration pneumonia 346
Oils in bronchography 143 396
Omentum thoracic, 863
Ophthalmic tests in allergy 254
Oral cavity cancers 728
Orthoxine® in cough 231
Osler Rendu Weber's syndrome 151
Otolaryngology and pulmonary disease 223 225
See also Nose and throat pathology
Overdistention 624
Overinflation 624
Oxygen arterial blood saturation of 41
diffused, 32
therapy 897 898
in bronchiectasis 538
in emphysema 359
in respiratory impairment 891
transport in lung 40–42
Oxygenation effect of 34
Oxyhemoglobin 40
dissociation curve, 32
Oxytetracycline, in abscess of lung 611 620
in pneumonia 339
in tuberculosis 521

Pain in carcinoma 696
in spontaneous pneumothorax 838
Pain ne® aerosols, 894
Pancoast tumor 695 700 714
Pancreas, fibrocystic disease of pulmonary changes in 271
Pancreatic dornase 232 895
Papanicolaou cytology in bronchiolar carcinoma 742 743
Papilloma 665
Paraaminosalicylic acid in pneumonia 340
in tuberculosis 521
Paraffinoma 35
Parahydroxin® in cough 229
Paralysis abductor anesthesia in, 925
adductor anesthesia in 925
of diaphragm fluoroscopy in 122
of phrenic nerve fluoroscopy in 122
in tuberculosis 523
Parasitic diseases, 423 441
hydatid cysts 430–441
metazoa 425 429
protozoa 423 425
Parasympathectomy 466
Pasteurella infections and pulmonary changes 306
glanders, 307
plague 306
pulmonary anthrax 306
syphilis of lung, 307
tularemia 306
Patent ductus arteriosus 188
Pathogenetic concepts, 60–71
Pendelluft phenomenon 488 809
Penicillin in abscess of lung 610 620
in atelectasis 456
in emphysema 357
in pneumonia 339
Pentothal® anesthesia 922
Periarteritis nodosa 274
and asthma 263
Pericardial fat graft 863 867
Pericardits, acute nonspecific 190
chronic constrictive 195
Permanent up ts 896
Pertussis pulmonary changes in 304
Phosphorus radioactive 774 777 778
Photofluorographic survey 164
Phrenic nerve paralysis fluoroscopy in 122
in tuberculosis 523
Physiologic in cough 230
Physiology of lung 17 23 49–58
pathogenetic concepts 60–71
of respiration 24 36
pathologic 37 47
Plague pulmonary changes in 306
Planigraphy 136
Plasmacytoma 668
pulmonary changes in 270
Plastic surgery procedures 869–876, 879–887
See also Bronchoplasty
Platelet production in lung, 55
epinephrine affecting, 56
Pleural conditions anatomy 817
chylothorax 832
decortication 845 851
diseases 817 836
drainage 495 507
effusions in breast cancer 767
in carcinoma 697 765
in cardiopulmonary disease 175
in coccidioidomycosis, 420
fluoroscopy in 126
hemorrhagic 831 834
malignant radioisotope therapy in 774 778
fibrosis 68–70
fistula in children 638–639
hydrothorax 831
inflammatory diseases, 818–823
See also Pleurisy
mechanico-regulatory diseases, 830–833
mesothelomas 801
metastatic lesions 834
neoplasms 833 836
physiology 817
pyopneumothorax in abscess of lung, 613
roentgenology 111
shock 811
spontaneous pneumothorax 420 837 844
See also Pneumothorax
Pleurisy diagnosis of 825
dry 824
exudative See Pleural conditions, effusions
fibrinous, 818
in lung abscess, 64
physical signs of 824
physical signs of 824–825
pulmonary embolism and 210
purulent 820–823
See also Empyema
rheumatic fever and 188
serofibrinous 818–820
physical signs of 824
symptoms of 823 824
treatment of 827–830
Pleuropulmonary diseases, 817–861
resection in 853 861
Plombage thoracoplasty 524, 562–564
extrapleural 563

Pneumatocele, 329–331
cervical, 329
diaphragmatic, 328
in emphysema, 70
etiology of, 329
recognition of, 330
roentgenology in, 114
tension, 635
thoracic, 328
treatment of, 331
See also Cystic disease
Pneumococcal, empyema, 821
pneumonia, chemotherapy in, 341
Pneumoconiosis, 377–392
active, 380
asbestosis, 388 389
atmospheric concentration, 378
beryllosis 390–392
biologic capacity, 378
characteristics of particulate substance, 377
inert, 379
management of, 383
pathogenesis of, 377 382
personal factors, 379
silicosis, 385–388
Pneumomediastinum, diagnostic, 134–135
Pneumonectomy, 458
in abscess of lung 615
in bronchiolar carcinoma, 743
extrapleural dissection in, 853–855
in hemorrhage of bronchiectasis, 604
postoperative complications, 509–513
radical, in carcinoma 715–721
left side, 720–721
right side, 716–720
in multiple primary cancers, 727
in solitary tumors, 804
in tuberculosis, 524
in tumors, benign, 674
Pneumonia, 333–351
chemotherapy in, 336–345
regimen, 338–341
classification of infections, 337
development of, 66
differential diagnosis of, 334
fluoroscopy in, 124
host, 344
identification of organism, 338
Klebsiella, chemotherapy in, 342–343
lipoid, 346–351
aspiration in, 347
resection in, 461
roentgenography in, 347–349
sputum examination in, 347
lung abscess and, 609
mortality rate in, 336–337
myocardial infarction and, 194
pneumococcal, chemotherapy in, 341
Pneumonia (*contd*)
postoperative, prevention of, 227
rheumatic, 188
roentgenology in, 106, 109
sputum examination in, 84–85
tension pneumatoceles and, 635
viral, chemotherapy in, 343–344
Pneumonitis, aspiration, esophagogram in, 133
chronic obstructive, 66–68
differential diagnosis of, 210
radiation, 764
resection in, 462
rheumatic, 284
solitary lesion in, 794, 800
Pneumoperitoneum, diagnostic, 79, 134
in emphysema, 359, 373–376
in respiratory impairment, 891
in tuberculosis, 523, 591–595
Pneumotherapy, in tuberculosis, 591–595
See also Pneumoperitoneum and Pneumothorax
Pneumothorax, anesthesia in, 478
chronic recurrent, nerve surgery in, 471
clinical features of, 838
closed, 808, 837
diagnostic, 79, 133
fluoroscopy in, 126
open, 808, 837
in pleurisy with effusion, 826
spontaneous, 837–844
in coccidioidomycosis, 420
incidence of, 837
treatment of, 838–839, 841–844
aspirations, 839, 841
bedrest, 839, 841
thoracotomy with water seal, 839, 841–844
tension, 638
in trauma, 815
in tuberculosis, 523, 525, 591–595
Pneumotyphoid syndrome, 306
Poisoning, beryllium, 390–392
Poliomyelitis, pulmonary changes in, 303
Pollens, 251–252
Pollinosis, 251–259
Polyarteritis, 263, 274
Polycythemia, pulmonary changes in, 270
Ponmycin, in emphysema, 357
Pontocaine® anesthesia, 144
Postnasal drip, in upper respiratory infection, 223
Postoperative complications, 451–457, 506–514
atelectasis, 451–455
fat embolism, 456
lung abscess, 457
vascular, 455–456
Postural drainage, in abscess of lung, 612, 620
in bronchiectasis, 598
Posture, effects on tuberculosis, 62
Pot-amide®, in emphysema, 358
Potassium iodide, in blastomycosis, 398
in bronchial asthma, 265
in bronchomoniliasis, 396
in cough, 230
Potter-Bucky chest x rays, 132
Predisone®, in bronchial asthma, 265
in hay fever, 257
Prednisolone®, in bronchial asthma, 265
Pressure breathing, 46, 890, 898–905
in air travel, 935
in anesthesiology, 483
continuous, 479, 899
in emphysema, 357, 360, 362–372
intermittent, 899
physiology of, 898–900
in pneumothorax, 478
Pro-banthine®, after vagotomy, 465
Promizole®, in tuberculosis, 556
Prostatic cancer, inoperable, 767
Prostigmine®, in gastrointestinal distention, 344
preoperative, 925
Prothricin®, in abscess of lung, 620
Prothrombin decrease in pulmonary capillaries, 57
Protozoa, 423–425
amebiasis, 424
malaria, 423
toxoplasmosis, 424
Pseudo asthma, 470, 471
Pseudocavity, 121
Pulmonary, conditions *See* Lungs
heart disease *See* Cardiopulmonary diseases
Purinethol, in leukemia, 771
Pyopneumothorax, in abscess of lung, 613
Pyothorax, 820–823
See also Empyema
Pyrazinamide, in tuberculosis, 521
Pyribenzamine®, in hay fever, 257

Q fever, pulmonary changes in, 304
Quadrinal®, in bronchial asthma, 265

Radiation trauma, 813–814
Radiogold, colloid, 778
in pleural effusions, malignant, 774–777
silver-coated, 779
in pleural effusions, 765
precipitate, 779
seeds, 778
Radioiodine, in thyroid cancer, 767, 773
Radioisotopes, diagnostic, 80
therapeutic, 773–780
cesium, 780
cobalt, 779

Radioisotopes, therapeutic (contd.)
colloidal chromic phosphate, 778
colloidal gold, 778
gold seeds, 778
interstitial therapy, 778
intravenous therapy, 779
iridium, 780
in leukemia 774
in malignant pleural effusions, 774–778
telecurie therapy, 779
in thyroid cancer, 773
transbronchial therapy, 779
yttrium, 778
zinc, 779
Radiology See Roentgenology
Radiolucencies, 101–103, 104
cavitary, 103, 113–114
in blebs, 114
in bronchiectasis, 114
in bullae, 114
in lung cysts, 114
in pneumatoceles, 114
linear, 101, 113
in emphysema, 113
lobar, 103, 113
in emphysema, 114, 115
in pulmonary embolism, 115
miliary, 101
peripheral contour, 103, 113
at diaphragm, 116
at mediastinum, 116
at thoracic wall, 115
Radiopacities, 100–101, 102
few streaks or bands, 107
granular, 101, 107
linear, 100, 106
in bronchial secretion accumulations, 107
in dilatation of pulmonary vessels, 106
in inflammatory infiltration 106
in interstitial deposits of substances, 107
in lymphatic neoplastic infiltration, 107
in lymphatic vessel engorgement, 107
lobar, 101, 110
miliary, 101, 107
nodular, 101, 108
cysts, 109
in encapsulated pleural fluid, 109
in fibrin bodies, 109
in Loeffler's syndrome, 110
in mycotic infections 108
in neoplastic nodules 108
in pneumonias, 109
in pulmonary arteriovenous fistula, 109
in pulmonary edema 109
in pulmonary infarct 109
in tuberculoma, 108
Radiopacities (contd.)
peripheral contour 101, 111
at diaphragm, 111
at mediastinum, 112
at thoracic wall 111
submiliary 101 107
Radiophosphorus in leukemia 774
in malignant pleural effusions [illegible]
Radon seeds in bronchogenic carcinoma [illegible]
Rales bronchial 238
Rasmussen's aneurysm in ruptured [illegible]
Rehabilitation after surgery 915
[illegible]
Remnant [illegible] emphysema 35–
Rendu-Osler-Weber disease 151
[illegible]
Resection [illegible] 456–
in abscess [illegible] 619, 621
in [illegible]
in [illegible] tuberculosis
[illegible]
[illegible] tuberculosis
[illegible] 46
[illegible]
[illegible]
[illegible]
[illegible] 46
[illegible]
[illegible]
[illegible] 498–504
[illegible] 504
[illegible]
[illegible] of 498
[illegible] of 498
[illegible] 498
[illegible]
[illegible] fibrillation 502–503
[illegible] cavitary lesions 464
in children [illegible] 581
in bronchiectasis 574
in lung stationary caseous focus 560
in lobar atelectasis 572
in persistent segmental atelectasis [illegible]
in postprimary bronchiectasis 572
in primary cavity 570
in primary tuberculosis 569–574
in coccidioidomycosis 463
in cryptococcosis 464
in cystic disease of lung 463
decortication and 851
extrapleural, 853–855
in fungus infections, 463 464
in gangrene pulmonary, 461
in histoplasmosis 463
Resection (contd.)
in lipoid pneumonia, 461
lobectomy, 458
in metastatic tumors, 461
in middle lobe syndrome, 462
in mucoid impaction of bronchi 462
in neoplasms, 459–461
malignant, 459
non malignant, 461
in nocardiosis, 463
pleuropulmonary, 853 861
pleural considerations in, 855–856
after thoracoplasty failure, 856–857
in tuberculosis with empyema, 857 861
pneumonectomy, 458
in pneumonitis, 462
in sarcoma of lung, 460
segmental, 458
control of pain, 585
indications for, 583
intrapleural suction, 585
intratracheal suction, 585
overdistention of segments, 587
postoperative care, 584
preoperative care, 584
results of, 588
technic of operation, 584
in tumors, benign, 674
in suppurative diseases, 461 462
of trachea and bronchi, 869–876
in trauma to lung 464
in tuberculosis, 462 524 564–567
segmental resection, 582–589
wedge excision, 458, 674
Respiration, 493
A a difference, 31
acid base balance, 44–45
alveolar equation, 30
anesthesia in obstruction, 481–483, 921
arterial-venous differences and flow, 35
artificial, 478
arterial blood during, 43
in cardiac arrest, 501
in newborn 316
carbon dioxide and hydrogen ion concentration 33
carbon dioxide regulation in body, 42–44
circulation, 35–36
collateral ventilation, 22–23, 28, 34 66, 236, 627
compliance of lung 25, 39 179
dead space, 27
diaphragmatic breathing 516, 937
diffusion 29–32
dissolved oxygen 32
exercises, breathing 358, 370, 516, 891
expiration See Expiration
Fick principle, 35

Respiration (*contd*)
fluoroscopy in, 123
gas exchange, 29
gas transport, 32–35
hydrogen ion concentration, 33, 34
hyperventilation, 40
hypoventilation, 40
hypoxia, causes of, 32
impairment of functions, 888–892
control of impairment, 889
prevention of disease, 889
treatment of, 889–892
abdominal belts, 891
artificial cough, 891
breathing exercises, 891
bronchodilators, 890
cortisone, 892
diamox, 892
oxygen therapy, 891
pneumoperitoneum, 891
pressure breathing, 890
inspiration *See* Inspiration
intermittent positive pressure breathing (IPPB), 41, 46
See also Pressure breathing
lability of pulmonary vessels, 35
leukocyte levels in, 52
maintenance in anesthesia, 478–483
maneuvers in, Mueller, 52, 103, 122 124, 130, 324
Valsalva, 18, 52, 103, 120, 124, 130, 324
maximal breathing capacity (MBC), 25, 38, 178
measurements during air flow, 27, 45–46
measurements of lung volume, 37–40
membrane component, 31
metabolic cost of breathing, 27
minute ventilation, 45
non-aeration, acute, 65–66
oxygen transport, 40–42
oxygenation, effect of, 34
oxyhemoglobin dissociation and association, 32
paradoxic, 480
partial oxygen pressure in alveolar air, 29
pathologic physiology, 37–47
physiology, 24–36
poor oxygenation, effect of, 34
pressure breathing *See* Pressure breathing
pulmonary vascular resistance, 47
regulation of ventilation, 34
residual air capacity, 38
respiratory pump, 24
saturation vs. pressure, 33
static measurements, 24
stiffening of lung, 25, 179
systemic and pulmonic circuit differences, 35
tissue requirements, 35

Respiration (*contd*)
total lung capacity (TLC), 39
transpulmonary pressures, 24
venous admixture, 31
and oxygenation level, 33
component, 29
ventilation factor (V F), 39
vital capacity, 37
Respirators, 479
in emphysema, 360
Respiratory tract, upper, and pulmonary disease, 223–225
See also Nose and throat pathology
Respirometer, 37
Resuscitation, in newborn, 316
Resuscitators, oxygen in, 44
Rheumatic fever, 188–189, 284
and pleurisy, 188
and pneumonia, 188
pneumonitis, 284
Rheumatoid arthritis, 284
Rhinitis, allergic, 251–259
diagnosis of, 253–254
etiology of, 251–253
perennial, 257–259
prognosis of, 257
treatment of, 255–257
co seasonal, 256
perennial, 256
preseasonal, 255
symptomatic, 257
vasomotor, 257 259
Rhonchus, 238
Rib fractures, 816, 929
Rickettsial diseases, 303–304
Q fever, 304
scrub typhus, 304
typhus fever, 303
Riley technic, 29, 31
Robitussin®, in cough, 230
Roentgenology, 99–171
in abscess of lung, 620
in agenesis of lung, 310
angiocardiography, 80, 138, 147–161
See also Angiocardiography
apical lordotic chest x ray, 131
in arteriovenous aneurysm, pulmonary, 323
in asbestosis, 388
in atelectasis, 449, 451
of newborn, 315
barium enema, 133
barium swallow, 132–133
in beryllosis, 390
in breast cancer, 767
in bronchial asthma, 261
in bronchial fistula, 248
in bronchiectasis, 597, 603
in bronchiolar carcinoma, 742
bronchography, 79, 136–138, 143–146
See also Bronchography
in broncholithiasis, 243
in calcification, 108

Roentgenology (*contd*)
in carcinoma, 699–702, 703–704
preclinical, 686
in cardiopulmonary disease, 176, 183
in coin lesions, 783, 793, 797, 803
conventional chest x ray, 128
in cough, 232
in cystic disease, 649, 655
in detection of lesions, 164–166
diagnostic, 77, 163–164
differential diagnosis problems, 99–116
dual reading, 168–170
errors in, 163
esophagograms, 132
evaluation of change, 167–168
evolution of finding, 103–106
expiration chest x rays, 130
findings, 100–106
fluoroscopy, 78, 117–127, 138–139
See also Fluoroscopy
gastrointestinal series, 133
general considerations, 163
grid filtered chest x rays, 132
in hamartoma, 671, 679
in hemoptysis, 207
in Hodgkin's disease, 759, 767
in influenza, 301
inspiration chest x rays, 130
interpretation of, 163
in intralobar bronchopulmonary sequestration, 657
laminagraphy, 136, 680, 701
lateral chest x rays, 129
in lipoid pneumonia, 347–349
localization of segments, 139–142
lordotic chest x ray, 131
in lupus erythematosus, disseminated, 278
in measles, 301
Mueller maneuver, 52, 103, 122, 124, 130, 324
in multiple primary cancers, 725
oblique chest x-rays, 132
in periarteritis nodosa, 274
planigraphy, 136
in pleurisy with effusion, 826
pneumomediastinum, diagnostic, 134–135
in pneumonocele, 330–331
pneumoperitoneum, diagnostic, 134
pneumothorax, diagnostic, 133
in pulmonary embolism, 210
radiolucencies, 101–103, 104 113
See also Radiolucencies
radiopacities, 100–101, 102
See also Radiopacities
reliability of, 163–171
sectional radiography, 136
serial roentgenograms, 167–168
dual reading, 170
shadows, 99, 166
in silicosis, 385

Roentgenology (contd)
spatial relationship changes in 103 105
special techn cs 103
stereoscopy cl est x rays 128
stratigraphy 136
technics of 128–142
n tensio i disorders of childhood 632–639
in thrombos s, pulmonary 217
tomography 129 136
in tumors ben gn 671–672
Valsalva maneuver 18 52 103 120 124 130 324
Rol tansky lobes 4
Rom lar hydrobrom de* in cough, 229
Rupture, of pulmonary cysts 647
of Rasmussen s aneurysm 553

Salmonellos s, pulmonary cl anges in 302
Sarco dosis 287 299
bronchopneumonic nf itrations 294
diagnos s of 287 289
early stage of 289–294
hilar node enlargement in 289–292
late f brot c stage of 295 297
miliary nodulat on in 292 294
N cherson K tum cutaneous reac tion in 288
pat ent mater al 288
scalenus fat pad biopsy in 288
stages of 289–297
transitional stage of 294
treatment of 297 299
Sarcoma 752–754
carc nosarcoma, 754
resection in, 460
solitary les ons in 798
Scalenus fat pad b opsy in sar co dosis 288
Scapula vertebral borders of flu oroscopy of 118
Scarlet fever pulmonary changes in 304
Schistosomias s, 427
Scleroderma 282
Sclerosis tuberous, pulmonary changes in 272
Scol ces 432
Scratch test n allergy 253
Secret ons examination of 691–693
Sedimentation rate diagnost c 77
Selye alarm reaction 908
Sequestrat on bronchopulmonary 8–9 634 657–663
Serpas l* in hypertension 266
Shadows, in roentgenology 99 166
Shock pleural 811
pulmonary embol sm and 210
t ssues, 251
S deros s 387
Silicosis 385 388
diagnosis of 385 387
pathogenes s of 380
prevention of 387
treatment of 387–388
tuberculosis and 382 388
Silver-coated rad ogold 779
Sinobronchitis 225
Sinusitis 223
and bronch al asthma 259 264
and bronch t s 238
chronic 226
Skin t sts as d agnosis 77
n allergy 253
in pleur sy w th effusio 827
in sol tary tumors 794
Smallpox pulmonary cl anges in 302
Smoking dur ng a r travel 937
Spasmalg n* n en bolism 212
Sp ne fluoroscopy of 118
Spirogram trac ngs, 37
Splee activ ty of 57
Spor trichos s 402
Sputum exam nat on 6–7* 81 8 691–693
in abscess of lung 8, 618
in allerg c bronchial d sease 86
in bronch ectas s 86 603
in bronch t s 85-86
in broncho nonilias s 39,
in carc noma 704 725–726
in cyst of lung 87
in fungus infect on 87
in hemoptysis 207
in infarct on 87
in influenza 87
n lipo d pneumonia, 347
in neoplasm 87
in nontuberculous infect ons 84 87
in pleurisy with effus on 827
in pneumonia 84–85 334
in sil cosis 386
in tuberculosis, 81 521
mportance of pos tive cultures 82 84
Stab wounds 8 5
Status asthmat cus 267 268
cort costero ds in 910
cortcotroph n in 909
Stenosis bronchial in childhood 574
surgery n 875 883
mitral differential d agnosis of 211
pulmonary d sease and 189
pulmonary and cardiac disorders 187
and congestive heart failure 189
tracheal bronchoscopy in 96
tracheotomy in 933
Sternal traction in atelectas s of newborn 317–320
Stilbam d ne in blastomycos s 398
Stratigraphy 136
Streptococcal e npyema 821
Streptodornase 89,
Streptoduoc n in tuberculosis 521
Streptomyc n i abscess of lung, 611
in emphysema 357
in pneumon a 340
in tuberculos s, 521
Stridor bronchoscopy in 9,
Stroke volume calculations 900
Strongyloid asis 426
Sulfonamides, in abscess of lung 610
Supports, abdominal n emphy sema 358
Surgery 458–519
in abscess of lung 613 617 623
anesthes ology in 477 485
anterior approach in 486
ant b ot c therapy in, 496
autonom ic nerve surgery 466–475
of bronch and trachea 863 877
in bronch ectas s 598
bronchoplast c procedures 869–876 879–887
bronchoto my 673 867 869 874 875
in carcinoma 698 712–721
cavernostomy 524 564
closure of div ded bronchus 864 866
in cocc dio domycosis 417 422
in co n lesions 803–805
compl cations after 451 457 506–514
air leaks 507
atelectas s 508
bronchopleural f stula 509–513
cardiac failure 509
chest wall pain 513
empyema 509–513
hemorrhage 506
in cough from infections, 227
decort cat on 845–851
dra nage 495 507
exposure, 495
flap procedures 867 869
fluid administration in 496
in hydat d cyst, 437
improv ng vent lation and circu lation 491
lateral pos t on 487
med astinal movements 494
obese patients 491 927
open thorax procedures 493 497
per card al fat graft 863 867
pleuropulmonary resect on 853–86
plombage thoracoplasty 562 564
extrapleural 563
positions and approaches 486–491
posterolateral approach 487–489
rehabil tat on 515 5 9

Surgery (*contd*)
resection, 458 465, 564–567
segmental, 582–589
See also Resection
supine position, 486
suspended prone position, 488–490
apparatus for, 489
complications with, 490
sympathectomy, 466
thoracoplasty *See* Thoracoplasty
thoracotomy *See* Thoracotomy, exploratory
tracheotomy, 928–934
in tuberculosis, 558–567
vagotomy, 466, 469
ventilation considerations, 493
Sympathectomy, 466
Syncope, tussive, 227
Syphilis, cardiovascular, pulmonary complications of, 192–193
pulmonary, 307
Systemic diseases and pulmonary changes, 269–307
bacterial diseases, 304–306
blood disorders, 269–271
collagen diseases, 273–286
infectious diseases, 300–307
metabolic disorders, 271–272
sarcoidosis, 287–299

Tapeworm disease, 430
Tedral®, in bronchial asthma, 265
Telangiectasis, resection in, 464
Telecurie therapy, 779
Tension disorders, pulmonary *See* Cystic disease
Teratoma, 670
Terpin hydrate, in cough, 230
Terramycin®, in abscess of lung, 611, 630
in pneumonia, 339
in tuberculosis, 521
Tests in diagnosis, 77
in allergy, 253, 254
in histoplasmosis, 410
in hydatid cysts, 435, 440
skin tests. *See* Skin tests
tuberculin, 520
Tetracycline, in abscess of lung, 611
Tetracyn®, in abscess of lung, 611
in emphysema, 357
Thephorin®, in hay fever, 257
Thoracentesis, diagnostic, 78, 828, 834
traumatic, 828
Thoracic
pain, postoperative, 513
wall, roentgenology of, 111, 115
Thoracoplasty, conventional, 560–561
decortication with, 851
failure of, pleuropulmonary resection after, 856–857
plombage, 562–563
extrapleural, 563
Thoracoplasty (*contd*)
in tuberculosis, 523
Thoracoscopy, 79, 523
Thoracotomy, exploratory, 80
in carcinoma, 709–710
in coin lesions, 783
in hemoptysis, 208
in multiple primary cancers, 726
in solitary tumors, 805
tracheotomy after, 933
with water-seal, in spontaneous pneumothorax, 839, 841–844
Thorazine®, *in* emphysema, 355
Throat and nose pathology, 223–225
See also Nose and throat pathology
Thrombosis of pulmonary arteries, 217–222
diagnosis of, 217–218
incidence of, 217
pathogenesis of, 217
postoperative, 455
symptoms of, 217
Thymol, *in* actinomycosis, 406
Thyroid, cancer of, inoperable, 767
radioiodine therapy in, 773
substernal, fluoroscopy, 124
Tissue extracts effects of, 55
Tomography, 129, 136
Tonsils, infected and cough, 224
Torulosis, 397, 464
Toryn®, in cough, 229
Toxoplasmosis, 424
Trachea, fluoroscopy in disorders of, 124
surgery of 863 877
See also Bronchoplasty
Tracheobronchial
tree, 18–19
development of, 2, 3
vomiting, 20
Tracheobronchitis, in children, 239
Tracheomalacia, fluoroscopy in, 124
Tracheotomy, 928–934
after thoracotomy, 933
non-obstructive, 308
in postoperative laryngeal edema, 932
prophylactic, 933
technic of, 933
in tracheal compression, 933
Traction, sternal, in atelectasis of newborn, 317–320
Transfusions, leukemic donors in, 51
leukocyte removal after, 50
Transplants, lobar, in bronchial adenoma, 871
Trauma, and abscess of lung, 609
blast injury, 811–812
bronchial, surgery in, 875, 880–883
burns, 812–813
crushing injuries, 814–815
Trauma, crushing injuries (*contd*)
tracheotomy in, 929–932
hemothorax, 810, 813
inhalation, 813
laryngeal, tracheotomy in, 932
and mediastinal emphysema, 807
non penetrating injuries, 811–815
pathology of, 806–811
penetrating wounds, 815–816
pneumothorax, 815
pulmonary, 806–816
resection in, 464
radiation, 813–814
rib fractures, 816, 929
tension pneumothorax, 808
from thoracentesis, 828
tracheal, surgery in, 875
tracheotomy in, 928
Trichinosis, 427
Trichylene, in breast cancer, 767
in bronchogenic carcinoma, 765
in Hodgkin's disease, 760, 769
Trisocort®, in emphysema, 357
Tryptar®, instillation before aspiration, 195, 830
Tubercle bacilli, in gastric cultures, 81
in sputum, 81
Tubercles, epithelioid cell, in sarcoidosis, 287
Tuberculin
reaction, 251
test, 520
Tuberculoma, 414
differential diagnosis of, 679
roentgenology in, 108
Tuberculosis, 60–62, 520–595
in adolescent, 574–580
angiocardiography in, 153
bacteriology during chemotherapy in, 527–529
bronchography in, 143
cavities in, 537–542
after chemotherapy, 538–5
healing of, 537–538
progression of, 537
in children, 534–537
resection in, 568–581
diagnosis of, 520–521
drug resistance in, 529
duration of chemotherapy in, 531–532
efficacy of chemotherapy in, 530–531
emphysema and, 543
pleuropulmonary resection in, 857–861
endobronchial, 60
plastic surgery in, 875
fatal hemorrhage in, 546–551
fibrosis and, 543
lymph nodes in, 60
morphologic changes in, 526
necrotic foci after chemotherapy in, 61, 542
pathology of, 582

Tuberculosis (contd.)
perifocal reaction in 526
physiopathology of 582
pneumotherapy in 591 595
resection in 462
segmental 582 589
sectional radiography in 136
silicosis and 382 388
surgery in 558–567
cavernostomy 524 564
collapse therapy 523 560–561
contraindications to 559
decortication 524 848–849
extrapleural pneumothorax 525
plombage thoracoplasty 562 564
postoperative care in 567
preoperative evaluation 559
resection 524 564 567
in children, 568 581
tracheobronchial bronchoscopy *in* 94 96
treatment of 521 525
chemotherapy 526–534 538–542
isoniazid 521
oxytetracycline 521
para aminosalicylic acid, 521
pyrazinamide 521
rest therapy 522
streptomycin 521
surgery and chemotherapy 532
viomycin 521
virulence of bacilli after therapy 529–530
Tularemia pulmonary changes in 306
Tumors 664–780
adenocarcinoma 695 804, 872
adenoma bronchial *See Adenoma bronchial*
pulmonary 665 732
alveolar cell 735
resection in 460
benign 664–674
endoscopy in 672
location of 670
pathology of 665–670
roentgenology in 671–672
solitary 794
symptoms of 670–671
treatment of 673–674
bronchoscopy 673
bronchotomy 673
enucleation 674
lobectomy 674
pneumonectomy 674
segmental resection, 674
wedge resection 674
bronchial, *surgery in* 869, 872, 883
bronchiolar *carcinoma* 735–745
carcinoma 694–698
inoperable 761–772
preclinical 686–690
See also Carcinoma
Tumors (contd.)
in childhood 771
chondroma 667 678
cytology in 691–693
of developmental origin 669
endothelioma 667 833
epithelial 665–666
fibroma 667
hamartoma 669 678–685
See also Hamartoma
of heart 195
hemangioma 464 667 671 678
inoperable cancer treatment of 761 772
intrabronchial 667
leiomyoma 668
lipoma 668
lymphoma 669 767
lymphomatoid lesions *See* Hodgkin's disease
mesodermal 666–669
metastatic 746–751
aspiratory spread 747
bronchiolar carcinoma 743
and calcification of lungs 271
carcinoma 695
diagnosis of 725 727
differential diagnosis of 680
inoperable 65 766
sites of 695
solitary metastases 729
cardiac 195
coelomic spread 747
diagnosis of 747 754
differential diagnosis of 750
direct extension into lungs 747
extrapleural resection in 854
frequency of 46
inoperable 65–766
invasion of blood stream 747
lymphangitic form 749
lymphatic spread 747
miliary form 749
nodular form 749 796 798
pathogenesis of 746–747
of pleura 834
pneumonic pattern 749
resection in 461
solitary nodules in 796, 798
treatment of 750–751
multiple primary cancers 722 733
myoblastoma 668
neoplasms *See* Neoplasms
neurogenic 669
papilloma, 665
peripheral 669
plasmacytoma 668
of pleura 833 836
radioisotopes in *See* Radioisotopes
sarcoma 460 752–754 798
solitary 783 805
See also Coin lesions
teratoma 670
of trachea surgery in 869 872
Tumors (contd.)
vascular 666
cavernous, 666
xanthoma 271 669
Tussal insufficiency 227
Tussive syncope 227
Typhoid fever pulmonary changes in 305
Typhus fever pulmonary changes *in* 303
Tyrothricin in abscess of lung 620

Urine examination as diagnostic aid 76
Urokon sodium® in angiocardiography 147

Vaccine therapy in blastomycosis, 399
Vagotomy 466
in bronchial asthma 469
in bronchospasm 469
Vagovagal reflex and cardiac arrest 499
Valley fever 400
Valsalva maneuver 18
in fluoroscopy 120 124
leukocyte count after 52
in roentgenology 103 130 324
Valvular disease mitral 189 190
Vaponefrin® 894
in abscess of lung 620
in bronchial asthma 265
in cough 232
in emphysema 357
Varidase® in empyema 613 830
Vascular conditions *cavernous* resection in 464
fluoroscopy of 120
as postoperative complications 455–456
ring anomalies, 187
solitary 793
tumors 666
Vasocort® in emphysema 357
Veins azygos lobe of 8 139
bronchial 22
carbon dioxide content of in disease 178
pulmonary anomalies of 9
angiocardiograms in 150–151
Vena caval syndrome angiocardiography in 155
Venous pressure *diagnostic* 80
in cardiopulmonary disease, 176
Ventilatory unit 900 904
Ventilation *See* Respiration
Vesicular emphysema 642
Viomycin in tuberculosis 521
Viral diseases and pulmonary changes 235 300–303
chicken pox 302
erythema multiforme exudativum 302
infectious mononucleosis, 302

Viral diseases and pulmonary changes (*contd.*)
influenza, 300–301
lymphocytic choriomeningitis 303
measles, 301
mumps, 301
pneumonia, chemotherapy in 343–344
poliomyelitis, 303
smallpox, 302
Visceral lung function, 629
Vital capacity measurement, 37
Vomiting, tracheobronchial, 20

Weber-Rendu-Osler's disease, 151
Wedge excision, 458, 674
Weinberg test in hydatid cyst, 435, 440
Wheezing, in bronchitis, 238
bronchoscopy in, 95
in carcinoma, 696
Wheezing (*contd.*)
causes of, 225
Worms, infection with, 426–429

Xanthoma, 271, 669
X-rays. *See* Roentgenology

Yttrium-90, colloidal, 778

Zepiran chloride®, in *bronchomoniliasis*, 396
Zinc, radioactive, 779